

Institute of Microbiology shows:

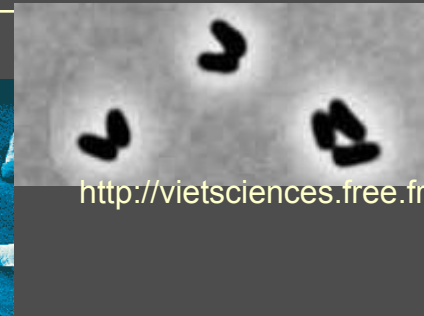

TRACING THE CRIMINAL

Part three: More G+ criminals

Survey of G+ bacteria

Story	Shape	In police evidence written as
P01	Medically important Cocci	Staphylococci (<i>S. aureus</i> , CONS)
P02		Streptococci (viridating, haemolytical)
1.		Enterococci (<i>E. faecalis</i> , <i>E. faecium</i>)
2.	Medically important Rods	Listeriae (<i>L. monocytogenes</i>)
3.		Corynebacteria http://web.fccj.org
4.		Bacilli



Listeriae a coryneforms do not sporulate, unlike *Bacilli*

Contents

Clinical characteristics – enterococci

Clinical characteristics – G+ rods

Enterococci and G+ rods: therapy

Diagnostics of enterococci and G+ rods (+ pictures)

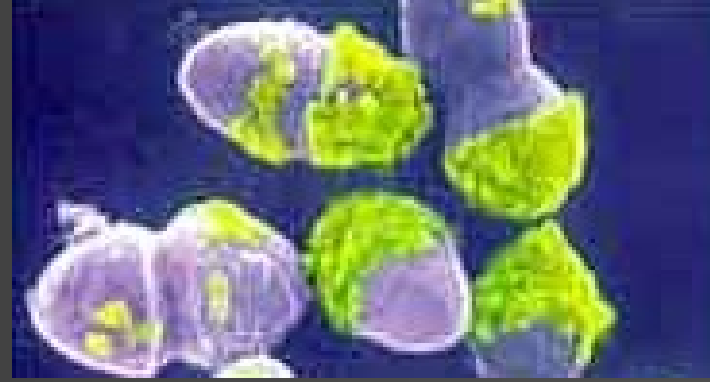
Differential diagnostics of enterococci and G+ rods

Clinical characteristics - enterococci

Story 1

- Lucy has problems with urination. Doctor prescribed Zinnat, but problems did not change. On the next visit, he let Lucy to urinate in a glass and sent her urine sample to microbiology. But the specimen could not be examined: urine was contaminated. Finally, it was possible to take urine aseptically and to change the therapy.


Criminal No 1



<http://www.lbl.gov>

- *Enterococcus faecalis*
- As the „entero-“ in his name tells us, it is a bug **normally present in the intestine**. Nevertheless, it is also a **common UTI pathogen**.
- The doctor is guilty, too – prescribed antibiotics before knowing microbial susceptibility. **Enterococci are resistant to all cephalosporin atb**. And he did not perform aseptic urine sampling in the first phase.
- *UTI (urinary tract infections) are mostly bacterial, and many pathogens are primarily or secondarily resistant to some atb-s. So bacteriological examination of urine is recommended, although often not done in practice.*

More about enterococci



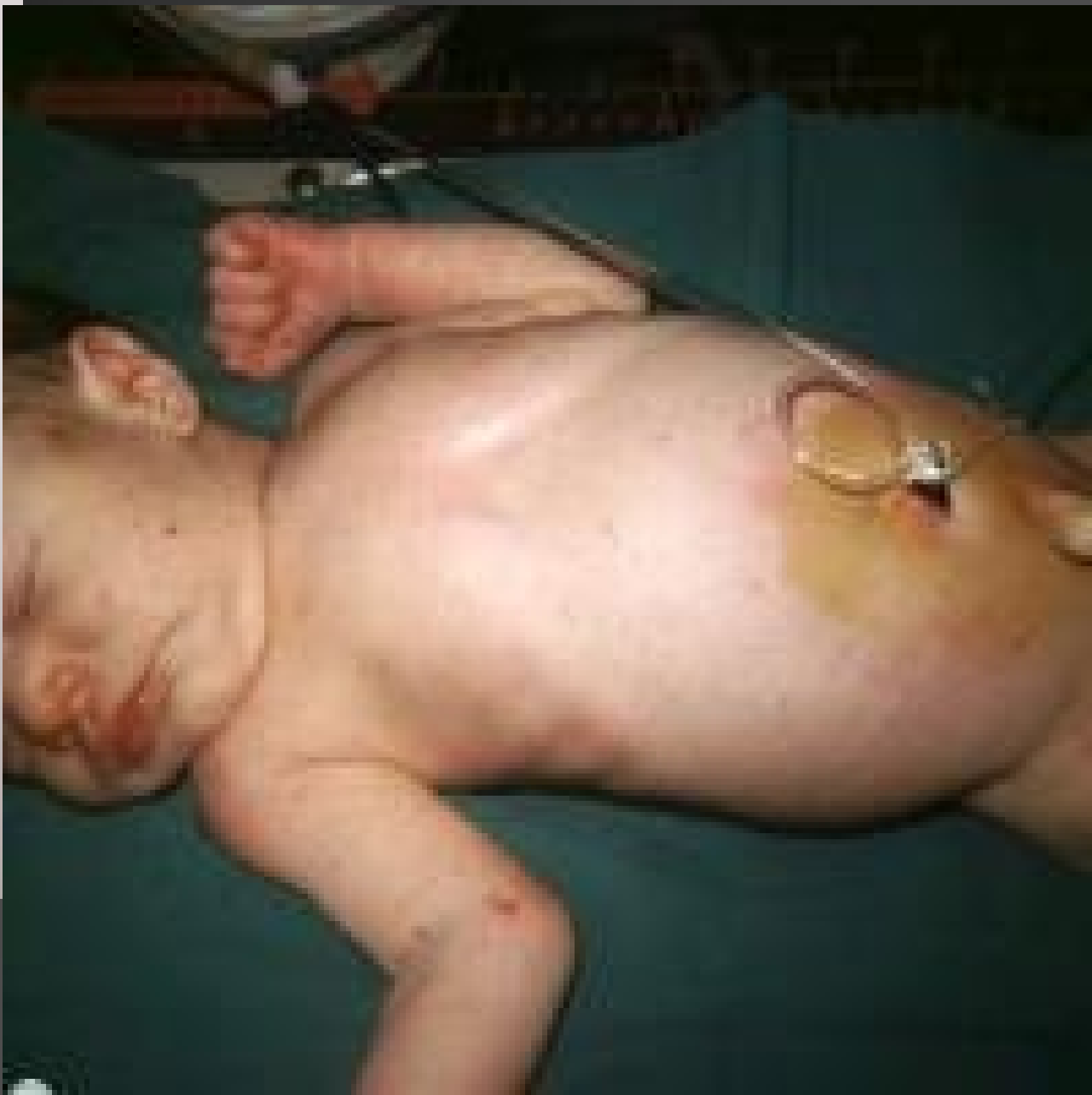- There are **tens of species** of them today
- All of them may be found
 - **in stool** (as a normal flora)
 - in the **urinary bladder** (as pathogen)
 - in the **vagina** (both symptomatically and asymptotically)
 - sometimes in **other sites** (wounds, bloodstream)
- Among two most common species, *E. faecalis* is slightly more often a pathogen, *E. faecium* is more often part of normal intestinal flora
- **Vancomycin-resistant enterococci (VRE)** are dangerous
- One of Enterococci, found in Brno, is named *Enterococcus moraviensis*

Clinical
characteristics —
G+ rods

Story 2

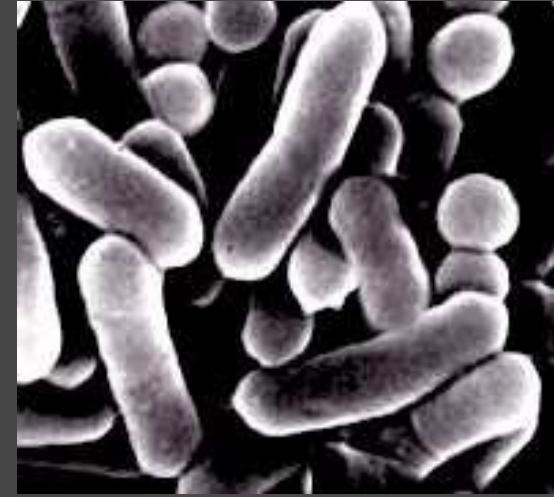
- European commission had to solve one more problem. French agriculturiers protested againsts several EU-members, that do not want to import some **delicatess French cheese specialities** to their area.
- German officials stated, that one pregnant woman, Mrs. Hildegarda Messerschmidt, after having eaten the cheese had **enlarged lypmphonodes** and after delivery, her baby suffered **newborn meningitis**

<http://www.leighday.co.uk>



<http://womansday.ninemsn.com.au>

Criminal No 2



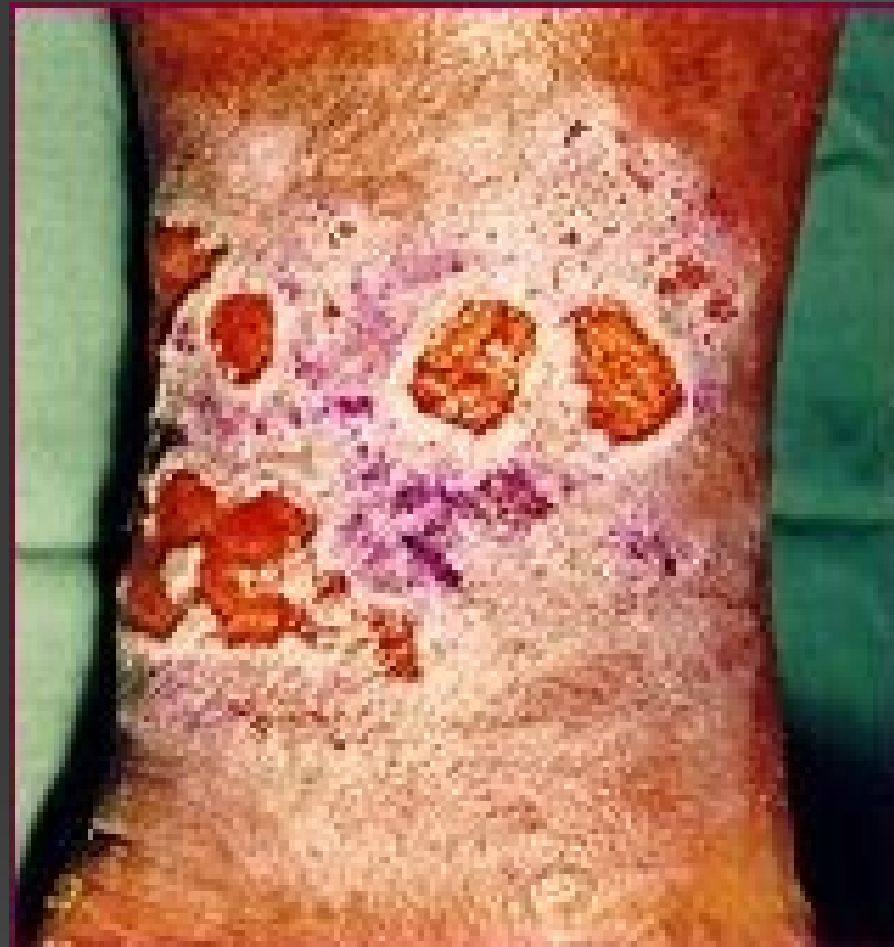- *Listeria monocytogenes* is a G + rod, able to grow at low temperatures and high NaCl concentrations
- Adult infections are rare, except lymphonode syndrom. Nevertheless, it is dangerous for pregnant, or rather for their future children
- In newborns, septicaemia, pneumonia and meningitis is typical.
- As it is rare, is it hardly a reason for true closing borders for camions. Nevertheless, of course, always a momentary situation is to be judged.

Classification des aliments selon le risque lié à *Listeria monocytogenes*

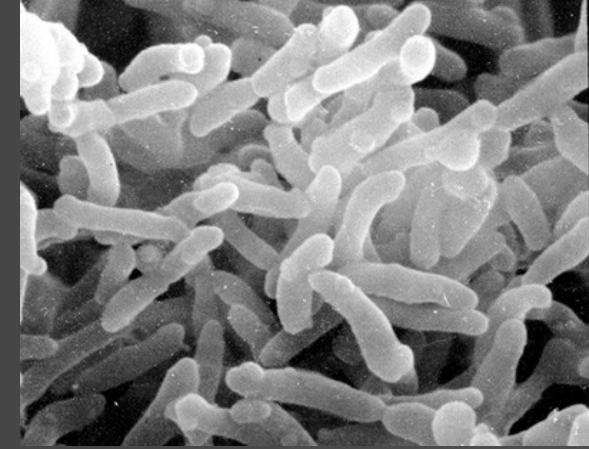


<http://www.territoire-belfort.gouv.fr>

Stroy 3



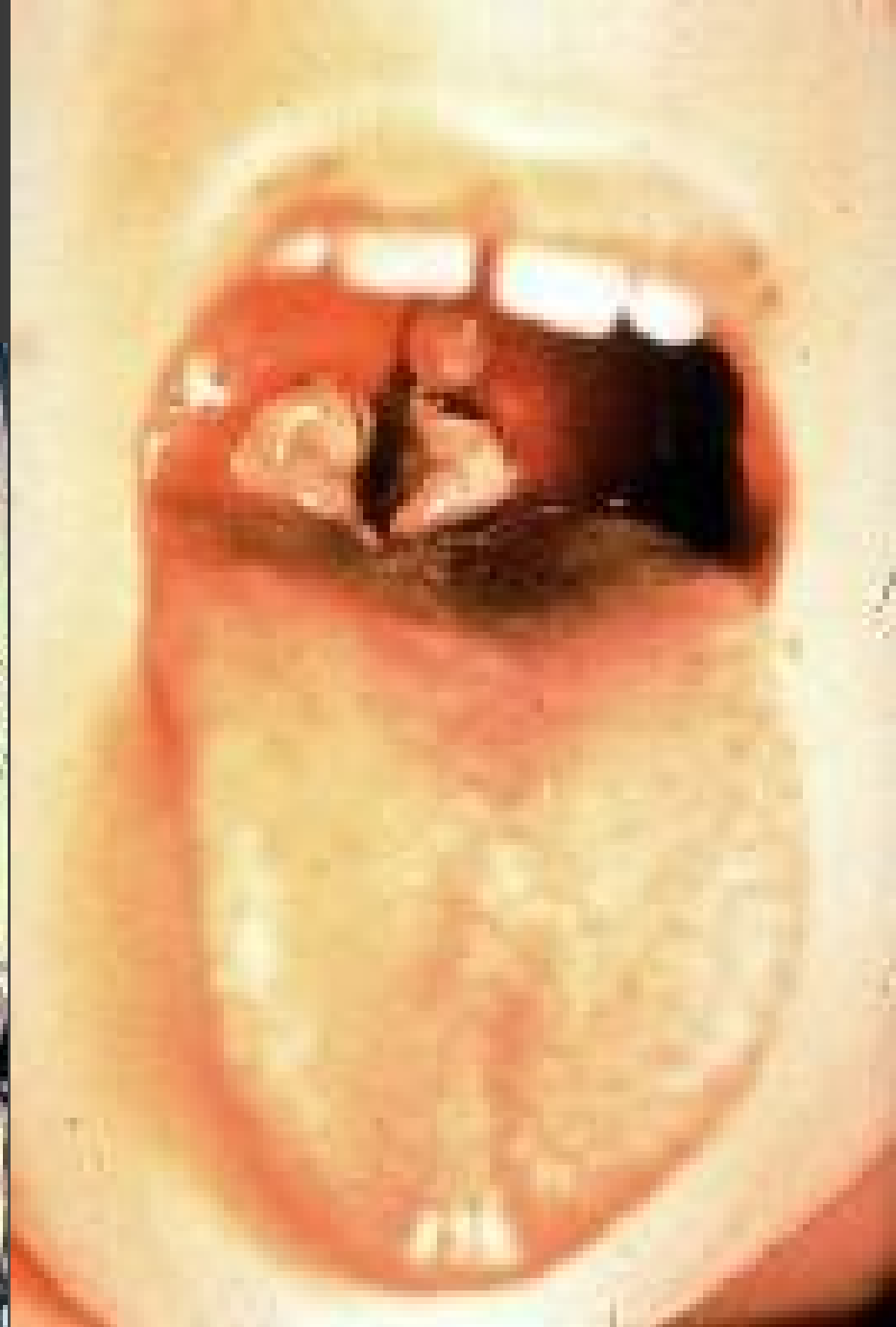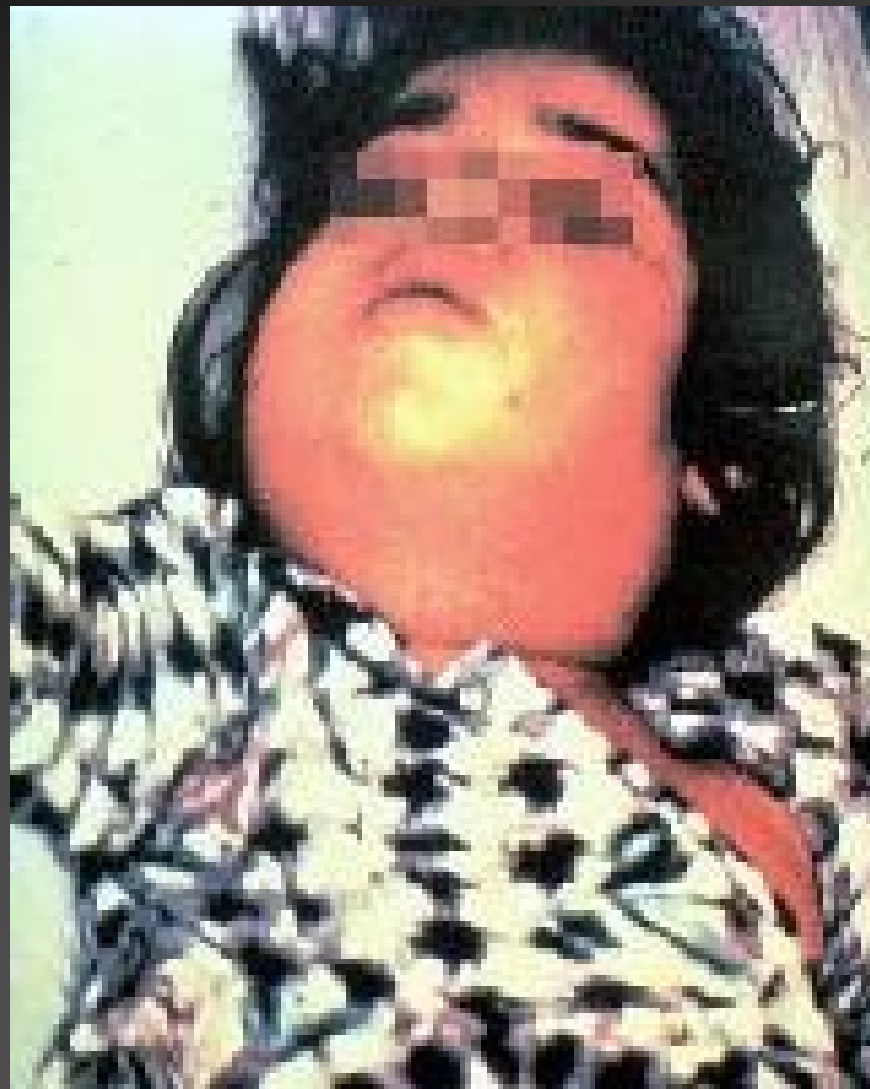- **Mr. Ulcerous**, chronic diabetic, treated for **ulcerations on his legs**. He is often infected by various pathogens. What will be the newest one?



Criminal No 3

- *Corynebacterium jejkeium*, the worst among non-diphtheria coryneforms. Its name is derived from „corynebakterium group JK“.
- Corynebacteria are grampositive rods club-shaped (*koryné* = club), sometimes pleomorphic.
- In the same genus, we have also diphtheria causative agent, rare in Europe, because of vaccination – *C. diphtheriae*.

Diphtheria



More about non-diphtherical corynebacteria

- Part of **normal flora of skin**, together with staphylococci and yeast. Pathogens in wounds
- In microscopy, they form „**palisades**“ – like the early medieval wooden fortifications



What are „coryneform rods“

- „Coryneform rods“ (eventually „diphtheroids“) are various rods that share similar morphology (although size of rods may vary considerably).
 - All of them are rare causative agents of various human infections.
 - *Arcanobacterium haemolyticum* is a rare causative agent of pharyngitis
 - Other genera: *Dermatophilus*, *Rhodococcus*^{*}, *Turicella* etc.
- Rhodococcus jostii* was found on the body of the Moravian Marques and uncrowned Roman Emperor Jodocus (Jošt), that died 1411. The body is buried in St. Thomas church in Brno.

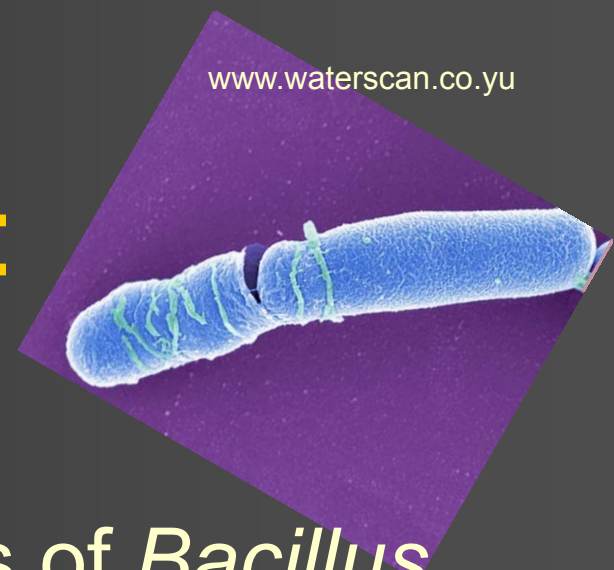
Story 4



www.dahlhausen.cz

- Nurse Eileen was shocked: microbiology examination of ward furniture, week ago taken by hospital epidemiologists, showed some **BACILLI!** Yes, it is here – *Bacillus* sp. Eileen was worrying all the night about it. In the morning, she asked microbiologists...

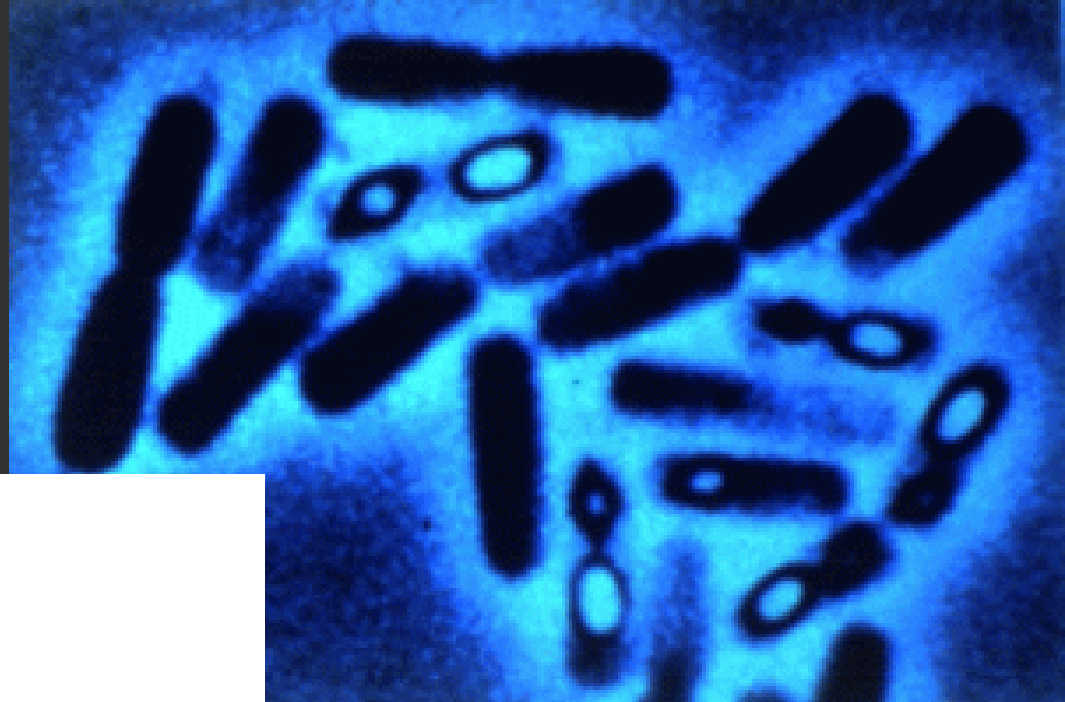
And she was very glad:




- it is no criminal! Usual members of *Bacillus* genus are **harmless microbes from external environment**. When found in clinical material, it is usually a contamination. So, the finding was not a problem – problem would be only when a *Bacillus* would be found from a site that is supposed to be sterile.

But some Bacilli are important

- *Bacillus anthracis* was popularized by Mr. Osama & Co.
- *Bacillus cereus* is causative agent of intoxications coming from cereals (one Swiss let a remaining spaghetti outside fridge, then he decided to eat it, and then he died)
- *Bacillus stearothermophilus* & *Bacillus subtilis* are able to survive hot temperatures → we use them as control organisms for hot air and steam sterilisers.



www.cropsoil.uga.edu




<http://membres.lycos.fr>

Enterococci and
G+ rods:
therapy

Therapy of infections caused by enterococci and G+ rods

- No cephalosporins to fight enterococci and listeriae! In *E. faecalis*, ampicillin, is good, but in *E. faecium* there is a primary resistance. More atb's are co-trimoxazol, doxycyklin, and, as a reserve, vankomycin. In haematooncological patients we can find epidemiologically serious vancomycin resistant strains – VRE. In such strains, only a new atb – linezolid – is effective

Antibiotics used for enterococci and G+ rods




- Enterococci are tested on MH. G+ rods are tested on MH + red blood cells.

Antibiotic	Abbr.	Reference zone
Ampicilin (aminopenicilin)	AMP	17 mm
Co-amoxicilin (aminopnc*)	AMC	18 mm
Co-trimoxazol (mixt. 2)	SXT	16 mm
Tetracycline	TE	15 mm
Chloramphenicol	C	21 mm
Vancomycin (glykopeptid)	VA	17 mm

*potentiated by a beta-lactamase inhibitor

Diagnosatics of
enterococci and
G+ rods
(+ pictures)

Description of criminals (diagnostics 1)

	Enterococ.	Listeria	Coryneform	Bacillus
Microscopy	<p>G+ cocci short chains</p>  <p>http://textbookofbacteriology.net</p>	<p>G+ rods chains or palisades</p>	<p>G+ rods palisades</p>	<p>G+ robust rods, sporulating (sometimes non visible)</p>
Cultivation	<p>greyish, as large as that of <i>S.</i> <i>agalactiae</i>, various hamolysis</p>	<p>like enterococci of <i>Strep.</i> <i>agalactiae</i></p>	<p>very tiny colonies, like flour</p>	<p>large colonies, sometimes intensive haemolysis</p>

Enterococci – colonies

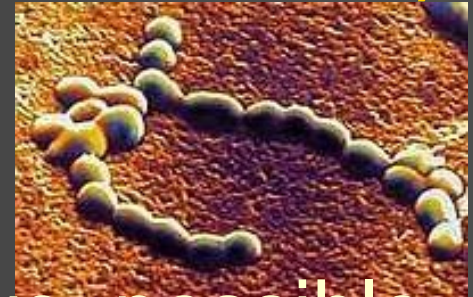<http://microbiology.mtsinai.on.ca>



Description of criminals (diagnostics 2)

Enterococci

<http://www.morgenwelt.de>



- **Biochemical tests:** **catalase** negative, possible biochemical determination, **arabinose splitting** (*E. faecalis* does not split, green medium, *E. faecium* makes it yellow)
- **Antigen analysis** used rarely. (Originally „group D streptococi“ according to Lancefield, as genus *Enterococcus* did not exist in time of Lancefield research)
- **Atb testing** on common MH agar. There exist also screening media for VRE.

Description of criminals (diagnostics 3)

G+ rods

- **Biochemical tests: catalase** positive in all three of our genera. But e. g. genus *Arcanobacterium* (not member of *Corynebacterium* genus, but nevertheless a coryneform) is CAT neg. Biochemical detection possible (API Coryne, Remel)
- **Growth at low temperatures, high NaCl concentrations etc.** used in *Listeria* dg.
- Biochemical dg. and atb testing are also a part of the diagnostics
- Antigen analysis – e. g. searching diphtheria toxin

Photos of criminal database 1

Enterococci

Microscopy

Bile-aesculin

Slanetz-Bartley

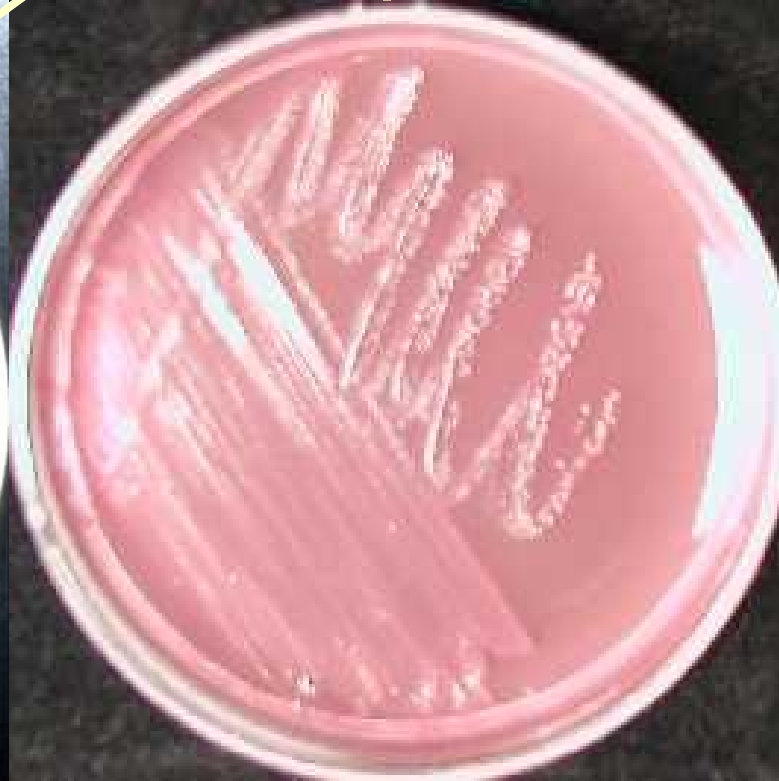
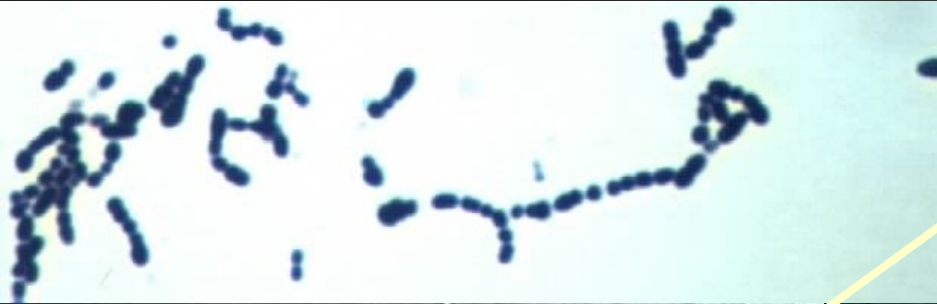

Photo:
www.medmicro.info
both left pictures
made by Prof.
MVDr. Boris
Skalka, DrSc.

Photos of criminal database 2

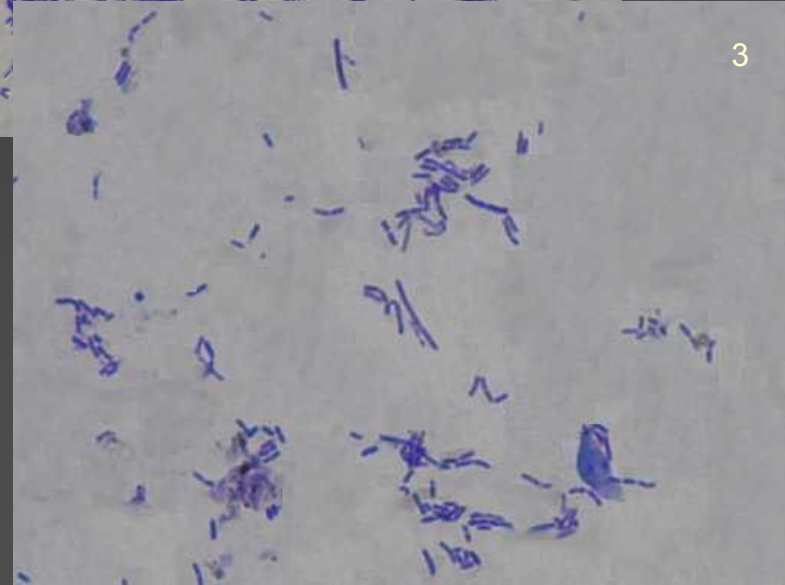
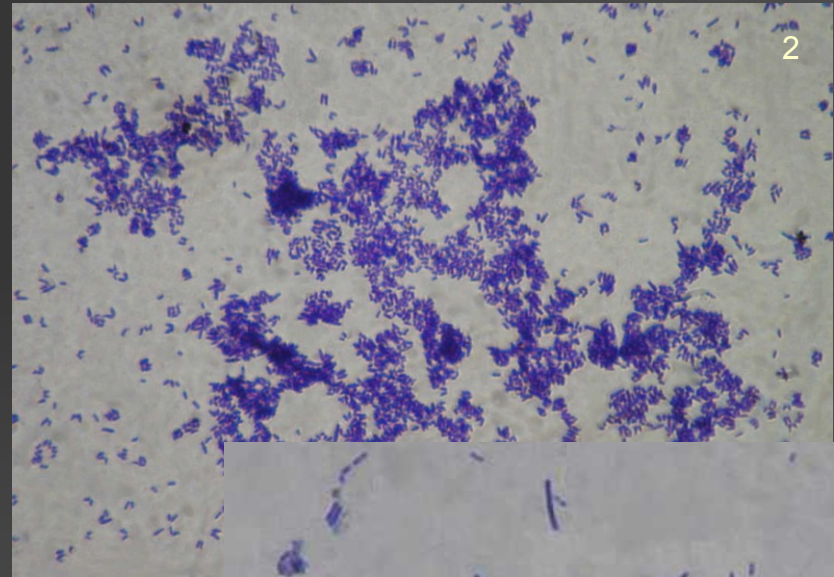
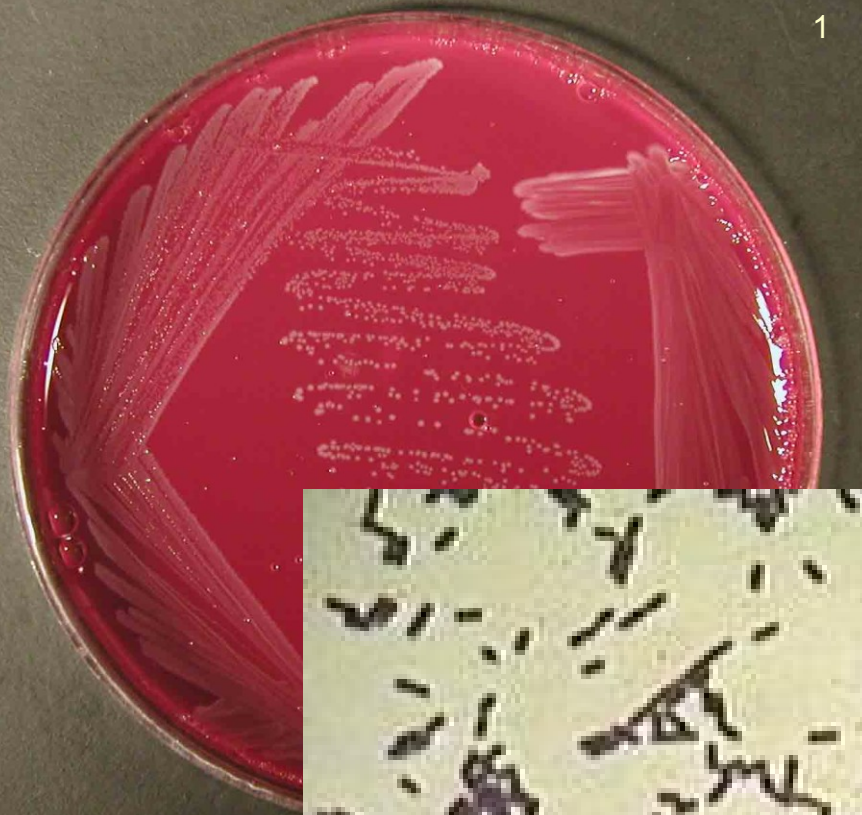Rods I

1, 2, 3 www.medmicro.info

4 <http://medinfo.ufl.edu>


Corynebacterium Gram

Listeria – BA, Gram



Photos of criminal database 3

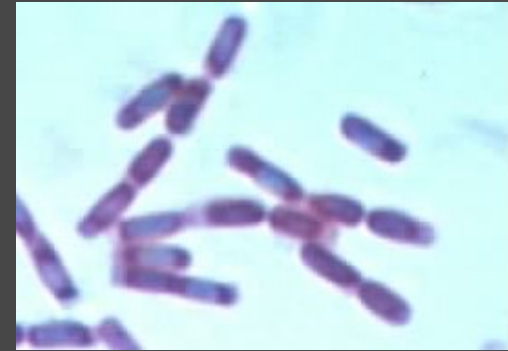Rods I – corynebacteria, forms



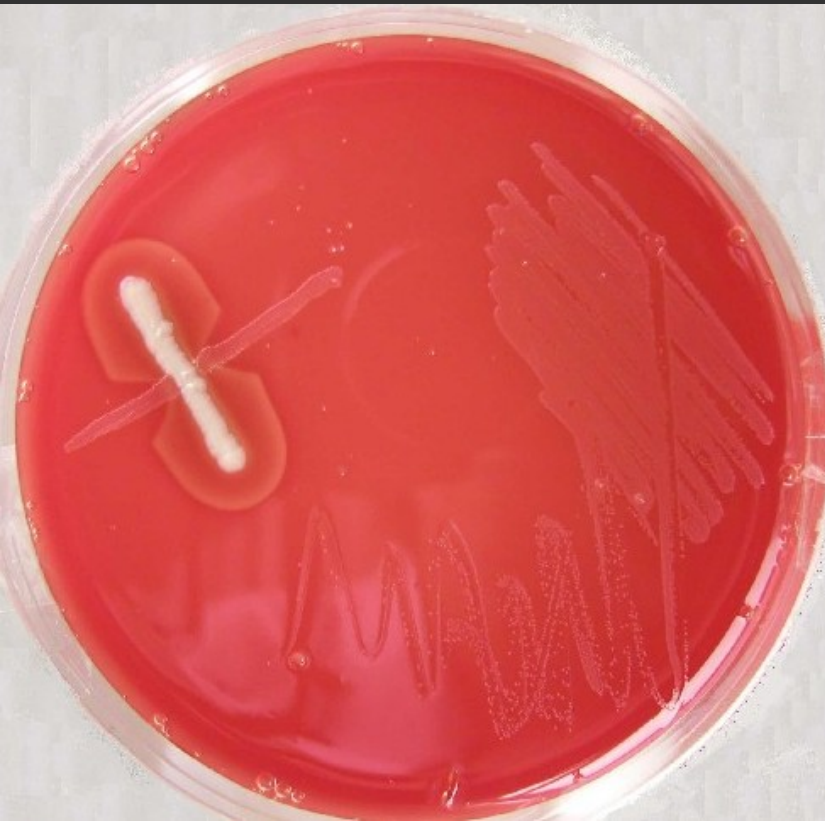Photos of criminal database 4

Rods III

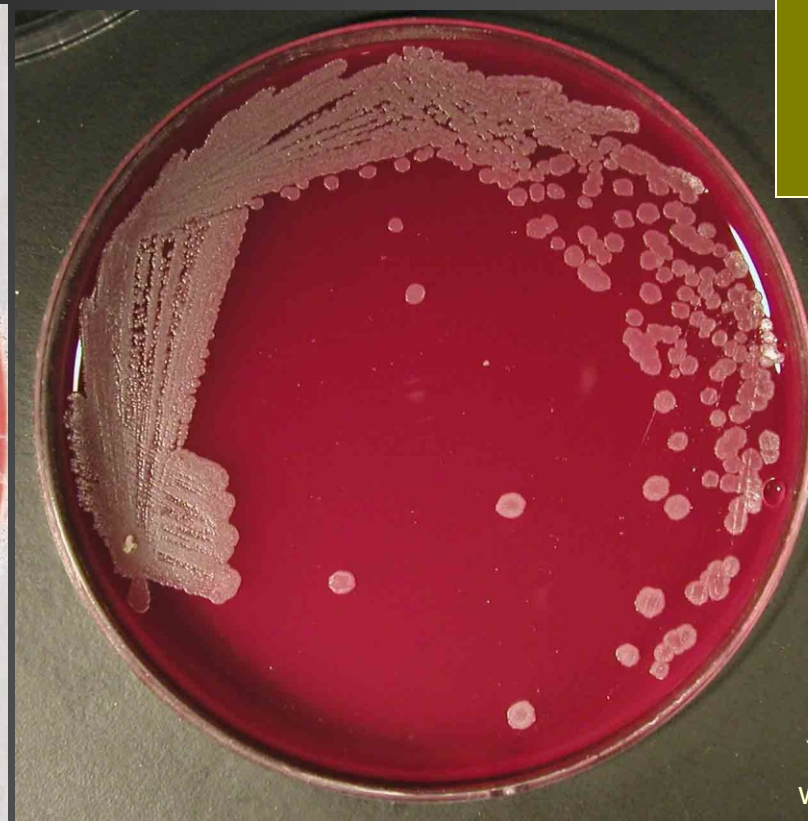
Bacillus cereus



Arcanobacterium haemolyticum



Bacillus subtilis



Differential
diagnostics of
enterococci and
G+ rods

Differential diagnostics - enterococci

- Gram staining differentiates Gram + cocci, Gram + rods and other bacteria.
- Catalase of NaCl differentiates staphylococci
- Slanetz-Bartley / Bile-aesculin, PYR test differentiates enterococci from streptococci
- Arabinose test/other biochemical tests – mutual differentiation of Enterococci

Differential diagnostics – *Bacillus*

- *Bacillus*, *Listeria* & coryneforms = G+ rods
- *Bacillus*:
 - **culture**: large, flat, dry, felt-like colonies, „spreading“ through the agar surface, sometimes with a massive haemolysis, sometimes with no haemolysis at all
 - **microscopy**: very robust rods, sometimes with finding of central or subterminal spores, that may, but must not be larger than the diameter of the rod.

Differential diagnostics – *Listeria* and coryneforms

■ *Listeria*

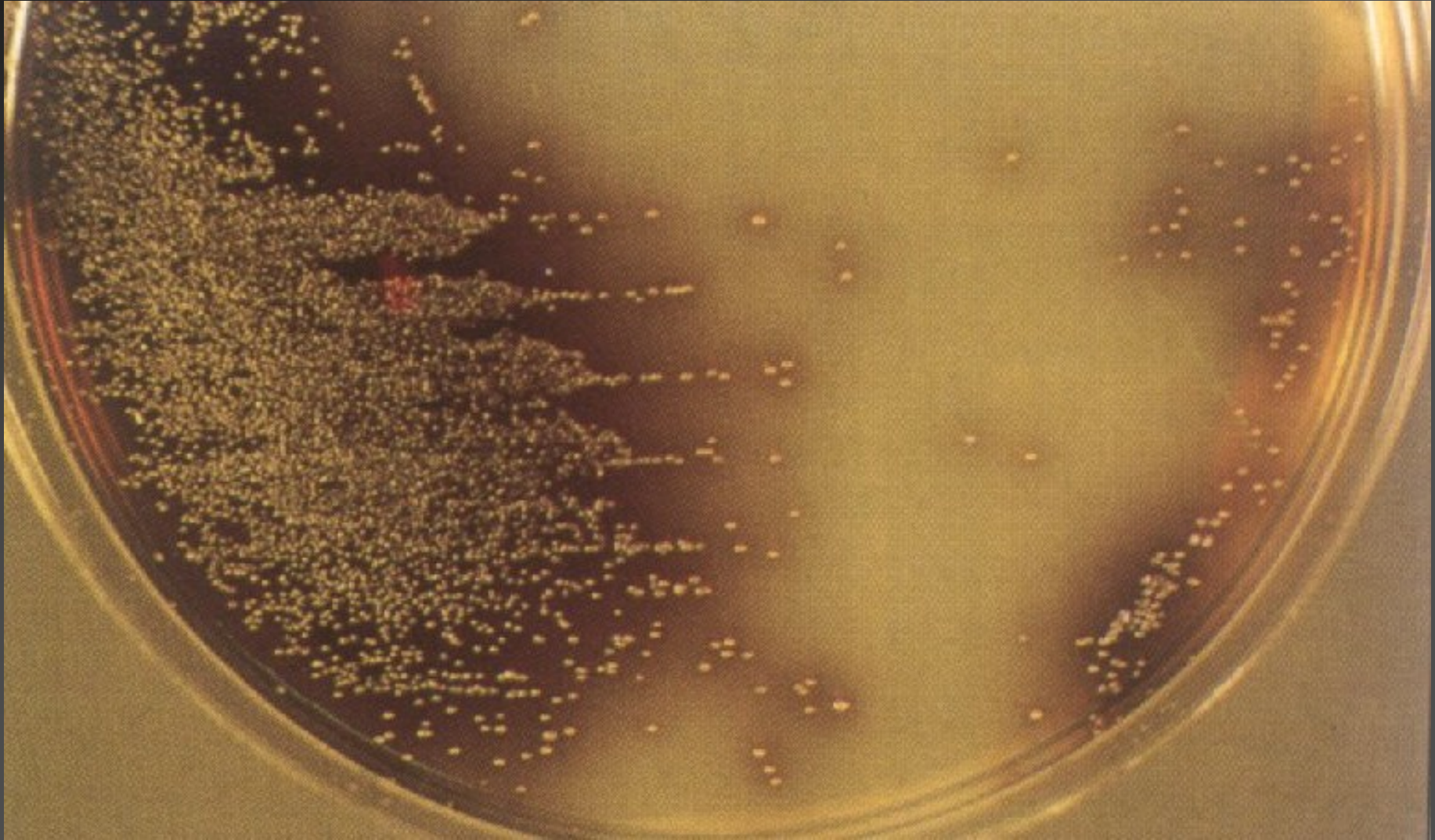- **culture:** colourless to greyish colonies, very similar to those of *Enterococcus*, with or without haemolysis
- it does grow on **bile aesculin** (but not Slanetz-Bartely) agar; it also does grow on BA at 4 °C
- **microscopy:** tinier than *Bacillus*, sometimes arranged in palisades, sometimes in short chains

■ *Corynebacterium* (and related genera):

- **culture:** greyish or whitish colonies similar to those of *Staphylococcus*, but less or more smaller, usually anaerolytical
- **microscopy:** rather smaller than previous, but club-shaped and arranged in palisades

Bile-aesculin agar

<http://www.geocities.com>



Differentiation of *Enterococcus*



- **Arabinose test:** colonies are mixed with arabinose and indicator, and let to incubate

Green	negative	<i>E. faecalis</i>
Yellow	positive	<i>E. faecium</i>

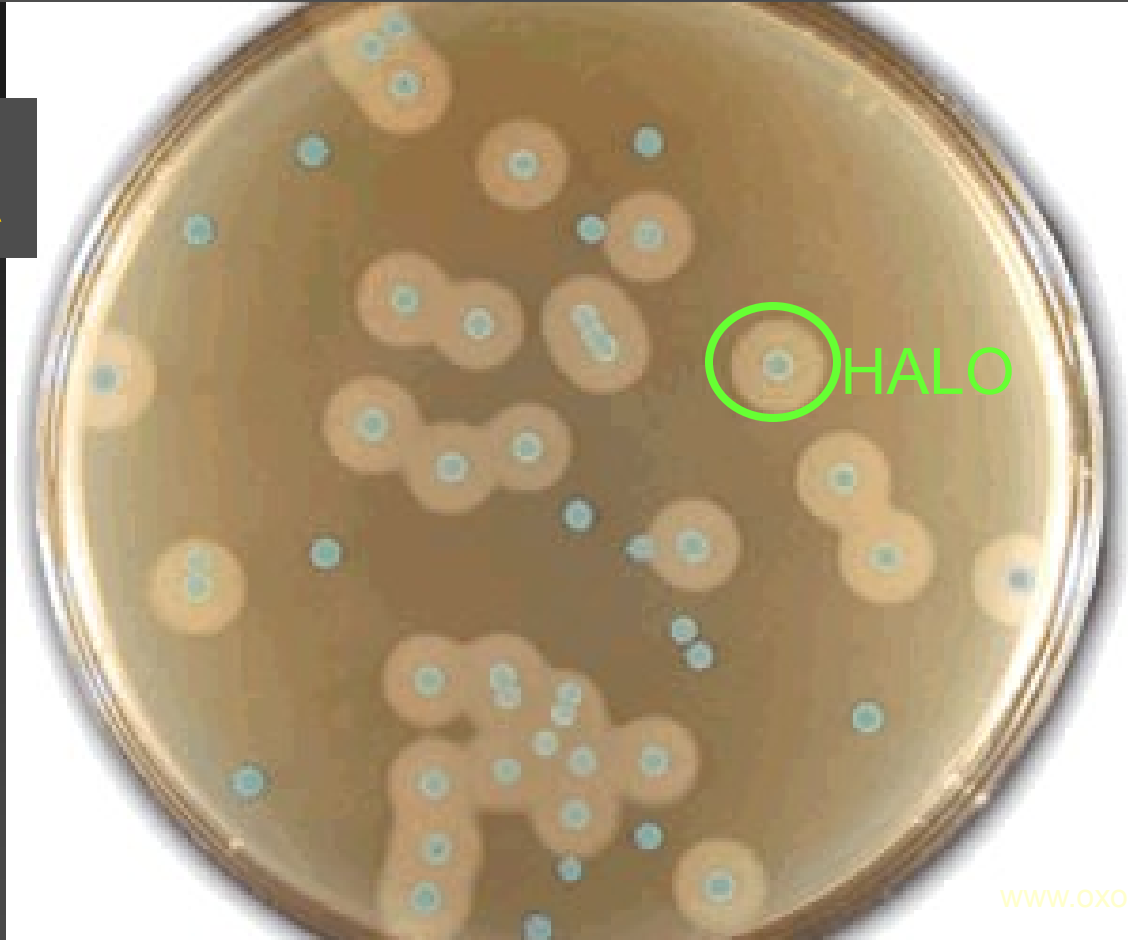
- ENCOCCUStest has only 8 reactions, but otherwise it is like other similar tests

Listeria growth at 4 °C

- Among Gram positive rods, only *Listeria* is able to grow in low temperatures. This enables it to spread in cheese factories
- Among other bacteria (not being G+ rod), there are some more species able to grow at such low temperatures (*Yersinia*, some *Pseudomonas* sp.)

A chromogenous medium

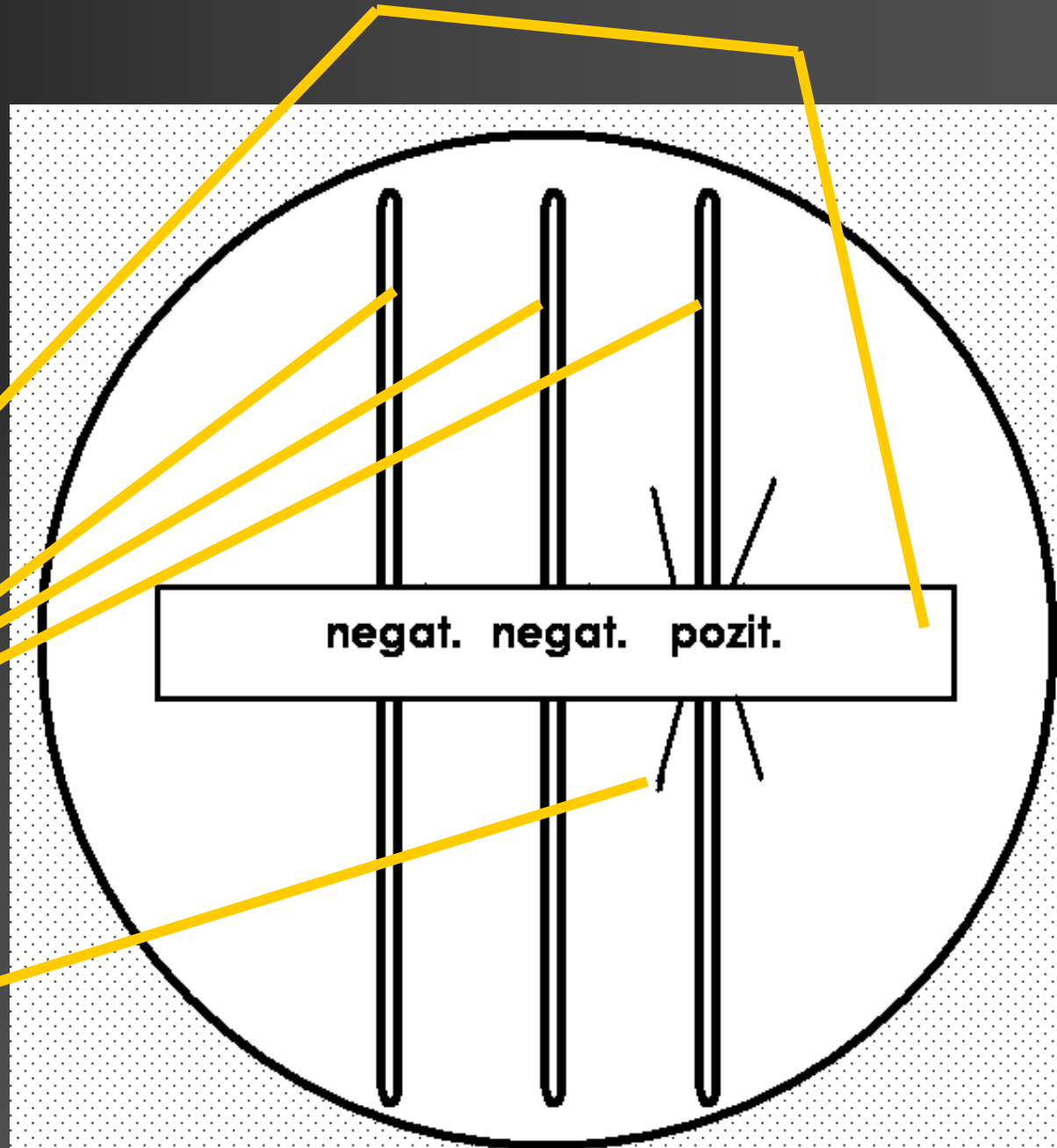
ALOA



A chromogen (colourless) is changed to a **blue dye** by a specific enzyme of *Listeria*. Pathogenic *Listeria* perform a **halo** due to some more enzymes.


Elek test

It is a detection of a toxin of *Corynebacterium diphtheriae*. We use a paper with specific antitoxin, that is put on the surface of the agar, then tested strains are inoculated. Positive result = precipitation lines.



The end

<http://www.cdphe.state.co.us>



Bacillus anthracis