

Institute for microbiology shows

TRACING THE CRIMINAL



Part nine:
Criminals in spiral form

From anthem of medical students

„Diabetes mellitus, icterus et vomitus“

(Second part)

Treponema pallidum

Gonococcus ruber

Ulcus molle, *ulcus durum*

Molle est reparaturum

Nos curabit ...

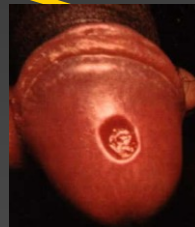*(name of a suitable
urologist of
dermatovenerologist)*

Causes syphilis

Old name of causative agent of gonorrhoea (*N. gonorrhoeae*)

Chancroid – caused by *Haemophilus ducreyi*

Chancre – one of typical symptoms of syphilis



www.med.sc.edu

(Melody of Gaudeamus igitur, iuvenes dum sumus)

Survey of topics

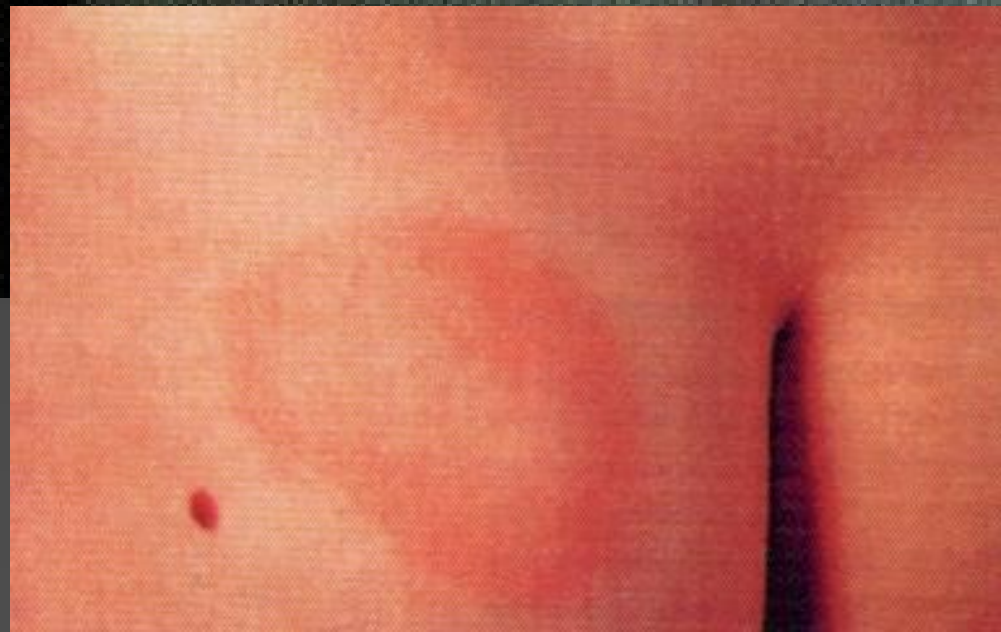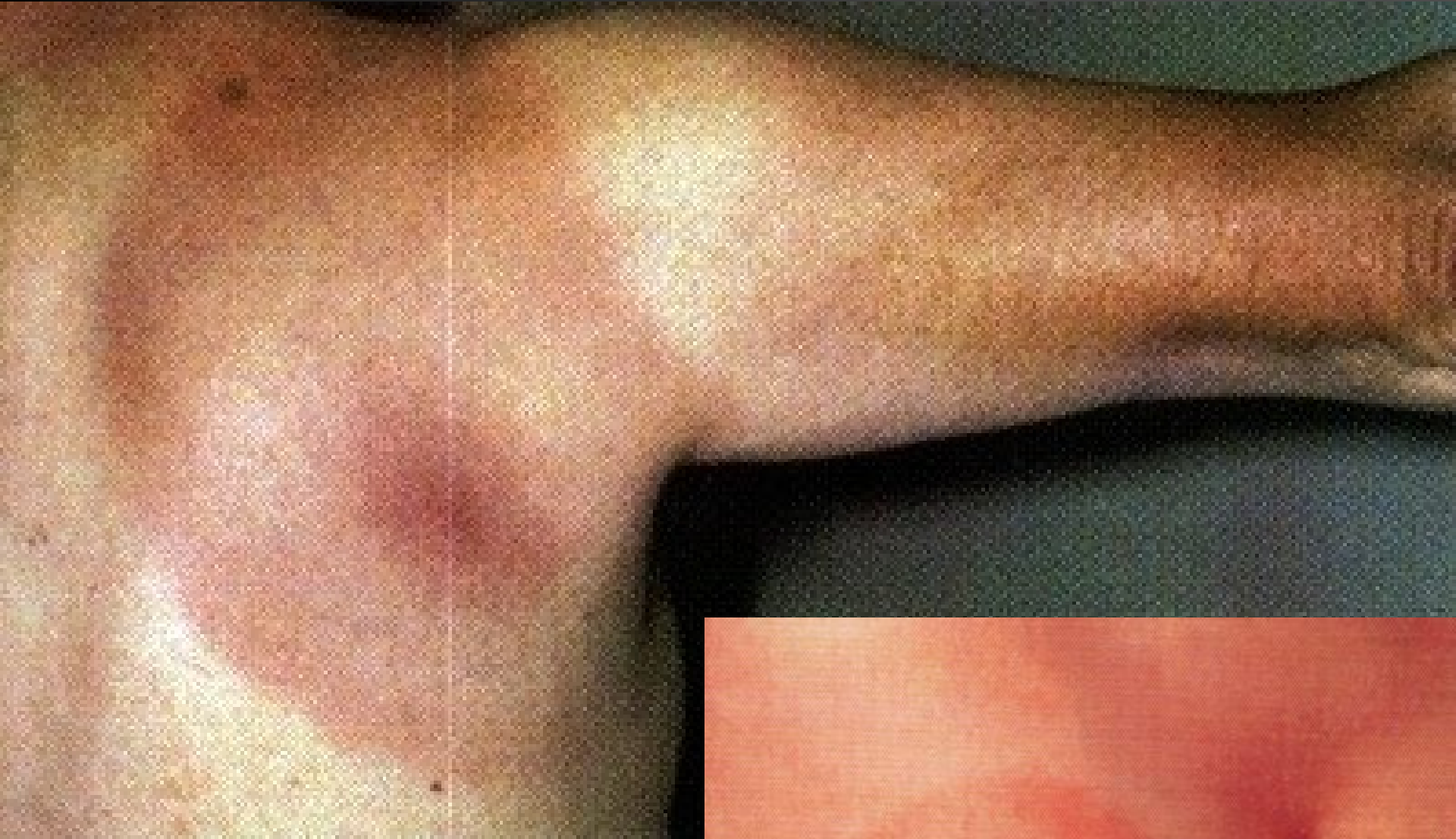Clinical characteristics of spiral bacteria

Microbiological characteristics & dg. of spirochetes

Clinical characteristics of spiral bacteria

Story one

- Roseanne Pinkspot started to have pink spots on her body. She thought, that probably... Oh yes, several weeks ago when she participated on a girl scout camp and several times during the camp she had a tick.
- Her GP sent her to children infection clinic, and experienced infectionist confirmed, that most likely it is the disease that Roseanne supposed. For sure, she took serum for antibody detection...

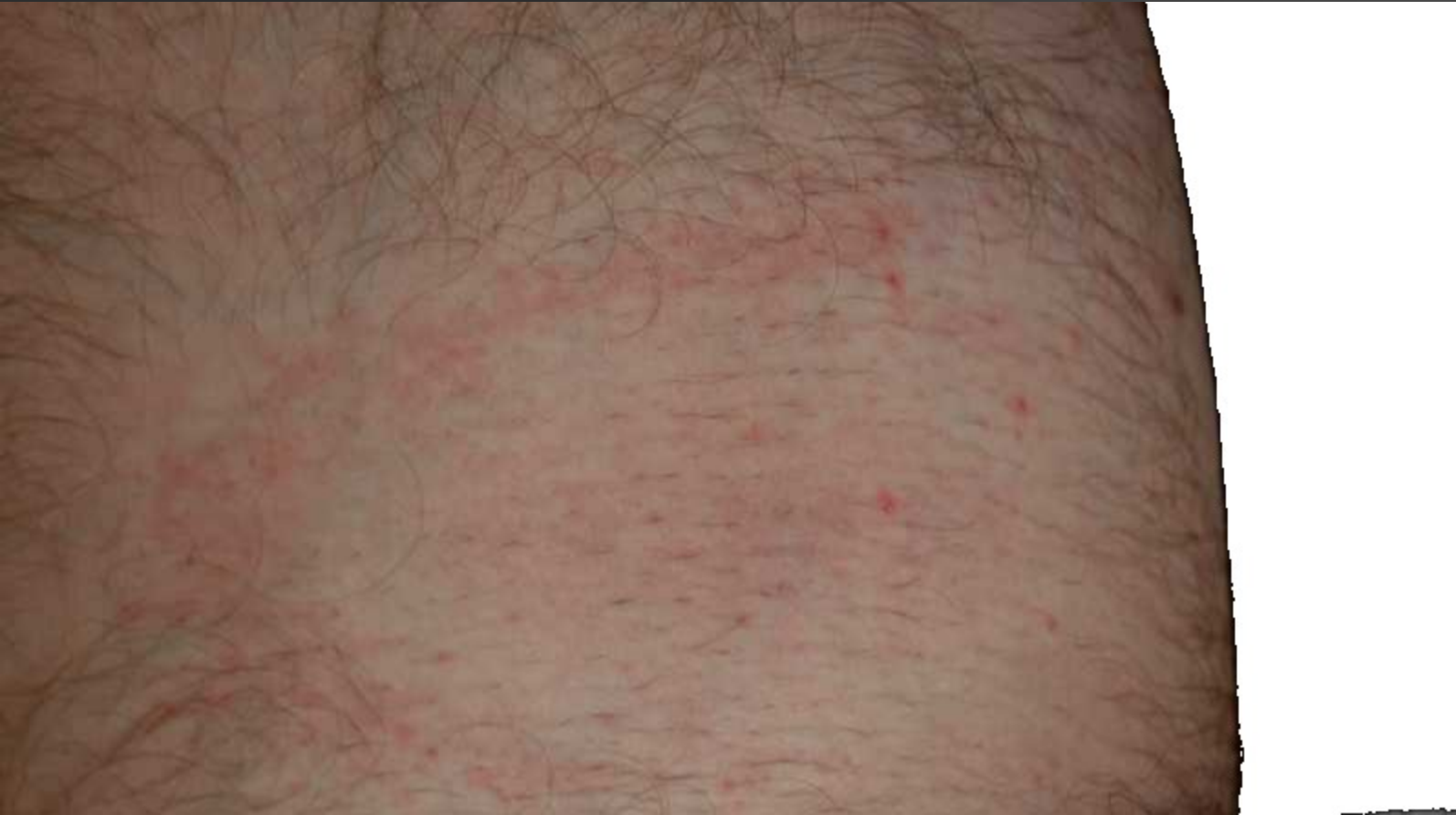

www.med.sc.edu

www.borrelia.de

Erythema migrans

- This is a picture of Erythema migrans of student M. M., who kindly agreed to let it for use in education

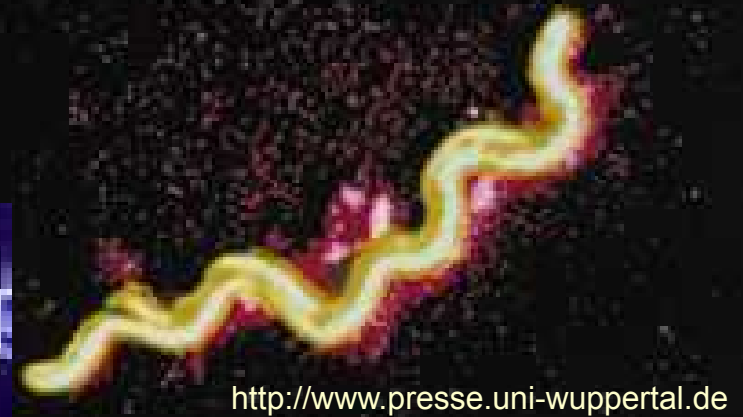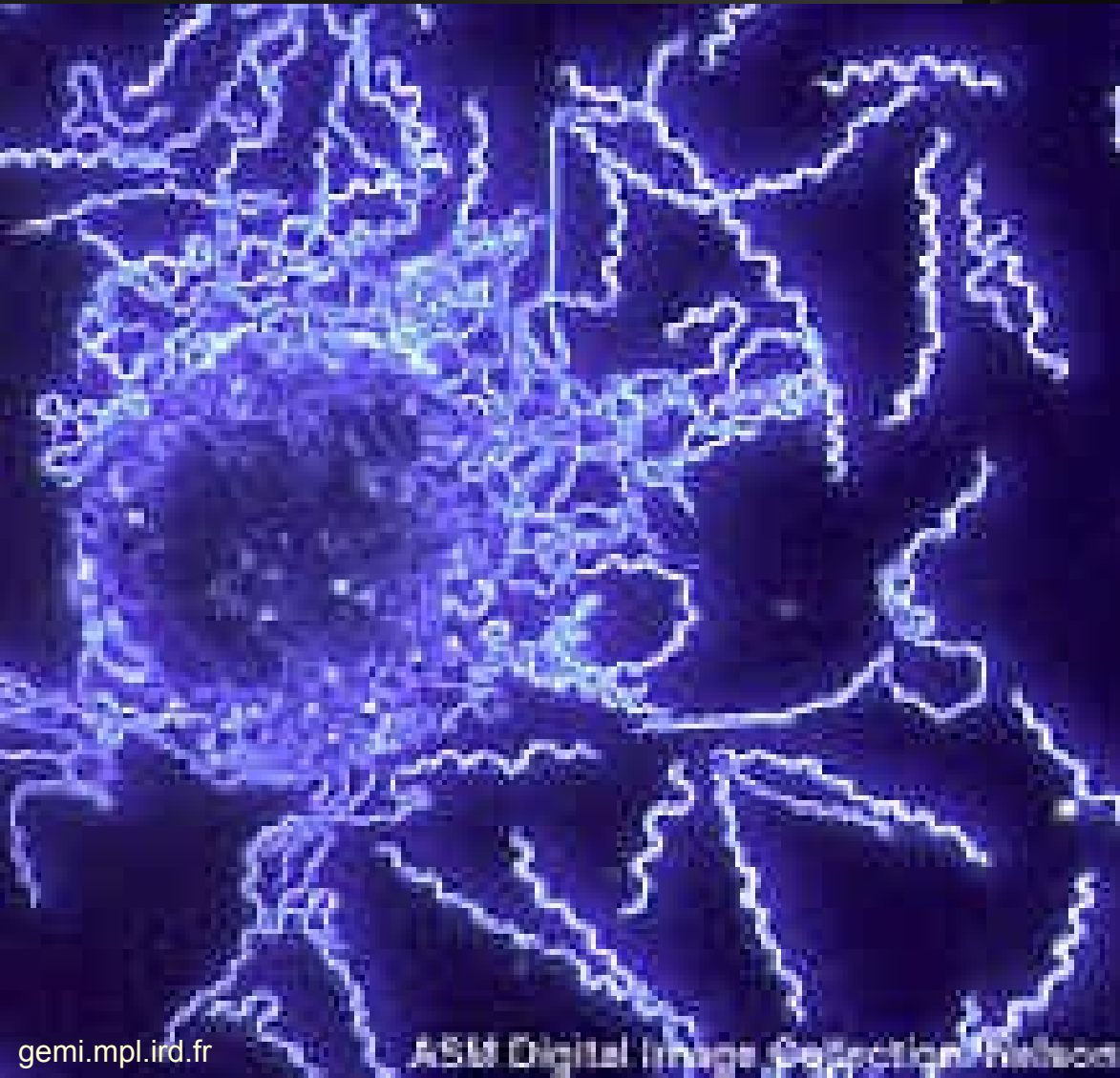




The causative agent was

- *Borrelia afzelii*, one of borreliae, causing Lyme disease and belonging to the group *Borrelia burgdorferi sensu lato* (= „broad sense of meaning“)
- This species „in broad sense“ is divided into several species „in narrower sense“. The most important are *B. garinii*, *B. afzelii* and *B. burgdorferi sensu stricto*
- While in the USA mostly the third of them is common and joint symptomatology is common, in Europe two first borreliae are more common, and the typical disease is neuroborreliosis
- Besides lyme diseases there exist other species causing recurrent fever (*B. duttoni*, *B. recurrentis*)

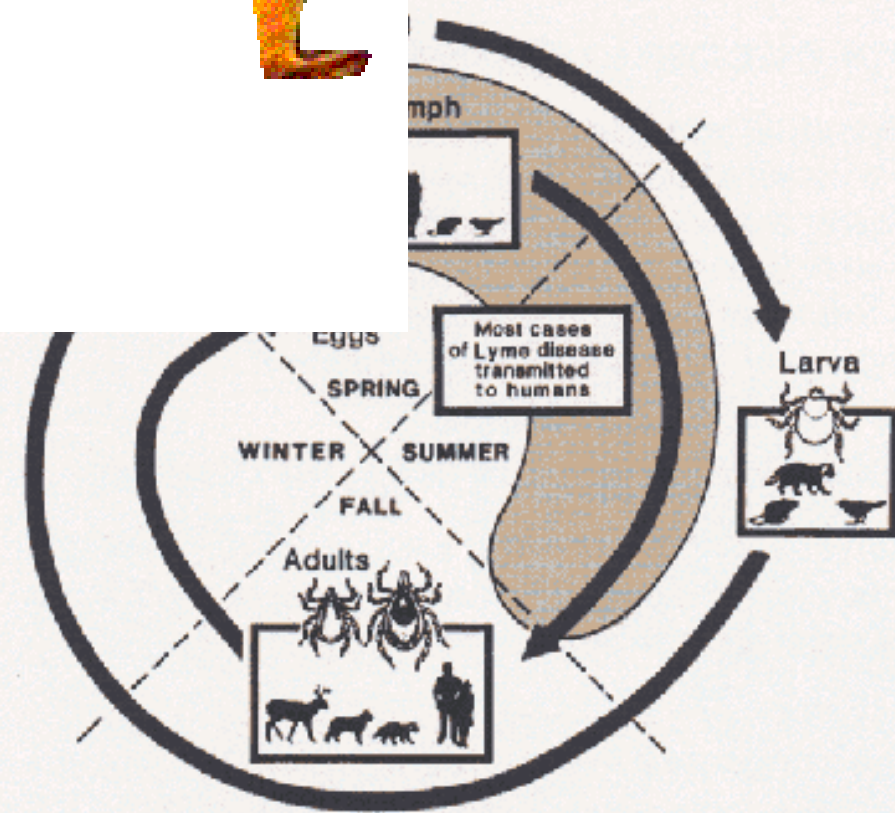
Borrelia burgdorferi



<http://www.presse.uni-wuppertal.de>

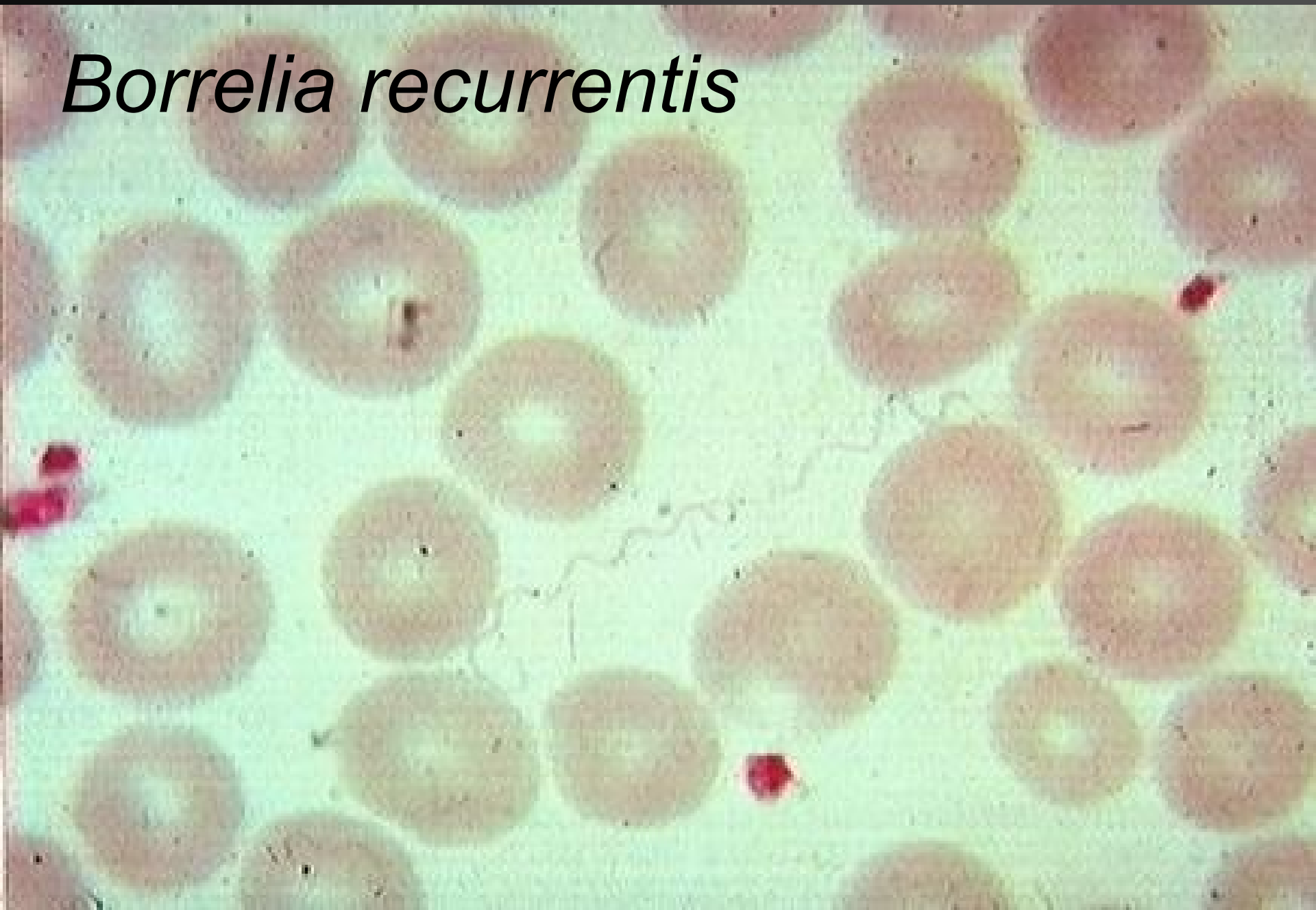


the disease ticks



Lyme disease – a tick borne zoonosis

Borrelia recurrentis

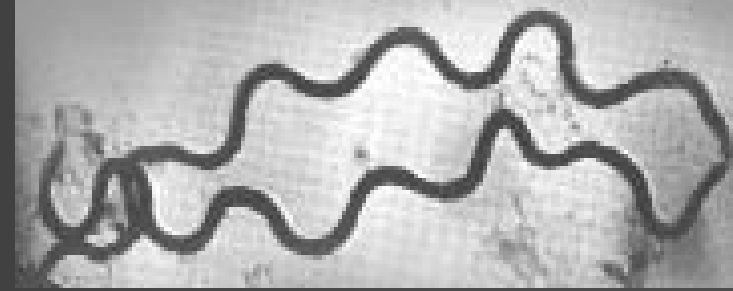


Story two (virtual, but basis is from a real story)

- When **Phyllis** found, that she really needs pervitin, and more and more, she decided to **earn money by her own body**.
- When the client paid more, **she went with him without a preservative**, she used anticonception and she felt more OK
- Then she fell in love and **decided to have a child**. She stopped the anticonception and was happy. Helmut will be a good father...

Story two – continuing

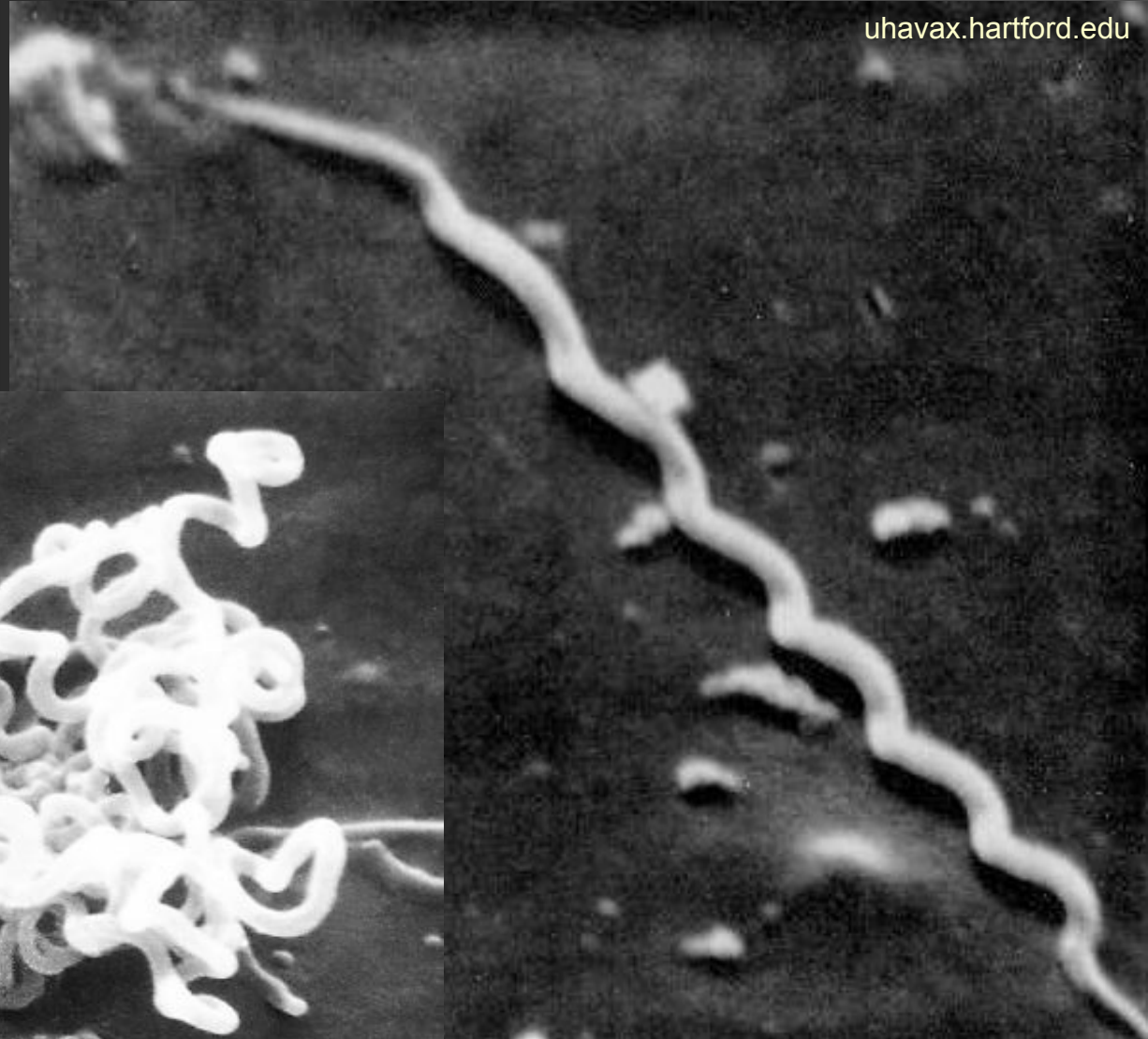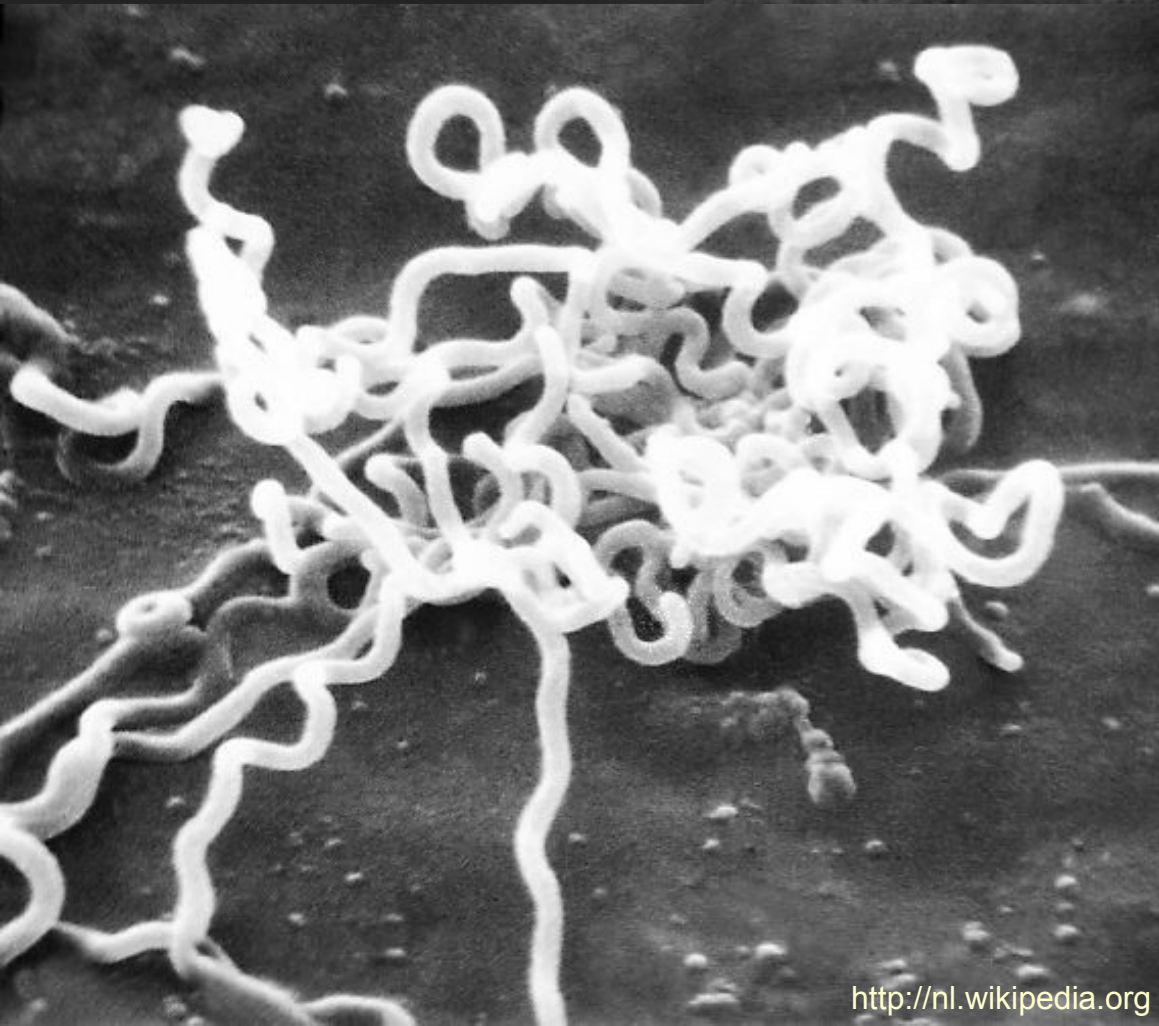- So Phyllis was pregnant. But she found herself a genital ulcer and her gynecologist took blood for serological examination. It was positive. Phyllis did not want interruption, it was too late and she wanted her child.
- Phyllis was treated, but the antibiotic was not chosen properly. The child was born ill and after two weeks it died because of a secondary *Klebsiella* septicaemia



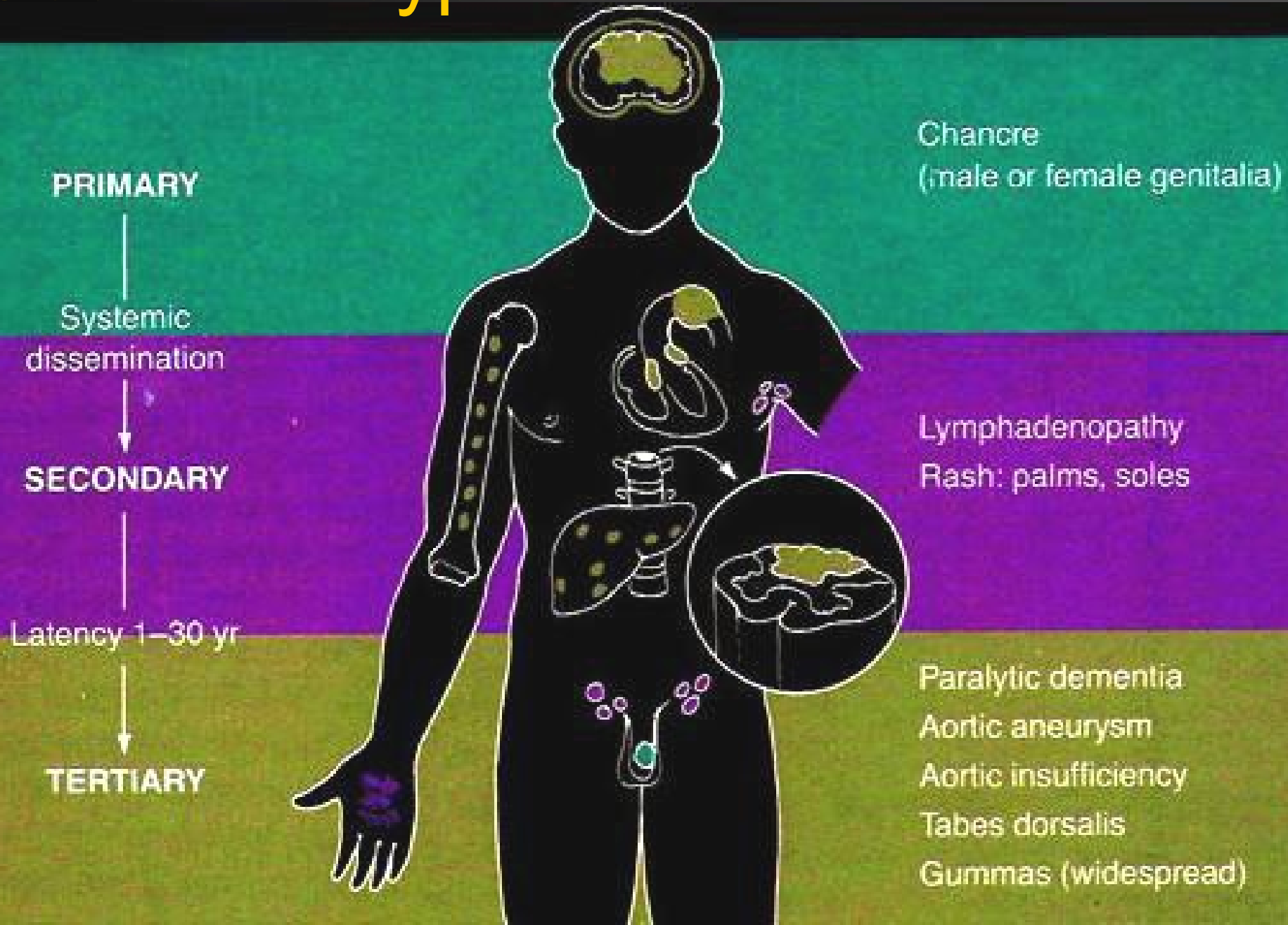
The criminal was

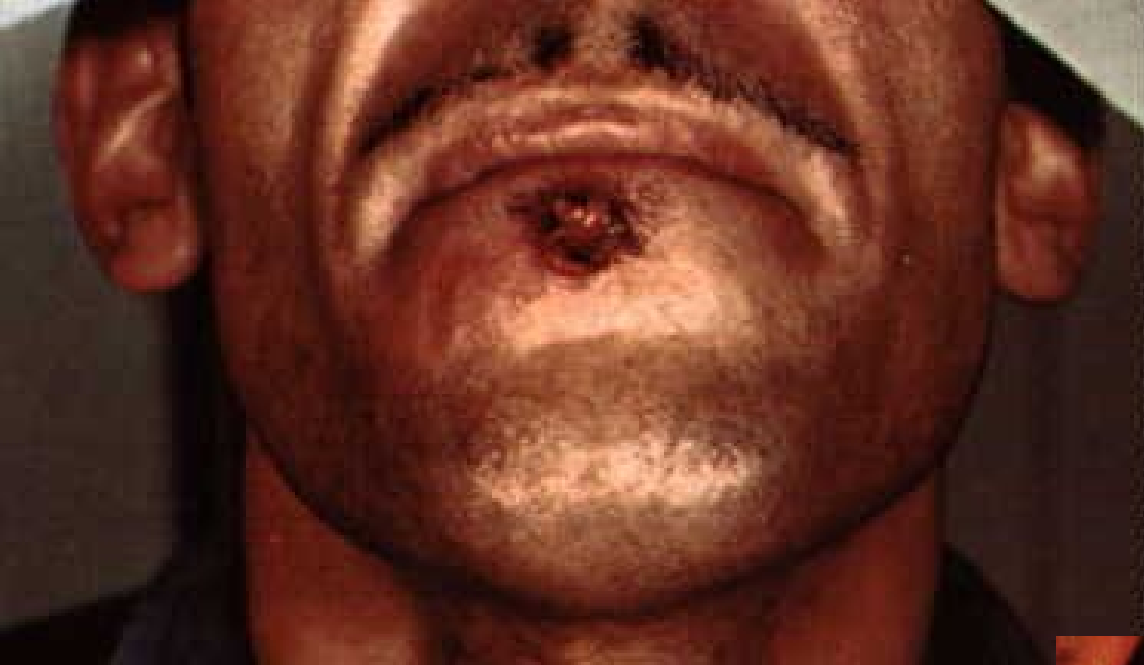- *Treponema pallidum*, causing syphilis (lues)
- Syphilis is a **classic sexual disease**. It is transmitted sexually only. But it is a systemic disease – in developed stages the **whole body is affected** (gummata, aortal dissection, neurosyphilis, psychological symptoms)
- Some subspecies of *T. pallidum* and some other treponemas cause **other, differently transmitted diseases** (framboesia – yaws, *T. pertenue*)
- Some treponemas are non-pathogenous

Treponema pallidum



Course of syphilis



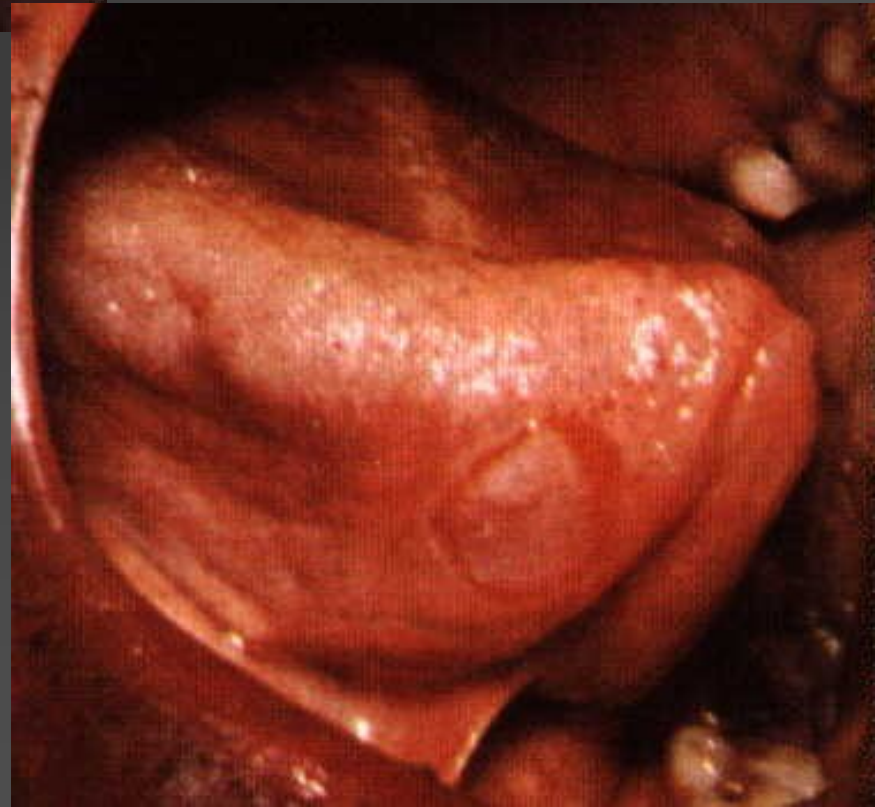


primary
syphilis
(„chancre“)

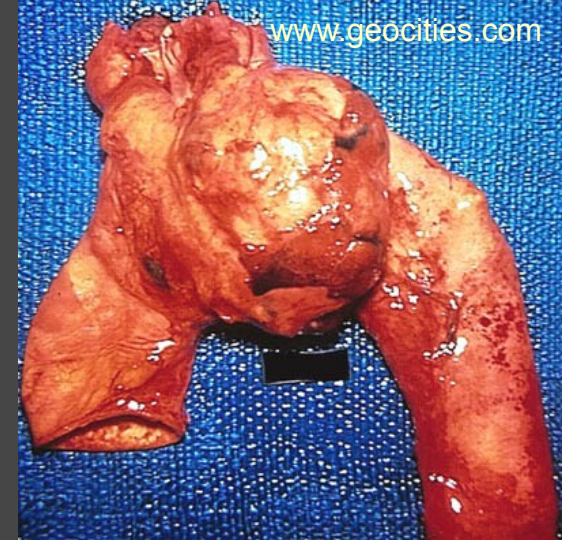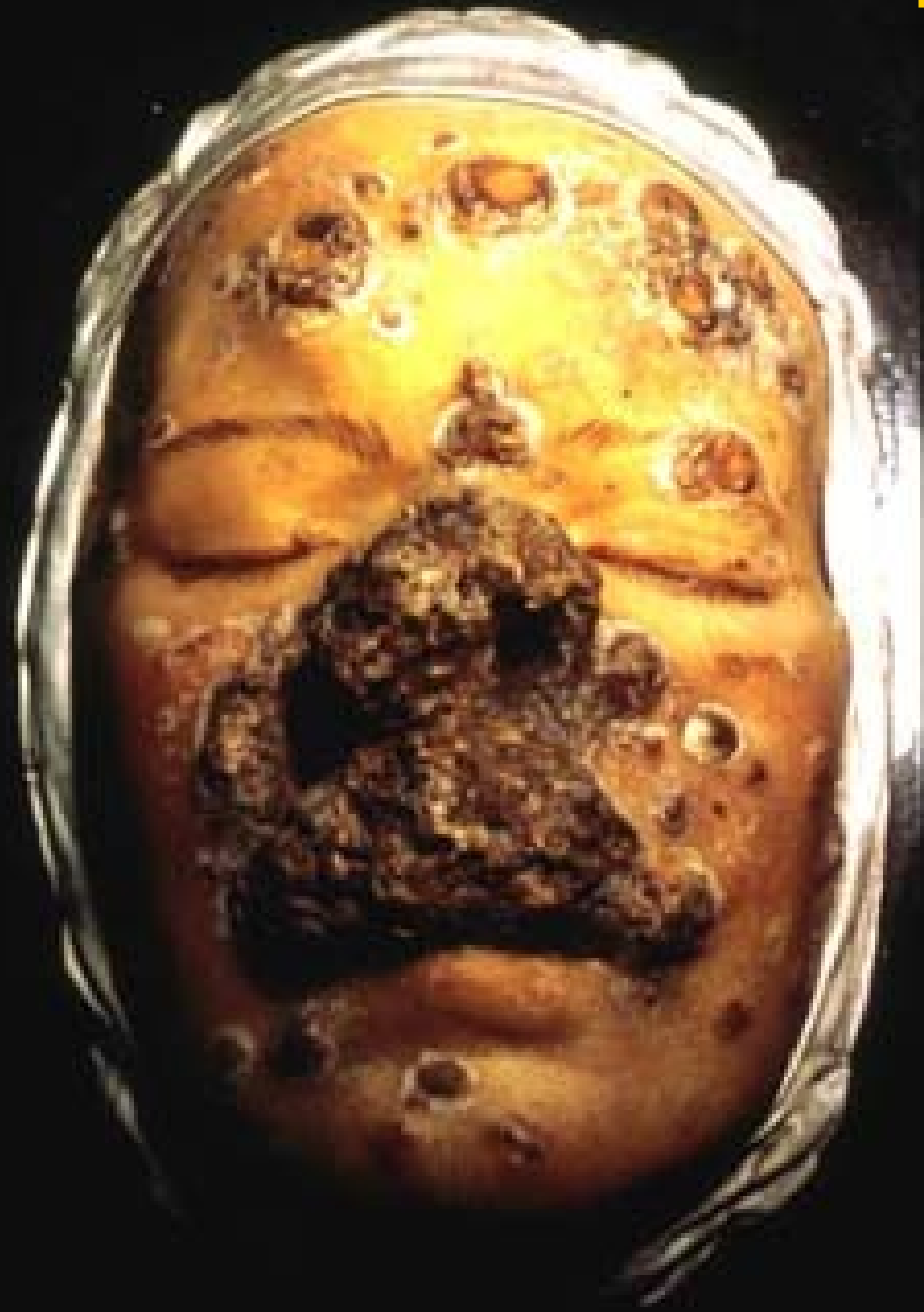uhavax.hartford.edu (2x)

Course of syphilis

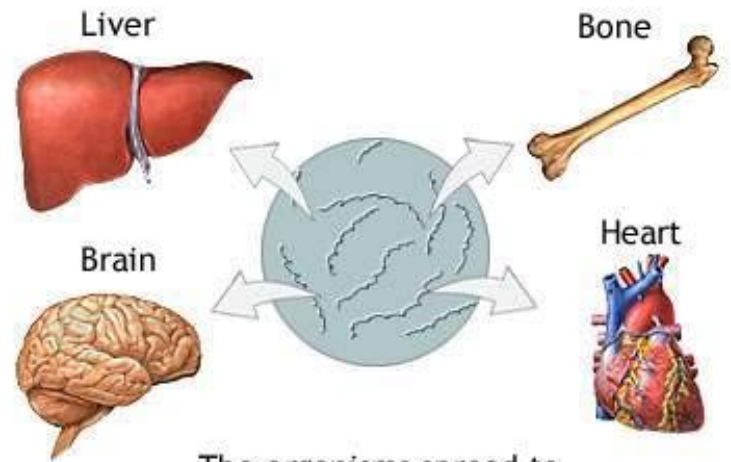
secondary
syphilis



Tertiary syphilis

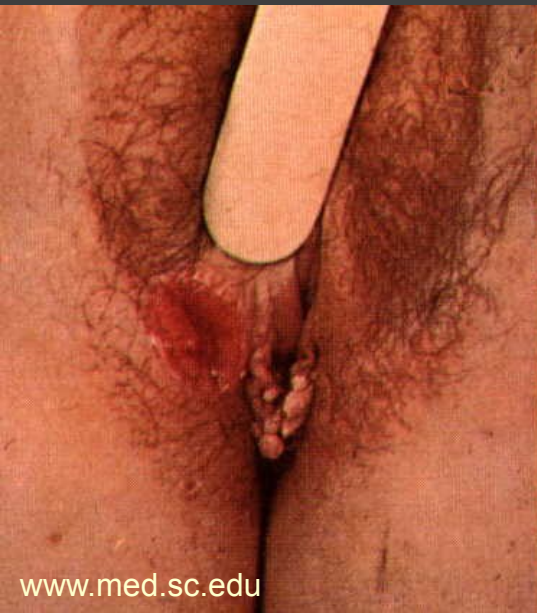


www.geocities.com



The organisms spread to various organs causing lesions or gummas

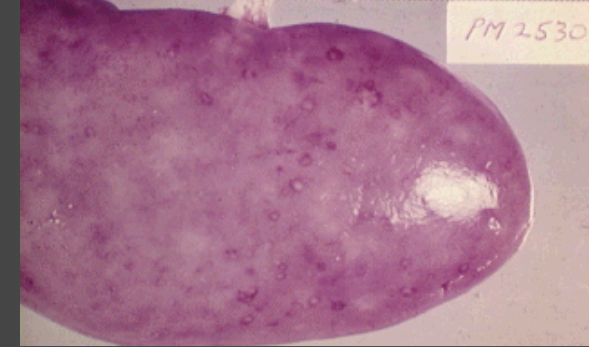Syphilis



Yaws (framboesia)



Kidney with the
corresponding
disease

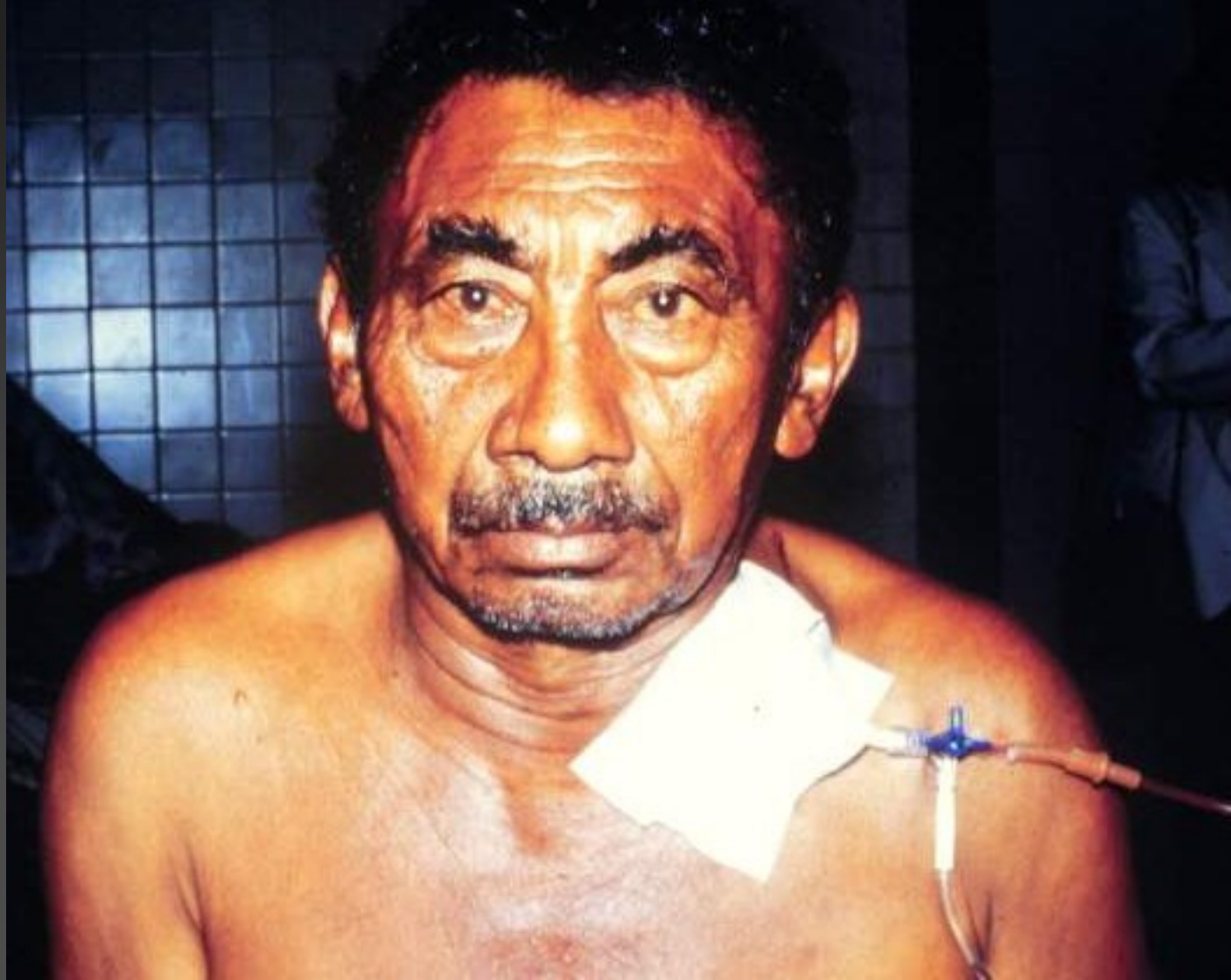

www.med.sc.edu

Story three

- **Mr. Ratter** was an employee of NWPS Ltd. (Nowhere Water Pipes and Sewage)
- His job was **sewage cleaning**. He knew all sewage corridors. He also knew **rat habits**, he liked rats and he understood them.
- Nevertheless, once there was some misunderstanding between him and the leader of rat group and **Mr. Ratter was bitten to his leg**.
- Some time after this, Mr. Ratter was hospitalized with **icterus and bleeding...**

This is not Mr. Ratter, but his Venezuelan colleague with a similar fate...



The disease is caused by...

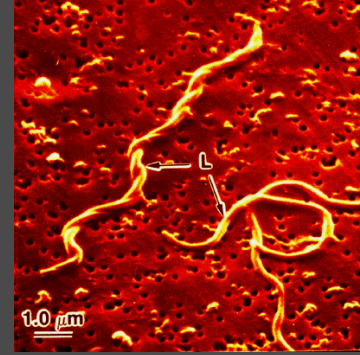


- *Leptospira interrogans* ser. Icterohemorrhagiae
- Formerly individual serovars of *Leptospira* were considered to be individual species, now all pathogenic ones are taken as a part of species *Leptospira interrogans* (second species *Leptospira biflexa* is non-pathogenic)
- **Symptomatology varies**, from „flu-typhoid“ symptoms of serovar **Grippotyphosa** (field fever, canefield fever) to jaundice and bleeding (Weil disease, as in Mr. Ratter) in serovar **Ictero-hemorrhagiae**.

(At least these two serovars are quite simple for remembering, try to remember at least them 😊)

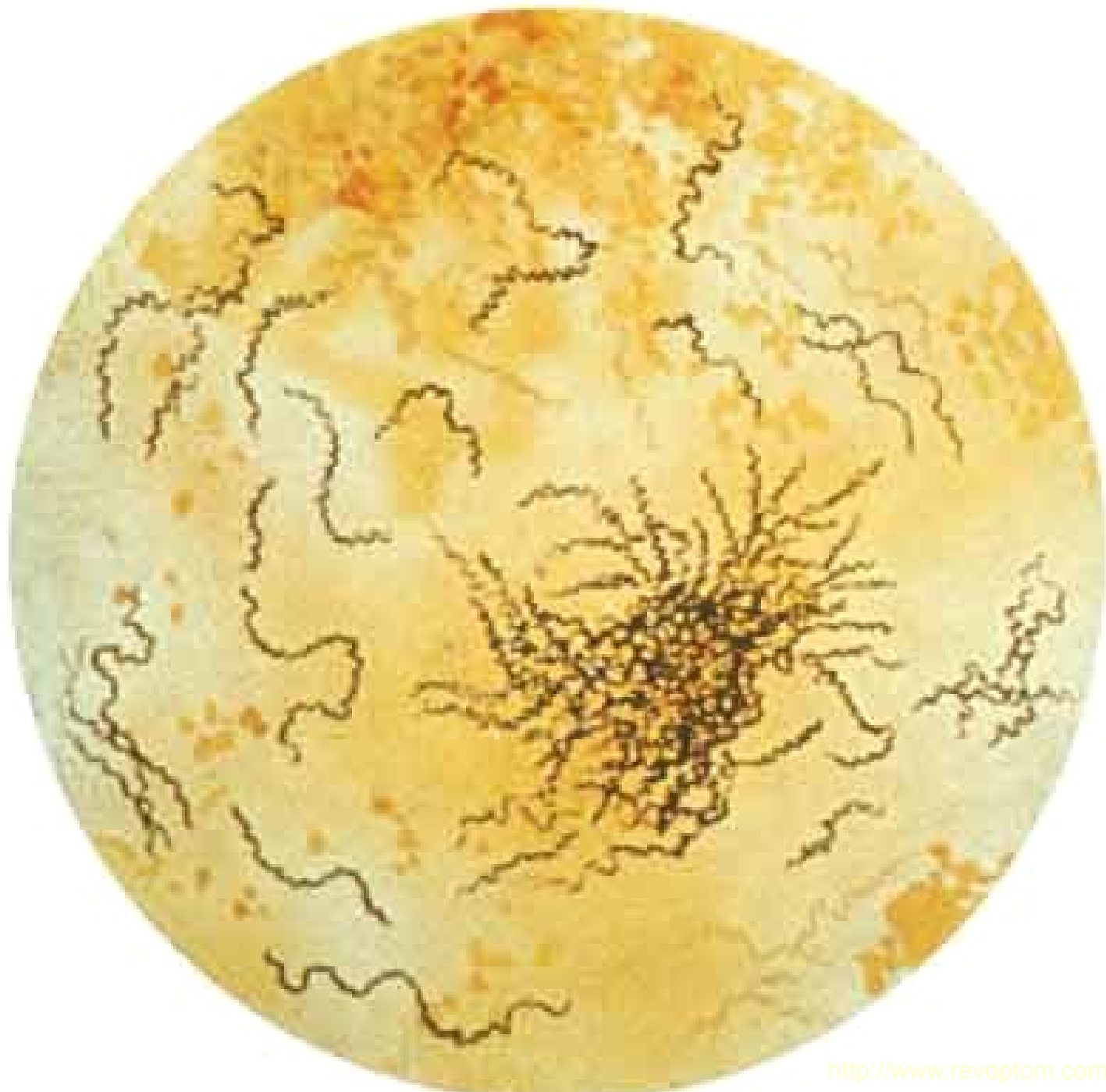
Microbiologic characteristics and diagnostics of spirochetes

Spirochets



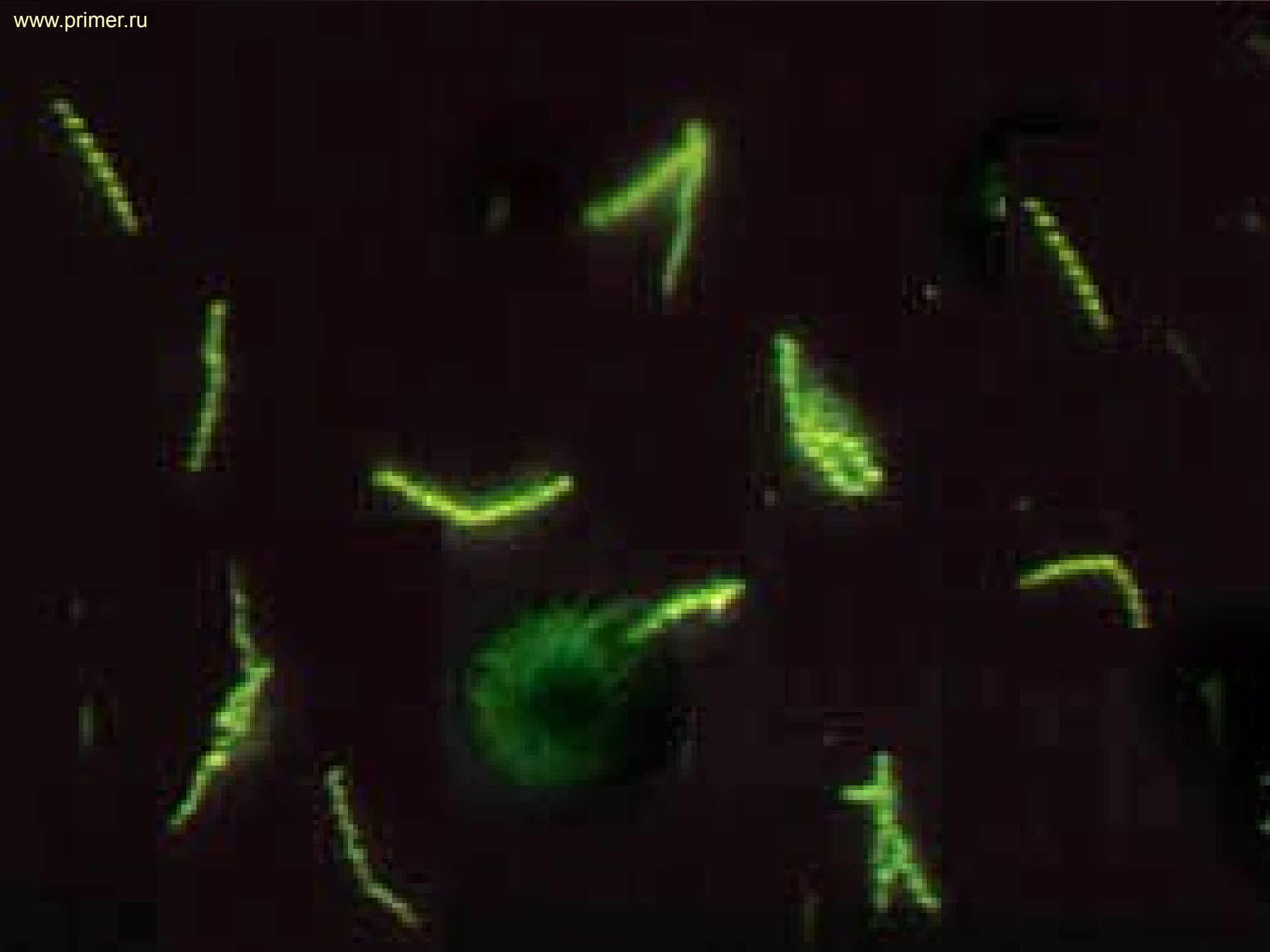
- Borreliae (but also treponemas and leptospiras) are **spirochets**, i. e. **spiral bacteria**.
- Their cell wall is close to a gram-negative one, but they do not **Gram stain** mostly because they are very thin. So we microscopy them only using dark-field or fluorescence microscopy, or immunofluorescence (**≠ fluorescence**)
- **Spirochets commonly are not culturable** (some of them can be cultured experimentally, but it has no practical meaning)

Treponema pallidum



Treponema: direct methods

- **Direct diagnostics** is rare, also because often there is hardly something to take. Only patients with chancre are available for scrapping.
- **Microscopy**: It is possible to use **wet mount – dark field**. It is strange, that although it is a wet mount, immersion is used (treponemas are very subtle). Besides that, **fluorescence staining can be used**
- **Neither culture nor biochemical methods** are used
- **Antigen detection** can be performed by direct IMF
- **Animal experiment**: There exist so named RIT – Rabbit infectivity test
- **PCR diagnostics** is more and more important. *This is an exception – besides chancre scrapping, it is also possible to send full blood for examination.*



Direct syphilis diagnostics – survey

- RIT – Rabbit infectivity test. For ethical reasons, but also as it is too much work, the RIT is minimized today.
- Dark field – shining *Treponema pallidum* is observed against the dark field
- Direct IMF – another direct, but difficult method
- PCR – also from blood

New Zealand Rabbit used for RIT


www.rockinjawrabbits.com



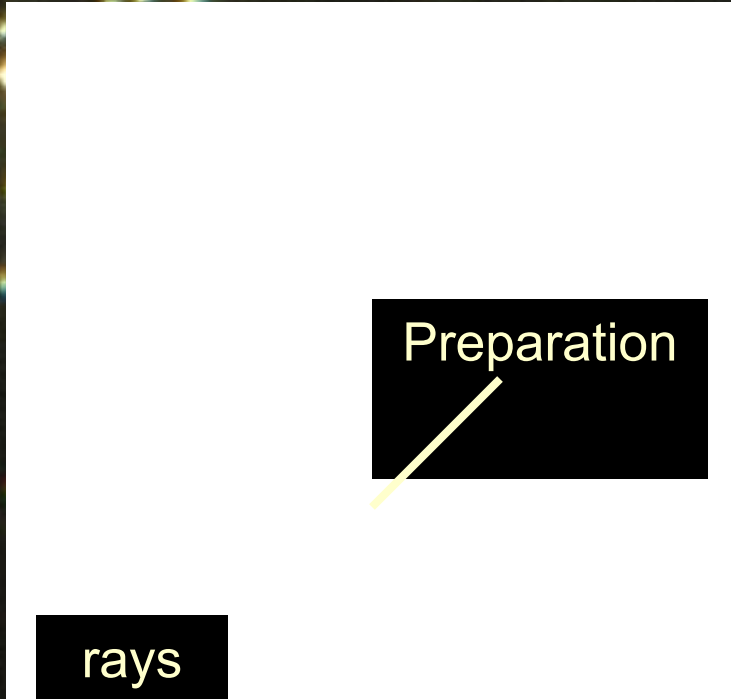
Dark field microscopy

www.medmicro.info

Only rays flexed at the preparation come to the observer's eye.
Therefore, the observer's eye can see dark field with shining object(s)

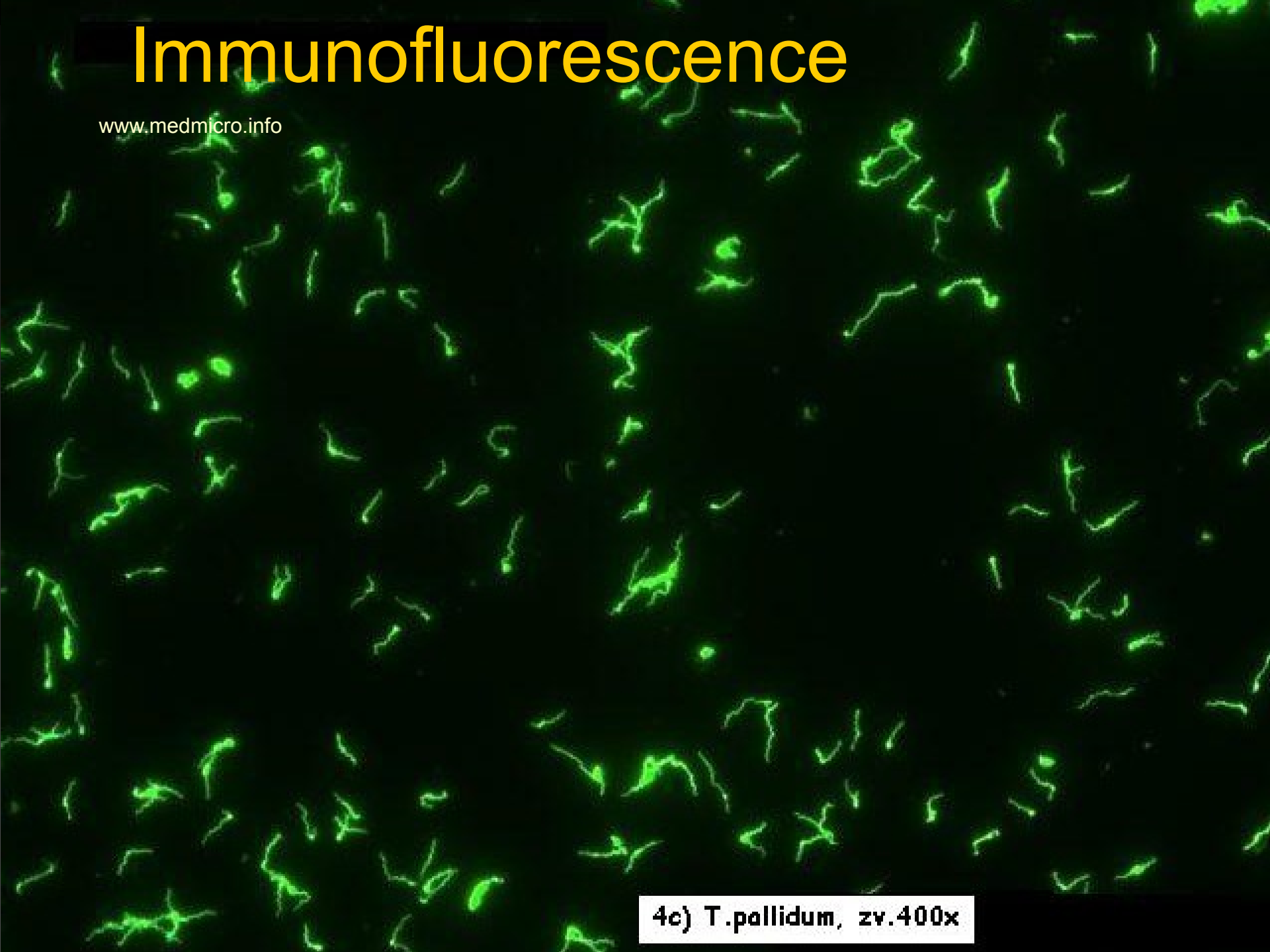

4B) *T. pallidum* - zástin



Immunofluorescence

www.medmicro.info



4c) *T. pallidum*, zv. 400x

Treponema: indirect methods

- We use **non-treponema tests**, where cardiolipin from bovine hearts acts as an antigen, and **treponema tests**, where we have a real antigen from *Treponema pallidum*
- **Diagnostics is composed of screening and confirmation.** We confirm everything that was positive or at least borderline at screening, in reasonable cases even negative results.
- **Screening** usually consists of a non-treponema and a treponema test
- **Confirmation** is performed by highly specific treponema tests

The most important indirect tests for lues

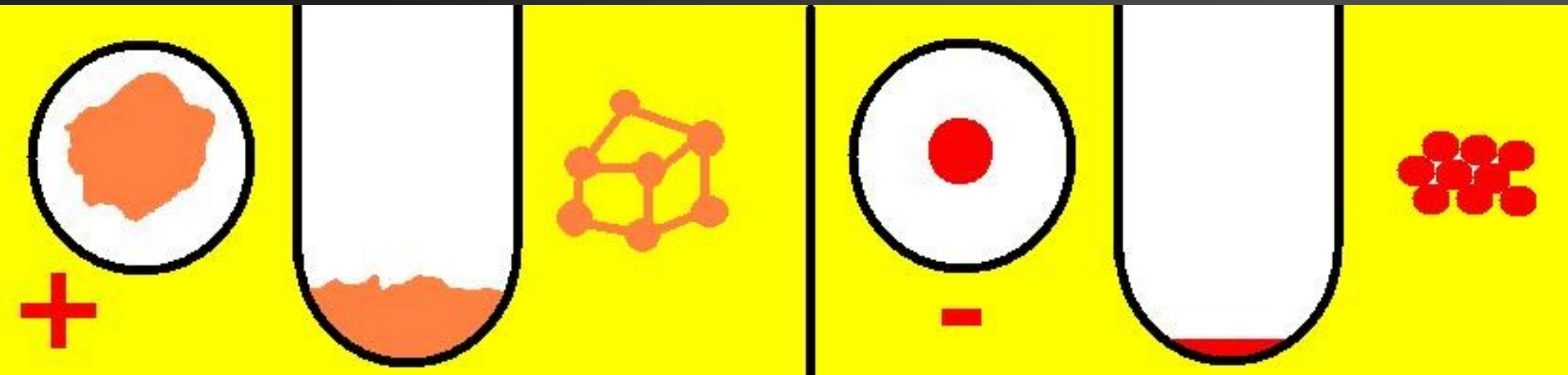
MHA-TP – test for passive haemagglutination.
now RBC use replaced by polycellulose

| | | |
|---|---|--------------|
| Historical | BWR – Bordet Wassermann | Nontreponema |
| Screening | RRR – Rapid Reagin Test <i>or RPR or VDRL test</i> | |
| | MHA-TP (TPHA) | Treponema |
| Confirmatory | ELISA | |
| | FTA-ABS (indir. imunofluor.) | |
| | Western Blotting | |
| <i>Historical, or superconfirmation</i> | <i>TPIT (Treponema Pallidum Immobilisation Test) = Nelson</i> | |

RRR and TPHA

- In **RRR**, the well with turbidity is positive (it looks like the positive control). It is necessary to shake the panel, otherwise the reaction would not be visible.
- **TPHA** is an agglutination on a carrier (RBC). A „potato shaped formation“ is positive, a dense dot is negative.

MHA-TP – to remember

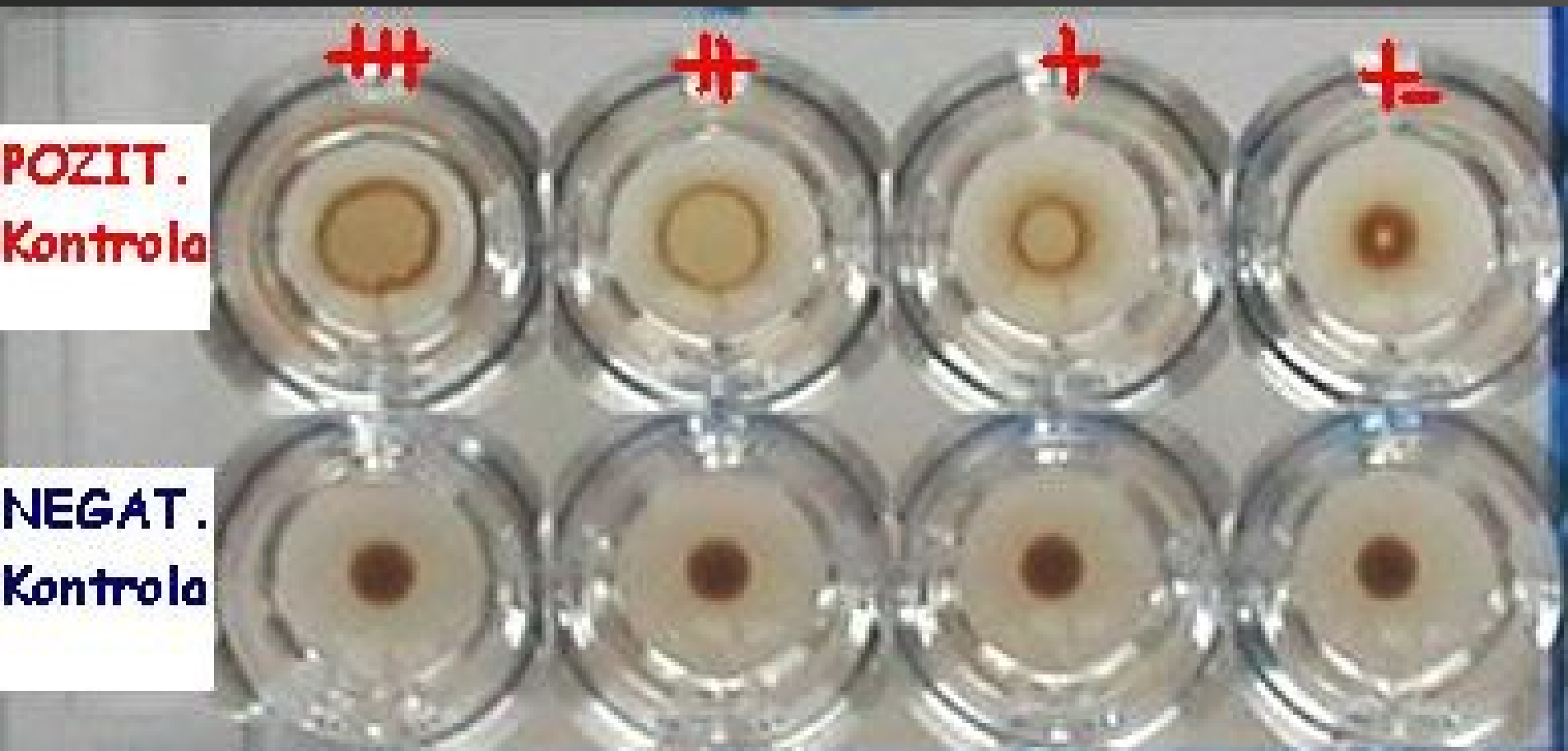


- **Positive** – agglutinate formed, viewed from up as **clot of irregular shape**
- **Negative** – RBC (polycelulose particles in newer variant) fall to bottom forming a **regular dense dot** viewed from up

RRR – reading: turbidity = positive, no turbidity = negative

TPHA – reading:

www.medmicro.info



Indications for confirmation

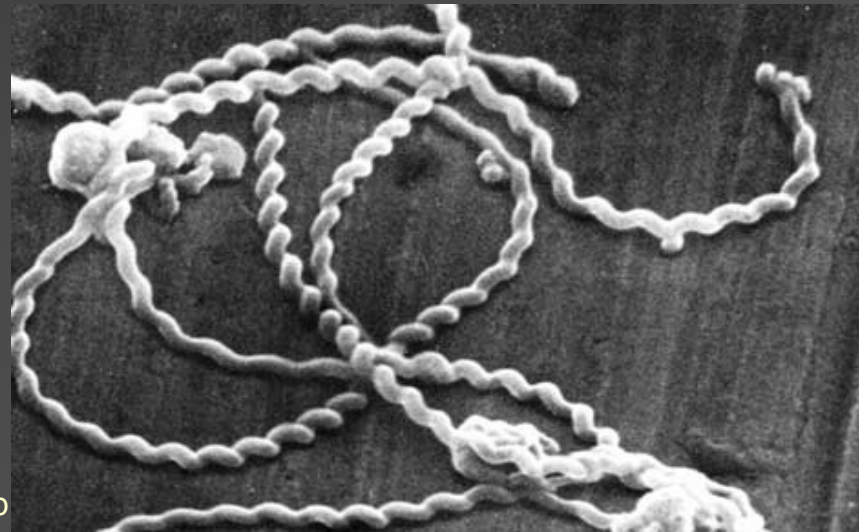
- Screening reactions are performed always, when somebody is to be tested for syphilis (including e. g. pregnant women that are not at all supposed to be positive). Screening reactions are performed only qualitatively or semiquantitatively
- Indication for confirmation is:
 - any positive or at least borderline result in RRR and/or MHA-TP reaction, OR
 - presence of suspicious lesions on body, or anamnesis of risky sexual intercourse – here even in case of negativity of both reactions

ELISA, Western blotting and PCR in spirochetal diagnostics

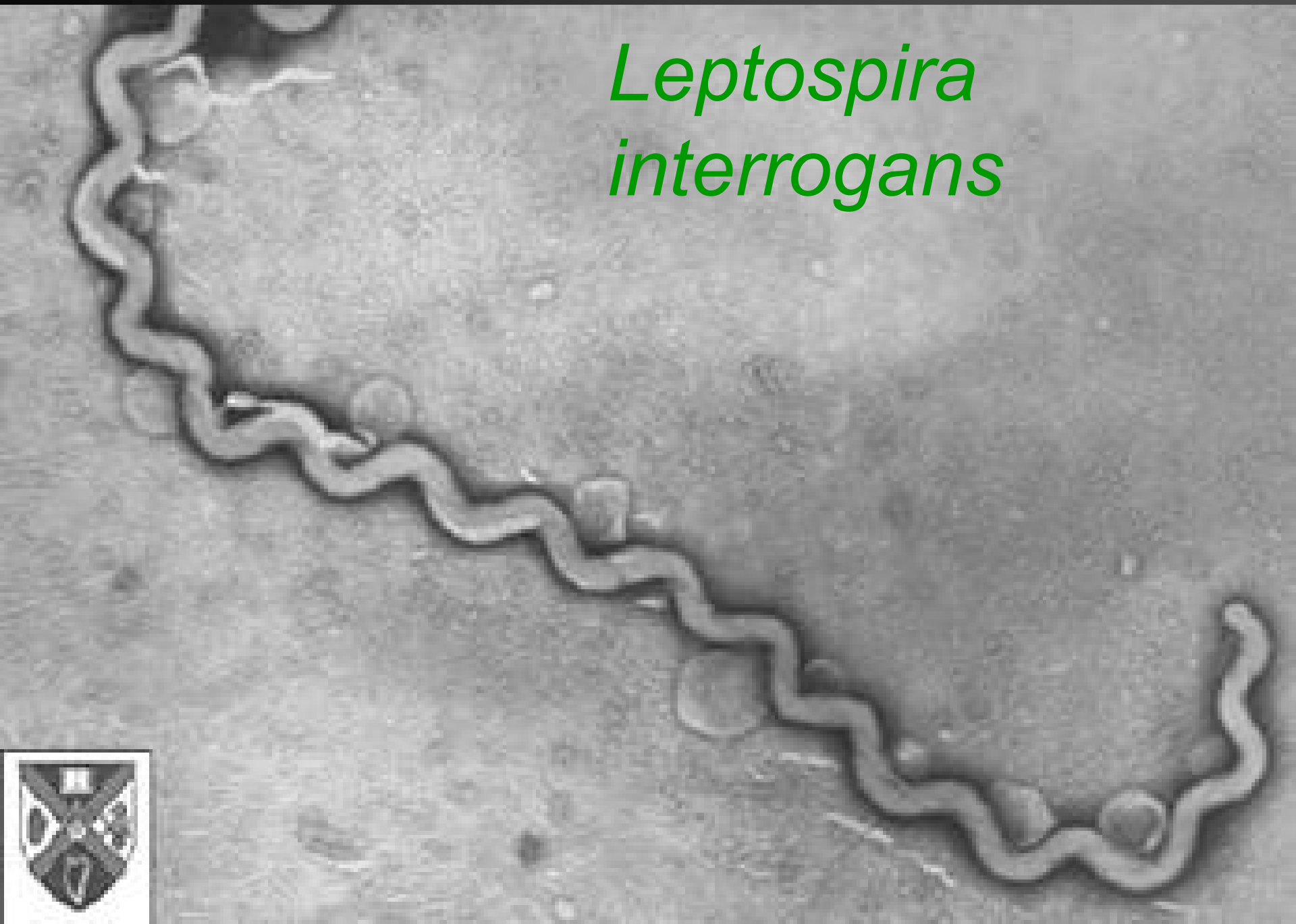

- ELISA, Western blotting and PCR – all of them are used in spirochets similarly as in other microbes – see J09 and J10 topics in spring term.
- Positive are patients with values of absorbance higher than a given value (CAL – calibration well, cut off etc.)
- Examination of IgG and IgM antibodies is important, mere IgG positivity is just a proof of a previous infection.
- PCR is used in diagnostics of syphilis and Lyme disease. It is usually positive sooner than methods detecting antibodies.

Borrelia and leptospira – course of investigation

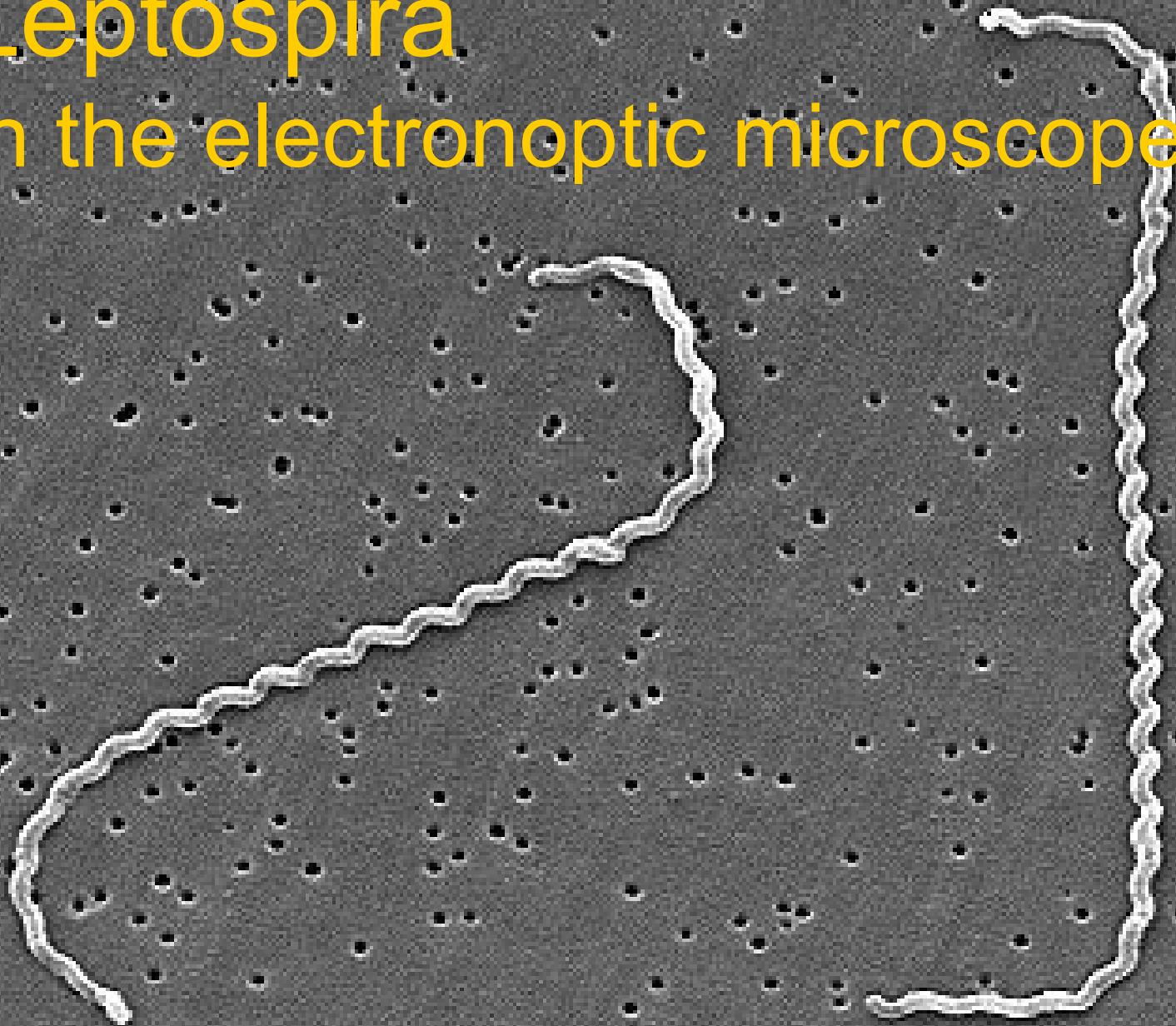- **Borrelia:** Mostly serology, event. PCR. In serology, IgM (typical for an early infection) and IgG antibodies are detected using ELISA method, positive finding is confirmed by Western blotting. Western blotting is more specific.
- **Leptospira:** Dark field microscopy and culture in special medium are used



*Leptospira
interrogans*

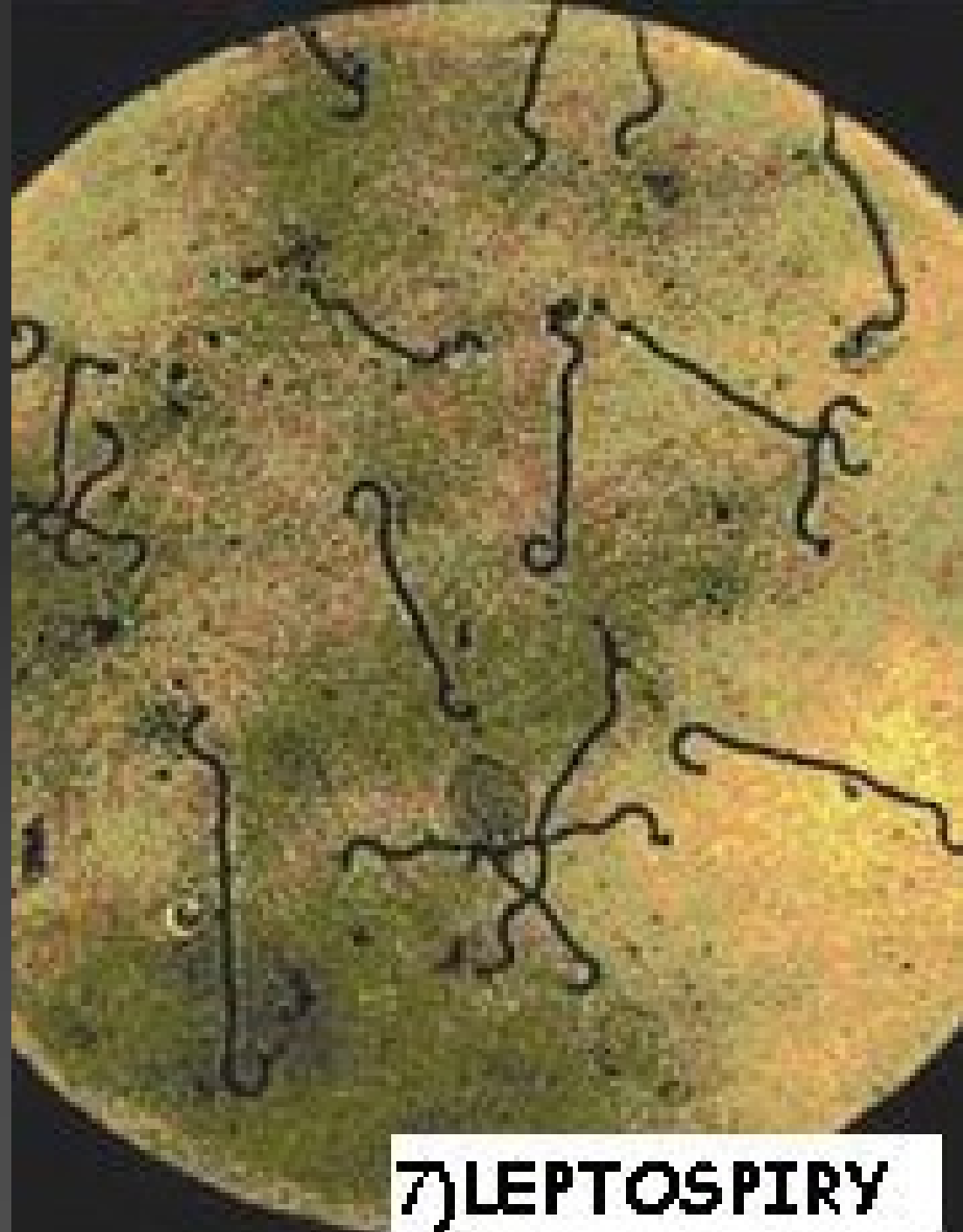

Leptospira in the electronoptic microscope



Leptospiral diagnostics

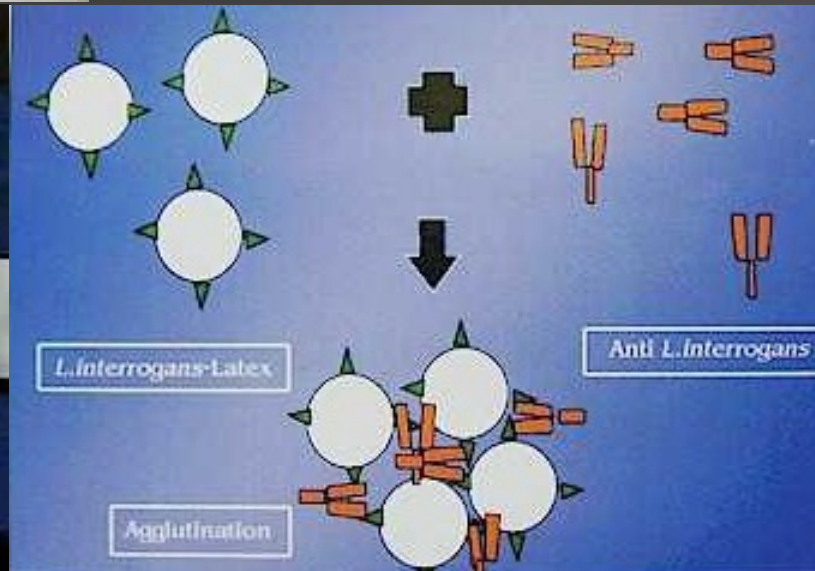
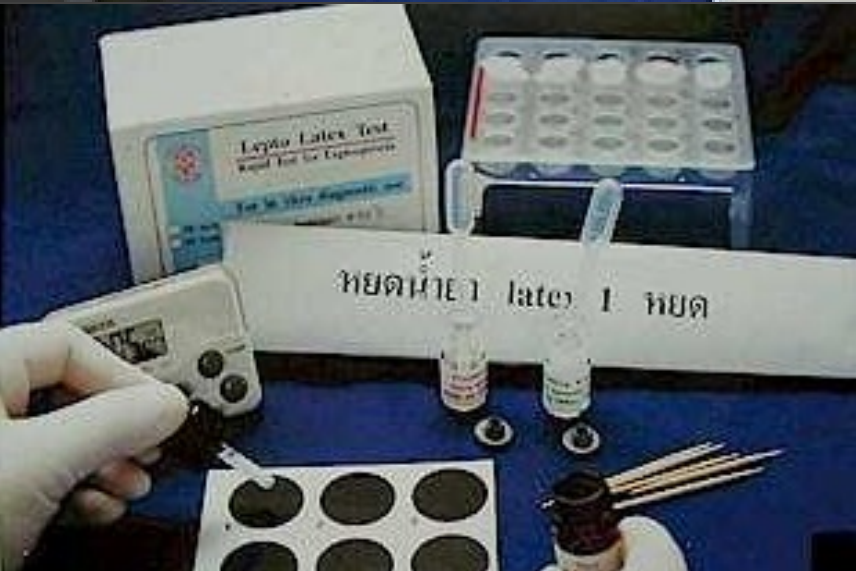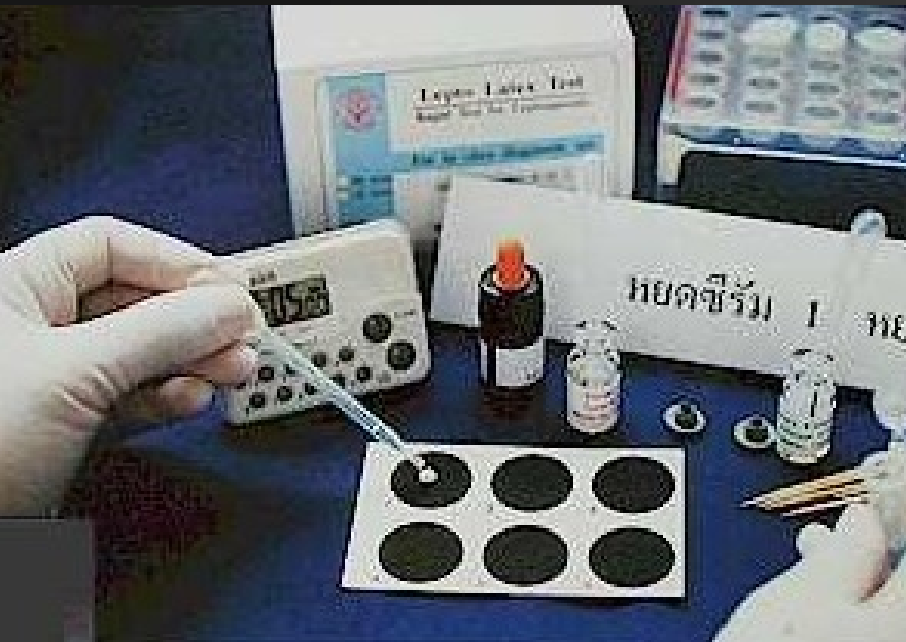- Microscopy of leptospira



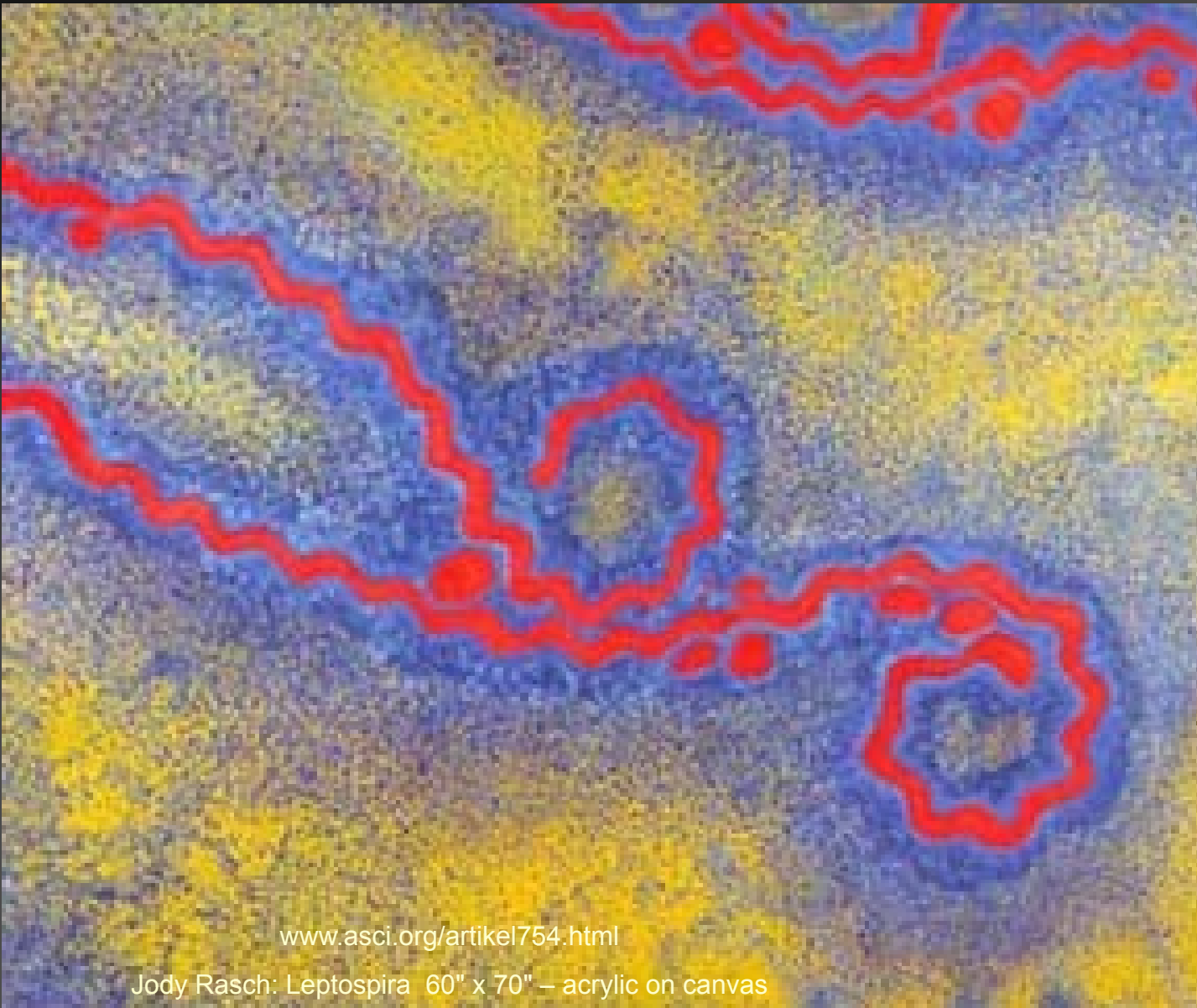
LEPTOSPIRY

More diagnostic opportunities in leptospira (latex agglutination)

4× www.thailabonline.com



The End



www.asci.org/artikel754.html

Jody Rasch: Leptospira 60" x 70" – acrylic on canvas

