

Prosthetic V.

Complete denture

Complete denture

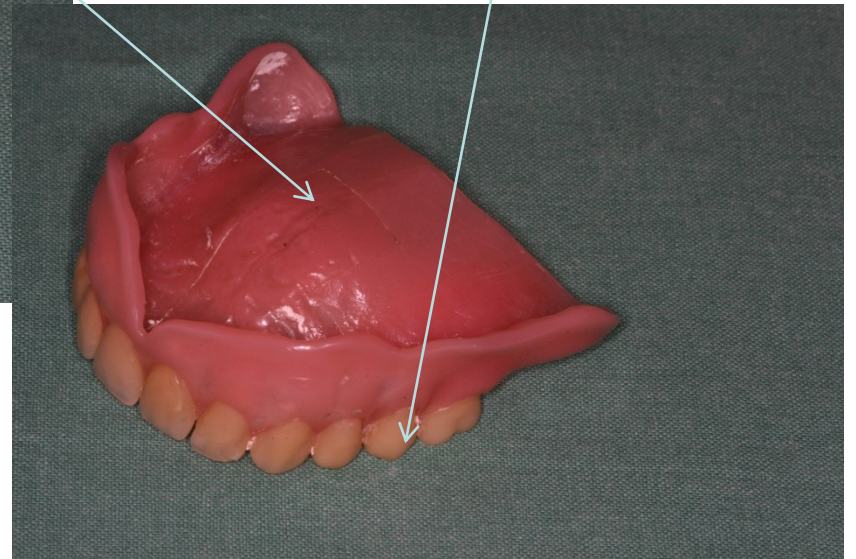
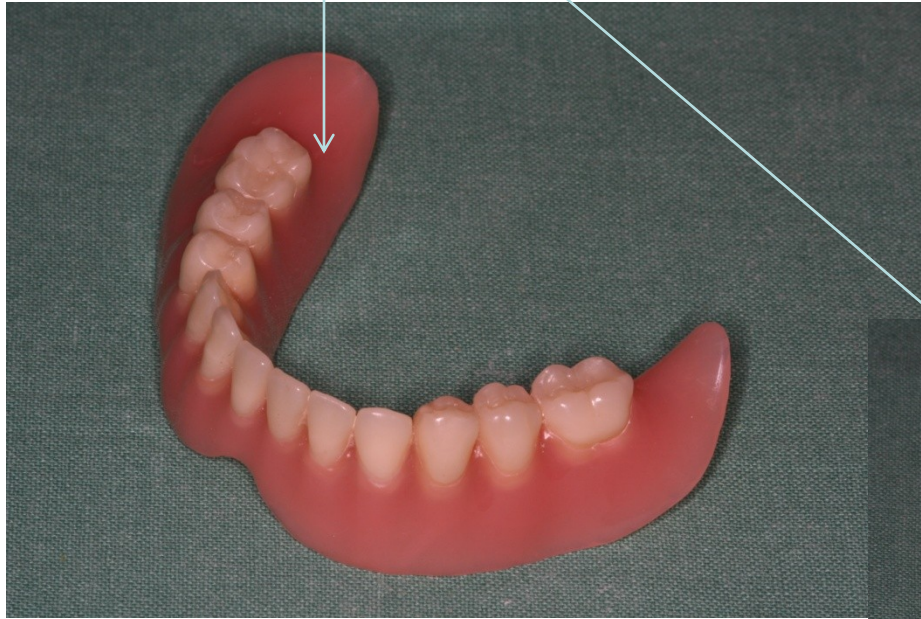
Replaces all teeth in the jaw with exception third molars.

It consist of only one part- resin body:

- Base (made usually of acrylic resin – methylmetacrylate)
- Teeth (made usually of acrylic resin)

Base

Teeth



Edentulous jaws

- The transfer of occlusal forces – mucous (gingival only).
- Tissue supported (born) denture.

Retention

- Adhesion –a capillar pressure between the base and denture bearing area
- Viscosity of saliva
- Resilience of the mucosa
- Marginal seal

Stability

- The ability to face up to horizontal forces

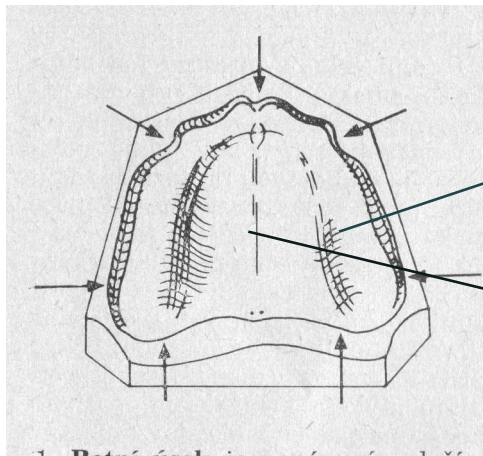
Most important: position of artificial teeth

Denture supporting area

Maxilla

- Area of primary loading - the middle of alveolar ridge
- Area of secondary loading
 - vestibular part of the alveolar ridge
 - area of hard palate

Upper complete denture



Region of primary loading (alveolar ridge)

Region of secondary loading
(vestibular part of alveolar process, hard palate)

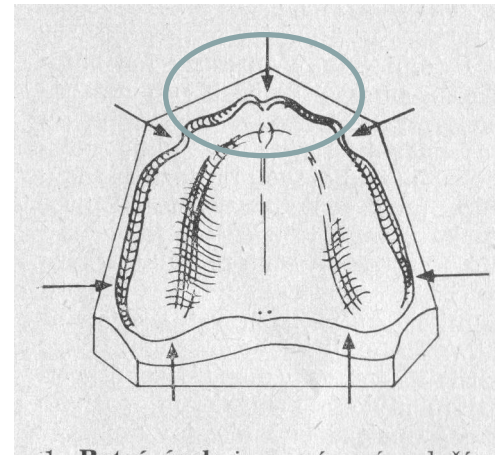
Marginal seal Maxilla

- Labial section

Between canines (crista canina)

Frenulum labii superioris (labial frenum)

The margin must respect these anatomical structures



Marginal seal Maxilla

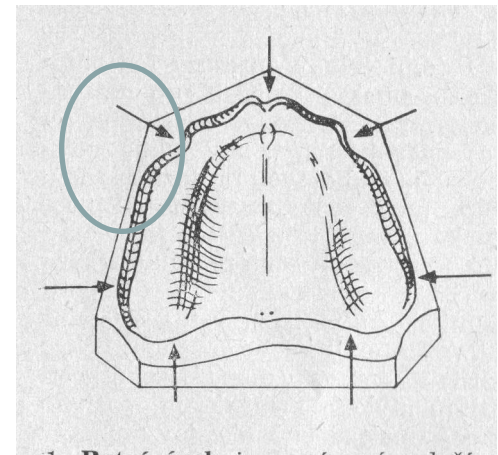
- Buccal section

Between crista canina and tuber maxillae

The margin must respect anatomical structures: buccal frenum with muscular fasciculus.

The margin must avoid them

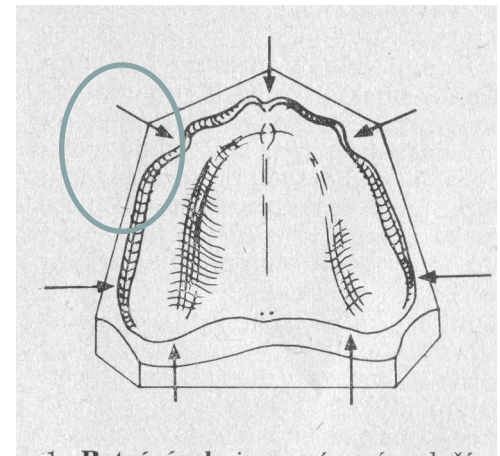
Upper facial vault – the denture supporting area can be extended.



Marginal seal Maxilla

Section tuber maxillae

The margin is lower and more narrow.



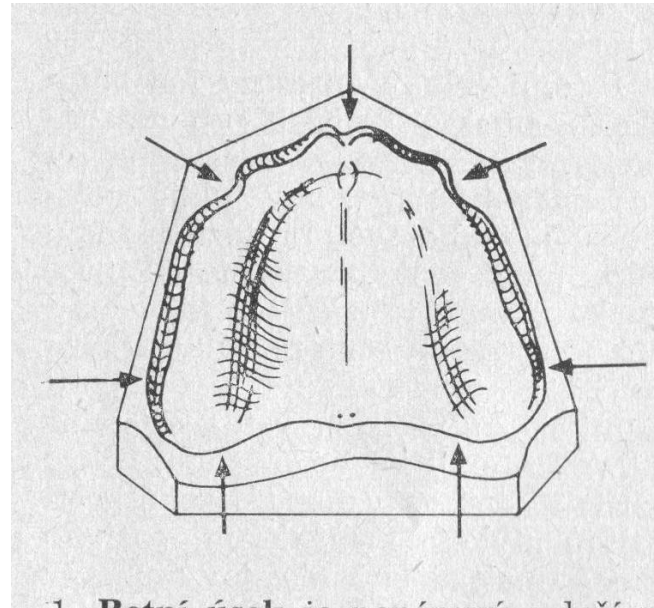
Marginal seal Maxilla

Palatal seal (post dam)

The border of the prosthesis is situated on the immobile part of the hard palate.

Between H and A line.

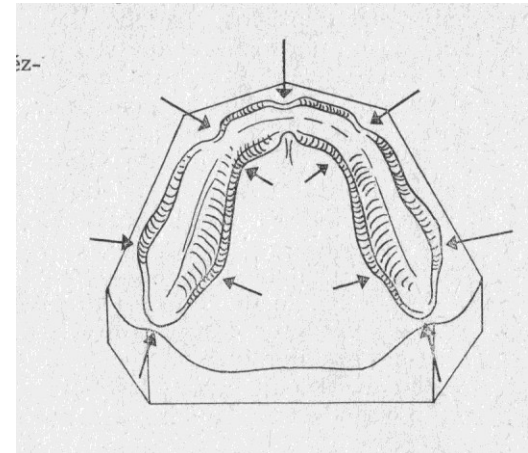
The border is like an arch avoiding the nasal spina



Margina seal Mandible

The denture supporting area
is limited on the alveolar ridge

In buccal vault an in sublingual region
It can be slightly extended.



Margina seal Mandible

Labial section – similar to maxilla, between canine crists, frenum in the middle.

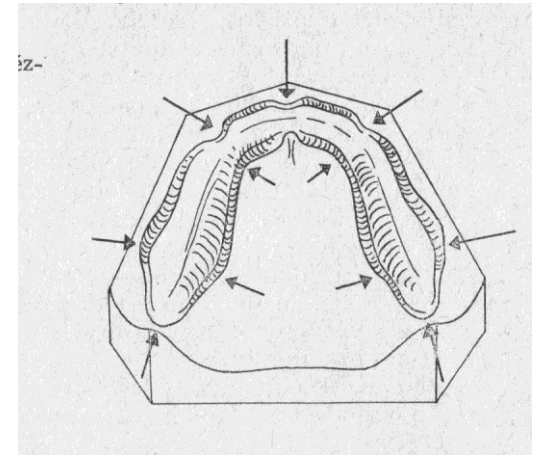
Buccal section – between canine crist and m.masseter. The border of the prothesis can be slightly extended.

M. Masseter section. The prothesis mus avoid this insertion

Distal seal (trigonum retromolare) – the border goes around it

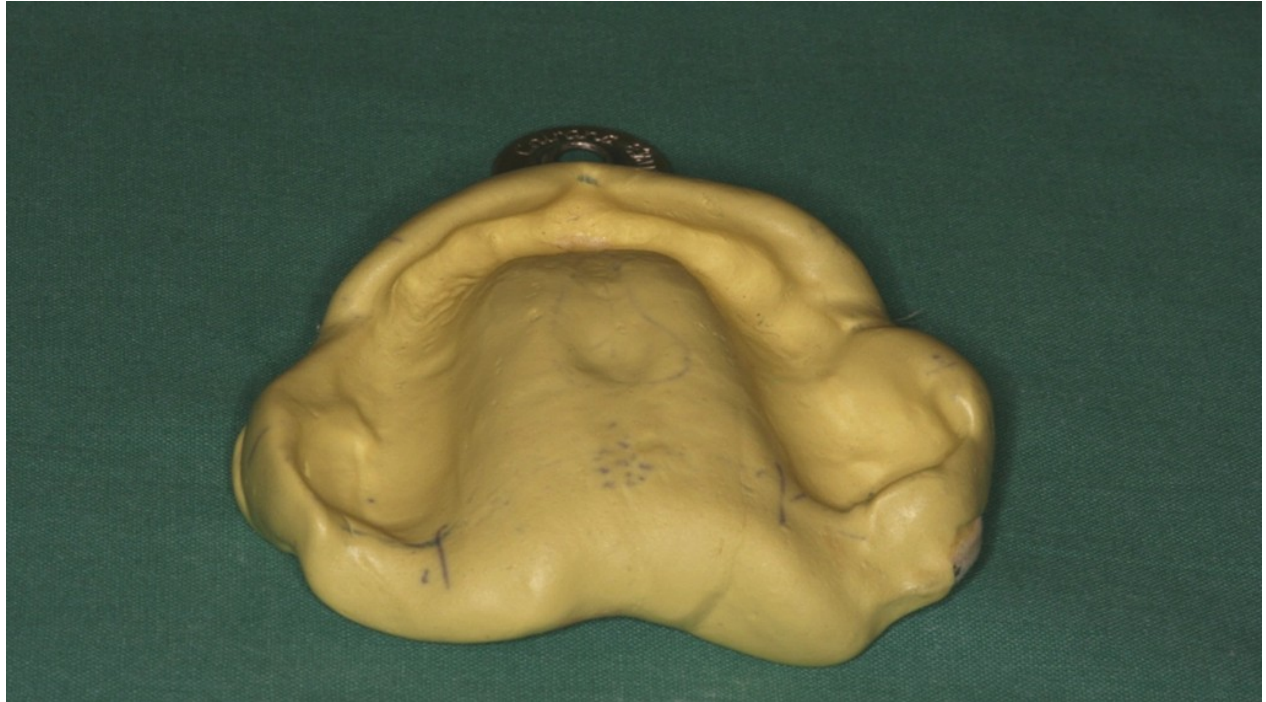Posterior lingual section- goes down and horizontal, ever over crista mylohyoidea

Central sublingual section – slight extension, avoiding sublingual frenum.



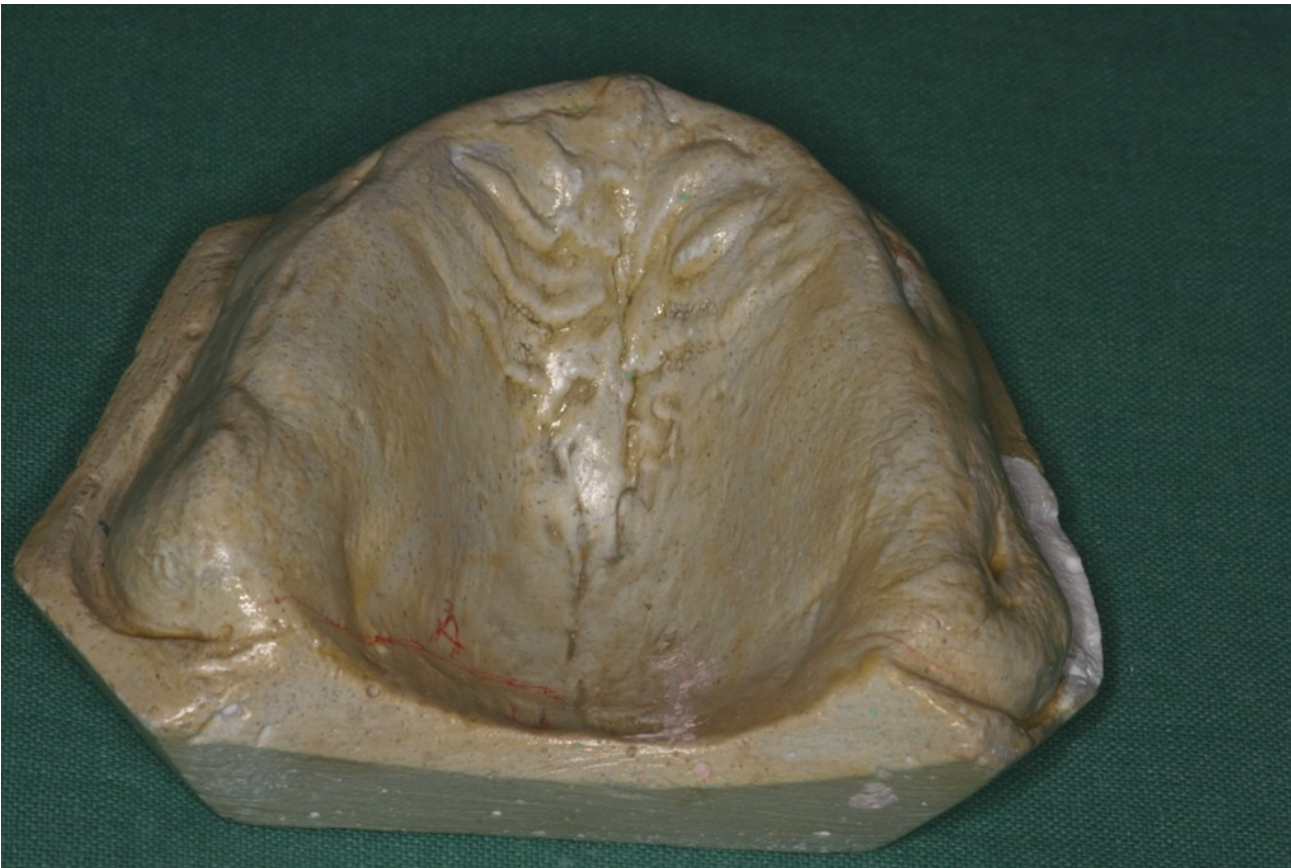Sequence of operation

- Taking impression (alginate the best choice)



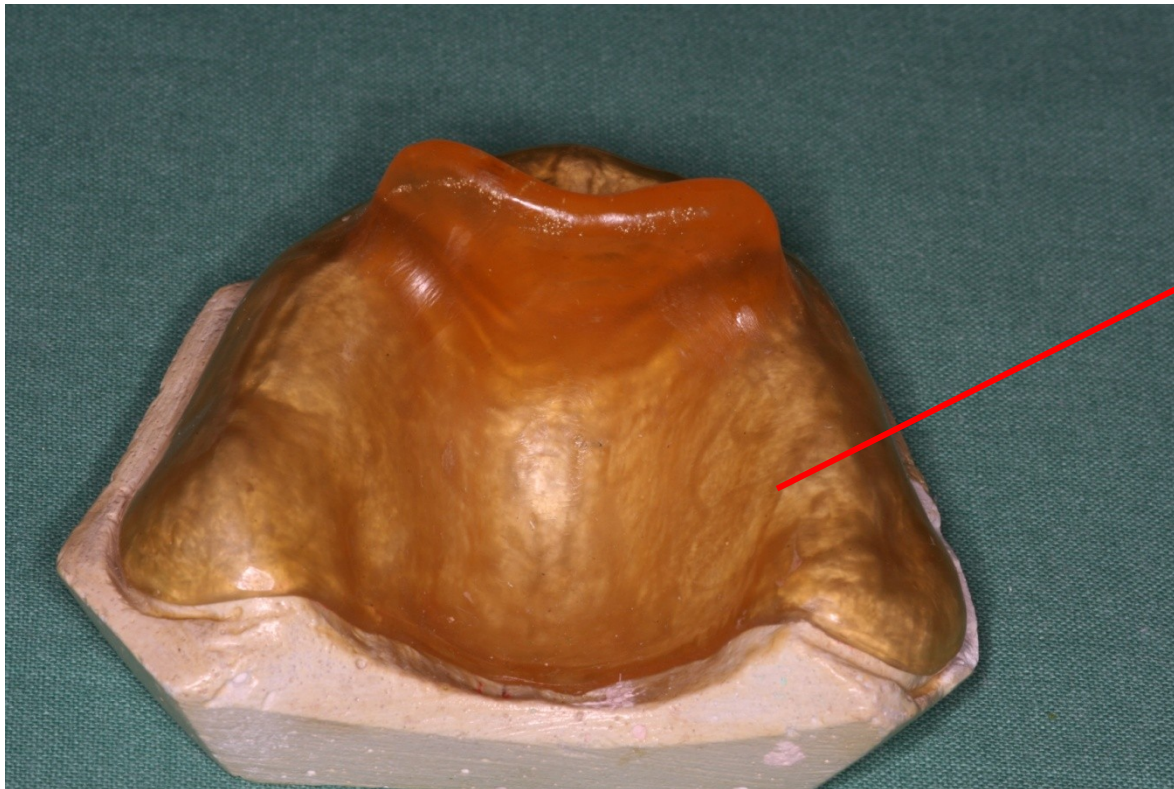
Sequence of operation

- Pouring: gypsum model



Sequence of operation

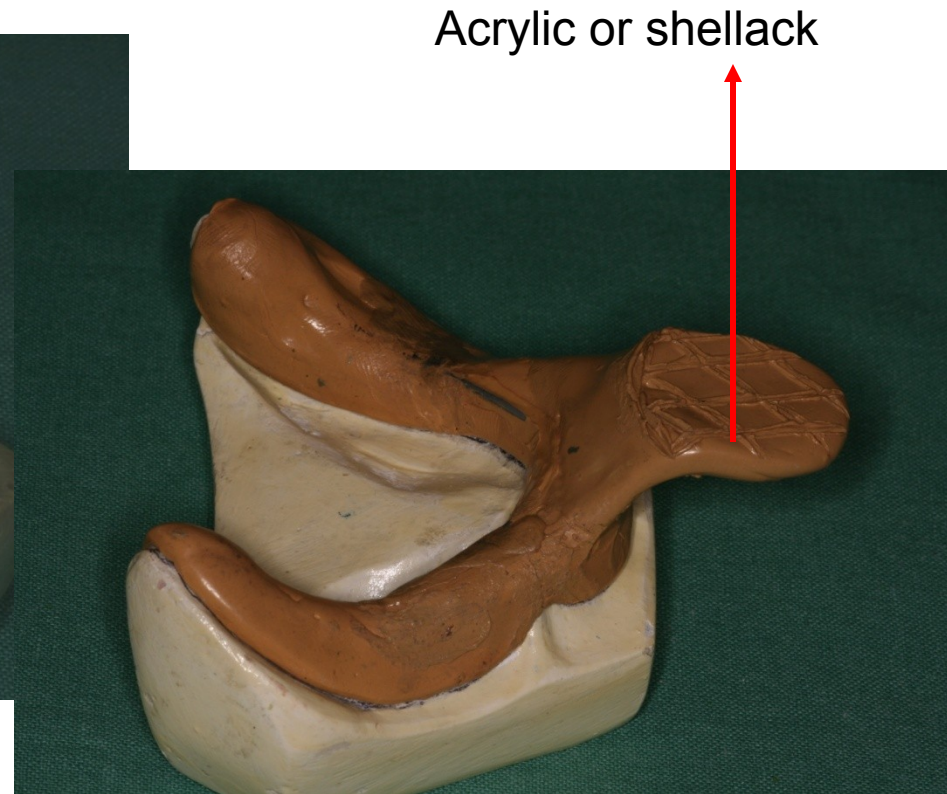
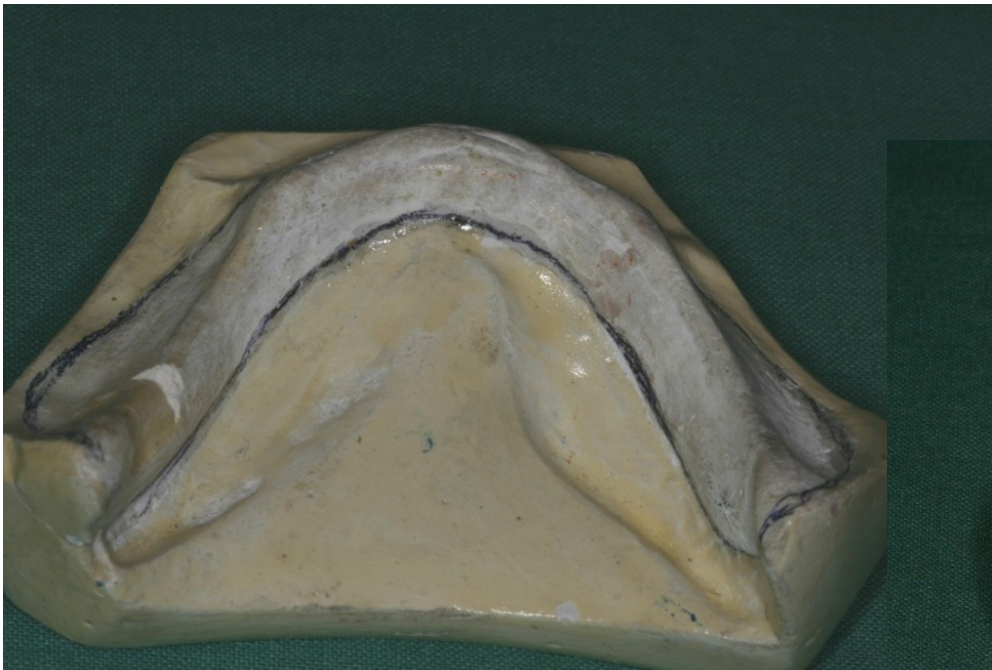Fabrication of the individual impression tray



Acrylic or shellack

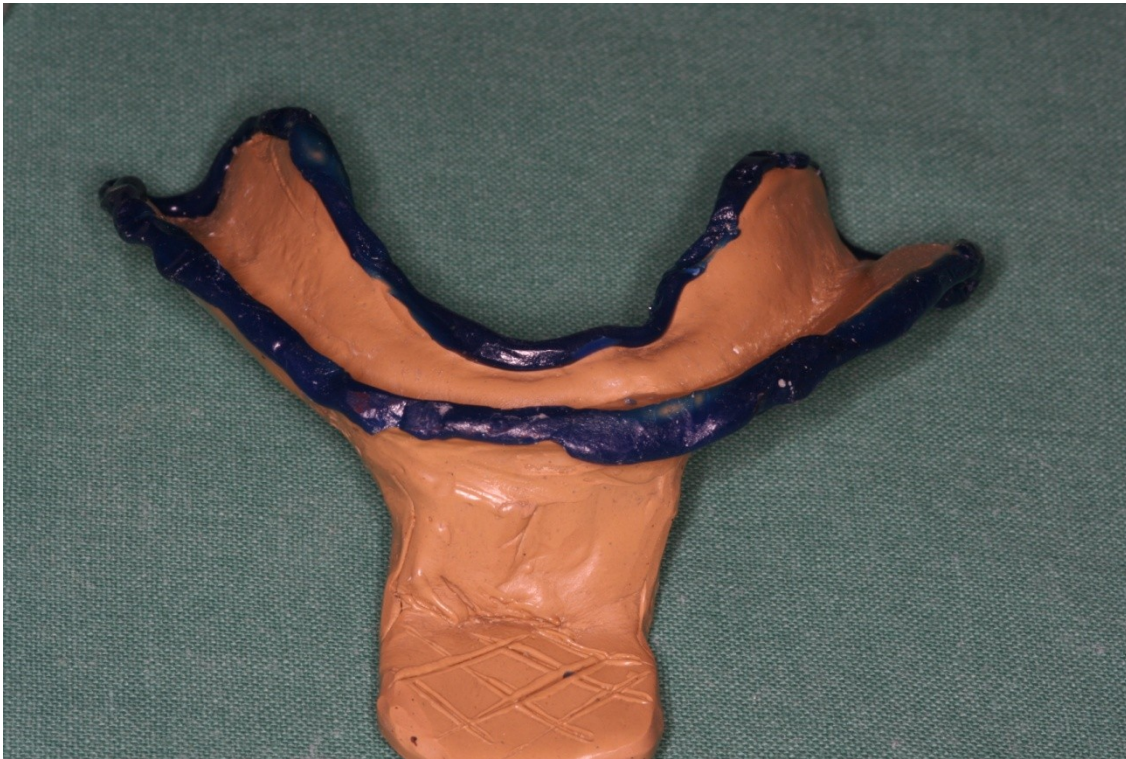Sequence of operation

Fabrication of the individual impression tray



Sequence of operation

Ranging with the special low – fusing wax (the functional tray)

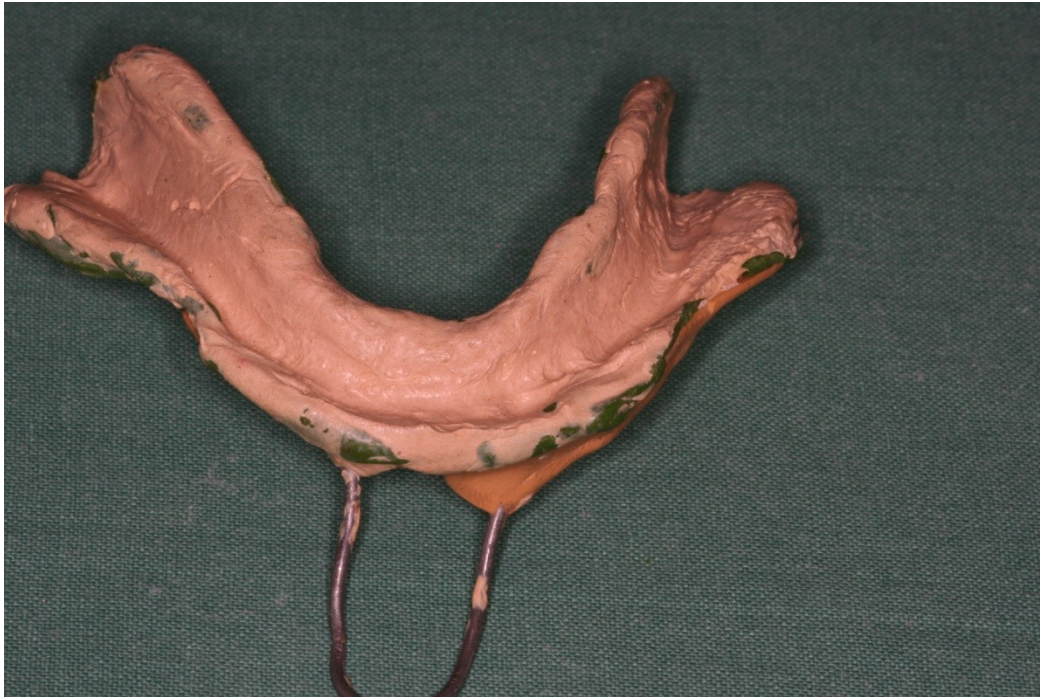

This procedure is done in the patient. The tray must be accurate without any excess, the wax makes the tray more precise patient moves with his/her lips and cheeks – the function is important

After this procedure the tray is called the functional tray

Sequence of operation

Functional impression

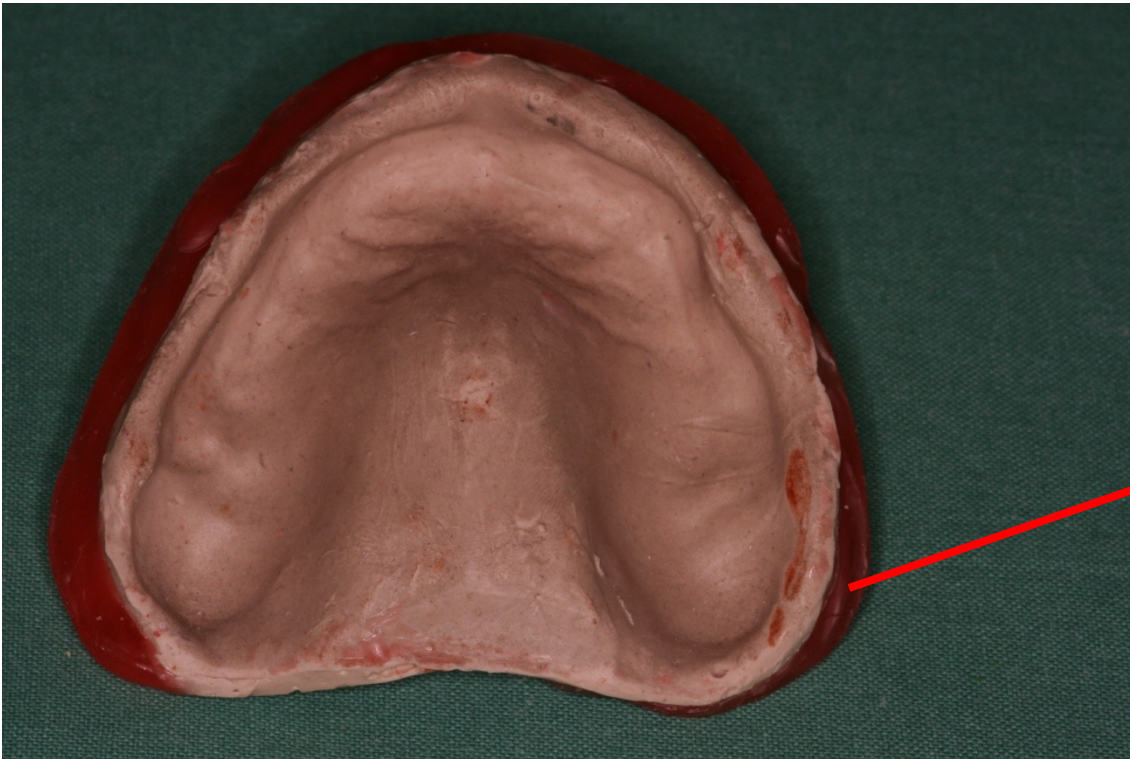


The impression after that is called the functional impression. During this procedure patient is moving with his/her lips and cheeks again.

The most suitable material is the zinkoxideeugenol paste.

Sequence of operation

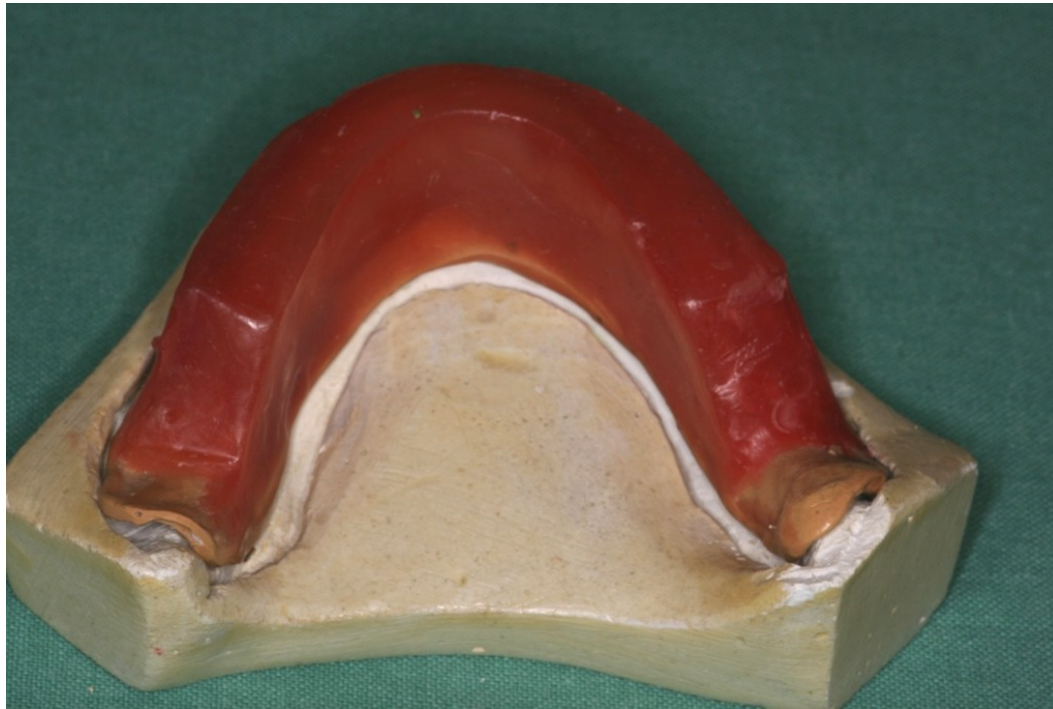Ranging of the impression with the wax



The border of the functional impression must be protected using the wax strip

Sequence of operation

Bite template

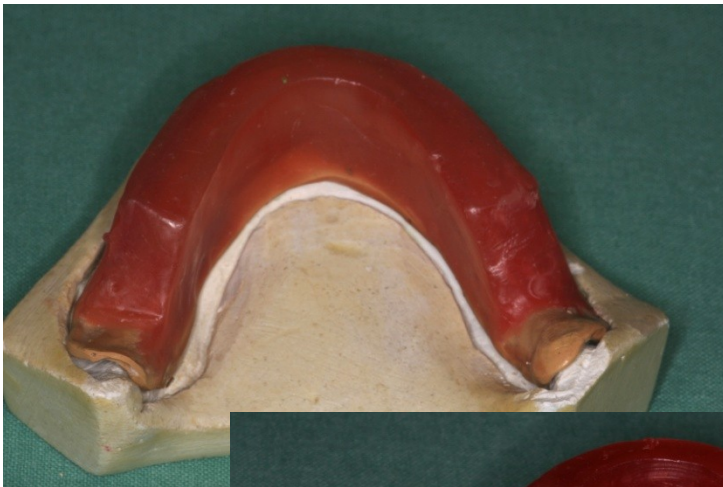

The bite template is fabricated as usual. The base is made of shellack or acrylic, the wall of wax.

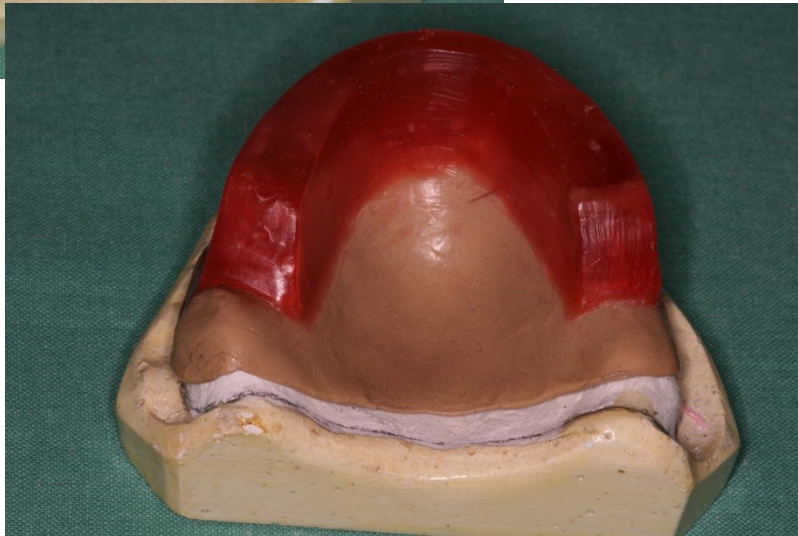The wall is approx. 0,5 cm wide in anterior area and approx 1 cm in posterior area. It terminates the region of 1st.molar.

Sequence of operation

Bite template



Lower



Upper

The bite template is fabricated as usual. The base is made of shellack or acrylic, the wall of wax.

Important terms

- Occlusal plane
- Incisal point upper and lower
- Bipupillary line
- Nasoaural plane
- Physiological rest position of mandible
- Occlusion
- Intercuspidation (intercuspation)
- Canine point
- Smile line

Physiological rest position of mandible

- This is position when the dental arches are not in contact, the mandible is in free position between muscles.
- If the patient sits normally the distance between dental arches is 2 mm.

Incisal point

- The point between incisal edges of incisors
 - upper incisal point
 - lower incisal point

Upper incisal point is more important for reconstruction of intermaxillary relation.
Its position is 2mm below upper lip.

Intercuspidation

Occlusal plane

- When the patient put both dental arches together (bites) the cusps in one dental arch fit into pits in the opposite dental arch. This is intercuspitation.
- The plane going through the upper incisal point and mesiobuccal cusps of the first upper molars is occlusal plane. All occlusal surfaces are inside in this plane.

Nasoaural plane

- The plane going through points:
Subnasale (the point below the middle of the nose)
Tragion (the most anterior point on the tragus)

In posterior area (premolar and molar) the nasoaural plane and occlusal plane are parallel.

Bipupillary line

- The line connecting the middles of both pupils.

The bipupillary line and the occlusal plane are parallel in frontal (anterior) area.

Overbite

Forebite

- The upper incisors overlap upper incisors

The distance between incisal edges upper and lower incisors is overbite.

The distance between incisal edges of upper incisors and labial surfaces lower incisors is forebite.

What can we recognise in edentulous patient?

- Rest position of mandible
- Bipupillary line
- Nasoaural plane

What can we reconstruct using the bite template?

Occlusal plane

- 2mm below the upper lip
- in anterior area parallel to bipupillary line
- in posterior area parallel to nasoaural plane

Incisal point

Canine point

Line of smile

Vertical relation

Two markers on the face

- Subnasale
- Mention

Rest position of mandible

Measurement of the distance of these markers (strip of the paper)

Vertical relation

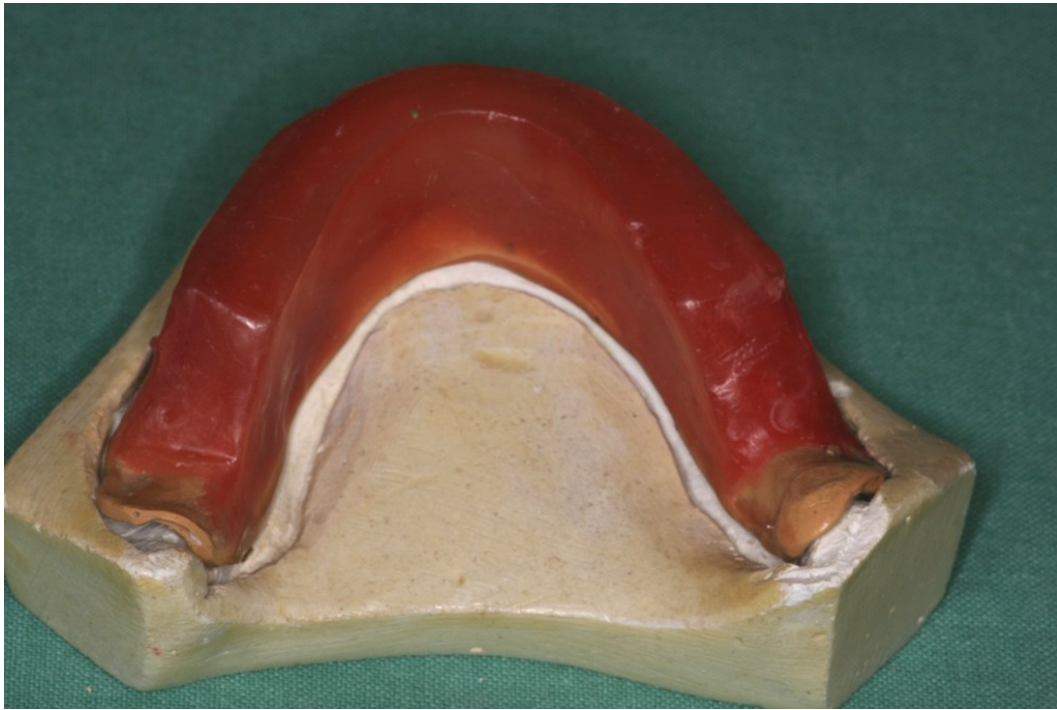Upper bite template is put into the oral cavity – there is marked

- a line in frontal area parallel to bipupillary line in frontal area 2 mm below the upper lip
- a line in posterior area parallel to nasoaural line

The modellation knife is used, the surface of the bite template must be plane and smooth.

Vertical relation

- Lower bite template is plain cut, it must fit on the upper bite template.
- After that the distance between markers on the face is measured, the lower bite template is cut until the distance is 2 mm shorter in comparison to the distance in free position of mandible.



Sequence of operation

Registration of the intermaxillary relation(ship).

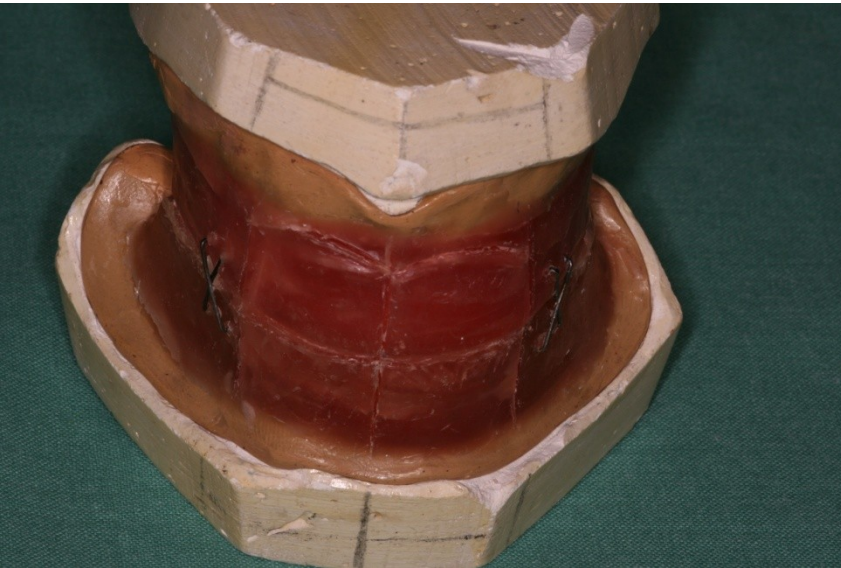
The procedure consist of two steps

1. Vertical relation

The neck of the patient is perpendicular to the horizontal plane. The occlusal plane must be parallel to the bipupillary line in the frontal area and to nasoaural line in the posterior area.

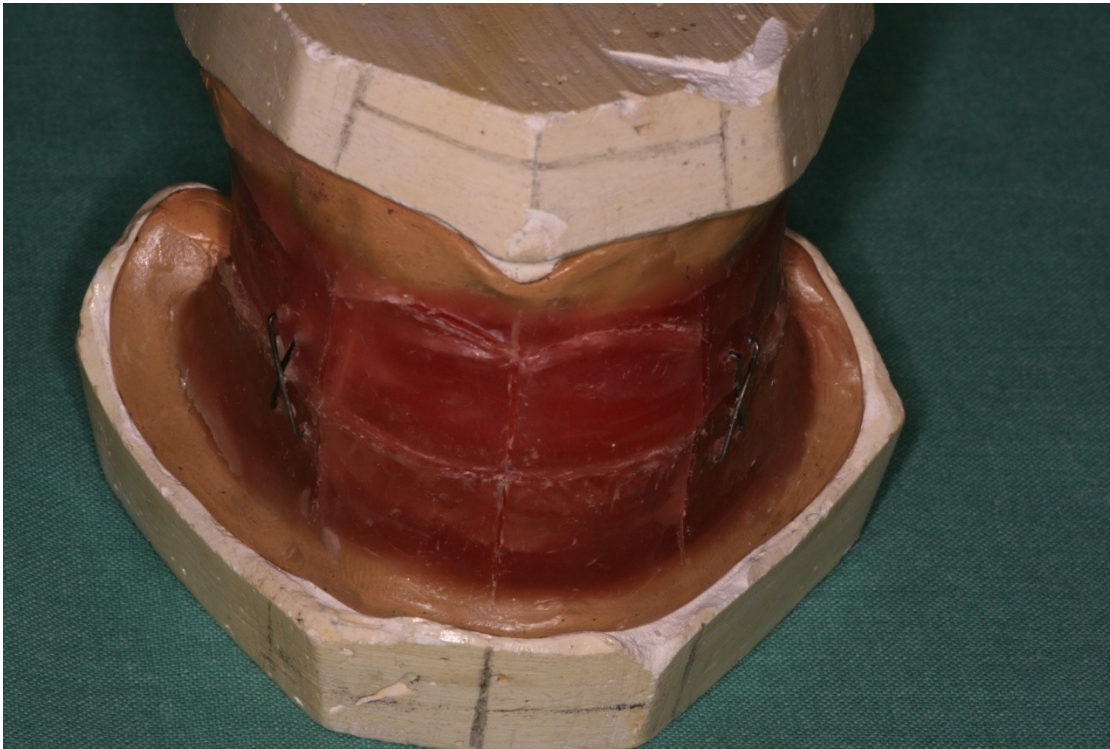
The wax walls must be plain cut, the height is according to the free position of the mandible. – physiological rest position.

After that the height is reduced – 2 mm. This is a vertical relationship



Sequence of operation

Registration of the intermaxillary relationship



The procedure consist of two steps

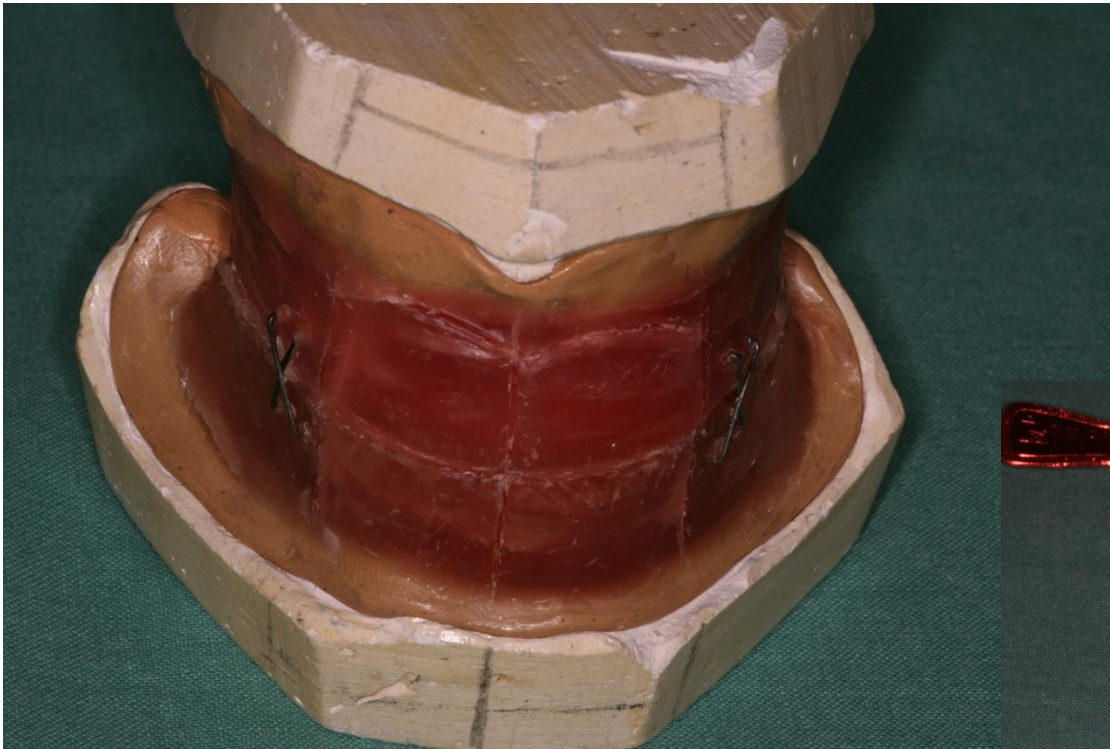
2. Horizontal relationship

The head of the patient is bent backward and he/she swallows. This can help us to find the horizontal relationship.

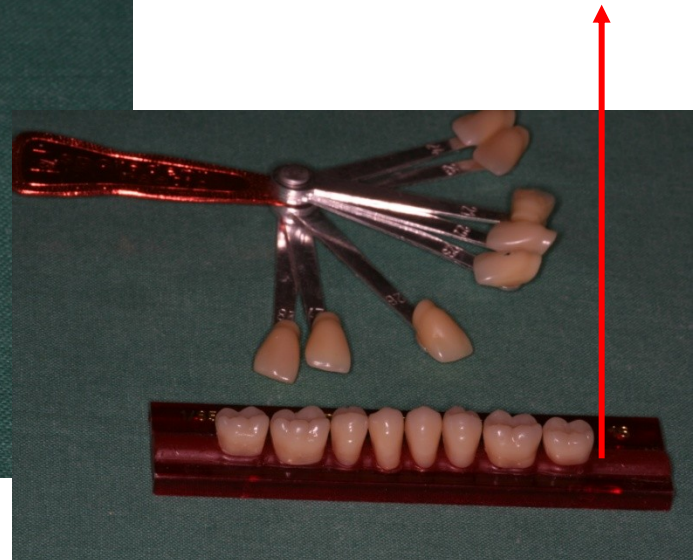
After these procedures the wax walls must be put together (with paperclips or wax or other material).

Sequence of operation

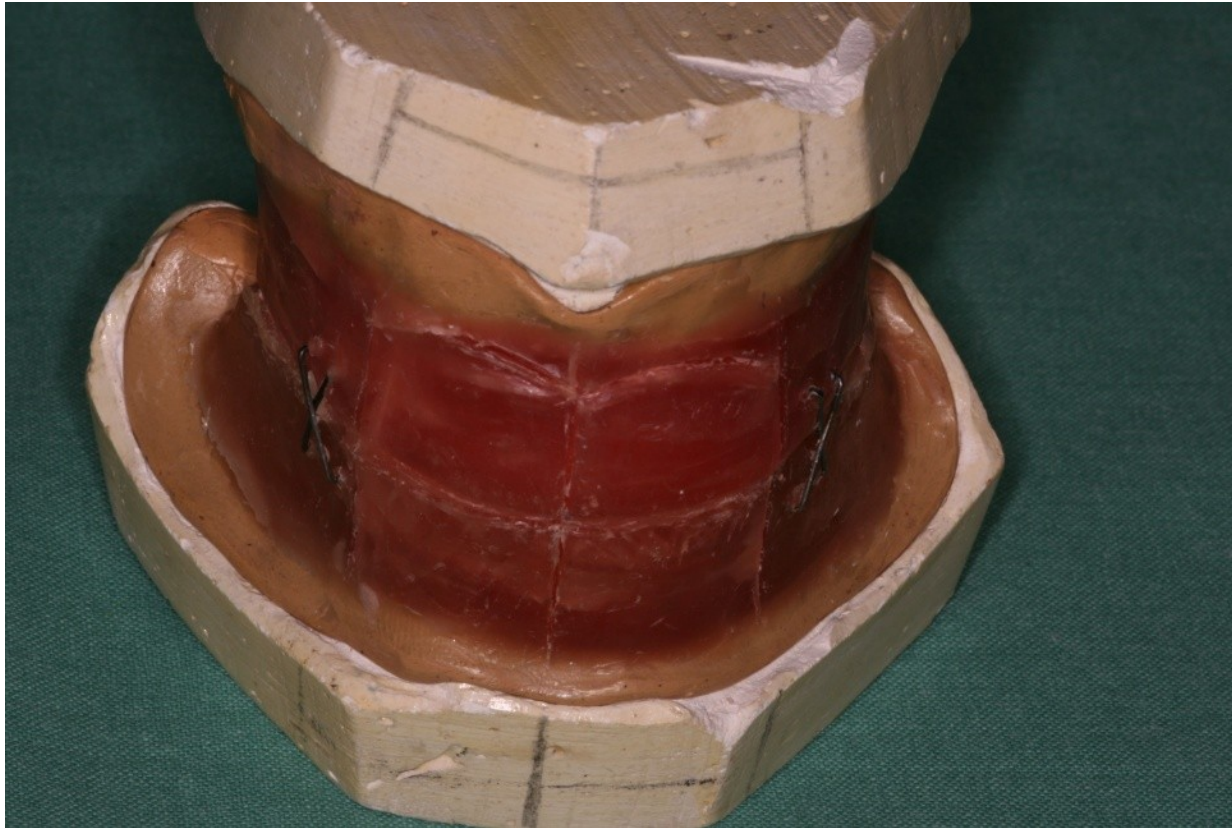
Registration of the intermaxillary relationship



After the registration the colour of teeth is chosen using the colour guide



The models are mounted into the occludor or articulator

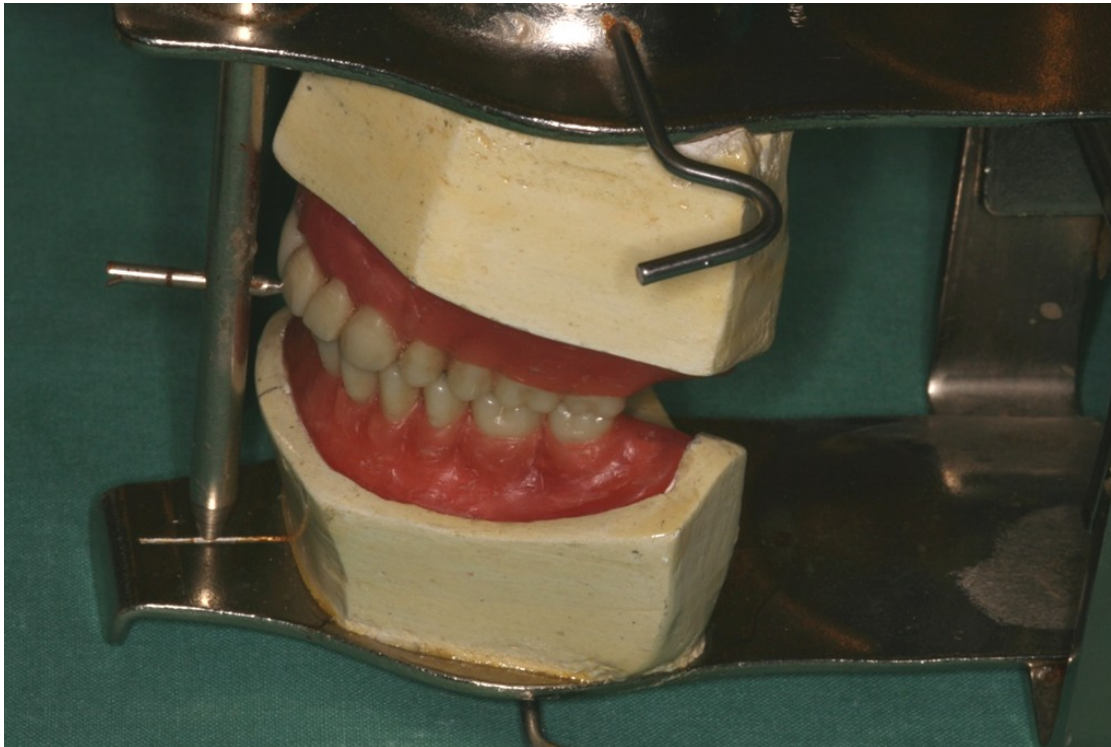


Important points must be marked

- Line of symmetry
- Occlusal plane
- Canine point (on the axis of the angle between the nose and nasolabial groove)

Sequence of operation

The wax pattern of the denture is made



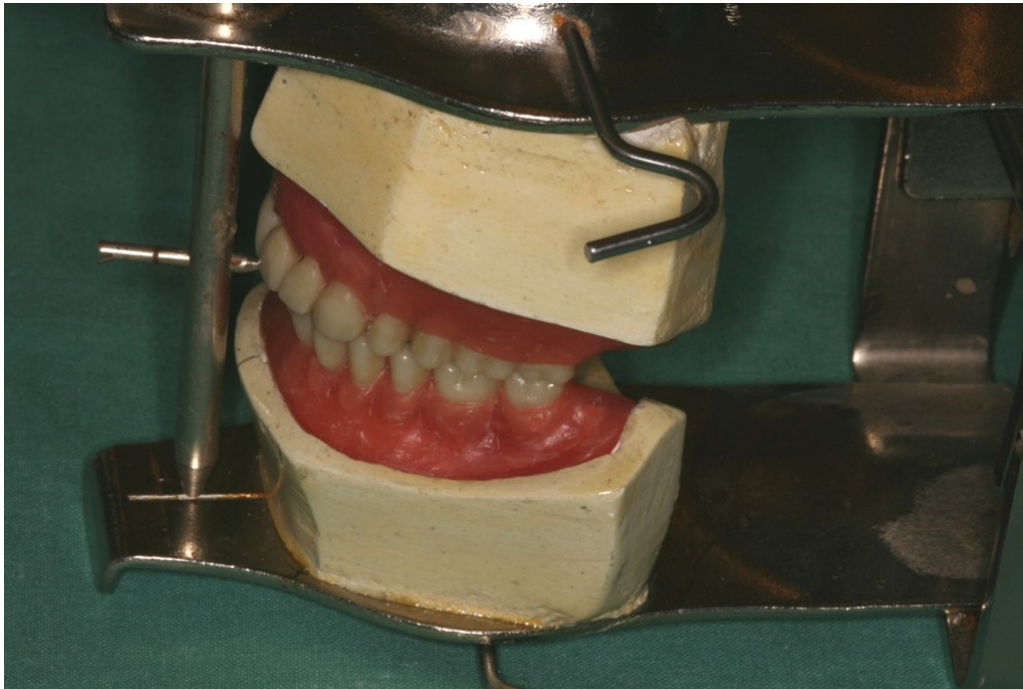
This is made of wax – base and acrylic teeth are built according to the registrate using the articulator or occludor.

The rules of the positioning of artificial teeth

- Posterior teeth – static rules (on alveolar ridge)
- Anterior teeth – aesthetic rules (before alveolar ridge) overbite, forebite.

Sequence of operation

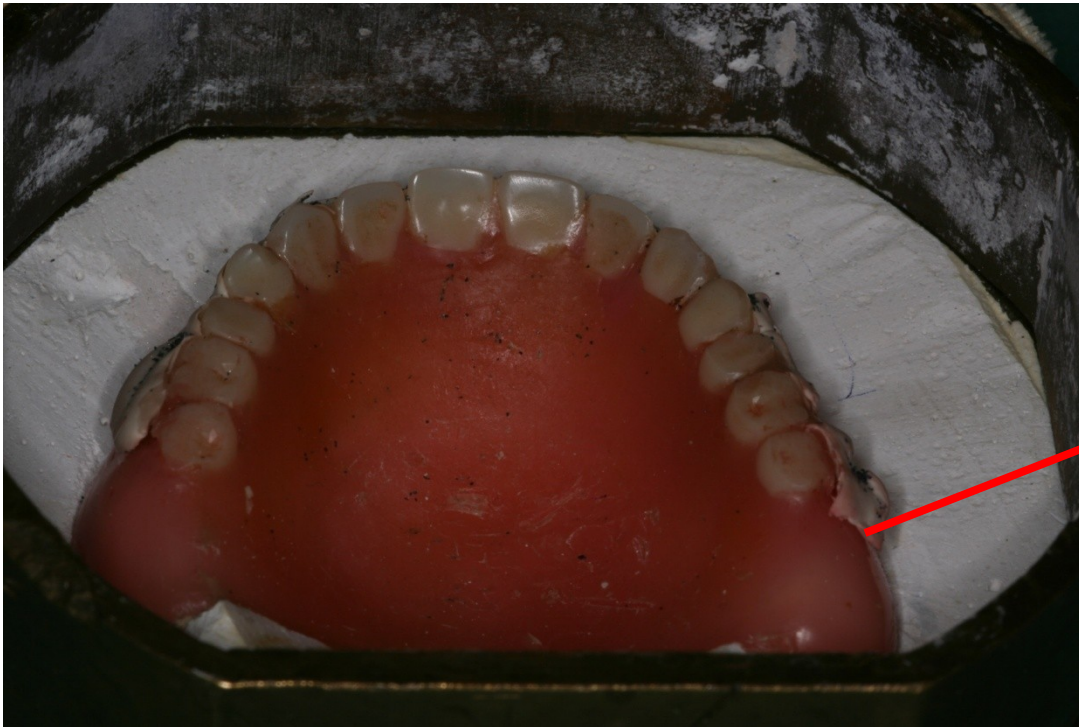
The wax pattern of the denture is tried out in the patient.



The dentist must check the colour, the form and the position of artificial teeth.

Sequence of operation

The wax pattern is flaked into a four parts flask using plaster

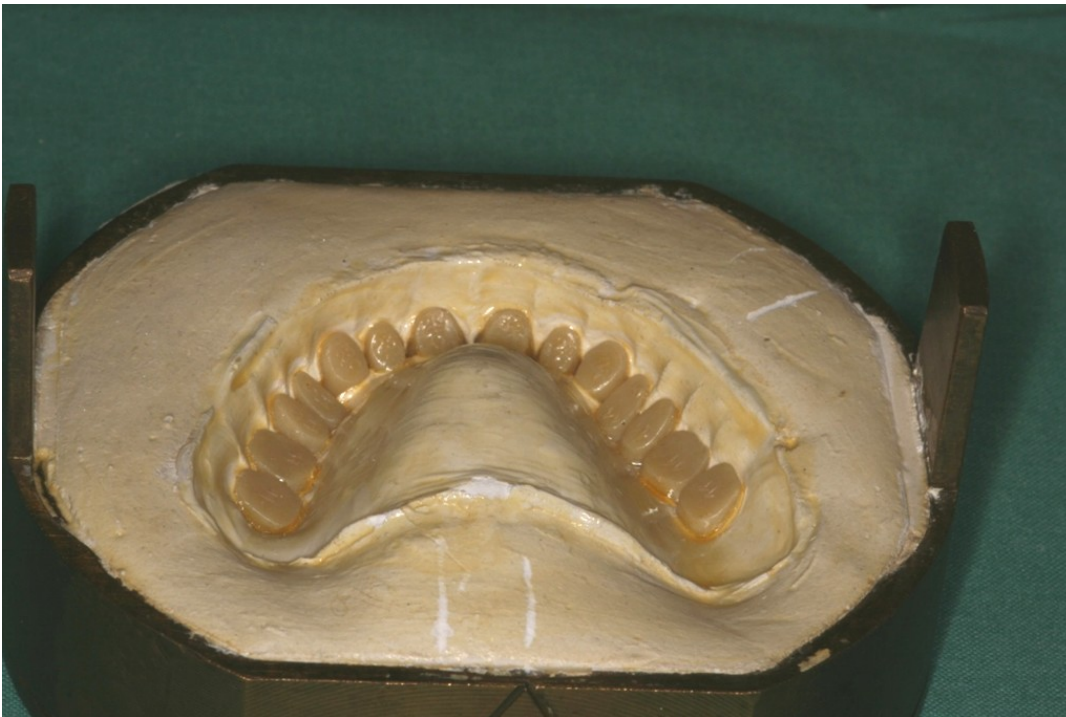

The teeth are insulated with a special silicone material.

The flask is closed and filled with the gypsum completely

Sequence of operation

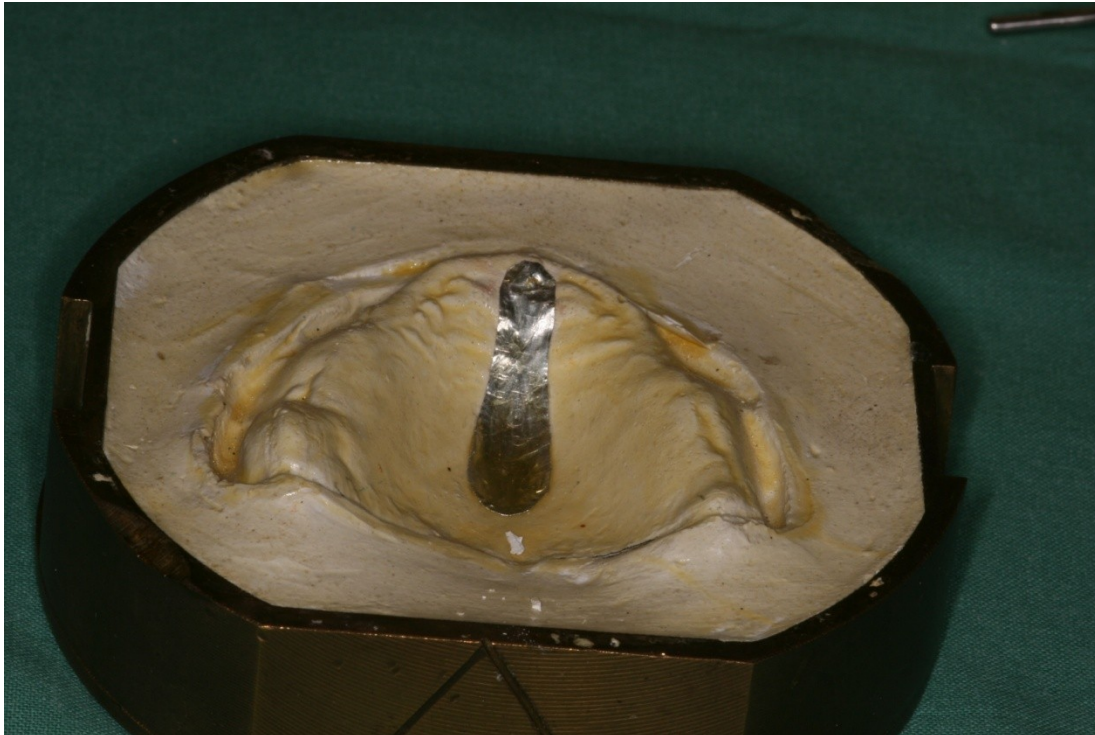- After the hardening of the plaster the flask is opened and the wax removed



The artificial teeth remain in one part of the flask

Sequence of operation

- After the hardening of the plaster the flask is opened and the wax removed



The wax is removed using hot water. This is the second part of the flask

A thin tin foil is put on some places, esp. on palatal suture in order to unload them. The insulating agent based on alginate is used. Without it the flask could not be opened

Sequence of operation

- After the hardening of the plaster the flask is opened and the wax removed



The resin dough is put into the form

Resin is mixed

- Polymer – powder
- Monomer – liquid

Ratio:

Polymer is partly dissolved in monomer

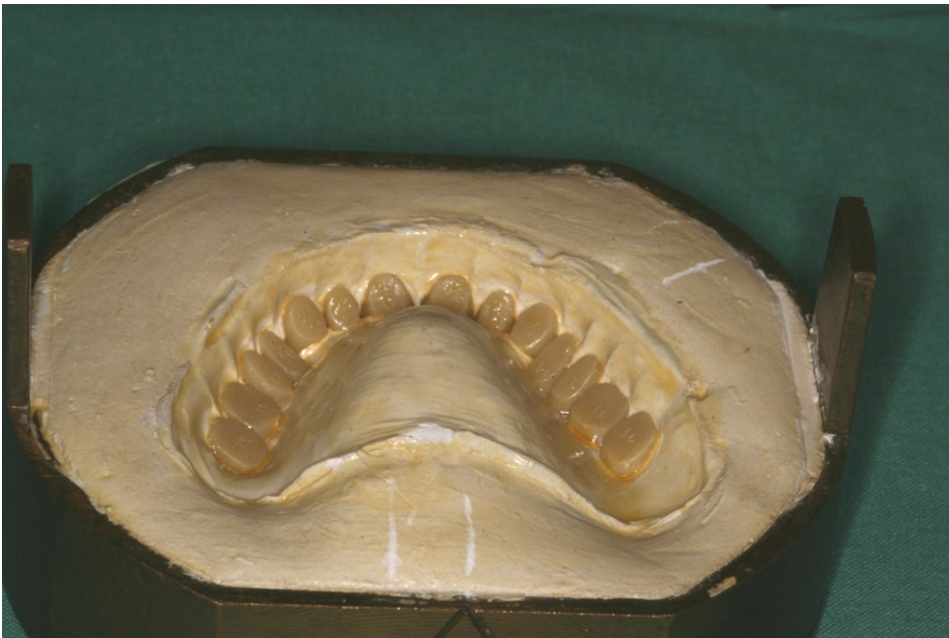The dough is pressed into the form and put into a special pressure machine. The excess is removed.

Sequence of operation

- The flask is closed and put into a special cleap.

The resin is polymerized using the 2,5 hours polymerization Schema:

1. During 1 hour reach the temperature 70°C ,
 2. 30min interrupt heating
 3. During further 30 min increase the temperature – reach 100°C
 4. 30 min stay on 100°C .
- After that let the flask cool slowly.

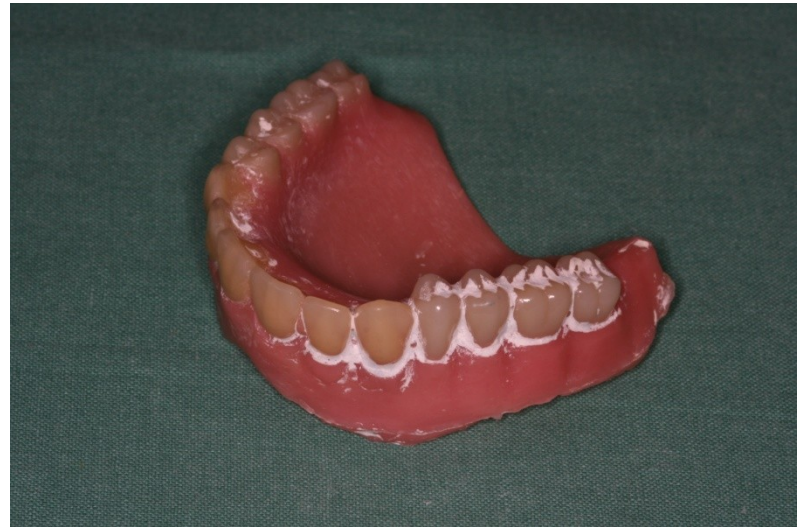
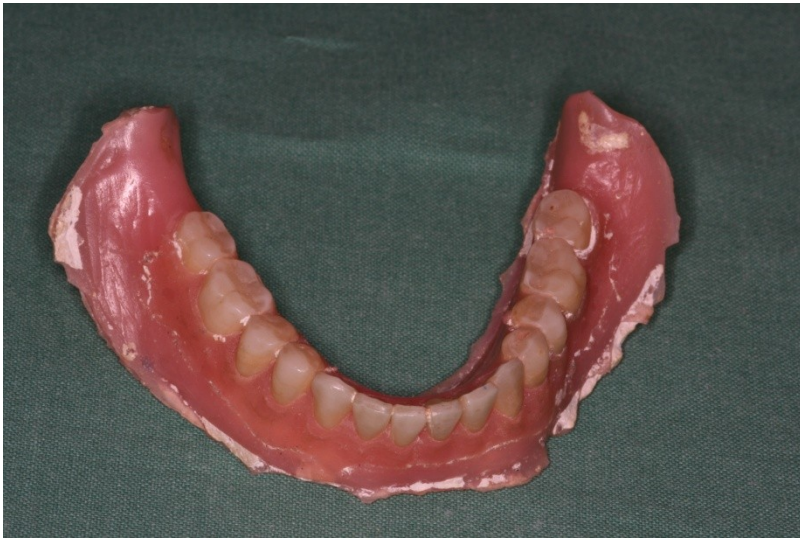
The four parts flask



Sequence of operation

- The denture is taken out finished and polished using special burs, grinding and polishing pastes.



Sequence of operation

- The denture can be tried in.

