

MANDIBULA

Lower jaw



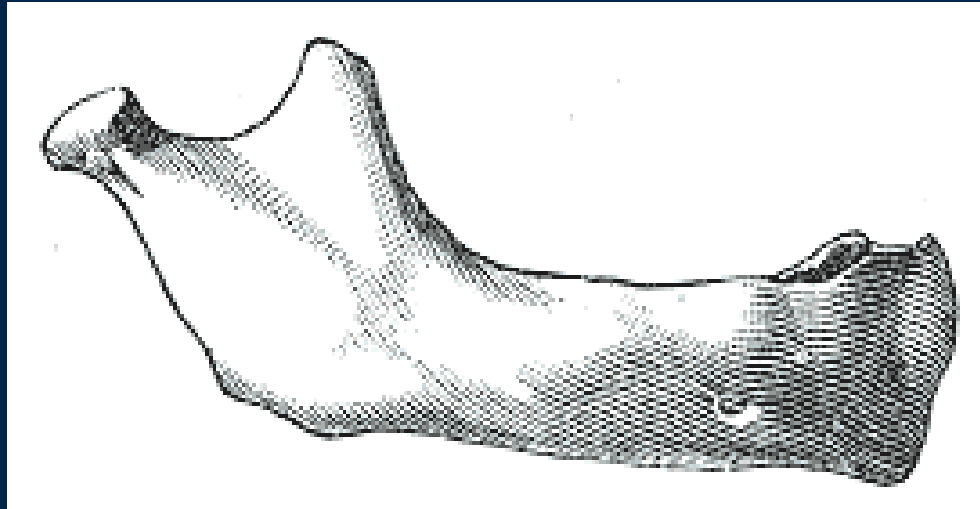
- **Anatomy (repetition)**
- **Widespread description and clinical notes**
- **Dentoalveolar topography:**
 - transverse asymmetry of alveolus
 - rate of spongy and compact bone
 - the relationship of root to neighbouring structures
- **Nerve and blood supply (repetition)**

A single facial bone that is the only freely movable part of the skull

During the development the mandible originates from two bones which unite together and form the lower jaw

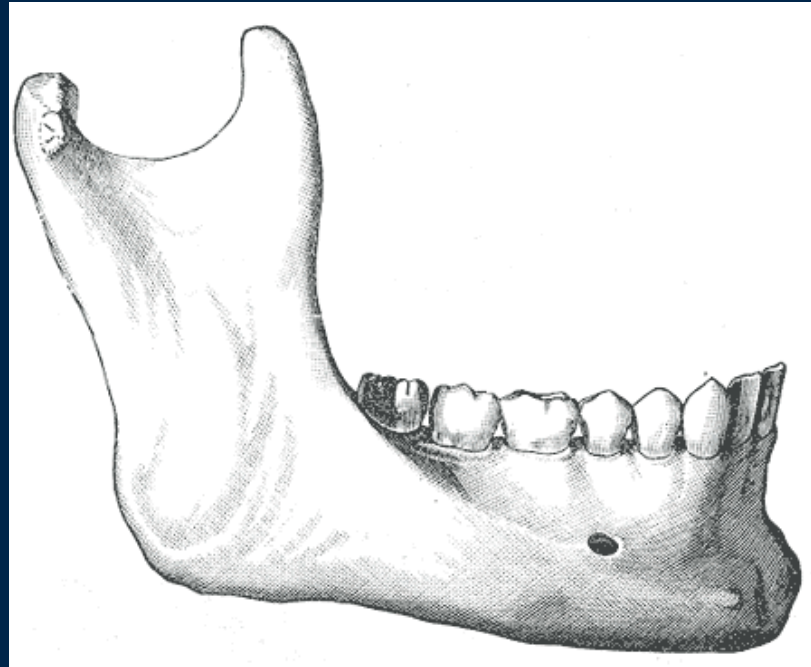


Newborn



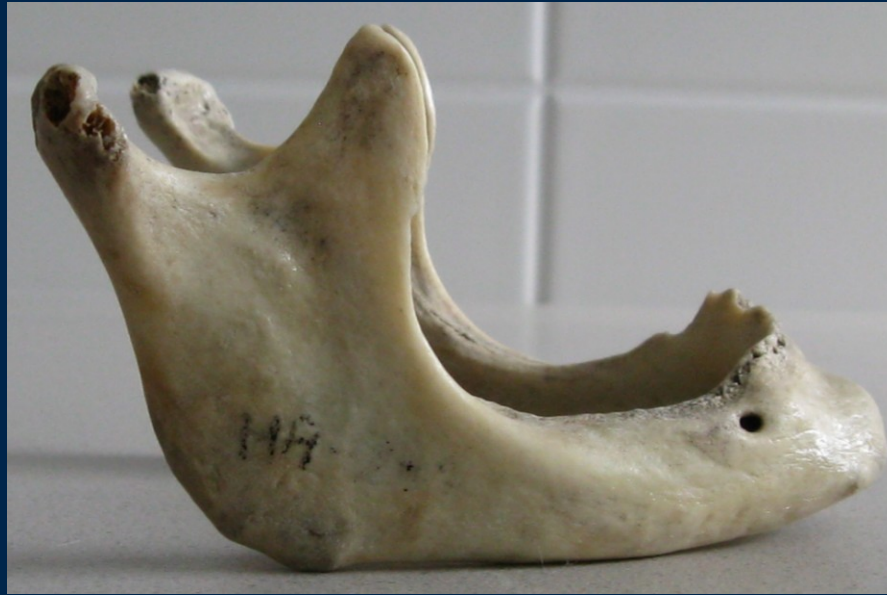- mandibular corpus is low
- the body contains the sockets of deciduous teeth
- the angle between corpus and ramus is 150
- mental foramen lies on the lower edge of corpus

Adulthood



- the angle is much sharper – about 120°
- condylar process is higher than the coronoid process and the sigmoid notch becomes deeper

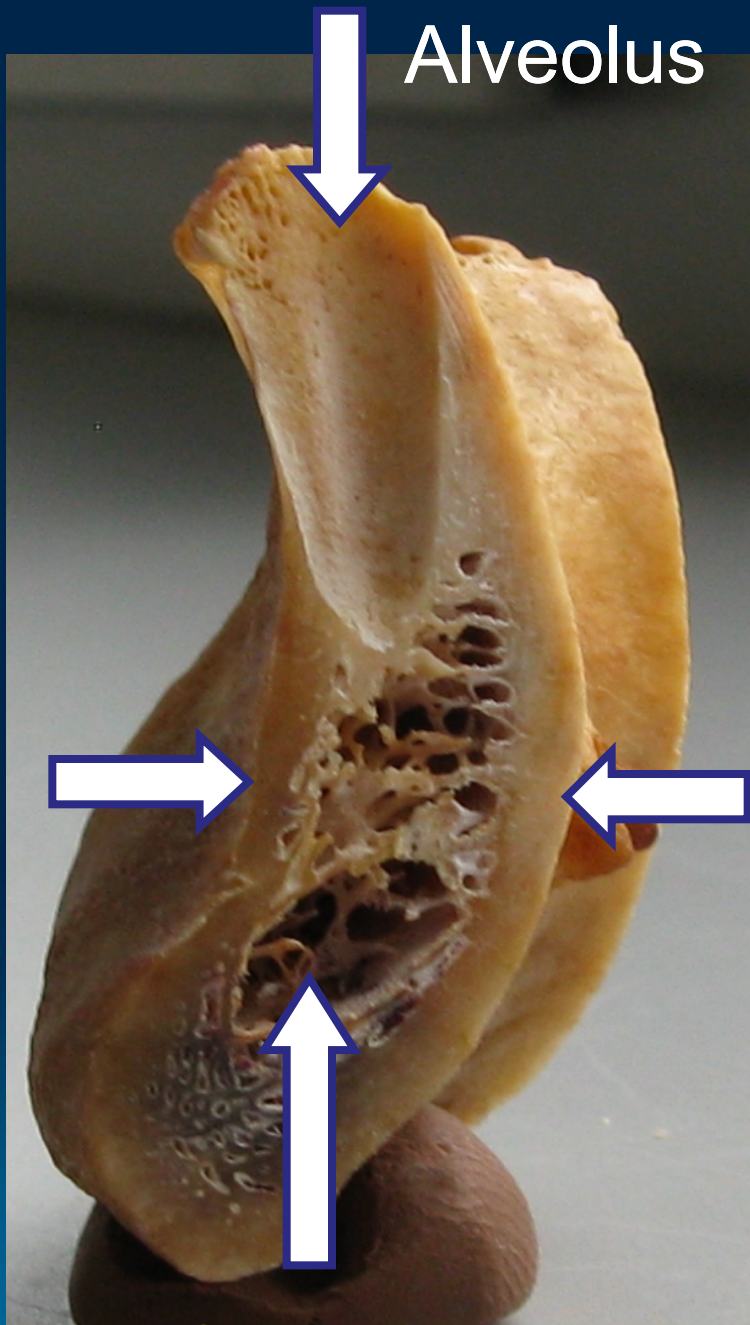
Old age



- after the loss of teeth, the body is reduced in volume (atrophy of the alveolar process) → mandibular foramen is closer to the alveolar border
- enlargement of the angle to 160°
- deepen pterygoid fovea → neck is tapered

Alveolar process

- The portion of the jawbone that contains the teeth and the alveoli in which they are suspended
- The development is dependent on **tooth eruption** and its maintenance on **tooth retention**
- Is composed of **compact** bone (0.1-0.8 mm) that enclose the **spongiosa**



Alveolus

Compact bone
(labial cortical
plate)

Compact bone
(lingual cortical
plate)

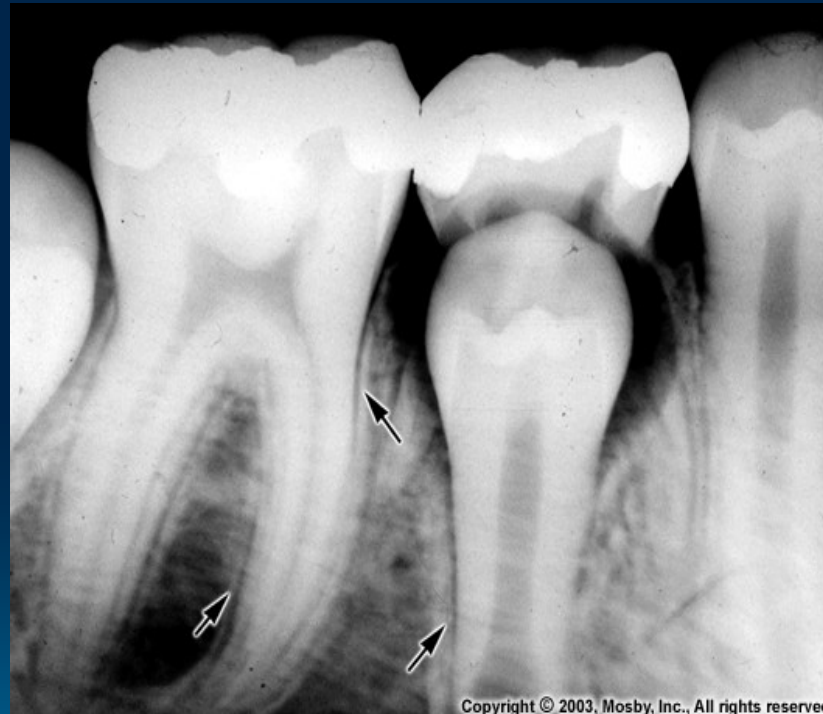Spongy bone

Alveolus

- Is composed of a thin plate of **cortical bone** with numerous perforations (or **cribriform plate**) that allow the passage of **blood vessels** between the bone marrow spaces and the periodontal ligament
- The coronal rim of the alveolar bone forms the **alveolar crest**, which generally parallels the cemento-enamel junction at a distance of 1-2 mm apical to it

Bundle bone

= the inner portion of the bone of the alveolus that surrounds teeth and into which the collagen fibers of the periodontal ligament are embedded

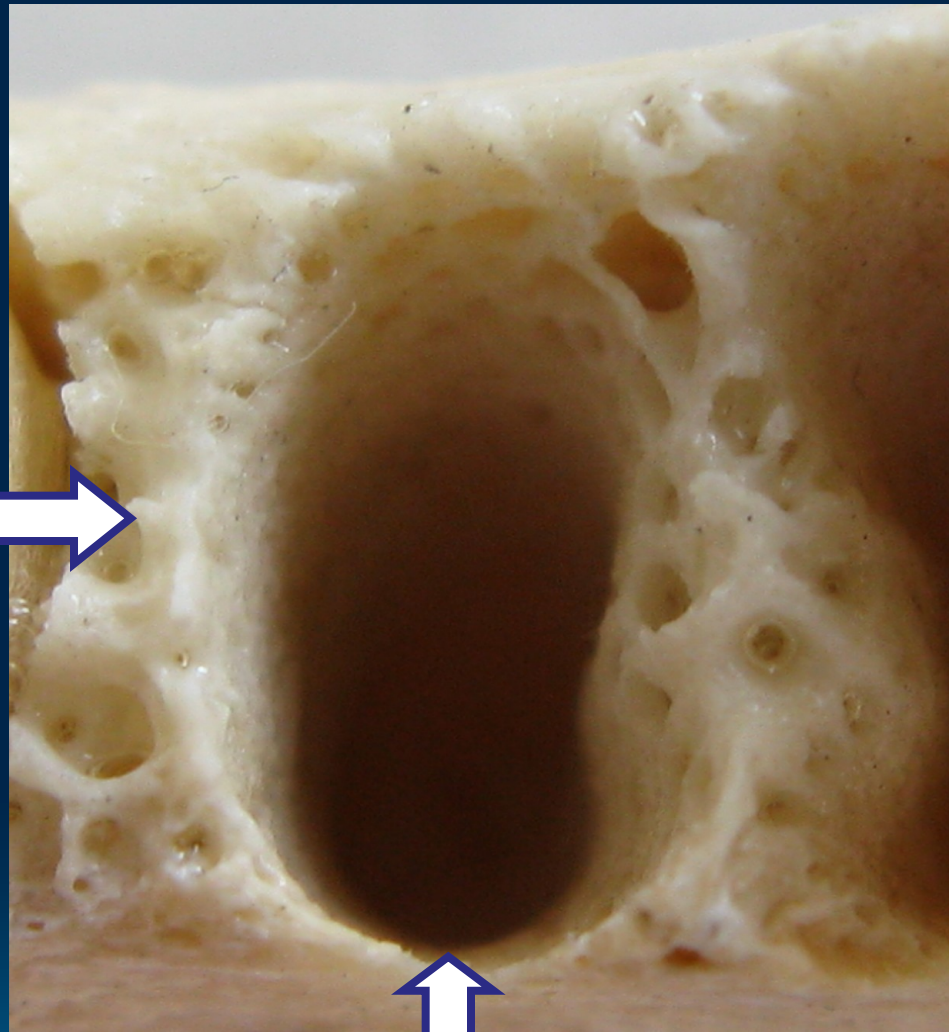


Copyright © 2003, Mosby, Inc., All rights reserved.

- Radiographically, the bundle bone is the **lamina dura**

Septum
interalveolare
(*spongy bone*)

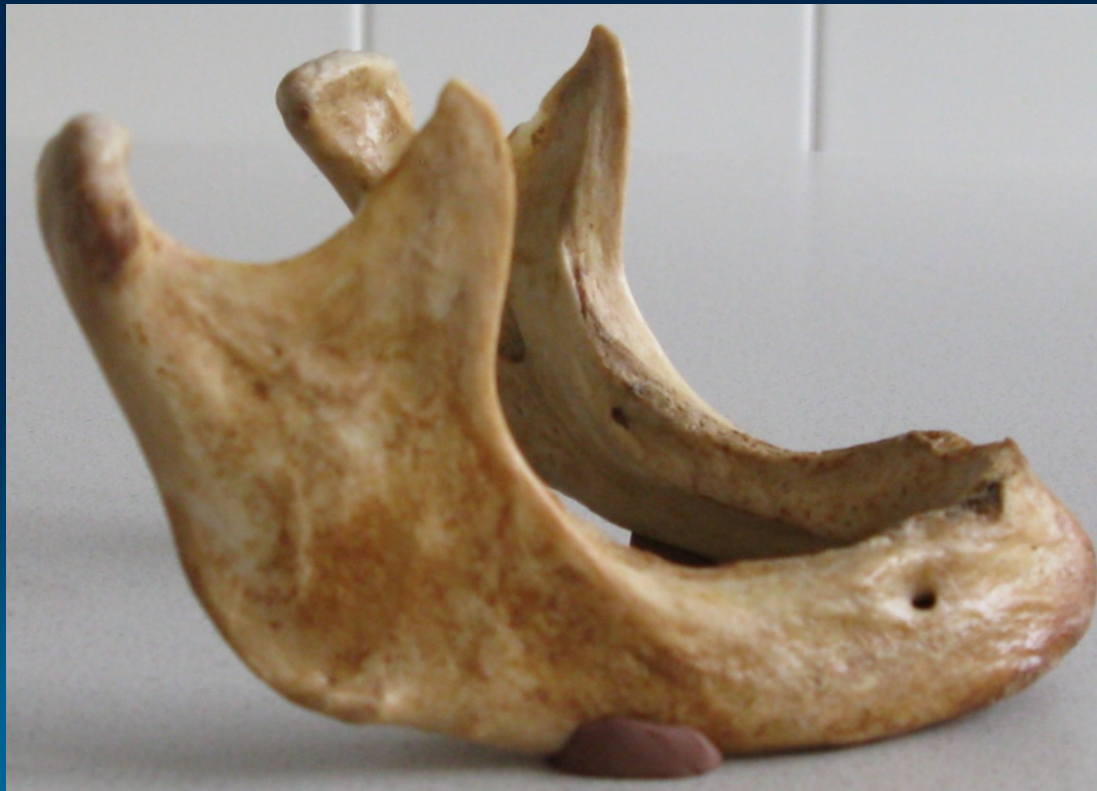0.7-14 mm



Alveolus
(*compact bone*)

Resorption of alveolar bone

Decreased bone (osteopenia) of alveolar process is noted when there is inactivity of tooth that does not have an antagonist



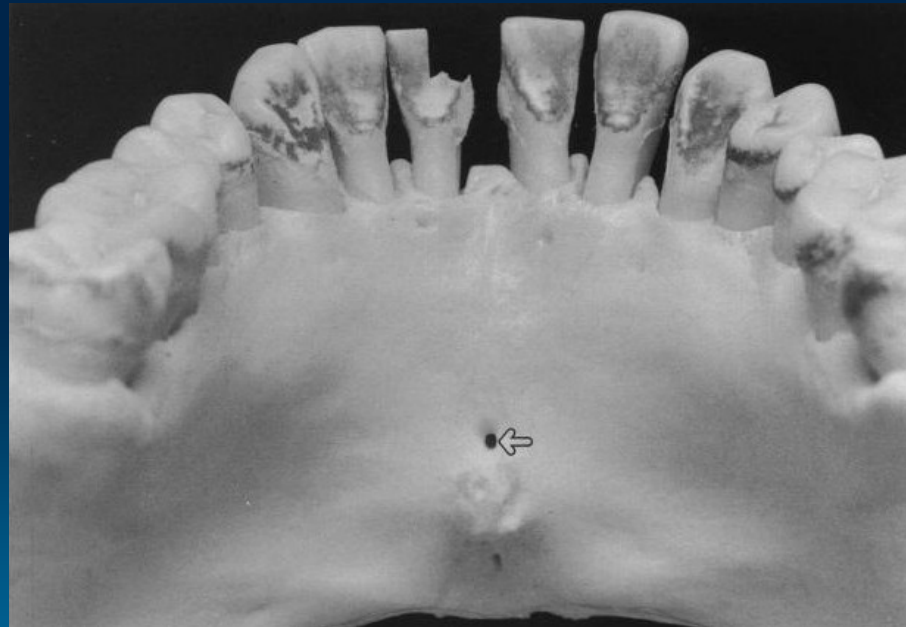
Reconstruction of alveolar bone

- The whole life the bone keep the potential to reconstruction
- Bone is resorbed on the **side of pressure** and opposed on the **site of tension** is regenerated
- Movement of a tooth by extrusion involves applying traction forces in all regions of the periodontal ligament to stimulate marginal apposition of crestal bone

Lingual foramen (canal)

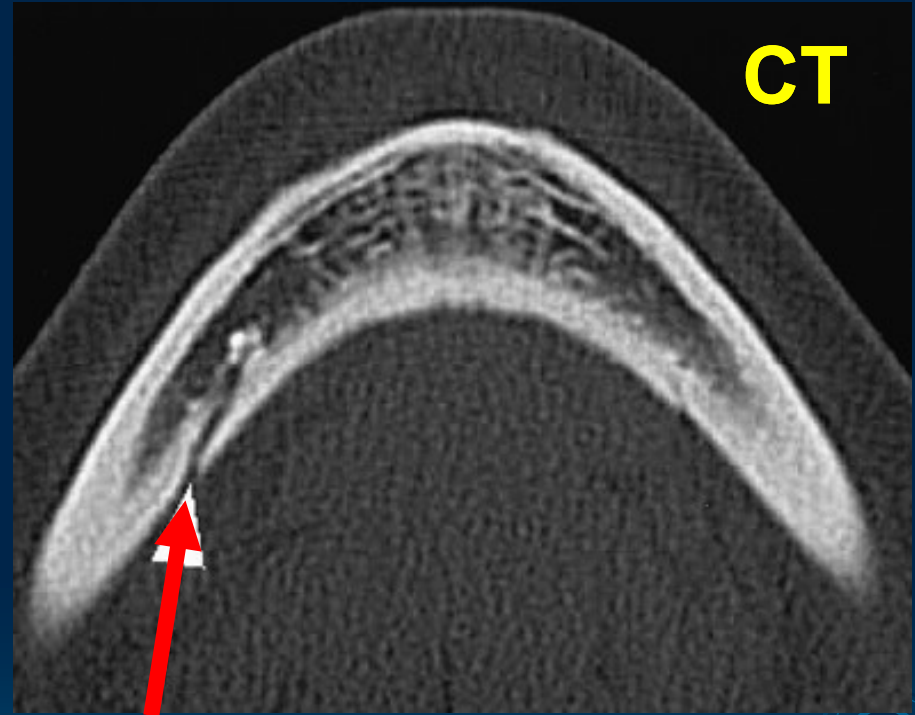
The contents of the foramen (foramina) were found to be an artery

Median



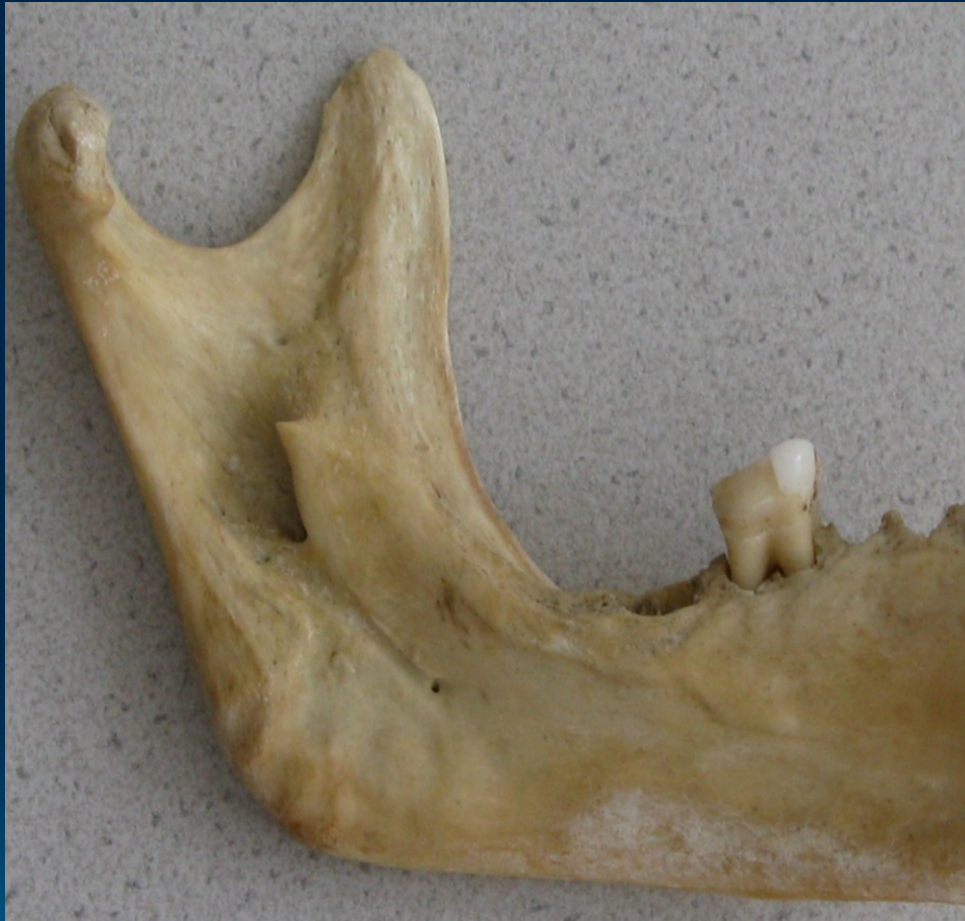Lateral (orifices accessories)

- Inner area of mentum sup. and inf. retromental for.
- Unilateral, bilateral or multiple
- In neighbourhood of mylohyoid line



CAVE! Bleeding (implant placement)

Mandibular foramen

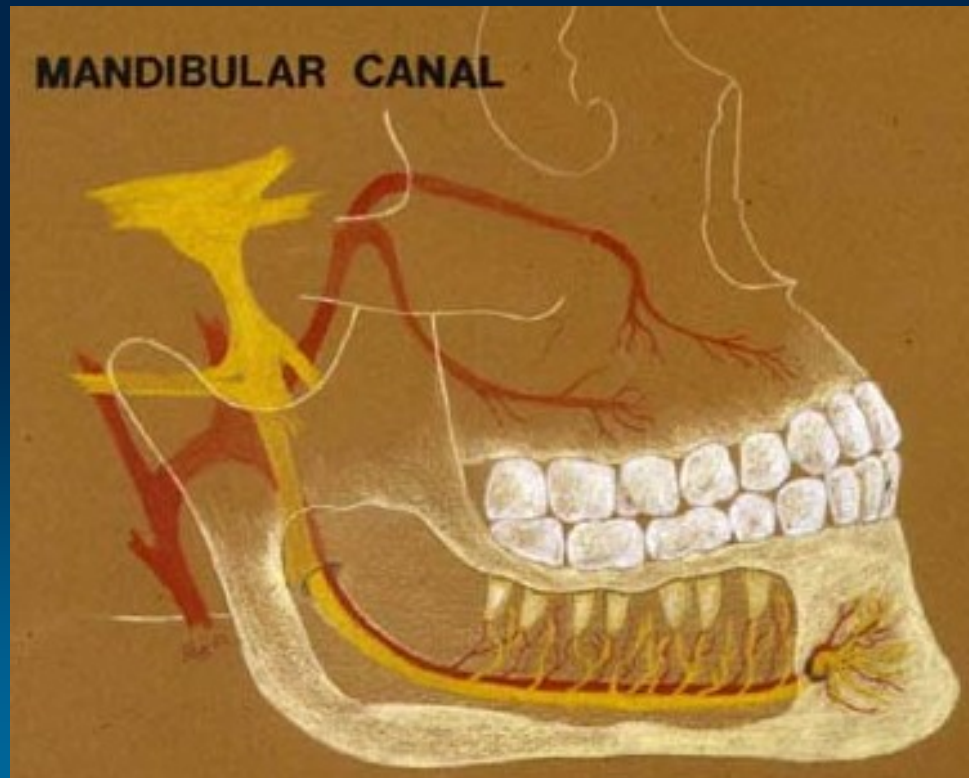


- Začátek canalis mandibulae
- Inner surface of ramus mandibulae
- middleline between anterior and posterior edge of ramus
- 1 cm above M3
- 2 cm behind M3

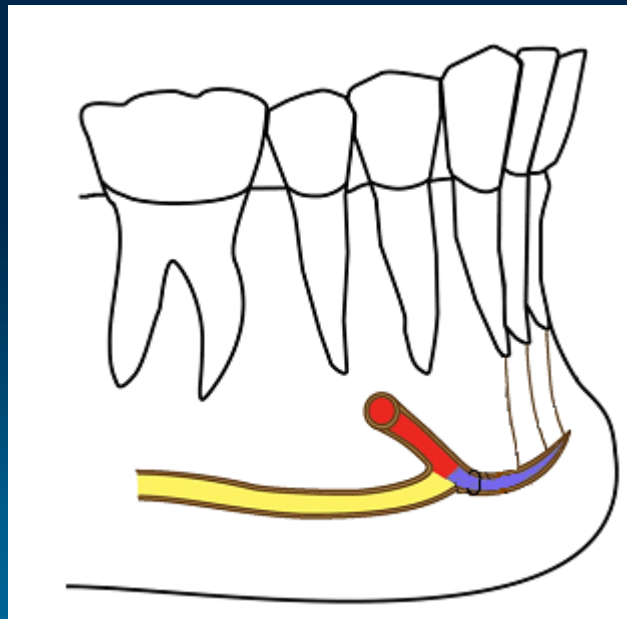
CAVE! Local anesthesia

Mandibular canal

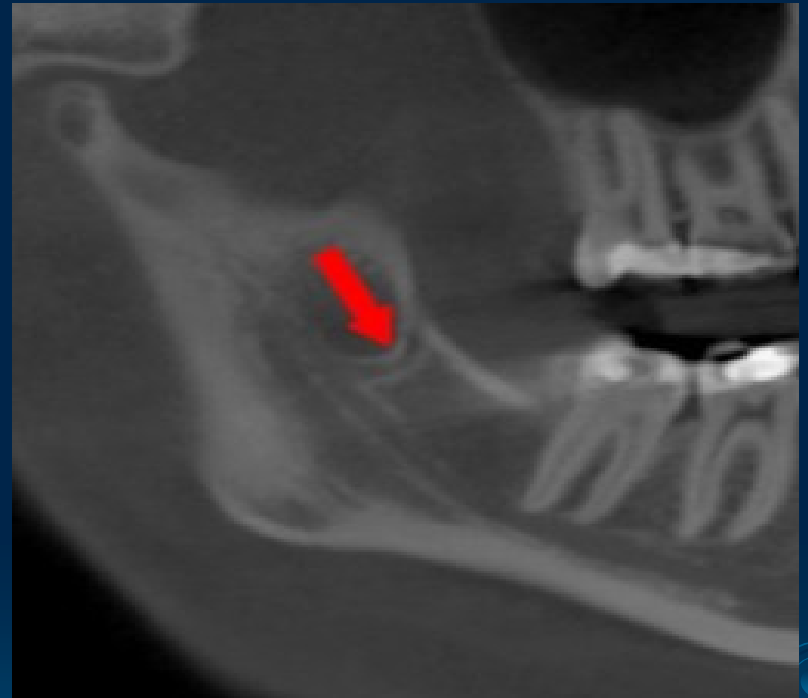
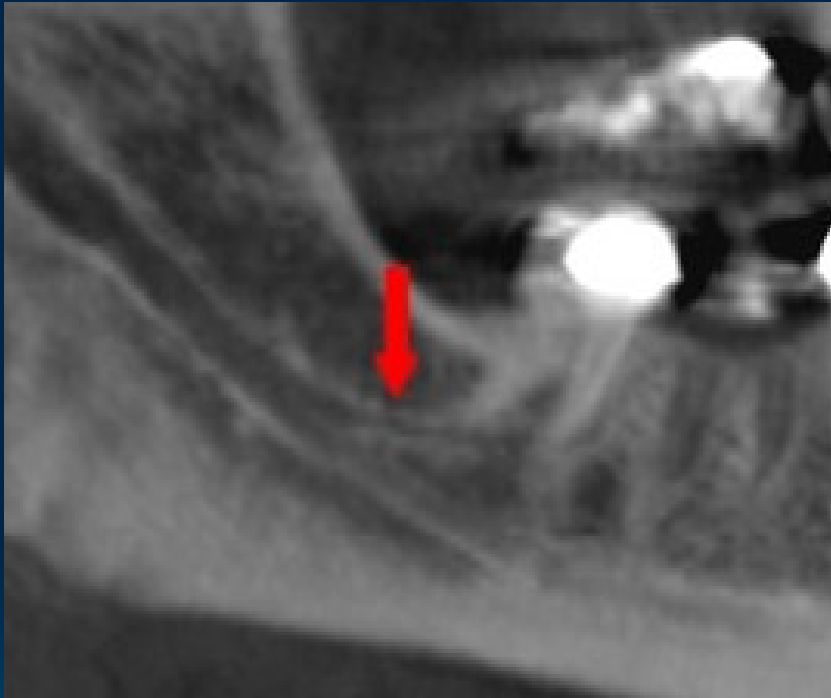
- Is placed under the alveoli and communicates with them by small openings
- Contains the **inferior alveolar nerve, artery, vein**



- Demarcate of the compact bone (noticeable to x-ray)
- On arriving at the incisor teeth, it turns back to communicate with the **mental foramen**, giving off a small canal known as the **mandibular incisive canal**



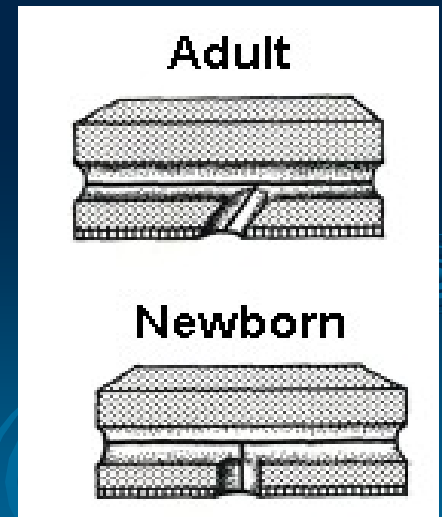
Canalis mandib. bifidus

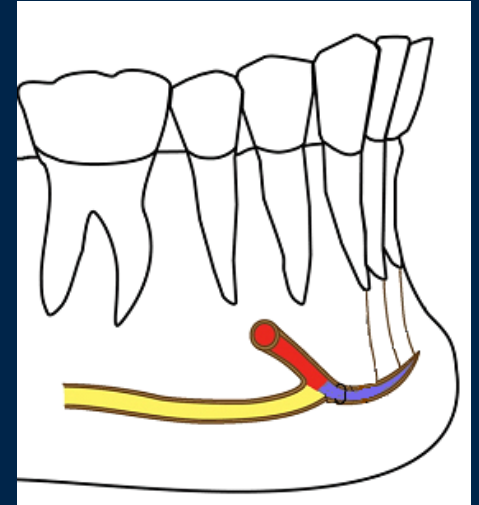
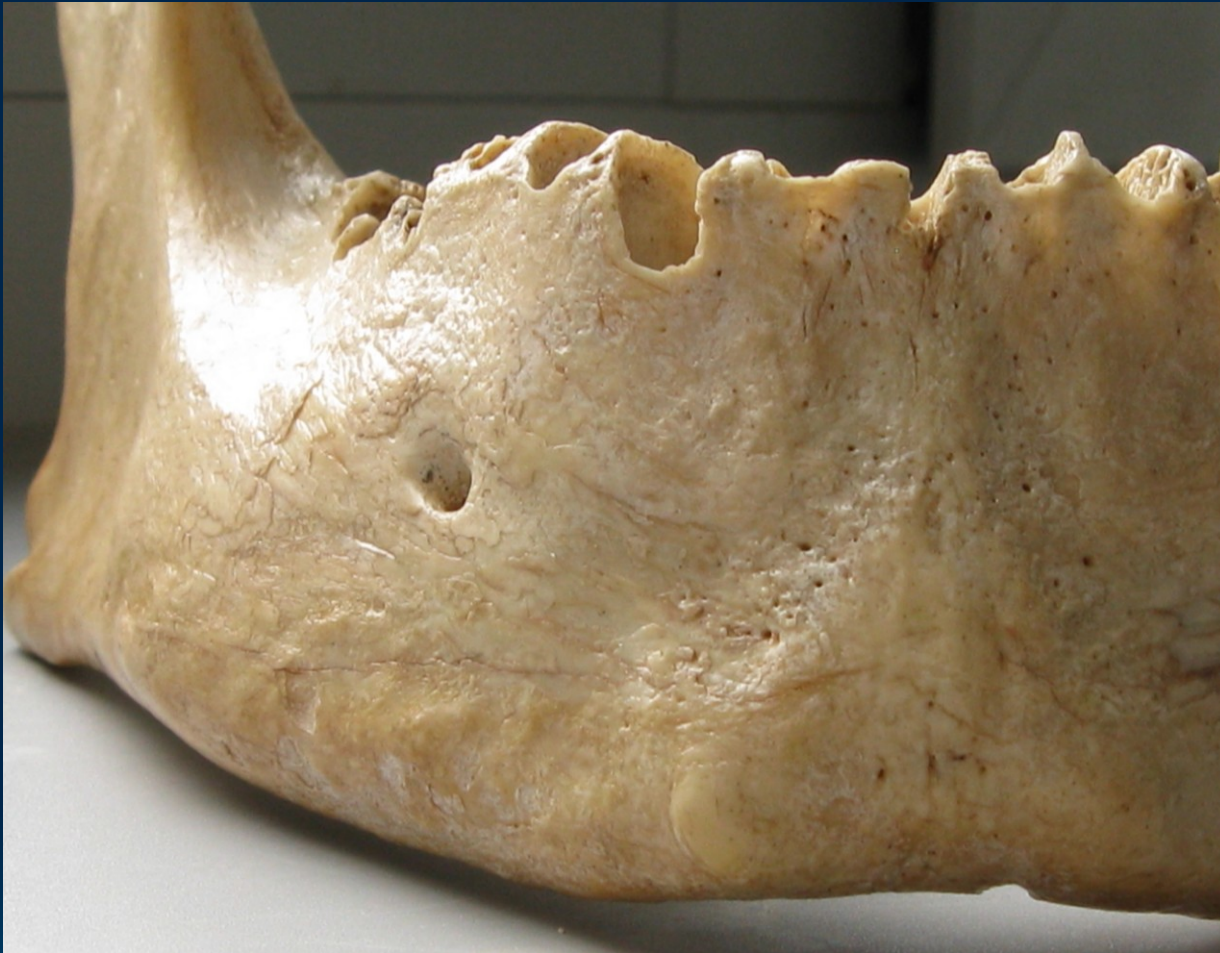

Summary 0.9%

Mental foramen

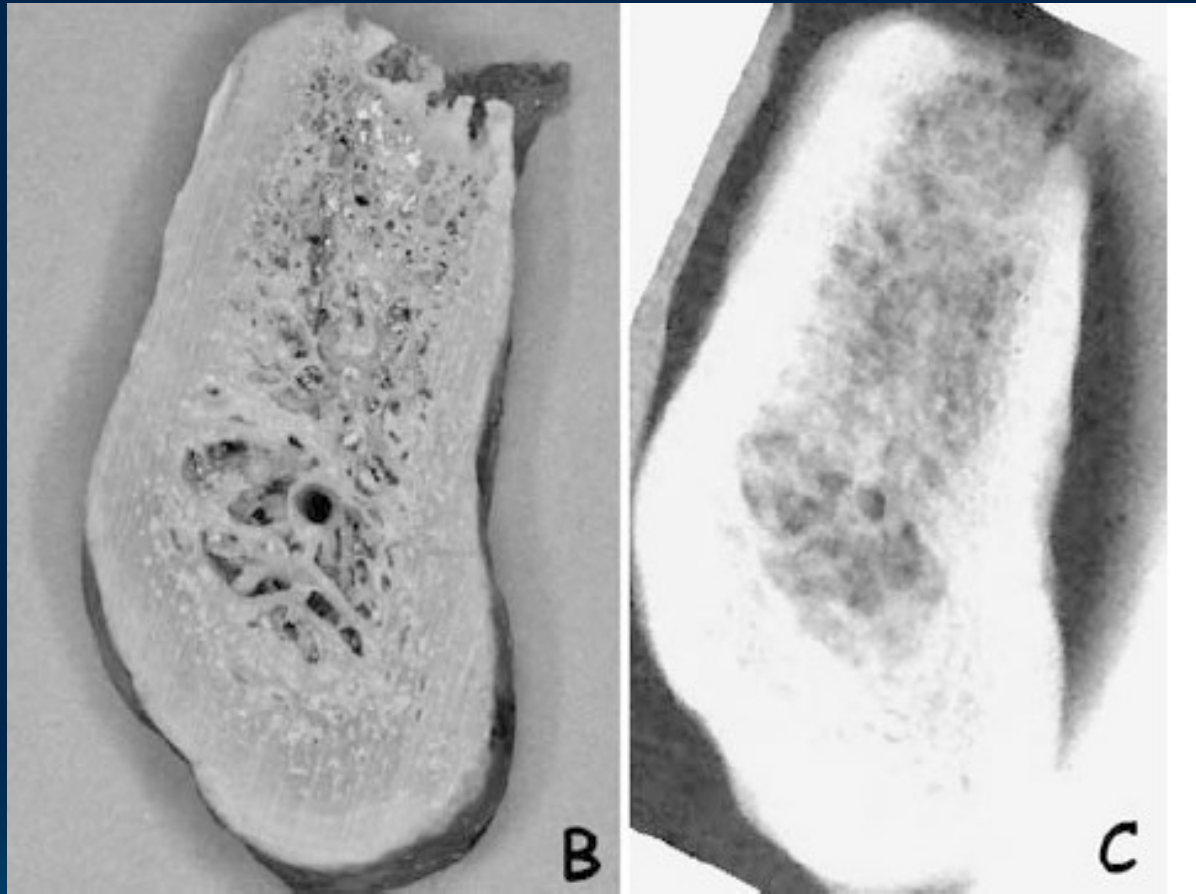
- The position of this foramen is most frequently **near the apex of the mandibular second premolar** and rested between the premolars
- The foramen **open upward and slightly posteriorly** in adults
- The foramen open **straight upward** in newborns





CAVE ! Local anesthesia

Incisive canal




Summary 96%

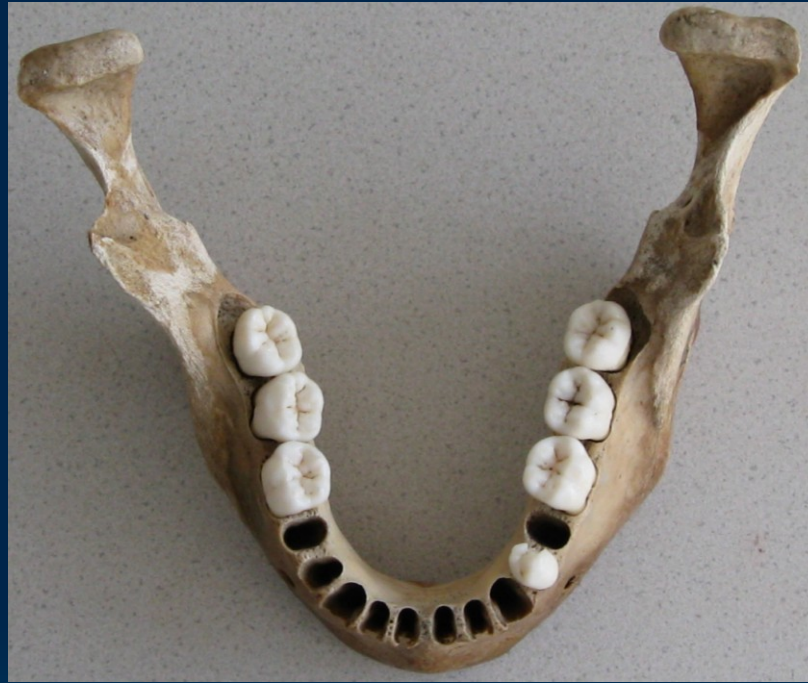Demarcate of the compact bone (noticeable to x-ray)

Dentoalveolar topography

Important for anesthesia, extraction, injury, implantology, endodontic treatment ...




1. The transverse asymmetry of alveolus
 2. The rate of the spongy and the compact bone
 3. The relationship the roots the lower jaw to neighbouring structures
- 

1. The transverse asymmetry of alveolus

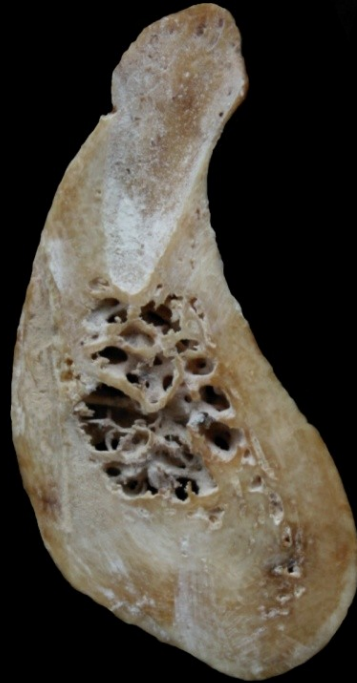

- The dental and skeletal arch are asymmetric !

2. The rate of the spongy and the compact bone

- The layer of **compact bone** is thicker than in the upper jaw
 - Roots of the incisivi and canini teeth are surrounded by the compact bone
 - Roots of the premolars and molars are surrounded by the **pre- and retroalveolar spongy bone** that is thin, fragile
- 
- 
- 

Incisivi, Canini



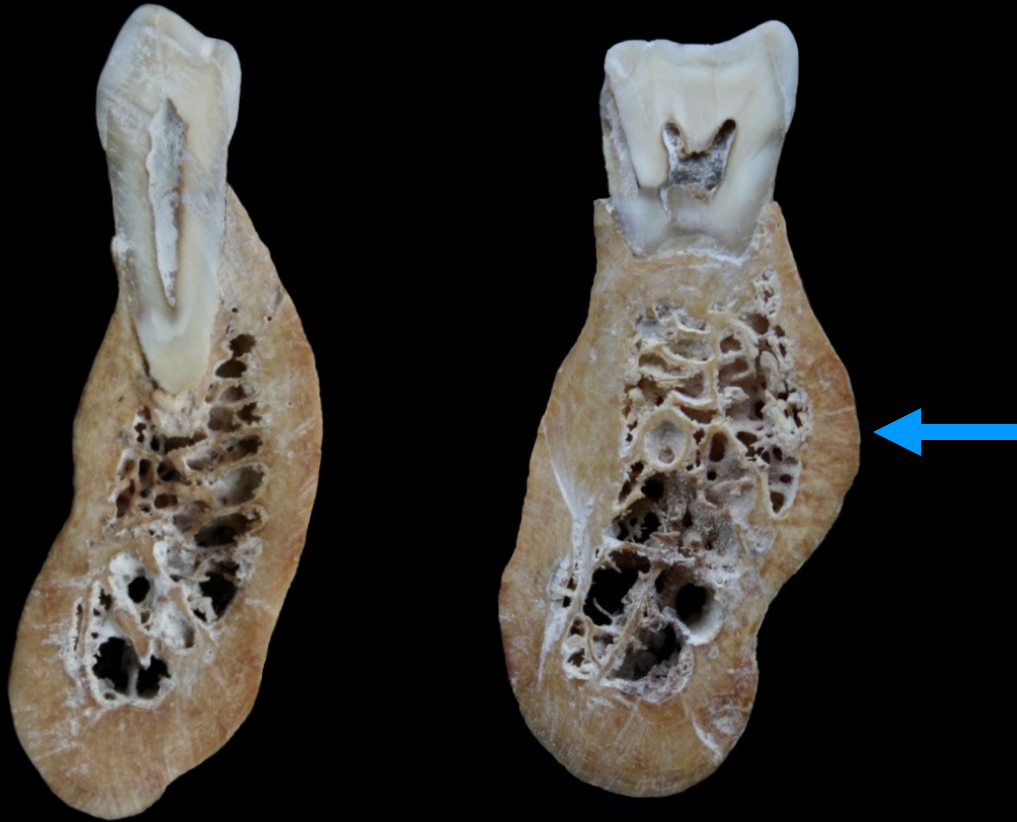
Compact bone only

CAVE!

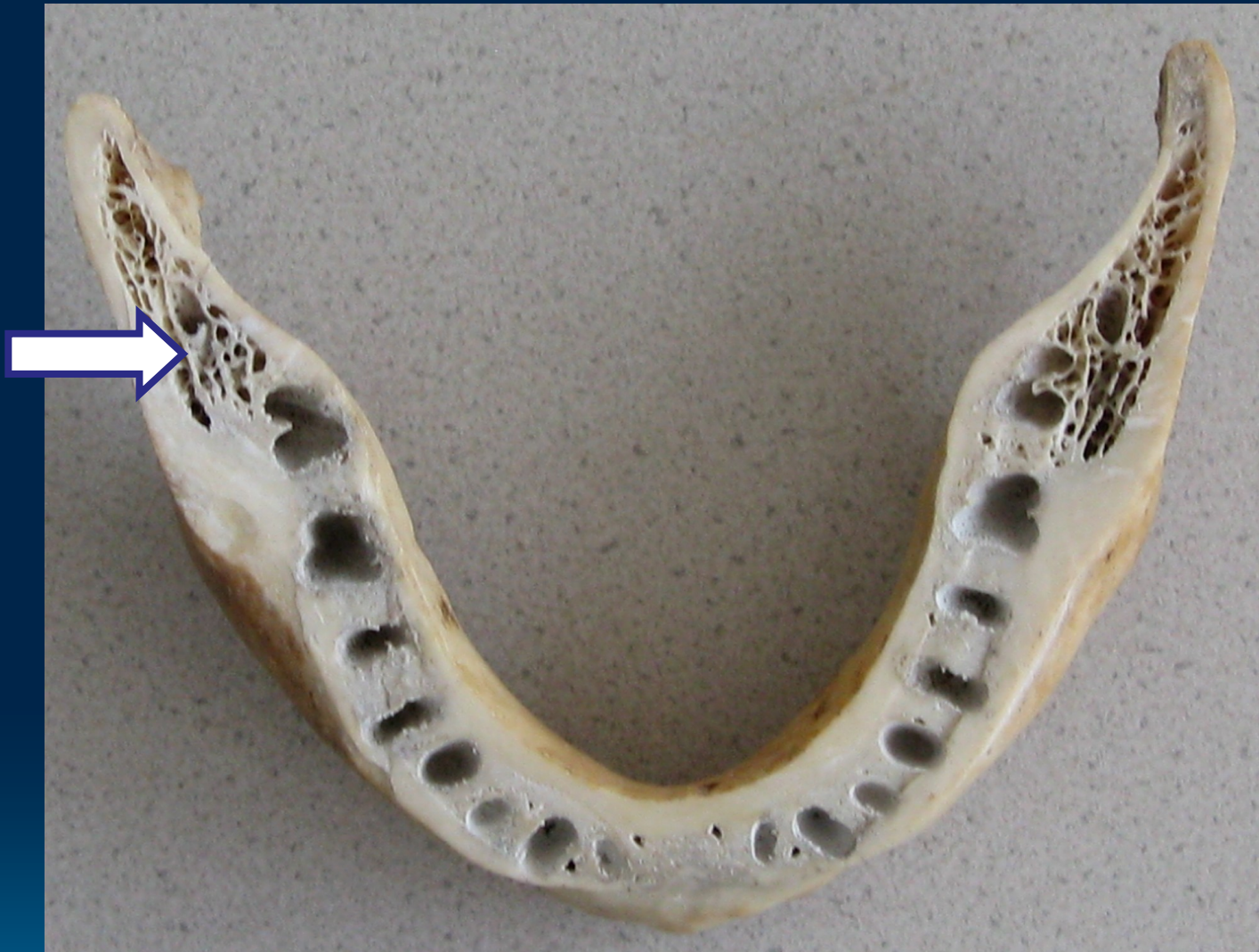- Fractures by extraction !
- Root of the 3rd tooth – fracture of mandible !

Premolars

Molars



Compact bone and variable thickness of spongy bone buccally and lingually ([linea mylohyoidea](#))

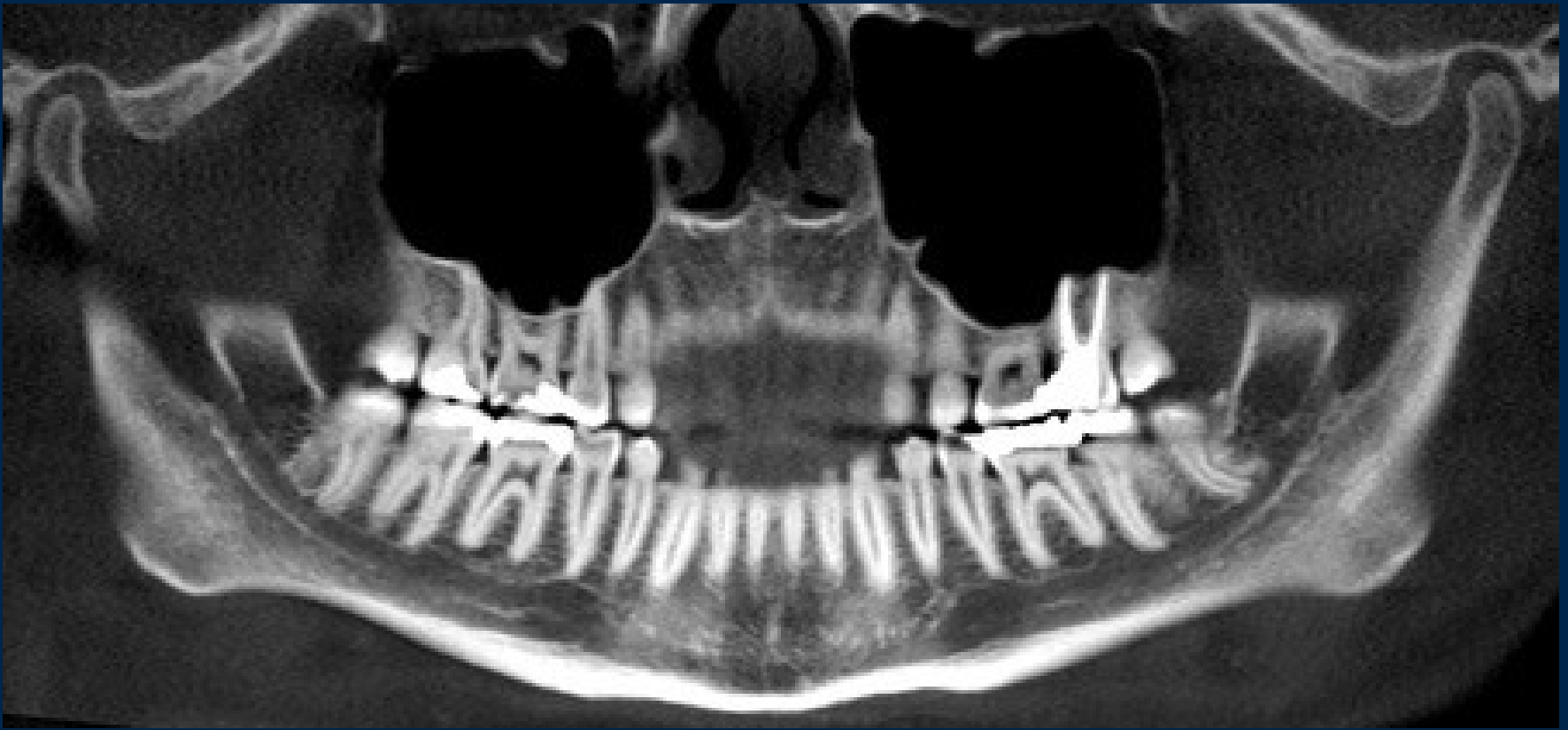


Spongy bone is distally to 8

3. The relationship the roots the lower jaw to neighbouring structures

Canalis mandibulae
(incisivus, mentalis)

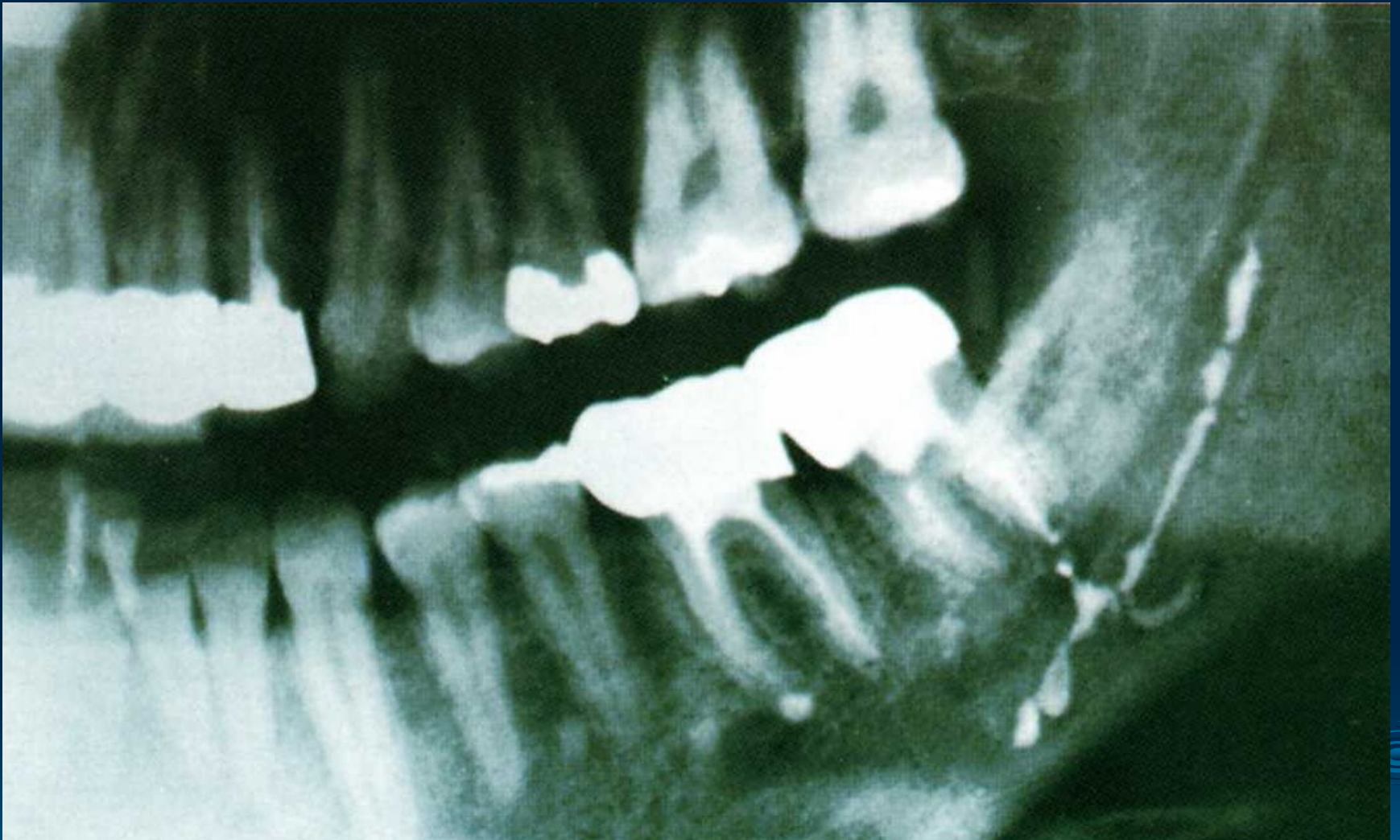



Variable layer of **spongy bone** between canals and teeth's roots

CAVE!

- Dehiscence the canal and the alveolus
- Implants



CAVE! The endodontic treatment

Nerve and blood supply



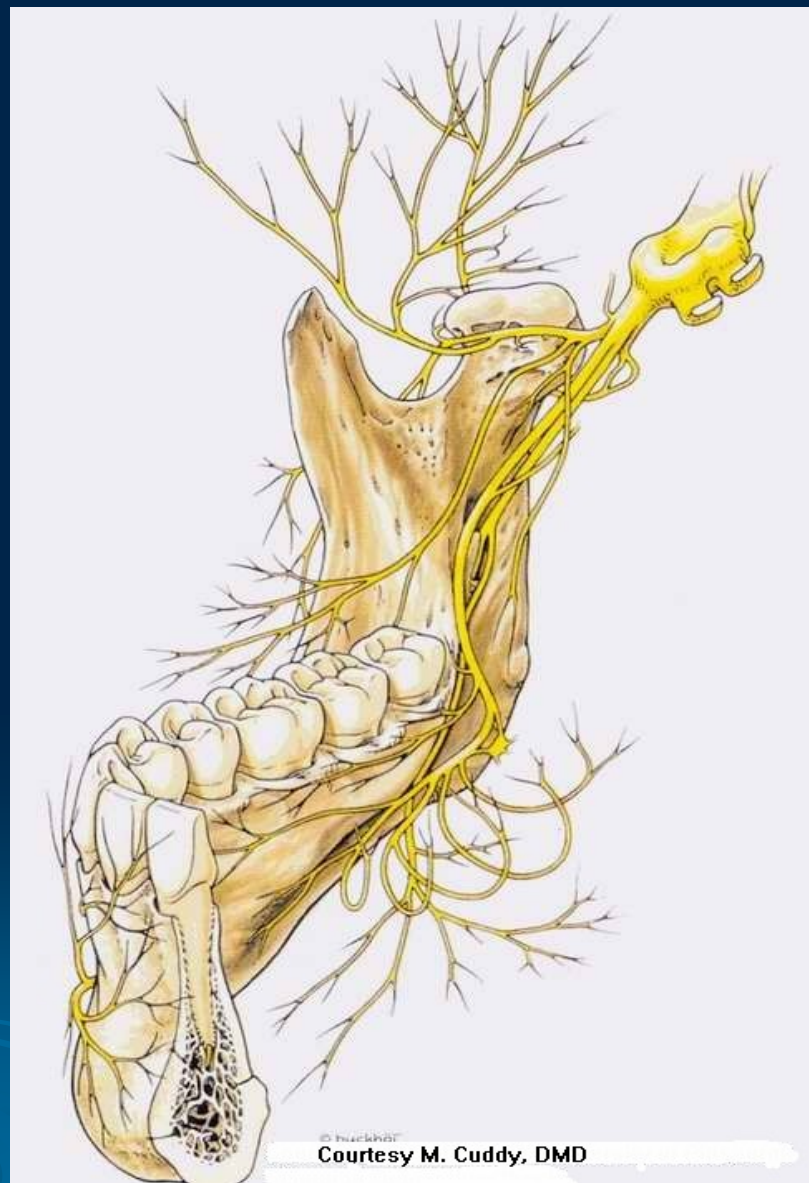
Trigeminal nerve

Alveolar inferior nerve
mental nerve
incisive nerves

Mylohyoid nerve

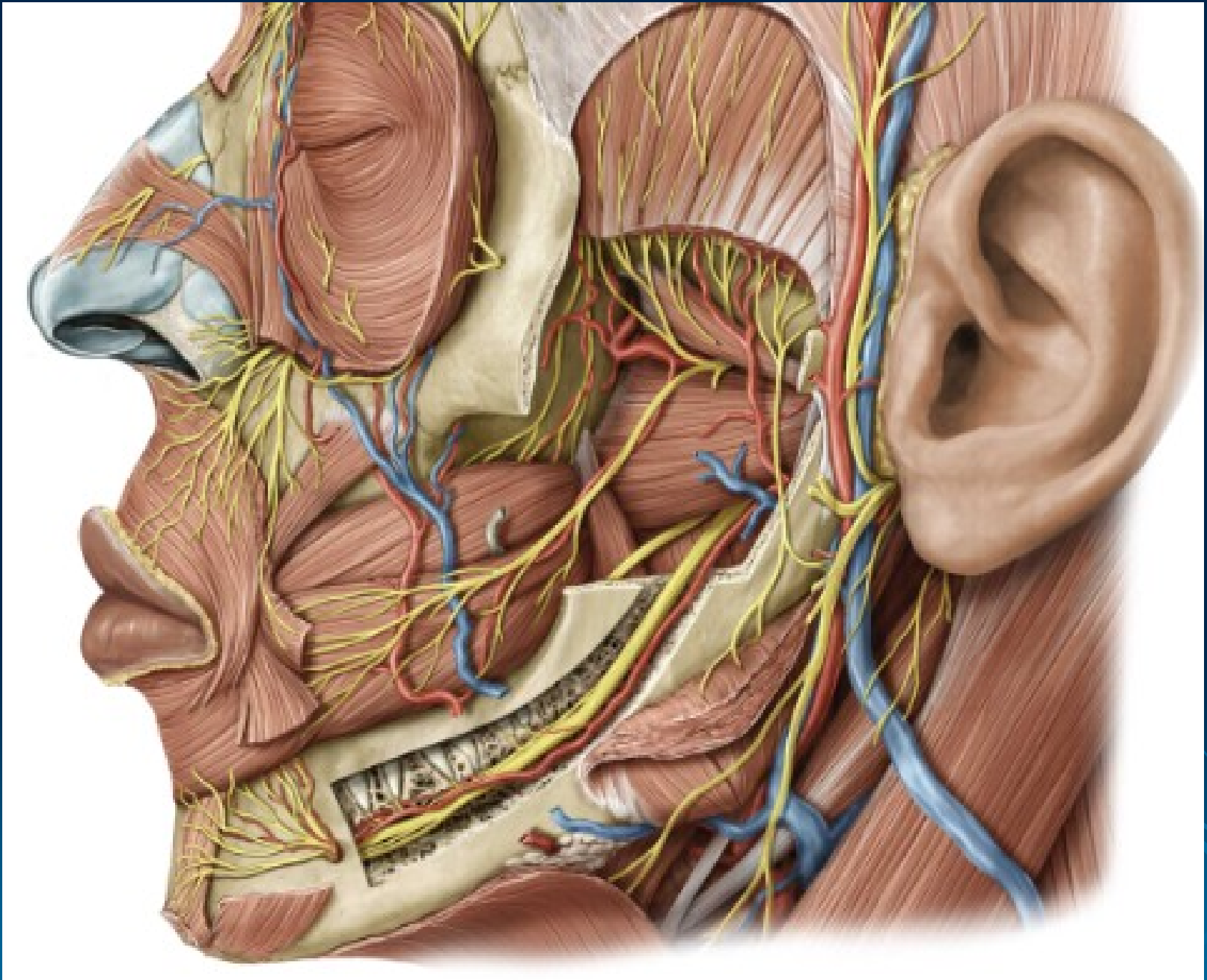
Buccal nerve

Lingual nerve



© huckha

Courtesy M. Cuddy, DMD



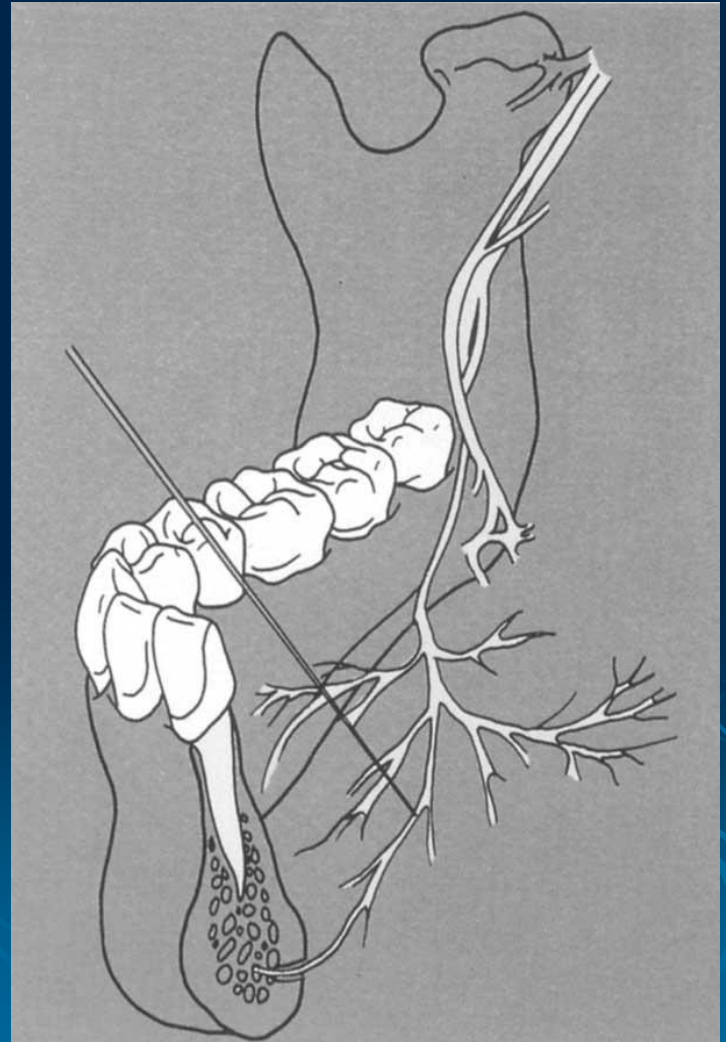
Variation

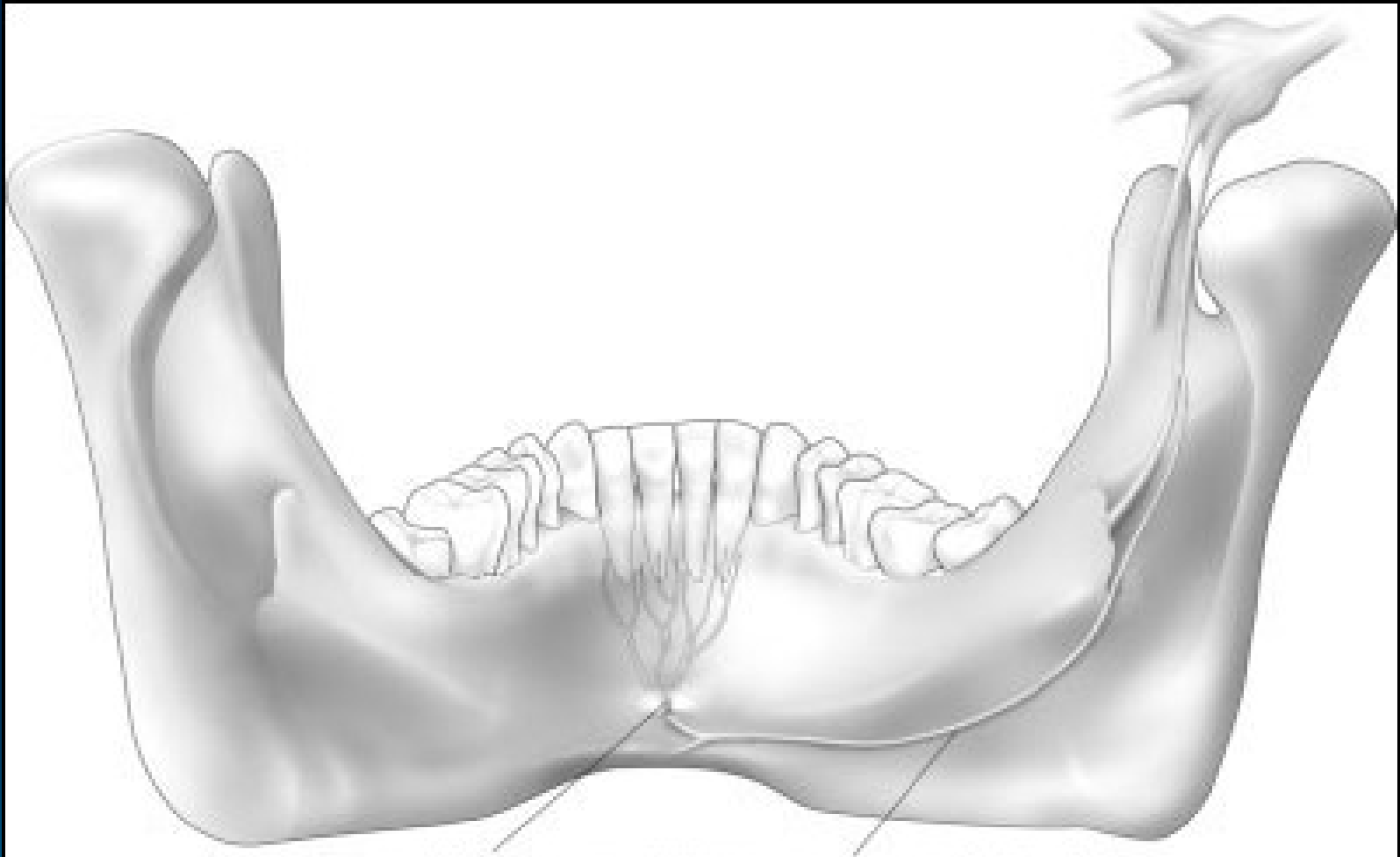
Important for anesthesia !

1.

Mylohyoid nerve

Can convey impulses from the **incisive, canine and premolar teeth and gingiva !**

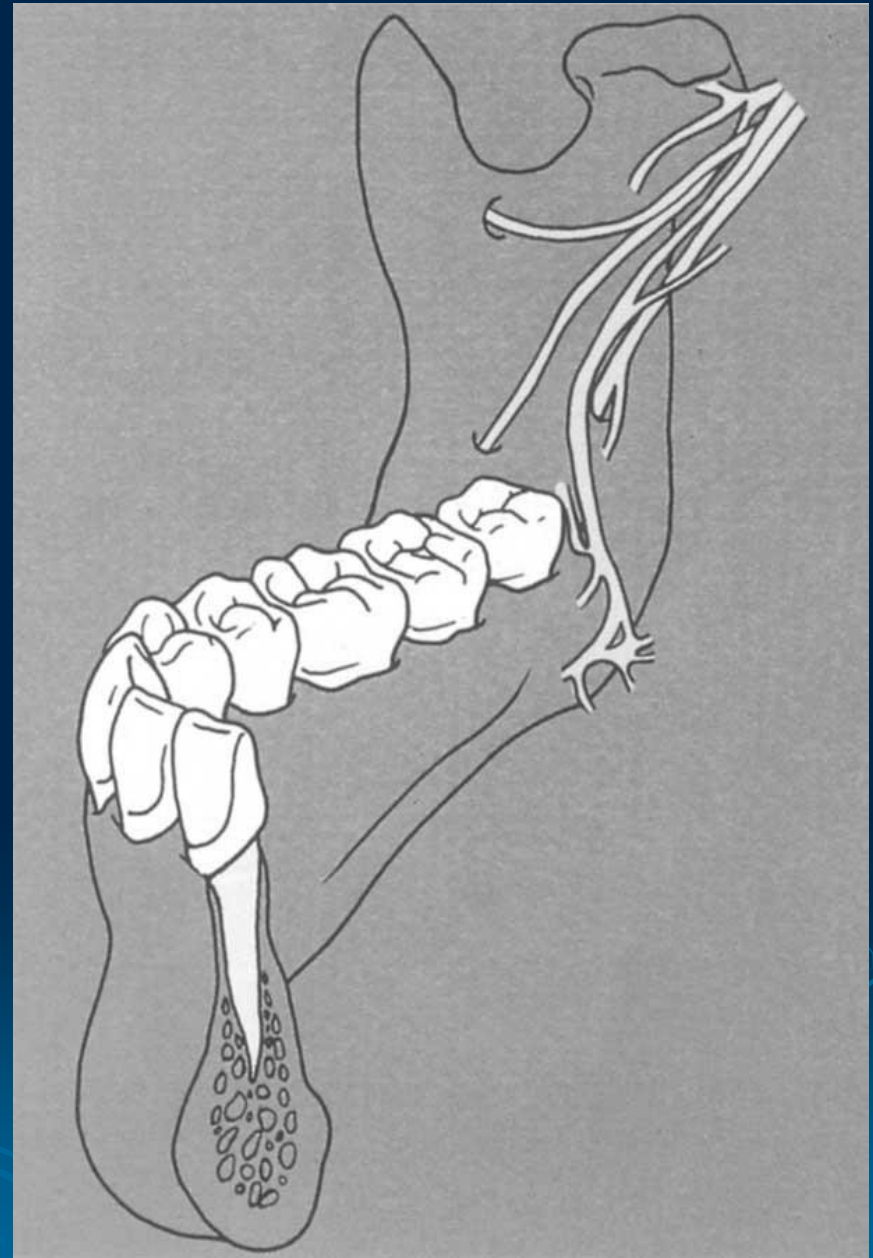




2.

Sometimes the branches entering separated bony channels laterocranial of mandible foramen and M3, M2

The nerves entering the mandible at the **retromolar fossa**



Maxillary artery

Inferior alveolar artery

mylohyoid a.
dent. et interalveolar a.
mental a.
incisive a.

Facial artery

submental a.

Lingual artery

sublingual a.

