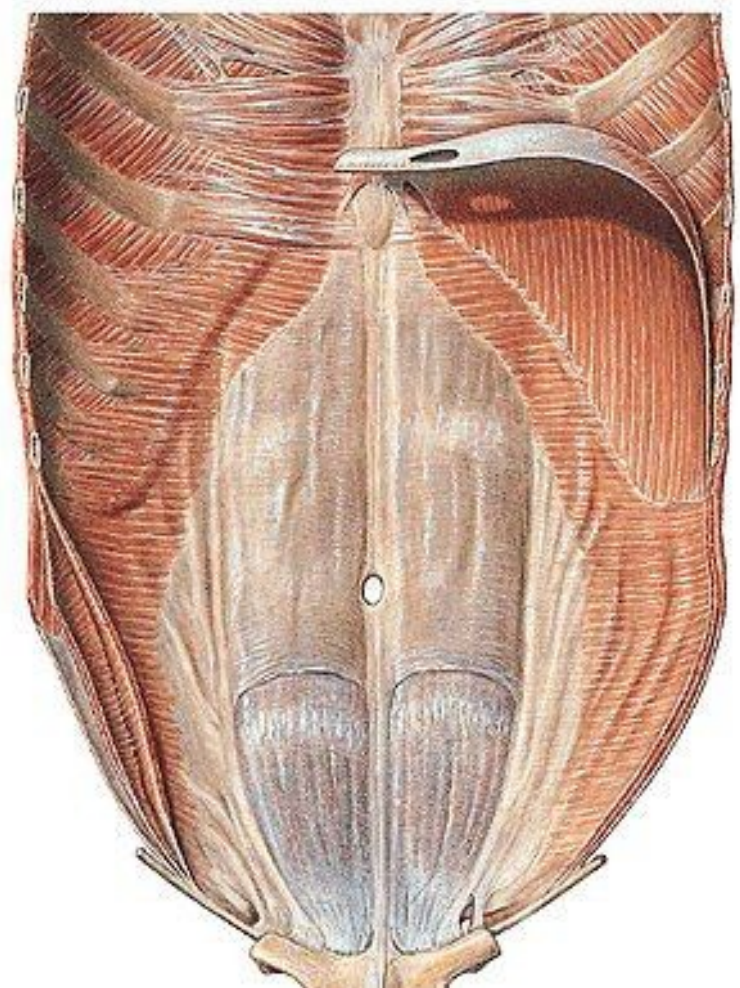
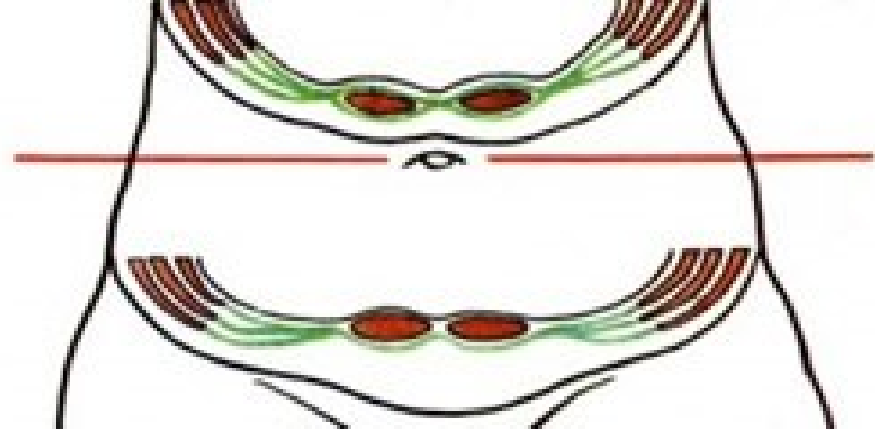
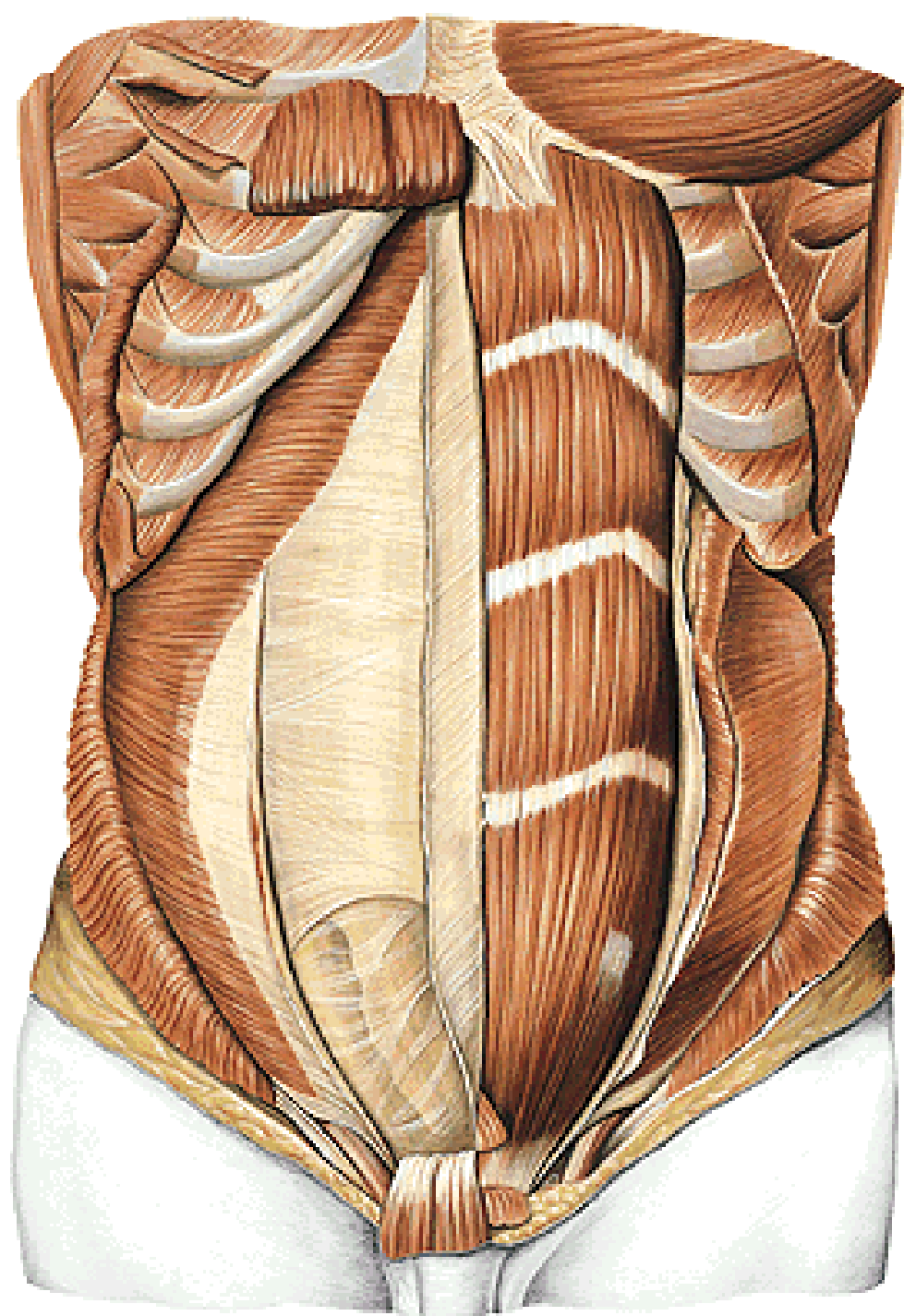
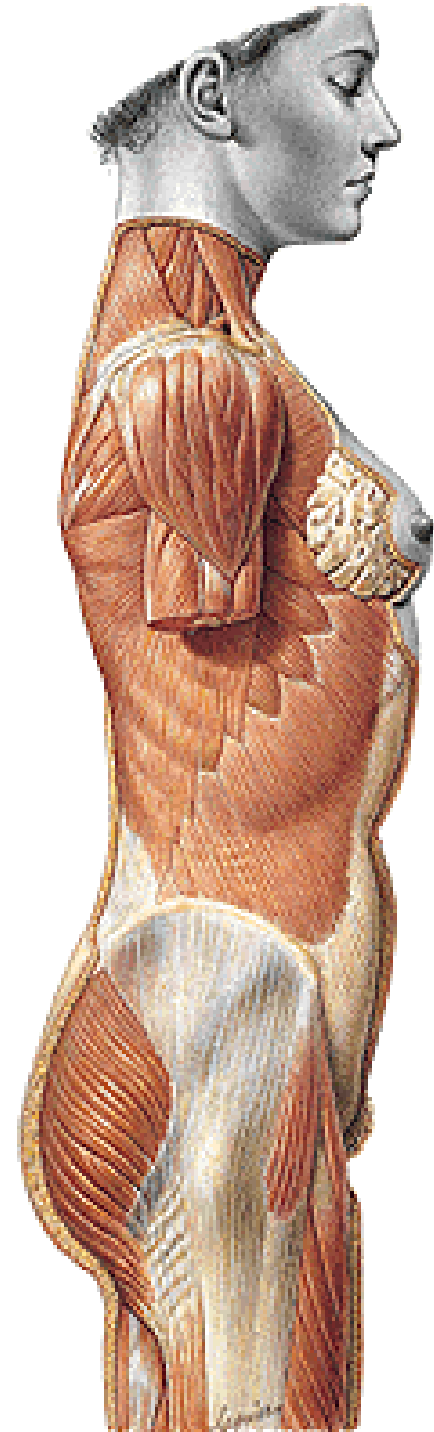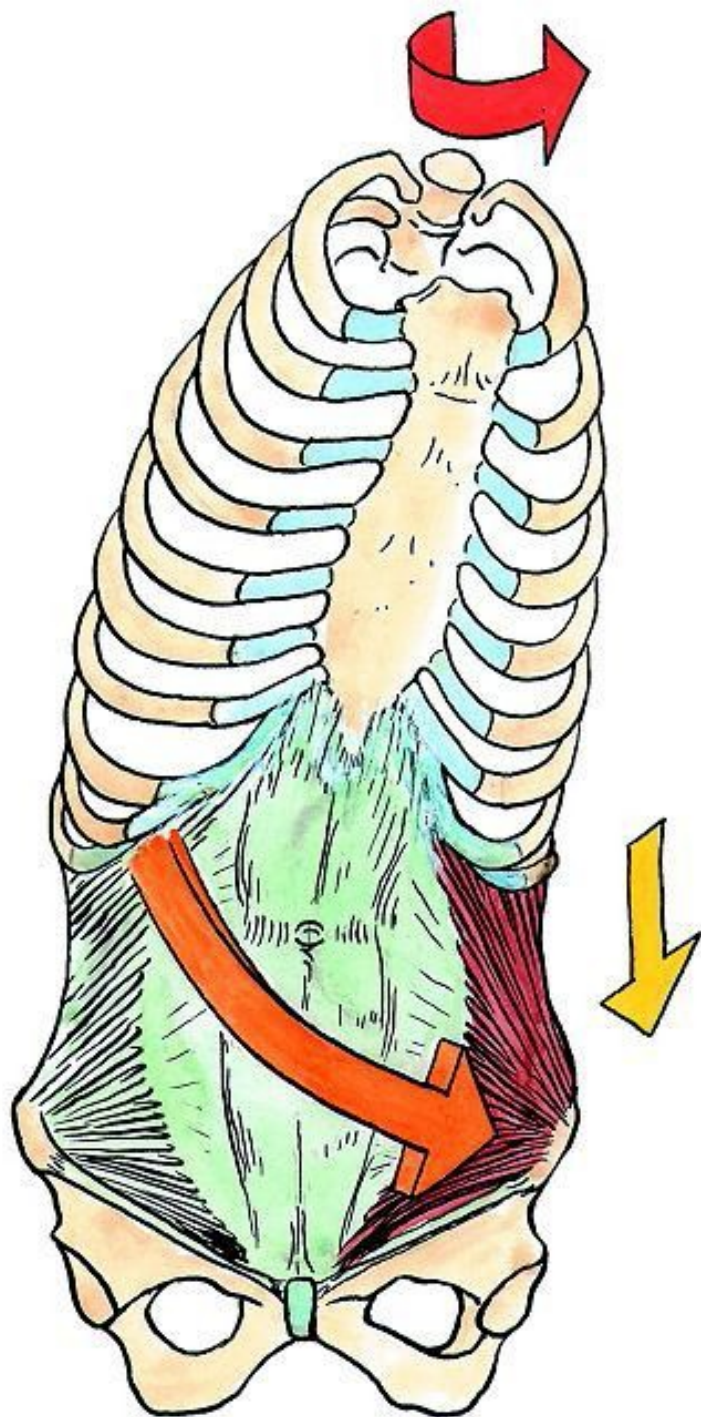
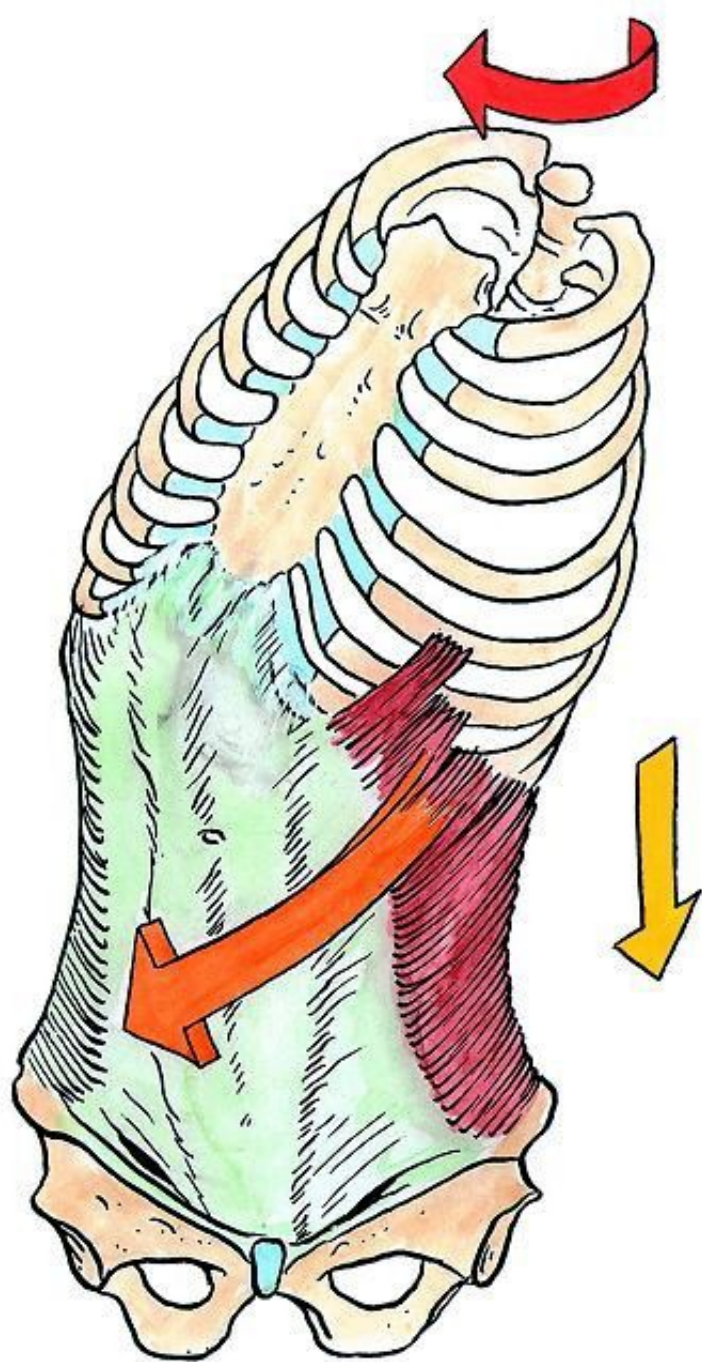
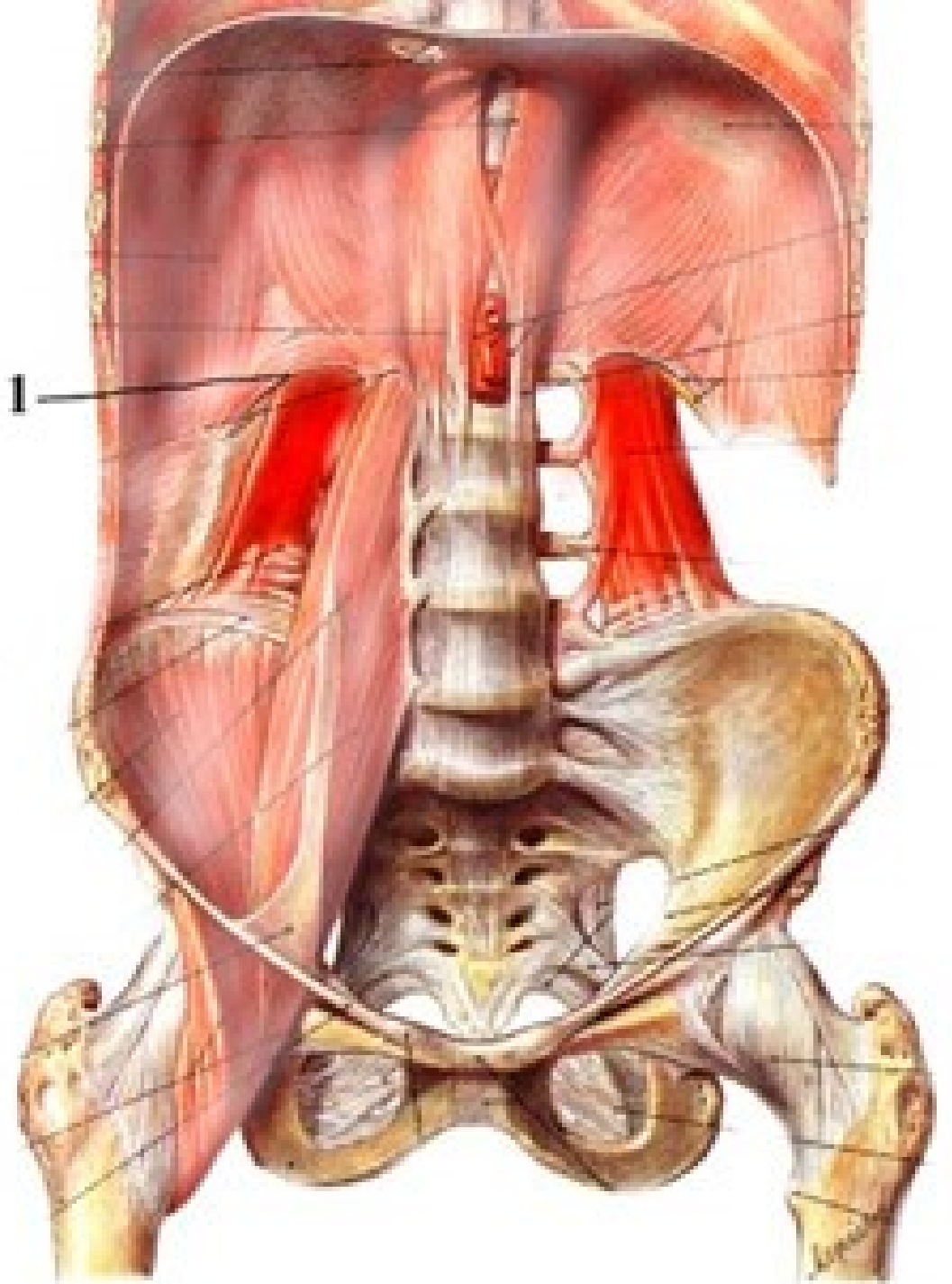
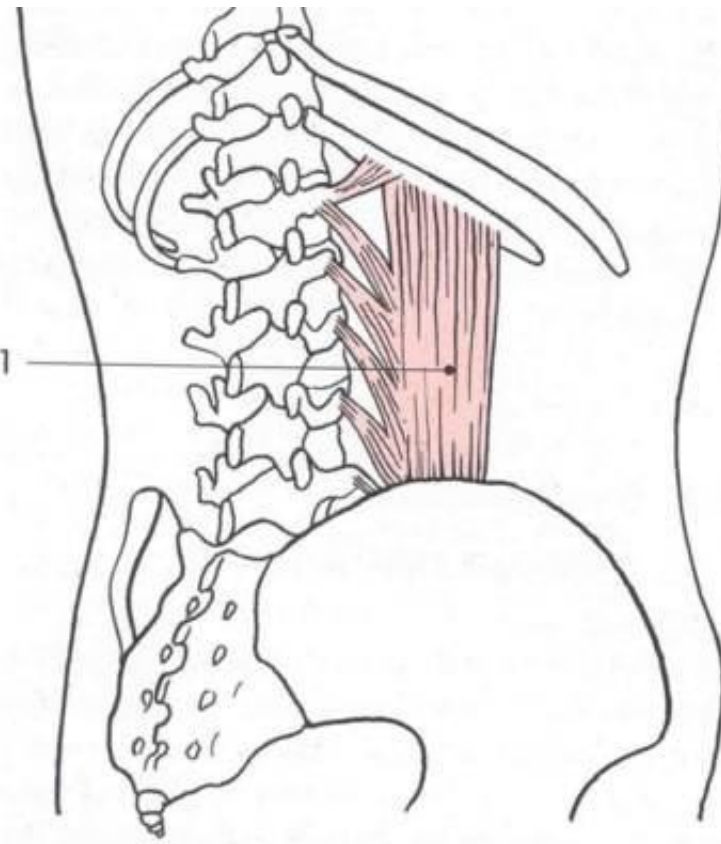
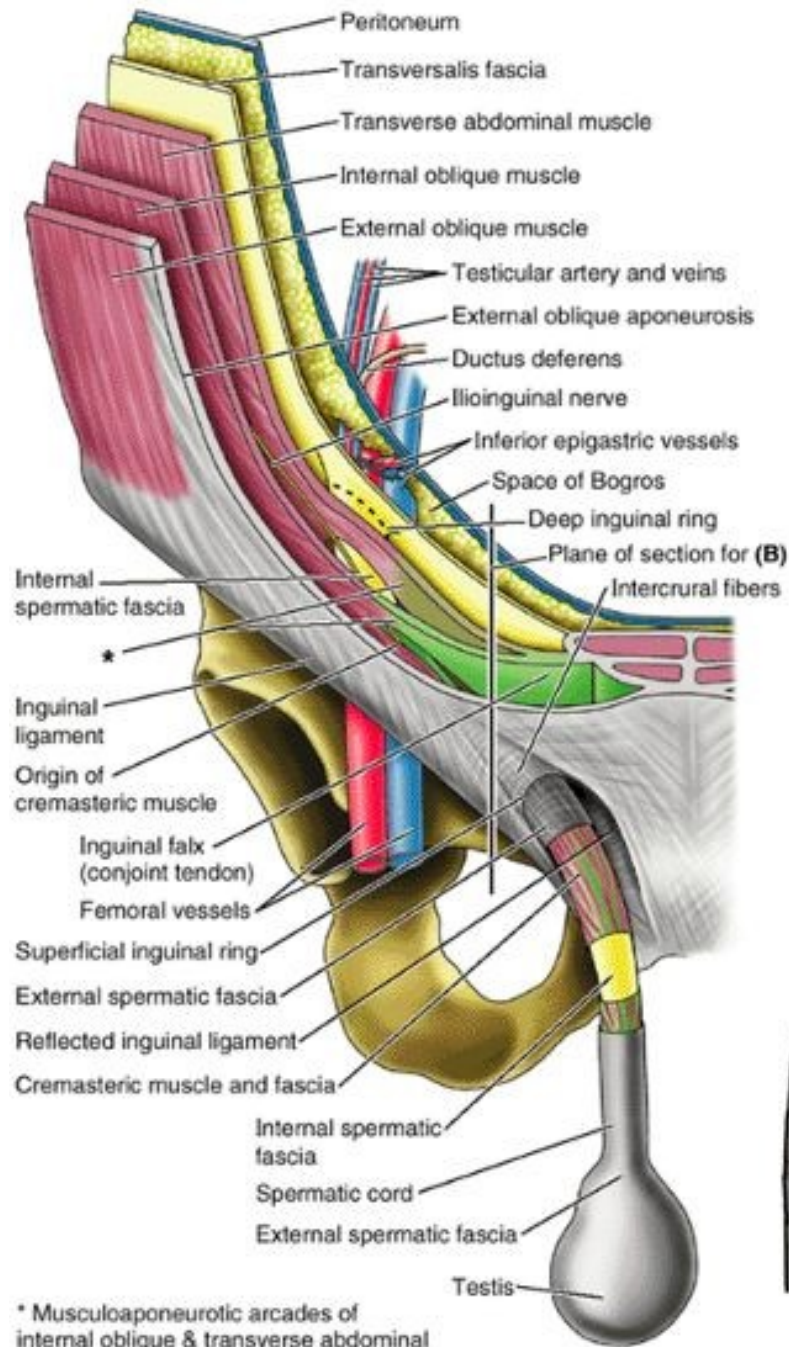


Mm.abdominis
Vagina m.recti abdominis
Canalis inguinalis
Peritoneal folds
Lacuna musculorum et vasorum



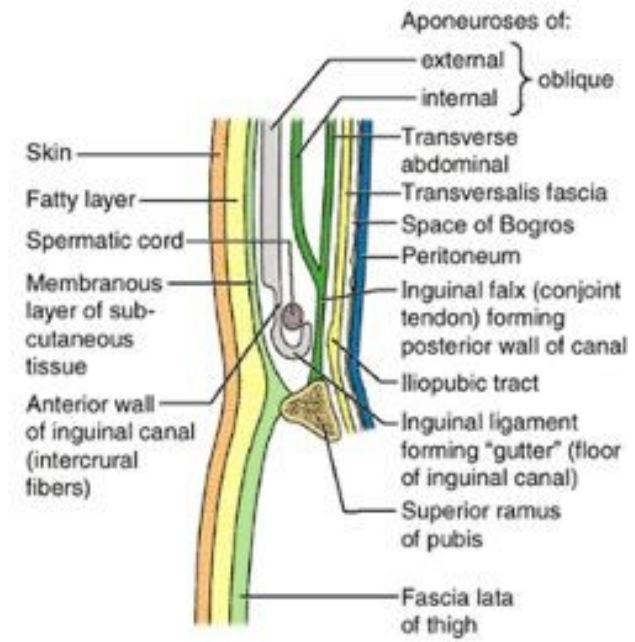




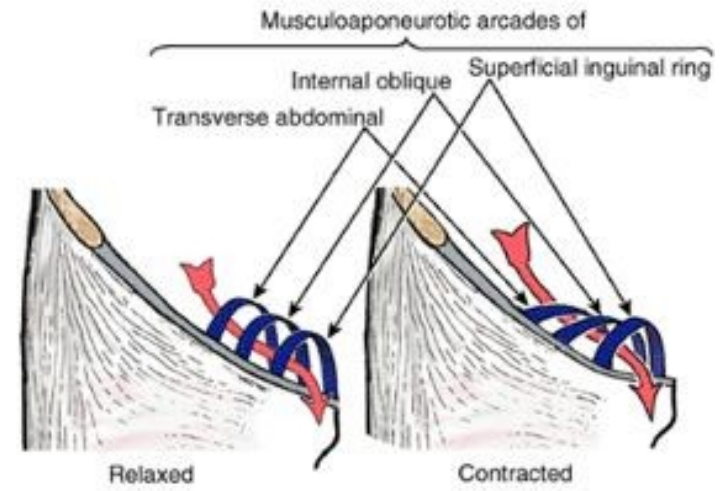


(A) Anterior view

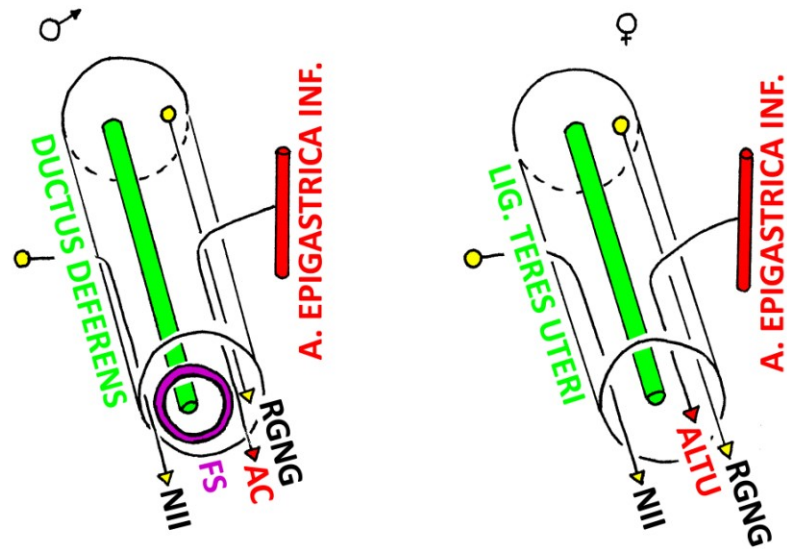
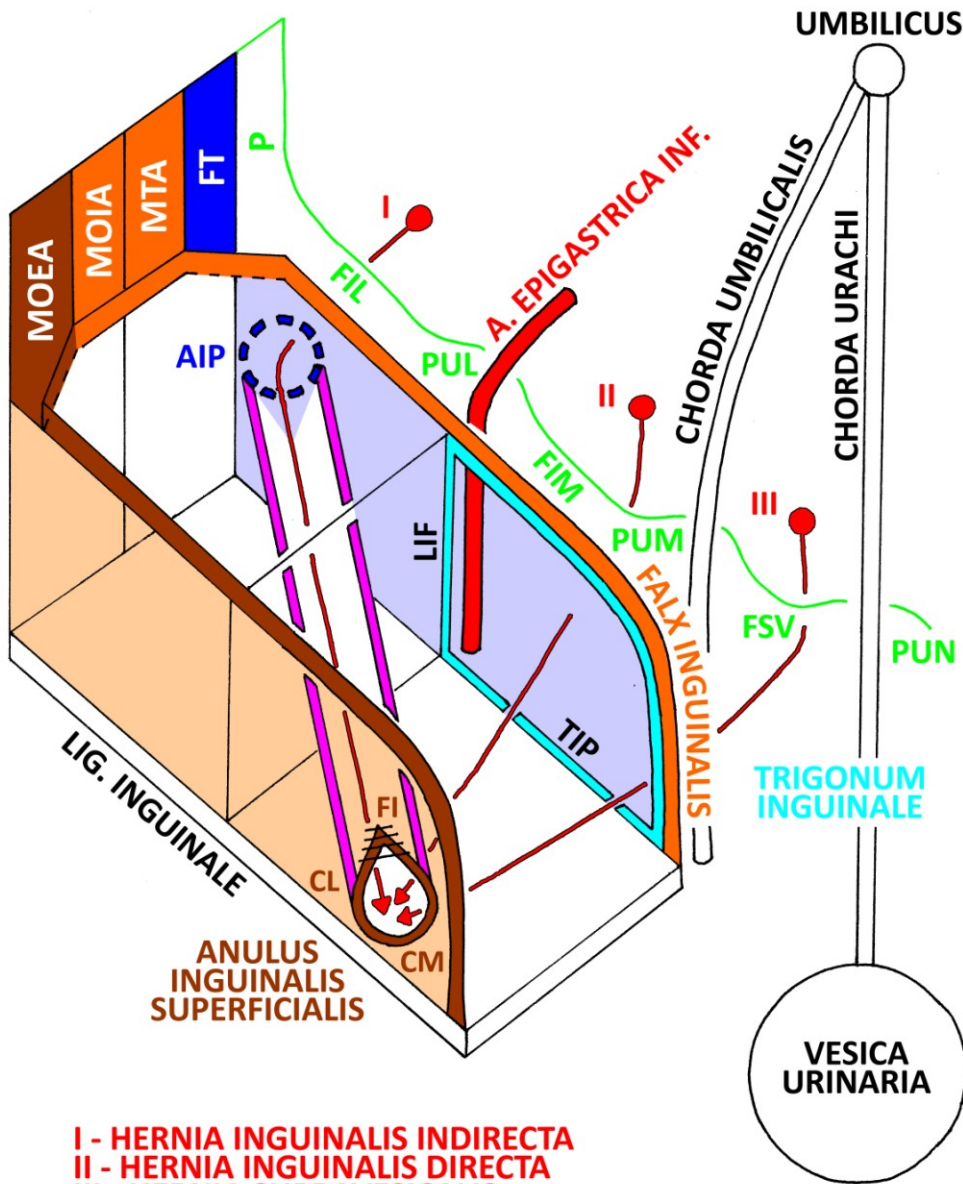
* Musculoaponeurotic arcades of internal oblique & transverse abdominal



(B) Schematic sagittal section



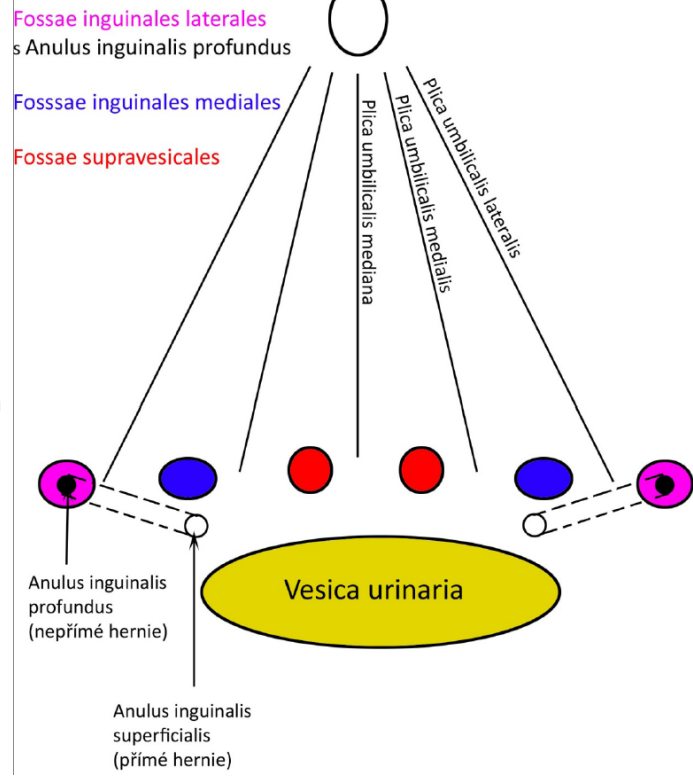
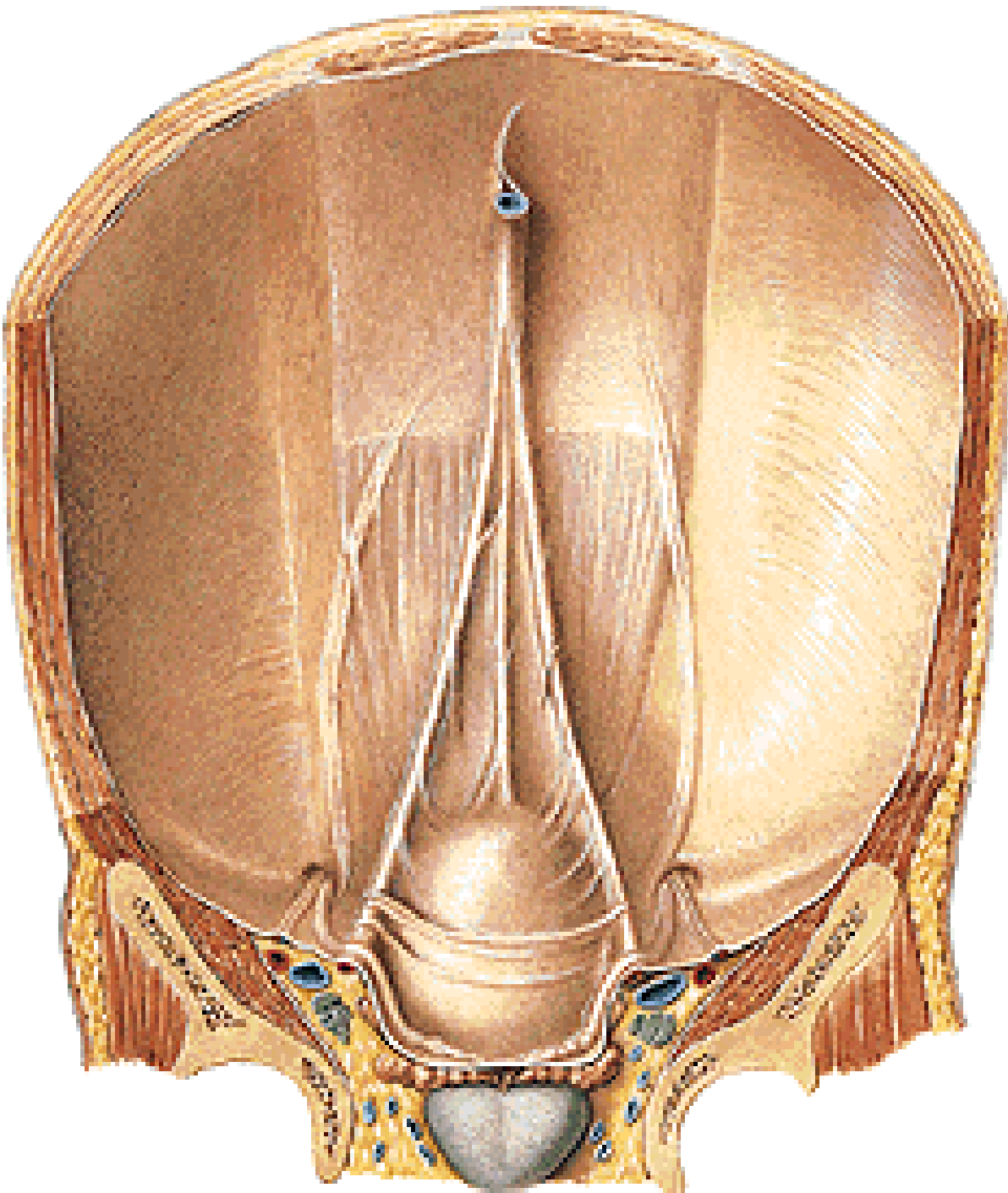
(C) Anterior view



MOEA - M. OBLIQUUS EXTERNUS ABDOMINIS
 MOIA - M. OBLIQUUS INTERNUS ABDOMINIS
 MTA - M. TRANSVERSUS ABDOMINIS
 FT - FASCIA TRANSVERSALIS
 AIP - ANULUS INGUINALIS PROFUNDUS
 P - PERITONEUM
 FIL - FOSSA INGUINALIS LAT.
 PUL - PLICA UMBILICALIS LATERALIS
 LIF - LIG. INTERFOVEOLARE
 FIM - FOSSA INGUINALIS MED.
 PUM - PLICA UMBILICALIS MEDIALIS
 FSV - FOSSA SUPRAVESICALIS
 PUN - PLICA UMBILICALIS MEDIANA
 TIP - TRACTUS ILIOPUBICUS
 FI - FIBRAE INTERCRURALES
 CL - CRUS LATERALE
 CM - CRUS MEDIALE

NII - N. ILIOINGUINALIS
 FS - FUNICULUS SPERMATICUS
 AC - A. CREMASTERICA
 RGNG - R. GENITALIS N. GENITOFEMORALIS
 ALTU - A. LIGAMENTI TERETIS UTERI

I - HERNIA INGUINALIS INDIRECTA
 II - HERNIA INGUINALIS DIRECTA
 III - HERNIA SUPRAVESICALIS



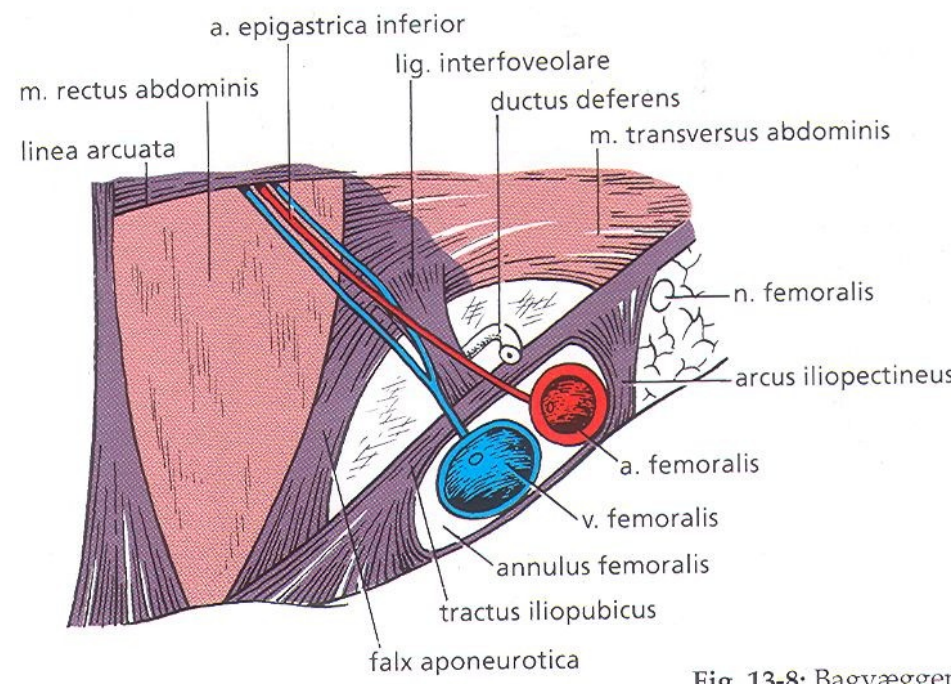
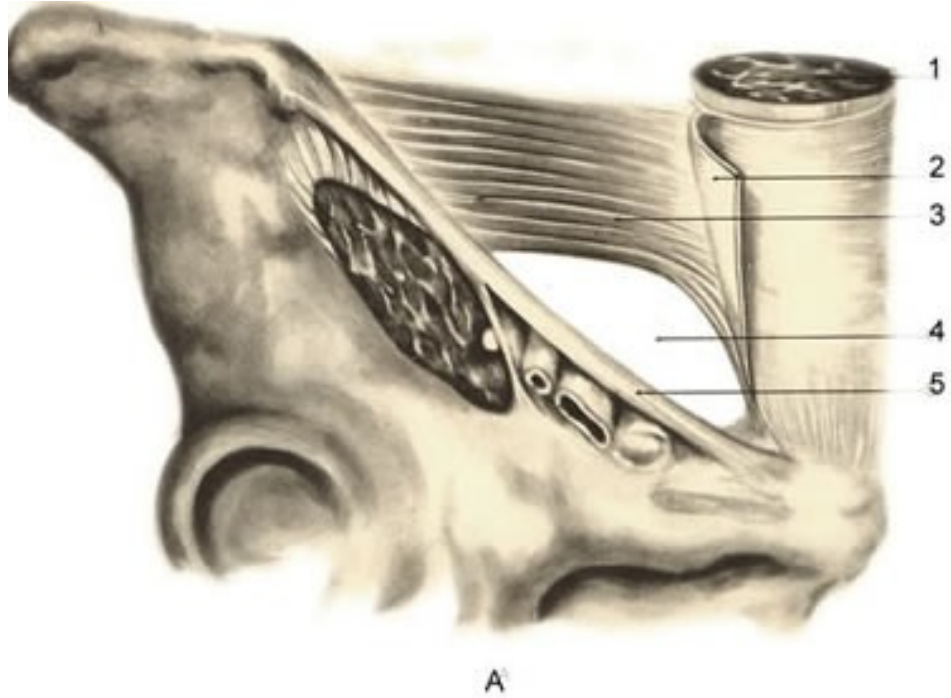


Fig. 13-8: Bagvæggen

