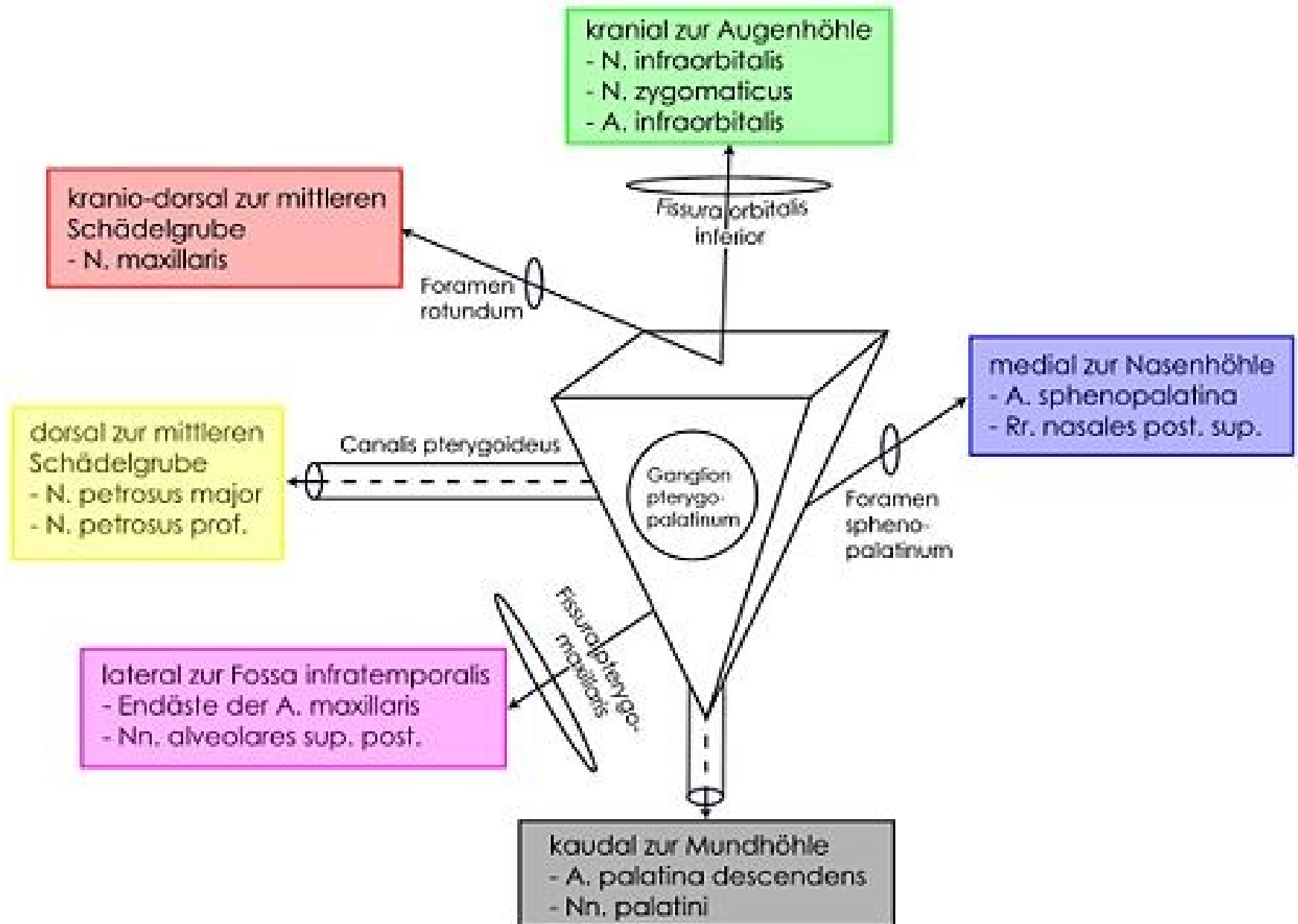


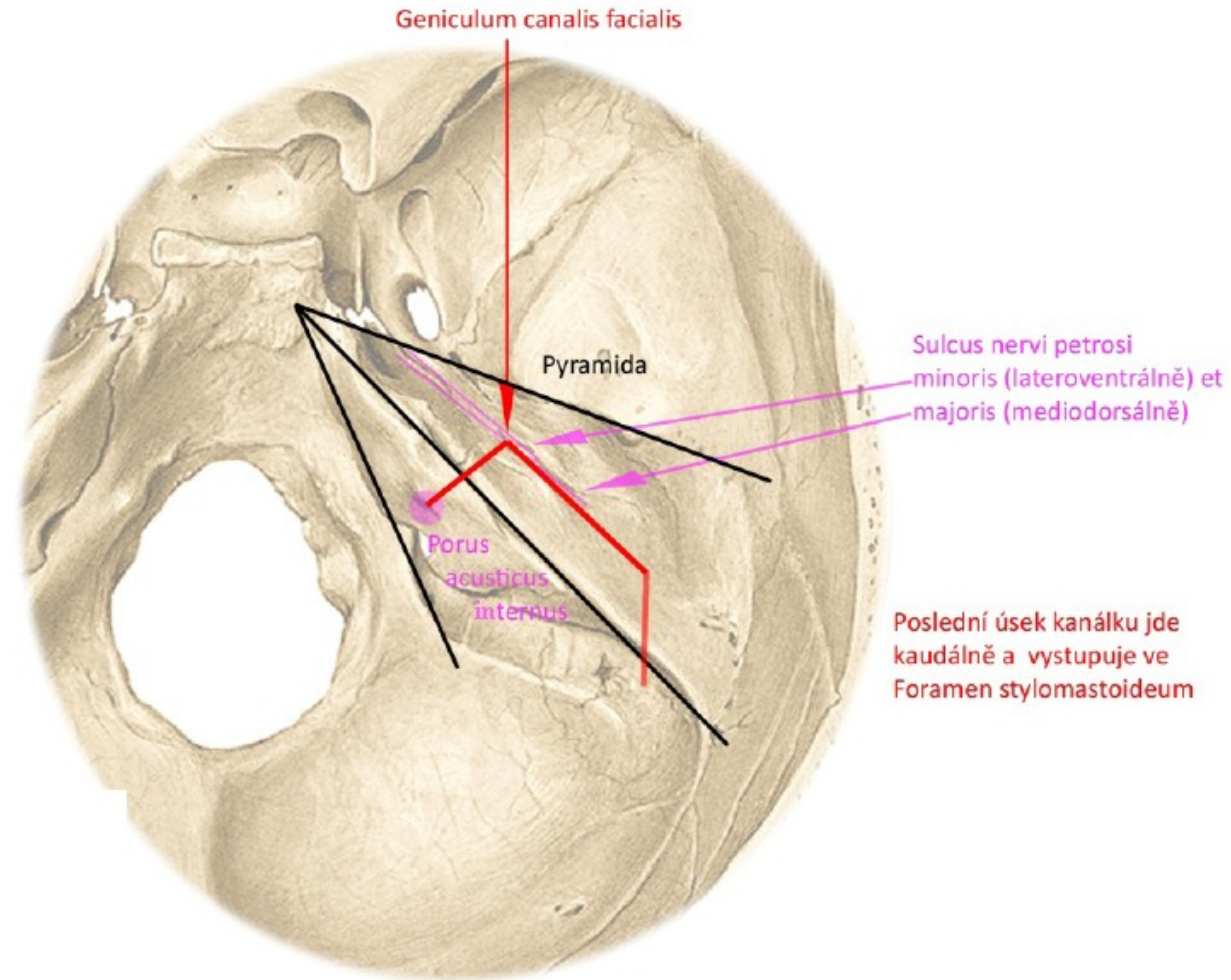
# **SCHÉMATA 1. A 2. SEMESTR**

# Fossa pterygopalatina

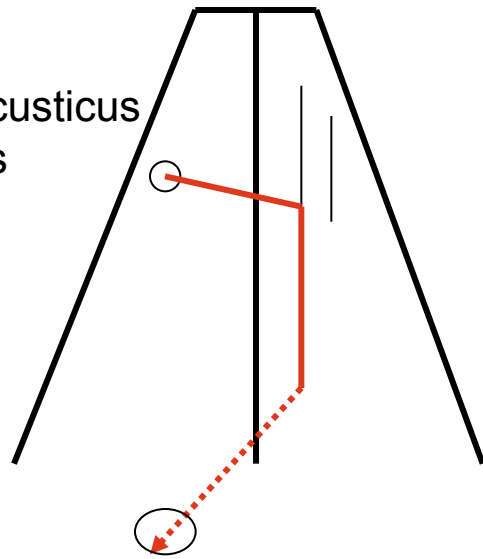


# PRŮBĚH CANALIS NERVI FACIALIS V PYRAMIDĚ

## Pohled shora

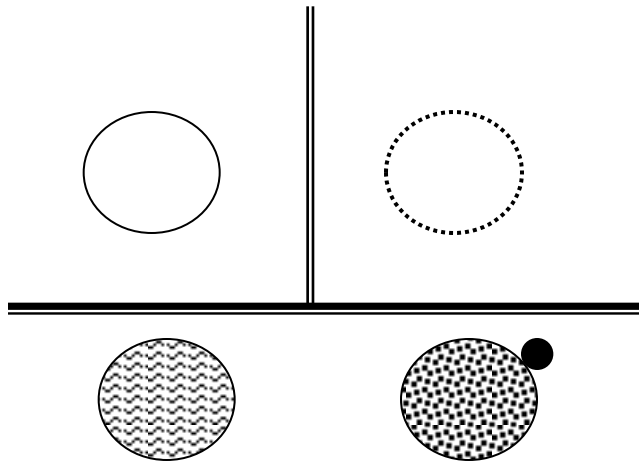
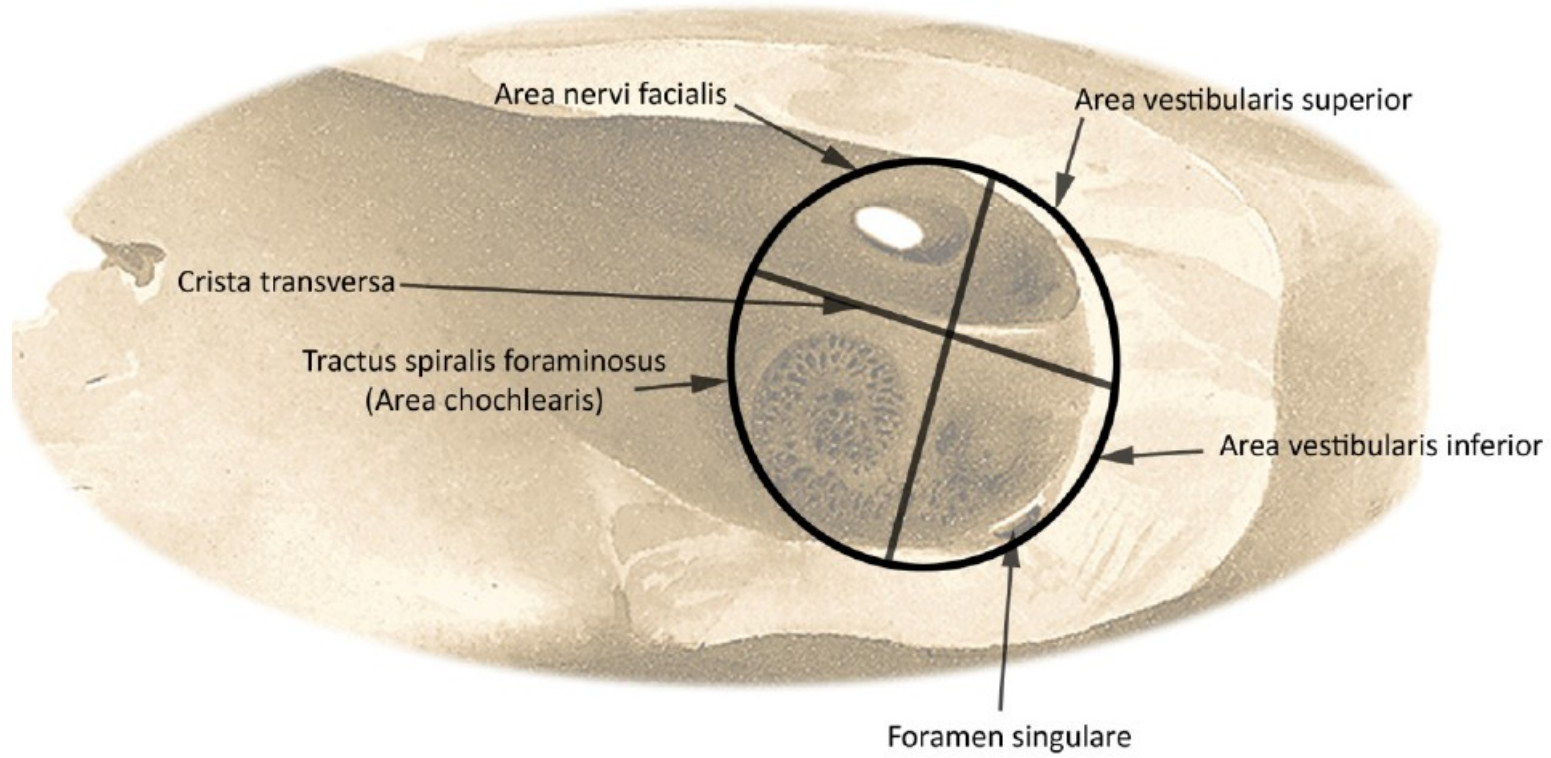


porus acusticus internus

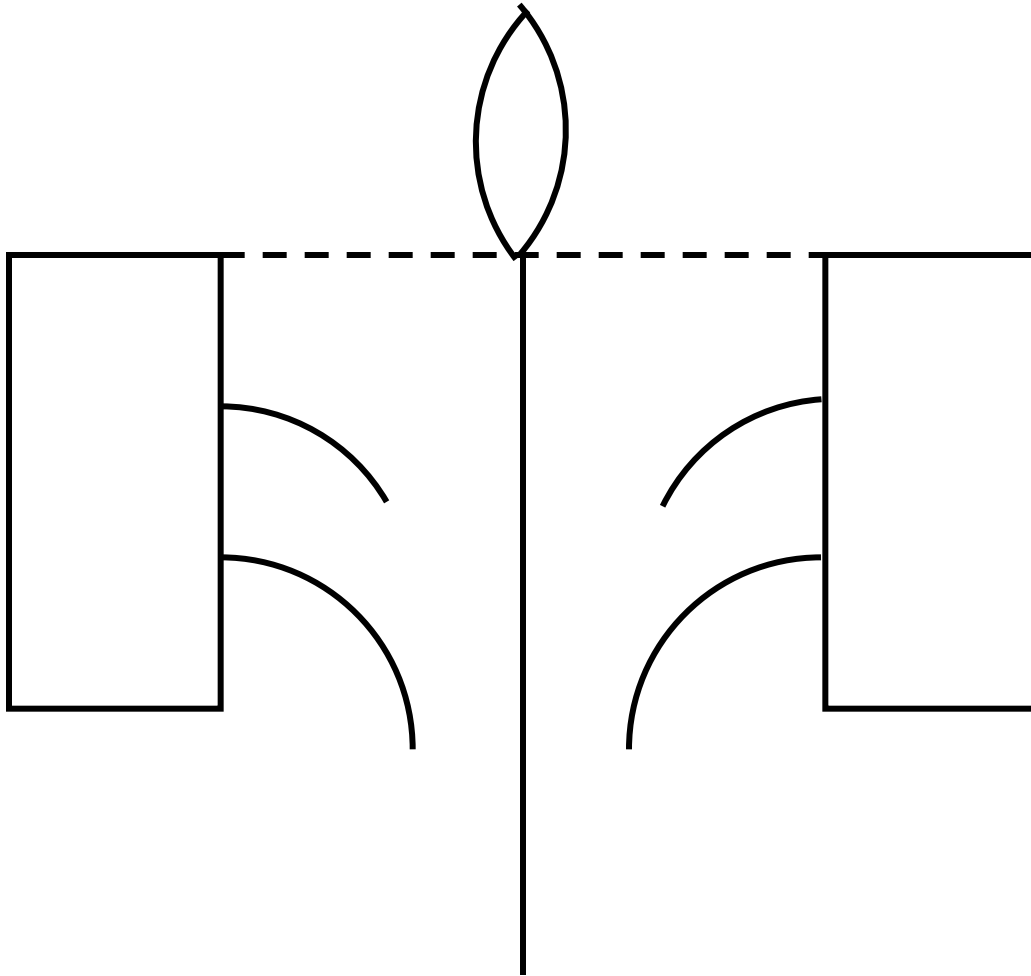


foramen stylomastoideum

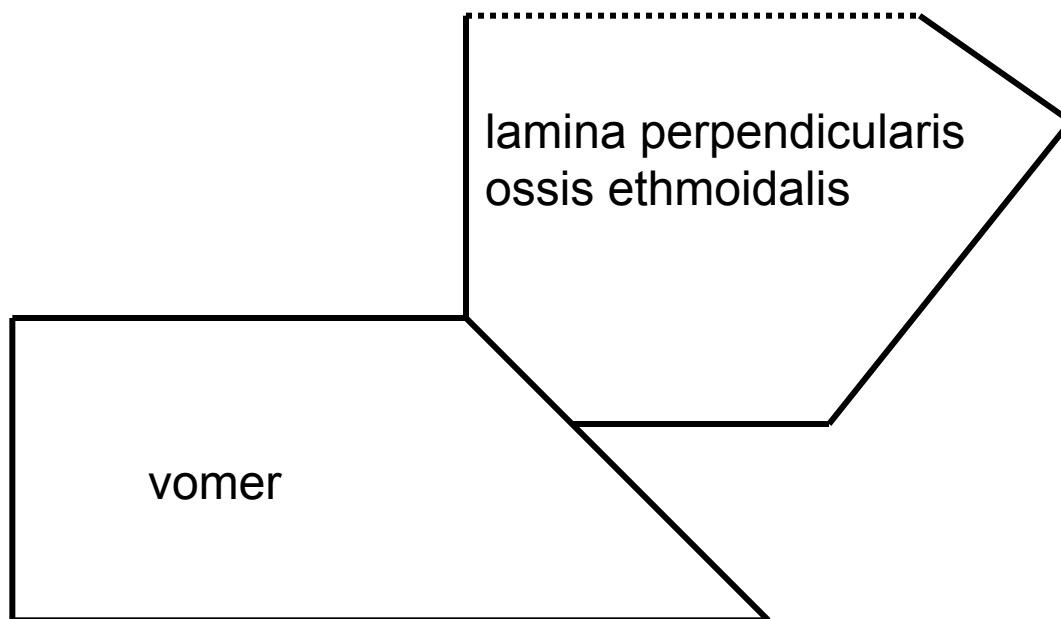
# ROZDĚLENÍ FUNDUS MEATUS ACUSTICUS INTERNUS



# Os ethmoidale



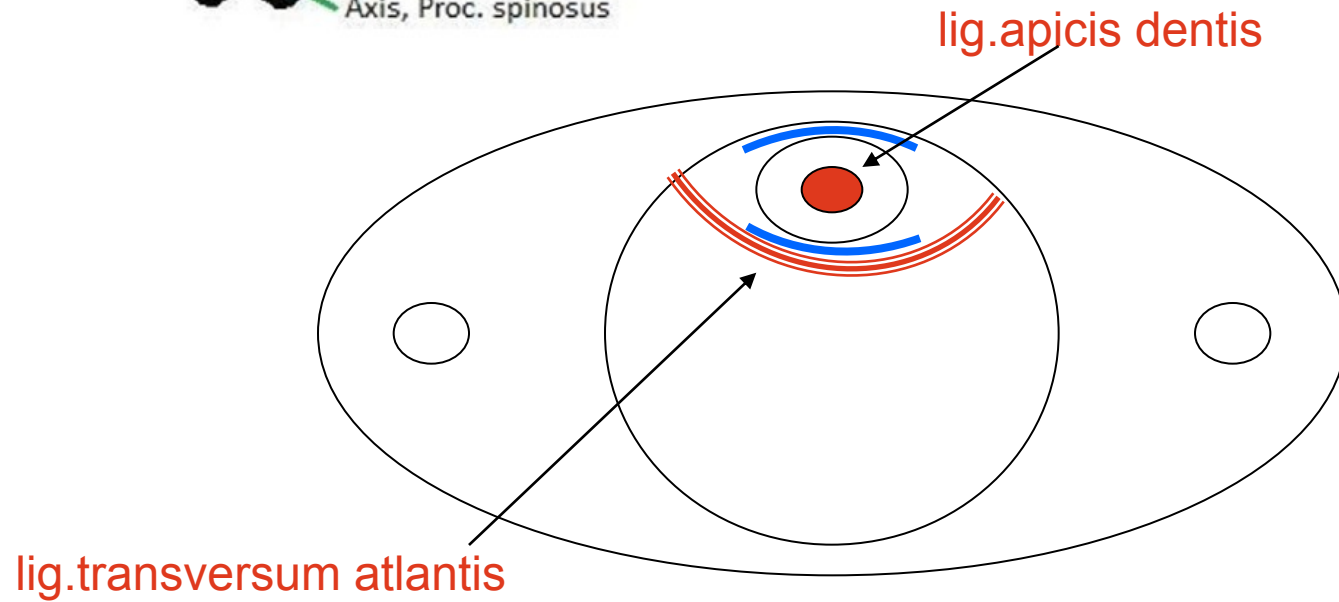
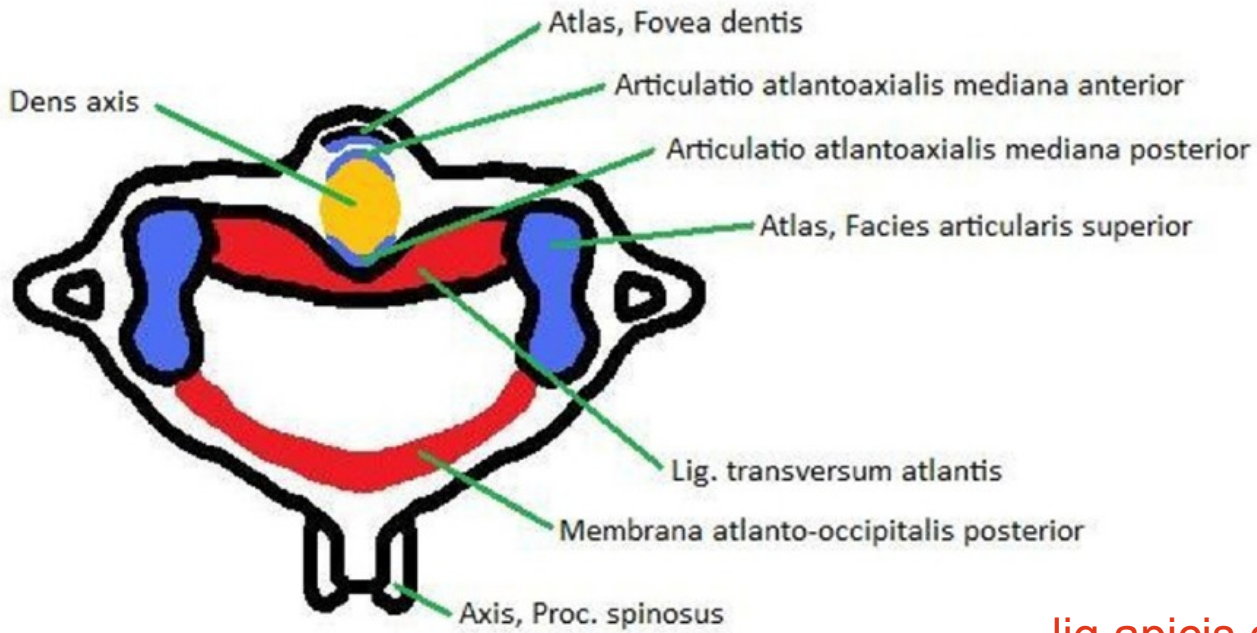
## Kostěná nosní přepážka



# Rozdíl mezi diskem a meniskem na příčném řezu



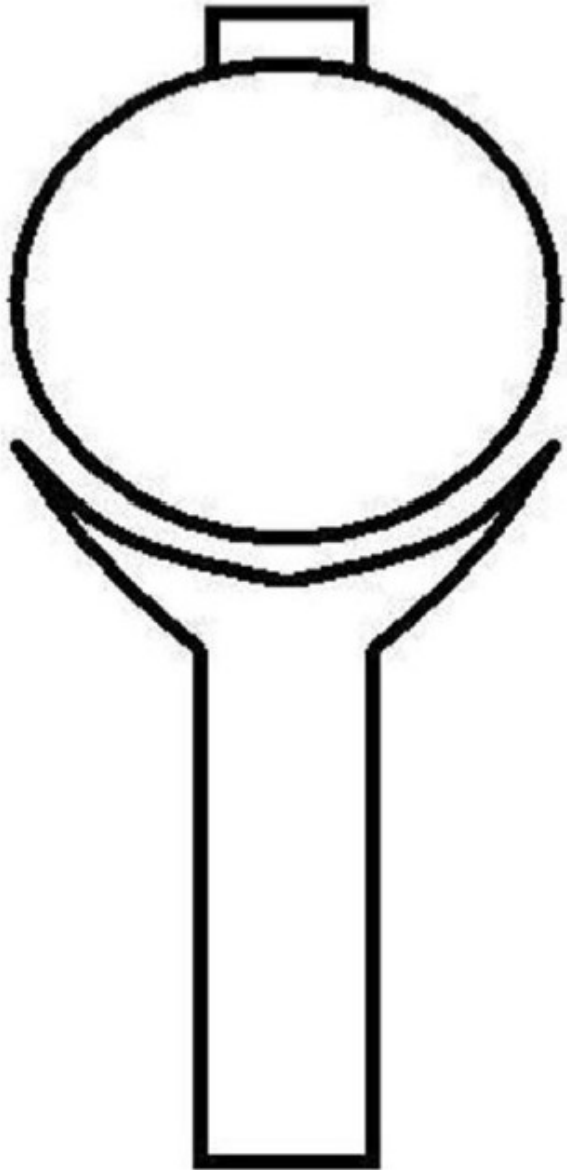
# Vazy atlanto-axiálního spojení, pohled shora



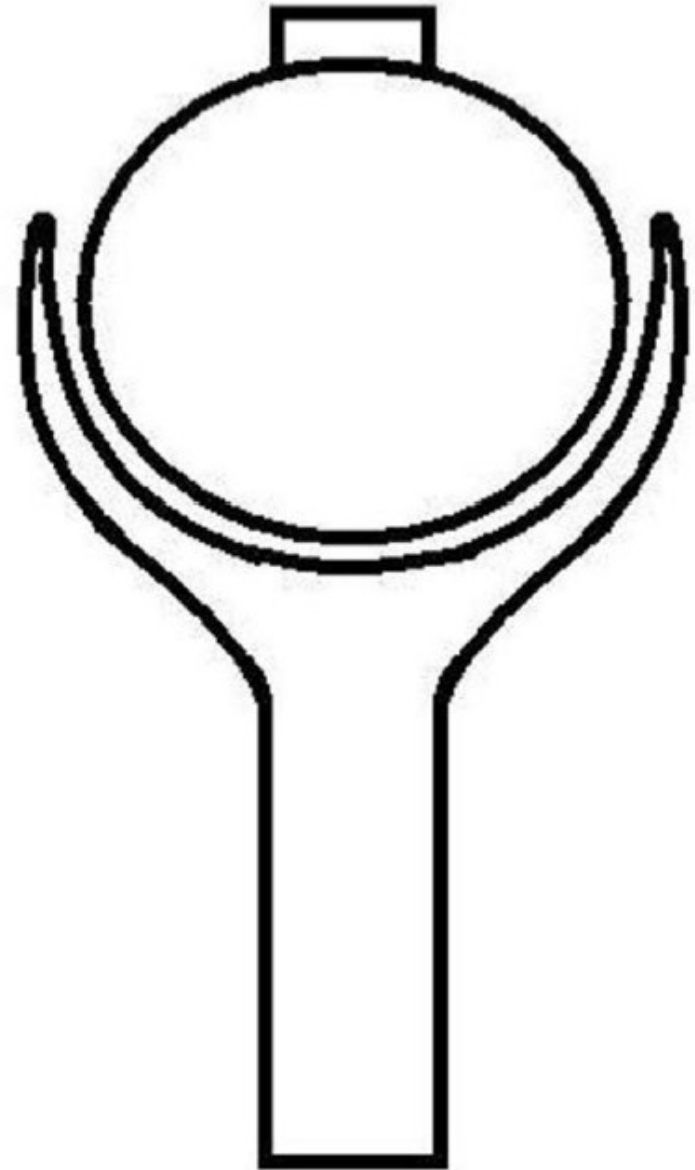


# Rozdíl mezi arthrodiem et enarthrosis

Kloub kulový volný (arthrodia)

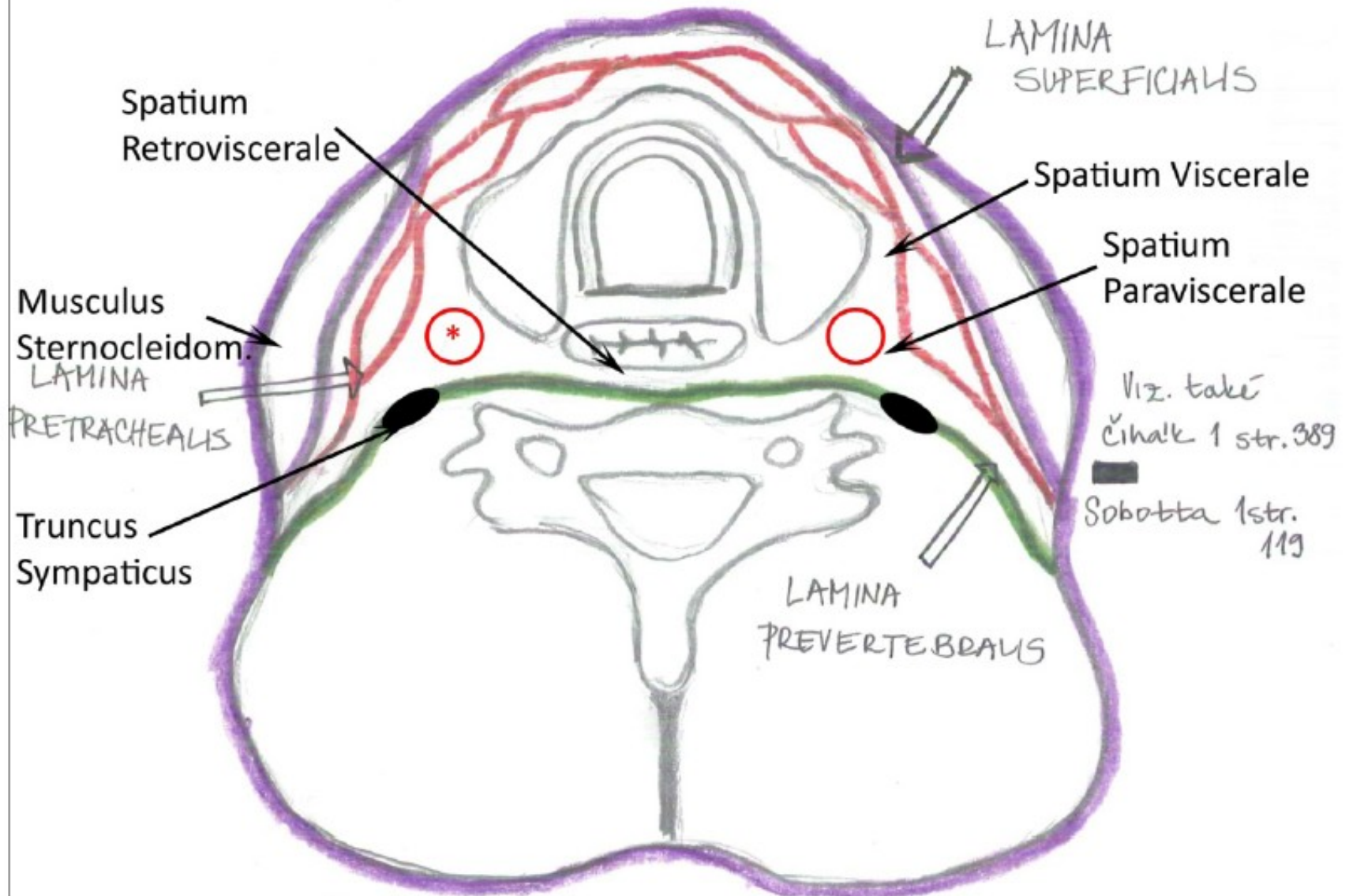


Kloub kulový omezený (enarthrosis)



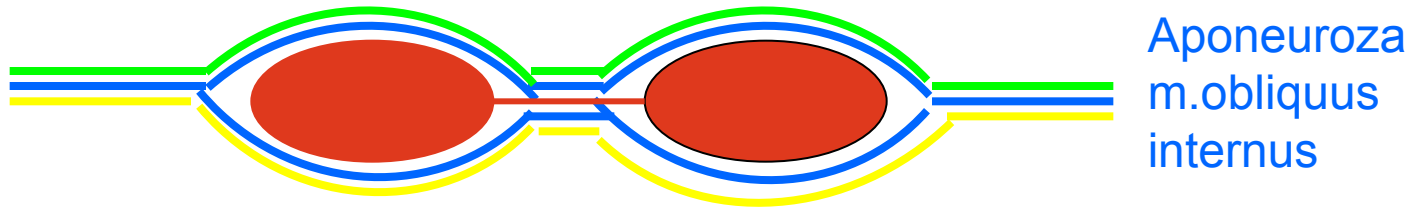
# Fasciae colli (horizontální řez)

\* A. carotis communis, v. jugularis interna, n. vagus

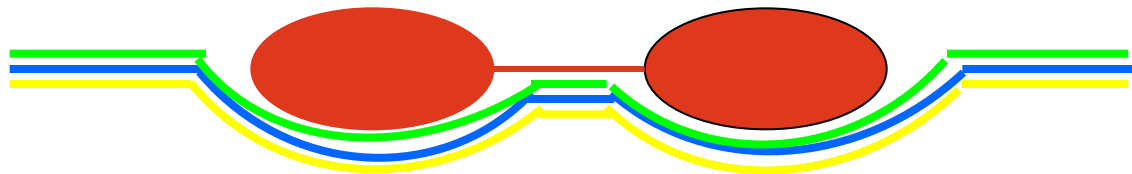


# Vagina m.recti abd.

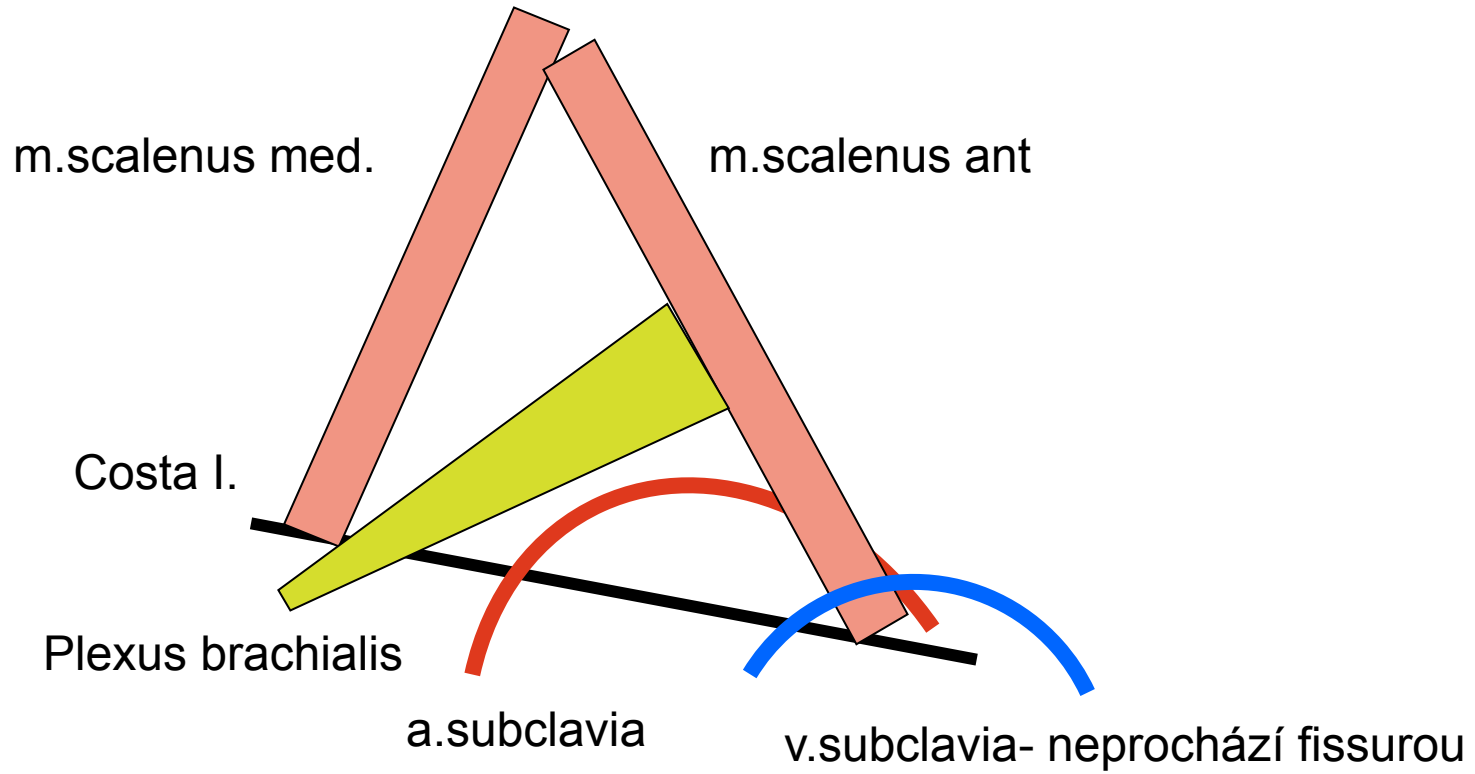
Aponeuroza m.transversus abdominis



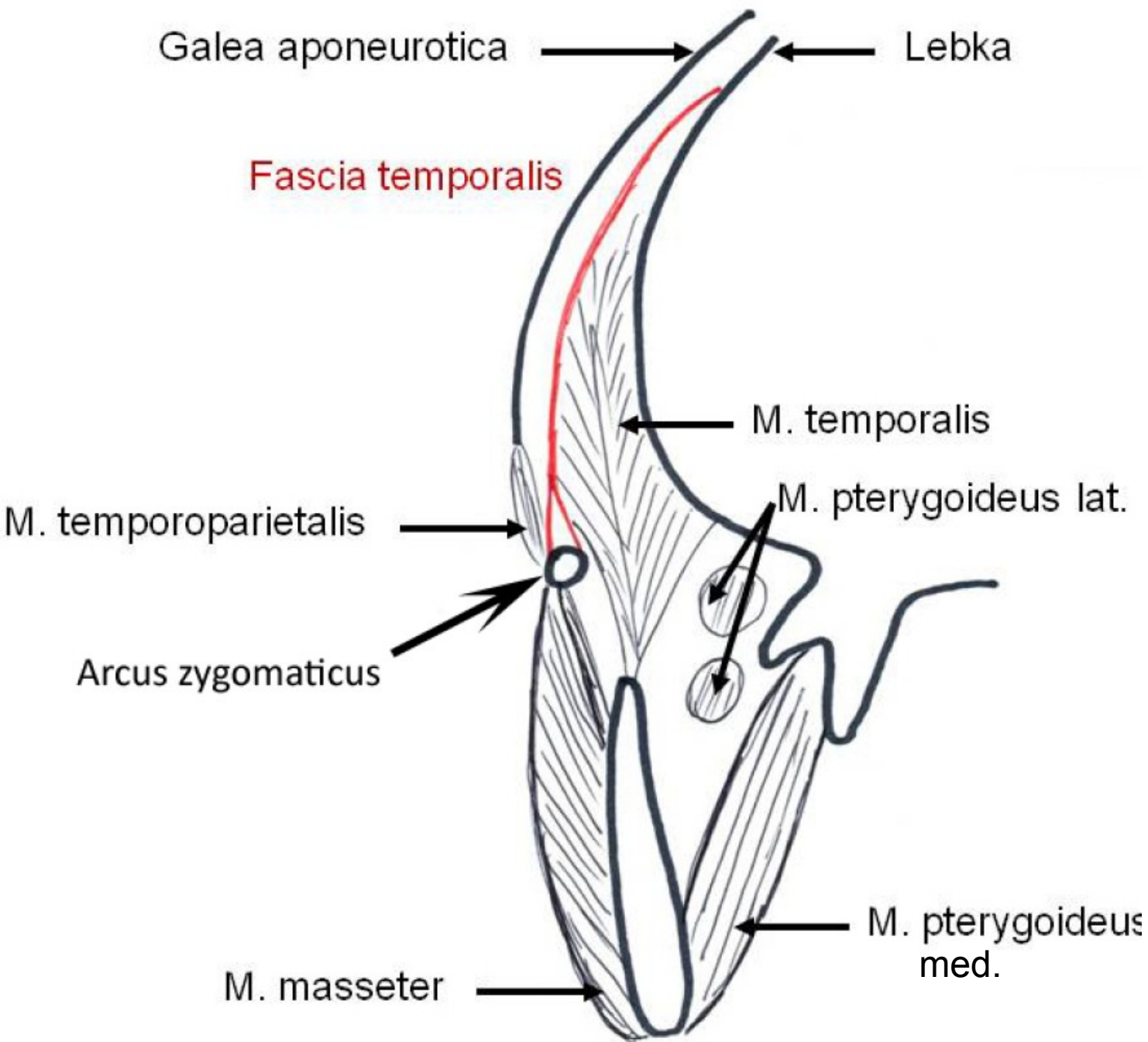
Aponeuroza m.obliquus externus

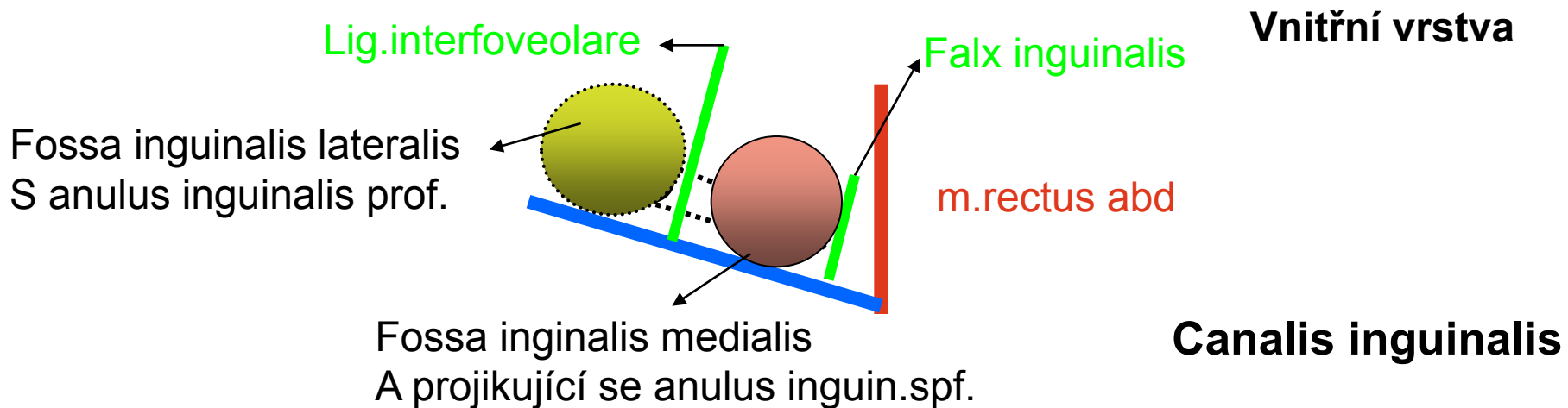
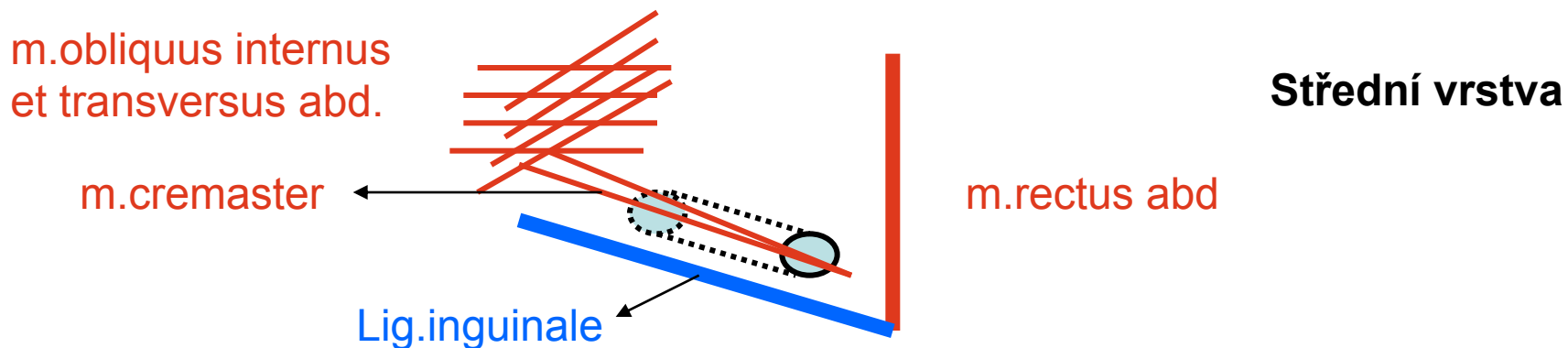
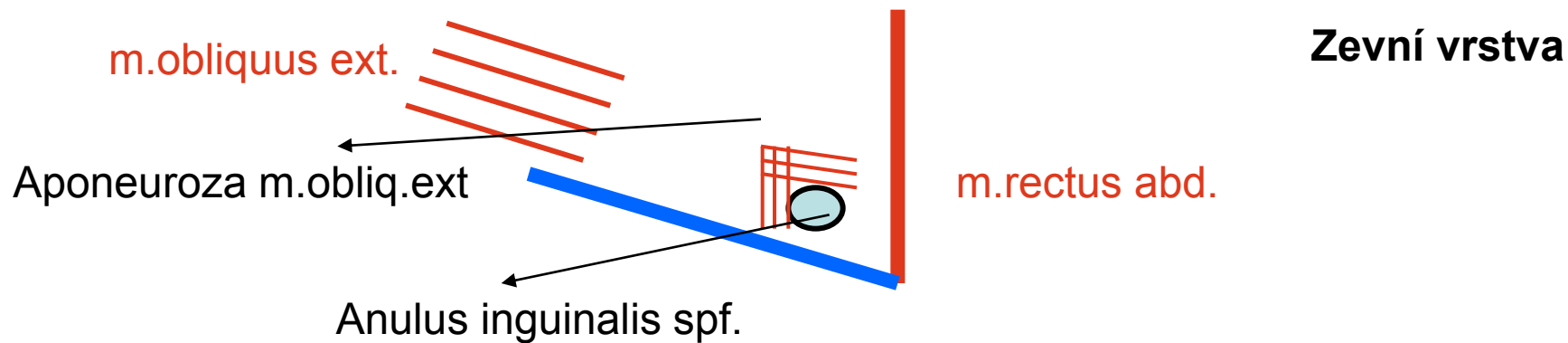


# Fissura scalenorum

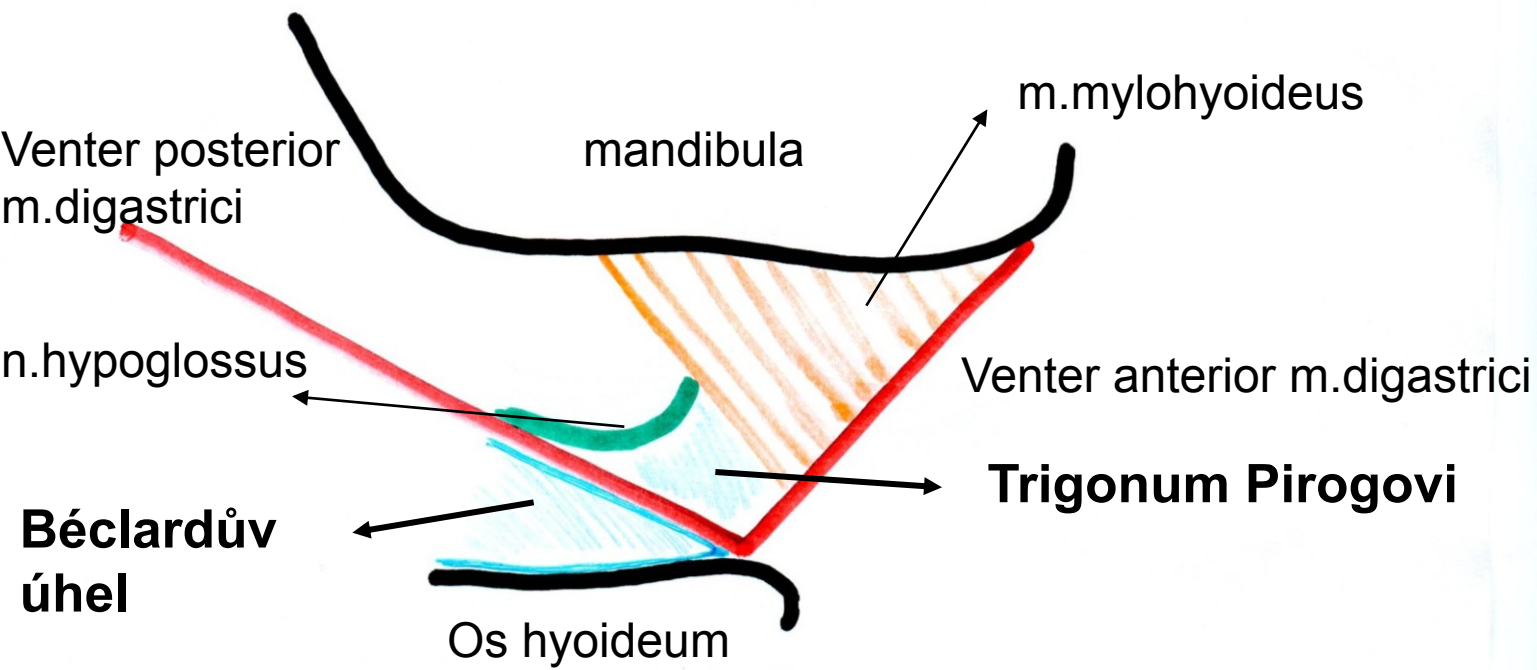
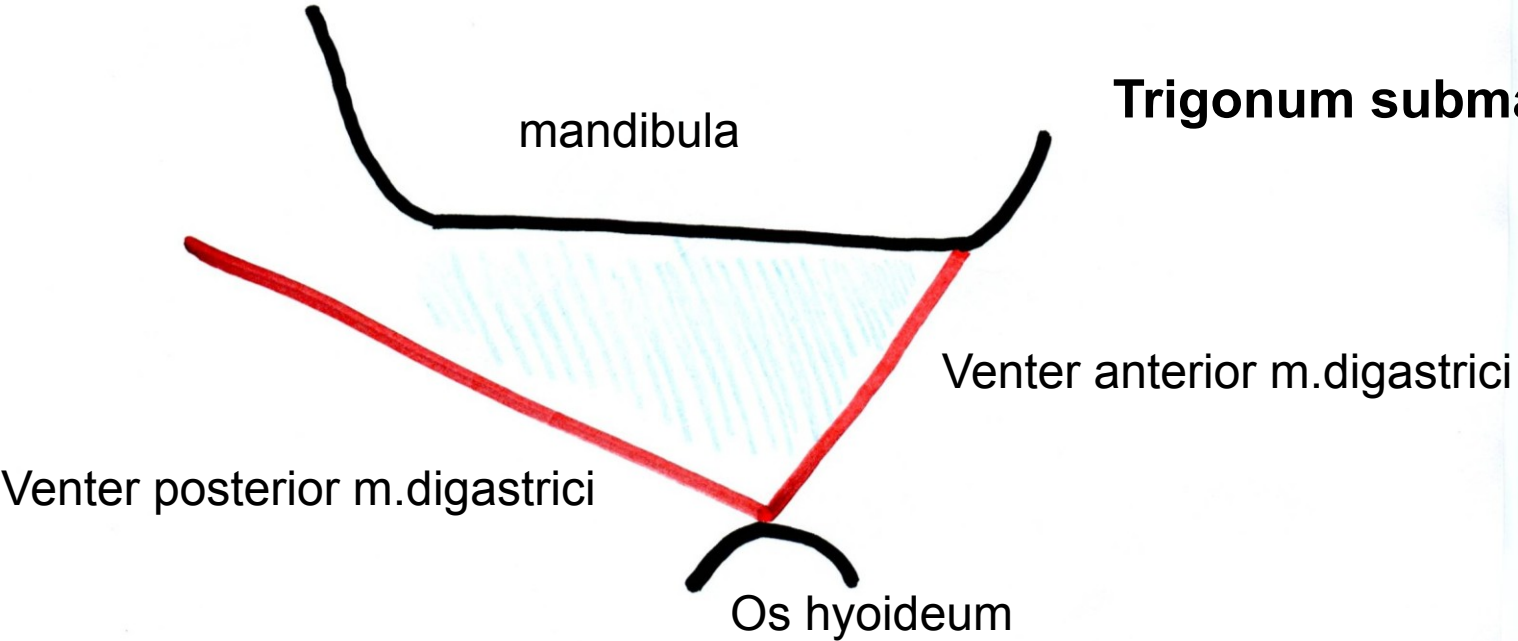


# Fossa temporalis na frontálním řezu, úpon fascie





# Trigonum submandibulare

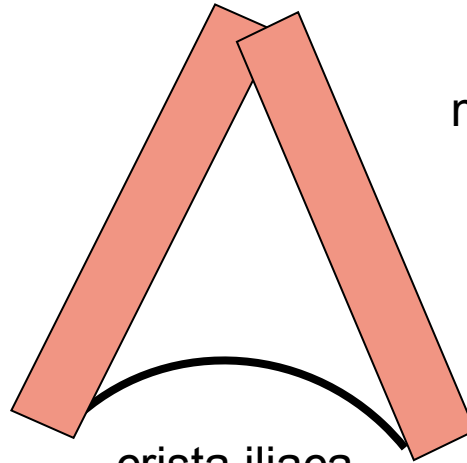


**Béclardův  
úhel**

# Trigonum lumbale- Petiti

m.latissimus dorsi

m.obliquus externus



crista iliaca

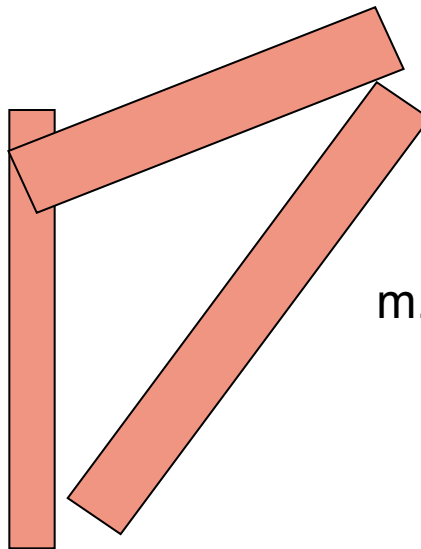


## Trigonum Grynfelti

m.erector spinae

m.serratus posterior infer.

m.obliquus internus



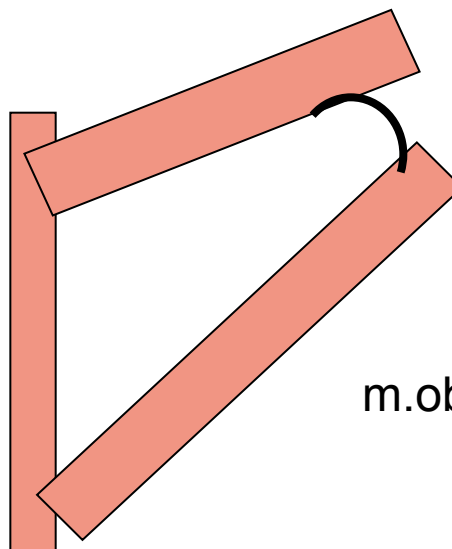
## Tetragon Krausei

m.erector spinae

m.serratus posterior infer.

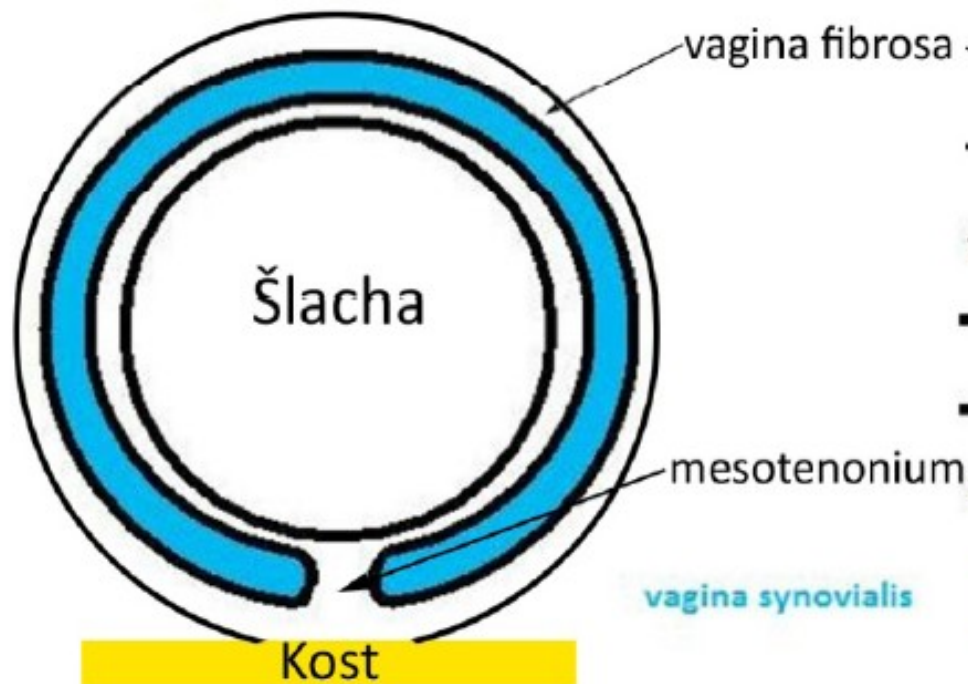costa I.

m.obliquus internus

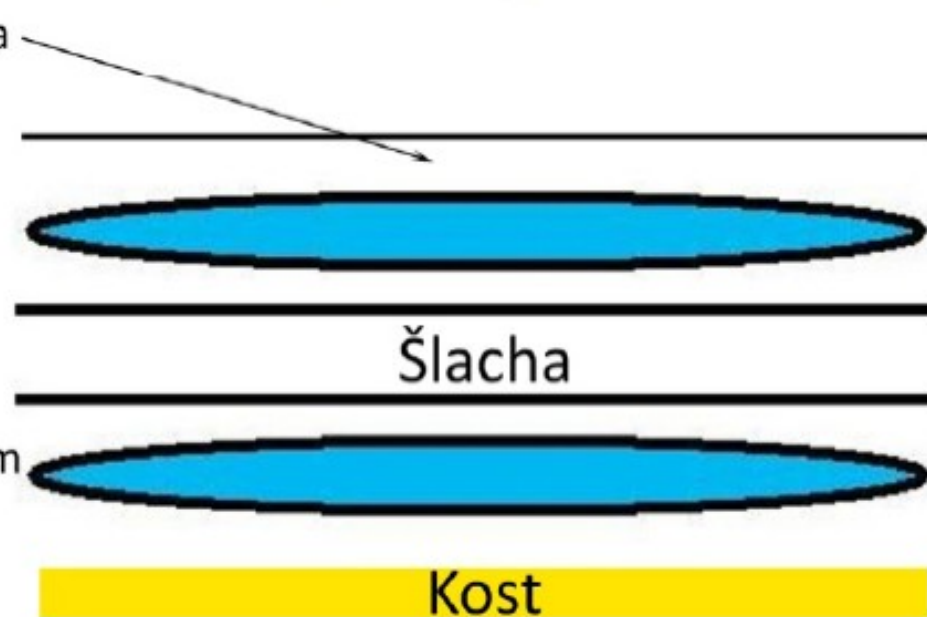


# Vagina synovialis na podélném příčném řezu

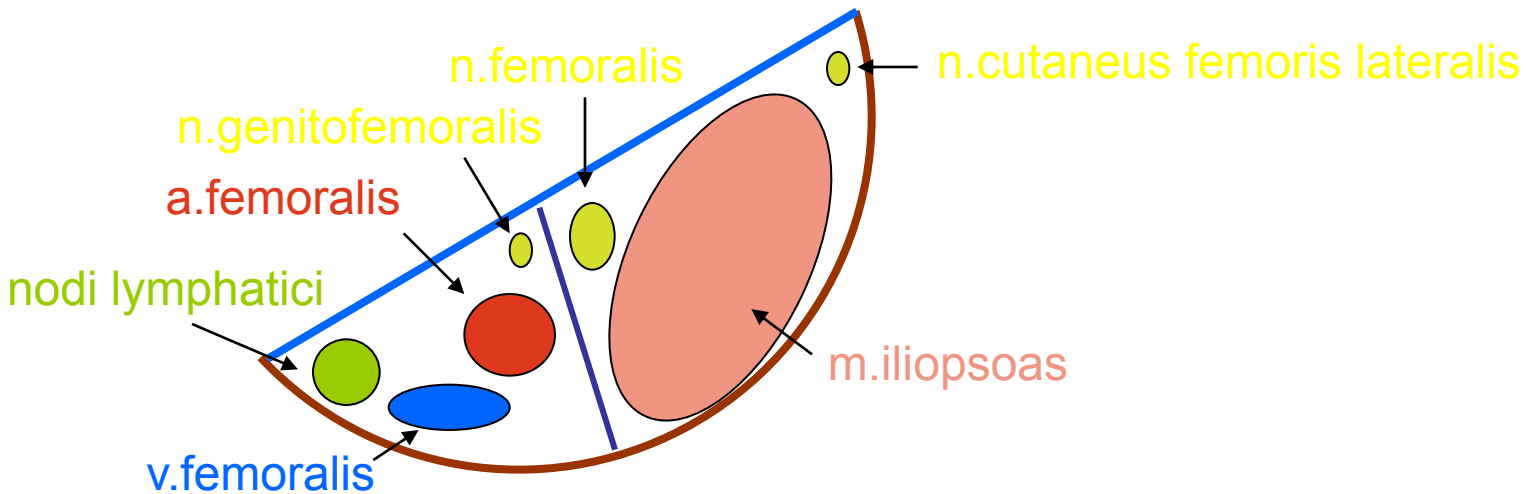
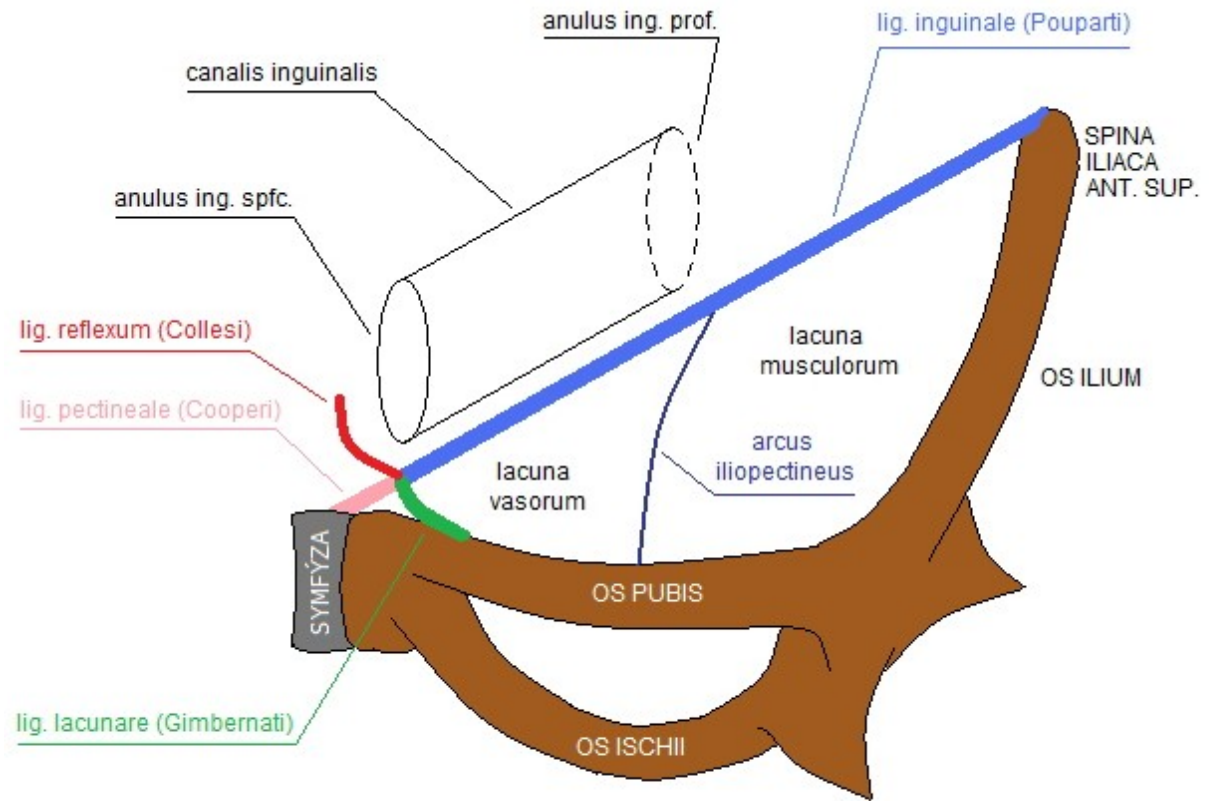
příčný řez



podélný řez



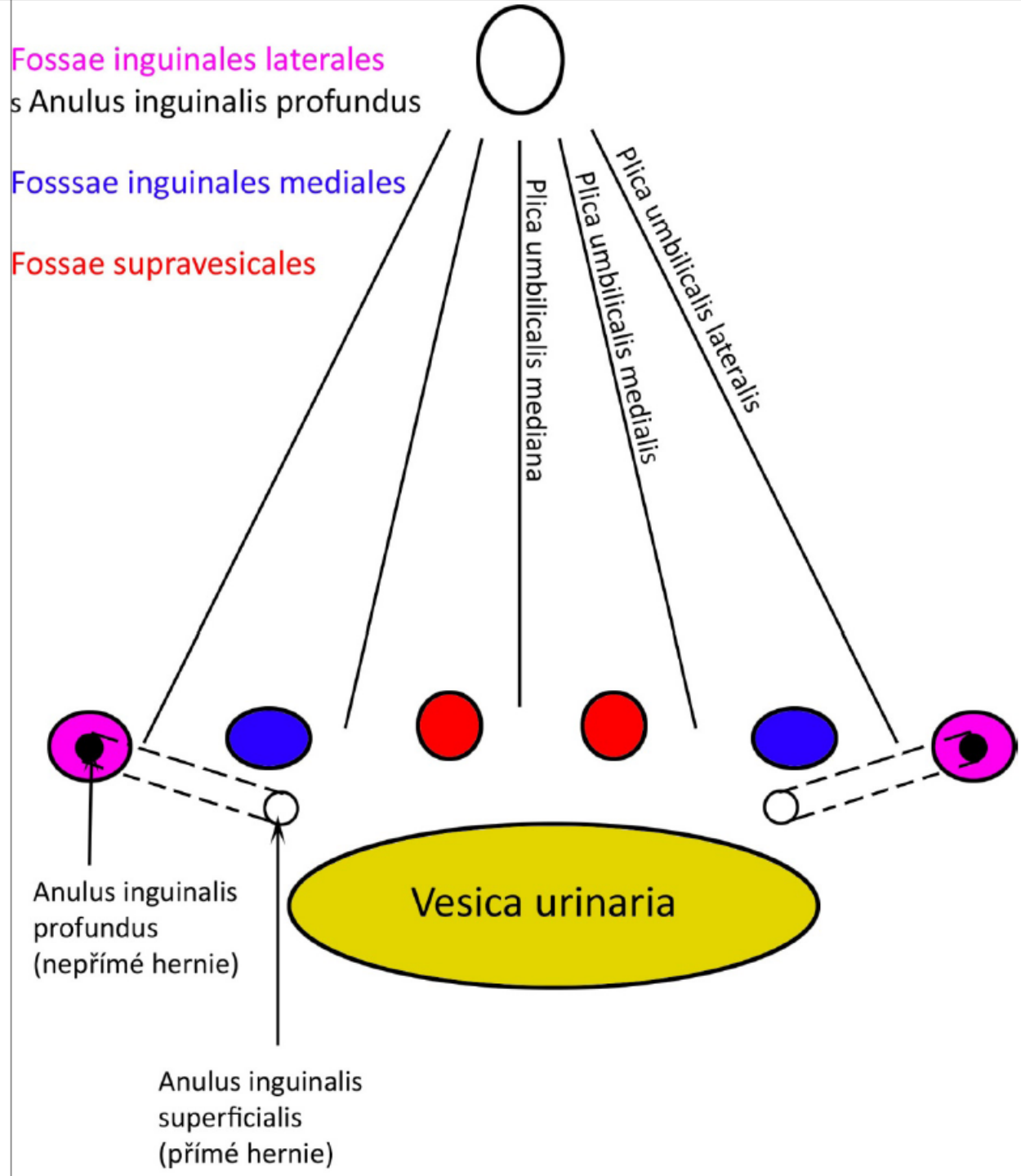
# Lacuna musculorum et vasorum



Plica umb.**mediana**=  
Lig.umb.**medialis**=  
obliterovaný urachus

Plica umb.**medialis**=  
Lig.umb.**laterale**=  
obliterovaná a.umbilicalis

Plica umb.**lateralis**=  
Lig.interfoveolare=  
vasa epigastrica inferiora



**Fossae inguinales laterales**  
s Anulus inguinalis profundus

**Fossae inguinales mediales**

**Fossae supravesicales**

Plica umbilicalis mediana

Plica umbilicalis medialis

Plica umbilicalis lateralis

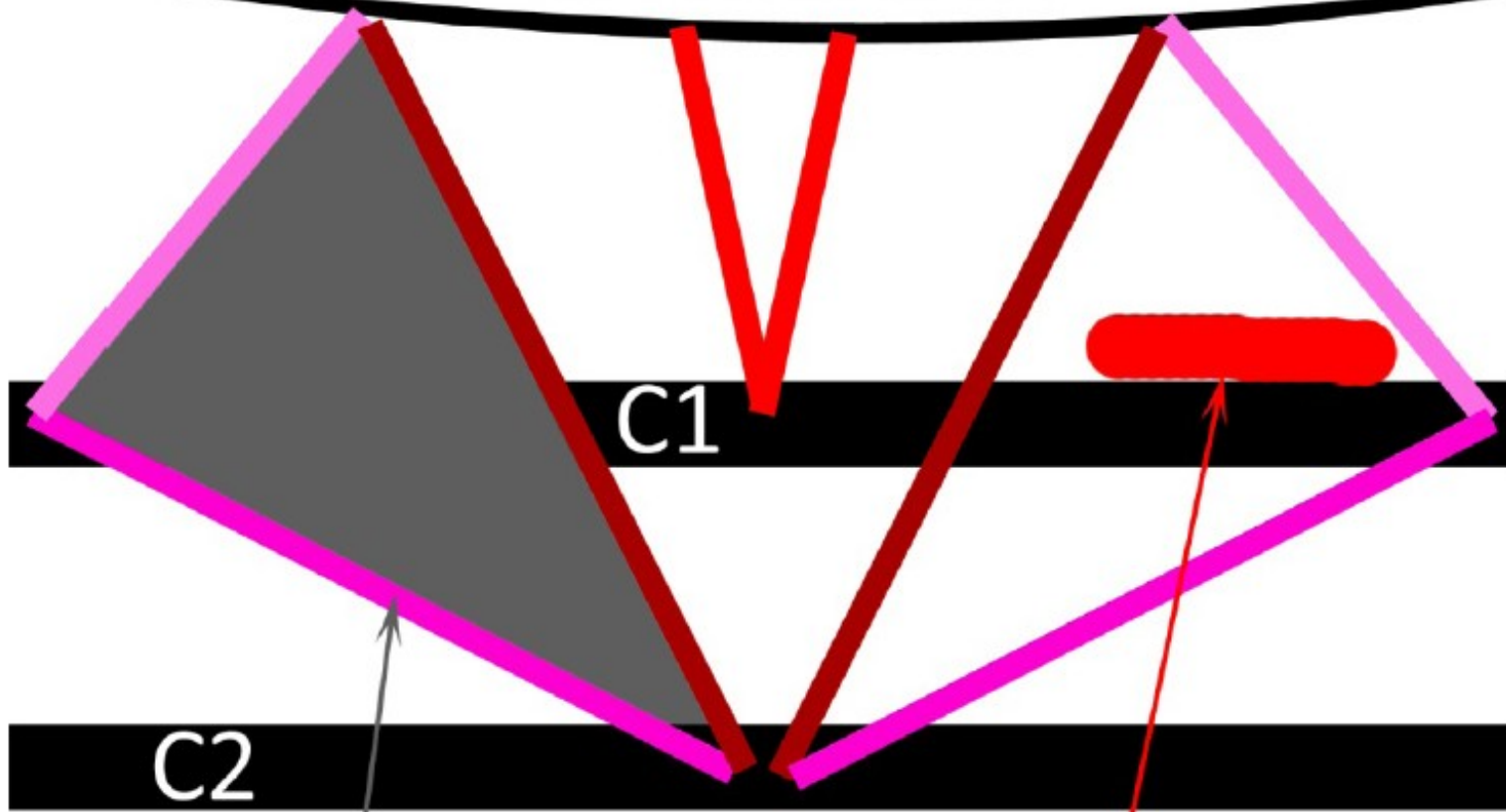
Anulus inguinalis profundus  
(nepřímé hernie)

Anulus inguinalis superficialis  
(přímé hernie)

Vesica urinaria

# Trigonum suboccipitale

Linea nuchae inferior



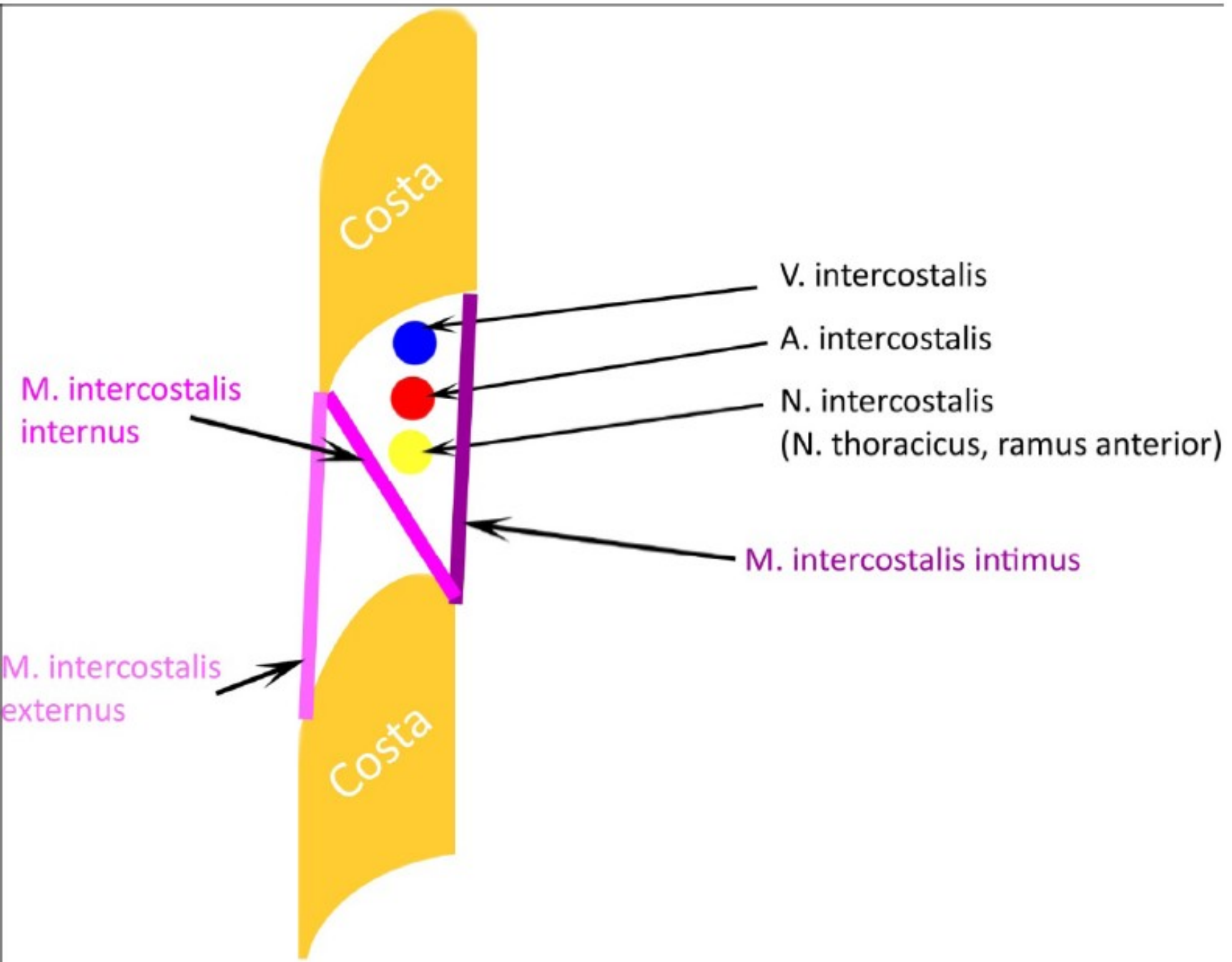
C1

C2

Trigonum suboccipitale

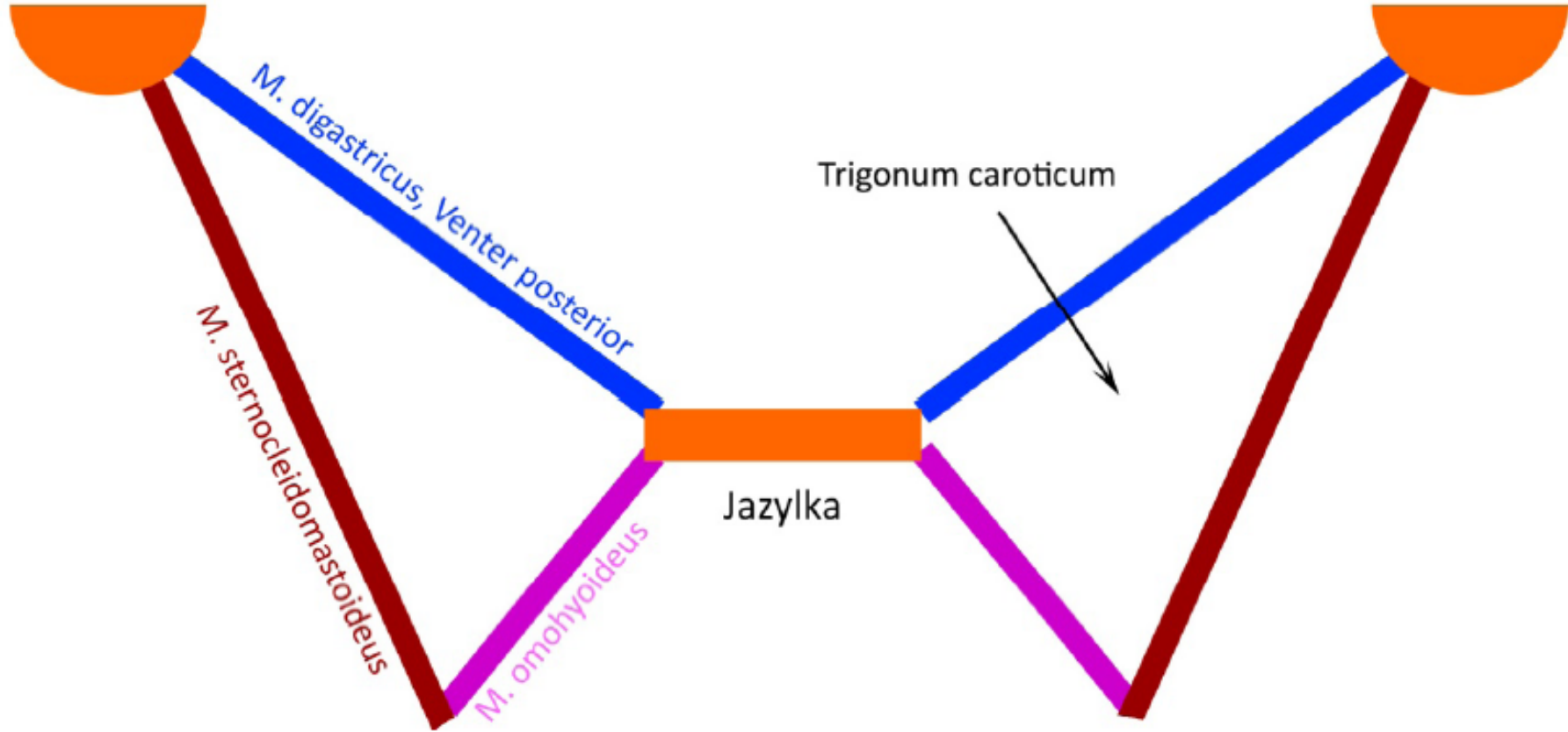
Arteria vertebralis

# Průběh nervů a cév v mezižebří



# Trigonum caroticum

processus mastoideus



# Trojúhelníky na krku

