

Recommended list of diagrams for the Anatomy final examination

Skeleton, joints, muscles

1. Pterygopalatine fossa – shape, walls
2. Course of facial canal in the pyramid – superior aspect
3. Floor of the internal acoustic meatus
4. Simple diagram of the ethmoidal bone
5. Osseous nasal septum (vomer, lamina perpendicularis ossis ethmoidalis)
6. Fasciae of the neck (horizontal section)
7. Sheath of rectus abdominis – transverse section above and below the umbilicus
8. Difference between the discus and meniscus – transverse section
9. Difference between the arthrodia and enarthrosis
10. Ligaments of the atlanto-axial joint – superior aspect
11. Synovial sheath at the longitudinal section
12. Palmar and dorsal interosseous muscles of the hand
13. Plantar and dorsal interosseous muscles of the foot
14. Muscular and vascular lacunae (lig. inguinale, arcus iliopectineus)

Digestive system

1. General structure of the tooth – longitudinal section
2. Gallbladder and bile ducts
3. Duodenum and pancreatic and bile ducts
4. Hepatoduodenal ligament – cross section through its structures
5. Supra- and infracolic peritoneal divisions, their blood supply
6. Peritoneal recesses at the ileocecal juncture
7. Cross section through the esophagus

Respiratory system

1. Pulmonary hilum, its structures on the right and left side, transition of the visceral pleura to the parietal one
2. Laryngoscopic picture of the laryngeal cavity

Urinary system

1. Nephron
2. Triangle of the urinary bladder

Male genital organs

1. Prostate – sagittal section
2. Testis – sagittal section
3. Coverings of the testis – derivatives of the abdominal wall
4. Deferent duct, seminal vesicles and ureter – posterior aspect
5. Male pelvic floor – inferior aspect

Female genital organs

1. Uterus – anteversion and anteflexion
2. Uterine tube and ovary (mesovary, mesosalpinx, broad lig. of the uterus) – sagittal section
3. Uterus and vagina, uterine cervix – sagittal section

4. Ligaments of the uterus
5. Female pelvic floor – inferior aspect

Cardiovascular apparatus

1. Skeleton of the heart, valves
2. Shape and structure of the semilunar valves
3. Cross section through the ventricles, papillary muscles
4. Blood supply of the ventricles – cross section with depicted papillary muscles
5. Aorta – portions
6. Aortic arch – branches, basic variability
7. Serous pericardium (Porta arteriarum et venarum, transverse and oblique sinuses)
8. Superficial and deep arterial palmar arches
9. Branches of the celiac trunk
10. Portal vein - origin

Lymphatic system

1. Section through the lymph node
2. Main lymph trunks
3. Lymph drainage of the female breast – lymph nodes

PNS

1. Basic linkage of PNS and CNS neurons (sensor, afferent axon, interneurons in the CNS, motoneuron, effector)
2. Spinal nerve, spinal roots
3. Pseudounipolar neuron, afferent axon
4. Cross section of the peripheral nerve – connective tissue sheaths
5. Brachial plexus – trunks, cords
6. All cranial nerves, types of fibers, source nuclei
7. Superficial and deep cervical ansae
8. Greater, lesser and the least splanchnic nerves – their origins from the symp. trunk

CNS

1. Zones of the grey matter
2. Circulus arteriosus Willisi
3. Veins of the brain, venous sinuses
4. Sinus sagittalis sup. – transverse section
5. Fossa rhomboidea
6. Capsula interna and its pathways – transverse section, position of grey matter nuclei
7. Crus cerebri – pathways
8. Autonomic ganglion
9. Difference between preganglionic and postganglionic symp. and parasymp. neurons (length of axons)
10. Frontal section of the cavernous sinus with passing cranial nerves
11. Nuclei of the thalamus, division into the main functional groups
12. Hypothalamo-hypophyseal portal system
13. Tr. hypothalamo-hypophysialis
14. Hypophysis – divisions
15. Basal ganglia, capsula interna, externa, extrema – cross section
16. Basic groups of the hypothalamic nuclei – rostro-dorsal and frontal section
17. Horizontal and vertical division of the cerebellum

18. Lateral ventricles, frontal section through the frontal horn and central part, interventricular foramen
19. Frontal section through the temporal horn of the lateral ventricle

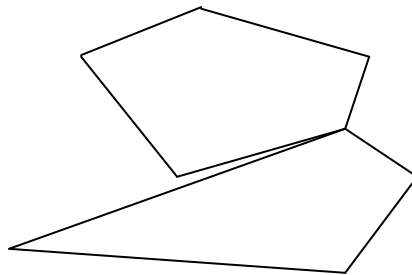
Senses

1. Cross section through the parts of the ear in the latero-medial direction
2. External surface of the tympanic membrane
3. Tympanic cavity – walls, structures
4. Osseous cochlea
5. Cochlear duct – cross section
6. Orientation of the saccular and utricular maculae
7. Pharyngotympanic (auditory) tube, shape of its cartilaginous part
8. Anterior and posterior chambers of the eyeball
9. Structure of the skin
10. Structure of the hair

Topographical anatomy

1. Temporal fossa – frontal section, attachment of the temporal fascia
2. Trigonum suboccipitale
3. Fasciae of the neck
4. Triangles of the neck
5. Beclard's angle
6. Pirogow's tringle
7. Trigonum caroticum
8. Trigonum submandibulare
9. Quadrangular and triangular openings (Foramen humero- et omotricipitale]
10. Intercostal nerve and vessels
11. Mediastinum – division (sagittal section)
12. Canalis inguinalis
13. Peritoneal folds of the anterior abdominal wall – posterior aspect
14. Trigonum lumbale Petiti
15. Trigonum Grynfelti, tetragon Krausei
16. Ischioanal fossa (fossa ischiorectalis, m. levator ani – frontal section)
17. Trigonum femorale
18. Canalis adductorius
19. Fossa poplitea including its floor
20. Fissura scalenorum – subclavian artery, trunks of the brachial plexus

Osseous nasal septum (vomer, lamina perpendicularis ossis ethmoidalis)

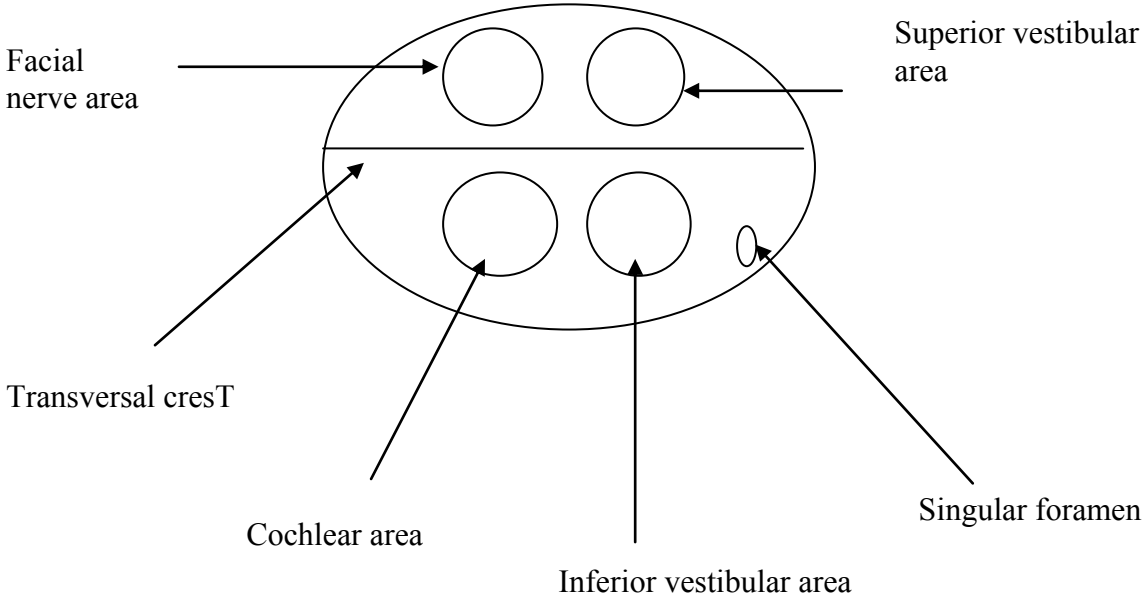


Kostěná nosní přepážka (lamina perpendicularis ossis ethmoidalis a vomer)

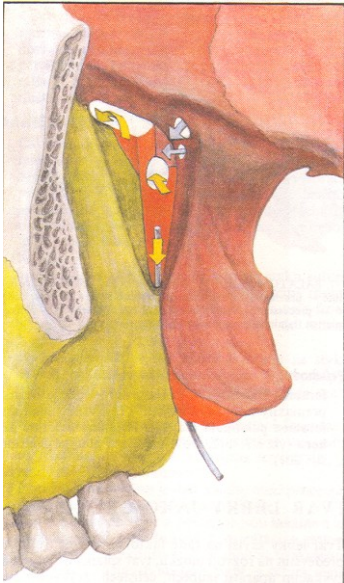
The bottom of internal acoustic meatus:

Medial side

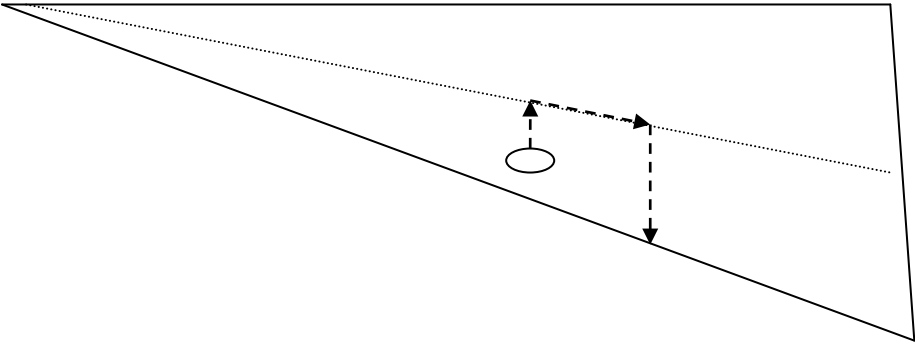
Lateral side



Pterygopalatine fossa – shape, walls



Course of facial canal in the pyramid – superior aspect



Simple diagram of the ethmoidal bone

