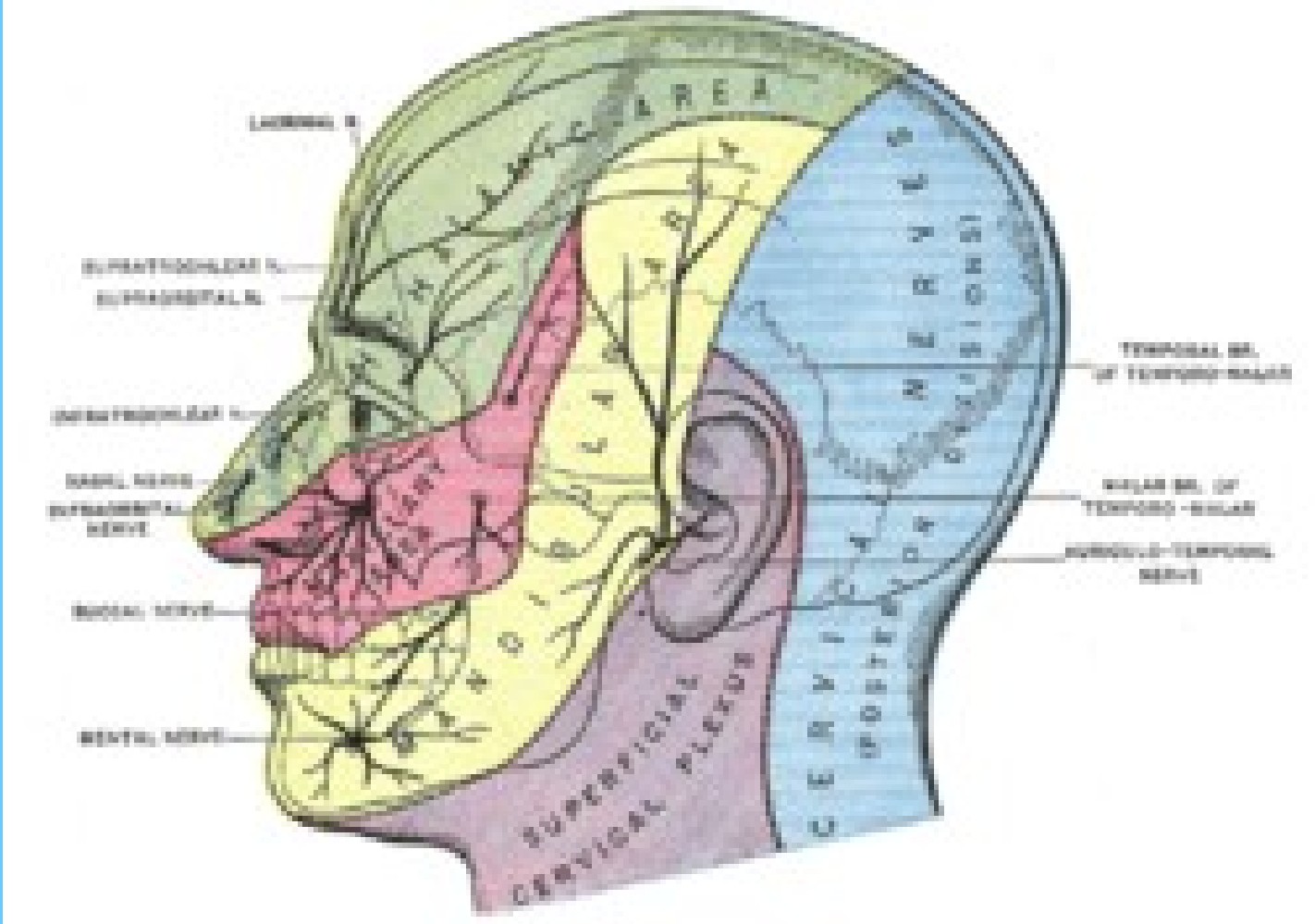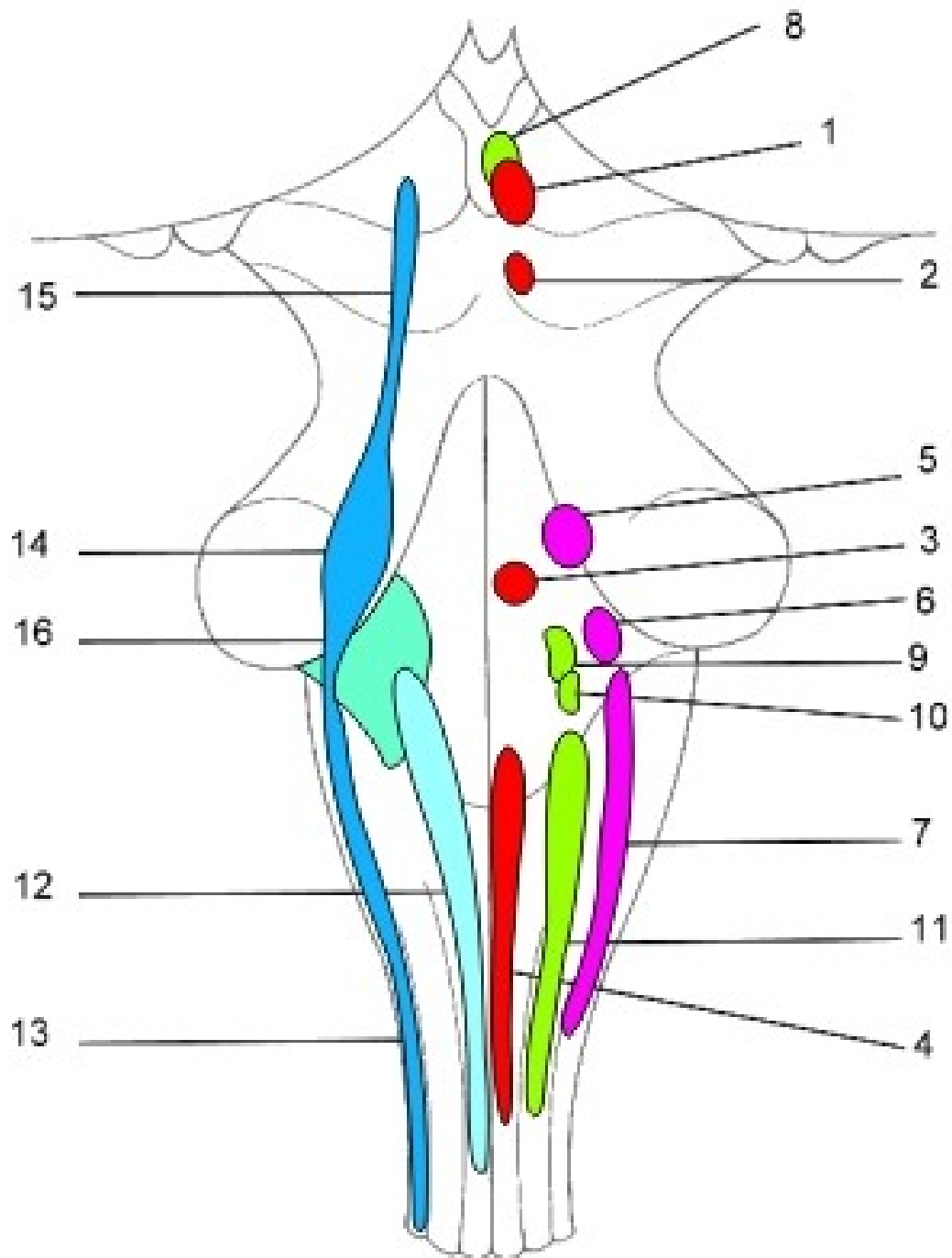
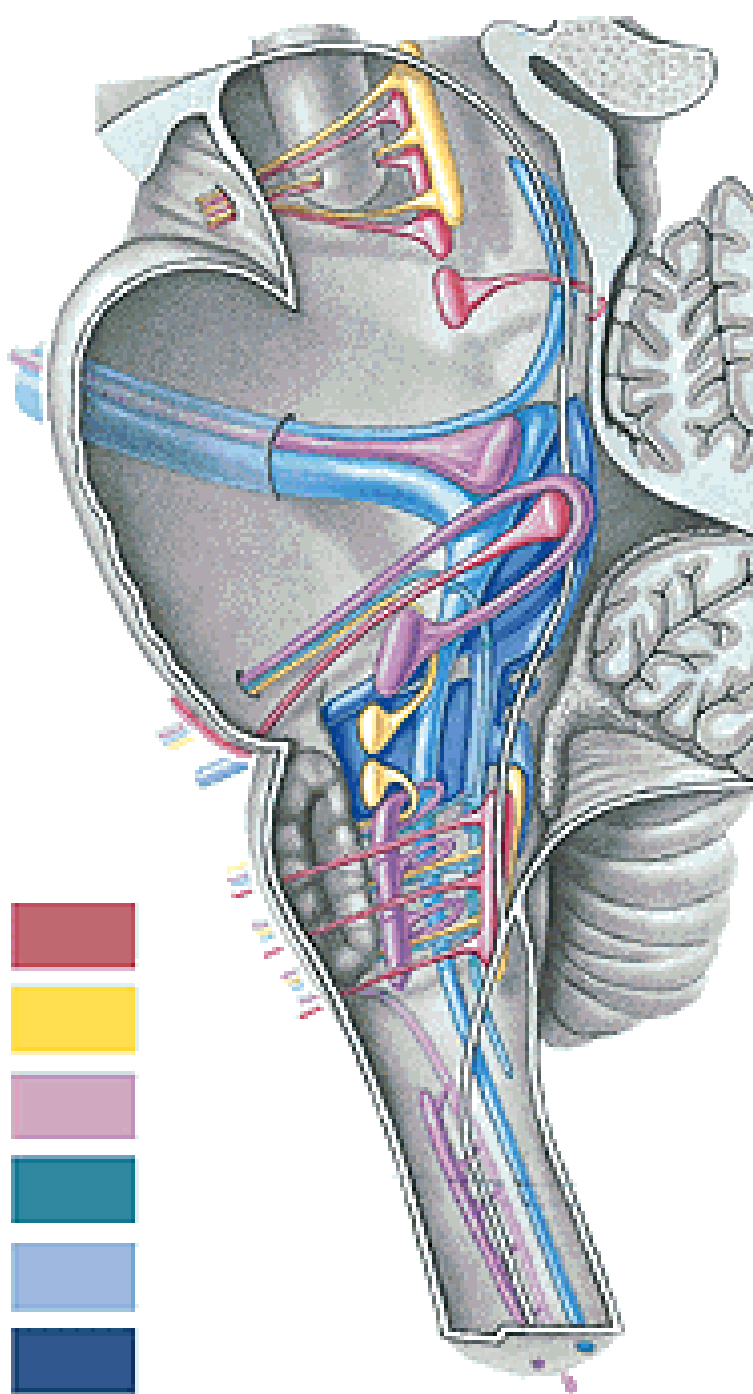


# NERVUS FACIALIS

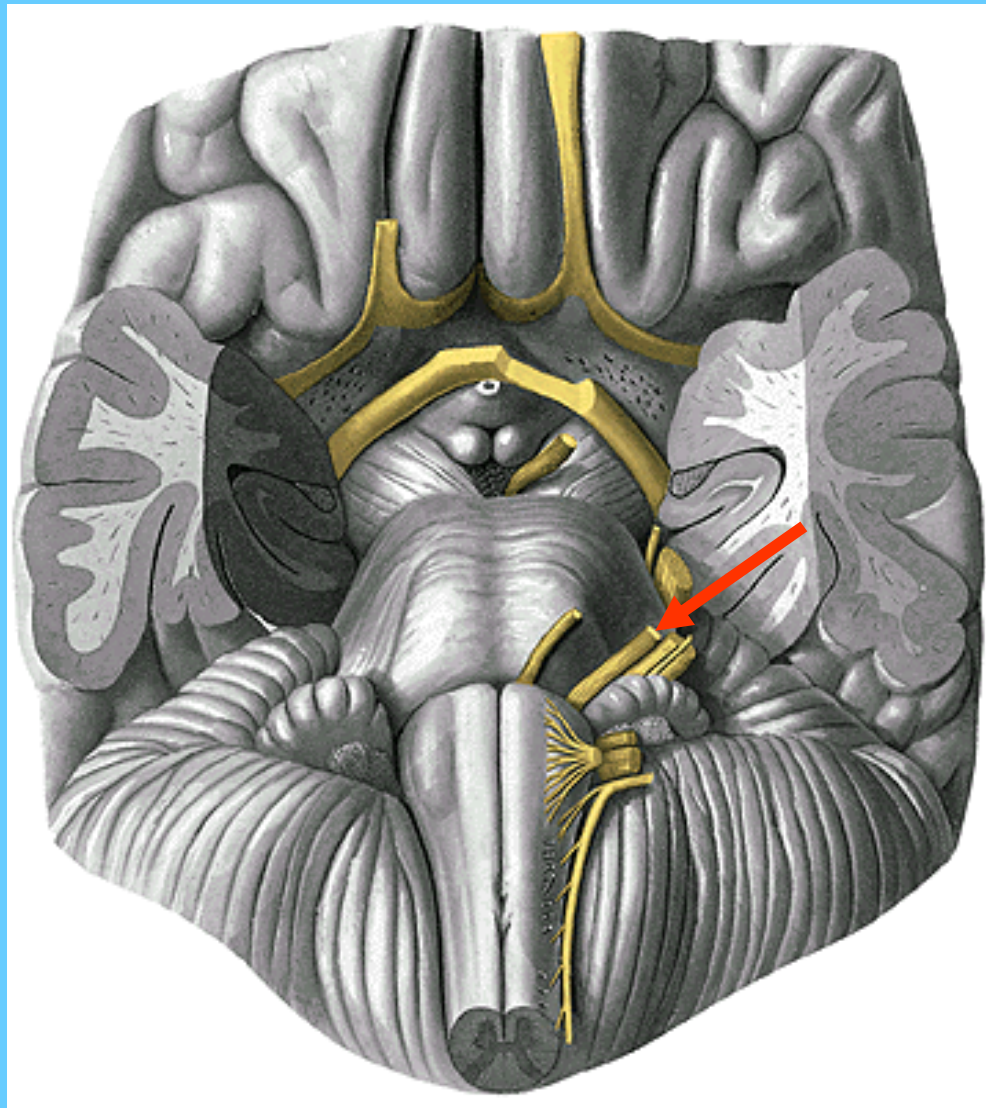
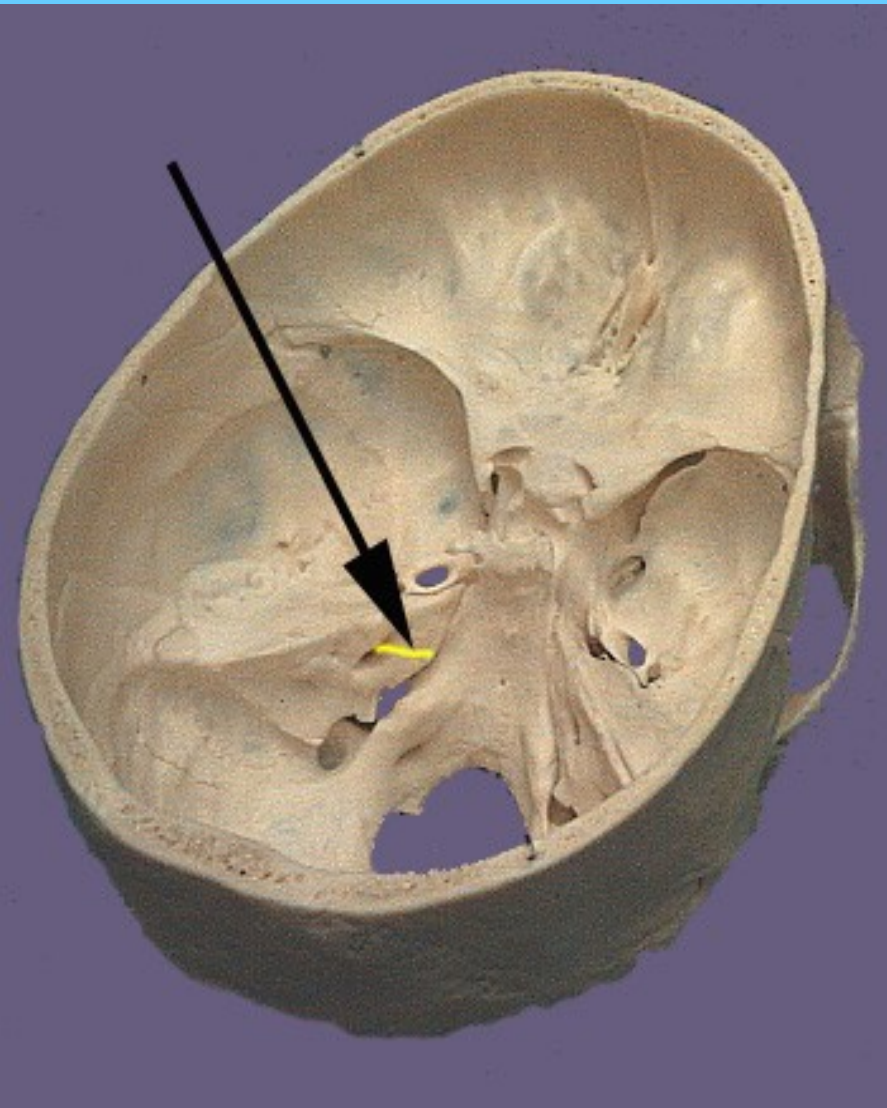
# CN VII



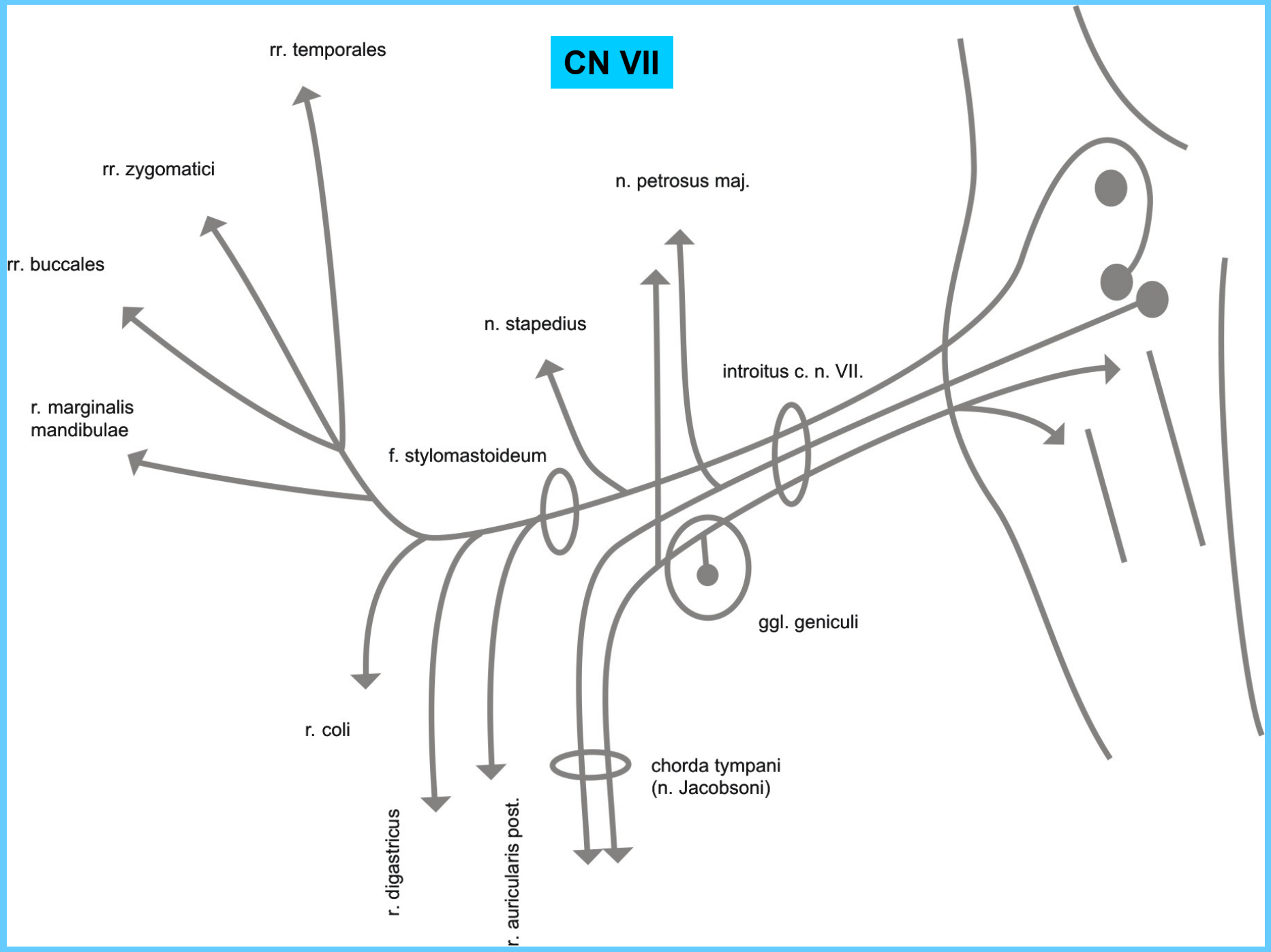
# CN VII

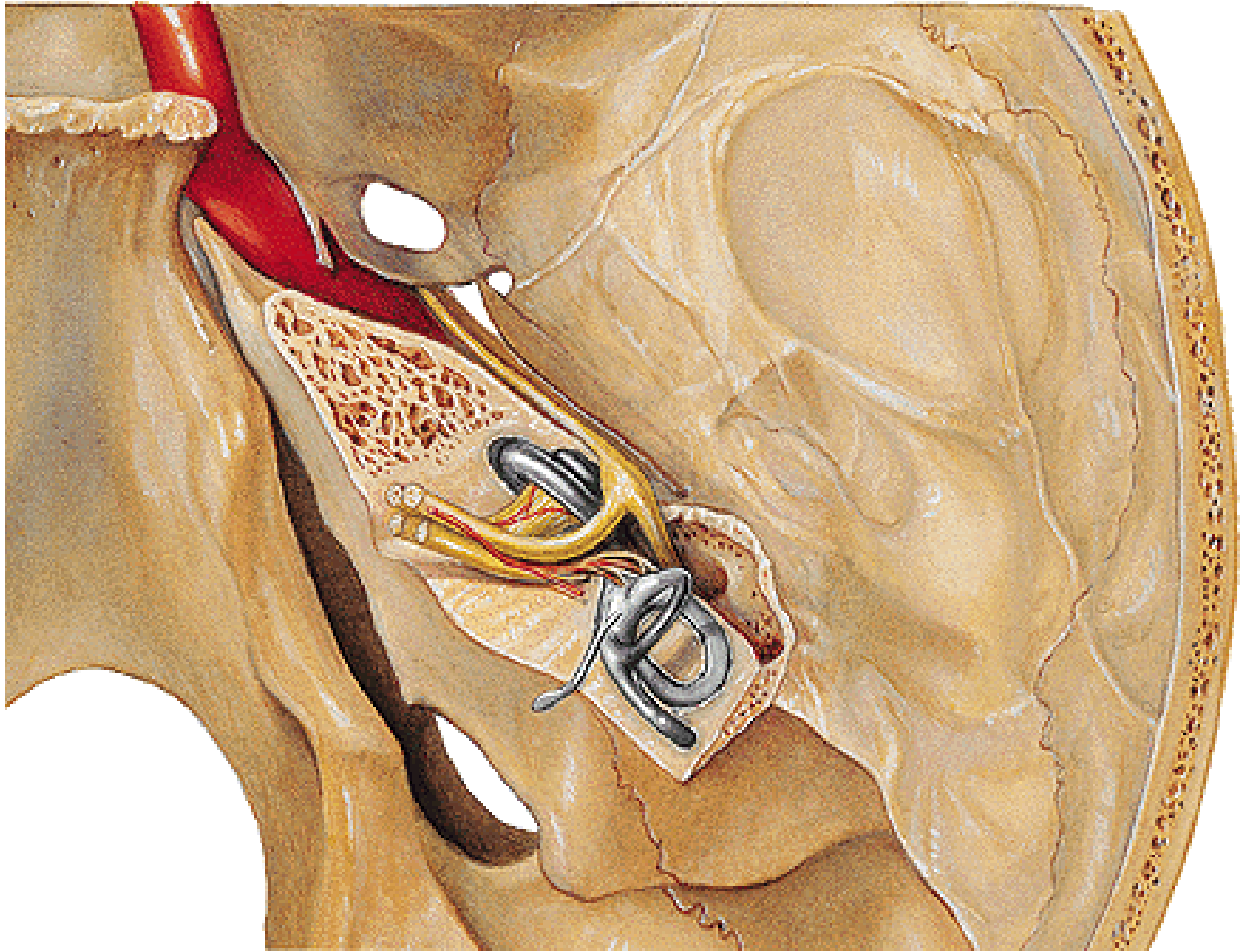


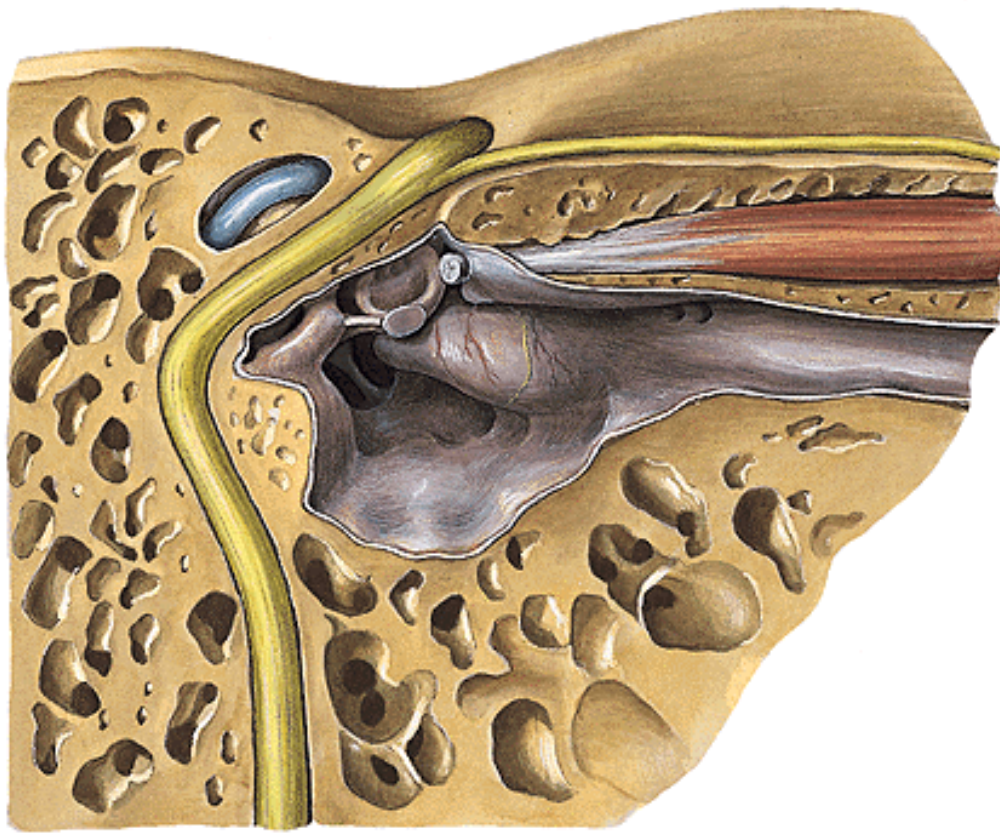
# CN VII



# CN VII



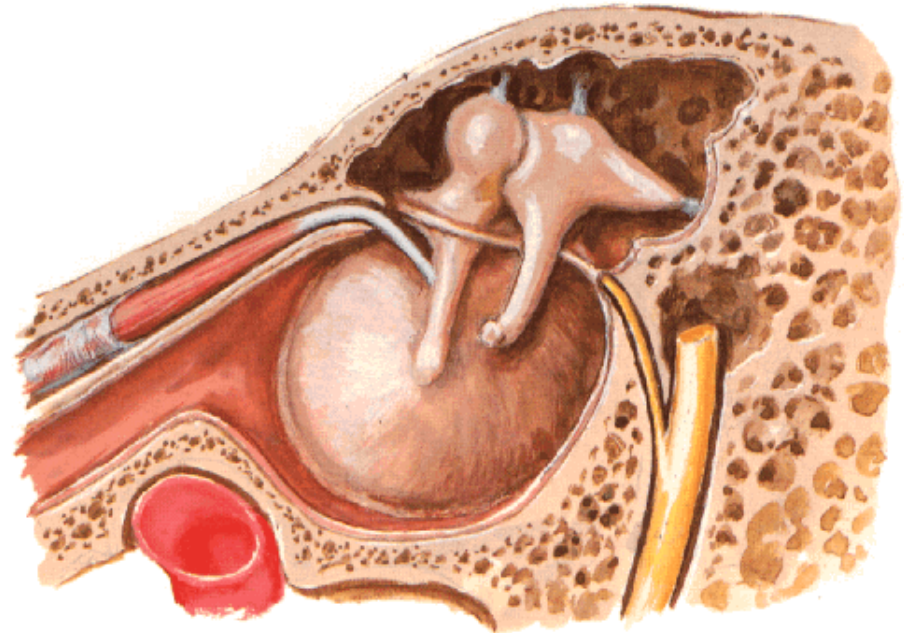




**Chorda tympani**

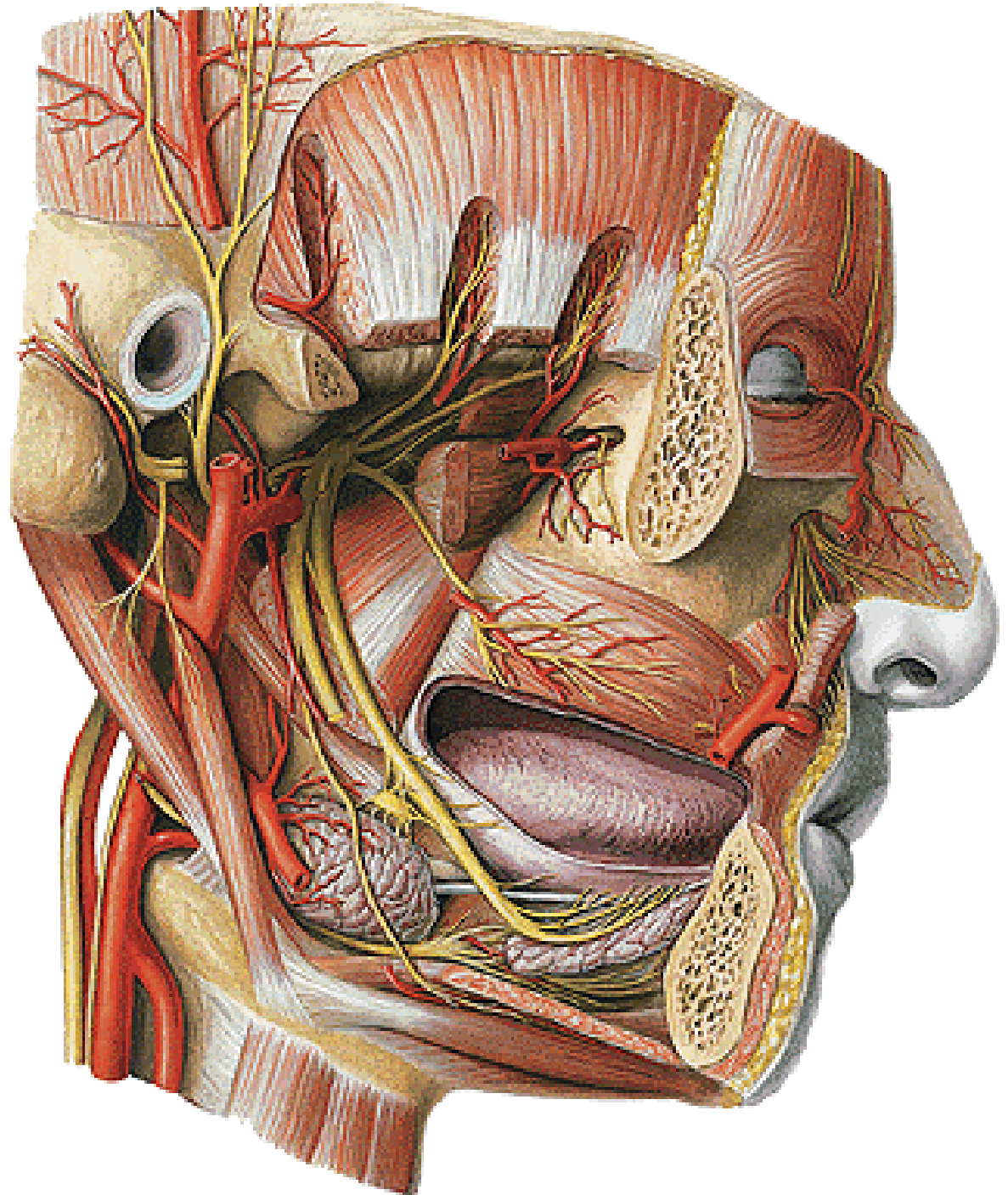
**Tympanic Cavity - Lateral Wall**  
Medial View

**N. petrosus major**

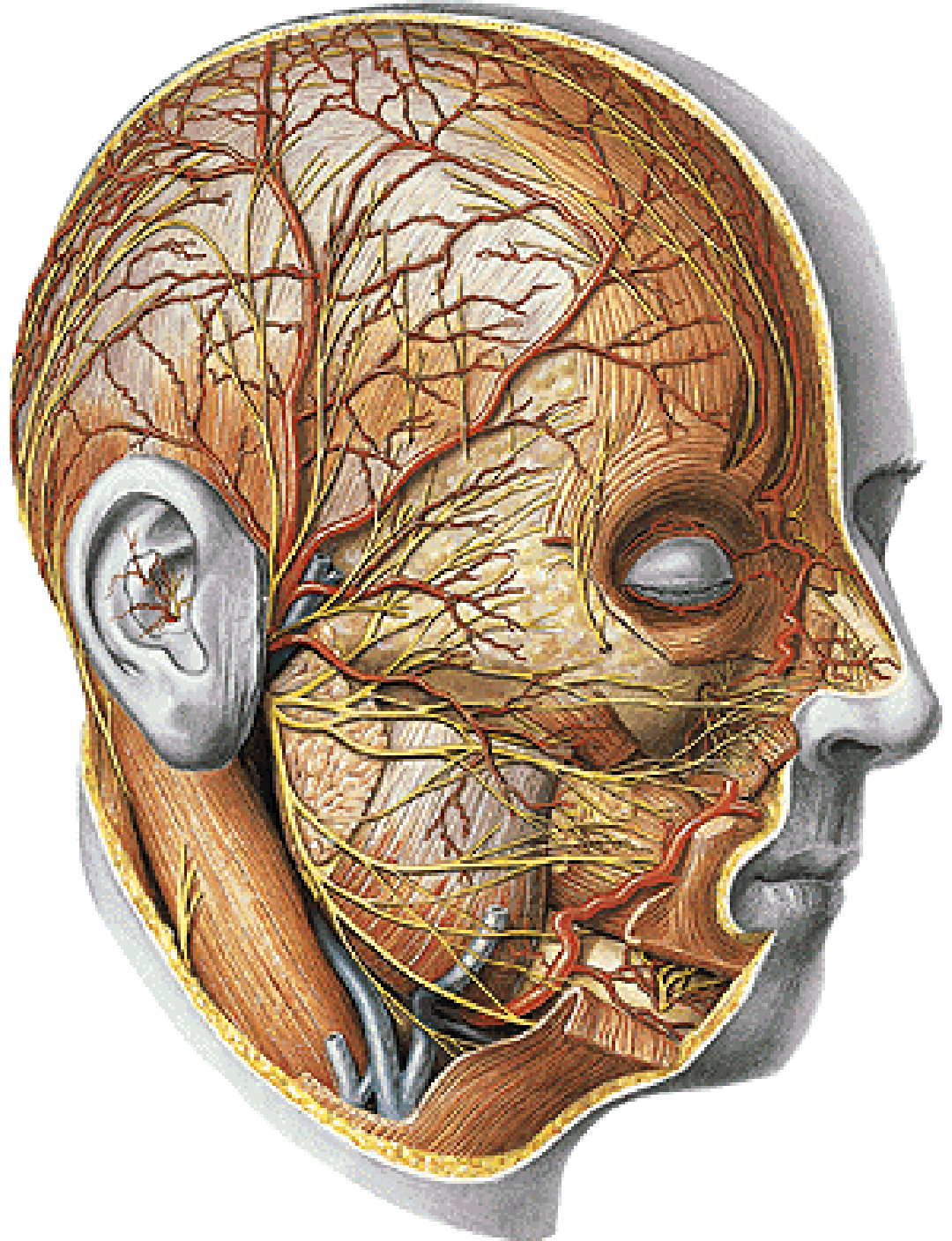




**N. auricularis post.**  
**Rr. musculares**

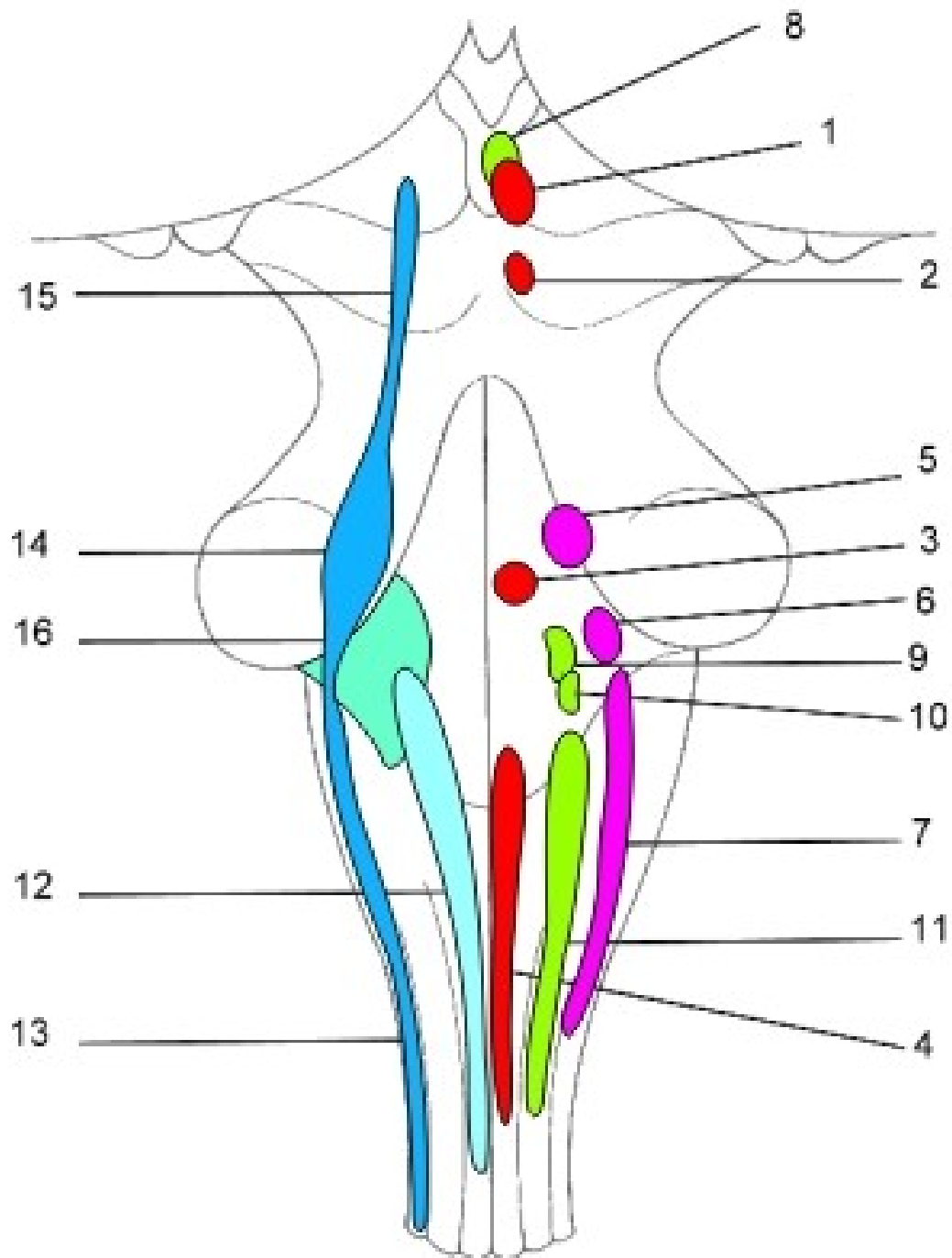


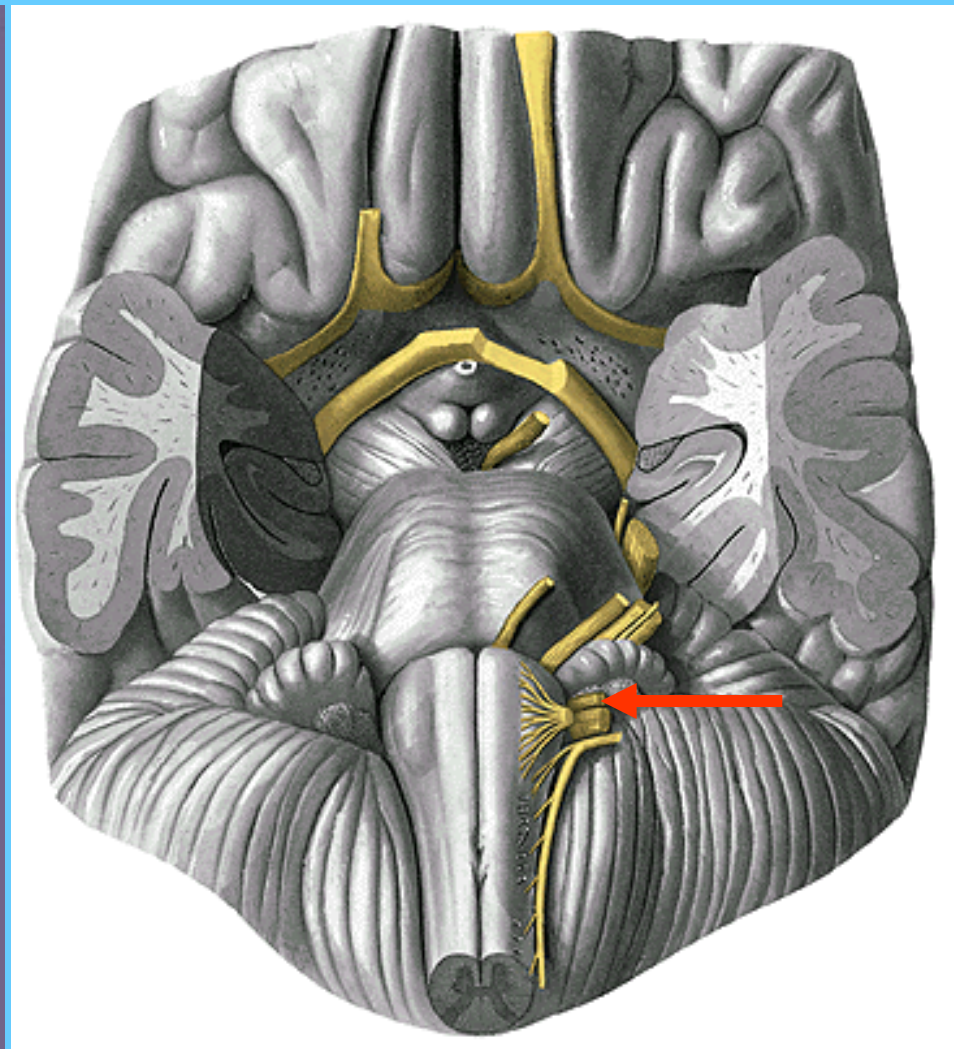
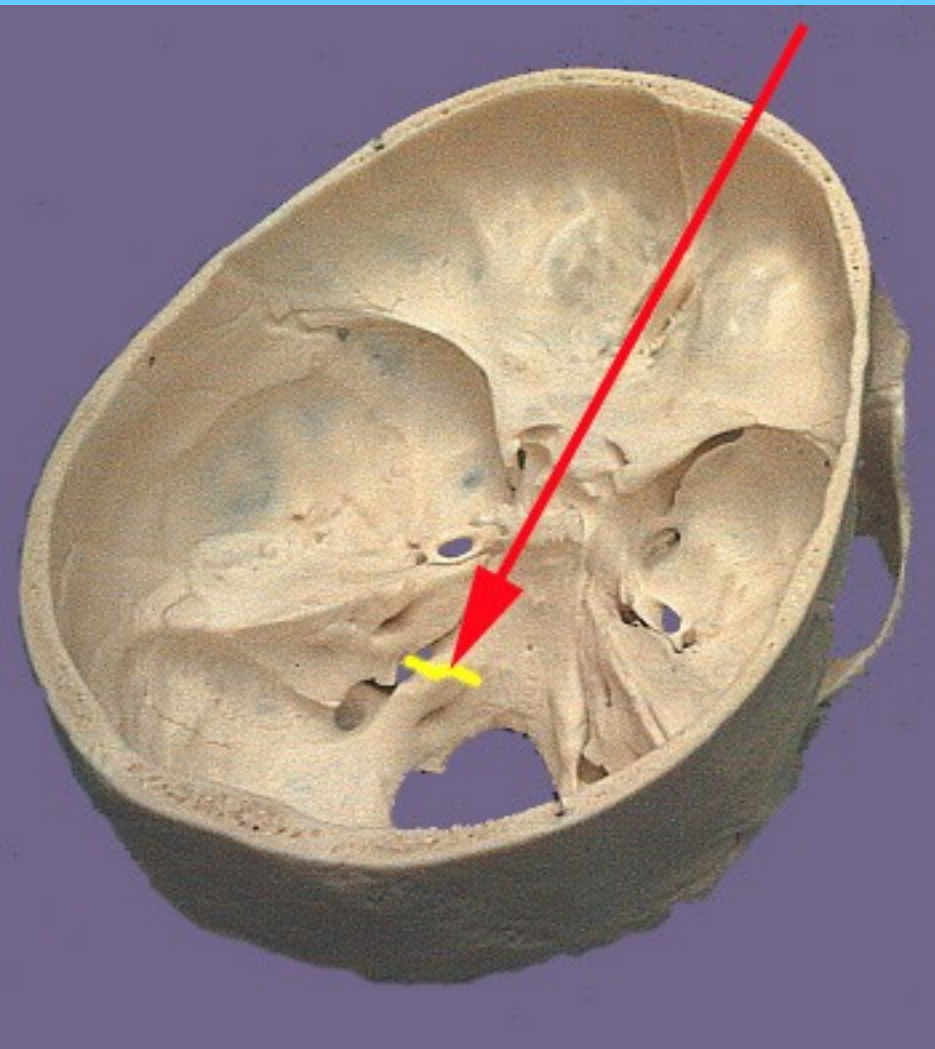
- Plexus parotideus  
(pes anserinus major)**
- rr. temporales
  - rr. zygomatici
  - rr. bucales
  - r. marginalis mandibulae
  - r. colli



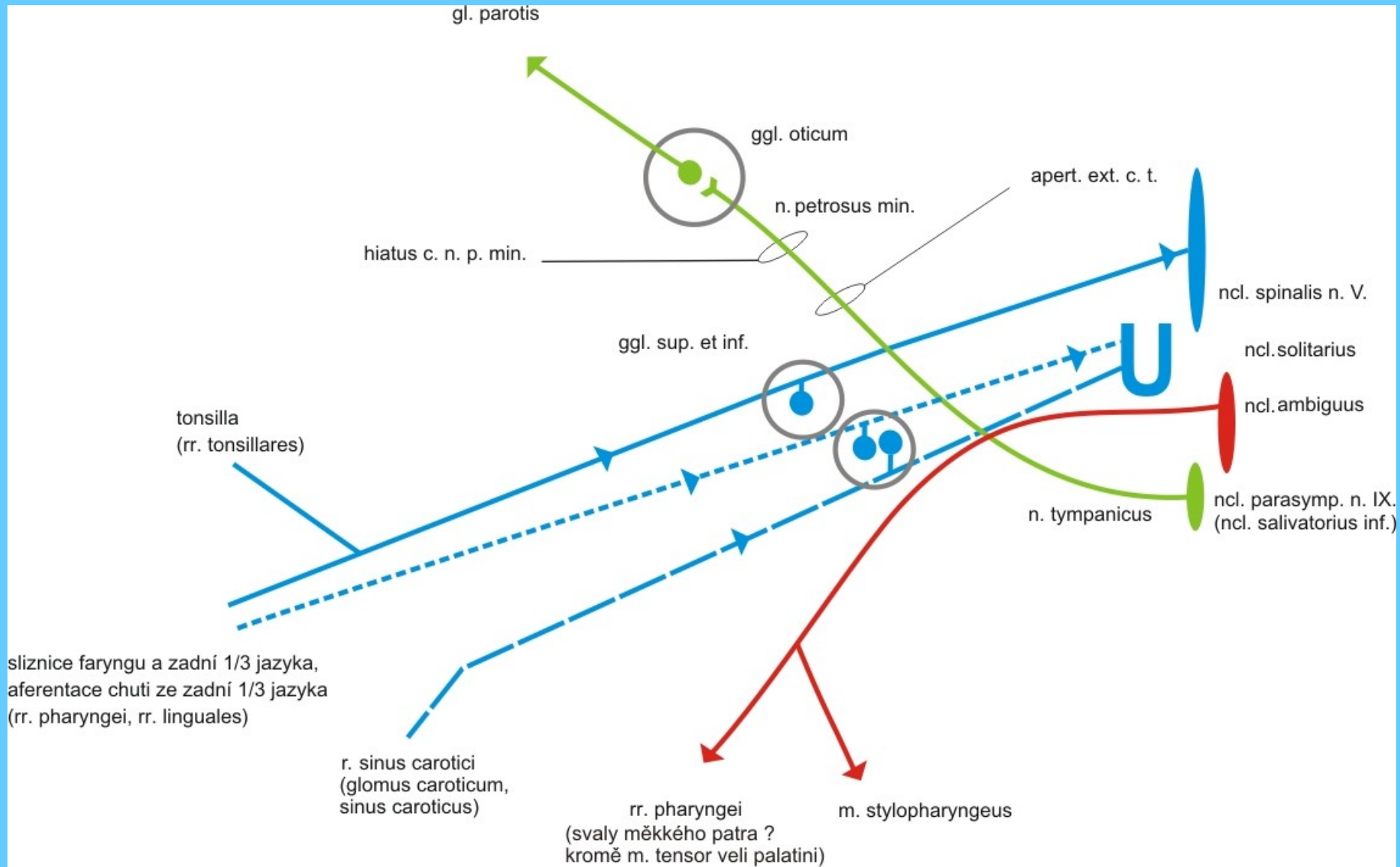
# NERVUS GLOSSOPHARYNGEUS

# CN IX



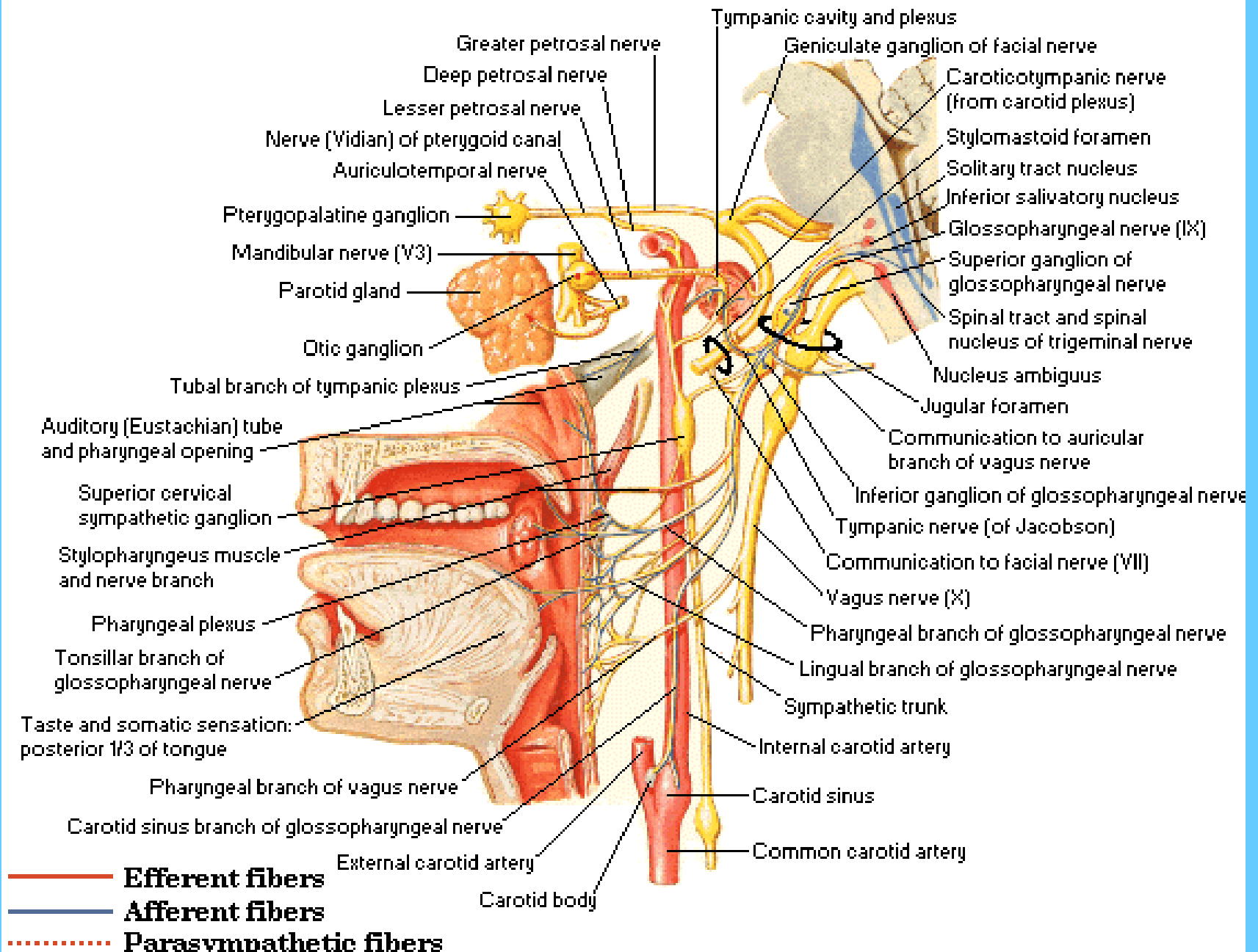


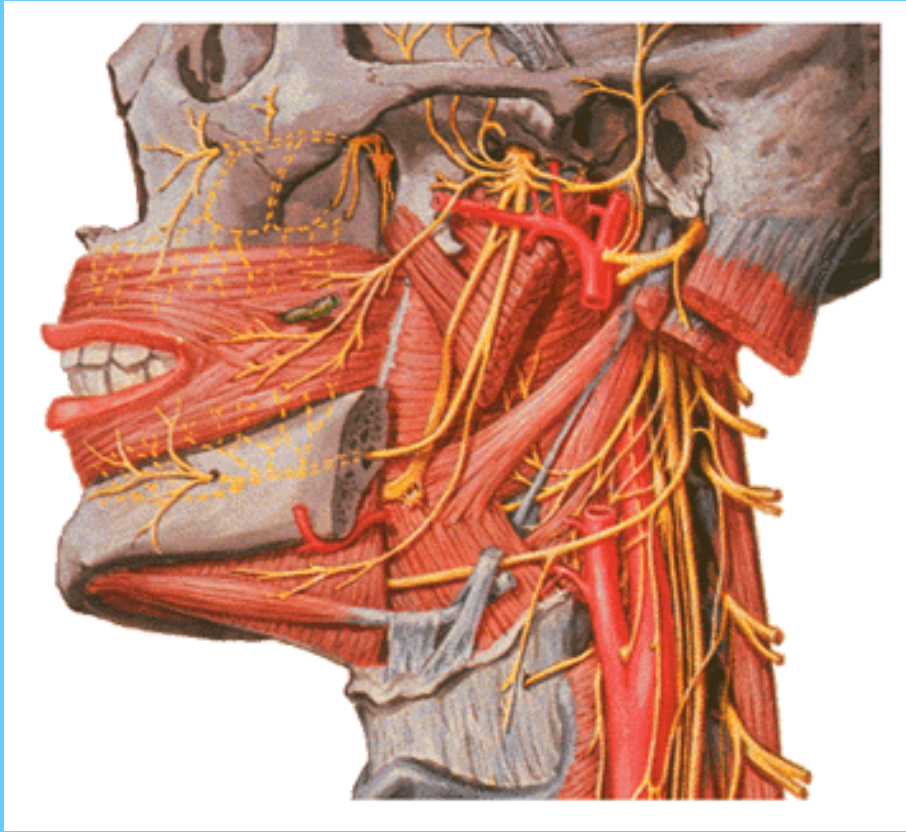
# CN IX



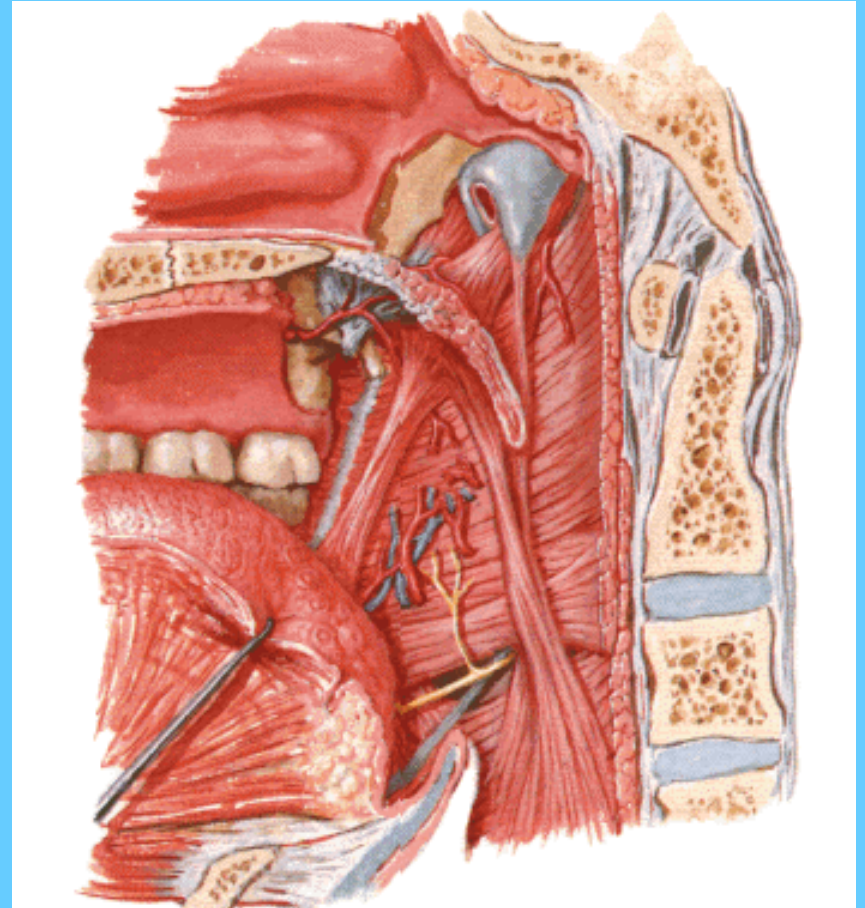
# Glossopharyngeal Nerve

## Schema





**Rr. tonsillares**  
**Rr. linguales**

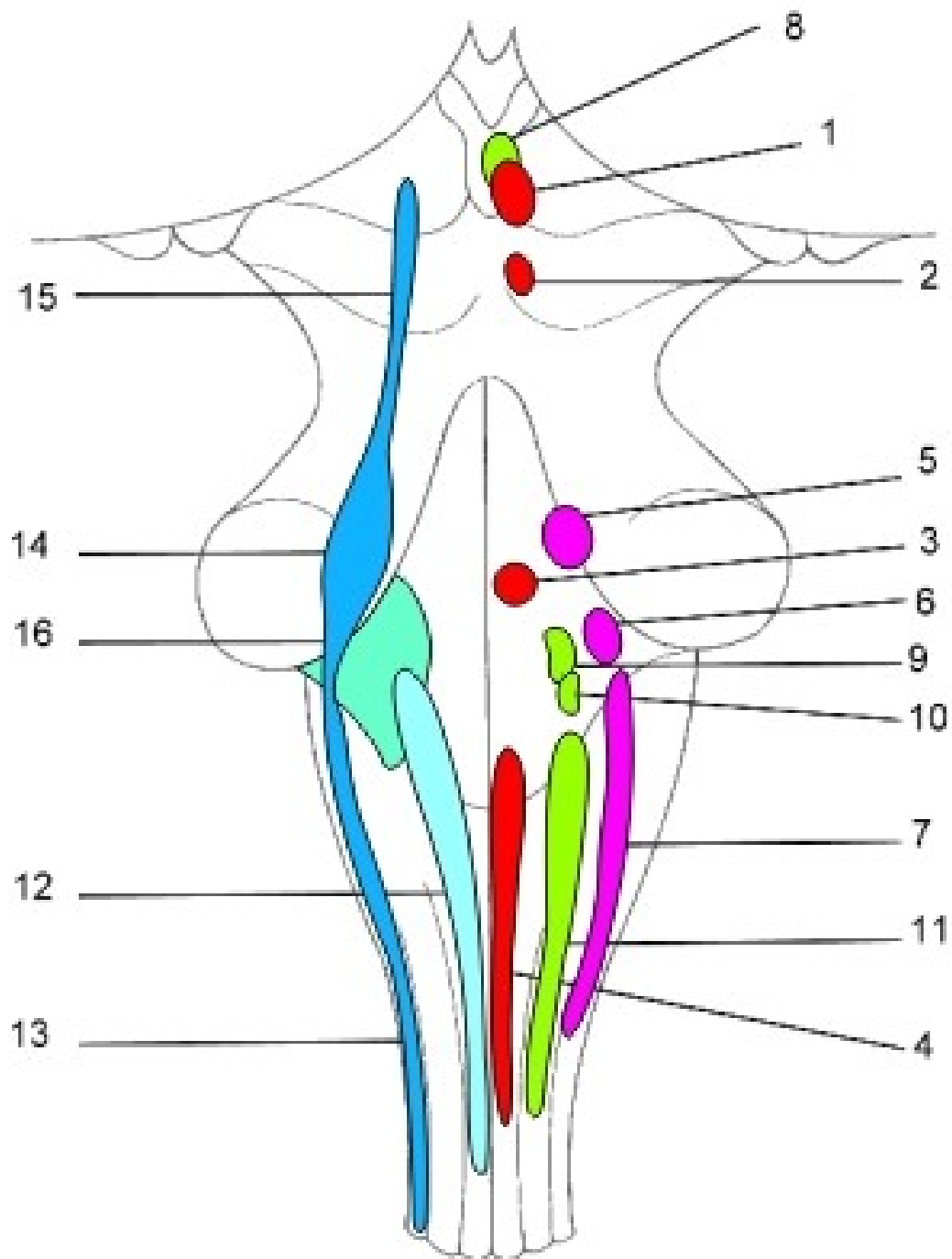


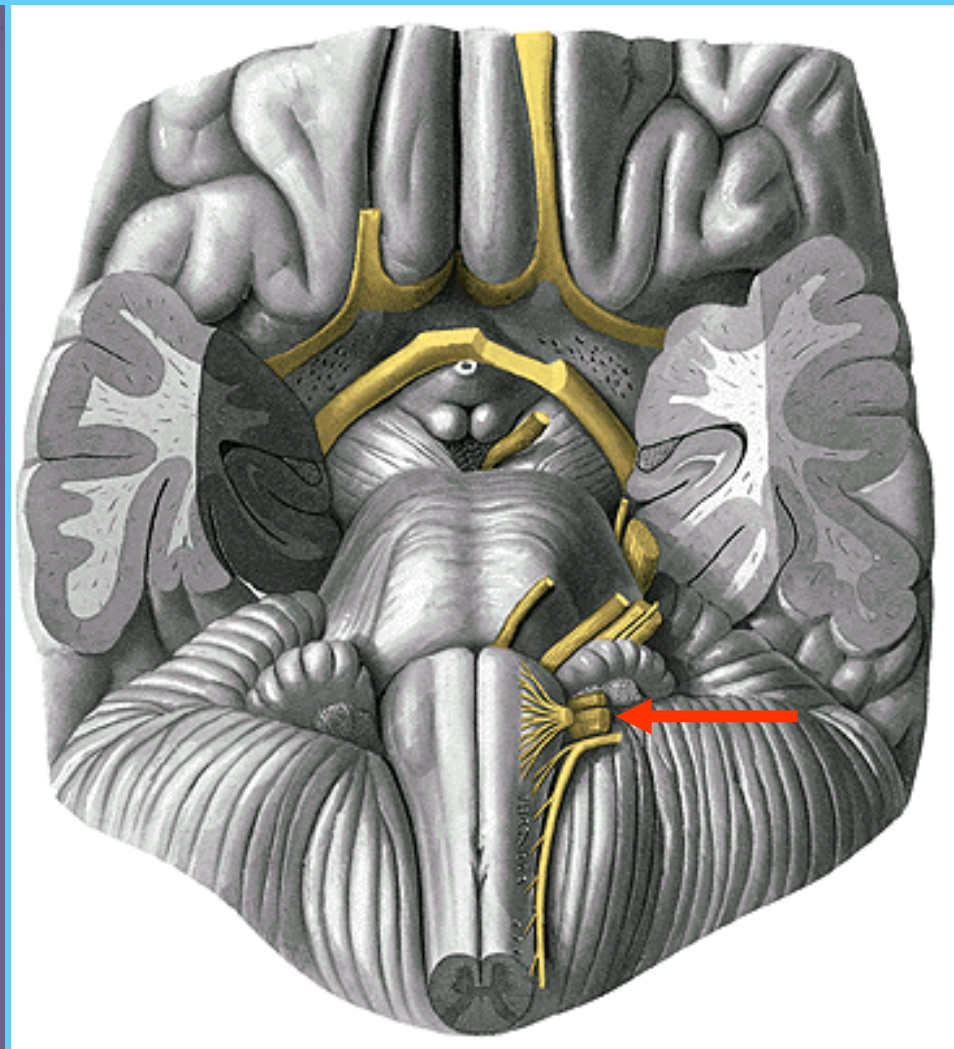
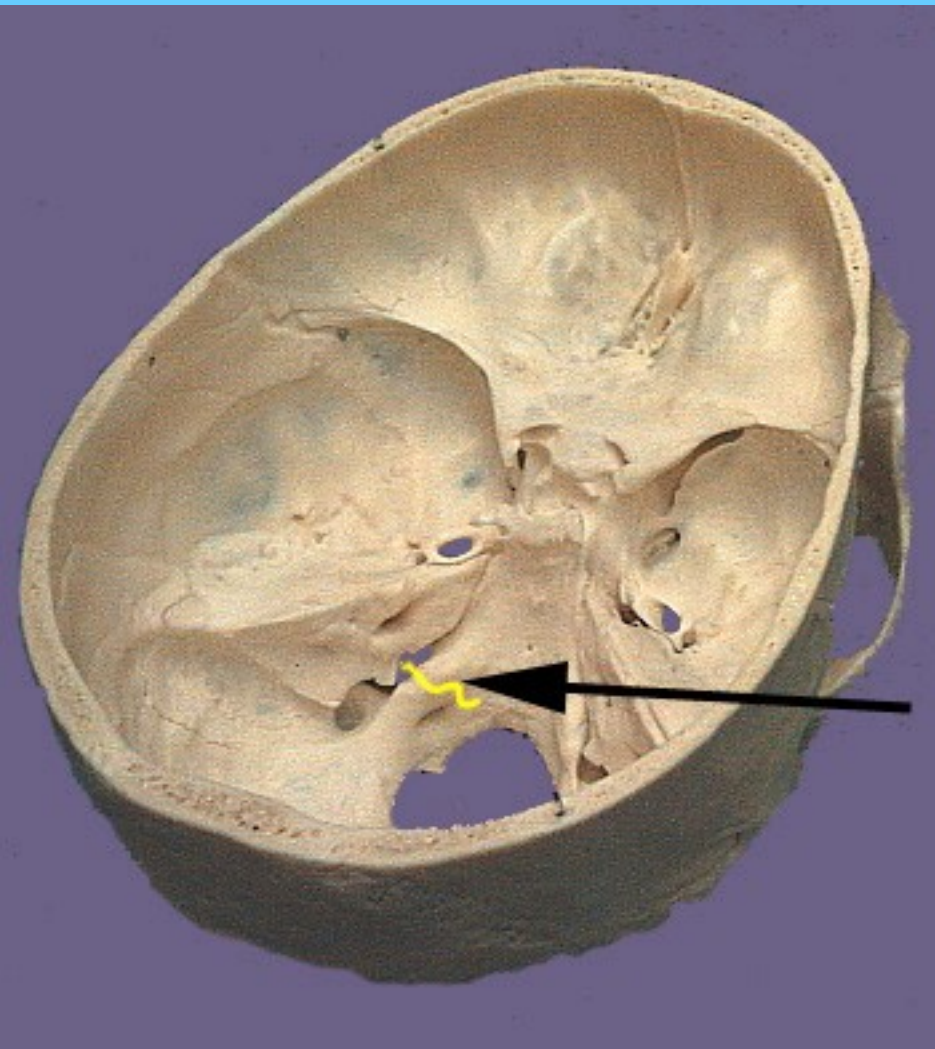
**Rr. pharyngei**  
**R. stylopharyngeus**



# NERVUS VAGUS

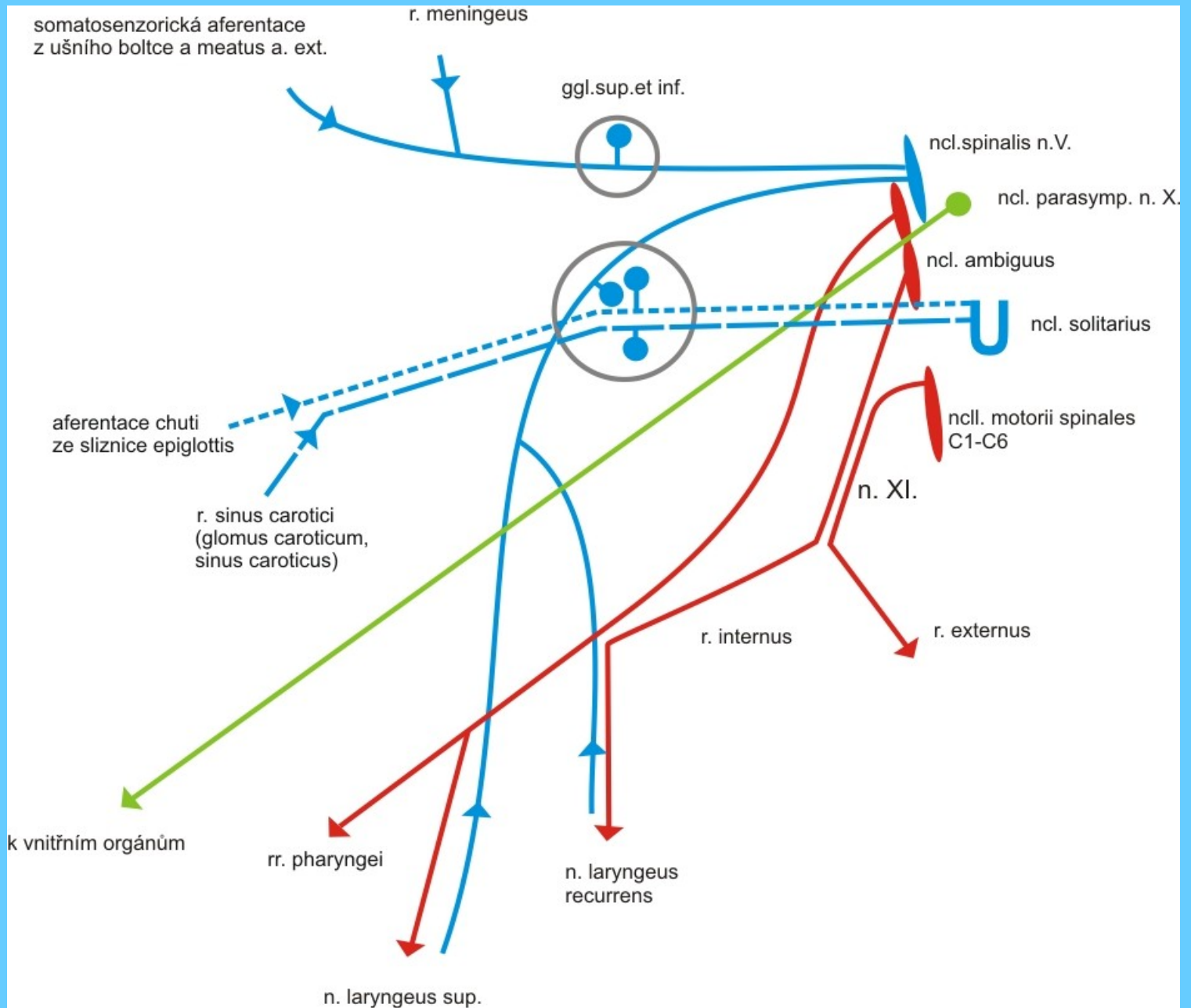
# CN X

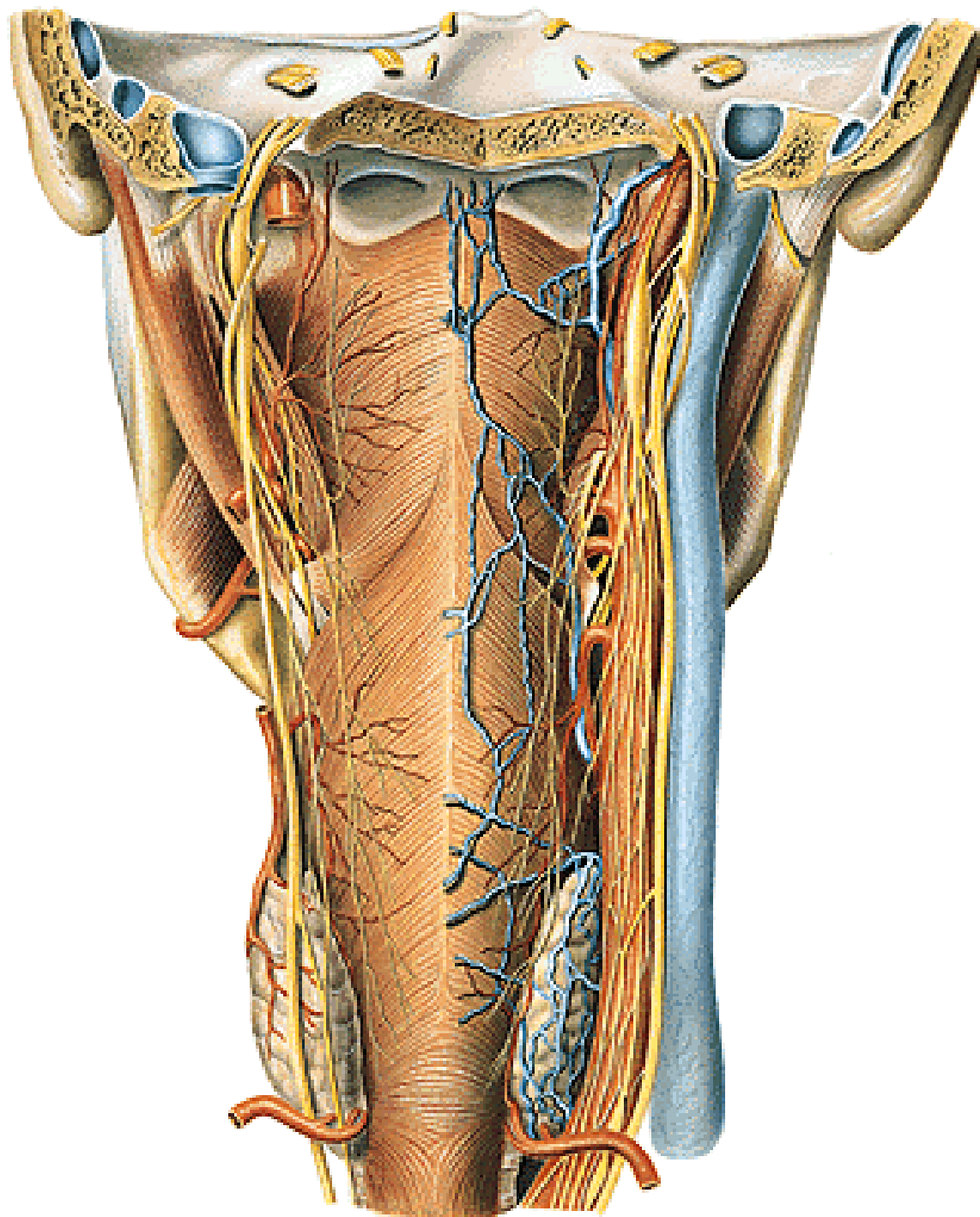


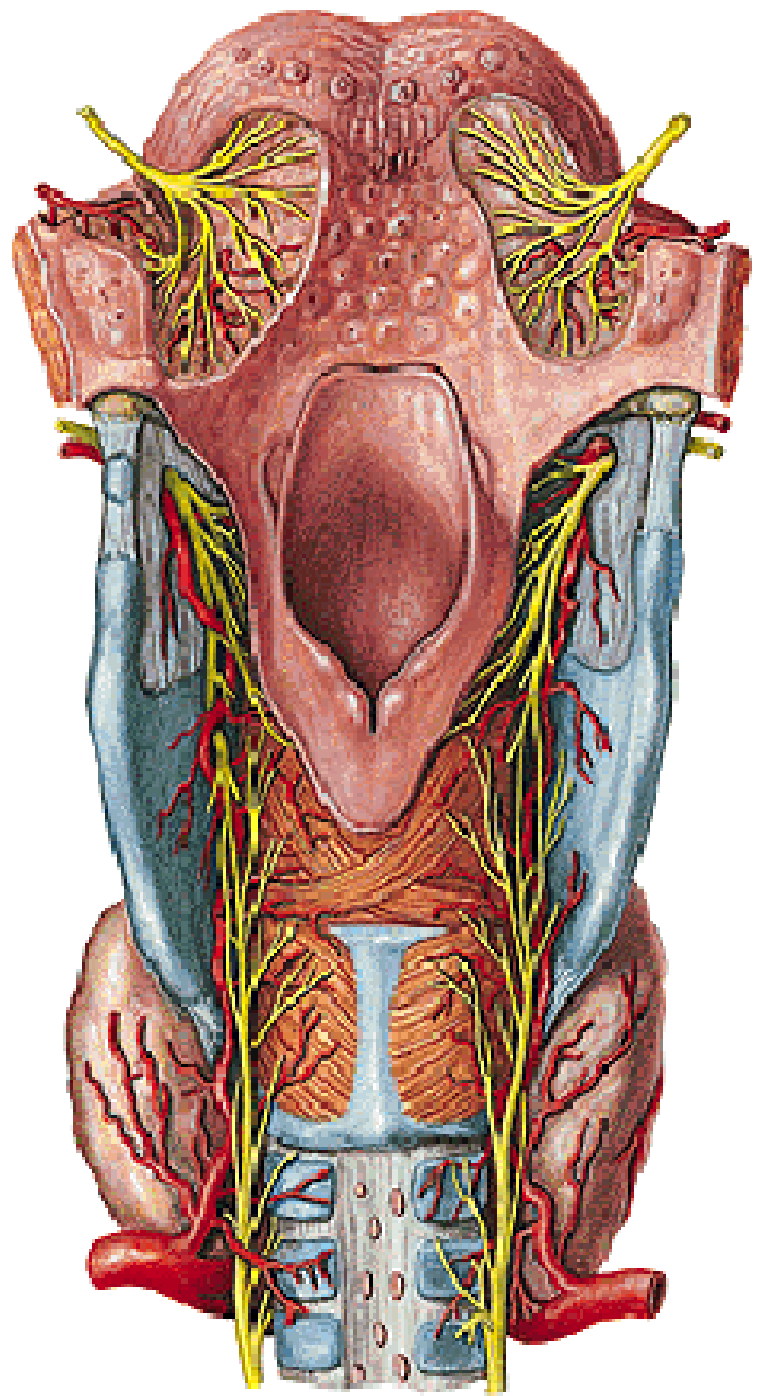
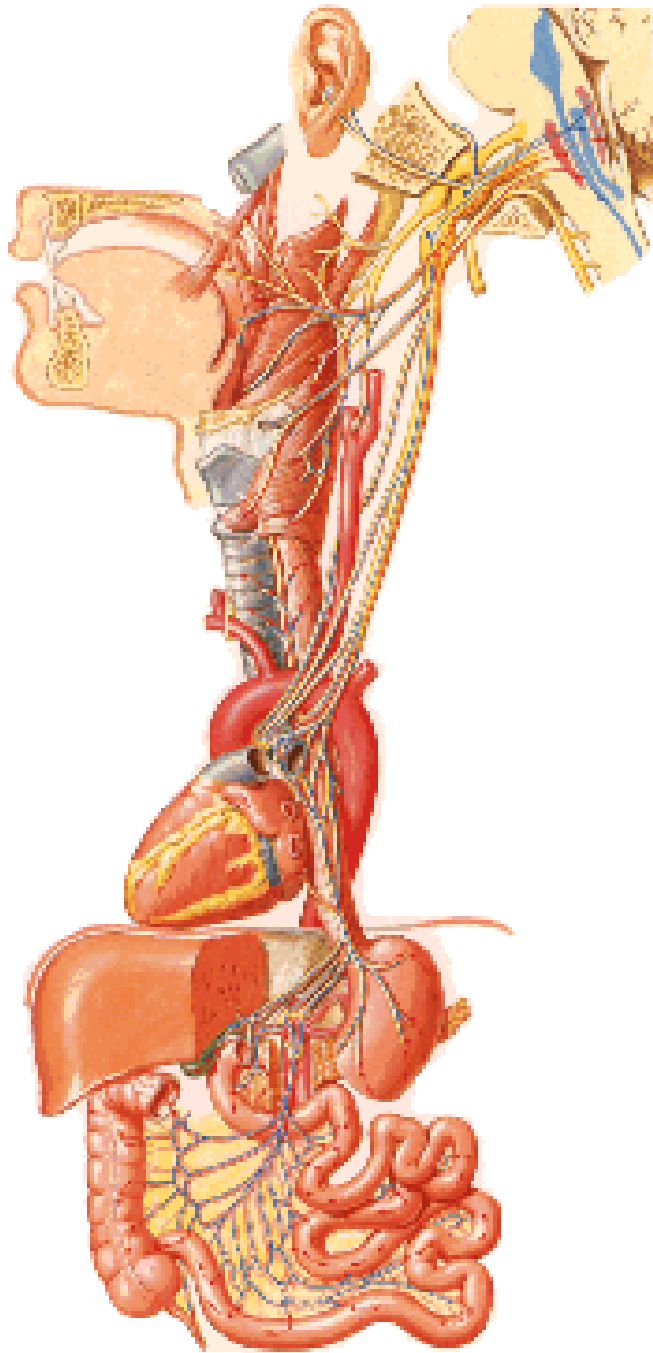


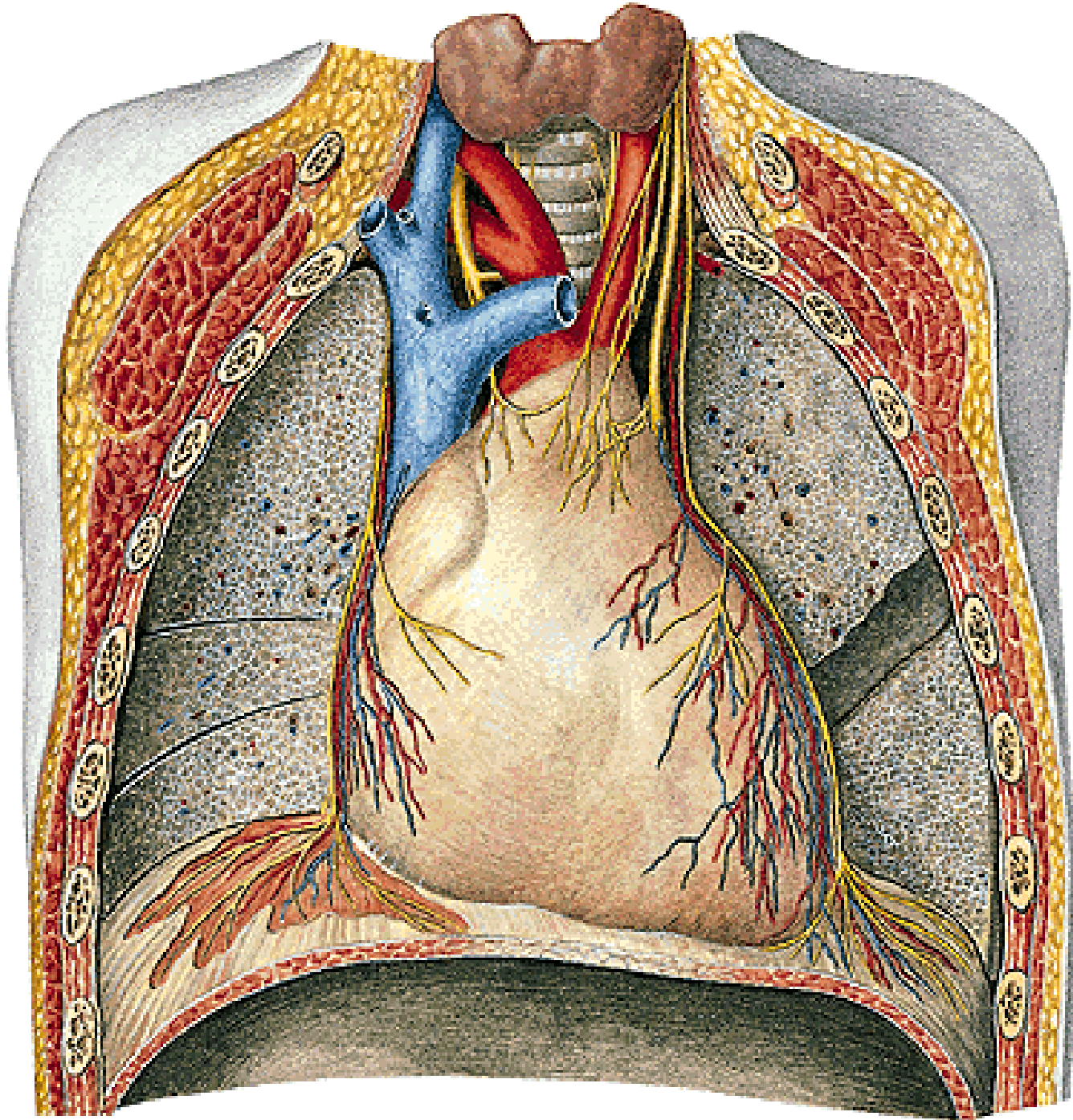
CN X

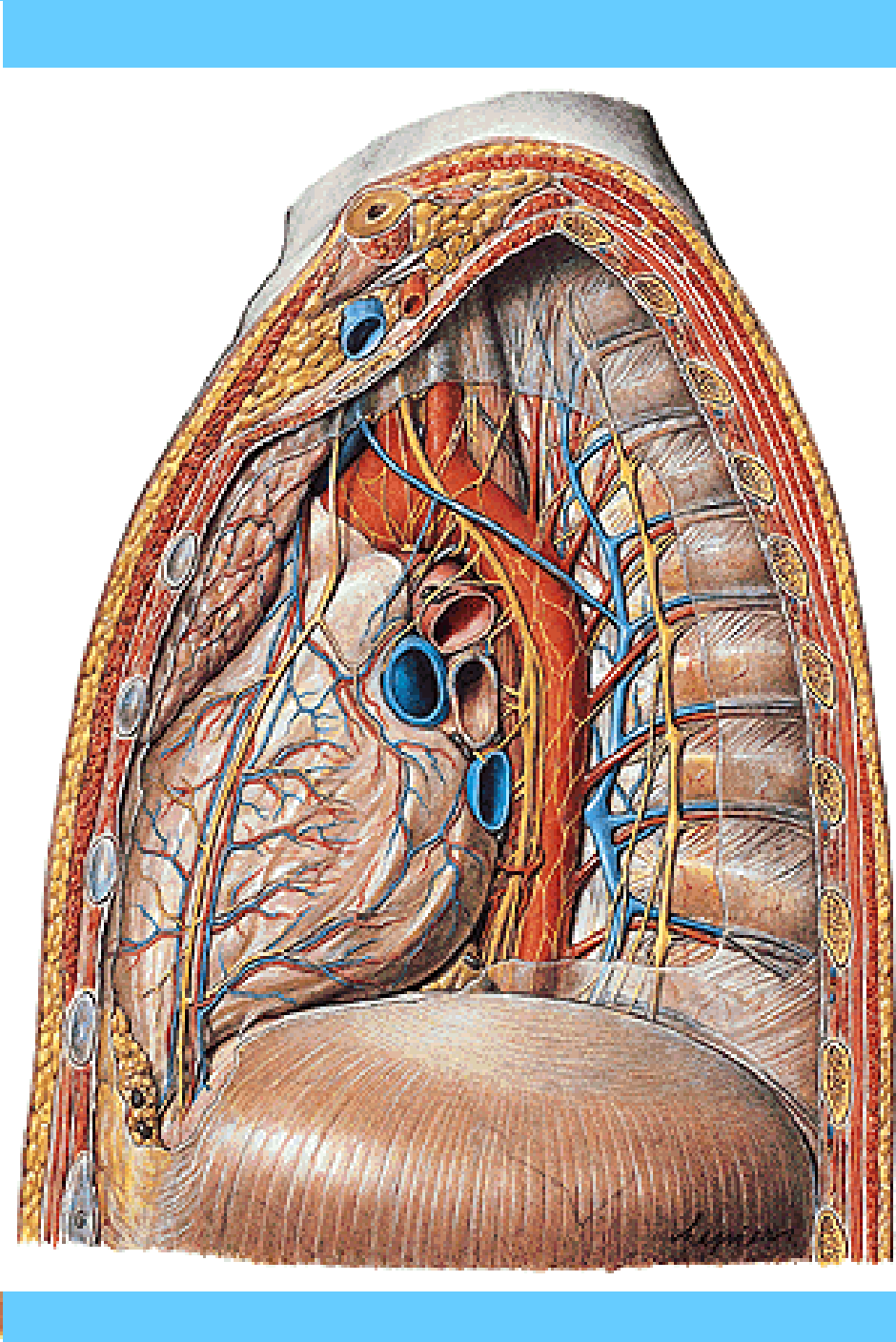
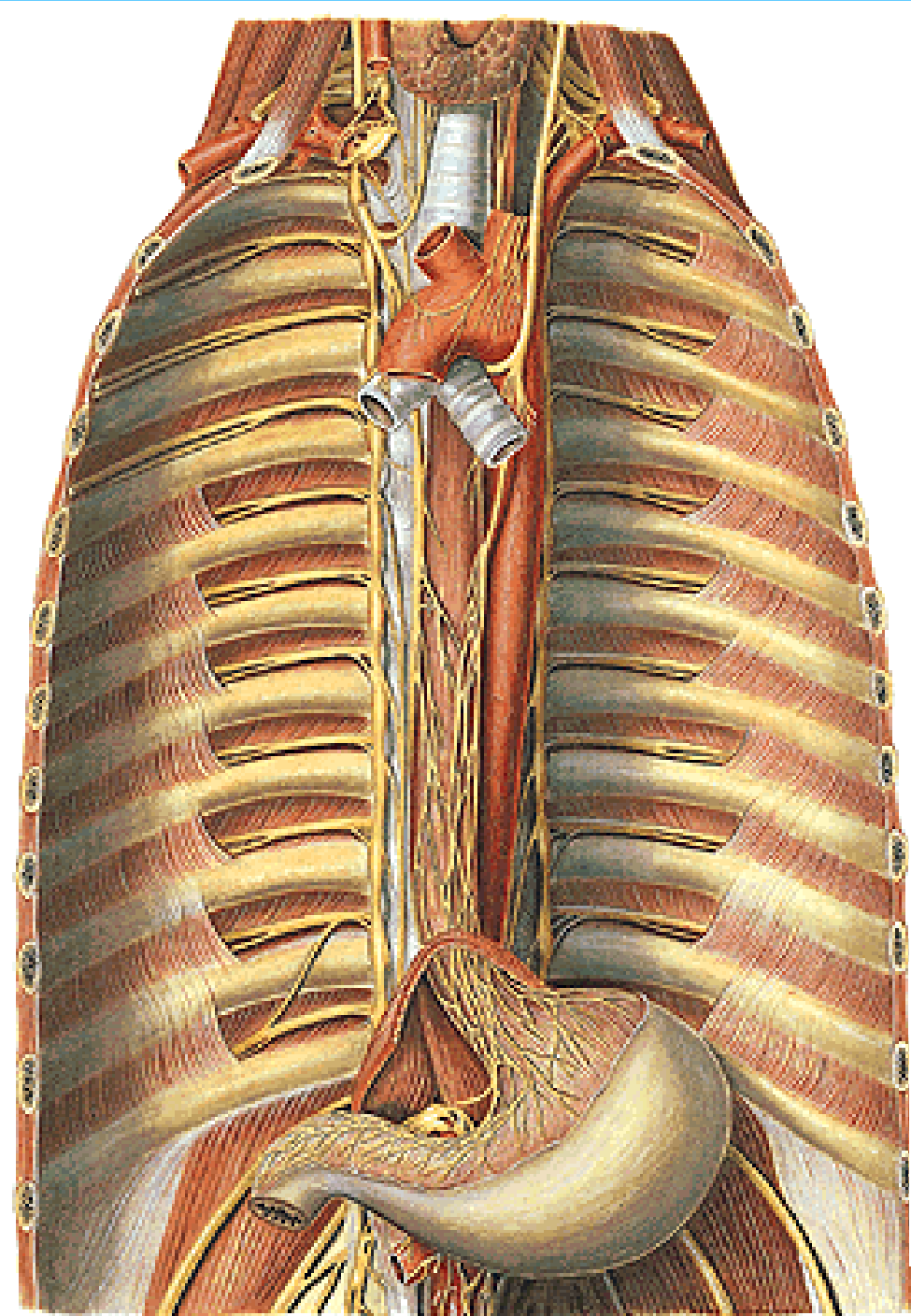
# CN X







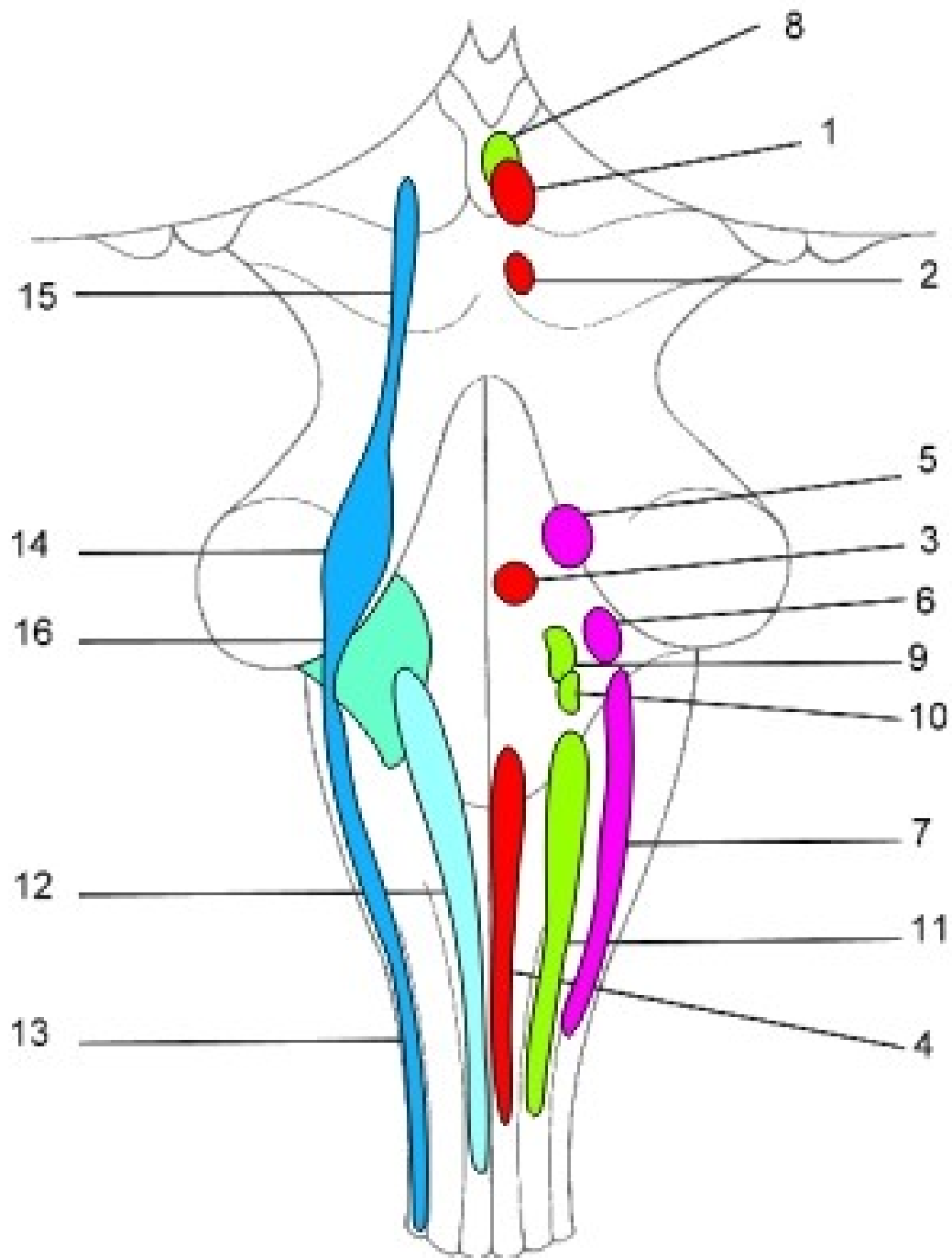




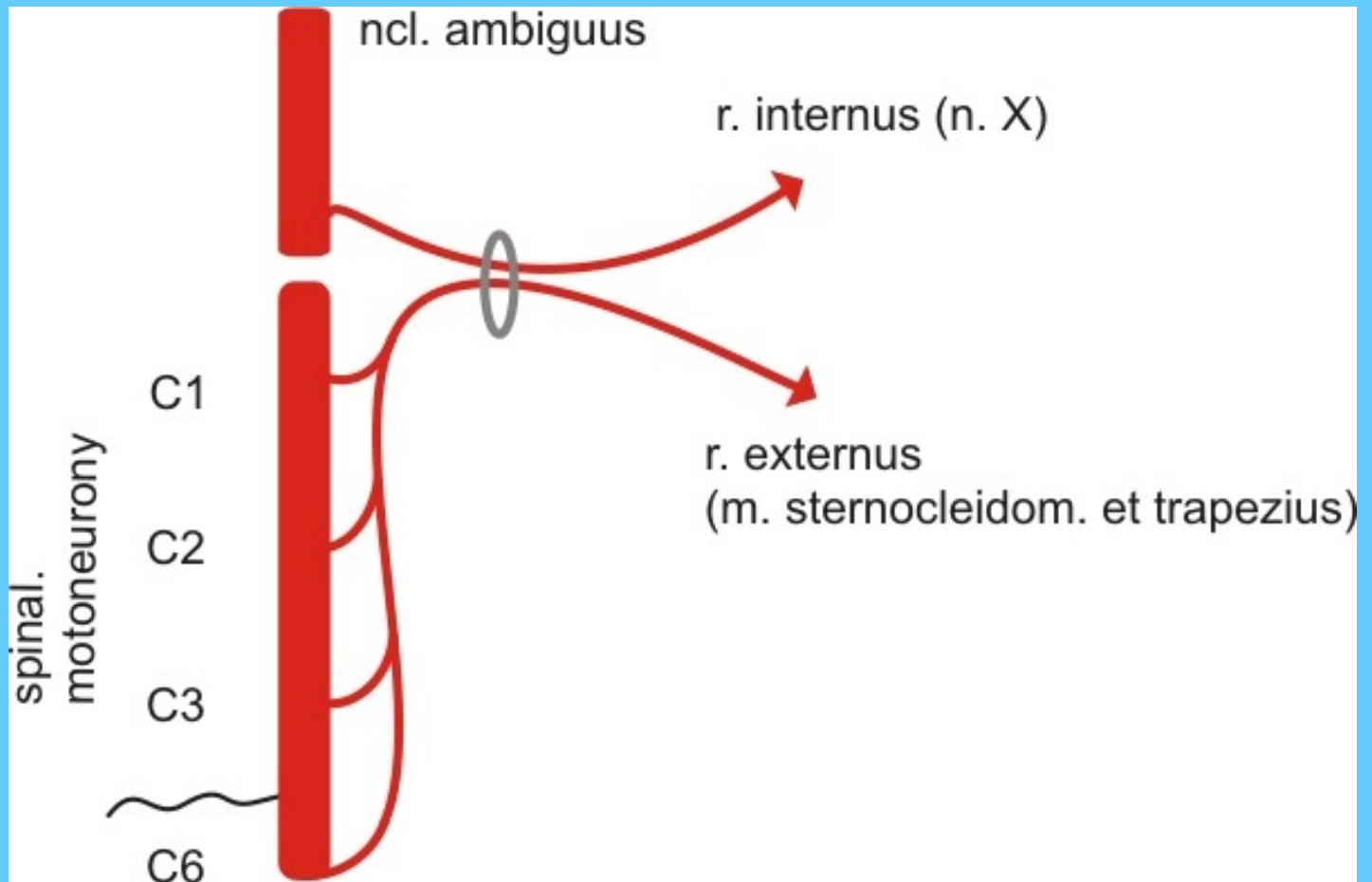


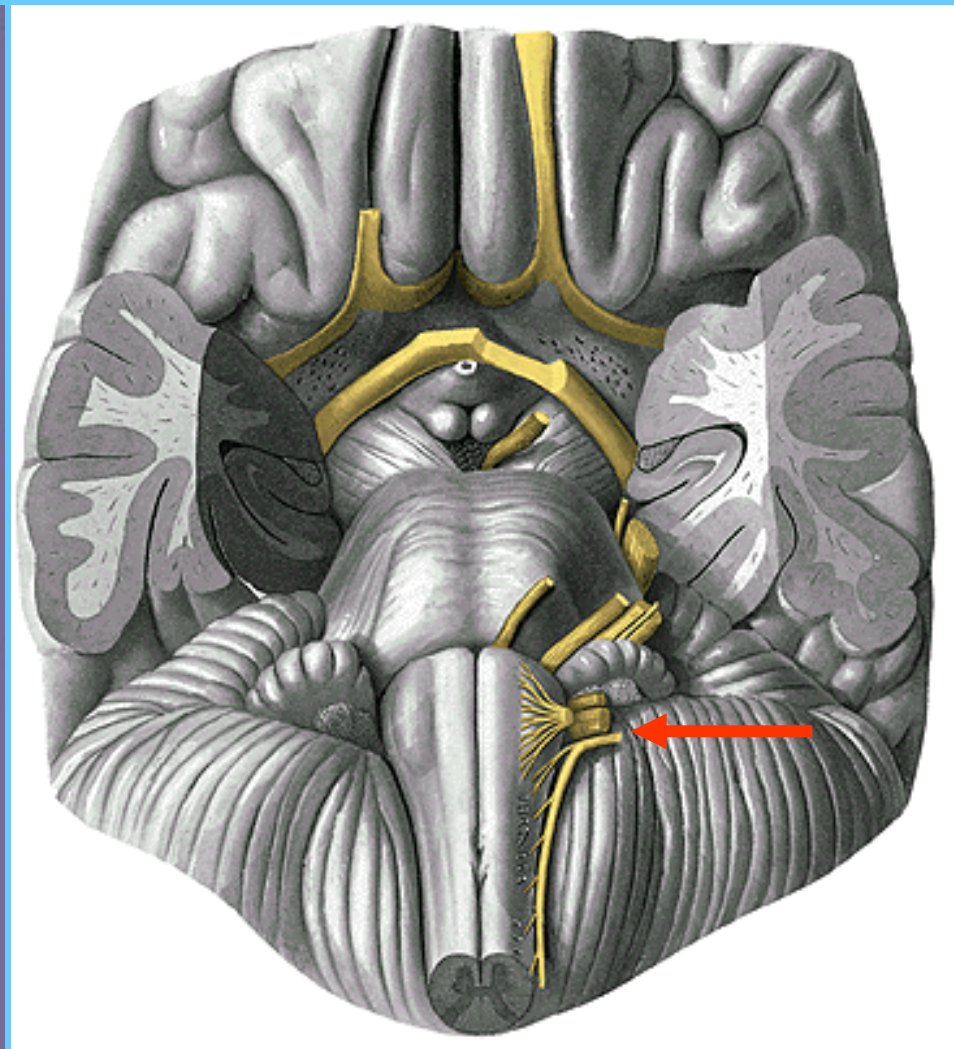
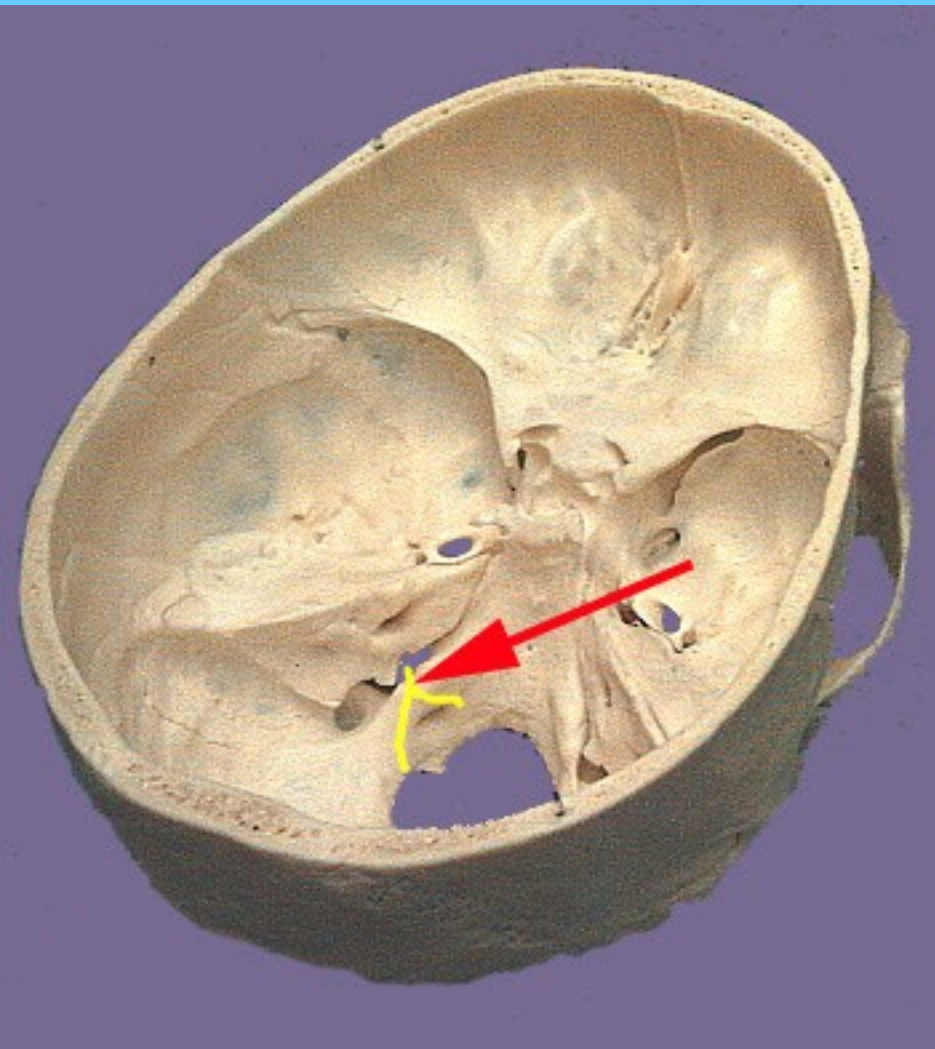
# NERVUS ACCESSORIUS

# CN XI

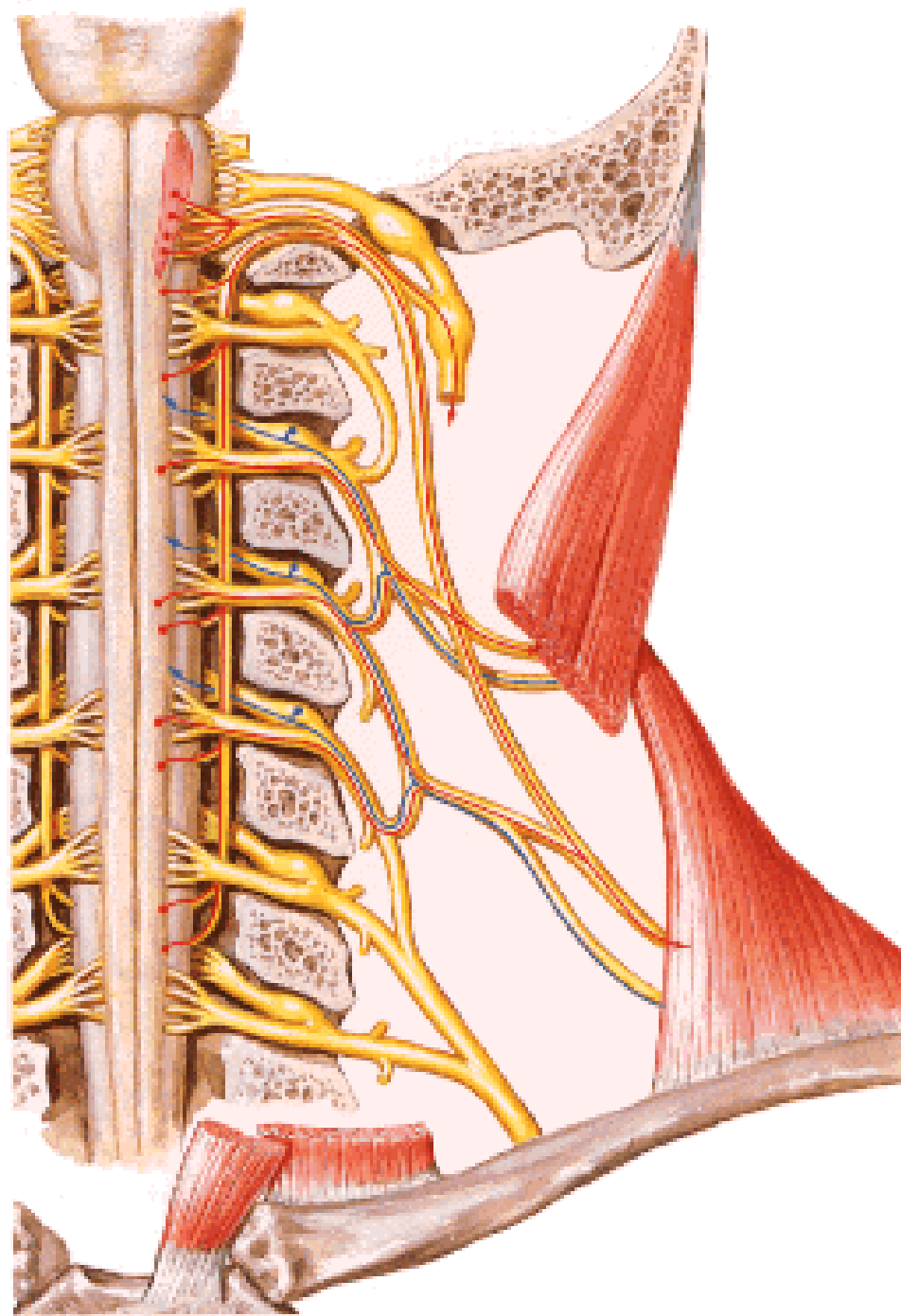


# n. XI.



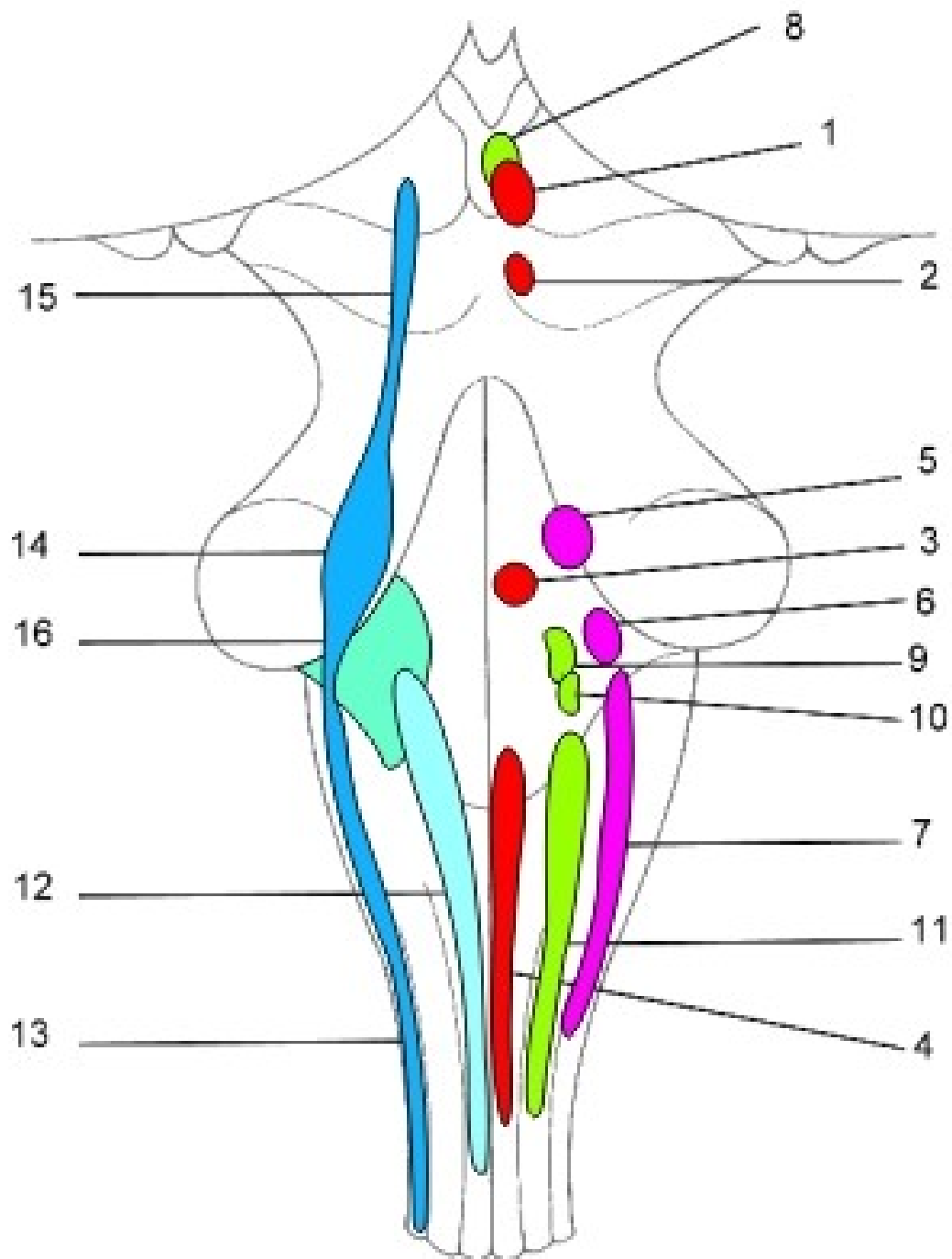


n. XI.

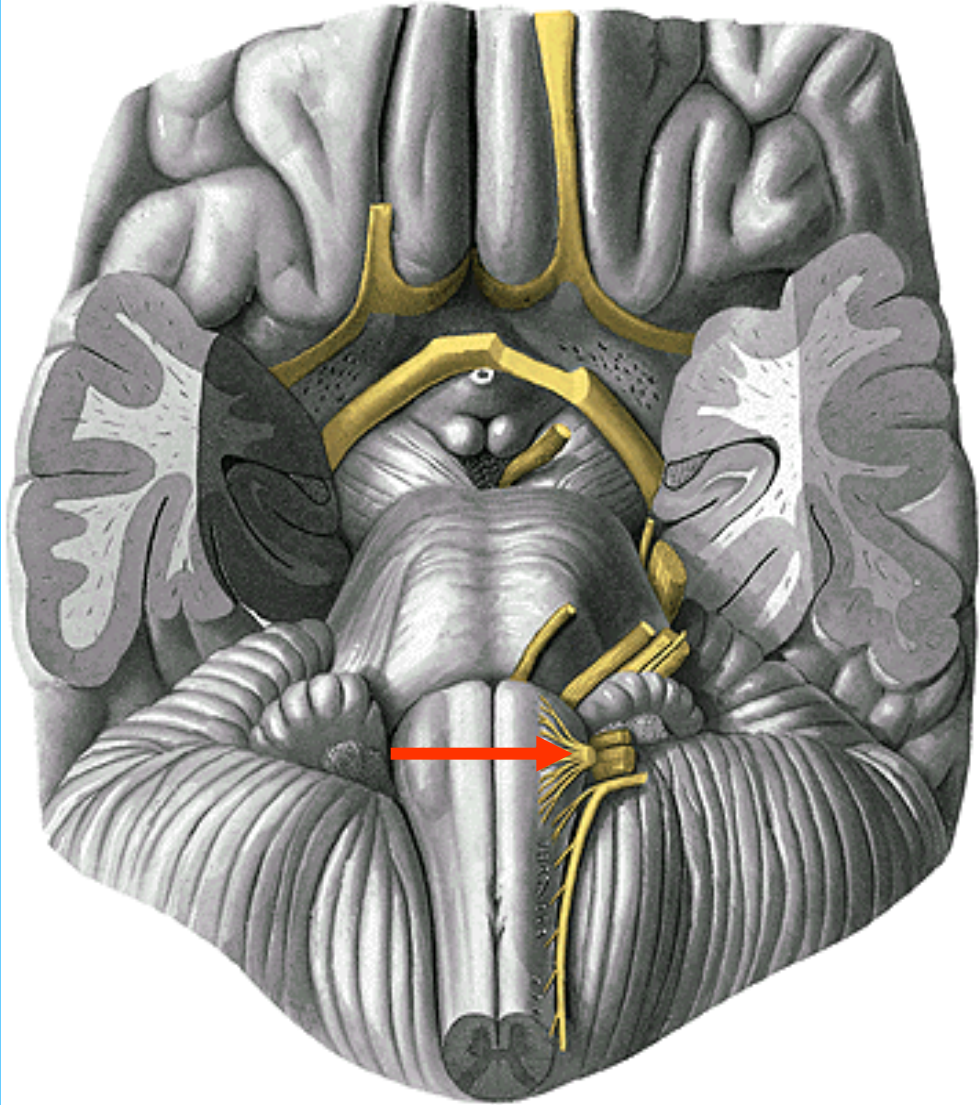
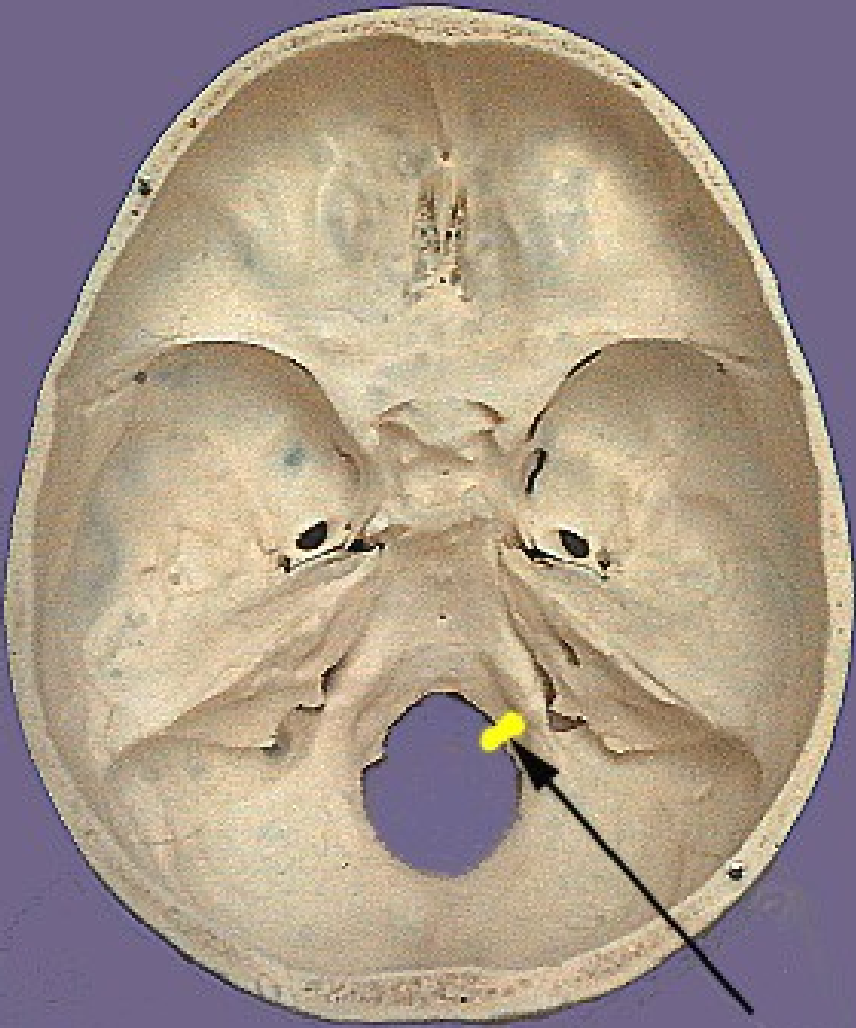


# NERVUS HYPOGLOSSUS

# CN XII

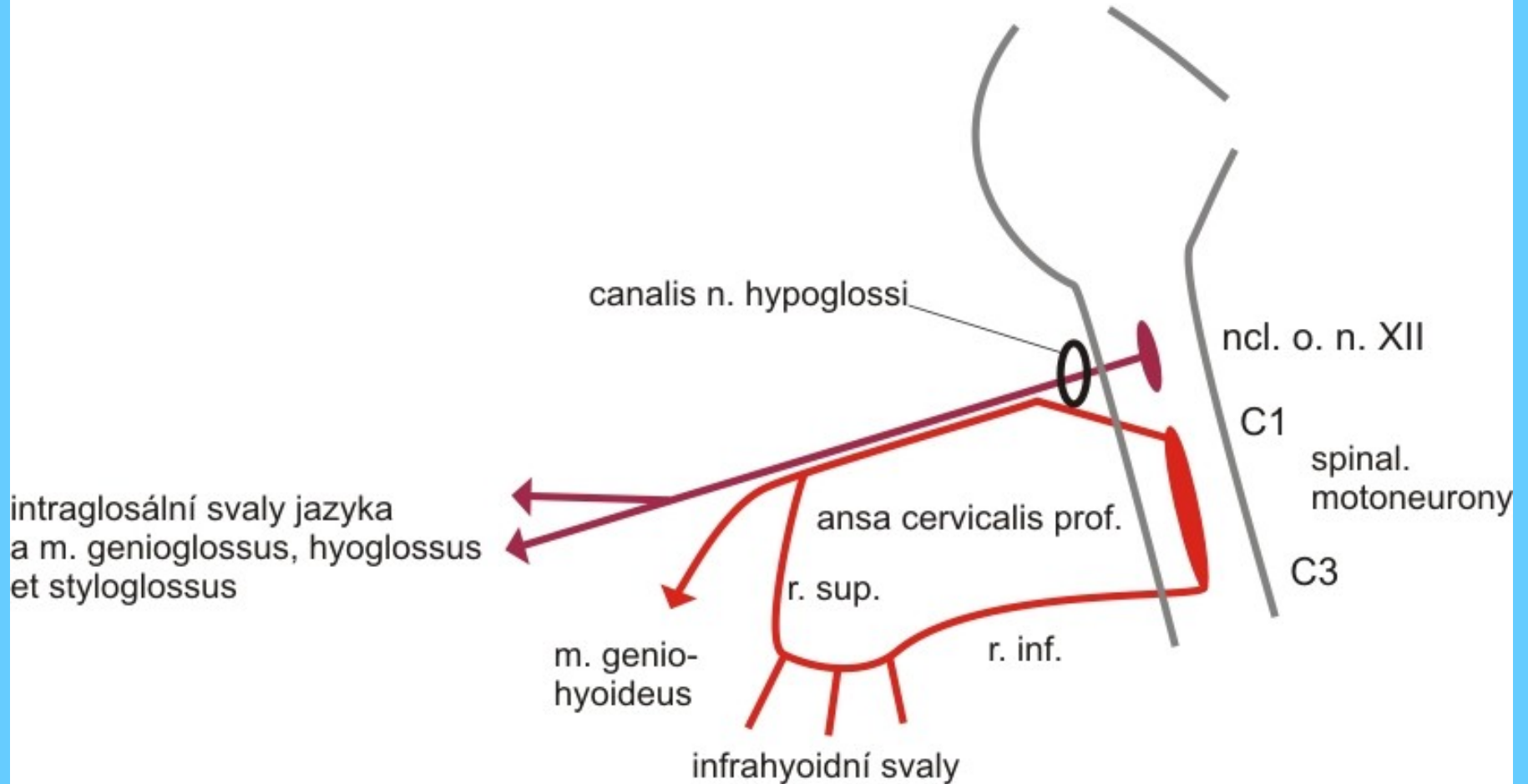


# CN XII

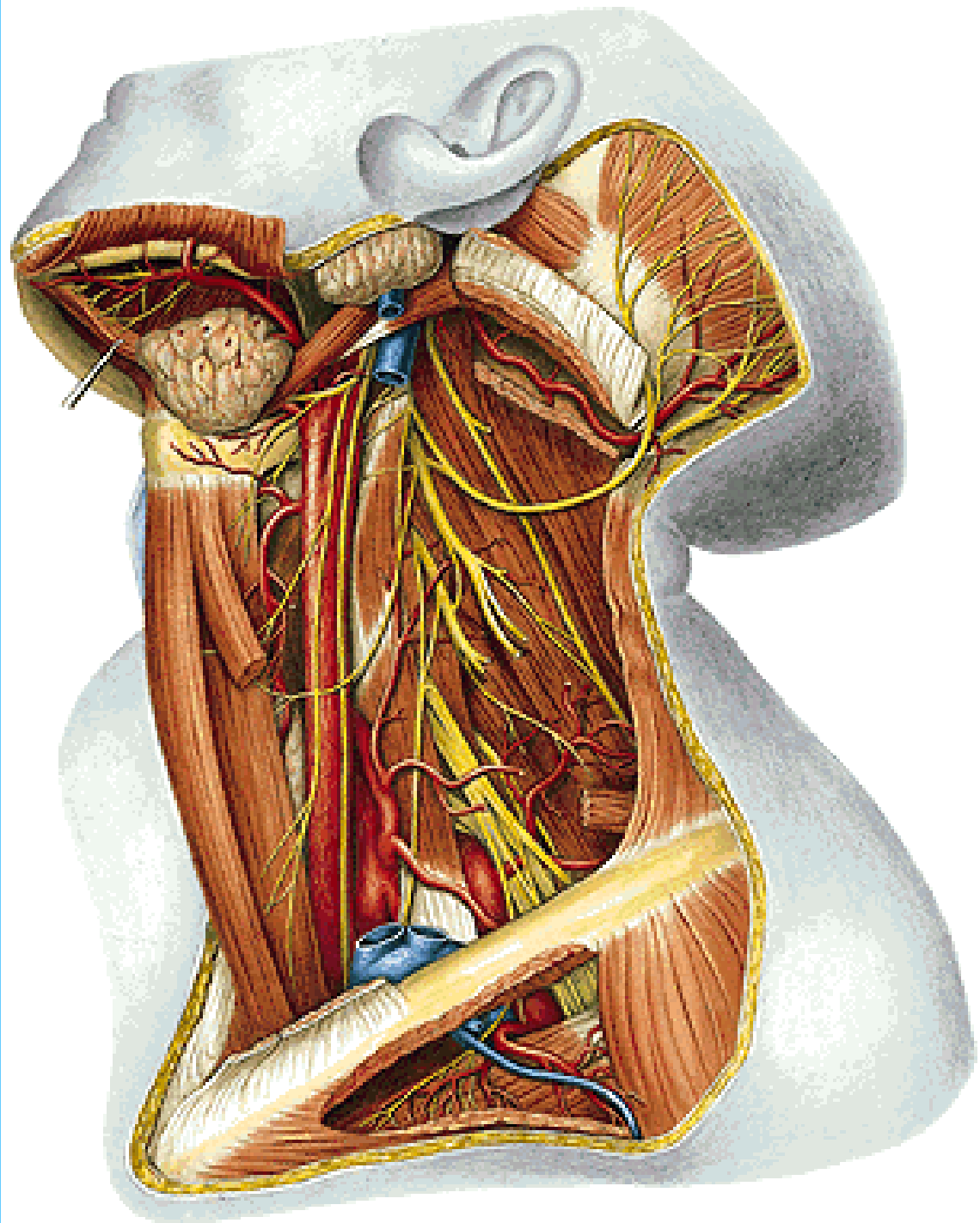


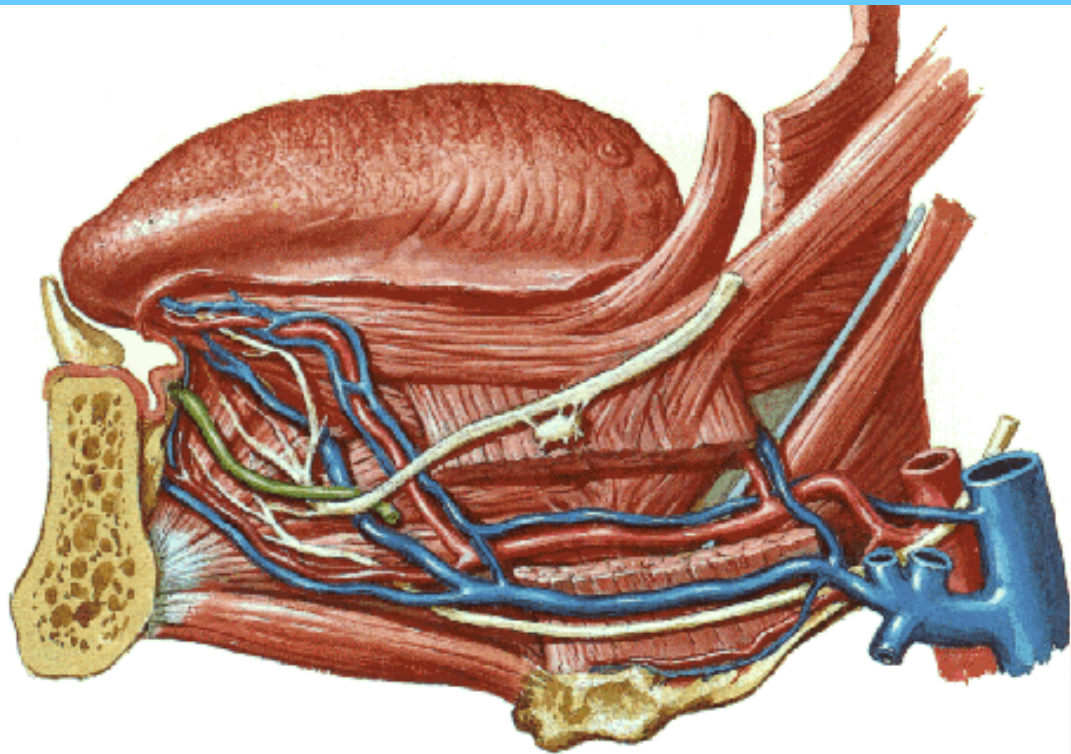


# n. XII.

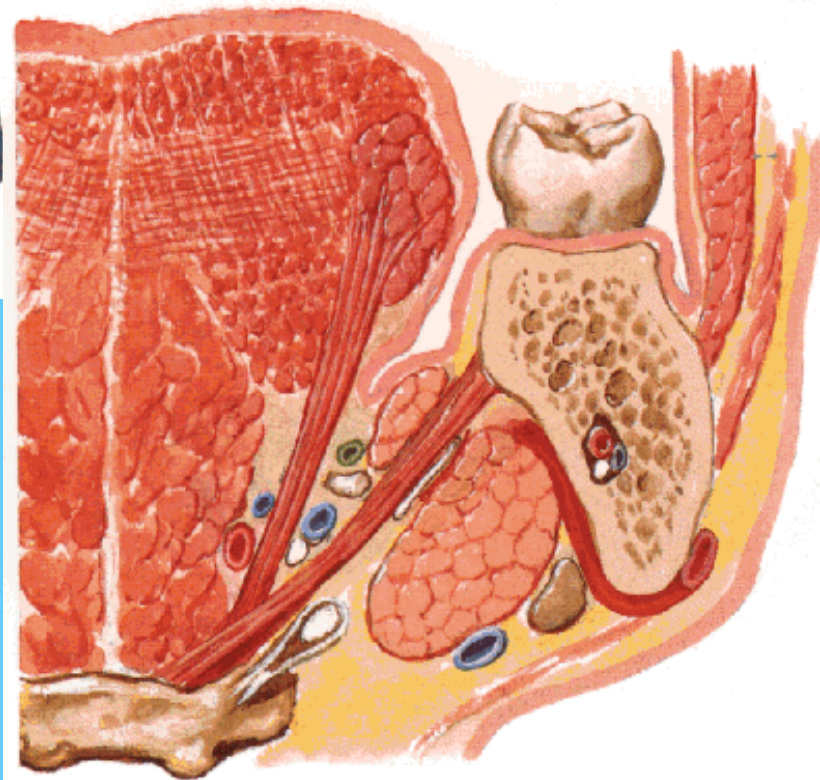


CN XII

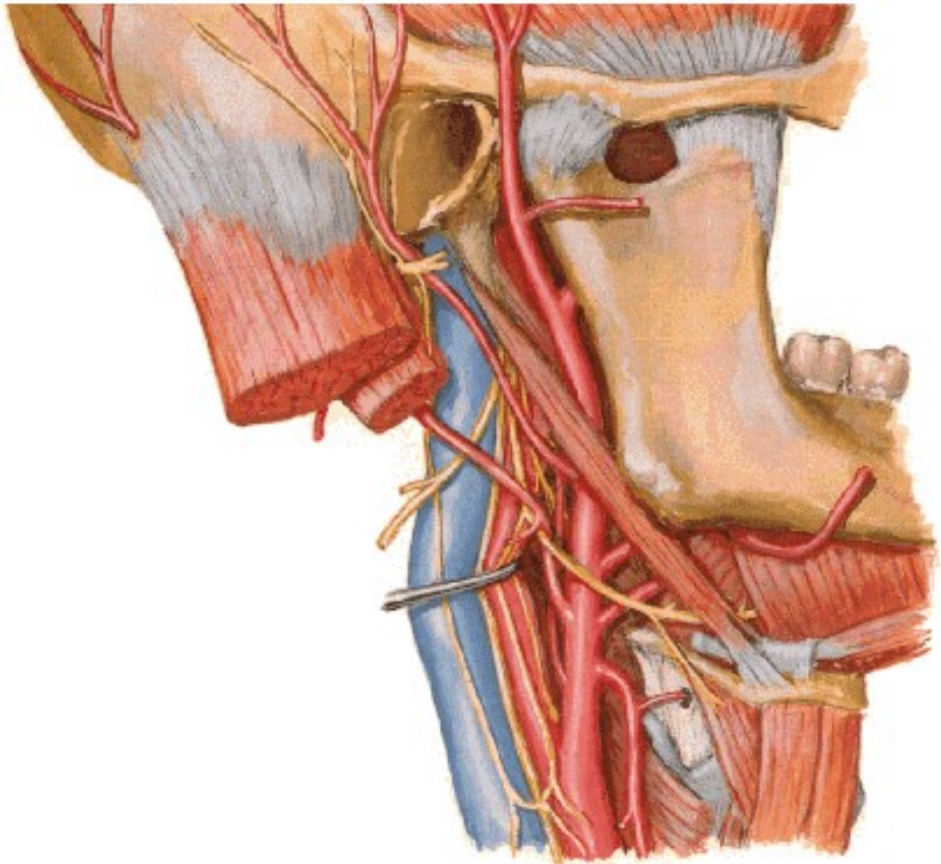




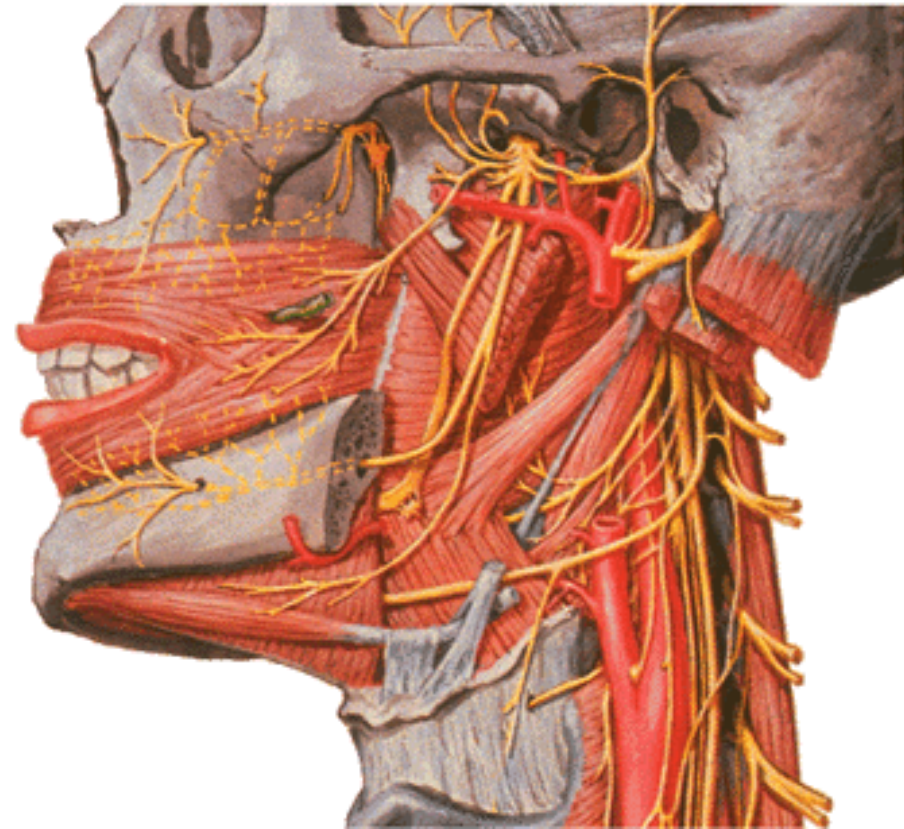
**CN XII**

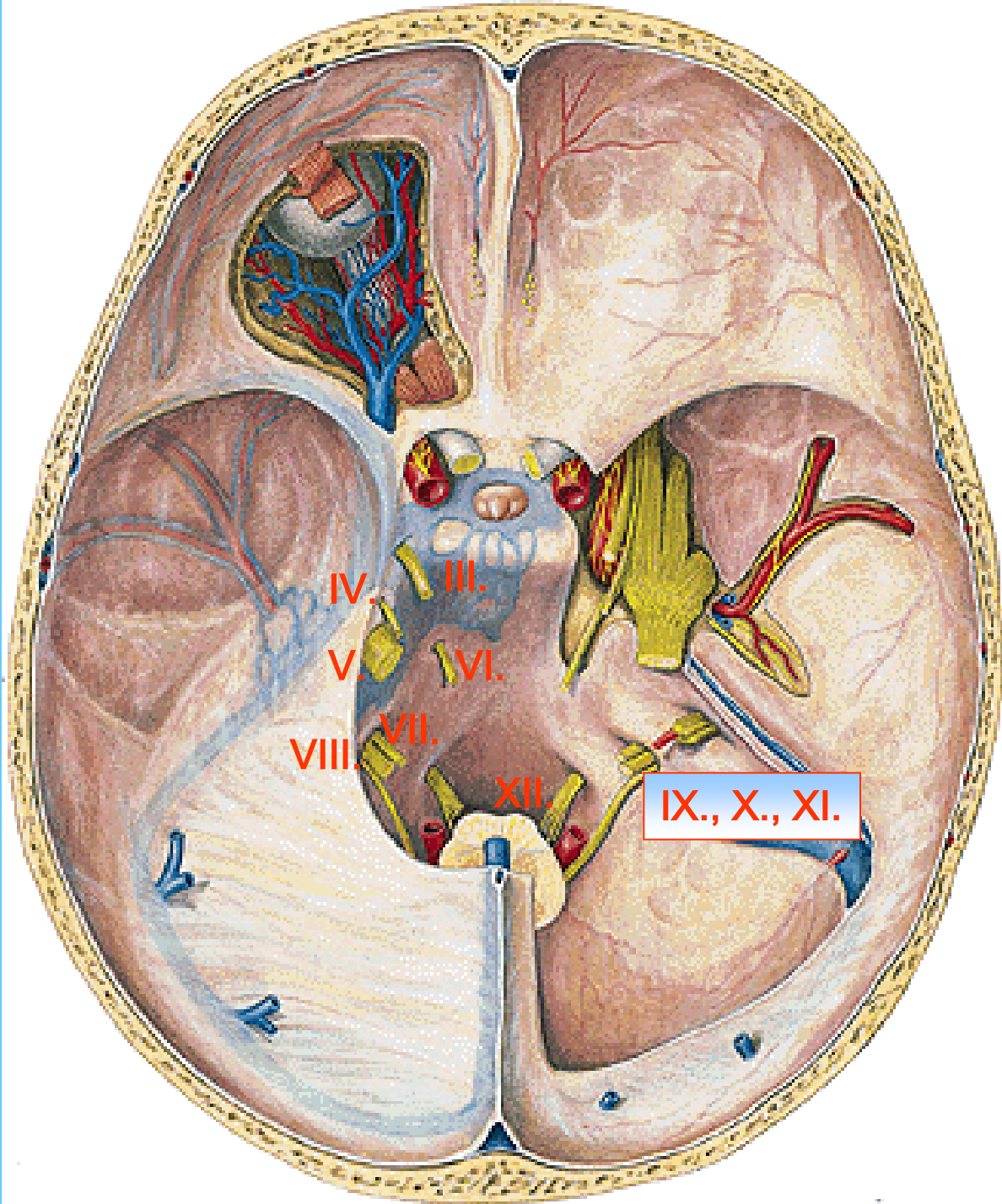


Sectioned behind 1st molar tooth



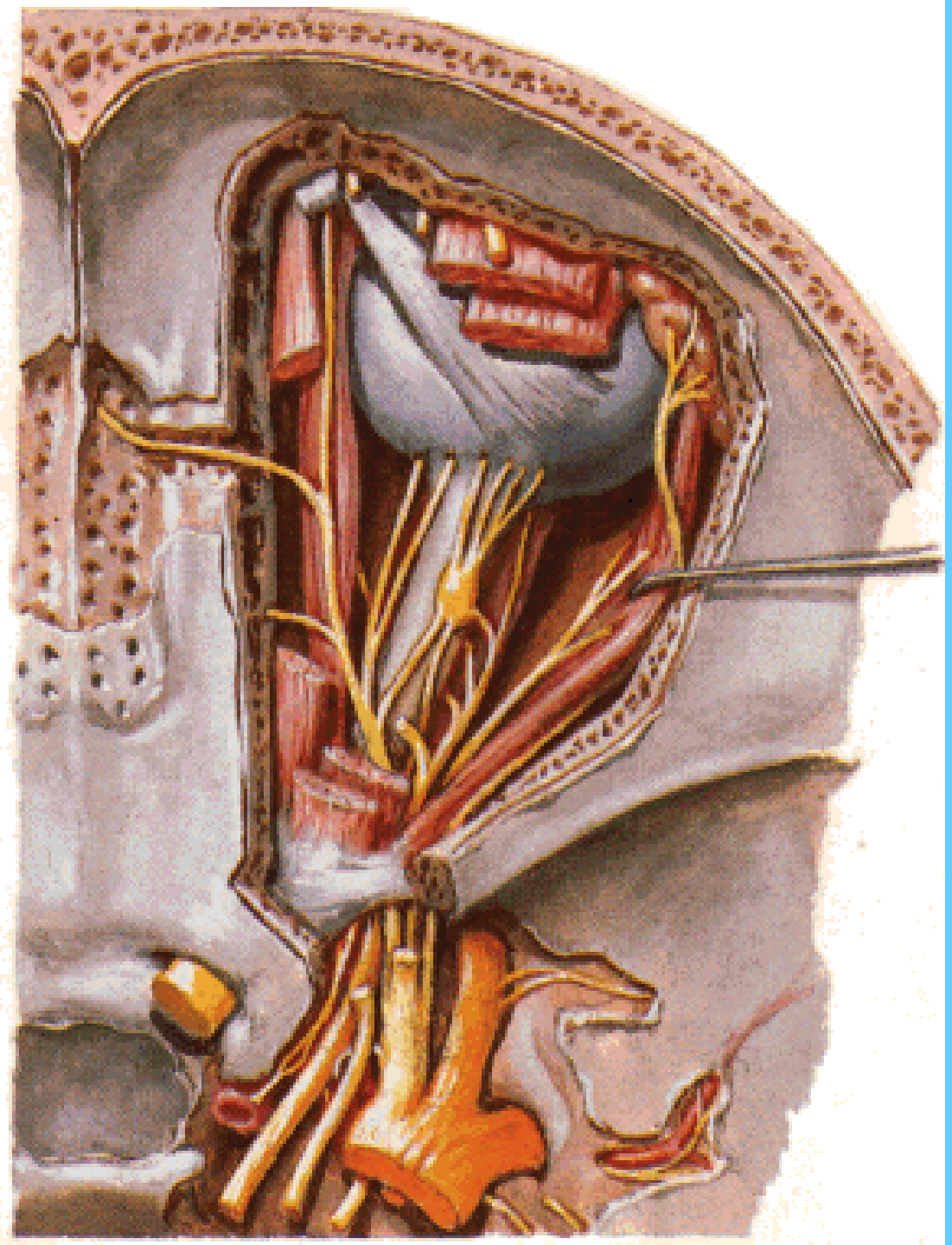**CN XII**

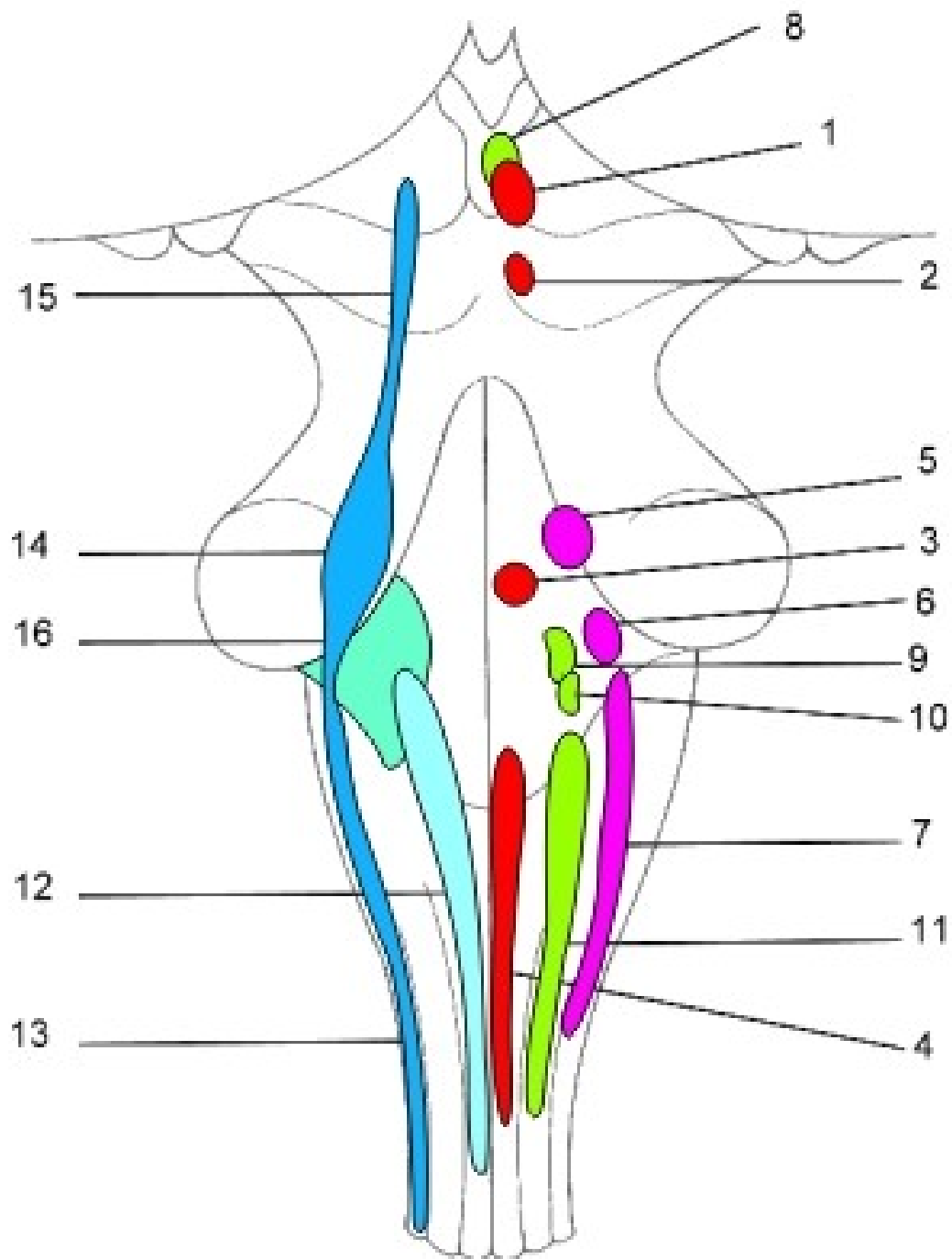




# PARASYMPATHETIC GANGLIA

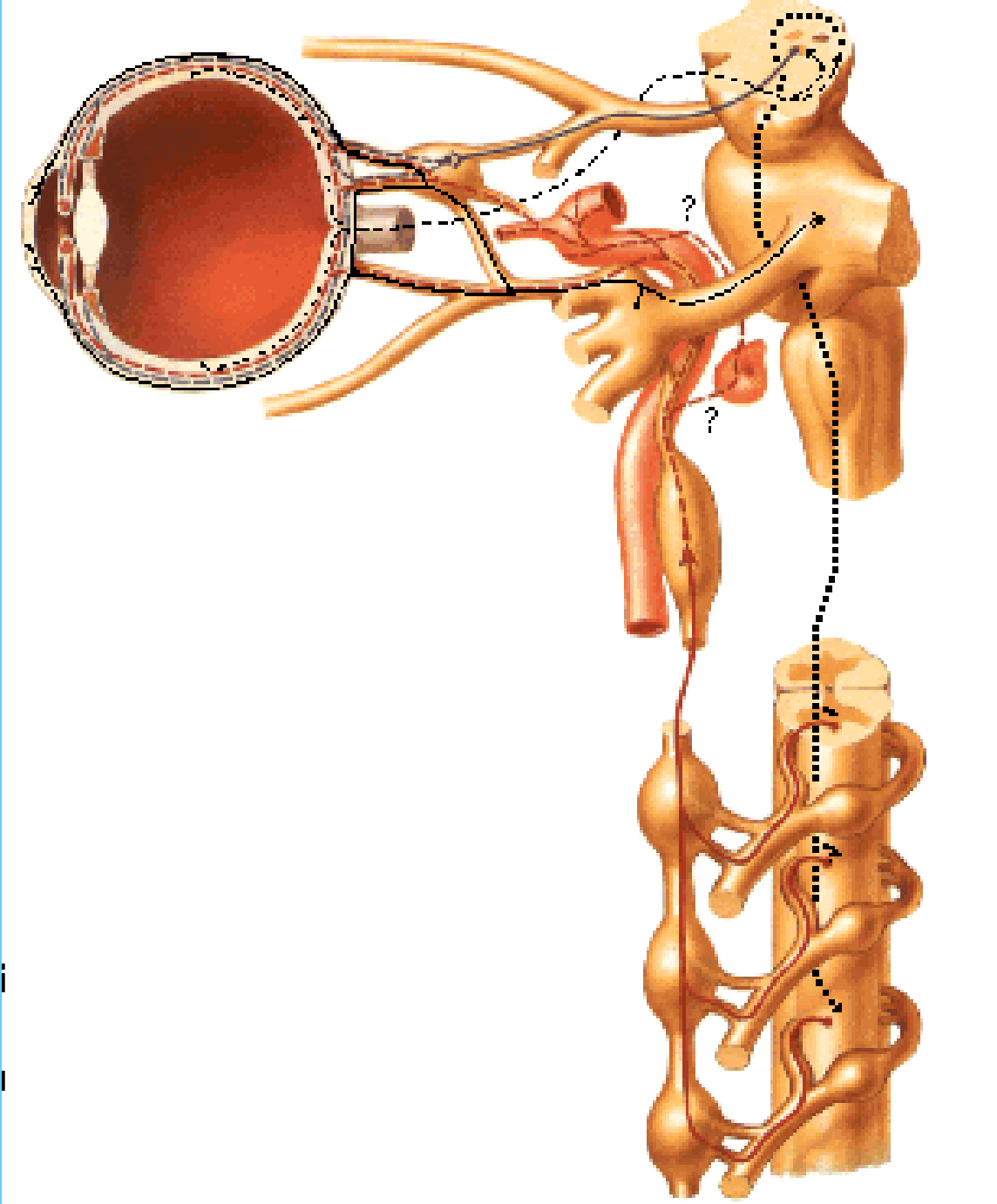
# GANGLION CILIARE







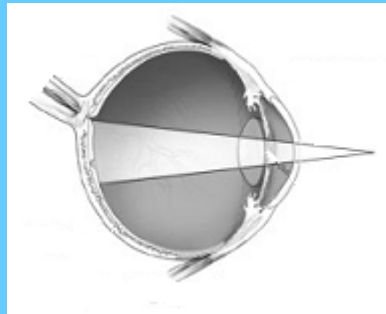
Ggl. ciliare



# Parasympathetic fibres

**M. sphincter pupillae**

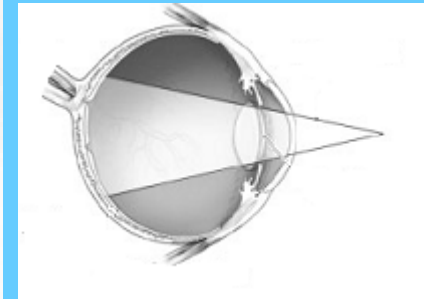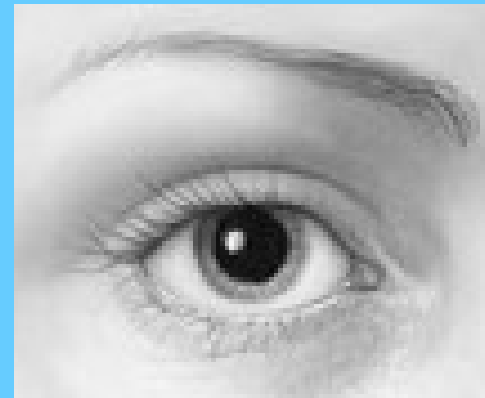**Miosis**



# Sympathetic fibres

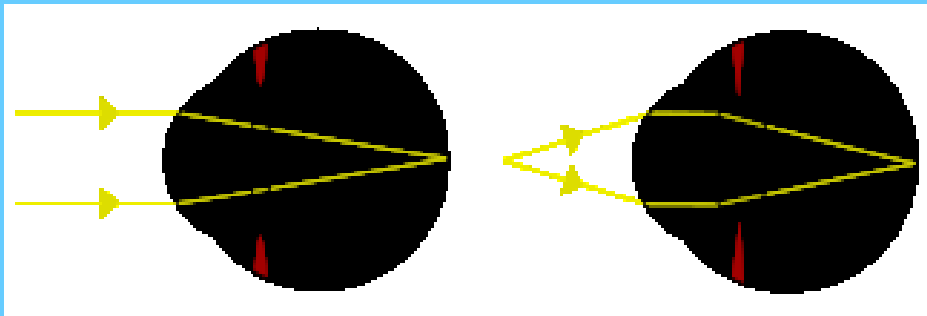
**M. dilatator pupillae**

**Mydriasis**

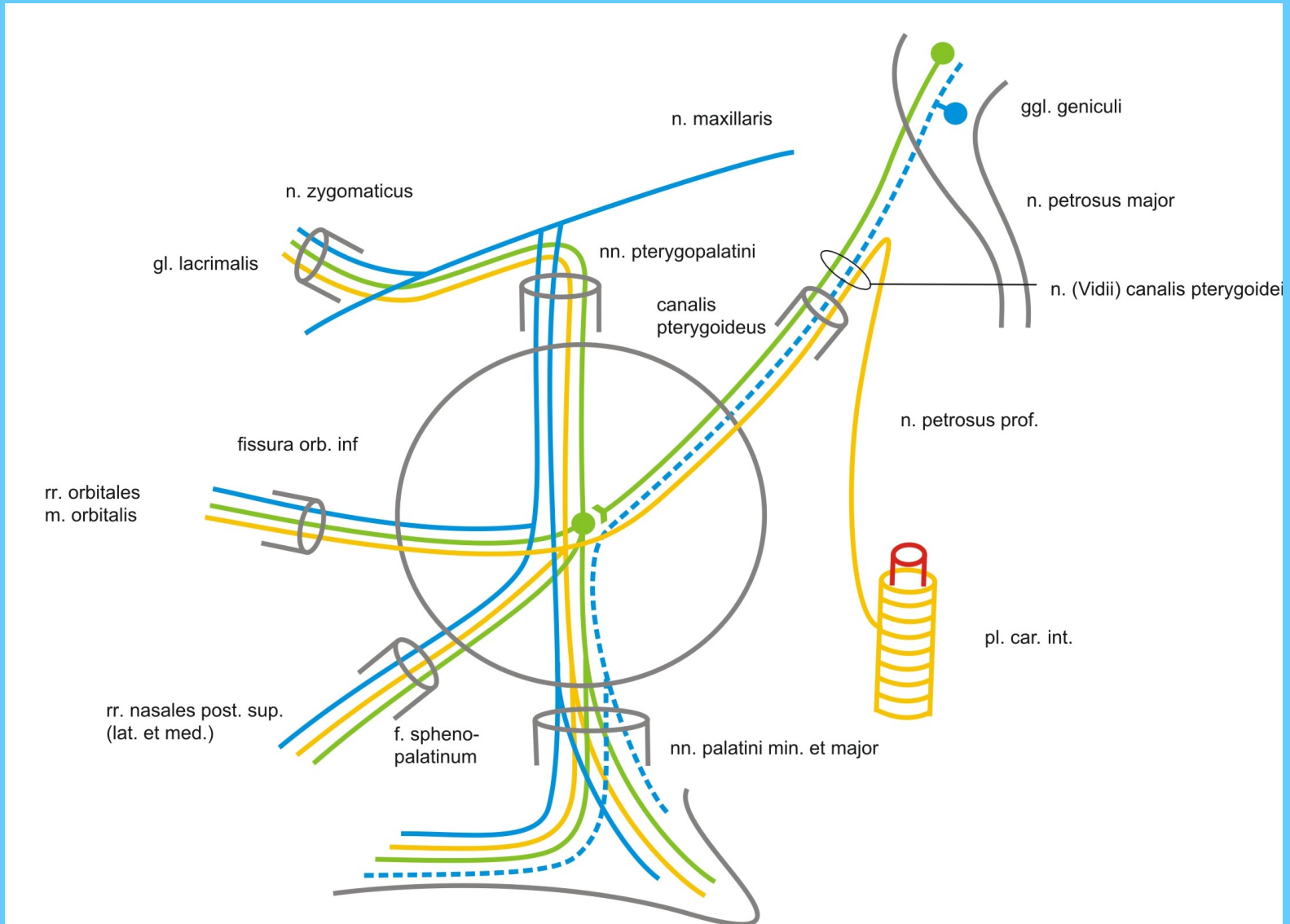


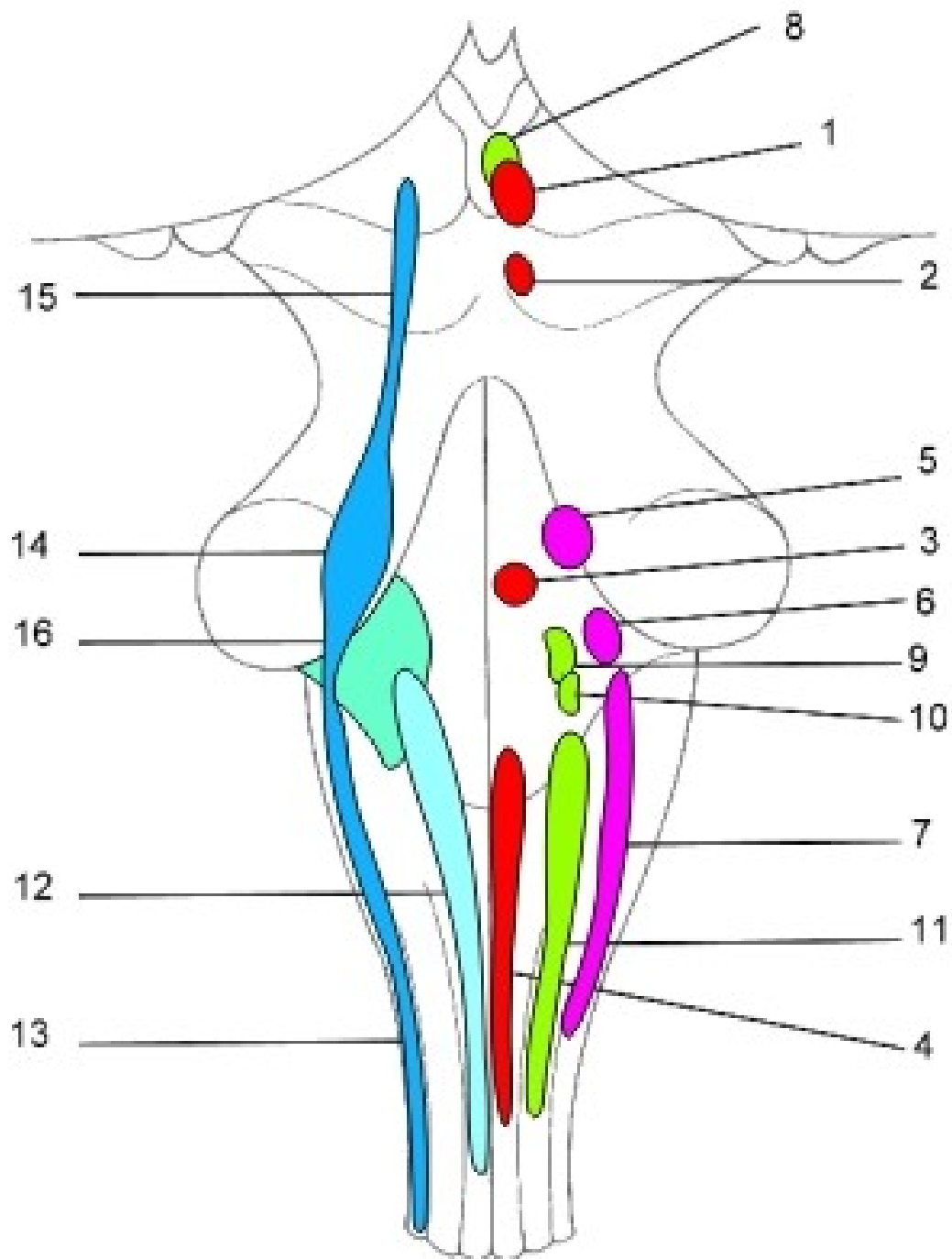
**M. ciliaris**

**Akomodation**

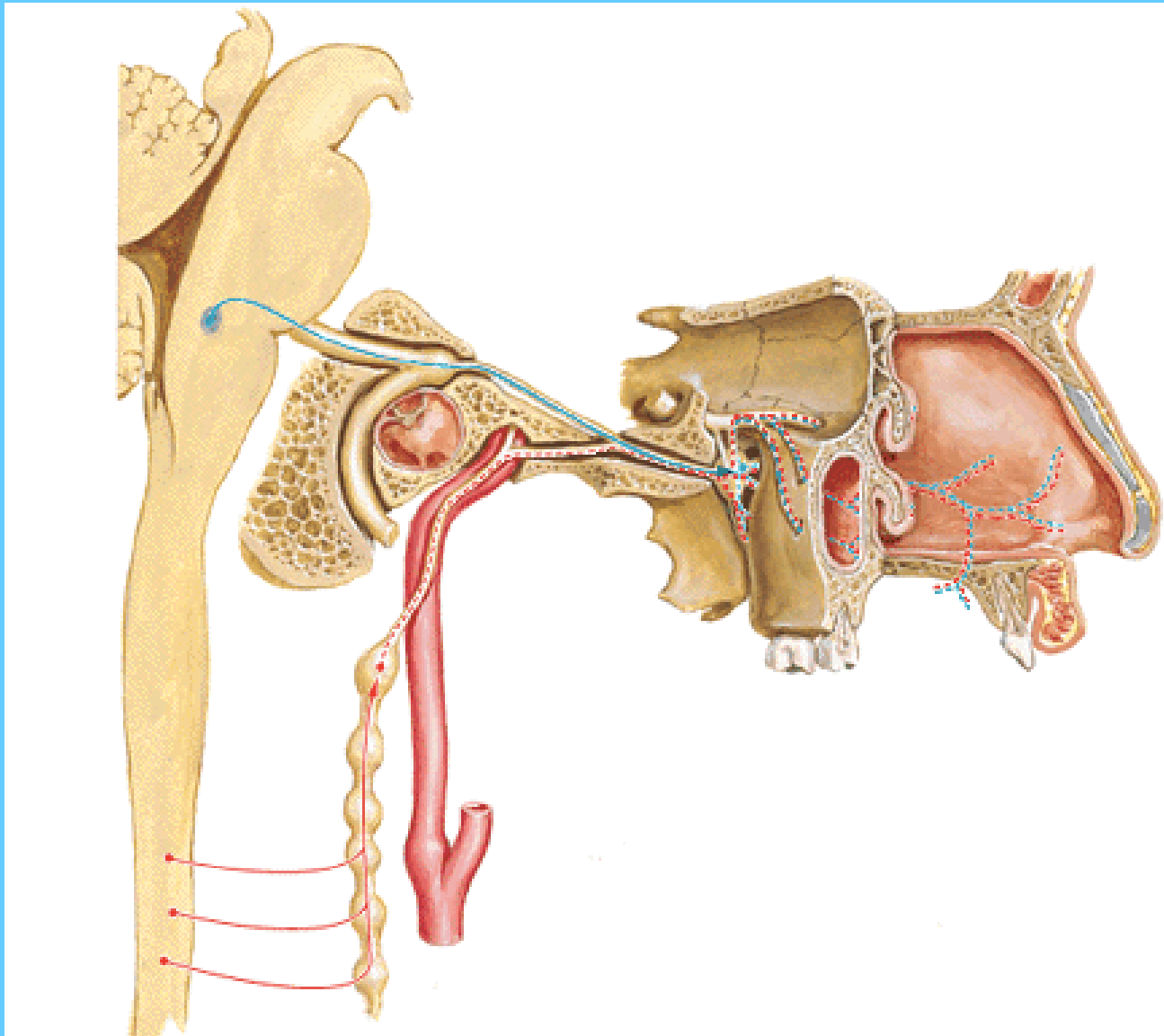


# GANGLION PTERYGOPALATINUM

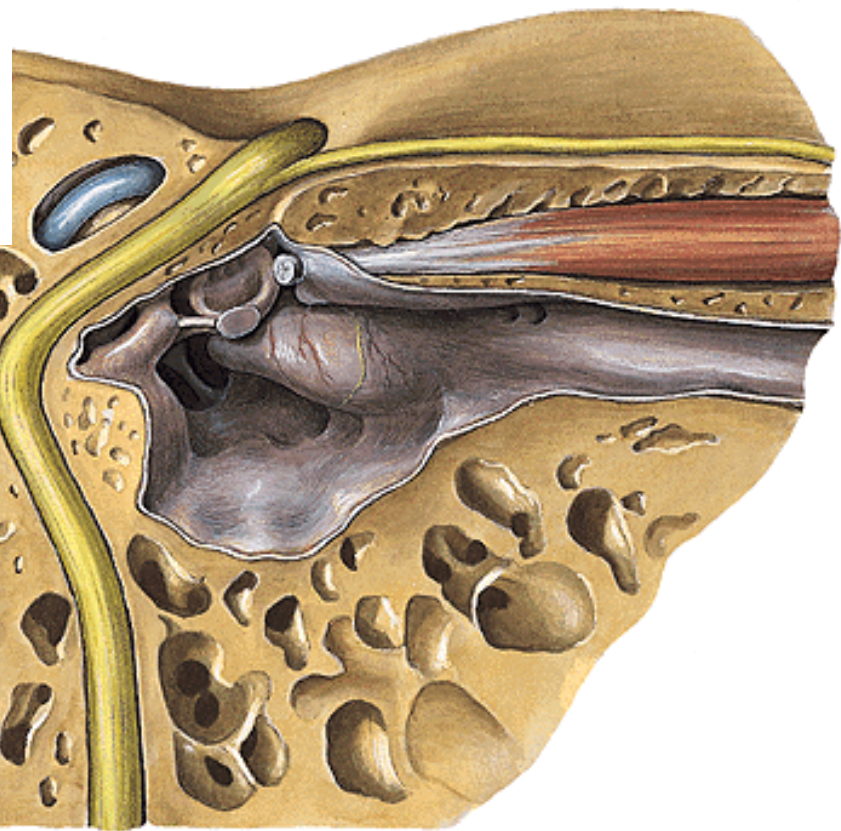
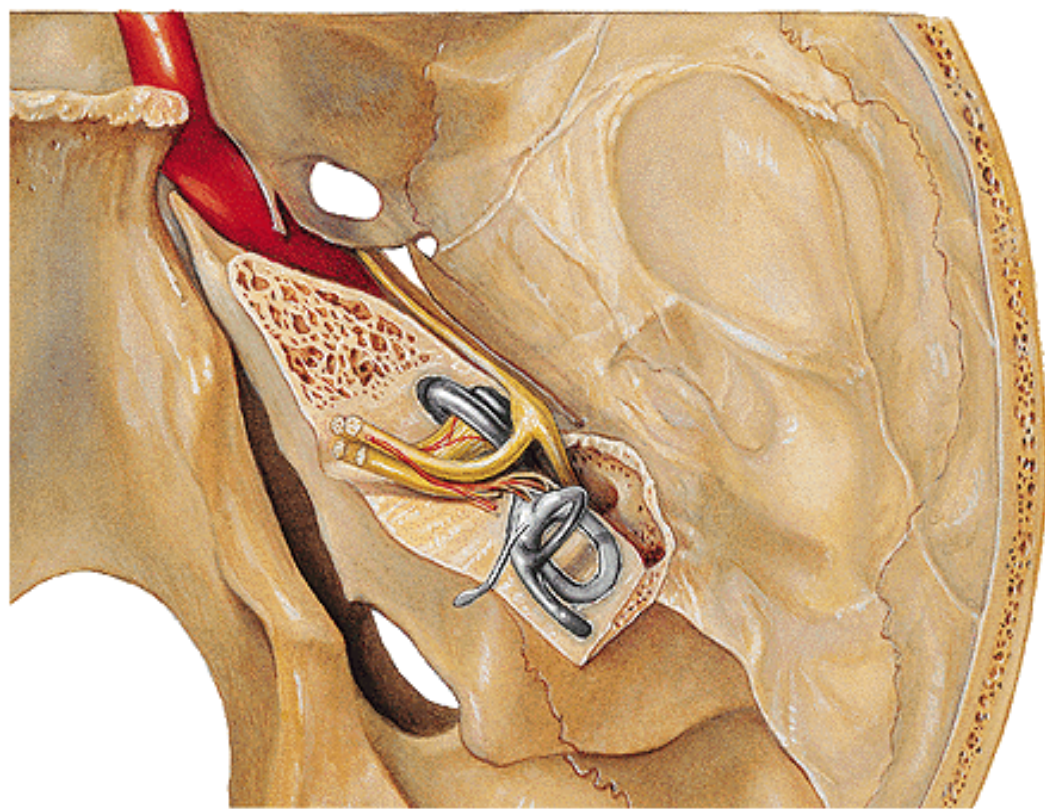




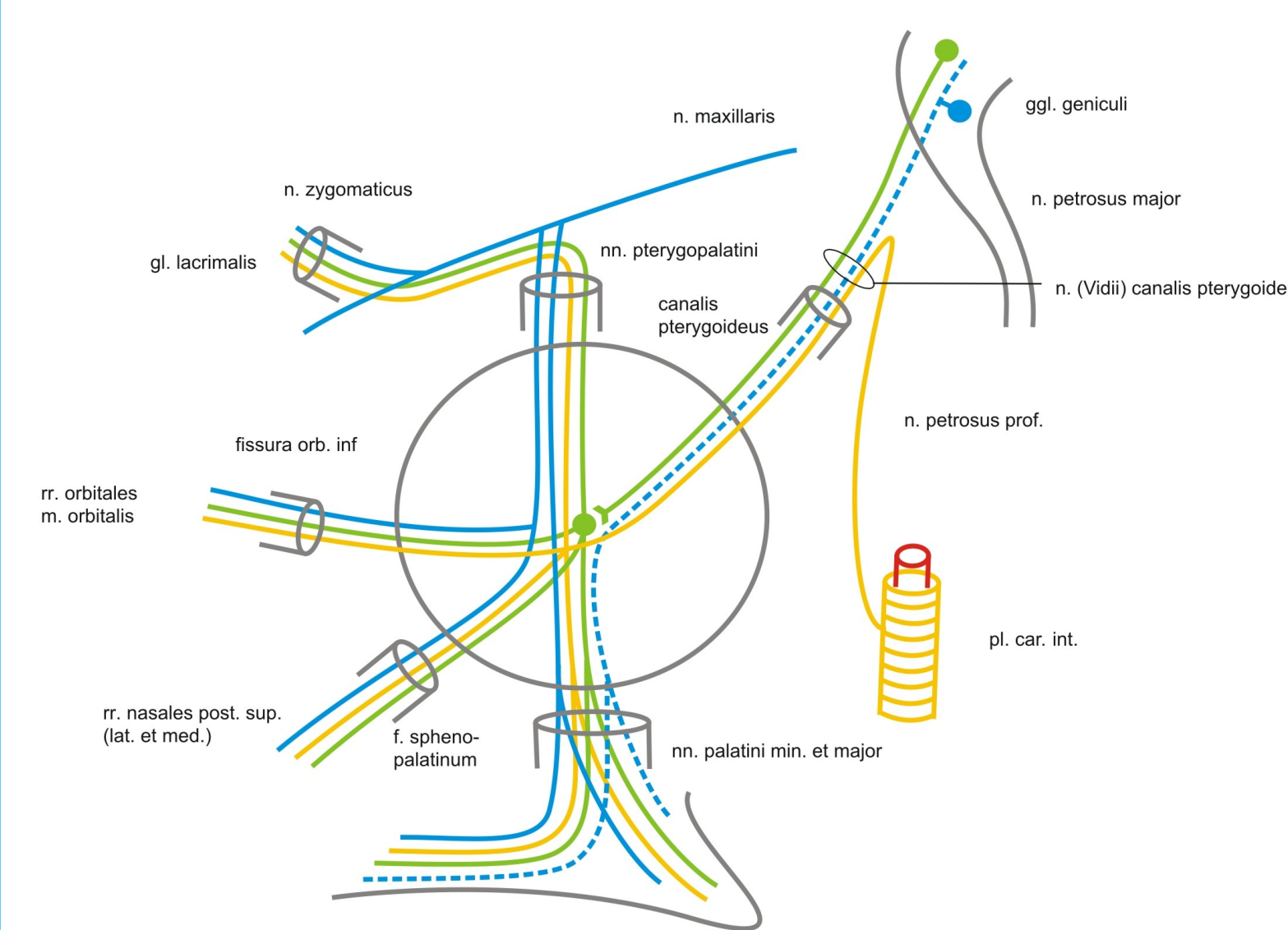
# N. canalis pterygoidei



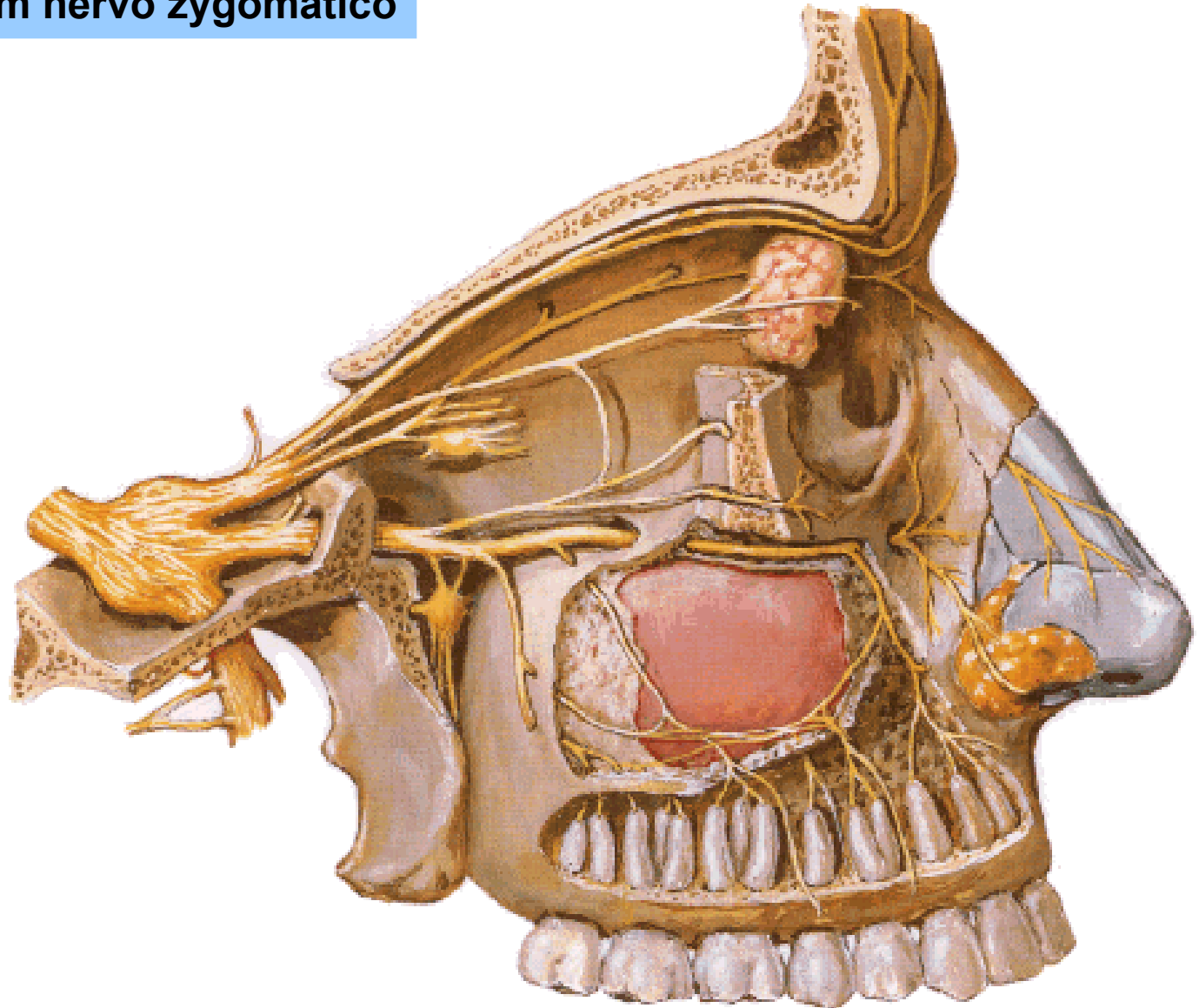
## N. petrosus major



# GANGLION PTERYGOPALATINUM

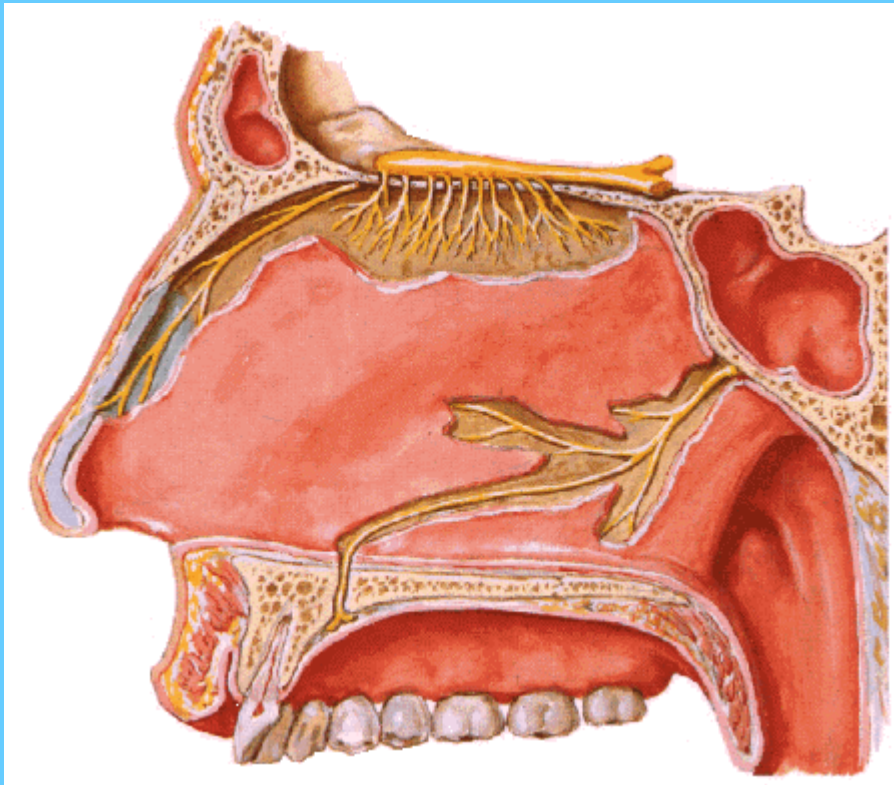


**R. communicans cum nervo zygomatico**

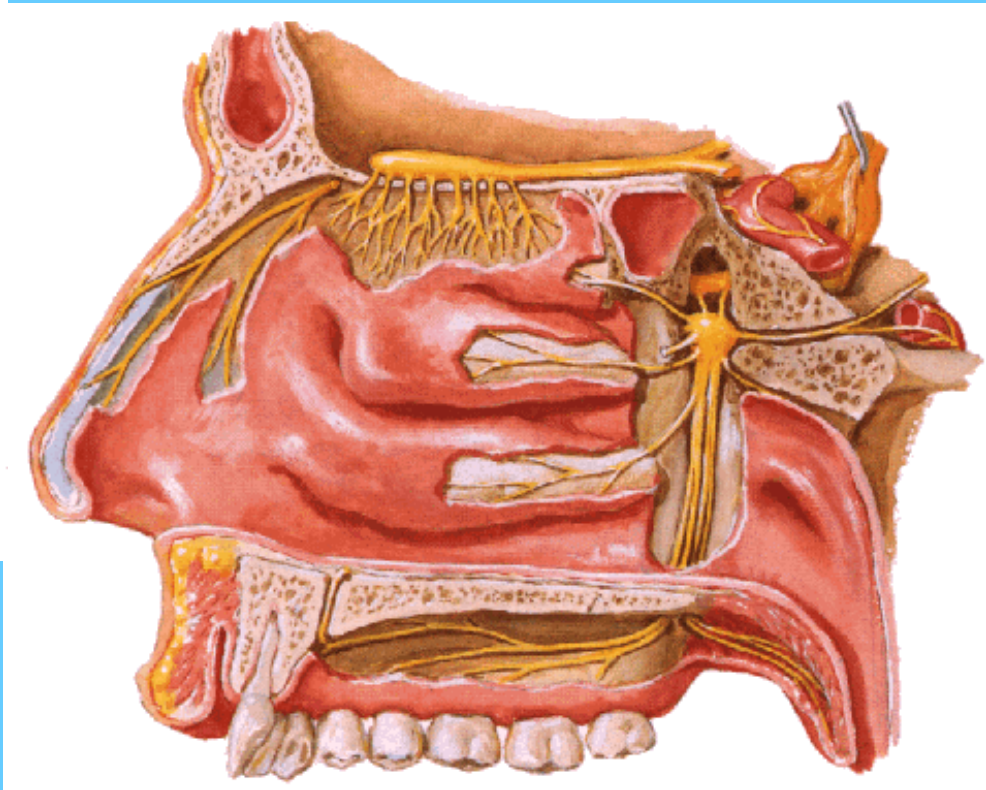




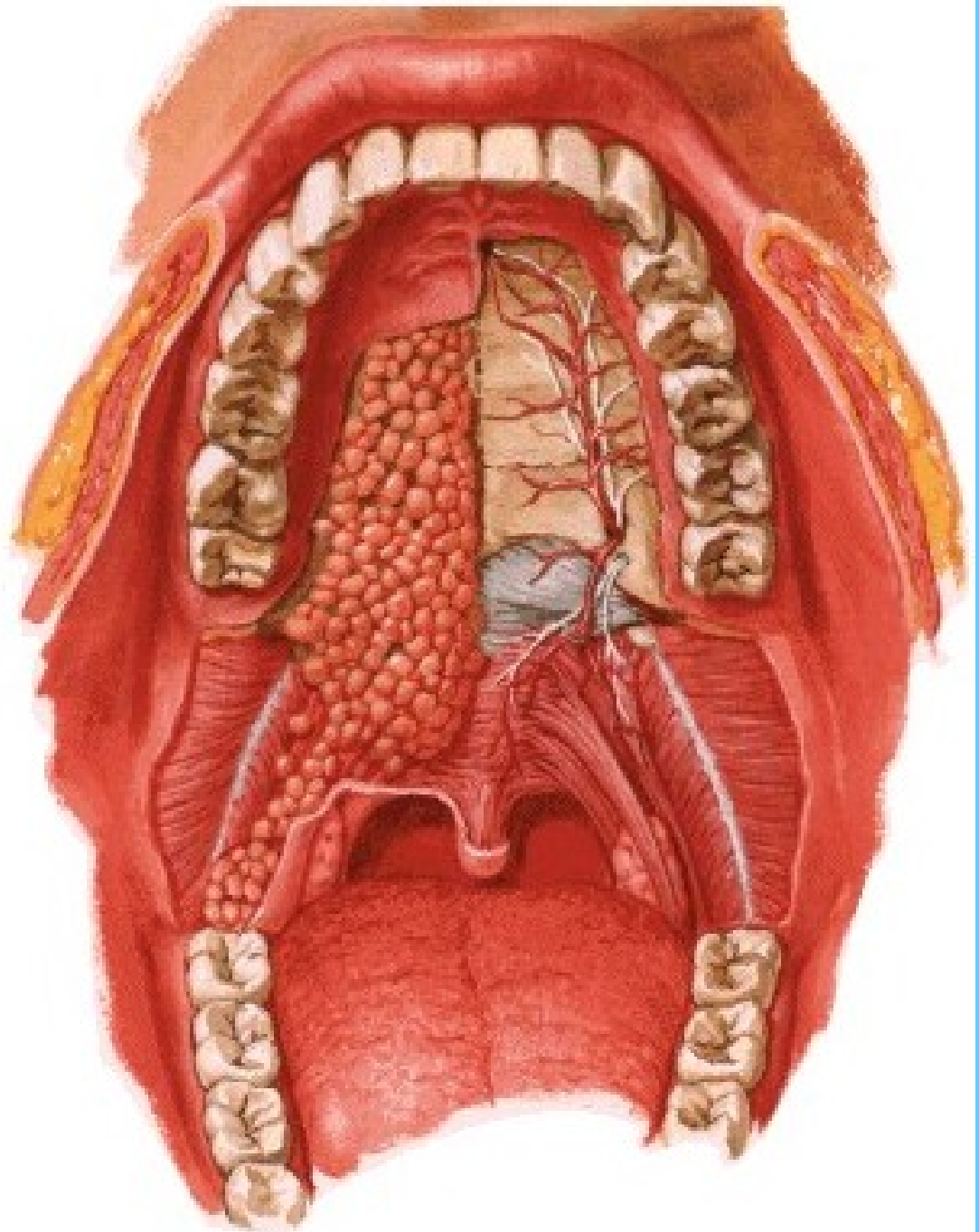
## Rr. nasales posteriores mediales et laterales



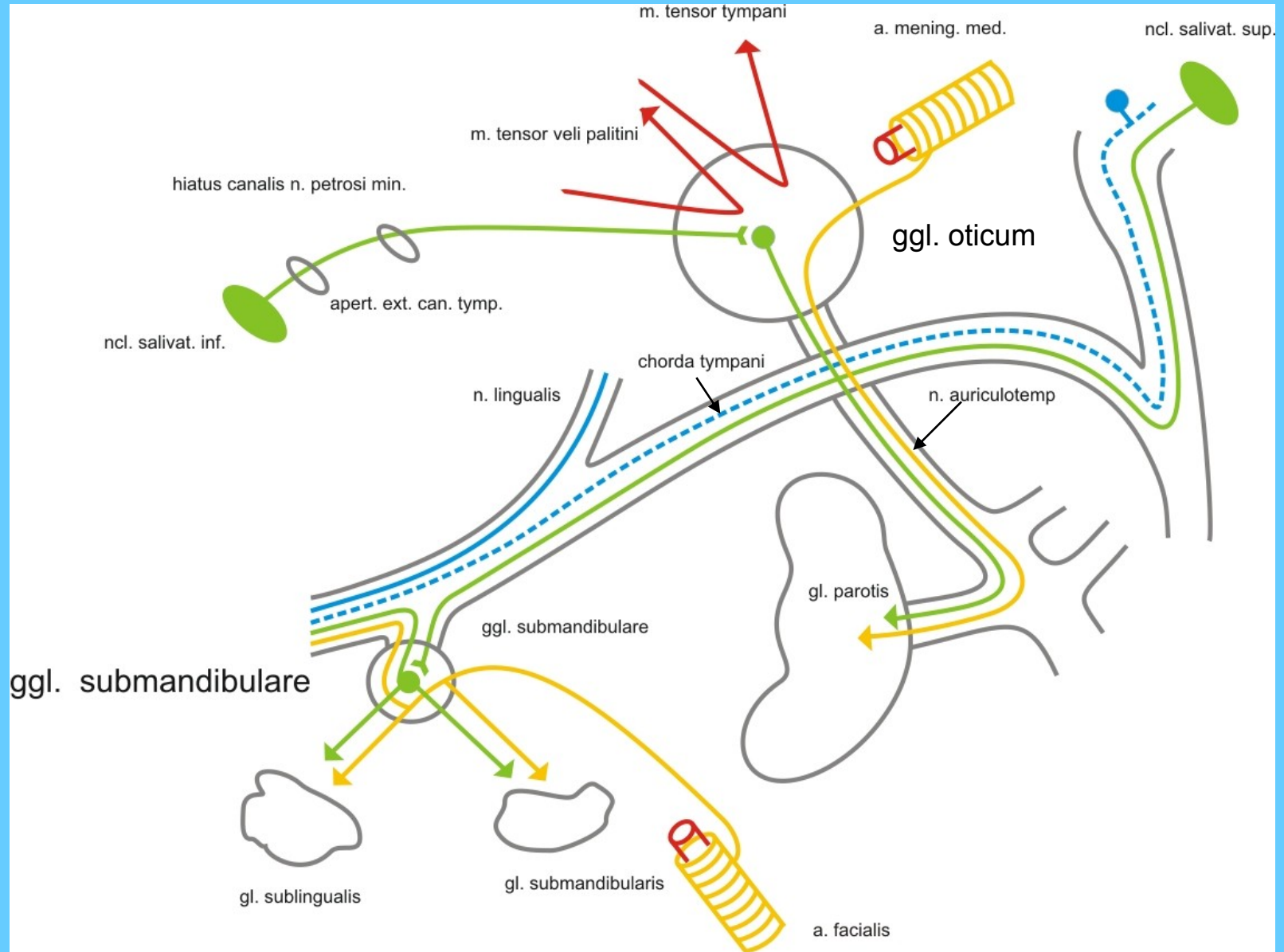
**N. nasopalatinus**

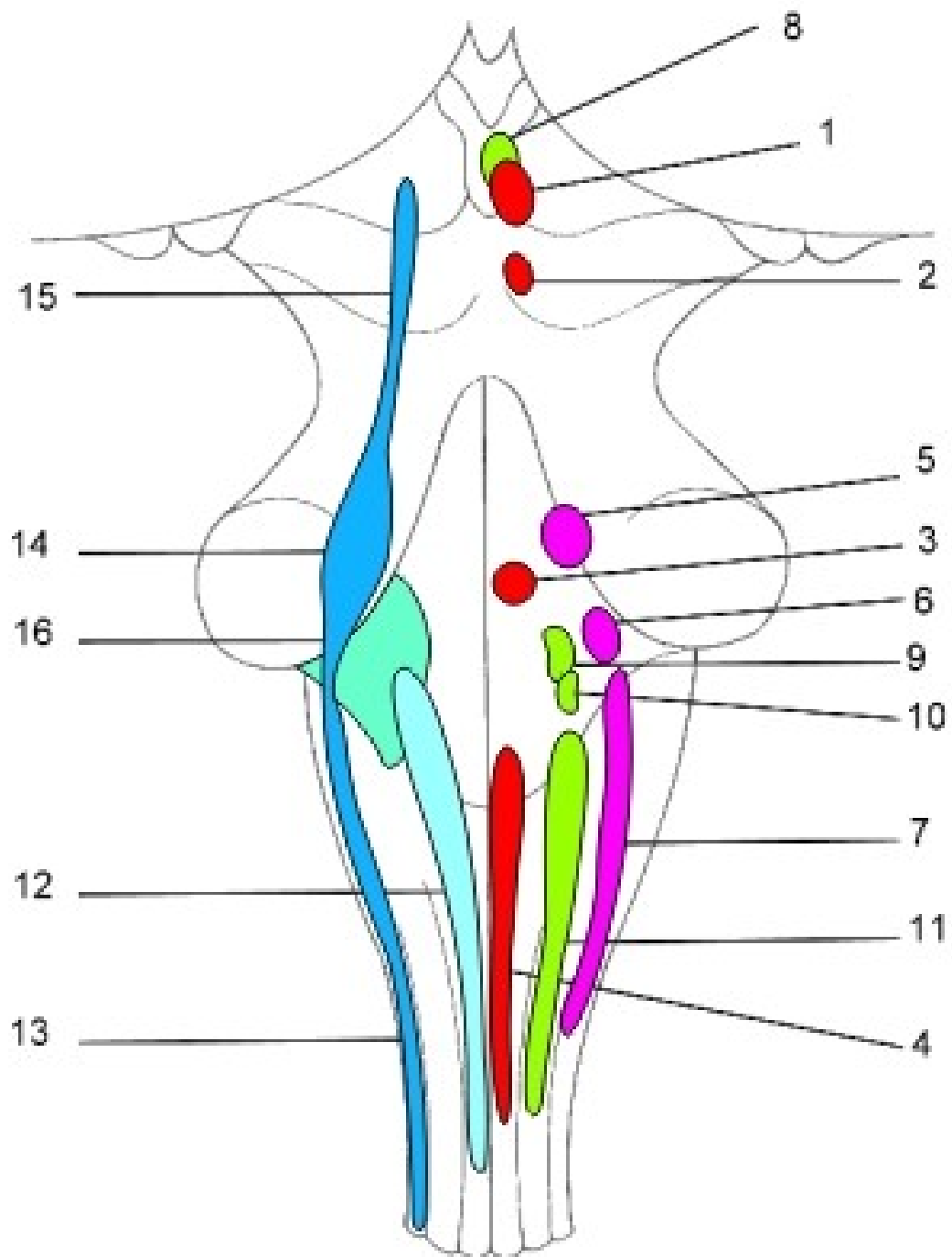


**N. palatinus major**  
**Nn. palatini minores**

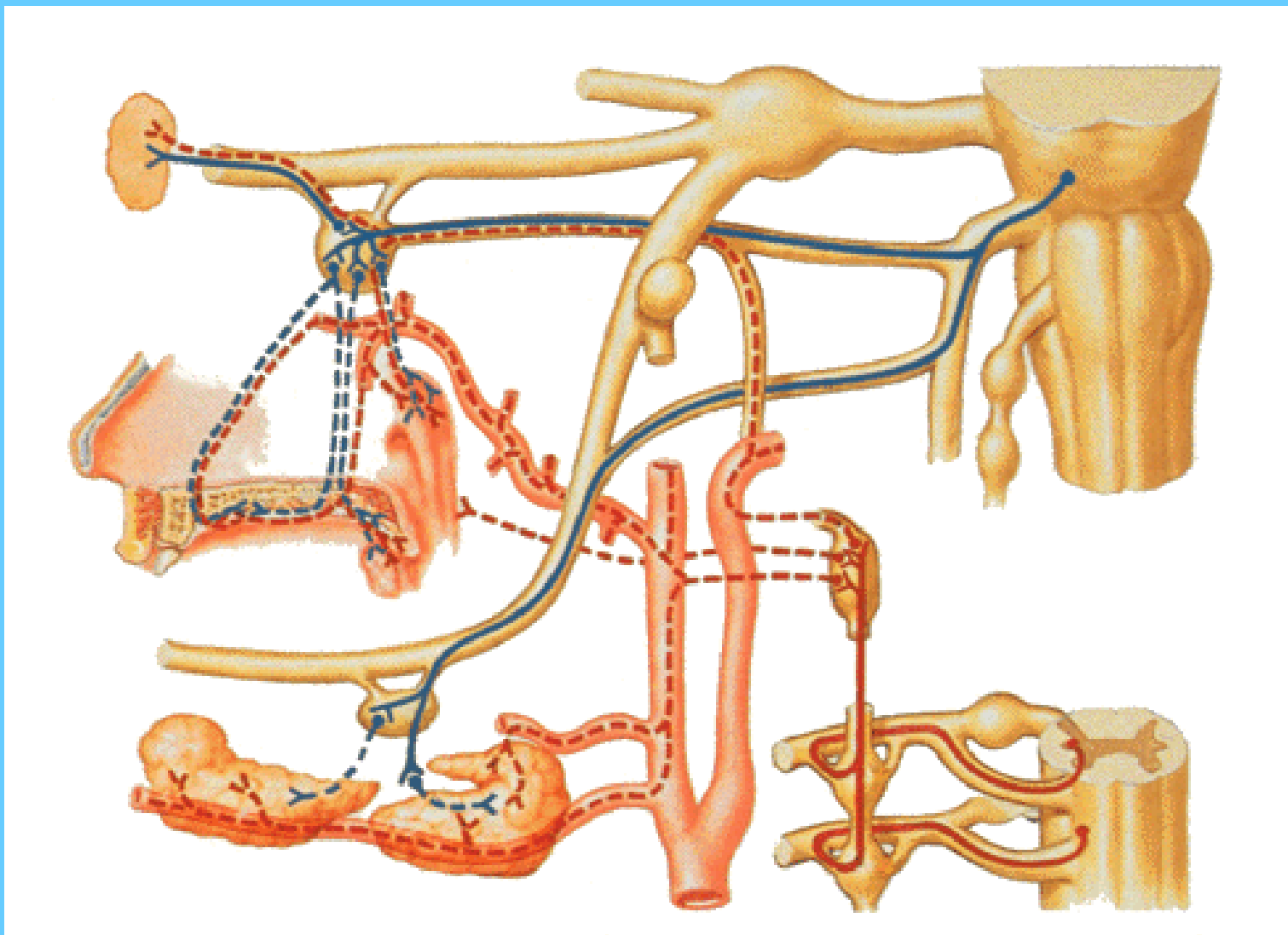


# GANGLION OTICUM ET SUBMANDIBULARE

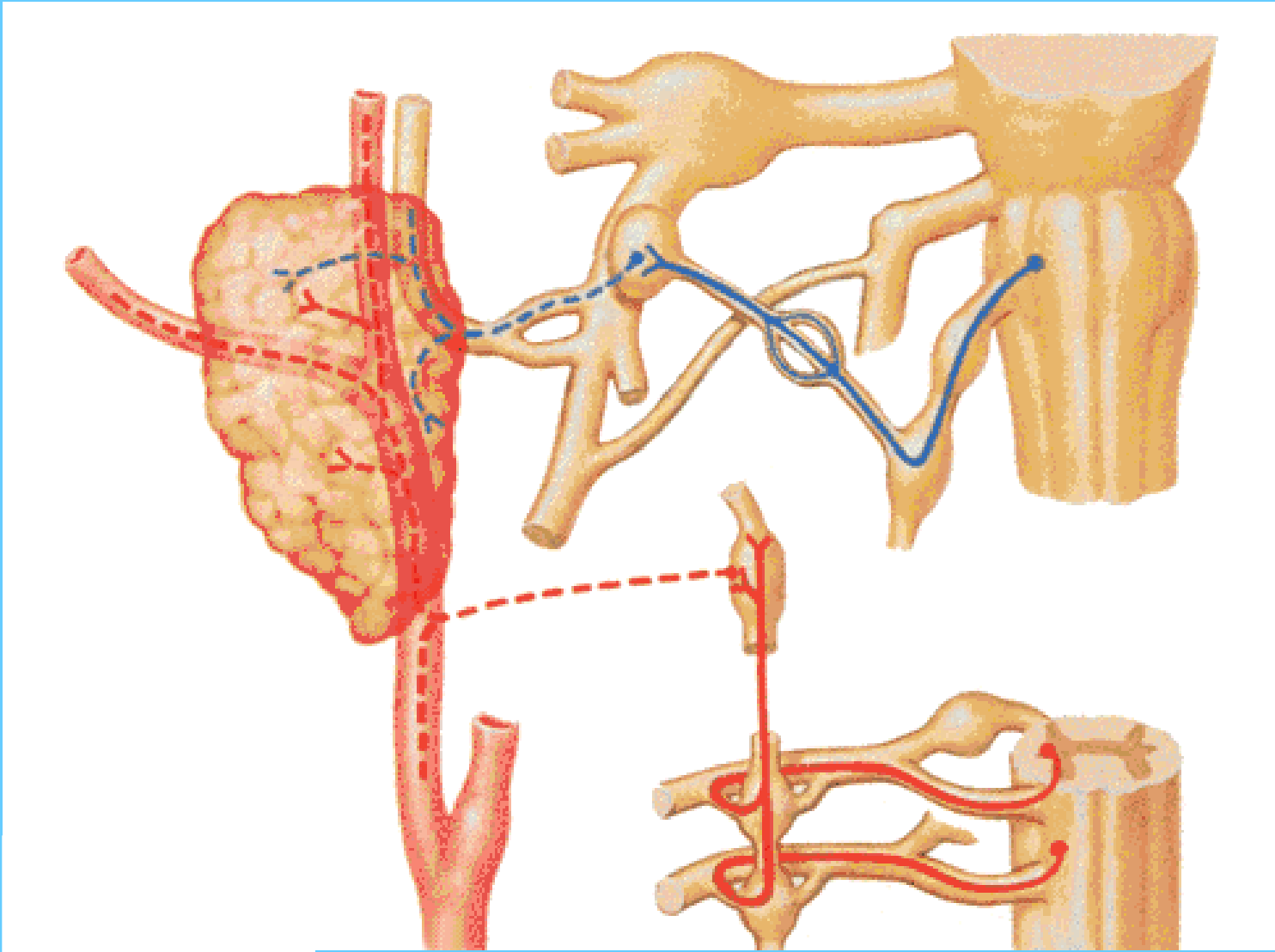


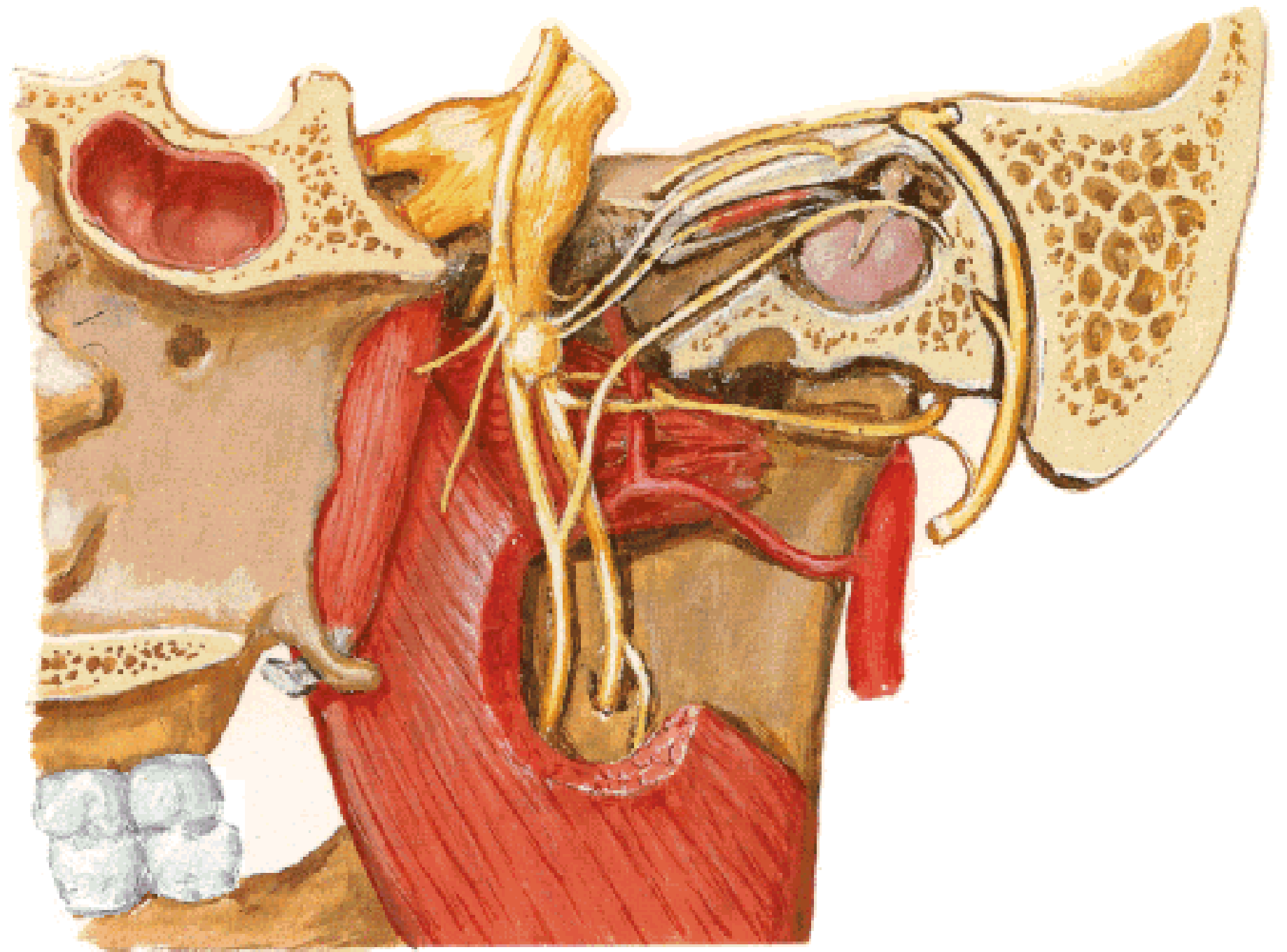


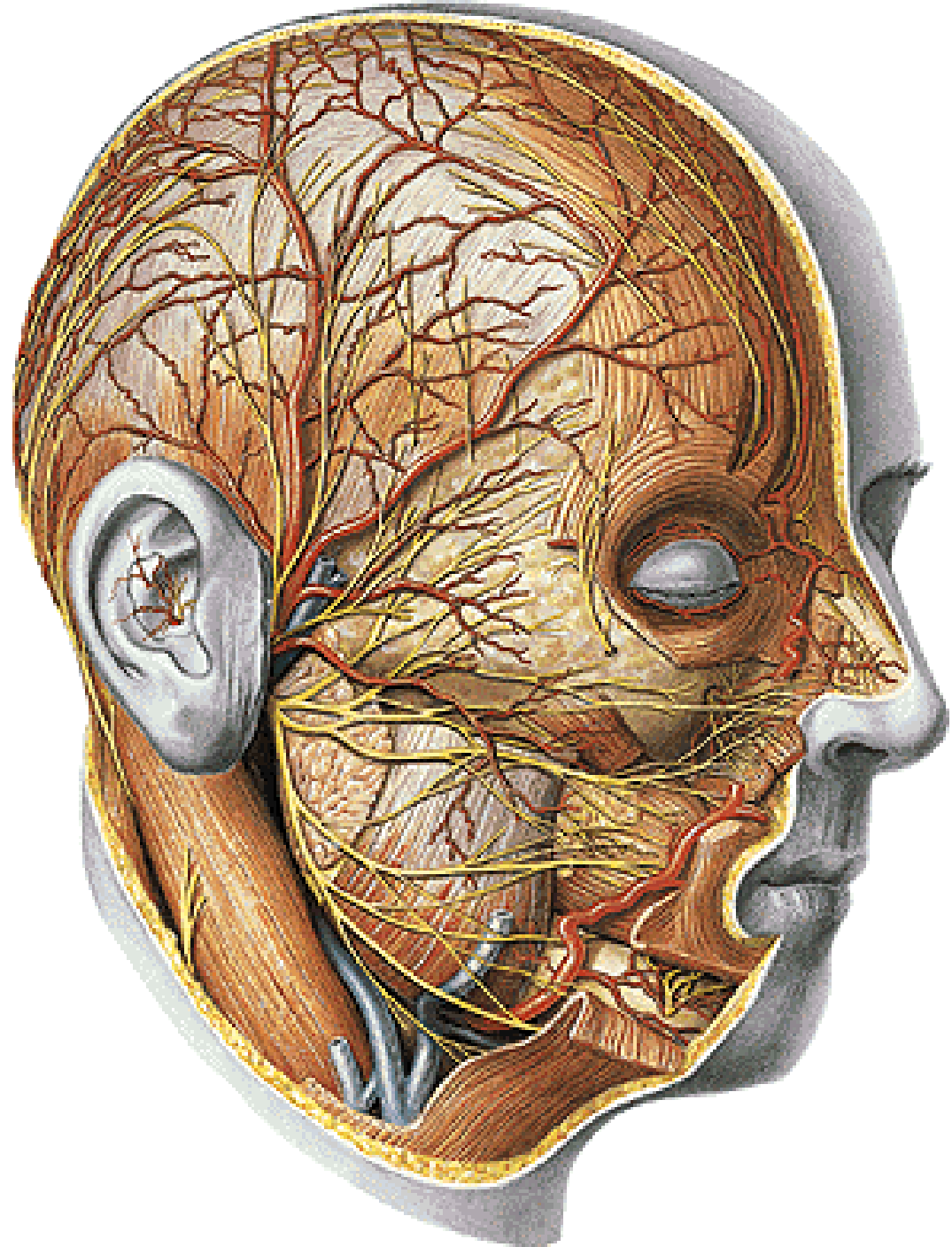
# Ggl. submandibulare



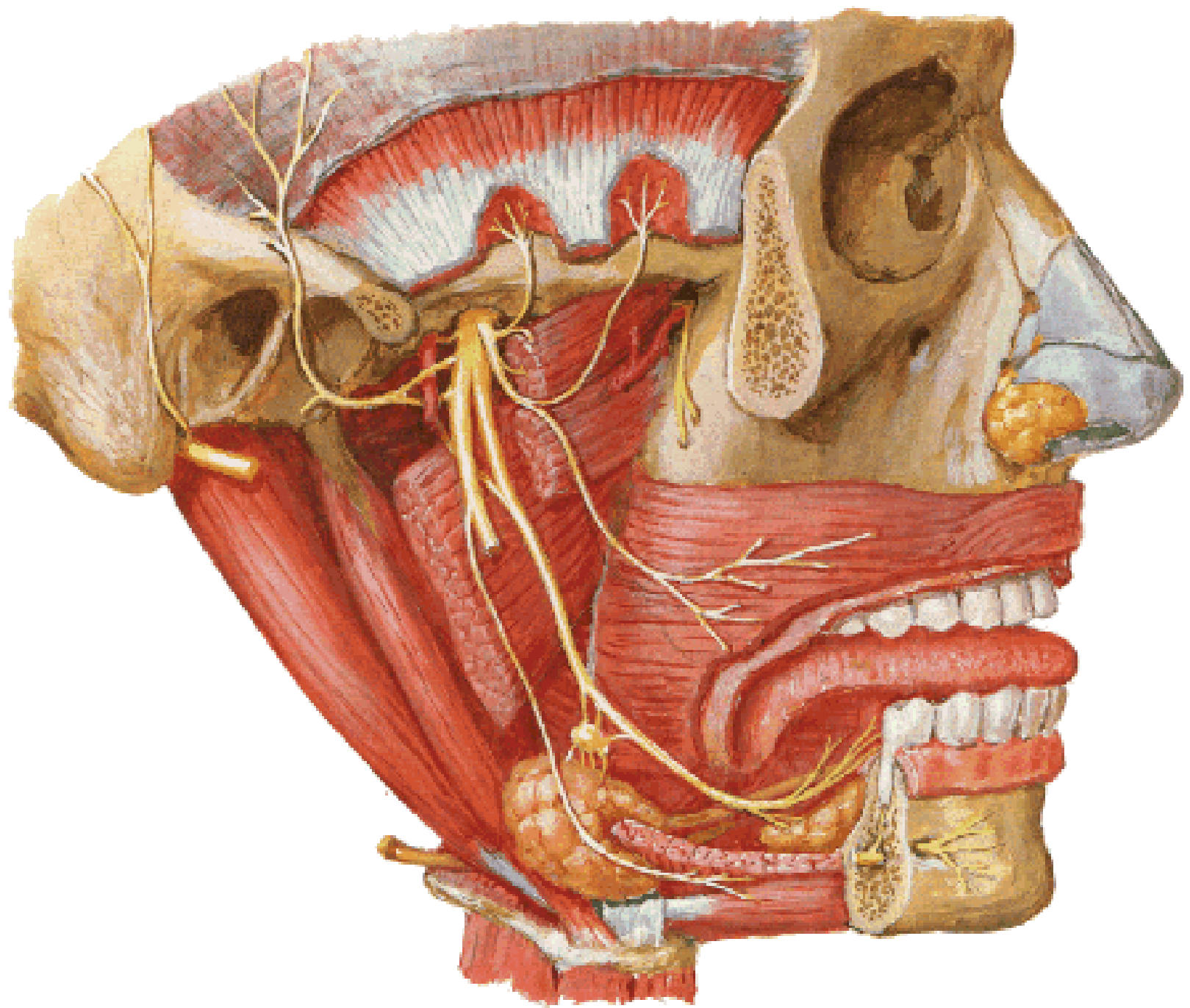
**Ggl. oticum**











- Illustrations were copied from:
- **Atlas der Anatomie des Menschen/  
Sobotta. Putz,R., und Pabst,R. 20.  
Auflage. München: Urban &  
Schwarzenberg, 1993**
- **Netter: Interactive Atlas of Human  
Anatomy. Windows Version 2.0**