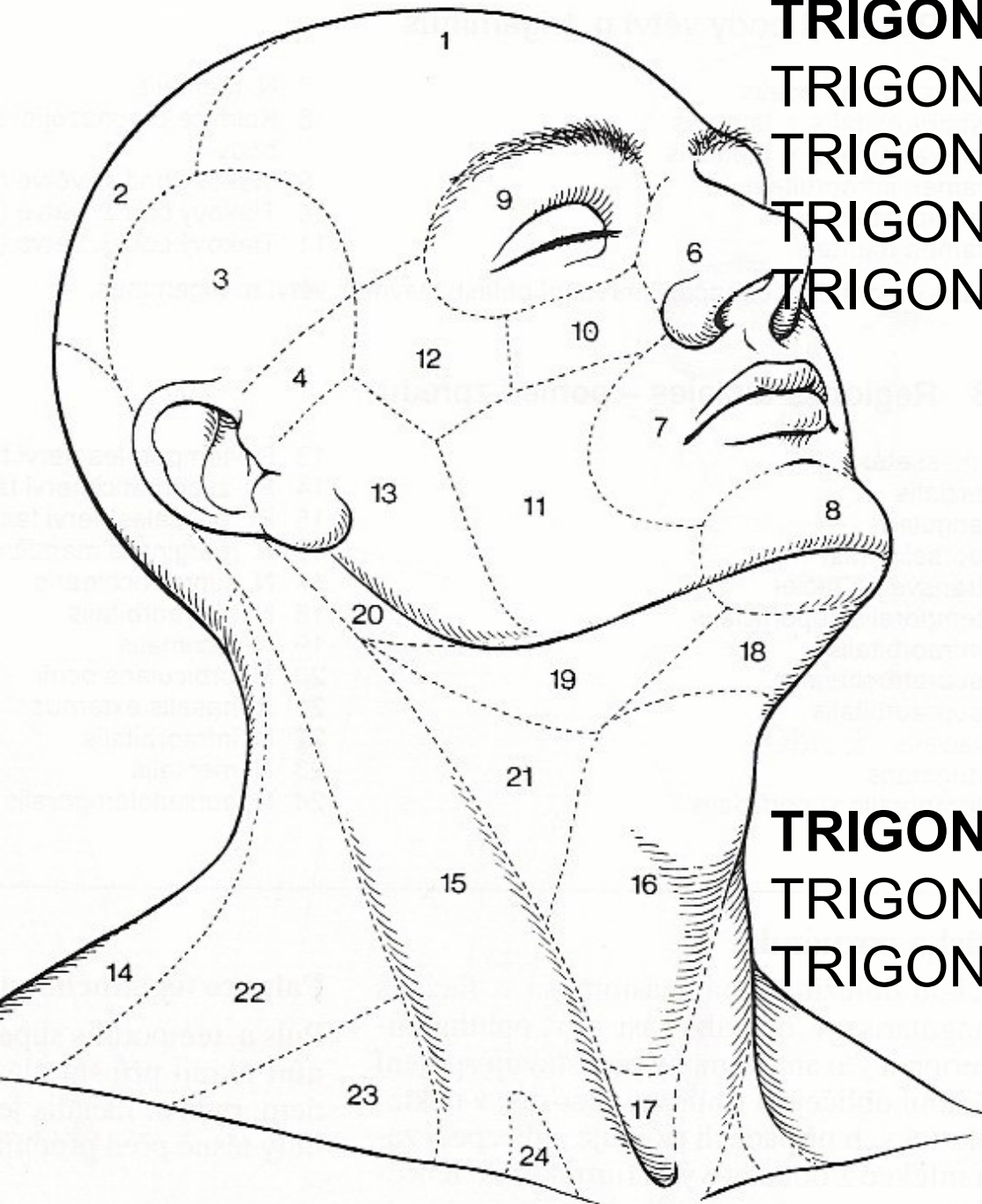
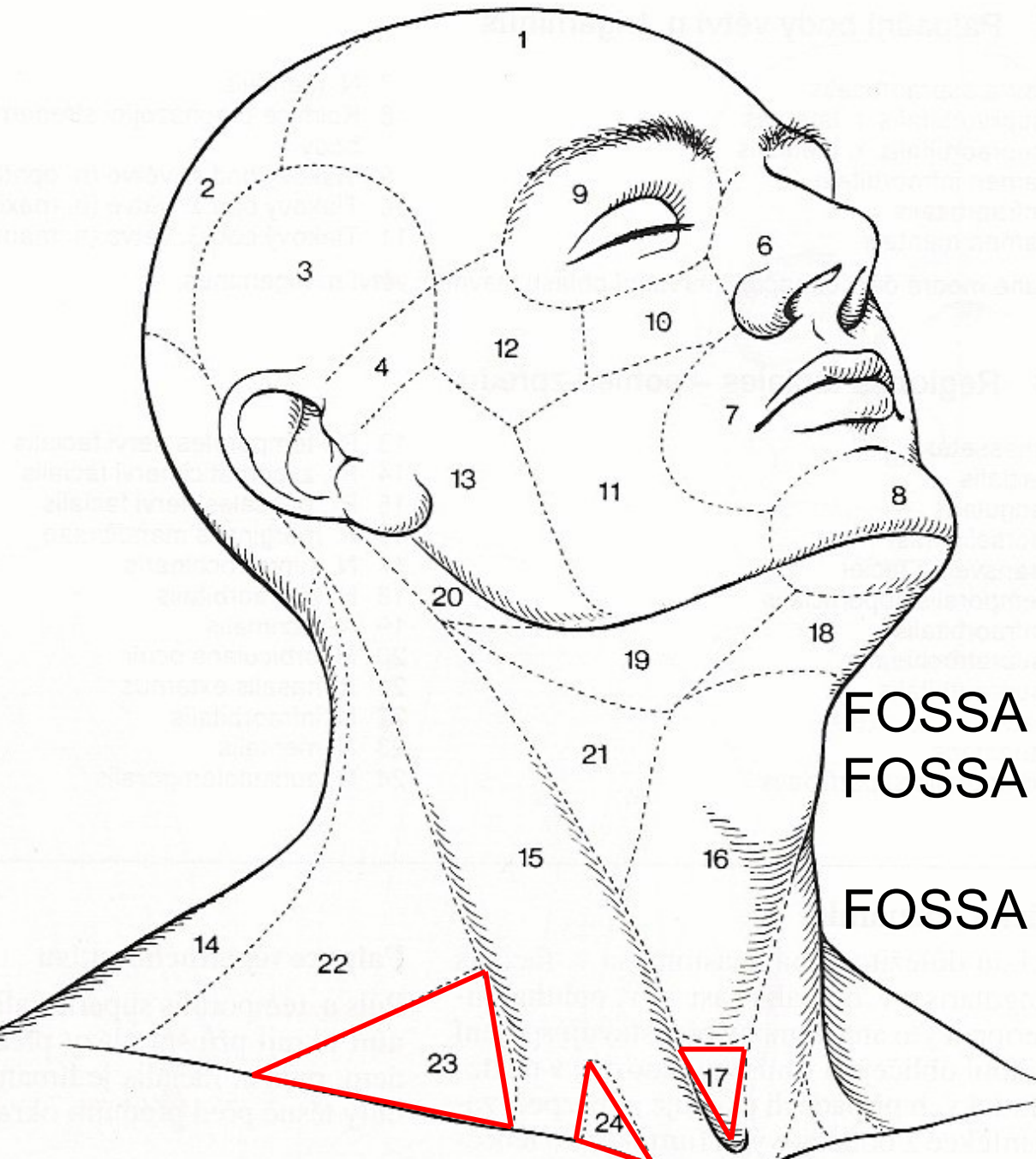


# **REGIONAL ANATOMY OF THE NECK**



**TRIGONUM COLLI MEDIANUM:**  
TRIGONUM SUBMENTALE  
TRIGONUM SUBMANDIBULARE  
TRIGONUM CAROTICUM  
TRIGONUM OMOTRACHEALE  
S. MUSCULARE

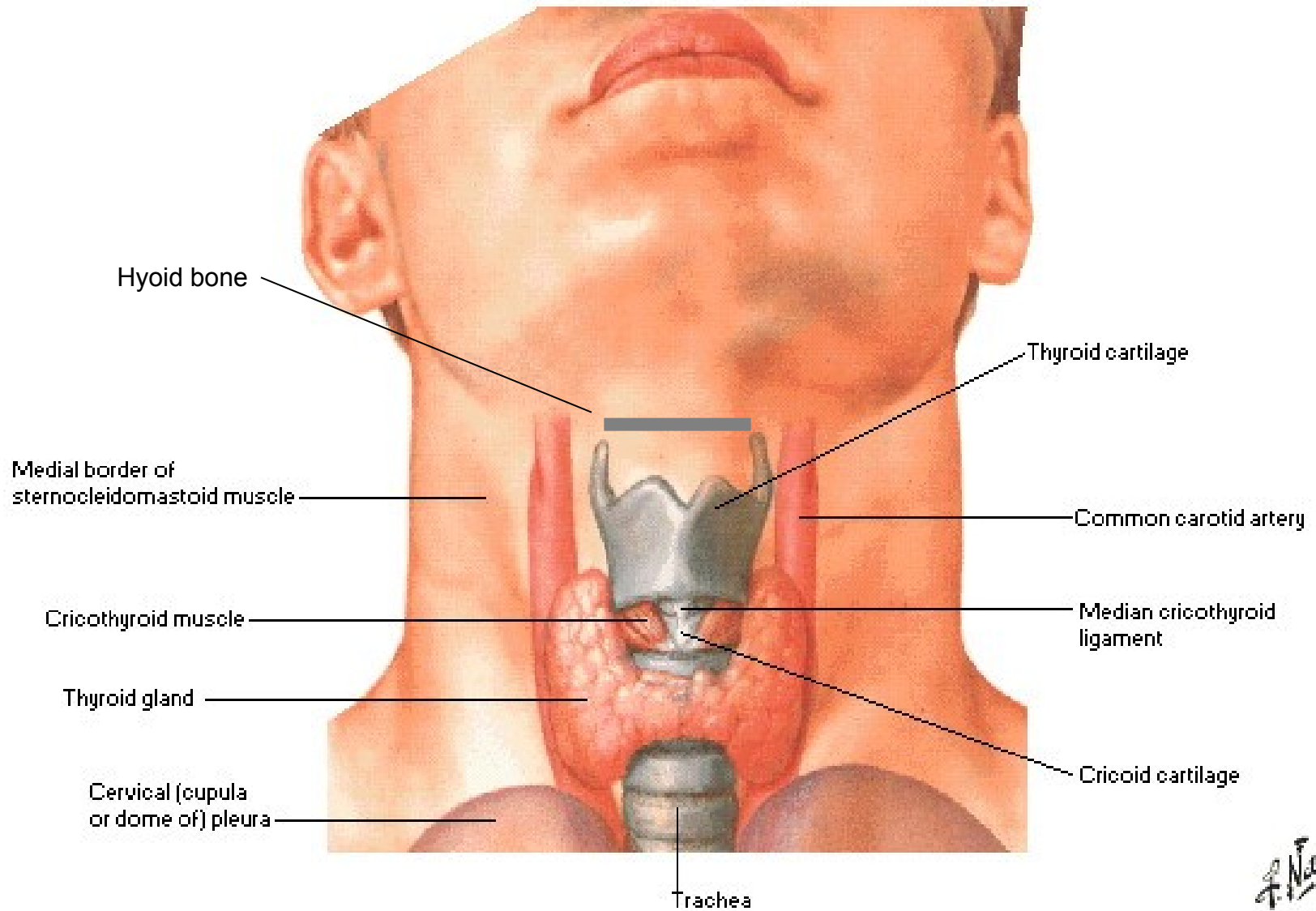
**TRIGONUM COLLI LATERALE:**  
TRIGONUM OMOCLAVICULARE  
TRIGONUM OMOTRAPEZOIDEUM



FOSSA JUGULARIS  
FOSSA SUPRACLAVICULARIS  
MINOR  
FOSSA SUPRACLAVICULARIS  
MAJOR

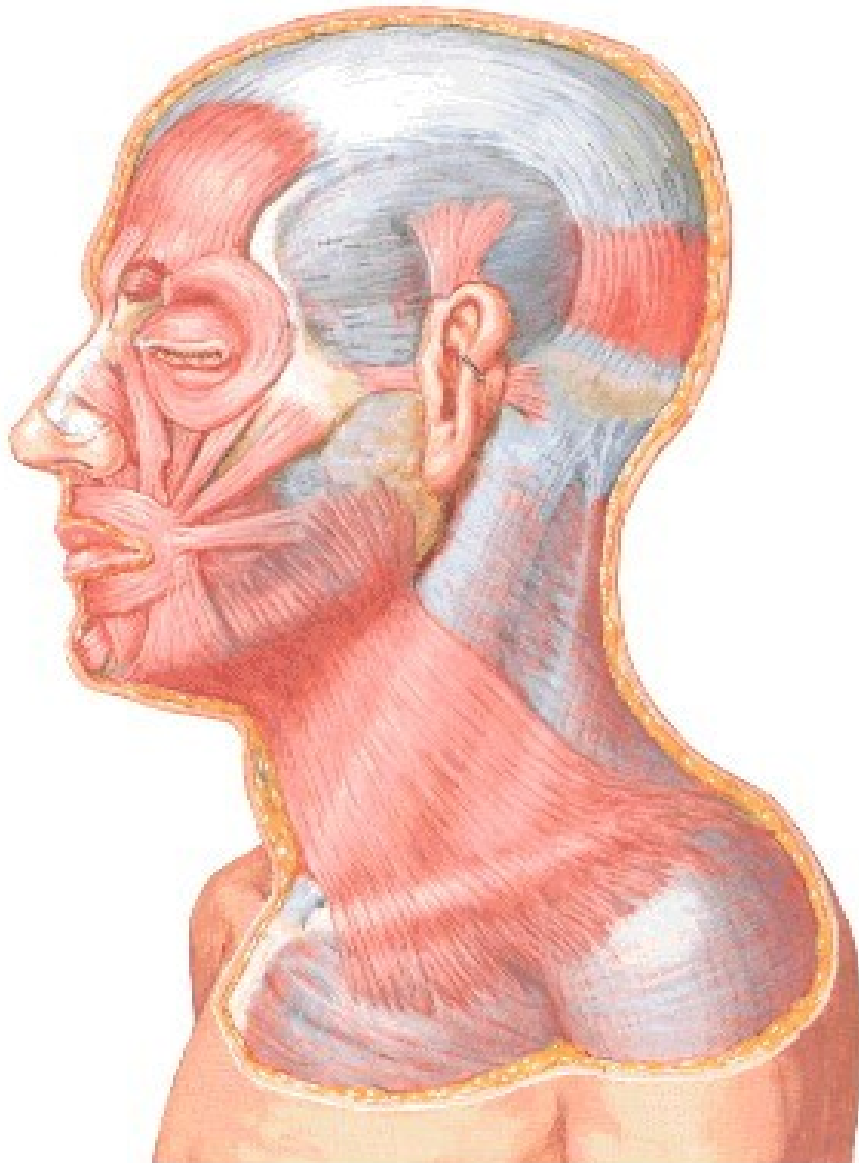
# Thyroid Gland in Situ

## Anterior View



# Muscles of Facial Expression

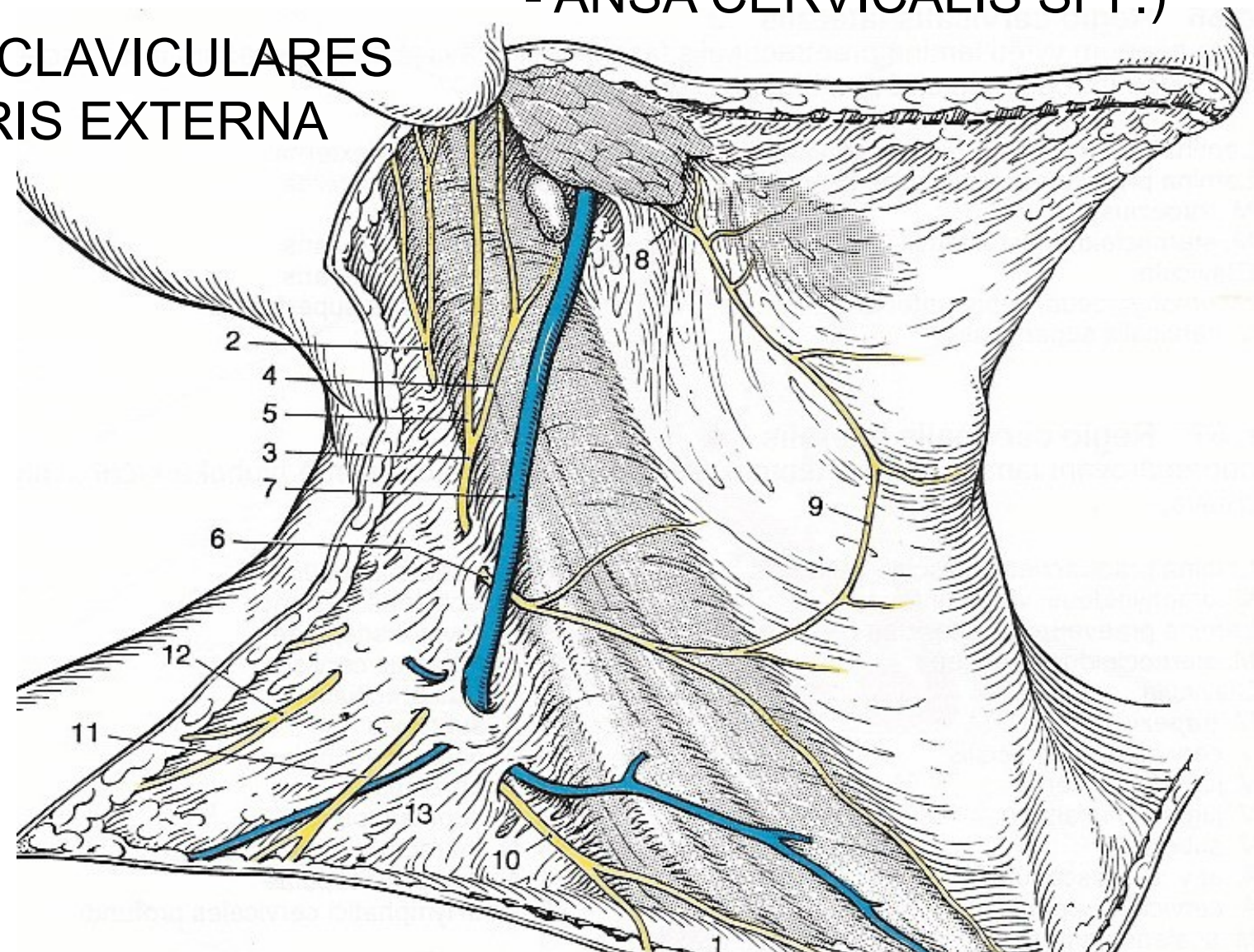
Lateral View



M. PLATYSMA

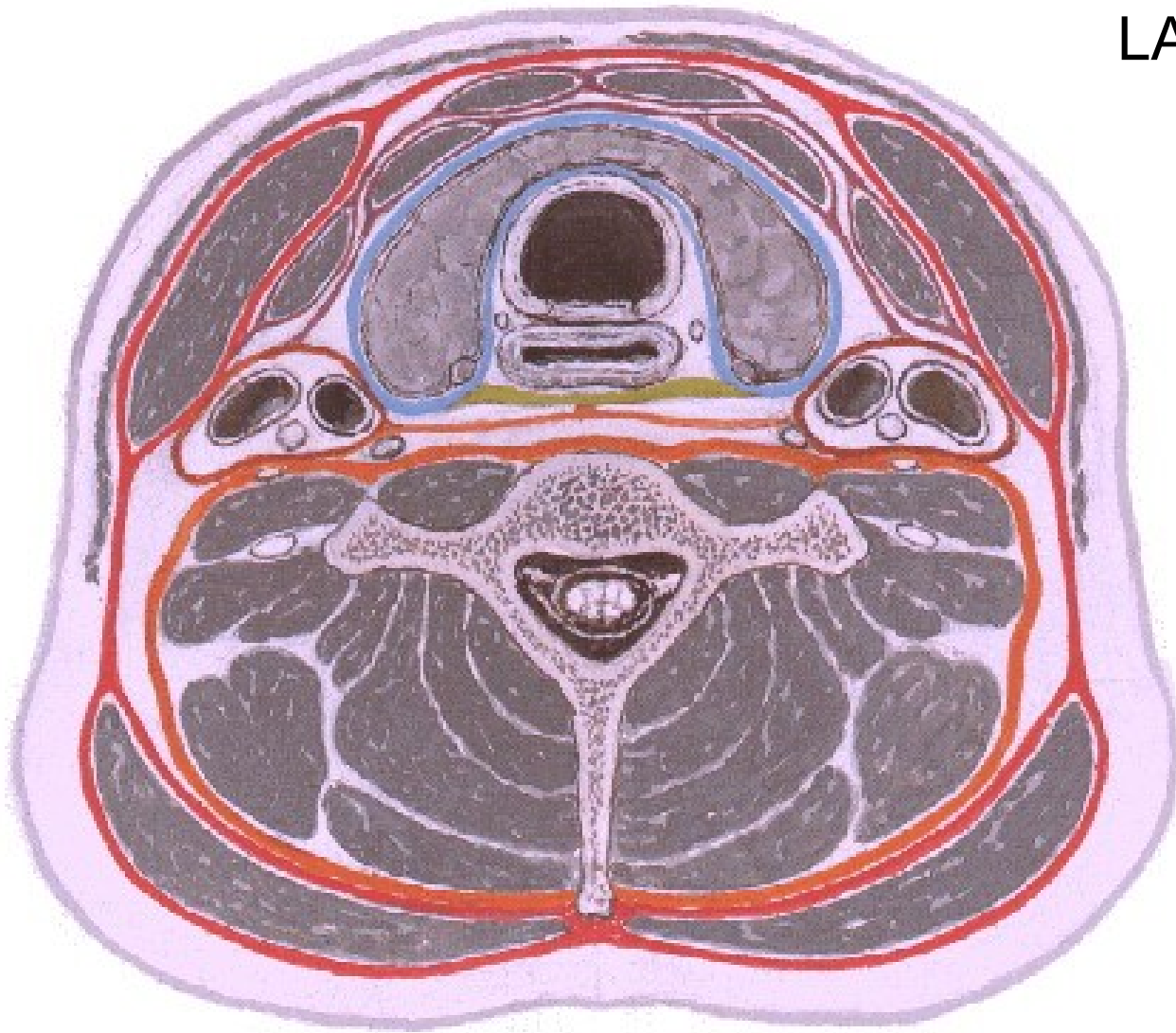
N. OCCIPITALIS MINOR  
N. AURICULARIS MAGNUS  
N. TRANSVERSUS COLLI (R. COLLI N. FACIALIS  
- ANSA CERVICALIS SPF.)

NN. SUPRACLAVICULARES  
V. JUGULARIS EXTERNA



# Fascial Layers of Neck

Cross Section



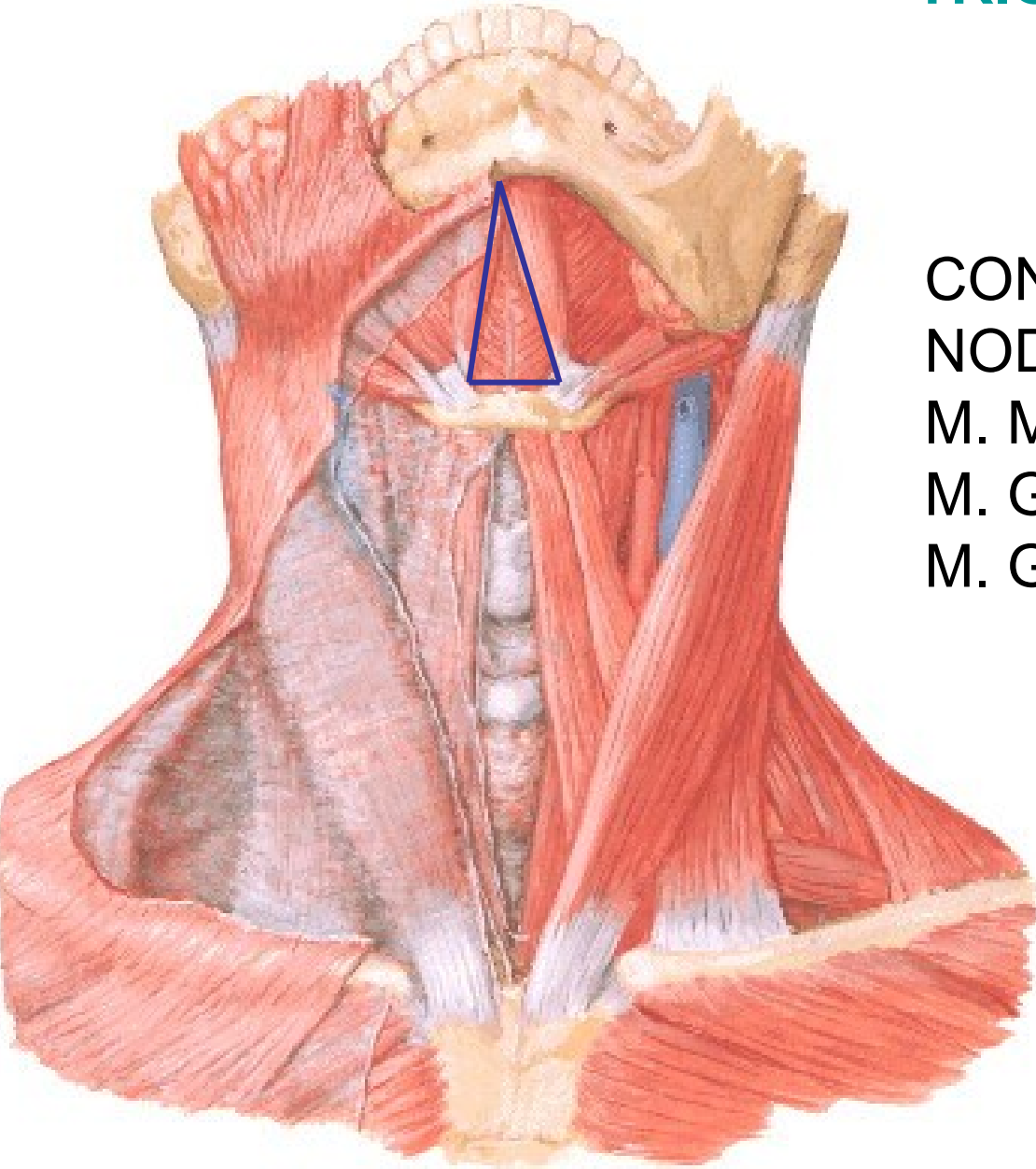
FASCIA COLLI:

LAMINA

- SUPERFICIALIS
- PRAETRACHEALIS
- PRAEVERTEBRALIS
- VAGINA CAROTICA

Anterior View

## TRIGONUM SUBMENTALE



CONTENTS:

NODI LYMPH. SUBMENTALES

M. MYLOHYOIDEUS

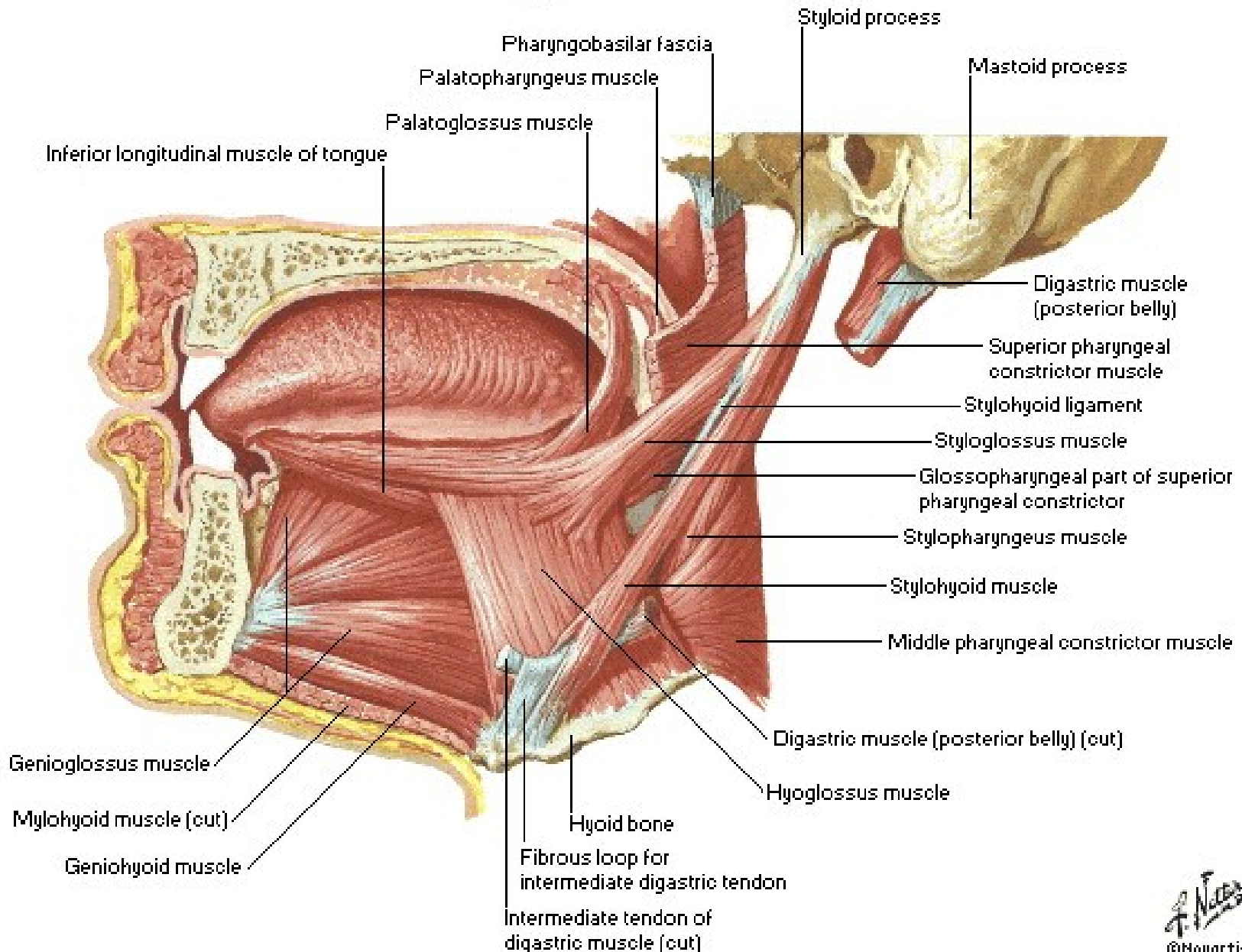
M. GENIOHYOIDEUS

M. GENIOGLOSSUS



# Muscles of Tongue

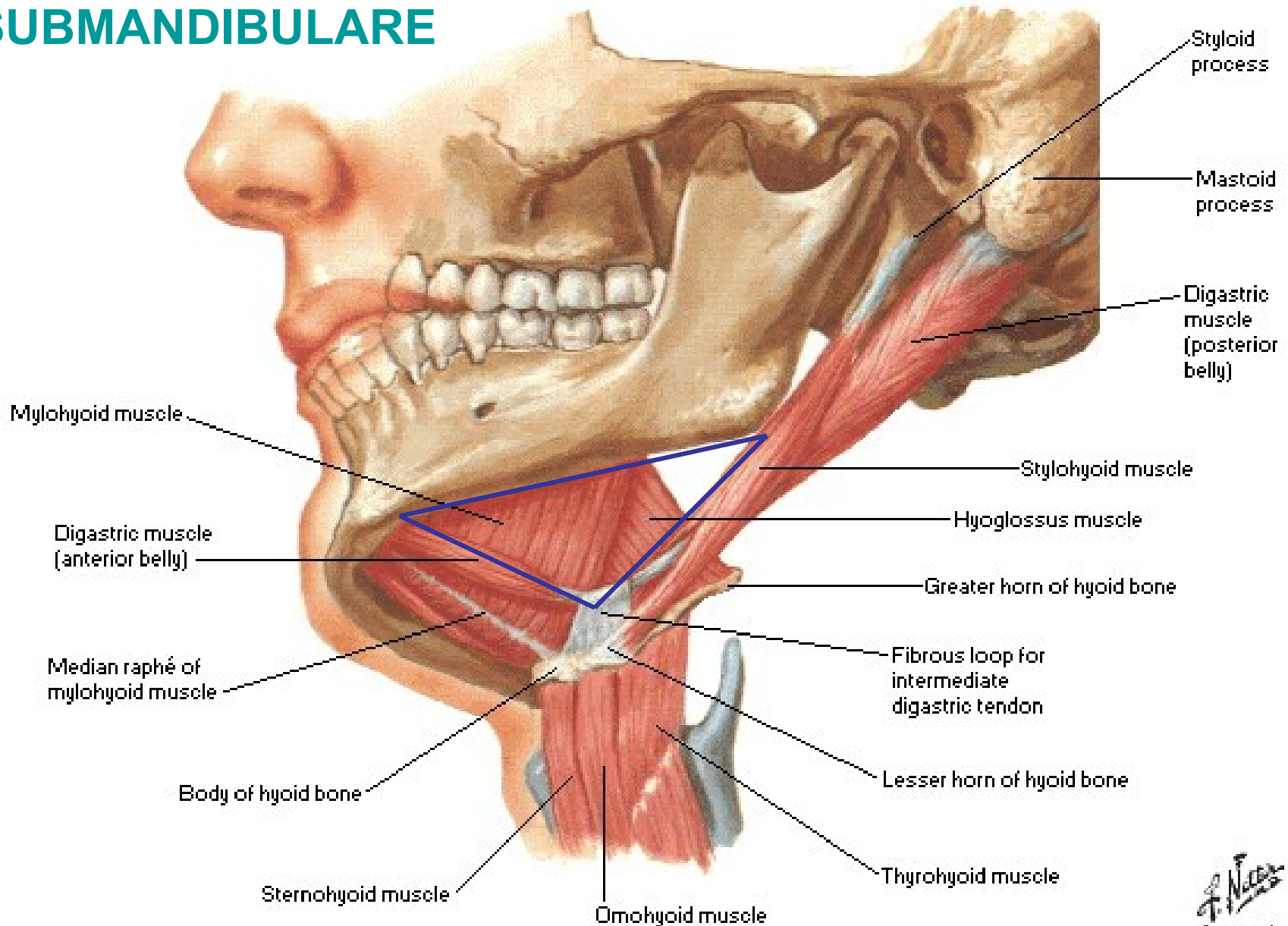
## Sagittal Section

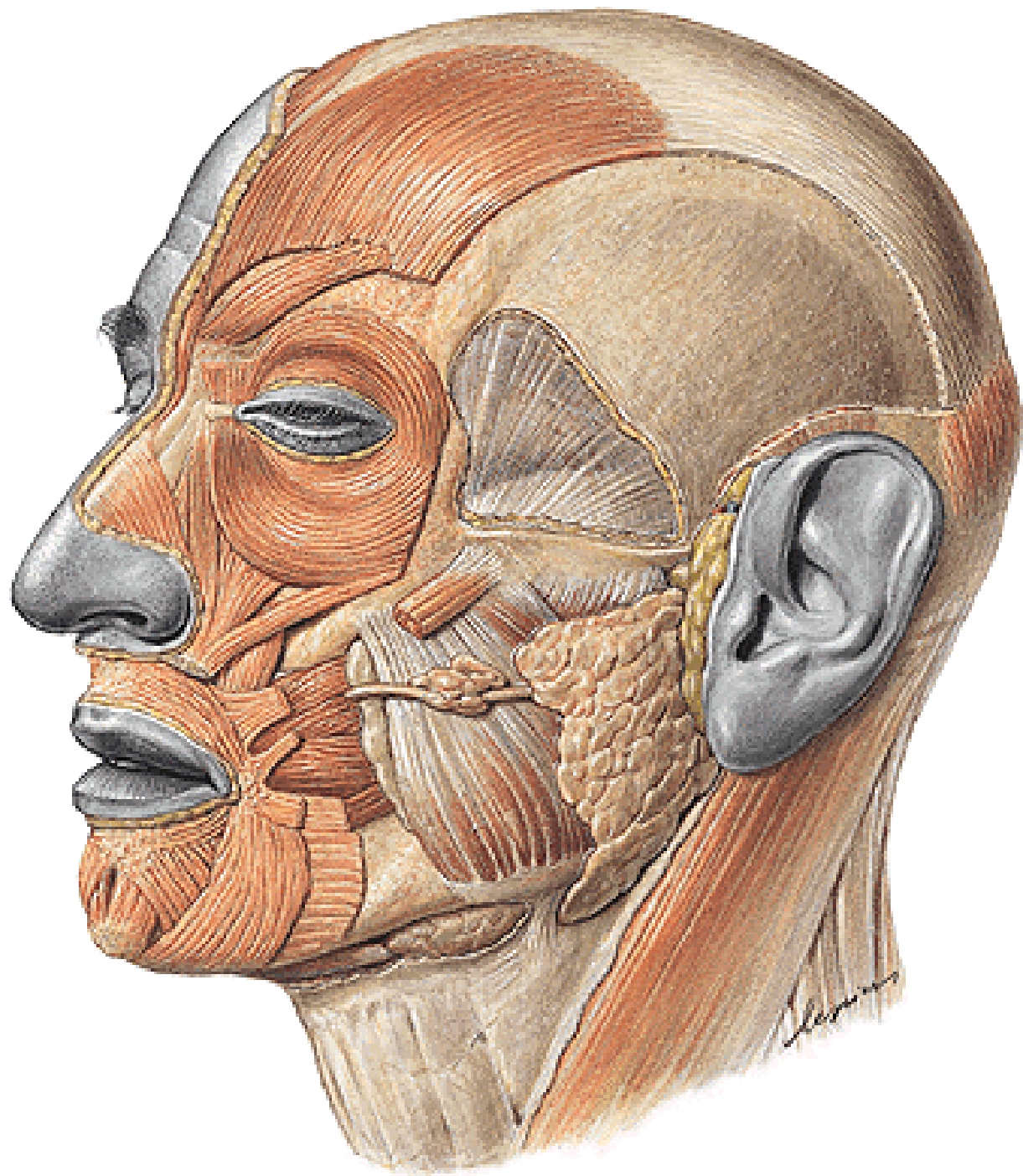


# Floor of Mouth - Musculature

Lateral, Slightly Inferior View

## TRIGONUM SUBMANDIBULARE

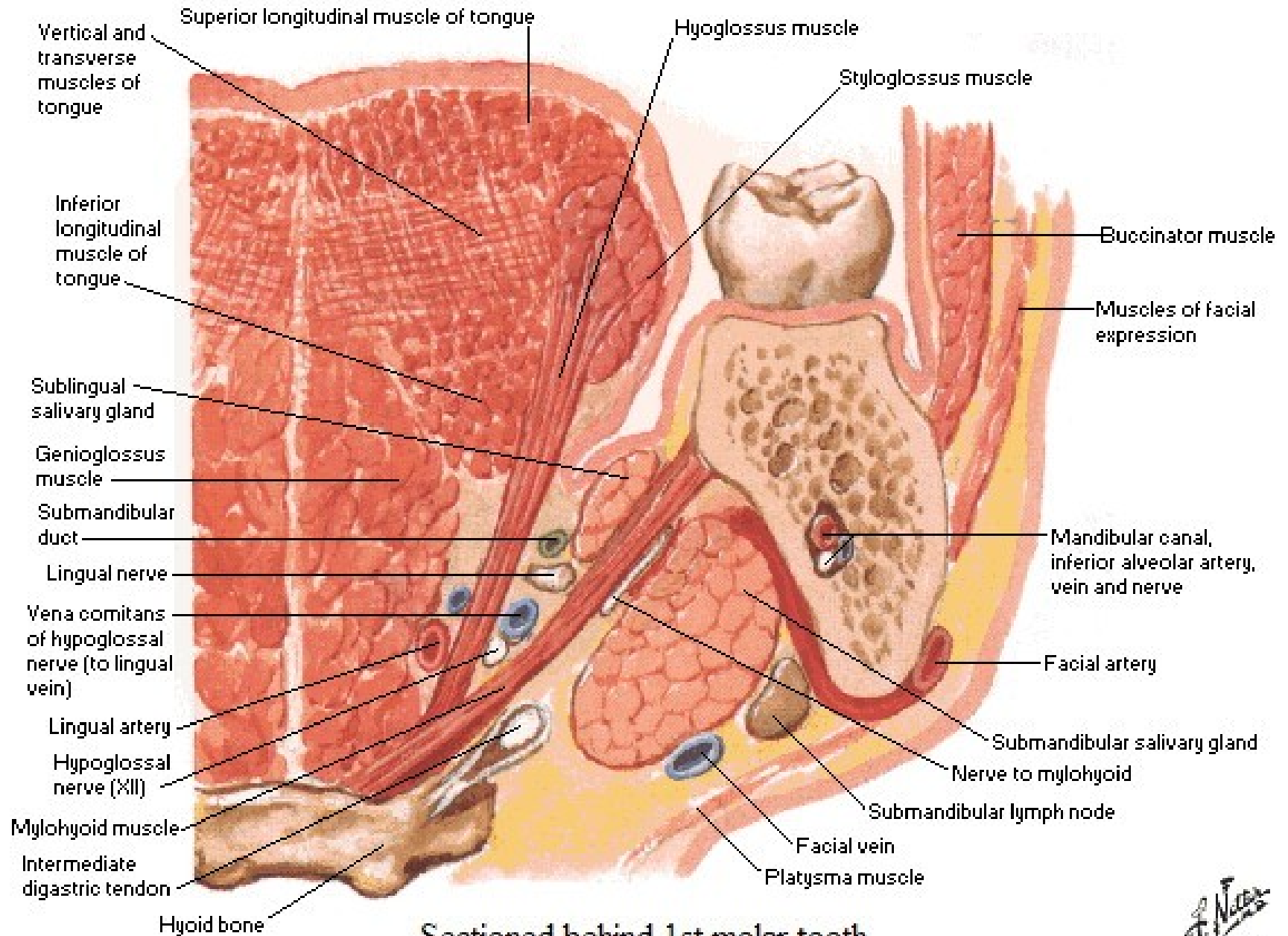




TRACTUS  
ANGULARIS

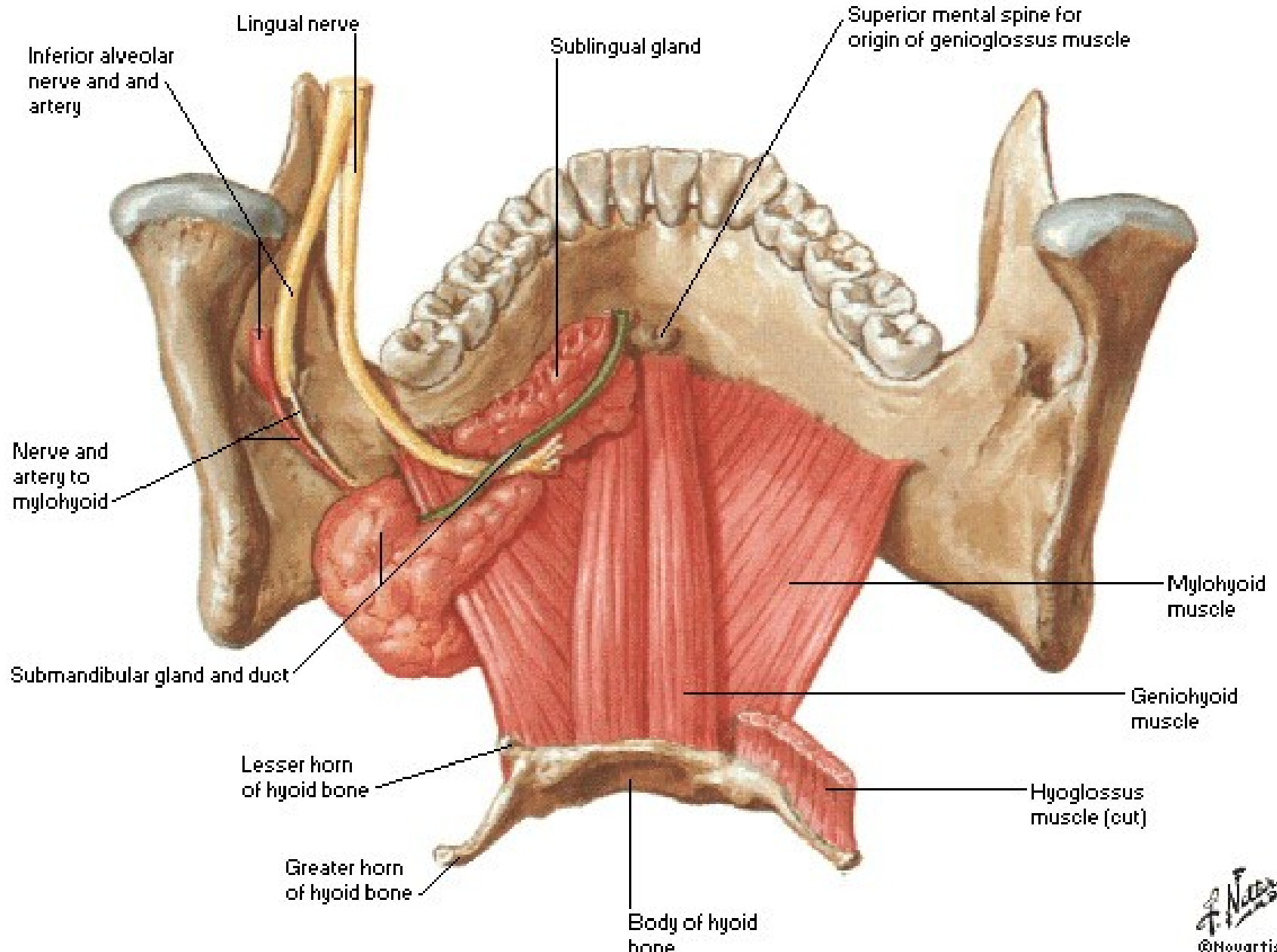
# Tongue and Mouth

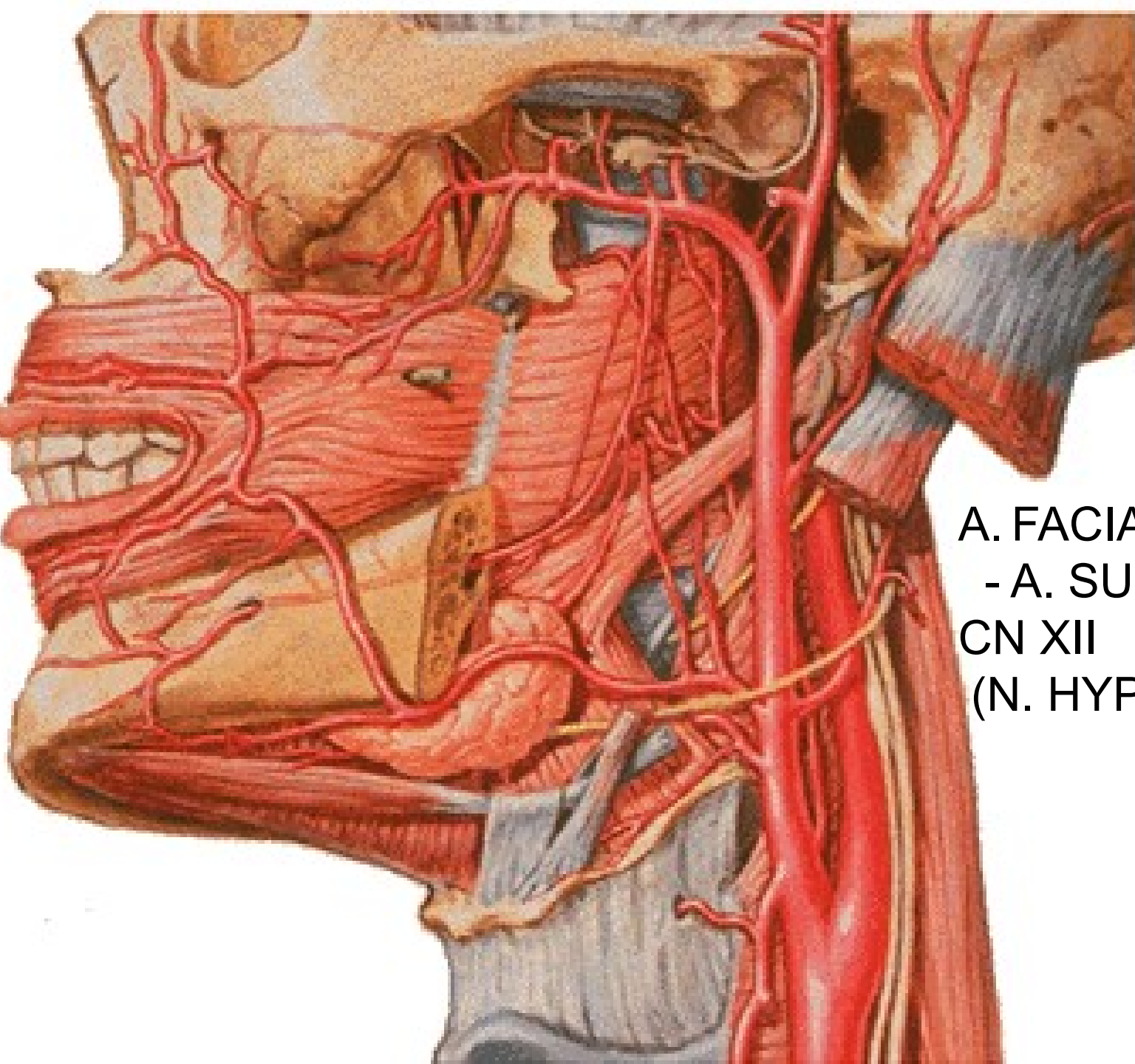
## Frontal Section - Anterior View



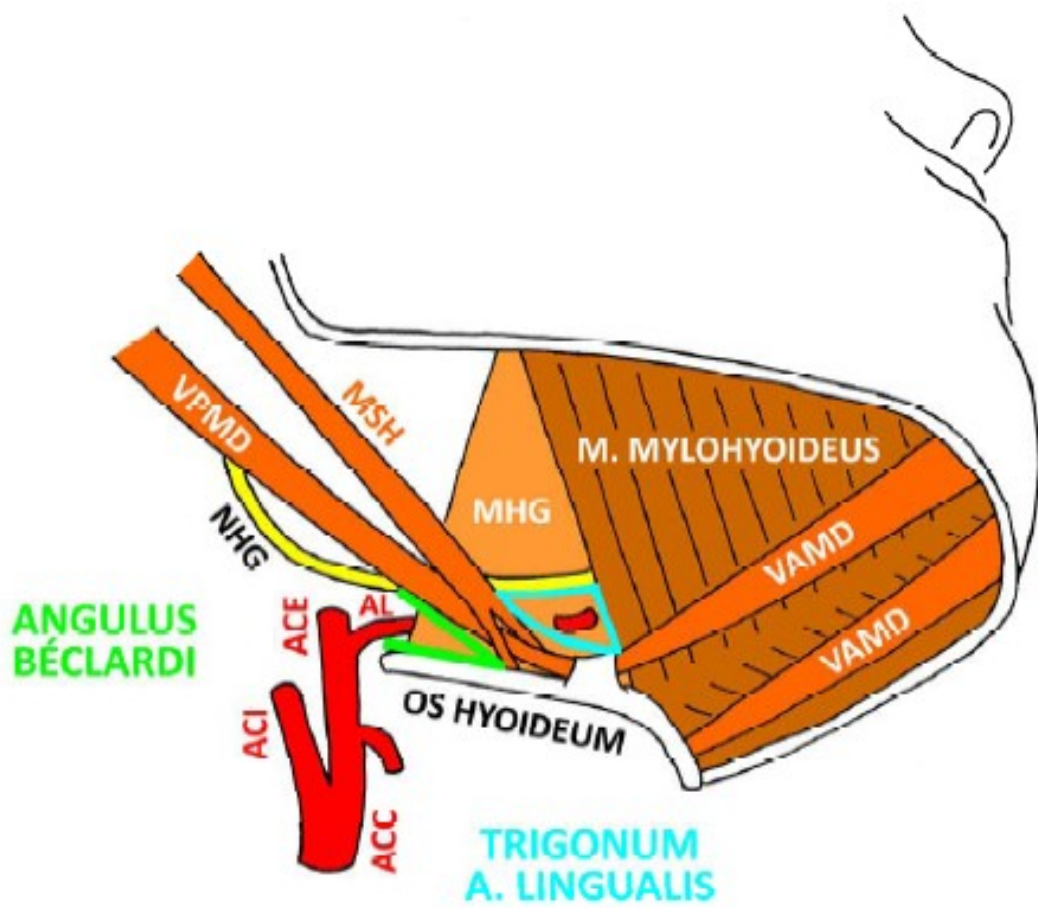
# Floor of Mouth - Musculature

## Posterosuperior View



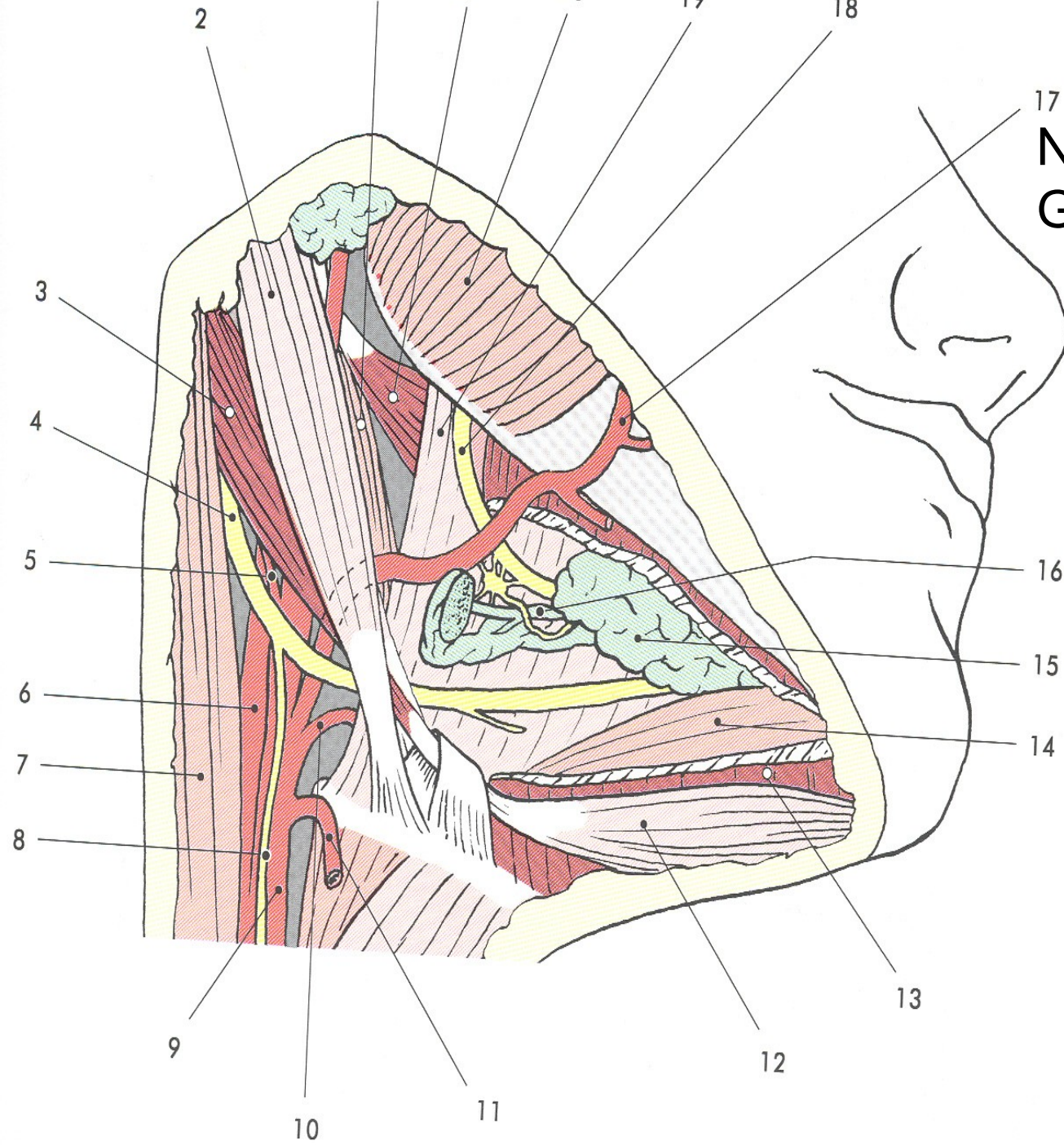


A. FACIALIS  
- A. SUBMENTALIS  
CN XII  
(N. HYPOGLOSSUS)

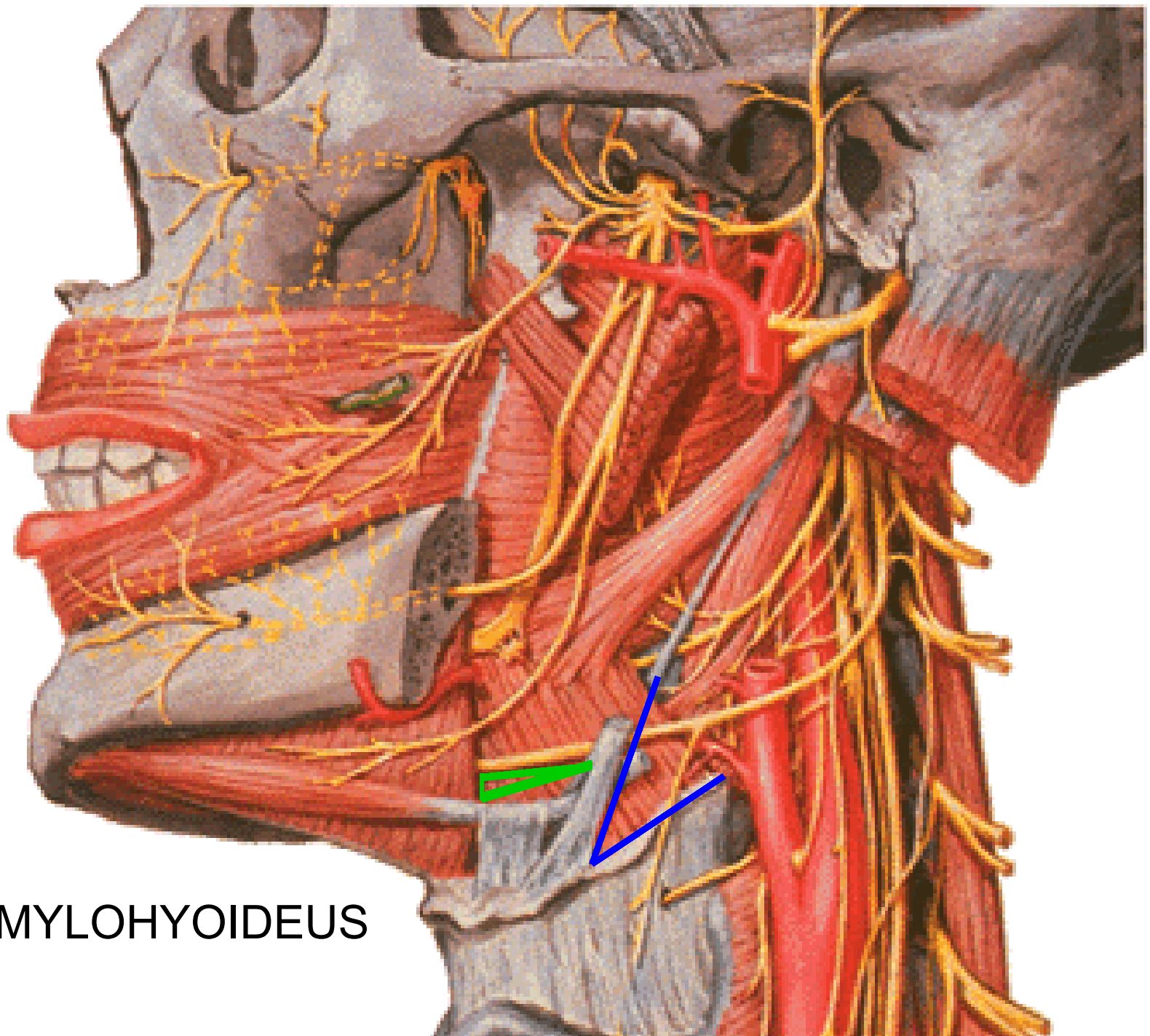


- VPMD - VENTER POST. M. DIGASTRICI
- NHG - N. HYPOGLOSSUS
- MSH - M. STYLOHYOIDEUS
- MHG - M. HYOGLOSSUS
- ACE - A. CAROTIS EXTERNA
- AL - A. LINGUALIS
- ACI - A. CAROTIS INTERNA
- ACC - A. CAROTIS COMMUNIS
- VAMD - VENTER ANT. M. DIGASTRICI

17  
**N. LINGUALIS**  
**GANGLION**  
**SUBMANDIBULARE**

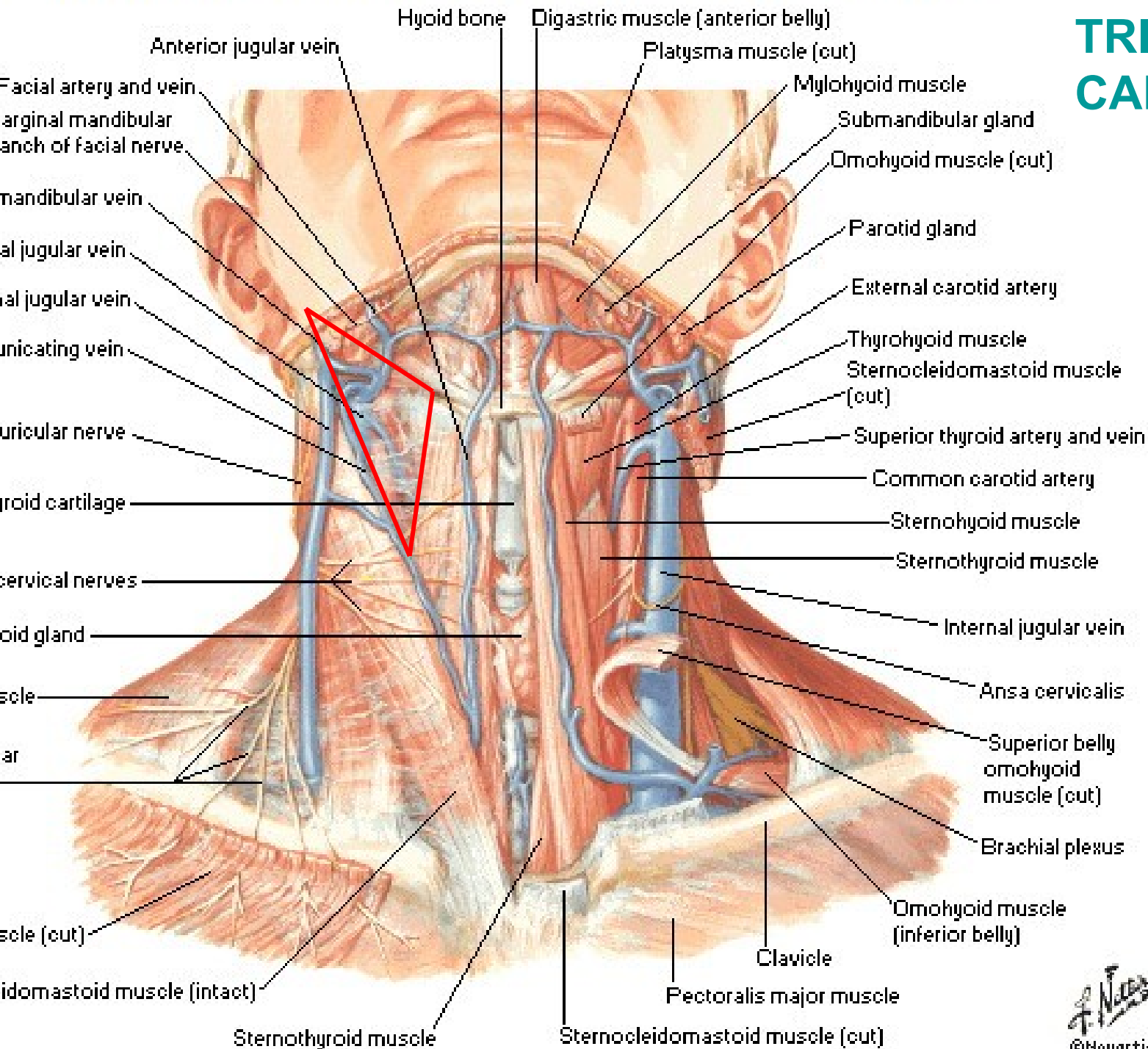


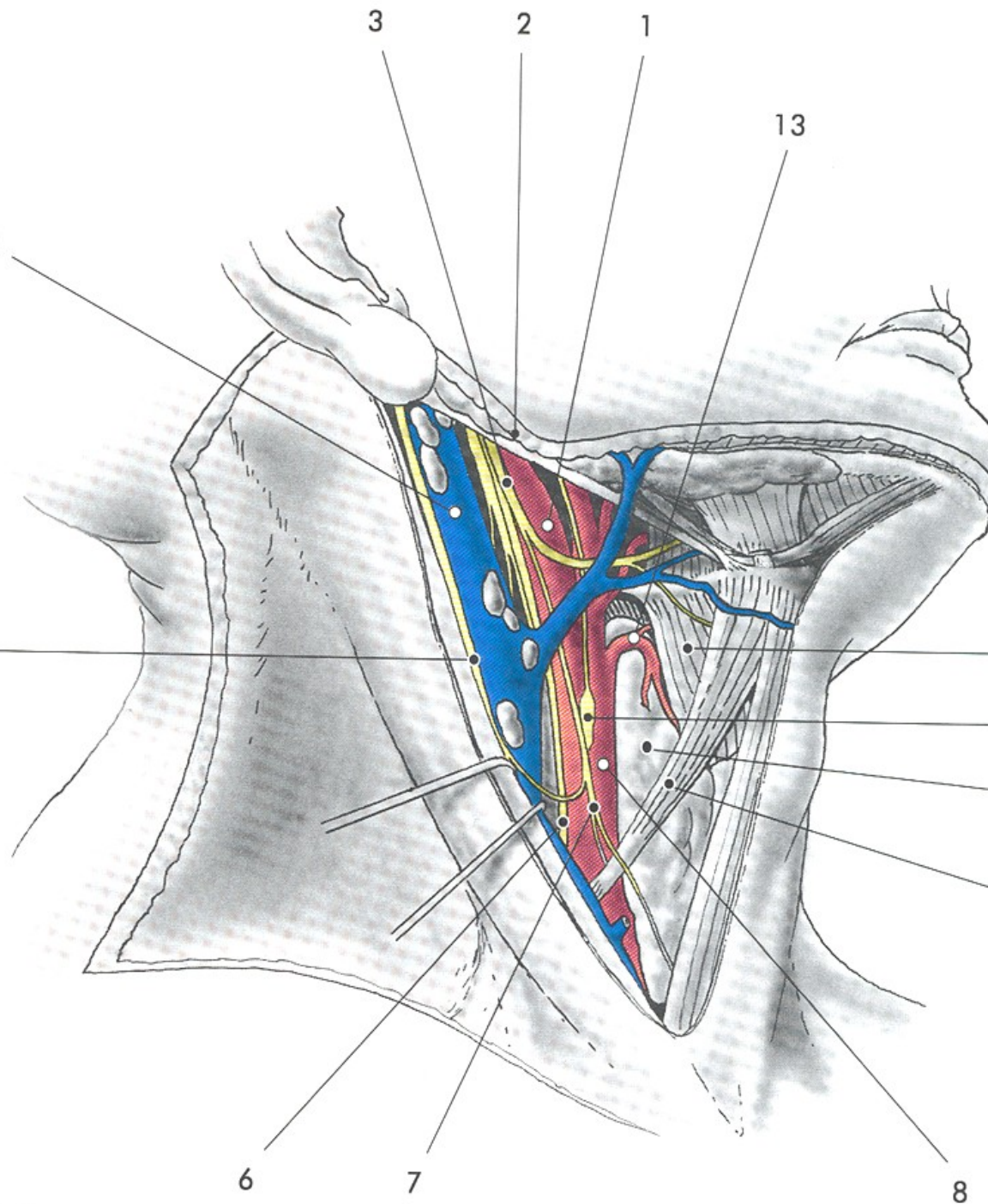




N. MYLOHYOIDEUS

# TRIGONUM CAROTICUM

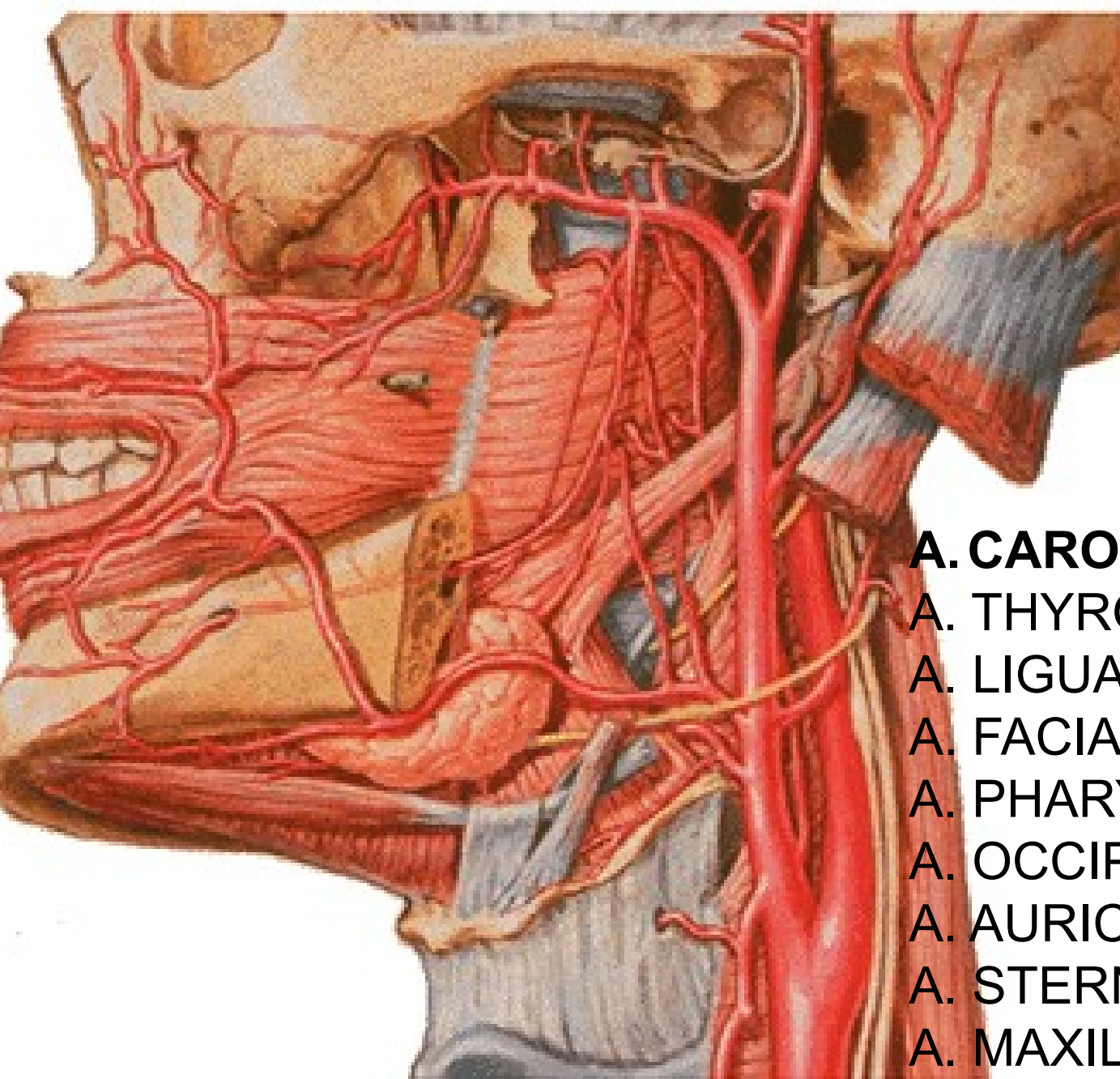




**CONTENTS:**  
**V. FACIALIS**  
**V. JUGULARIS INT.**  
**NL. CERVICALES PROF.**  
**A. CAROTIS COMM.-**  
**EXT.+INT.**  
**N. VAGUS**  
**N. HYPOGLOSSUS**  
**GLOMUS CAROTICUM**  
**SINUS CAROTICUS**

12  
 11  
 10  
 9

6  
 7  
 8



**A. CAROTIS EXT:**

A. THYROIDEA SUP.

A. LIGUALIS

A. FACIALIS

A. PHARYNGEA ASC.

A. OCCIPITALIS

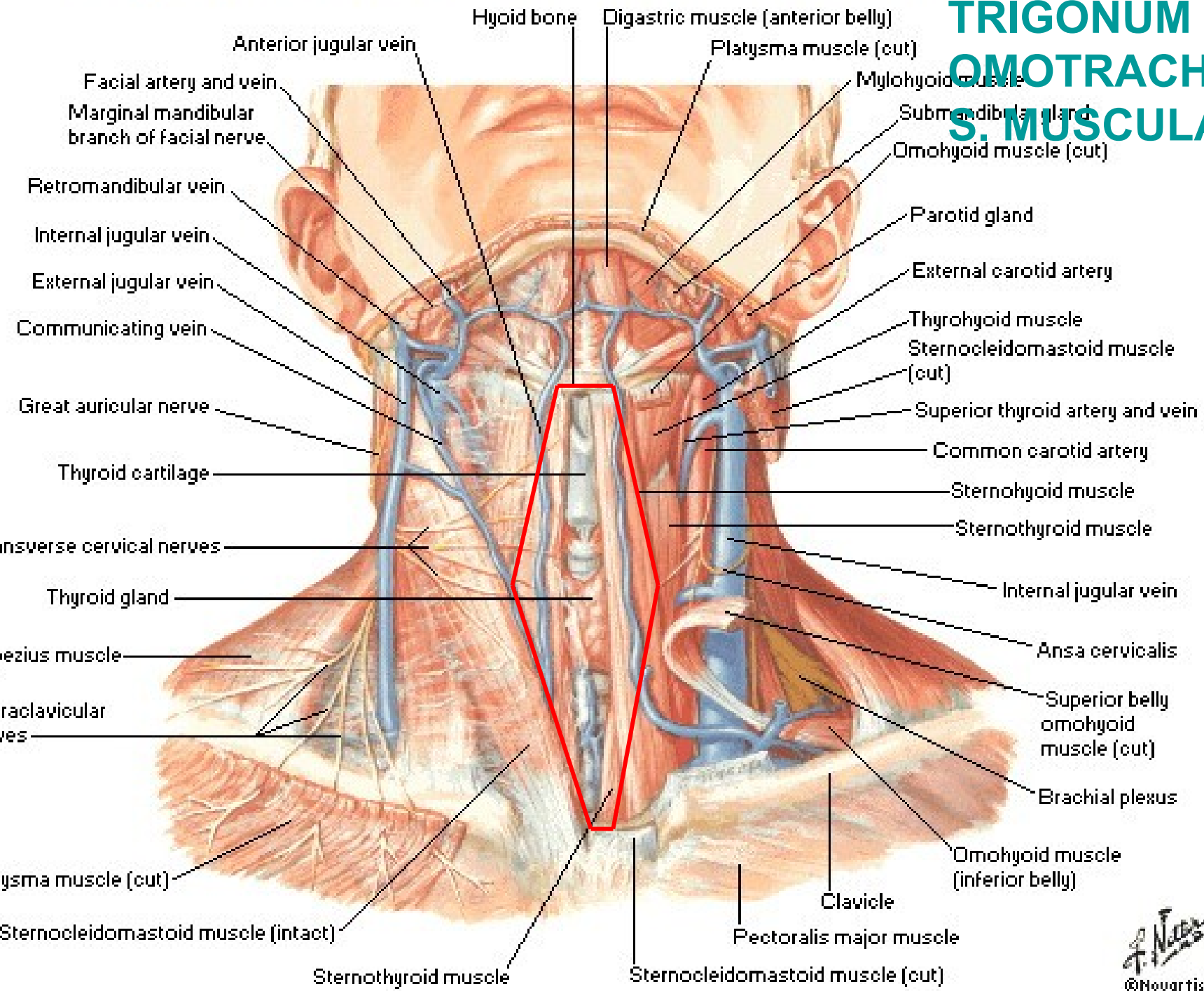
A. AURICULARIS POST.

A. STERNOCLEIDOMAST.

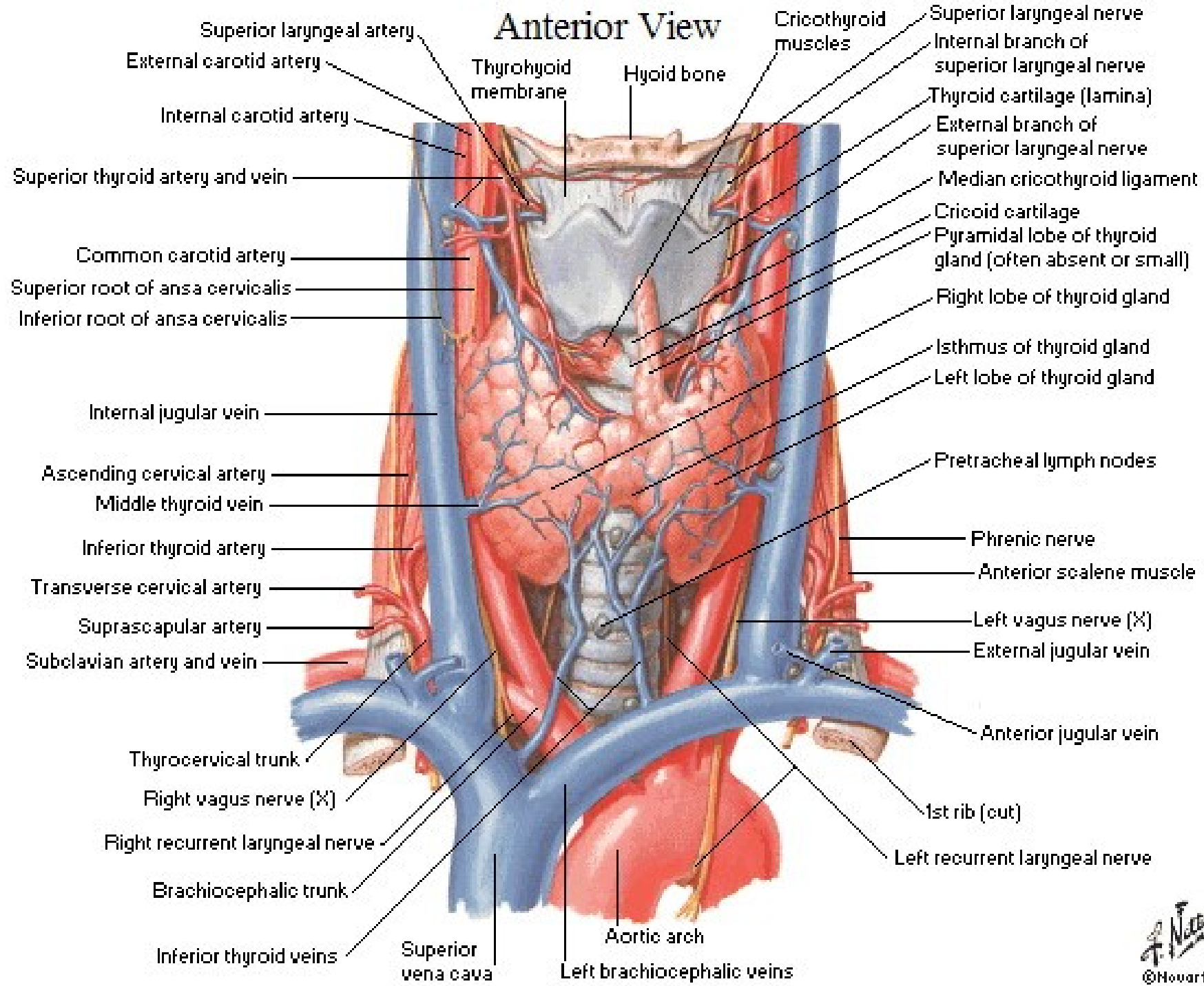
A. MAXILLARIS

A. TEMPORALIS SPF.

# TRIGONUM OMOTRACHEALE S. MUSCULARE



# Anterior View



Superior laryngeal artery  
 External carotid artery  
 Internal carotid artery

Thyroid membrane  
 Hyoid bone

Cricothyroid muscles

Superior laryngeal nerve  
 Internal branch of superior laryngeal nerve  
 Thyroid cartilage (lamina)  
 External branch of superior laryngeal nerve  
 Median cricothyroid ligament

Superior thyroid artery and vein  
 Common carotid artery  
 Superior root of ansa cervicalis  
 Inferior root of ansa cervicalis

Cricoid cartilage  
 Pyramidal lobe of thyroid gland (often absent or small)  
 Right lobe of thyroid gland  
 Isthmus of thyroid gland  
 Left lobe of thyroid gland

Internal jugular vein  
 Ascending cervical artery  
 Middle thyroid vein  
 Inferior thyroid artery  
 Transverse cervical artery  
 Suprascapular artery  
 Subclavian artery and vein

Pretracheal lymph nodes  
 Phrenic nerve  
 Anterior scalene muscle  
 Left vagus nerve (X)  
 External jugular vein

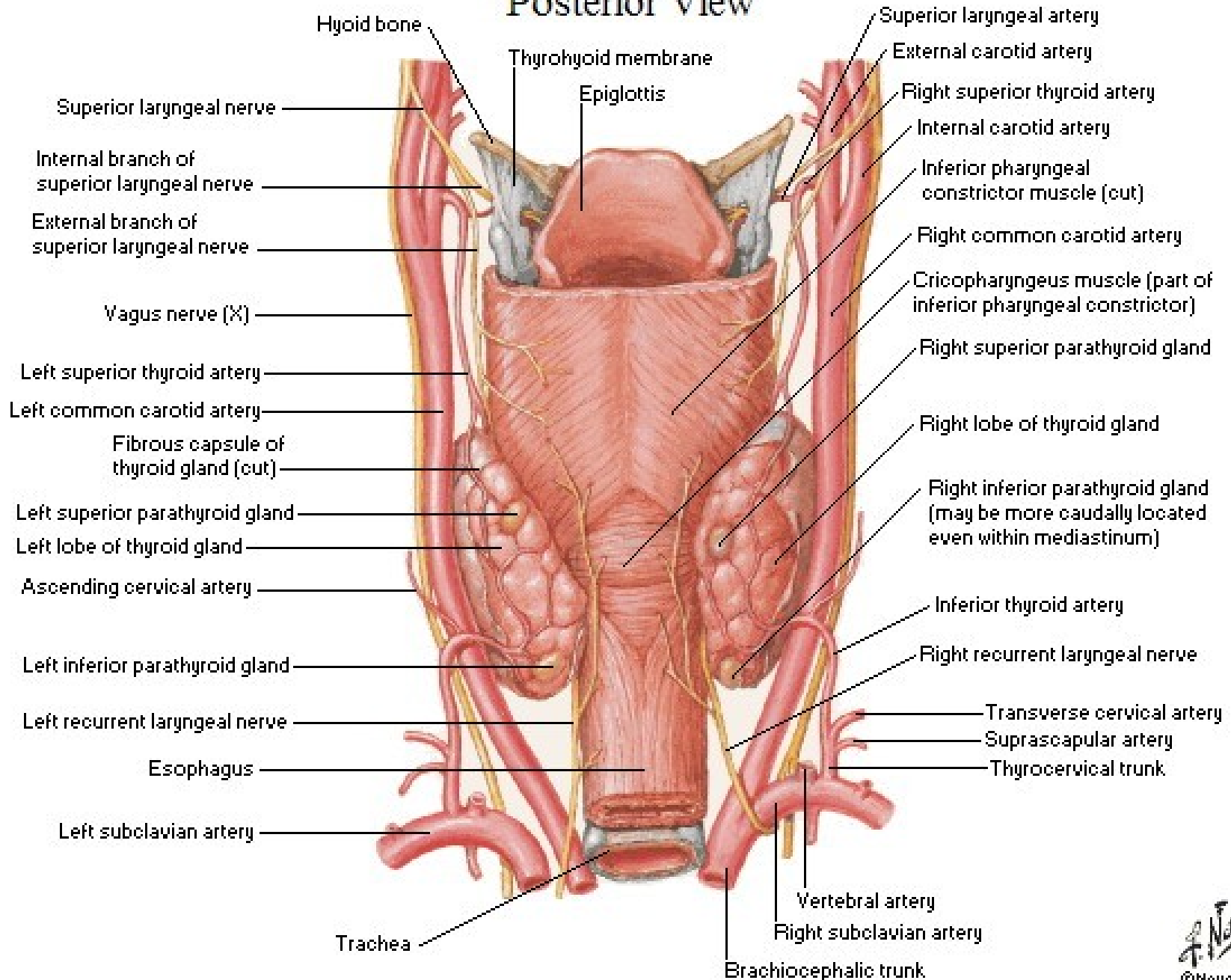
Thyrocervical trunk  
 Right vagus nerve (X)  
 Right recurrent laryngeal nerve  
 Brachiocephalic trunk

Anterior jugular vein  
 1st rib (cut)  
 Left recurrent laryngeal nerve

Inferior thyroid veins  
 Superior vena cava  
 Aortic arch  
 Left brachiocephalic veins

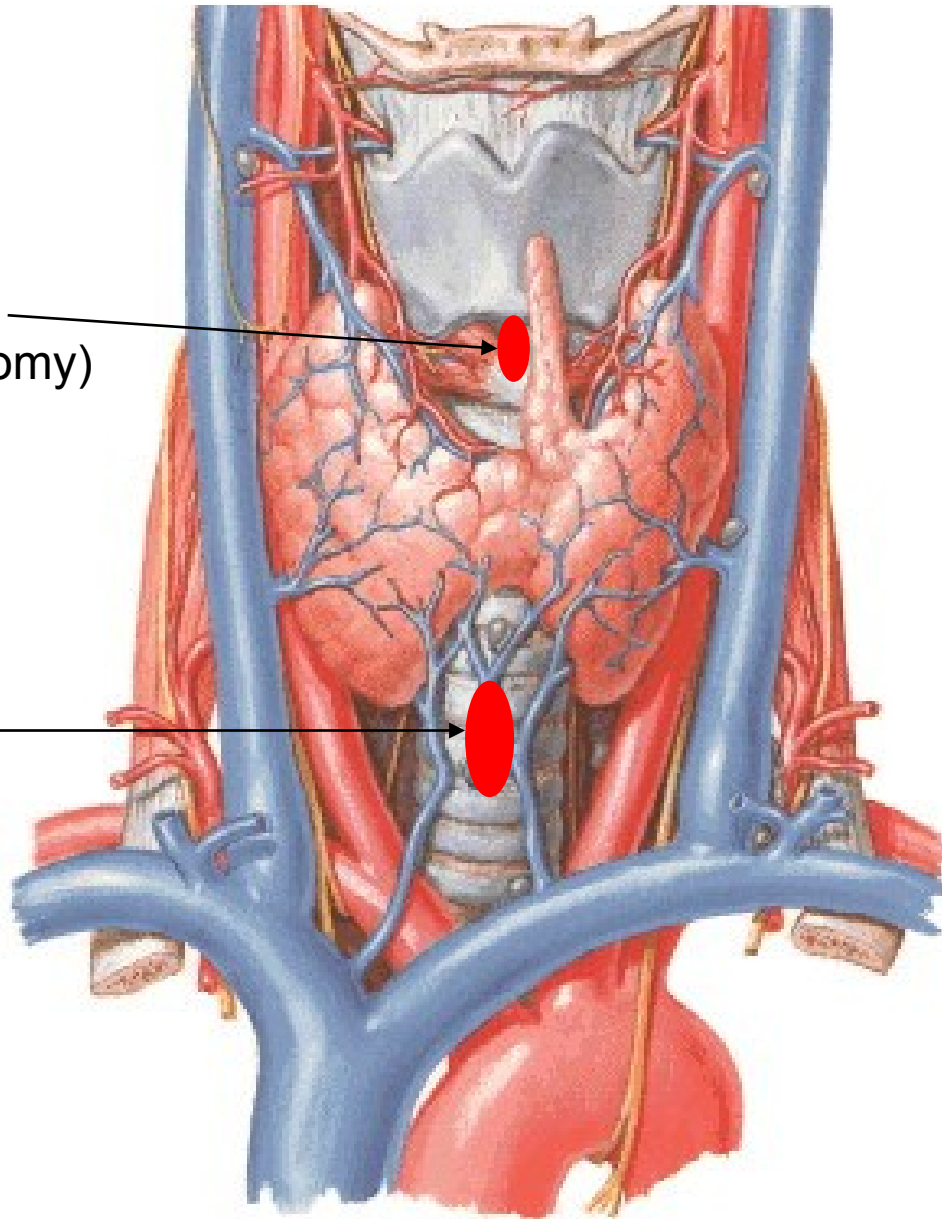
# Parathyroid Glands

## Posterior View



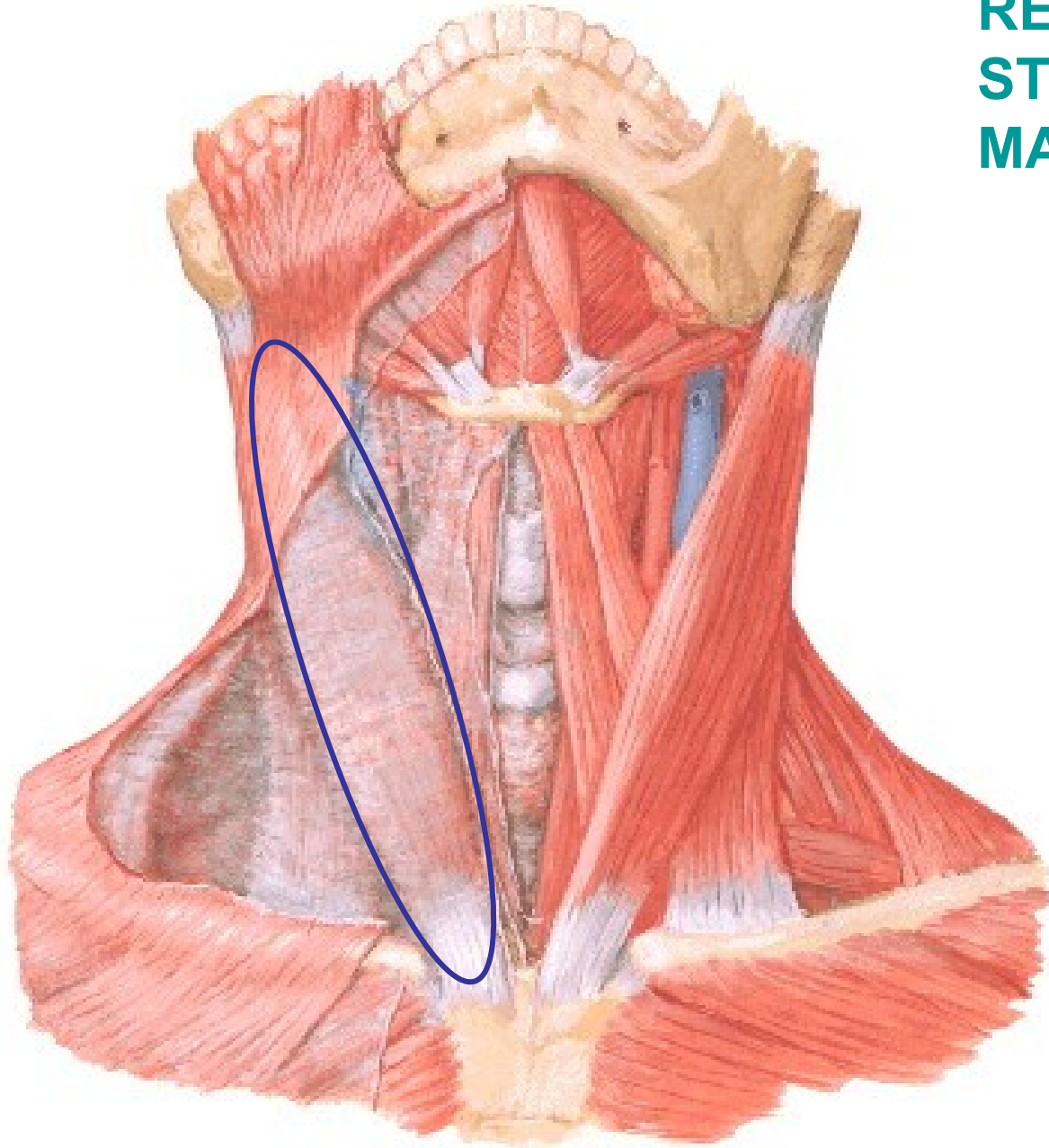
coniotomy  
(cricothyrotomy)

tracheotomy





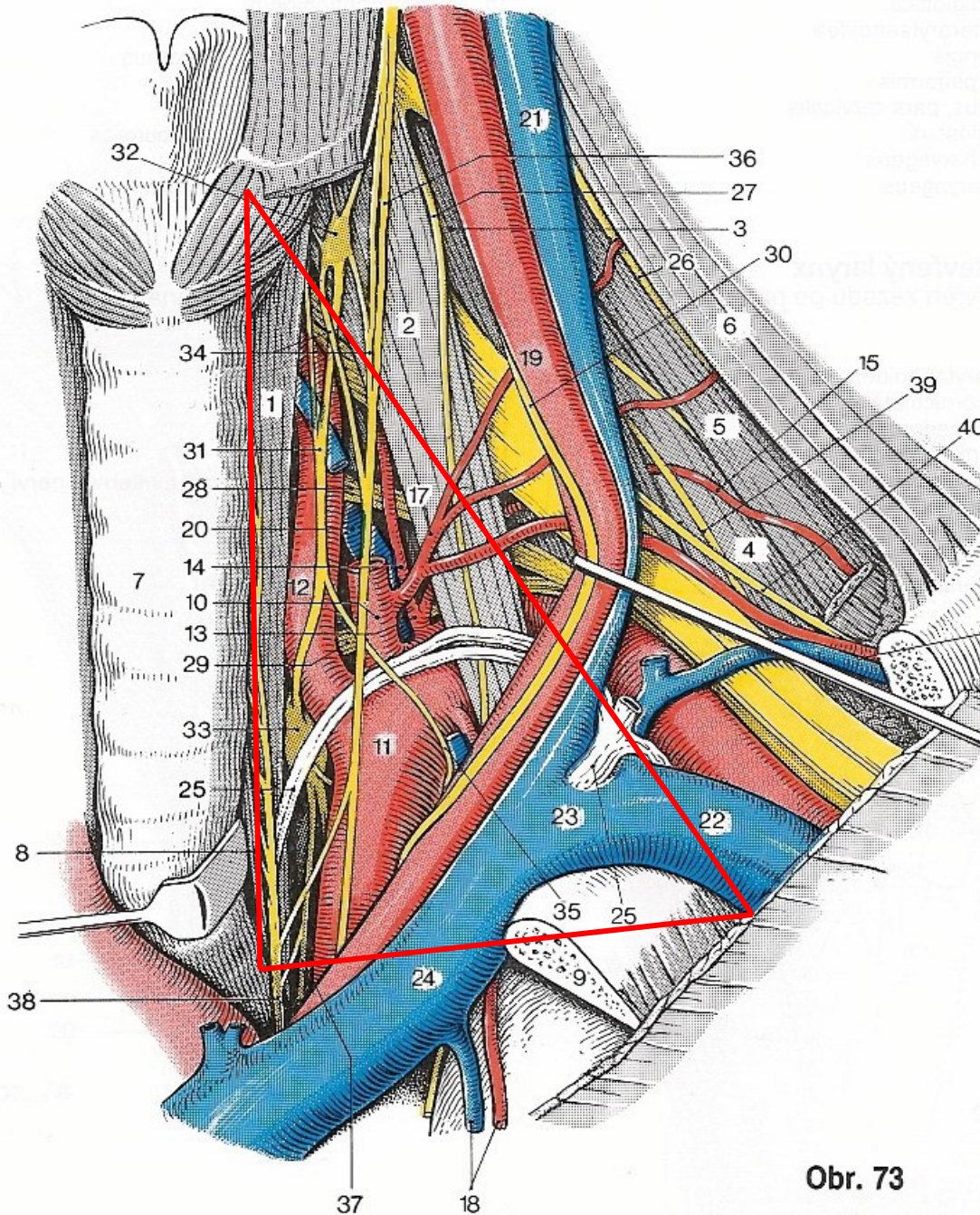
# REGIO STERNOCLEIDO- MASTOIDEA



# TRIGONUM SCALENOVERTEBRALE S. SUBCLAVIAE

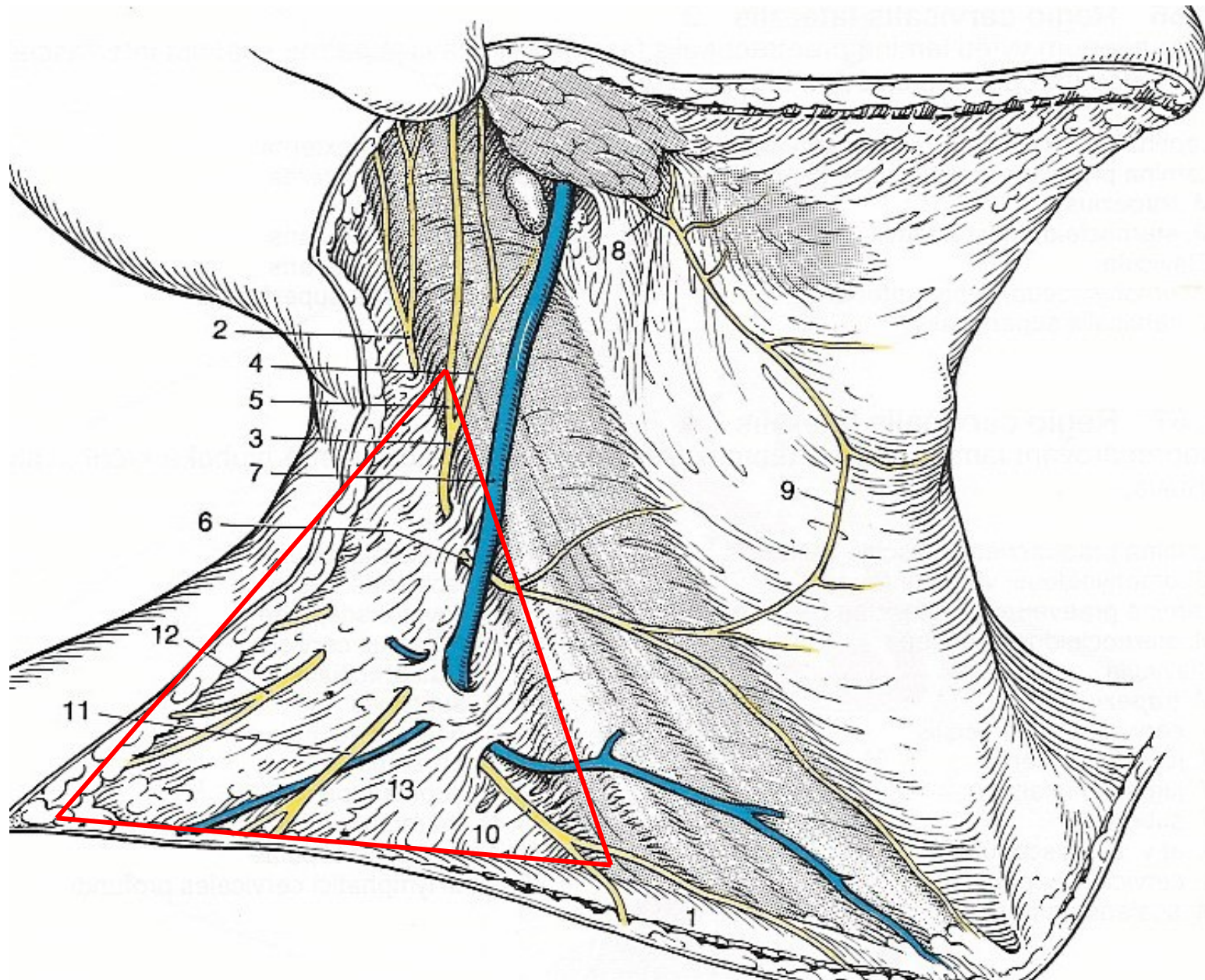
CONTENTS:

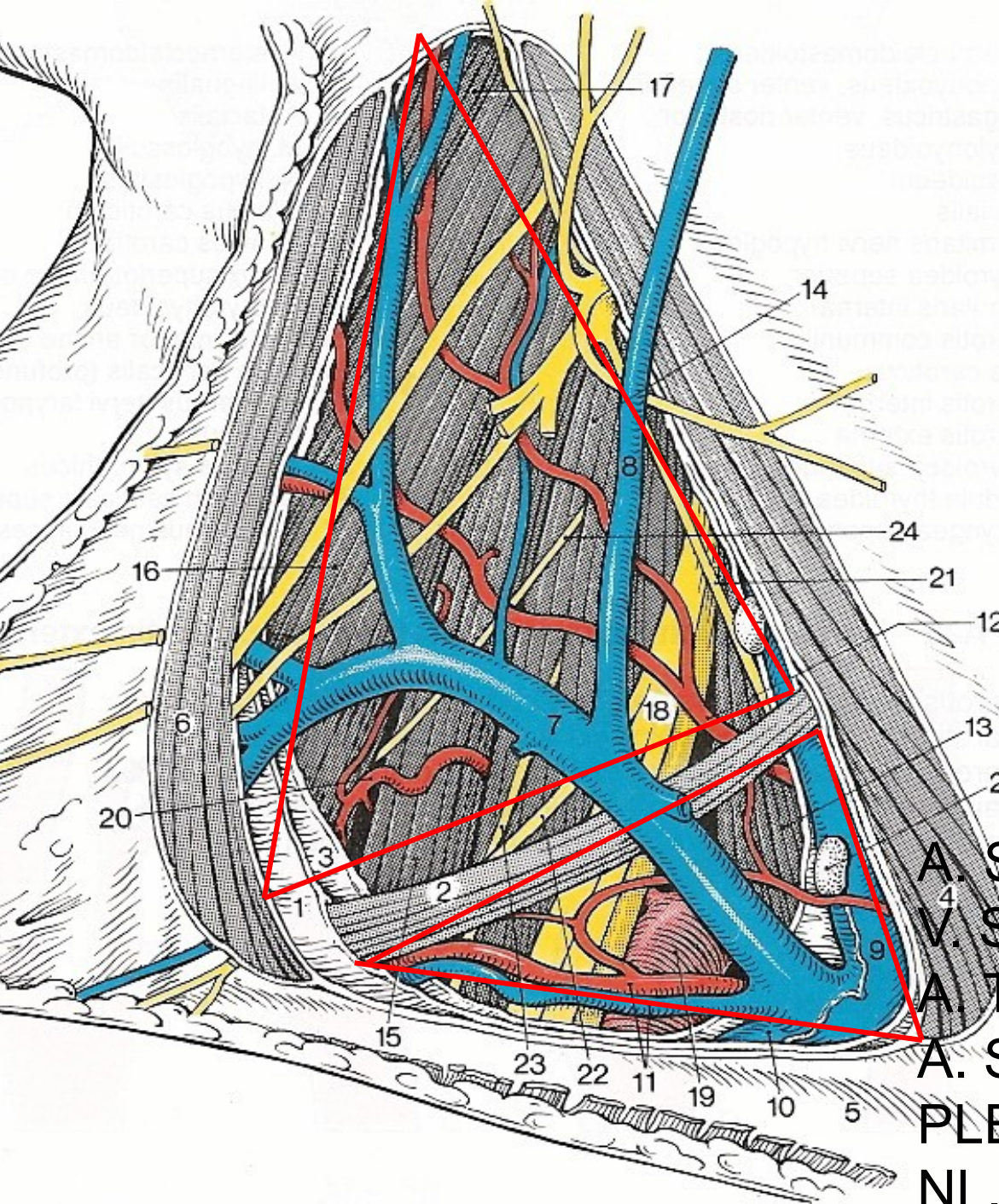
V. SUBCLAVIA  
V. JUGULARIS INT.  
V. JUGULARIS EXT.  
DUCTUS THORACICUS  
(TR. LYMPH. DEXTER)  
A. CAROTIS COMM.  
A. SUBCLAVIA  
TR. SYMPATICUS  
ANSA SUBCLAVIA  
N. VAGUS  
NN.+RR. CARDIACI  
N. PHRENICUS



Obr. 73

# TRIGONUM COLLI LATERALE





**TRIGONUM OMOCLAVICULARE**  
 A. CERVICALIS ASC.  
 A. CERVICALIS SPF.  
 CN XI  
 PLEXUS CERVICALIS

**TRIGONUM OMOTRAPEZOIDEUM**

A. SUBCLAVIA  
 V. SUBCLAVIA  
 A. TRANSVERSA COLLI  
 A. SUPRASCAPULARIS  
 PLEXUS BRACHIALIS  
 NL. SUPRACLAVICULARES