

PLEXUS CERVICALIS

PLEXUS CERVICALIS (C1 – C4)

Ansa cervicalis prof.

- radix superior
- radix inferior

N. transversus colli

Ansa cervicalis spf.

(r. colli CN VII)

N. auricularis magnus

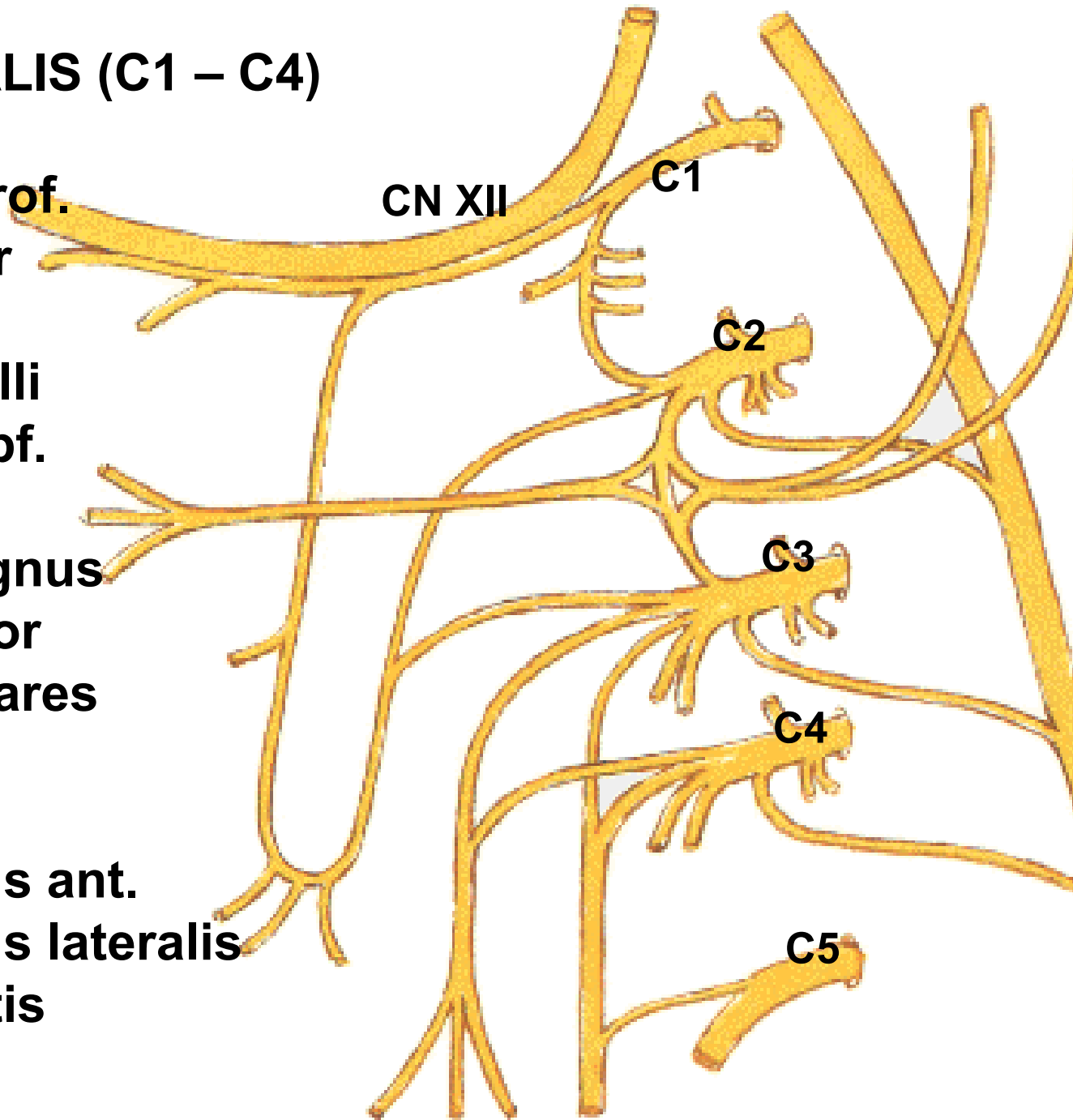
N. occipitalis minor

Nn. supraclaviculares

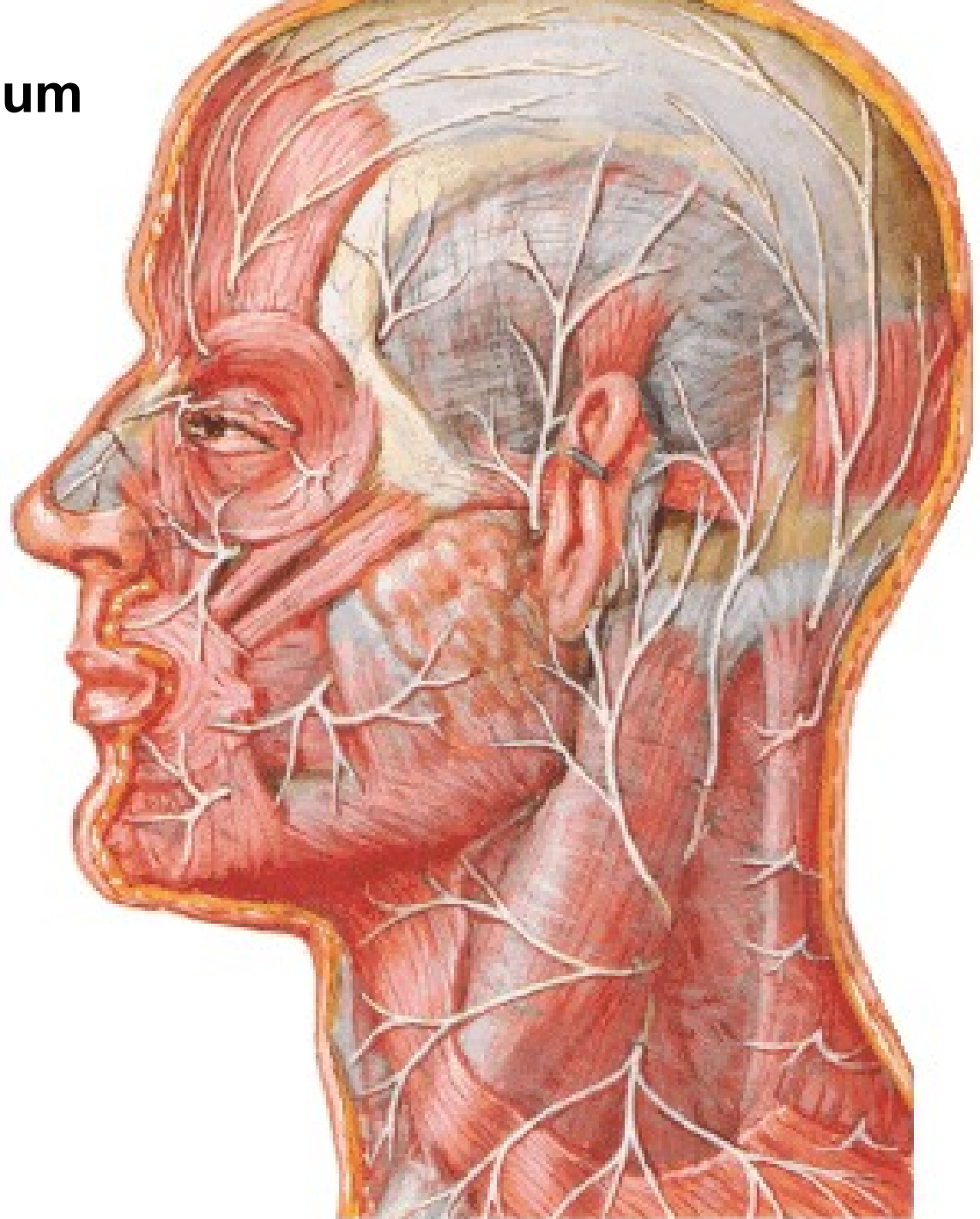
N. phrenicus

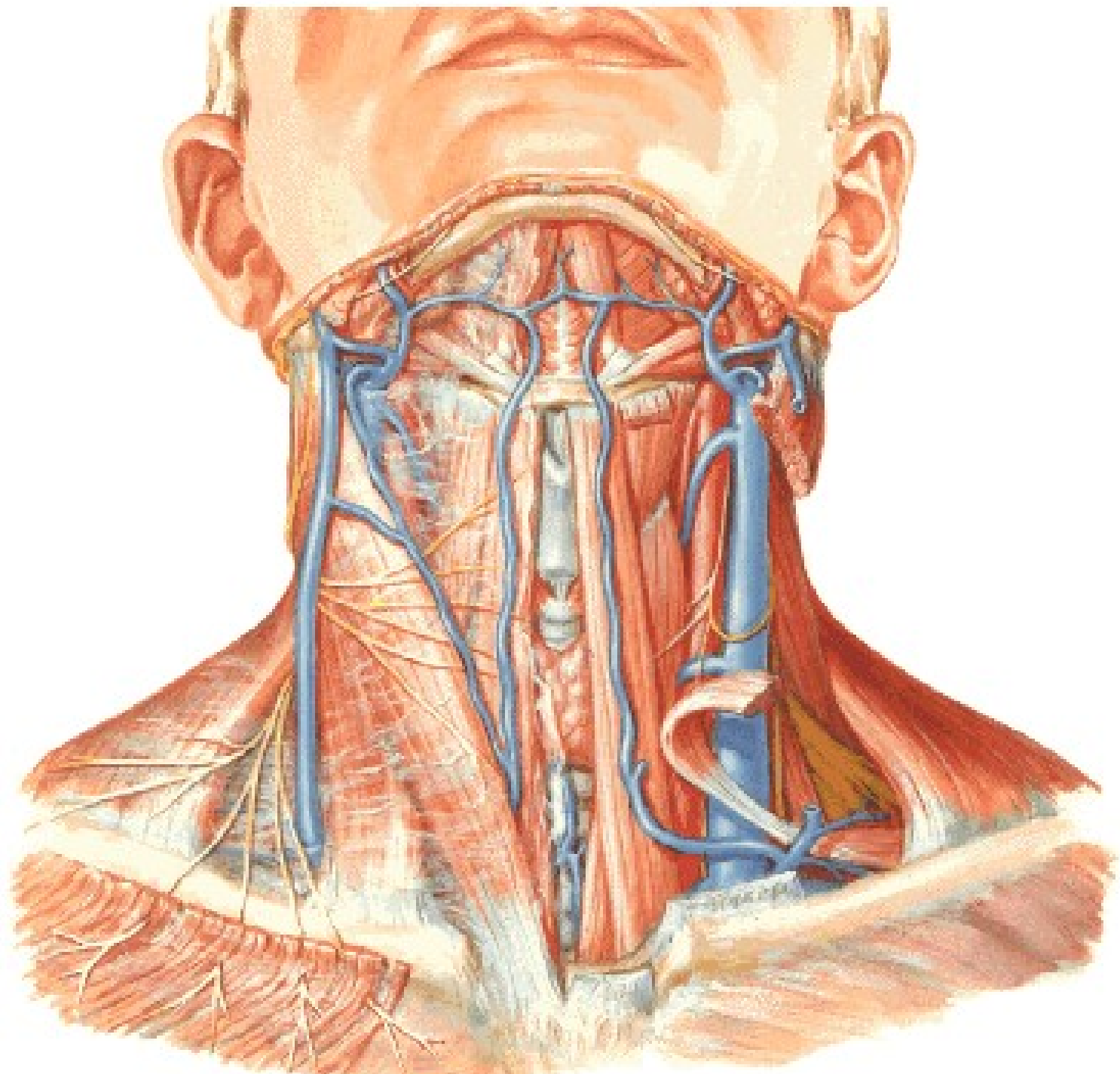
Rr. musculares

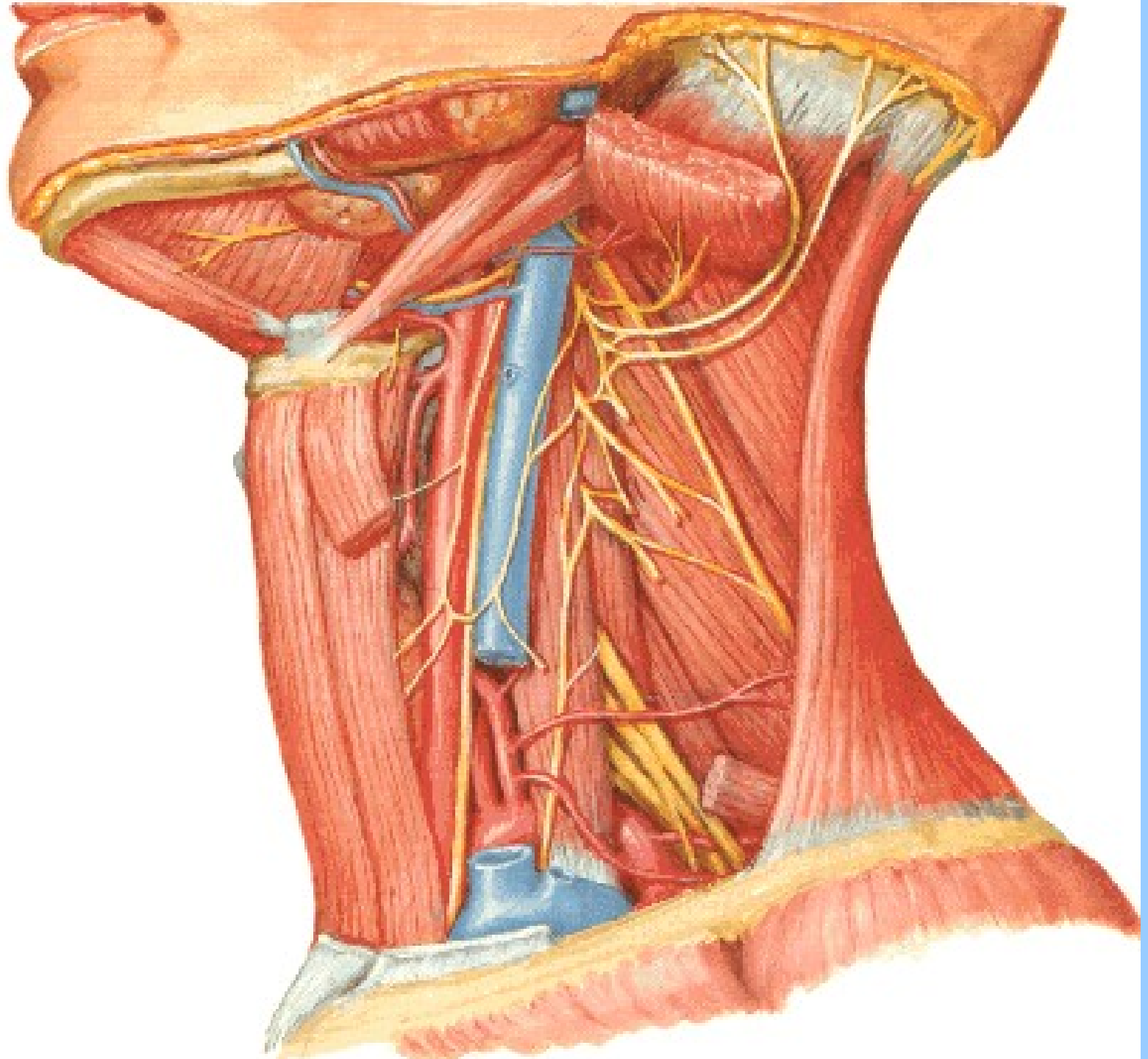
- m. rectus capitis ant.
- m. rectus capitis lateralis
- m. longus capitis
- m. longus colli
- mm. scaleni



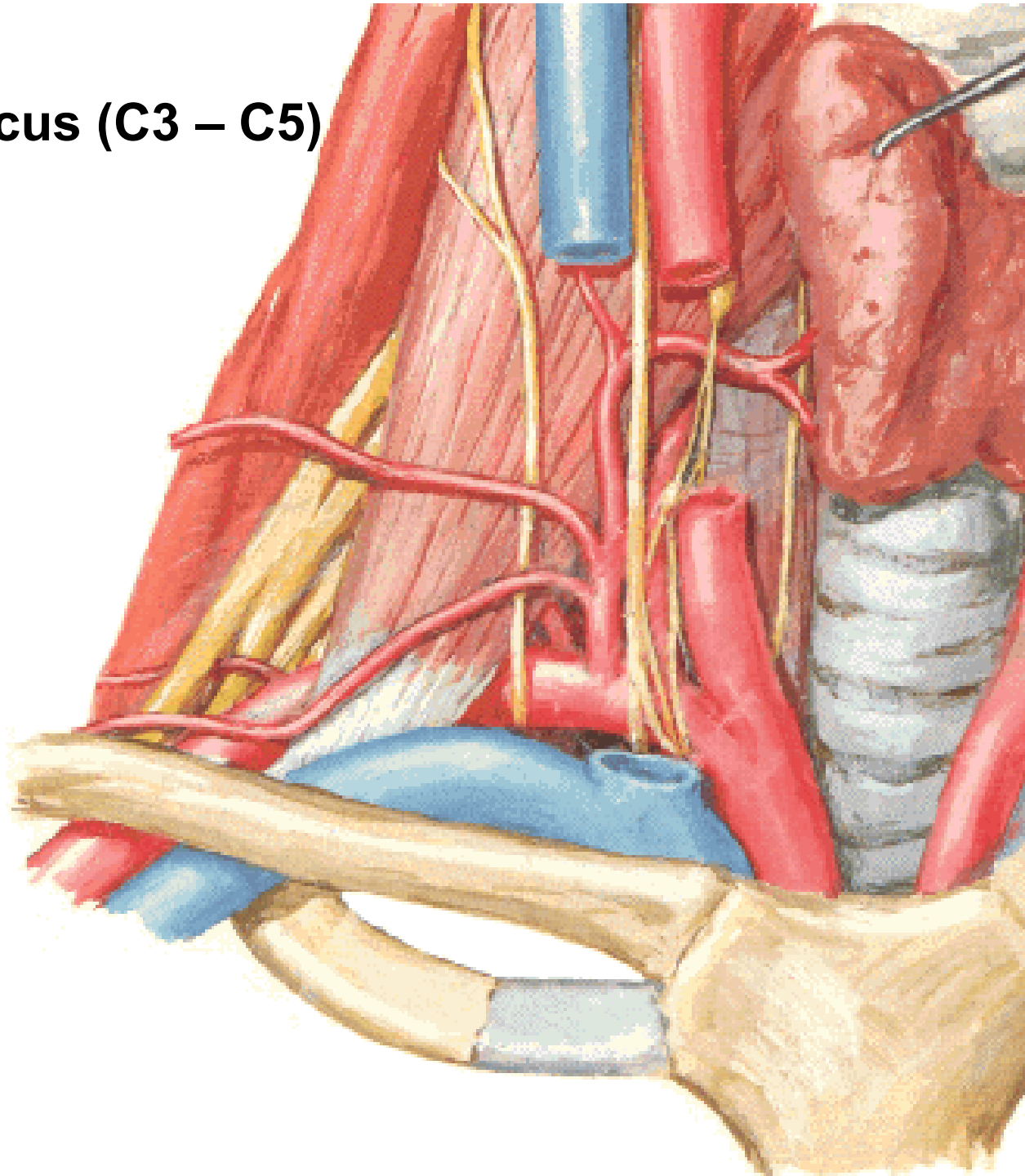
**Punctum nervosum
(Erb)**

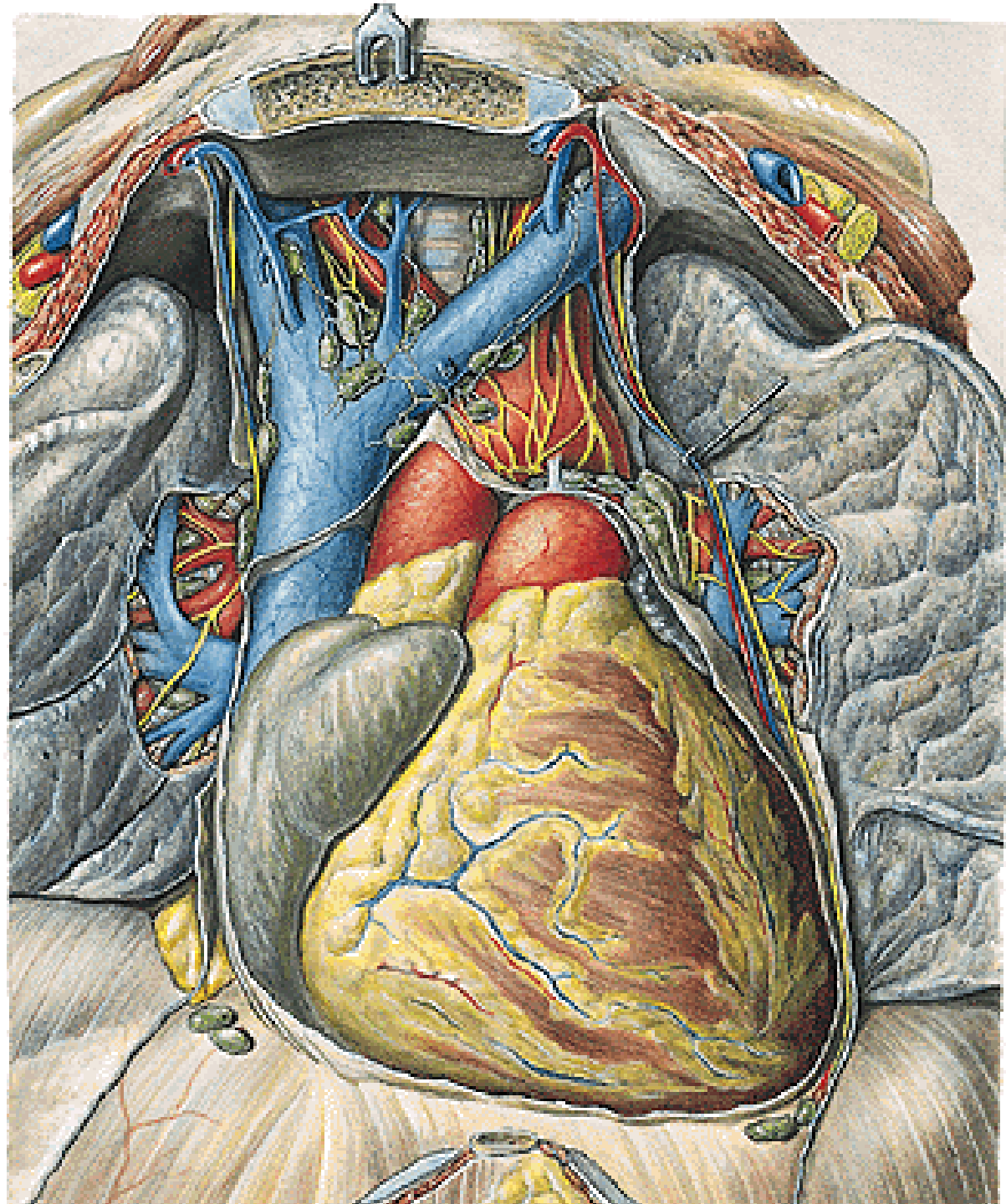


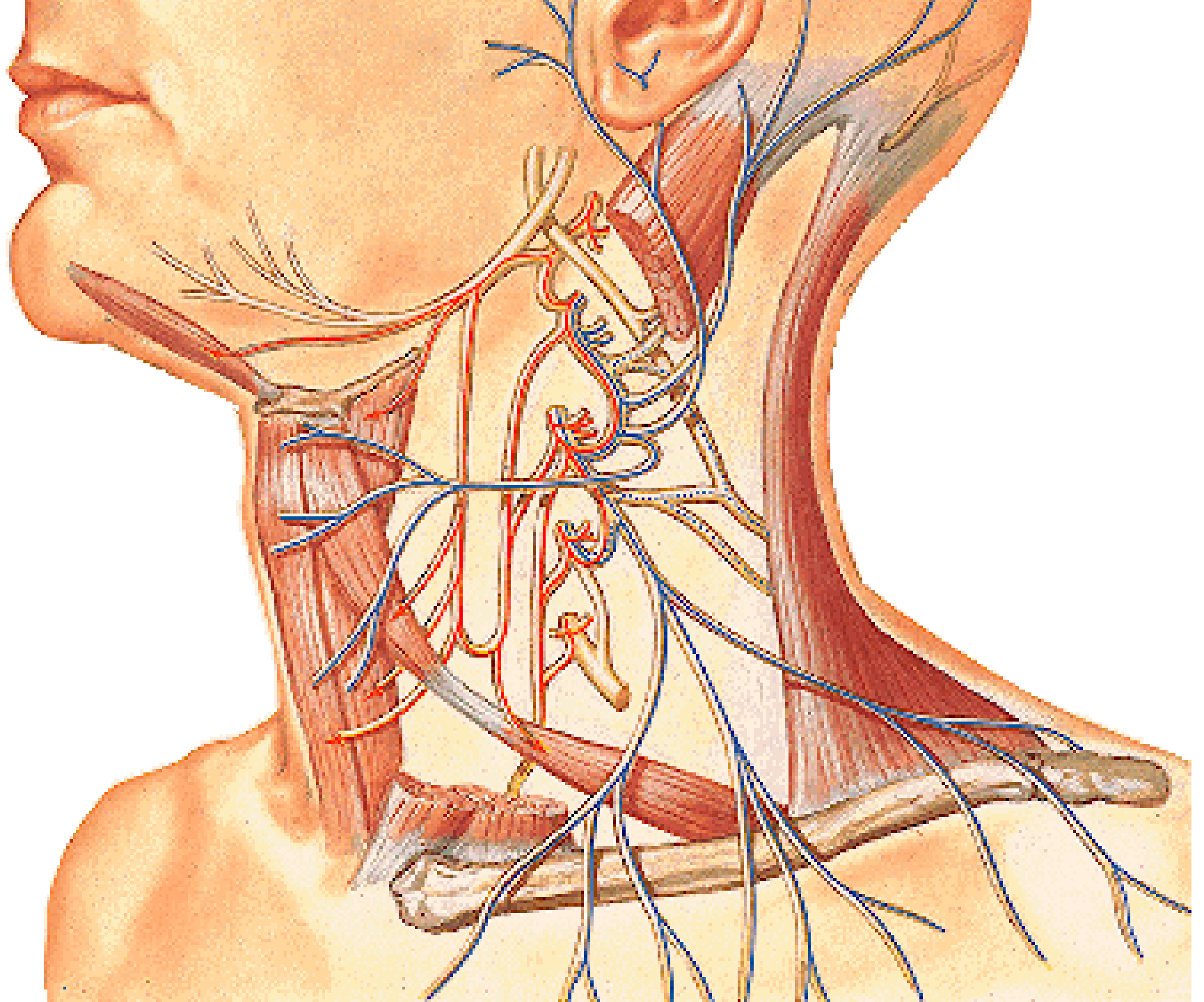




N. phrenicus (C3 – C5)







Illustrations and photographs were copied from:
Atlas der Anatomie des Menschen/Sobotta.
Putz,R., und Pabst,R. 20. Auflage. München:
Urban & Schwarzenberg, 1993
Netter: Interactive Atlas of Human Anatomy.
Windows Version 2.0