

Mikrobiologický ústav LF MU Brno

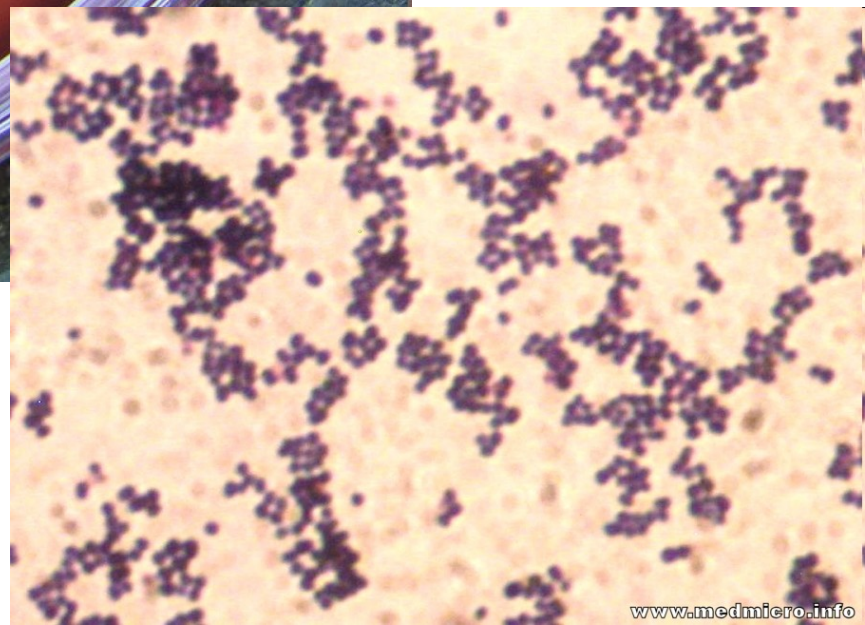
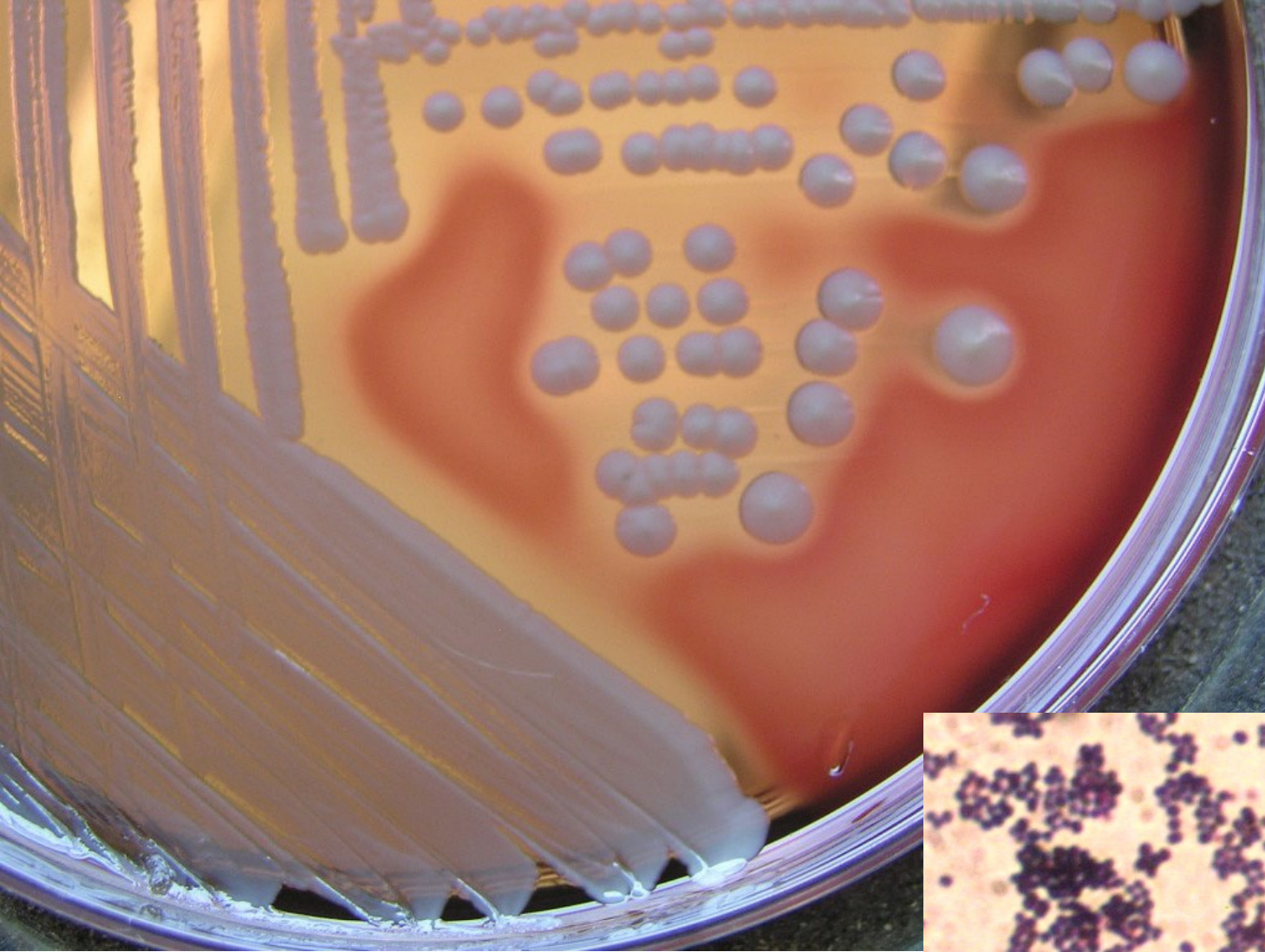
Infekce ran

Typy ran

- **povrchové**
- **zhmožděné**
- **vzniklé ve vodě**
- **vzniklé v tropech**
- **chirurgické**
- **popáleniny**
- **pokousání**

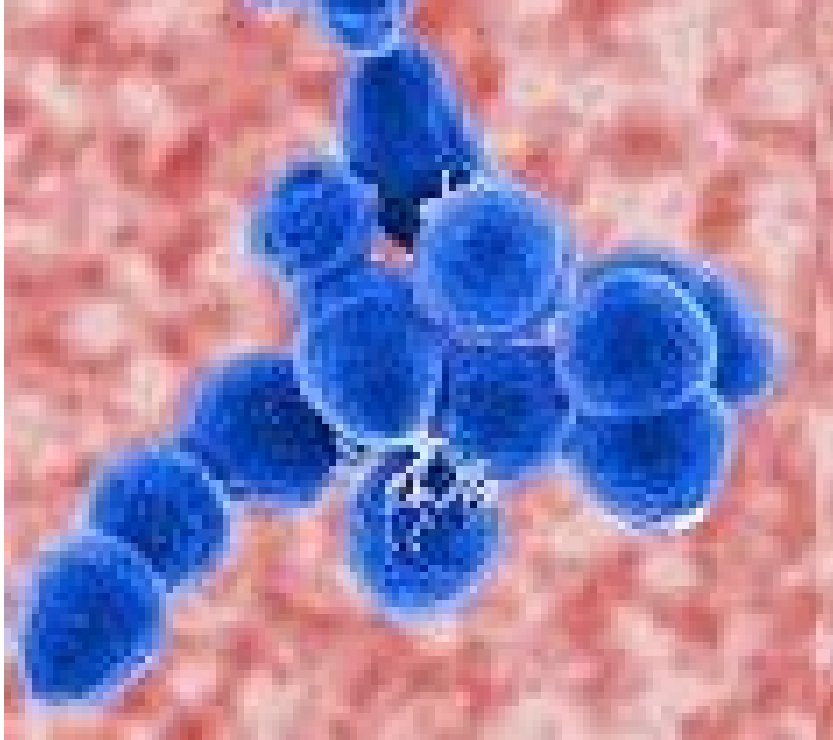
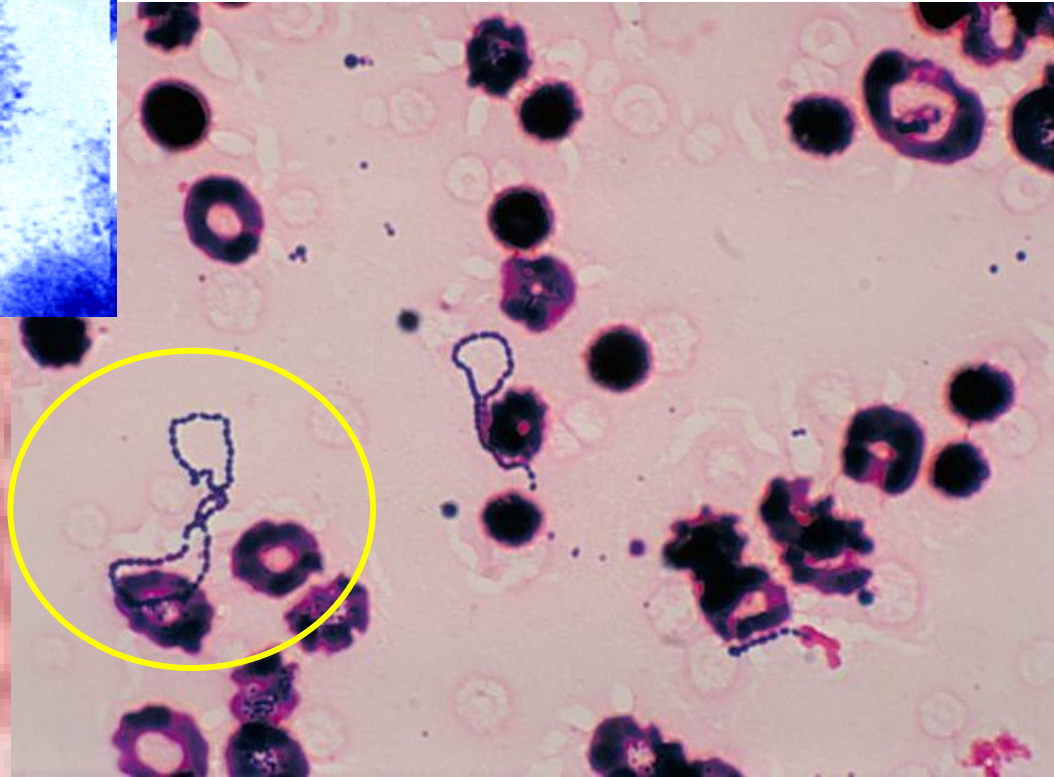
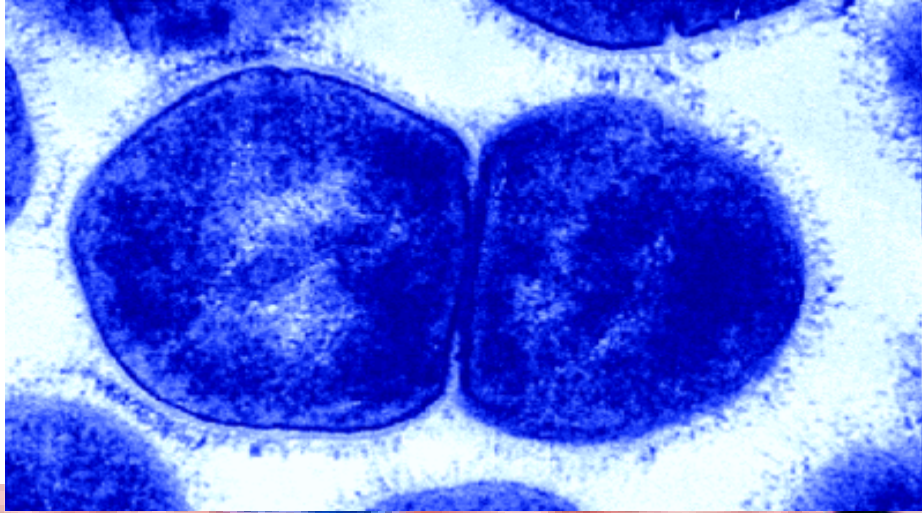
Povrchová poranění

- *Staphylococcus aureus*
 - *Streptococcus pyogenes*
 - beta-hemolytické streptokoky (G, F, C)
- ! cizí těleso (tříška), hluboká rána (vidle znečištěné hnojem): *Clostridium tetani***



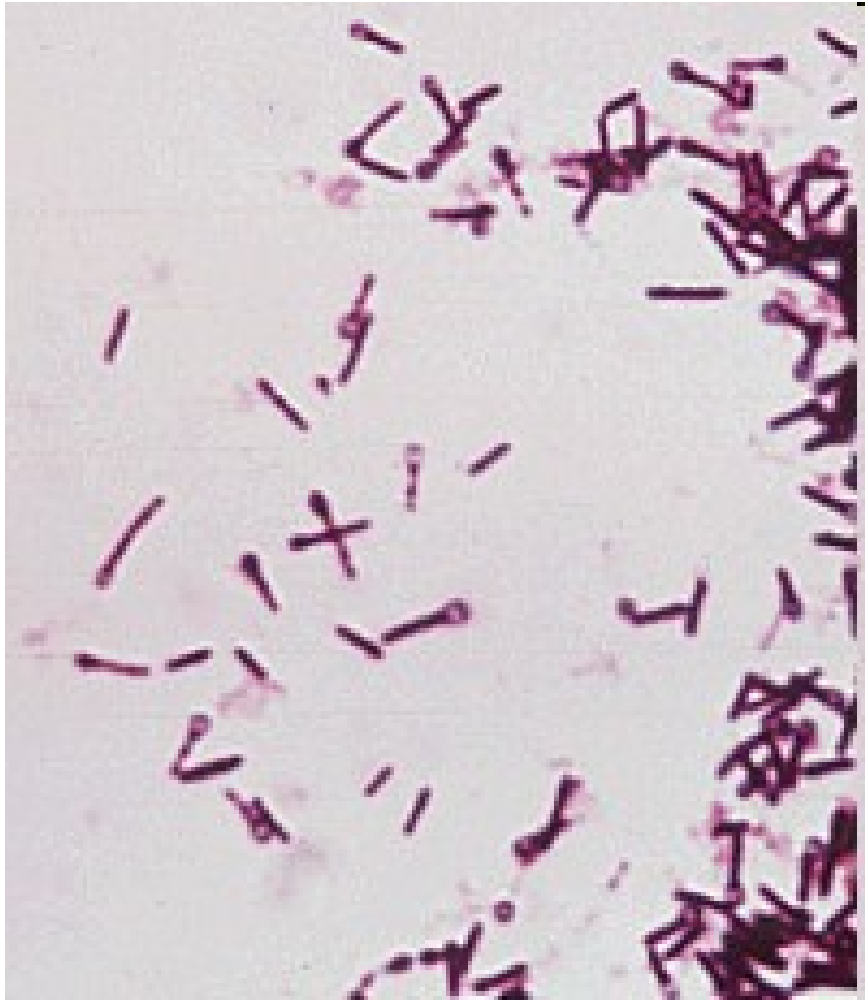STAFYLOKOKY

STREPTOKOKY

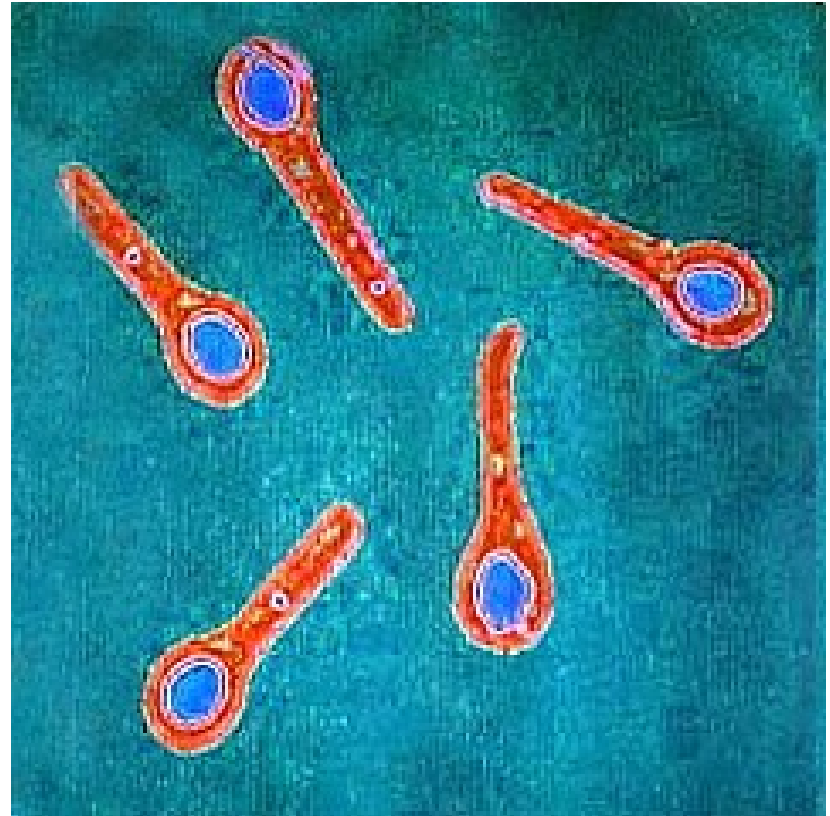


Left: microbewiki.kenyon.edu.

Below: <http://upload.wikimedia.org>



CLOSTRIDIUM TETANI



microbiologybytes.wordpress.com/

Sir Charles Bell's portrait of a soldier dying of tetanus.

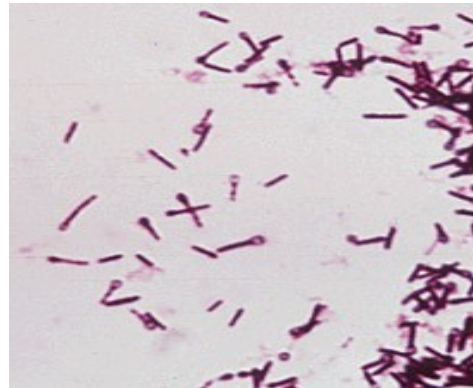
The characteristic **rigidity of the body** is referred to as **opisthotonus** and **risus sardonicus**.

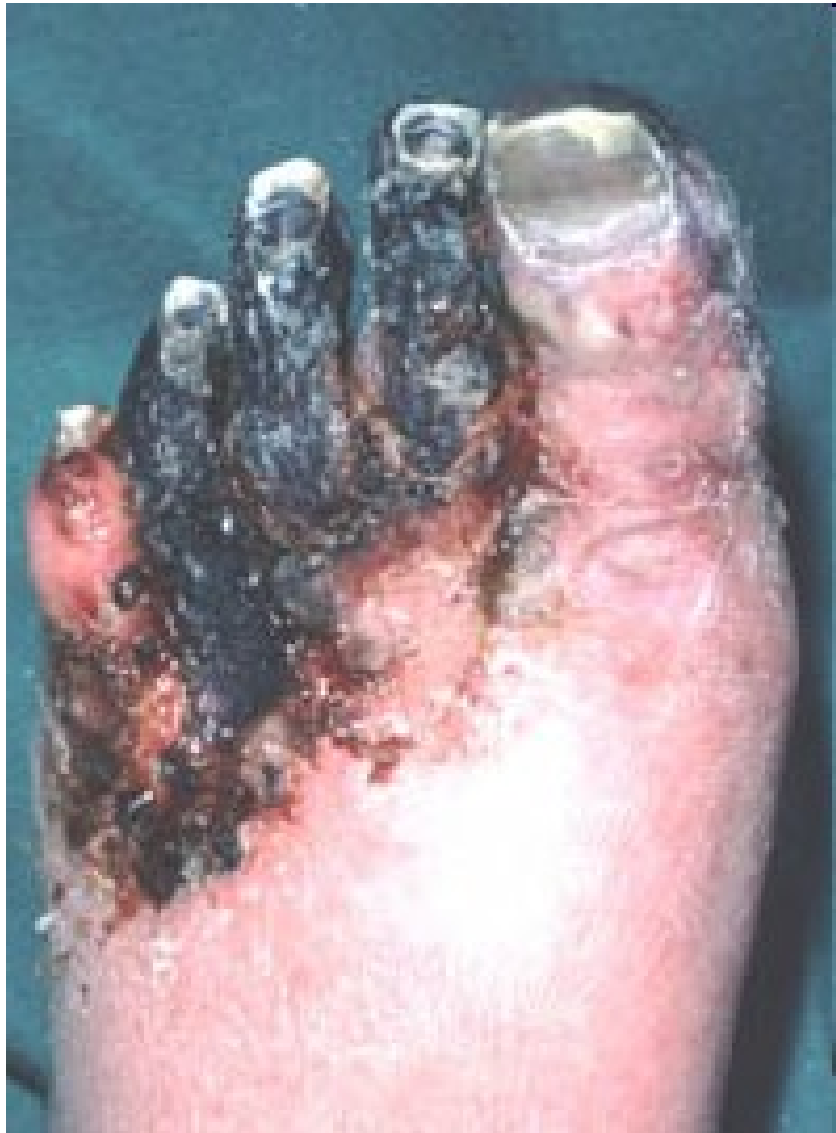(Original in the Royal College of Surgeons of Edinburgh, Scotland)



Zhmožděné rány

- **Původci klostridiové myonekrózy**
(*Clostridium perfringens*, *C. septicum*,
C. novyi, *C. histolyticum*)
= anaerobní traumatóza = plynatá sněť
- ***Clostridium tetani***





<http://www.thewoundcarecenter.com>

Rány vzniklé ve vodě

- Sladkovodní:

Pseudomonas aeruginosa

Aeromonas hydrophila

- Slané:

Vibrio parahaemolyticus, V. vulnificus

Mycobacterium marinum (bazény, akvária)

Rány v tropech

- **půdní nokardie**

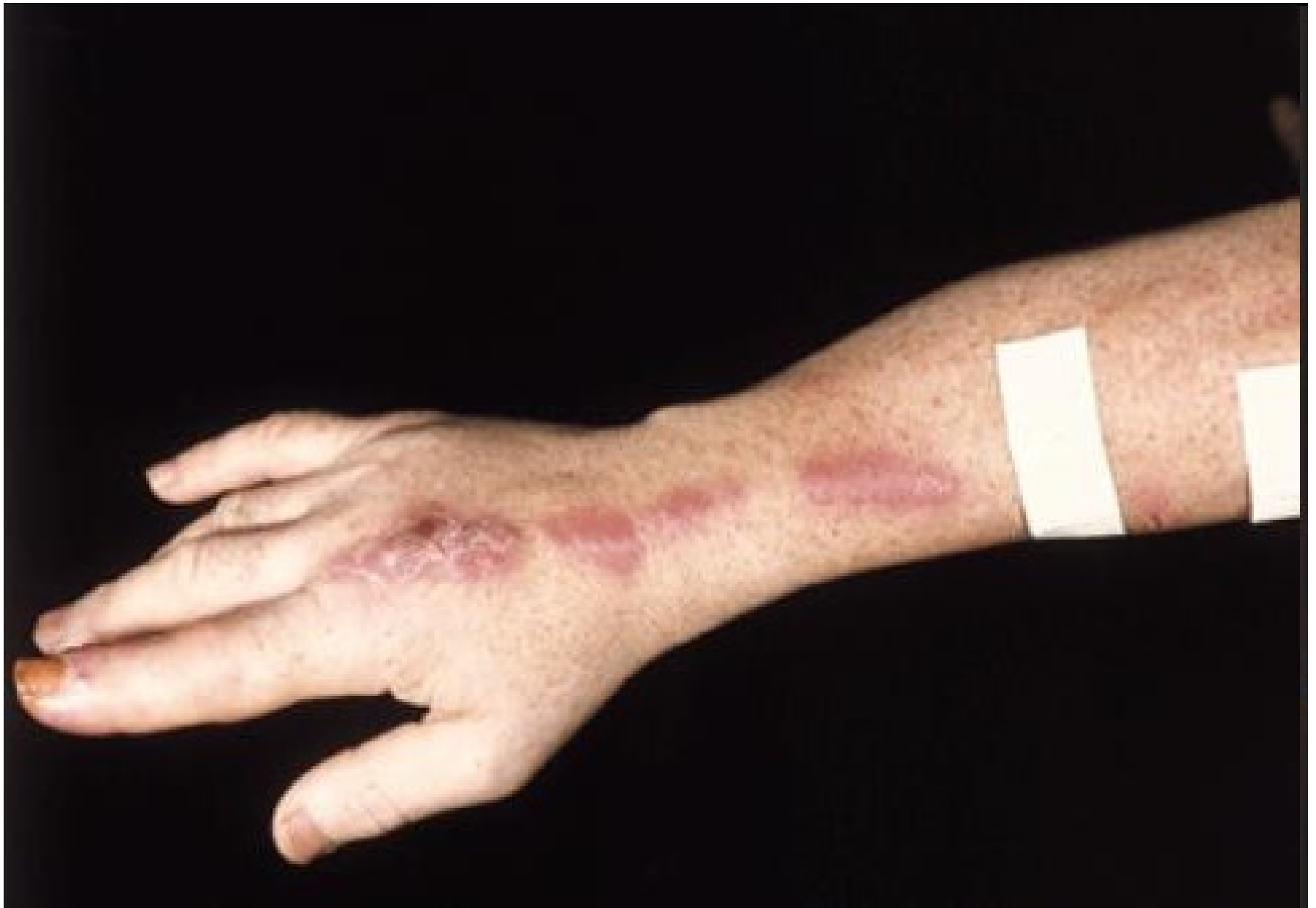Dermatophilus congolensis, Rhodococcus equi

- **atypická mykobakteria**

Mycobacterium ulcerans, Mycobacterium haemophilum)

- **micromycety**

Sporothrix schenckii, Paracoccidioides brasiliensis

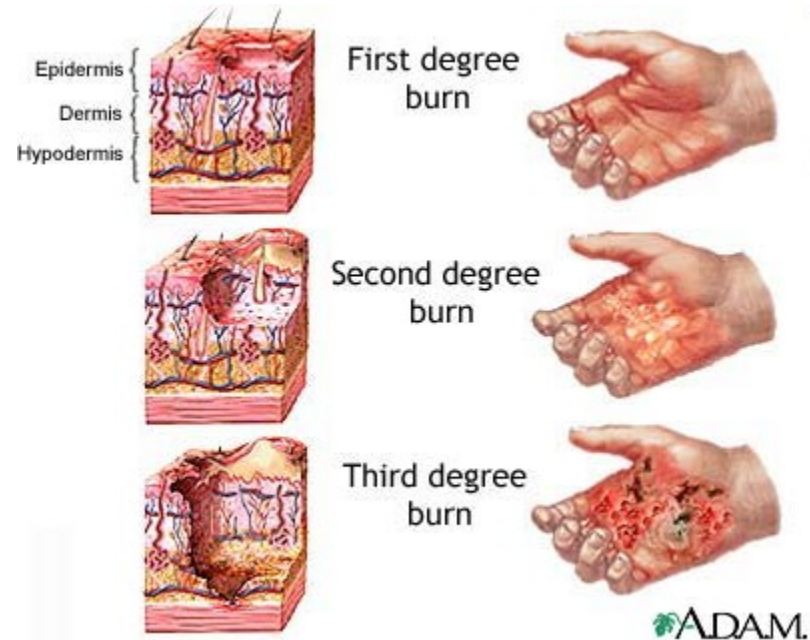


Chirurgické rány

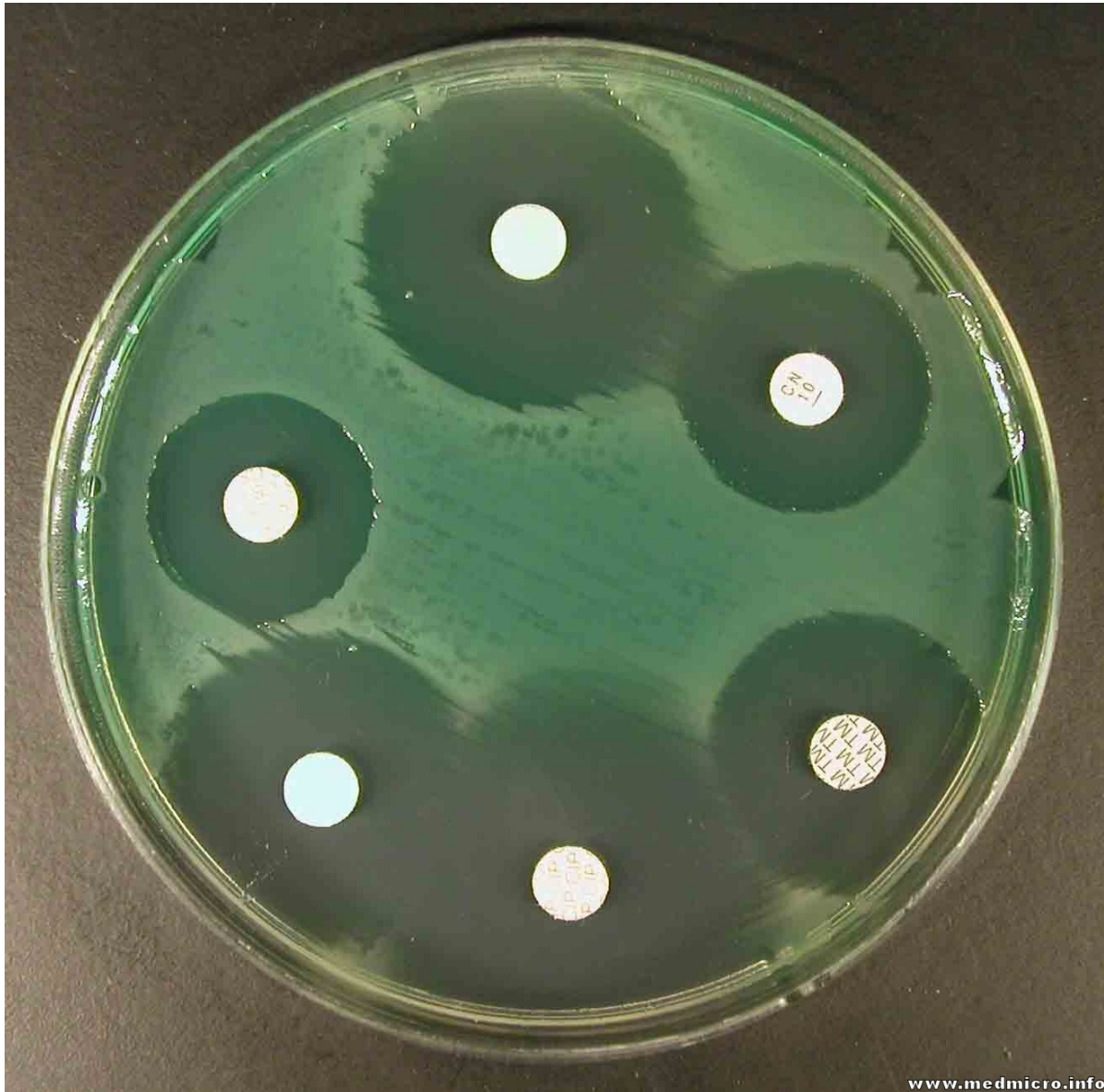
- *Staphylococcus aureus*
- *S. epidermidis*
- **Enterobacteriaceae** (*E. coli*, *P. mirabilis*)
- *Streptococcus pyogenes*
- anaeroby

Popáleniny

- *Pseudomonas aeruginosa*
- *Staphylococcus aureus*
- *Streptococcus pyogenes*
- enterokoky
- kvasinky, aspergilus



P. AERUGINOSA



Rány kousnutím

Orální flóra

- „ústní streptokoky“ (*Streptococcus sanguinis*, *S. oralis*, *S. anginosus*)
- anaeroby (*Fusobacterium nucleatum* ssp. *nucleatum*, *Porphyromonas gingivalis*)

Staphylococcus aureus

Pokousání zvířetem

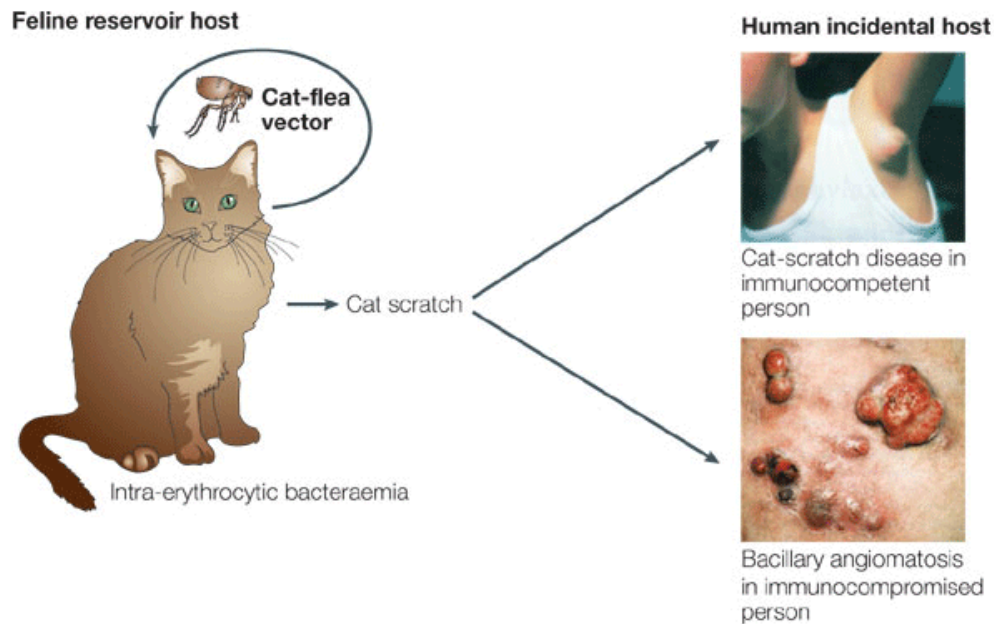
- *Pasteurella multocida* (psi, kočky)
- *Staphylococcus aureus*
- *Capnocytophaga canimorsus* (pes)
- *Streptobacillus moniliformis* (krysa)
- *Spirillum minus*
(myš, krysa, pes, kočka)

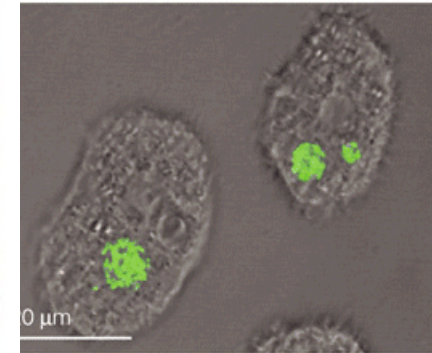
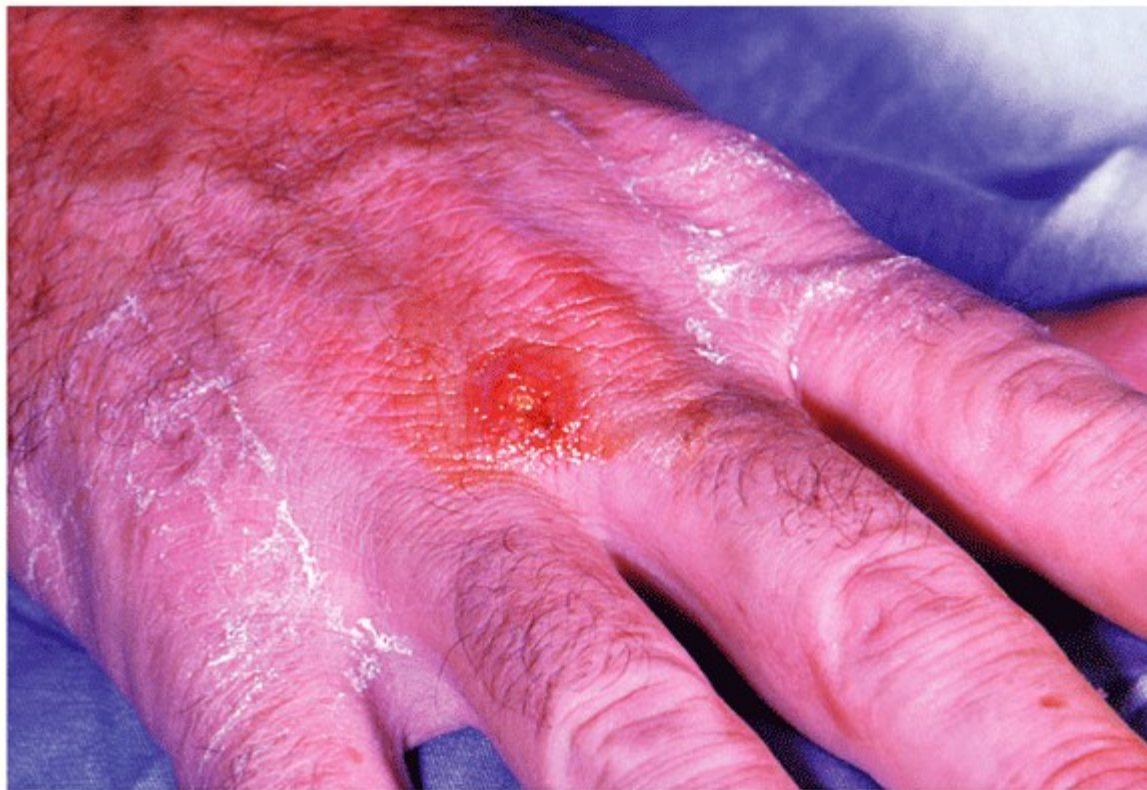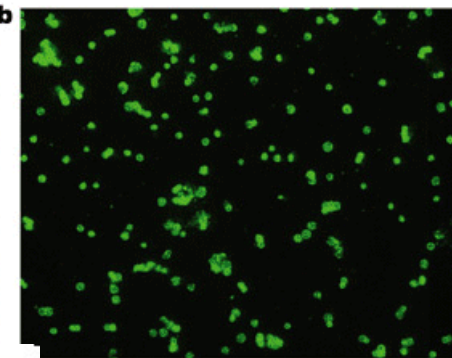
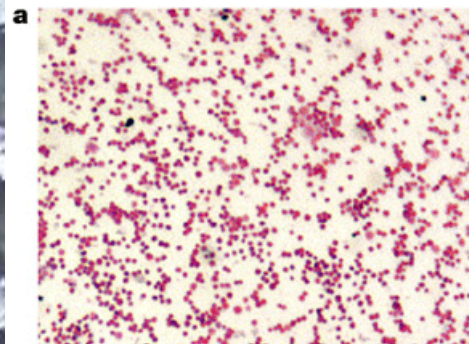
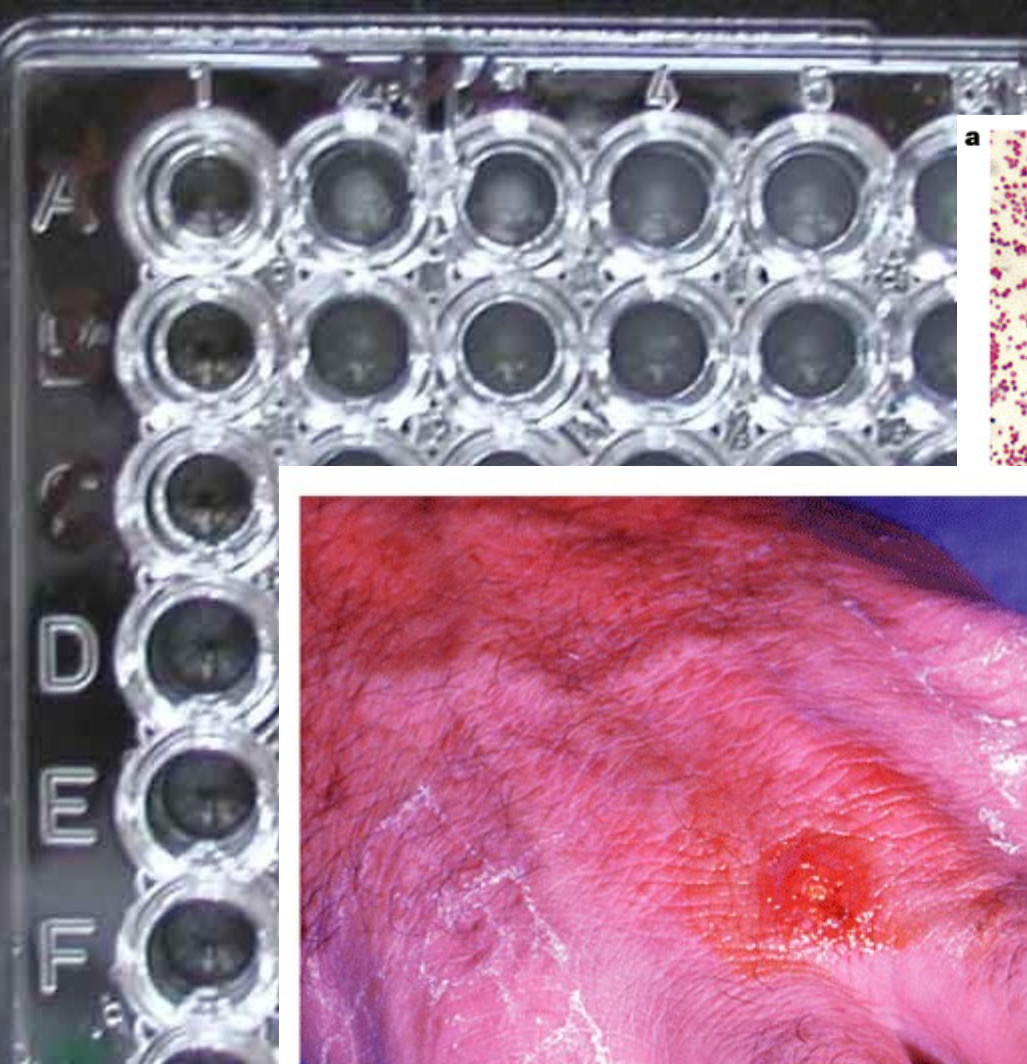


Poranění zvířetem

Francisella tularensis (hlodavci, zajíci – tularemia)

Bartonella henselae (“cat scratch disease”)





Nature Reviews | Microbiology

FRANCISELLA TULARENSIS

Nature Reviews | Microbiology

**Egon Schiele
(1890-1918):
Dead mother
(1910)**

