

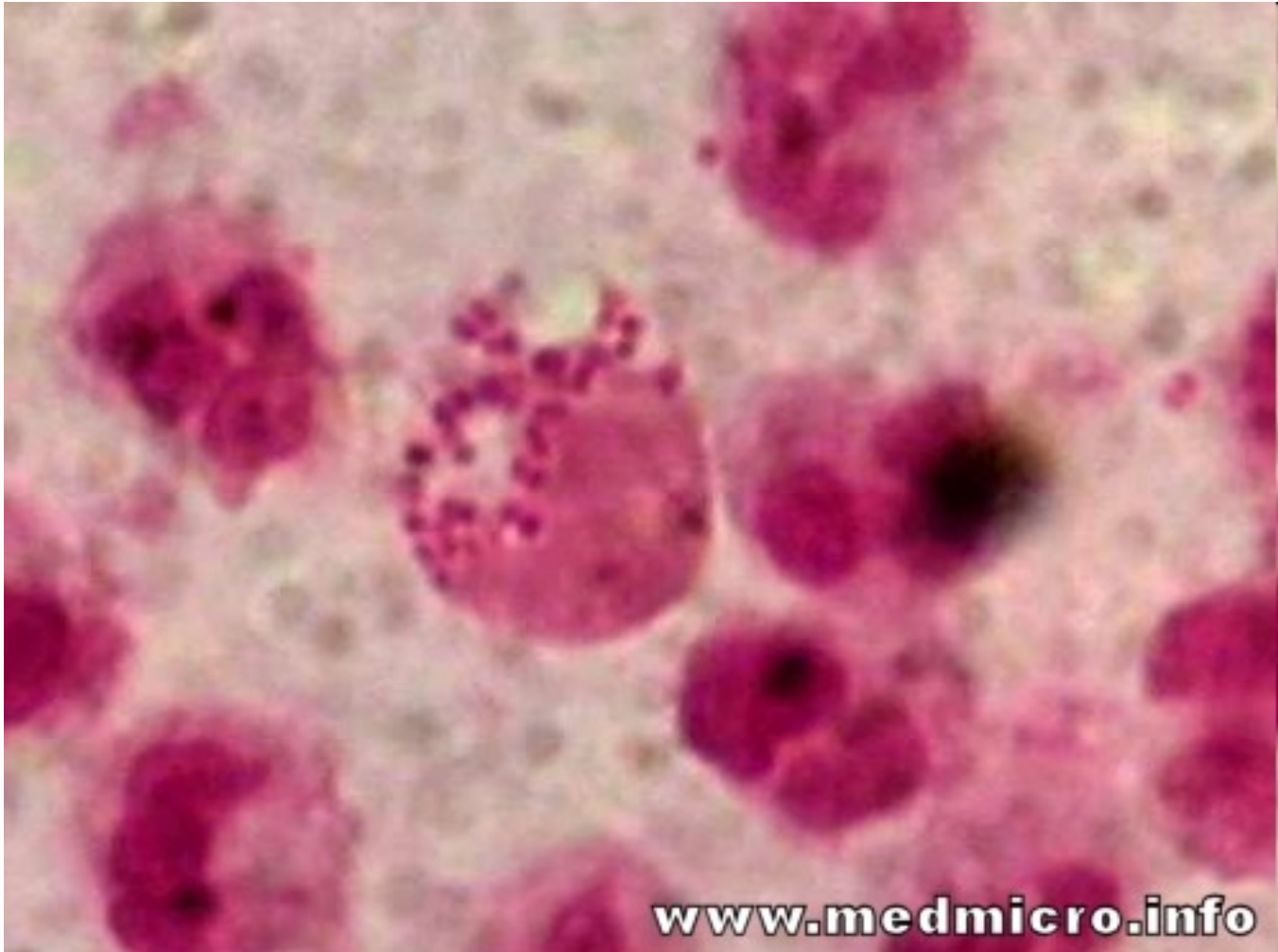
**Institute for Microbiology, Medical Faculty of Masaryk University
and St. Anna Faculty Hospital in Brno**

Agents of classical venereal infections

Classical venereal infections

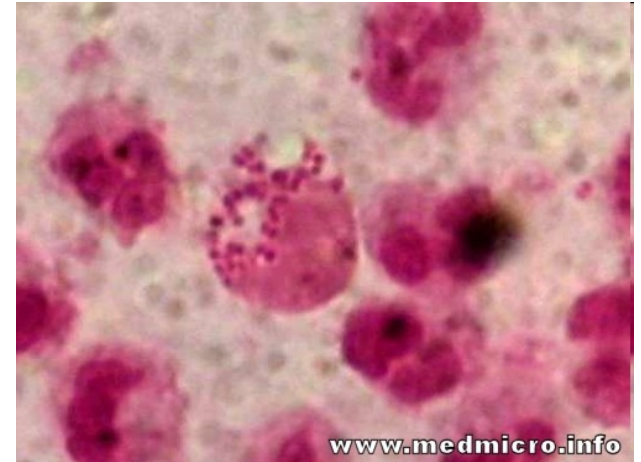
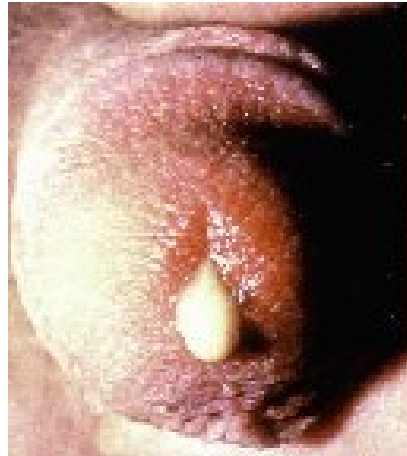- **Gonorrhoea** *Neisseria gonorrhoeae*
- **Syphilis** *Treponema pallidum*
- **Chancroid** *Haemophilus ducreyi*
- **Lymphogranuloma venereum**
Chlamydia trachomatis L₁, L₂, L_{2a}, L₃

Neisseria gonorrhoeae



GO: infections of the UGT

- Urethritis
- Epididymitis



- Cervicitis
- Urethritis
- Bartholinitis
- Endometritis
- Salpingitis, adnexitis (PID, pelvic inflammatory disease) → sterility!

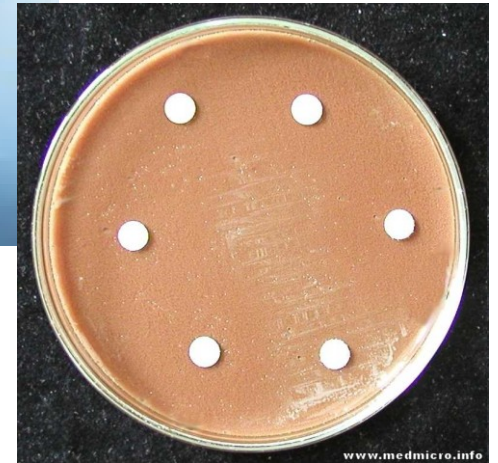GO: laboratory diagnostics – I

Direct detection only:

microscopy

culture

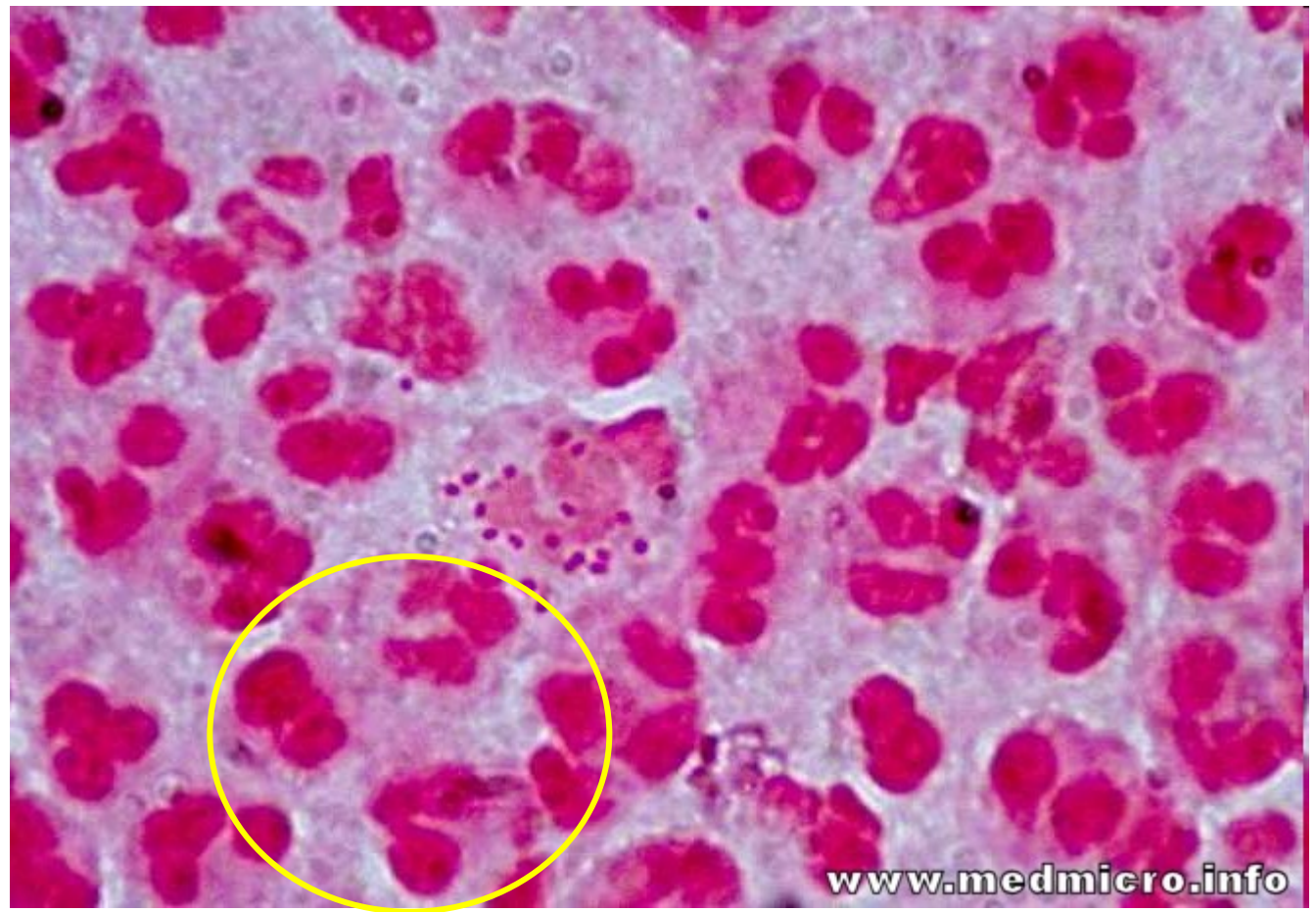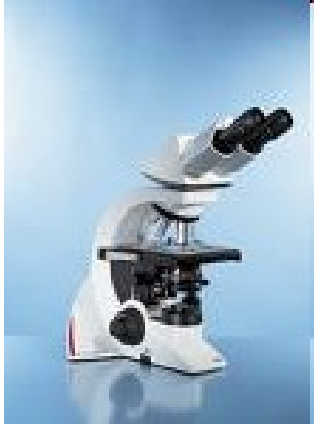molecular biology tests



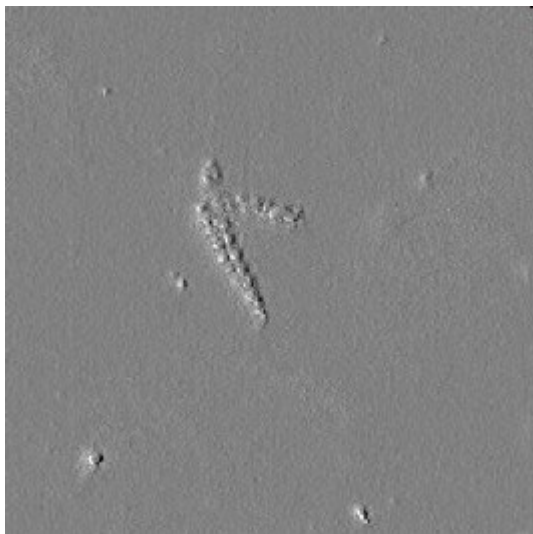
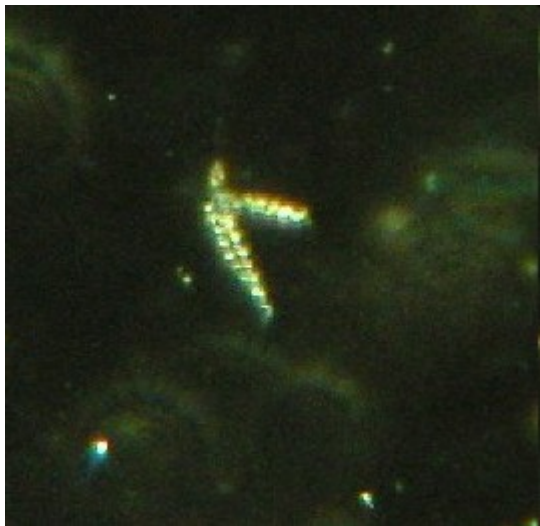Sampling places:

urethra

cervix, urethra, rectum, pharynx (if necessary)



Ceftriaxone or ciprofloxacin
usually a single dose, potential concurrent *Chla*
trachomatis: plus doxycycline or azithromycine



TREPONEMA PALLIDUM

Author: MUDr. Petr Ondrovčik

The course of syphilis

**A) Early syphilis: primary (ulcus durum)
secondary (mostly rash)
early latent**

**B) Late syphilis: latent
terciary (gummas, aortitis, neurological)**

C) Congenital syphilis: early and late

- Hutchinson s teeth
- mulberry molars

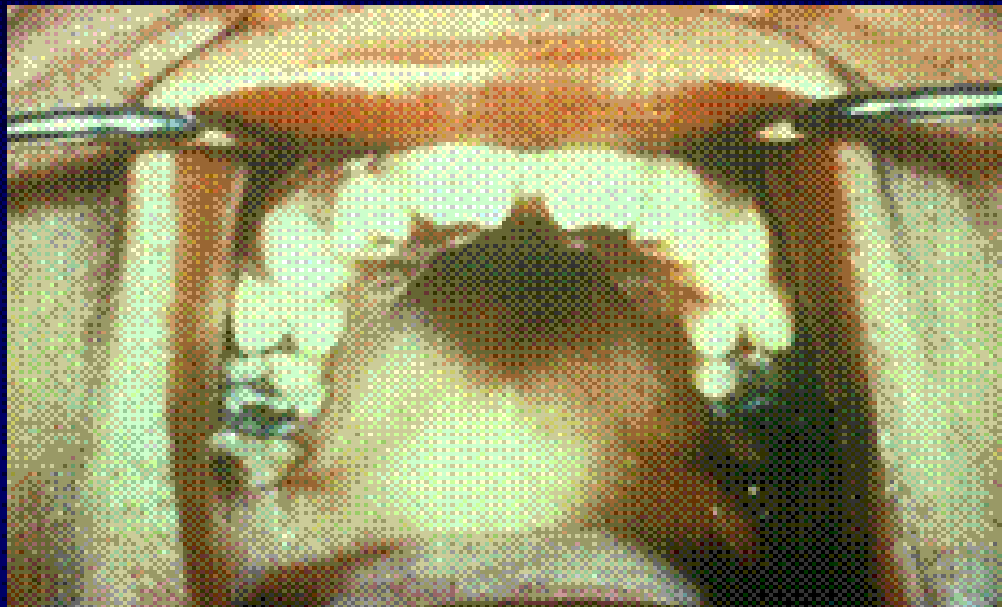
Hutchinson incisors

screwdriver-shaped central incisors seen in congenital syphilis

Syphilis Curriculum

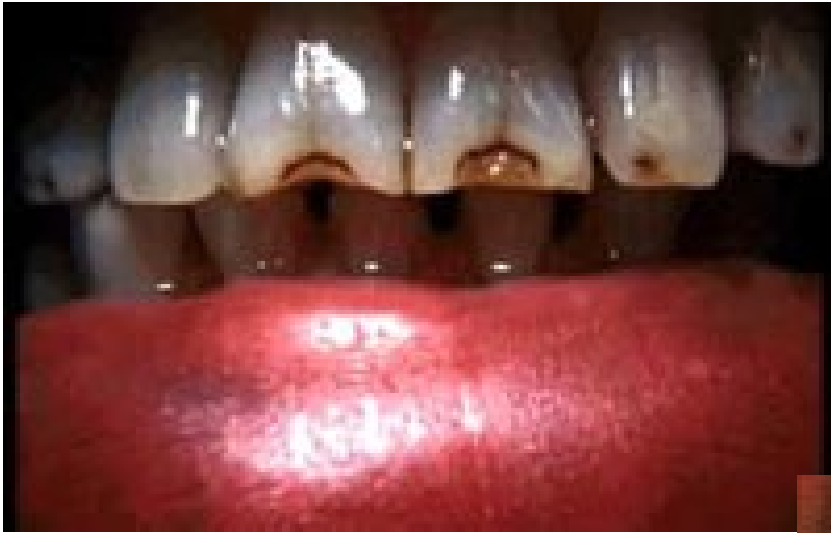Clinical Manifestations

Congenital Syphilis - Hutchinson's Teeth



Source: © DC/ NC HSTP/ Division of STD Prevention, STD Clinical Slides

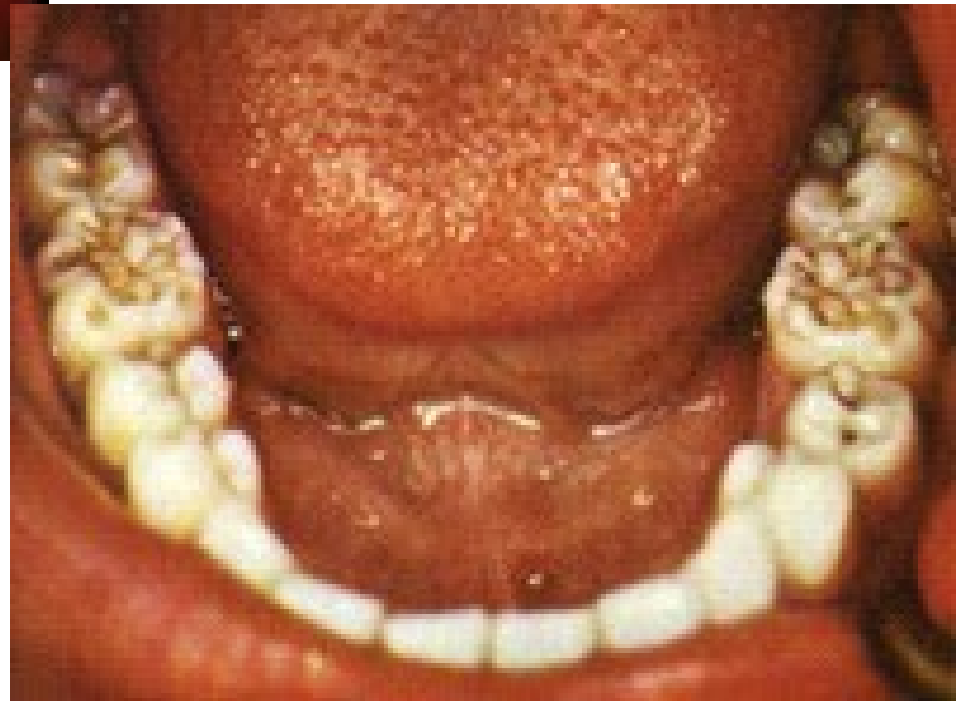


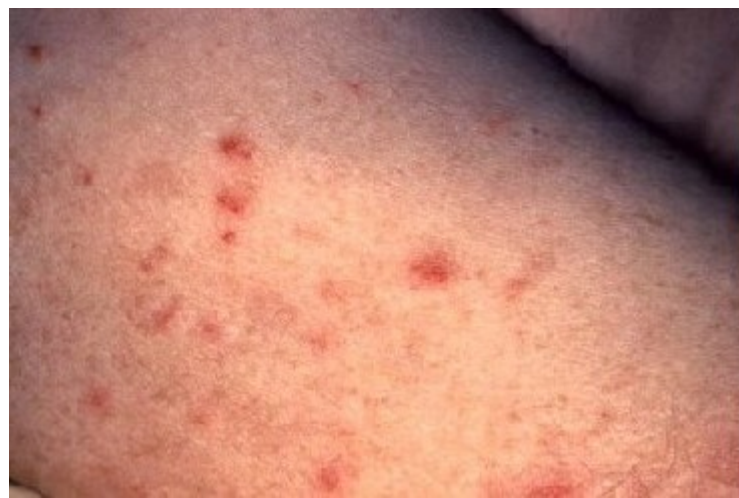
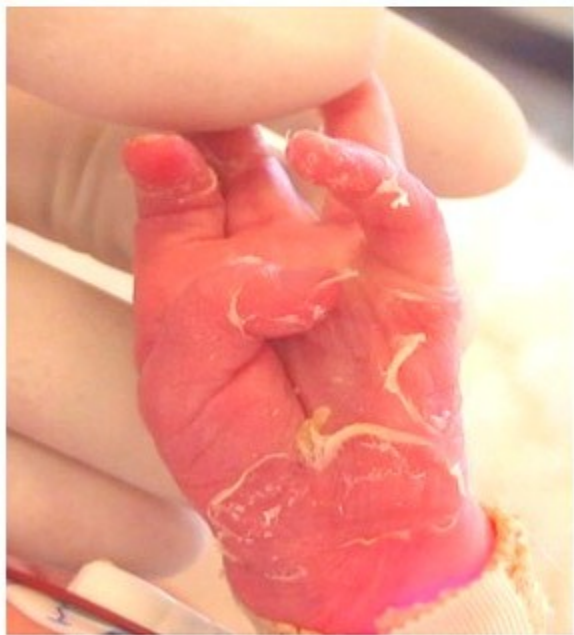
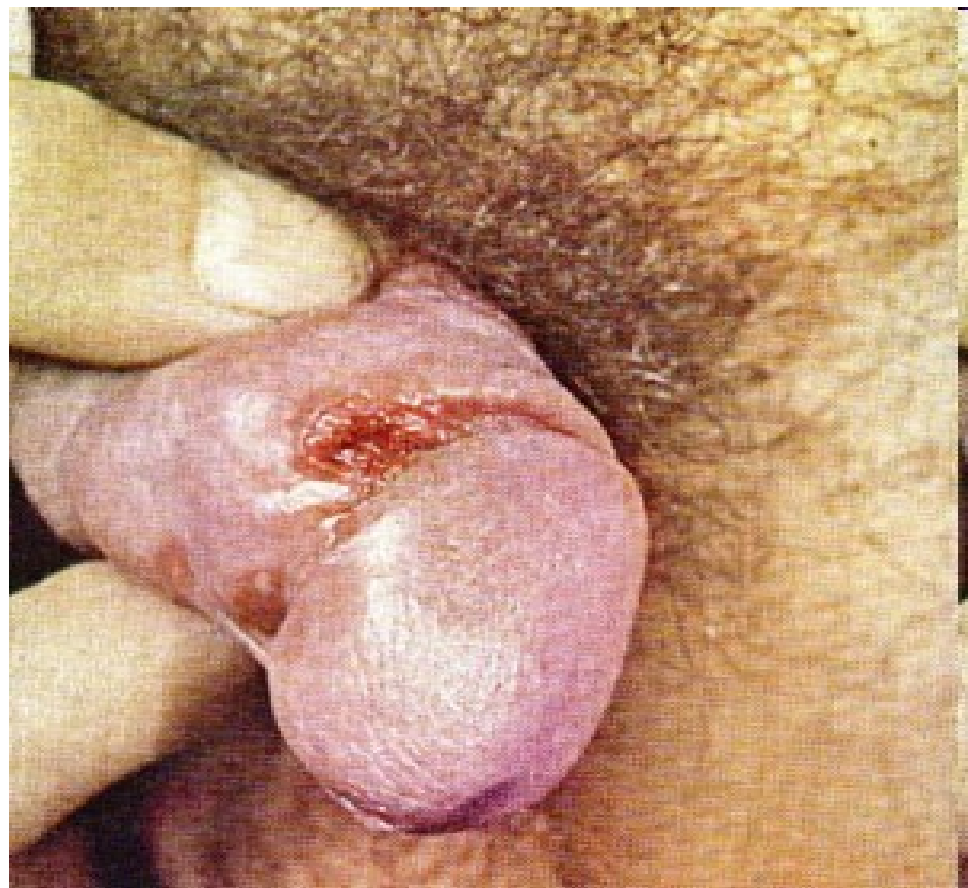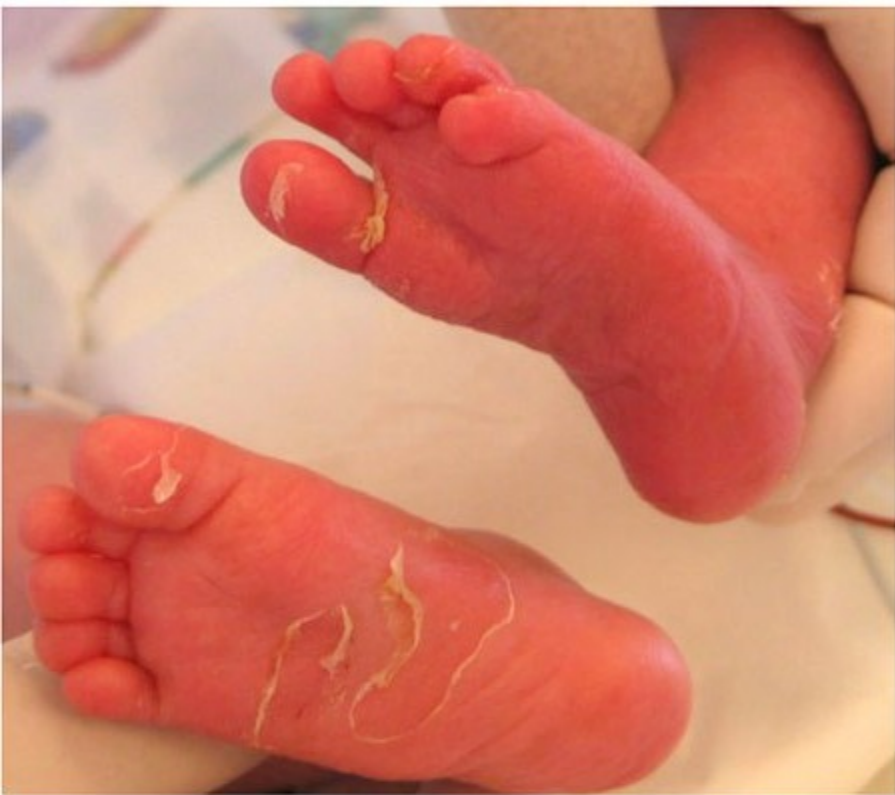**Hutchinson incisors
(left)**

mulberry molars (right)

- a first molar tooth whose occlusal surface is pitted due to congenital syphilis with nodules replacing the cusps





Syphilis: laboratory dg – I

Direct detection

From lesions (mostly *ulcus durum*)

darkfield examination

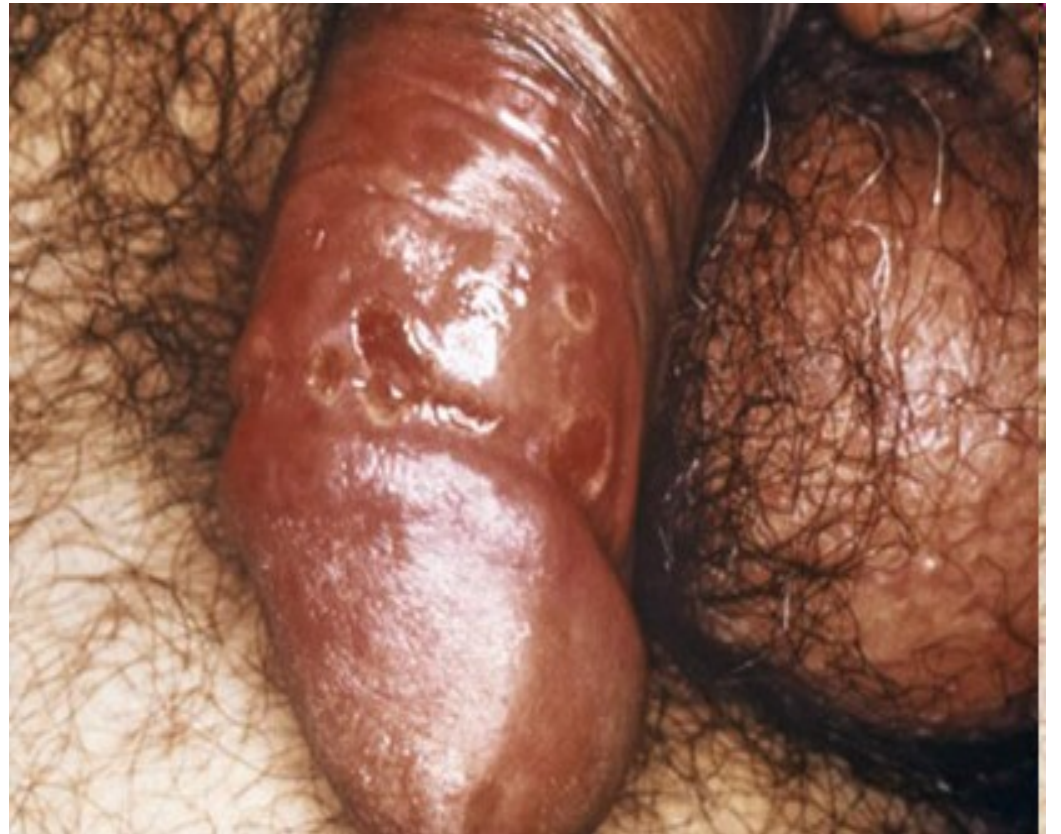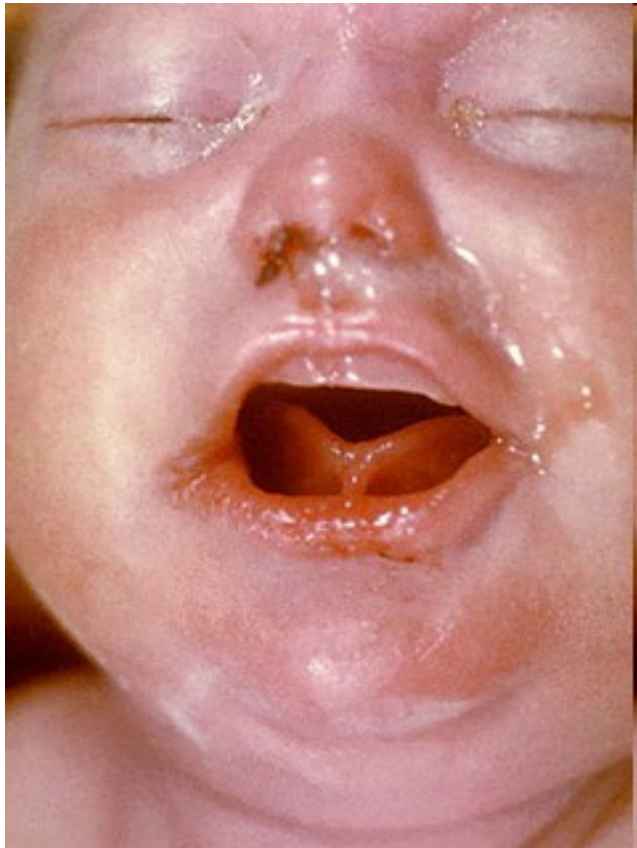PCR

immunofluorescence

Indirect detection (serology)

with nonspecific antigen (**cardiolipin**)

with specific antigen (***Treponema pallidum***)



Syphilis: laboratory dg – II

Nontreponemal:

RRR, VDRL, RPR

biologically fals positive

Treponema :

TPHA, ELISA, WB, FTA-ABS, TPIT

sensitive, specific, positive for life

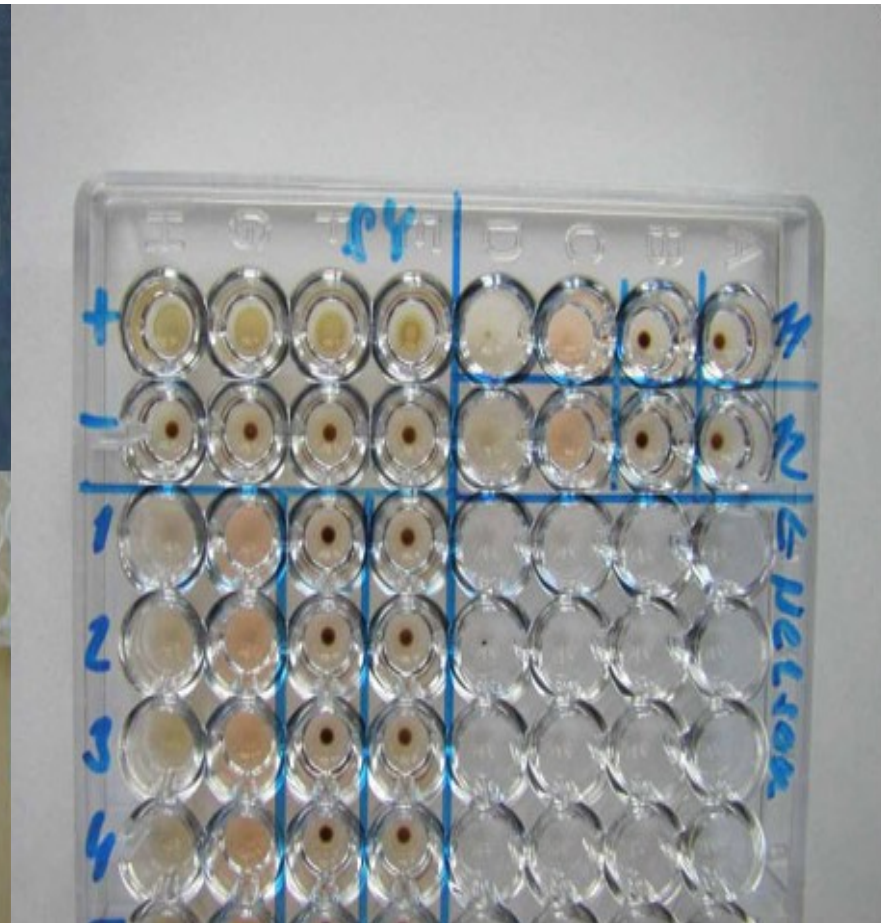
a Blood Test for all



PROTECTS YOU
against Syphilis

Poster, 1940

Screening: **cardiolipin test (RPR) + TPHA**



Gerrit van Honthorst (1590-1656): Dentist (1622)

