

**Institute for Microbiology, Medical Faculty of Masaryk University
and St. Anna Faculty Hospital in Brno**

Miroslav Votava, Vladana Woznicová

Skin infections

Infections with skin symptoms

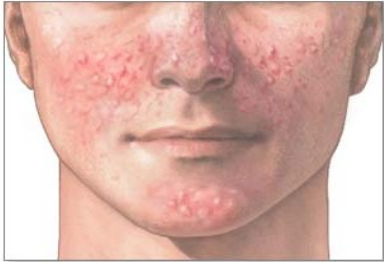
- **primary skin infections**
- **secondary infections of already diseased skin**
- **skin symptoms of systemic infections**

Etiology: - bacterial
- viral
- fungal
- parasitic

Bacterial skin infections

Primary acute bacterial skin infections – I

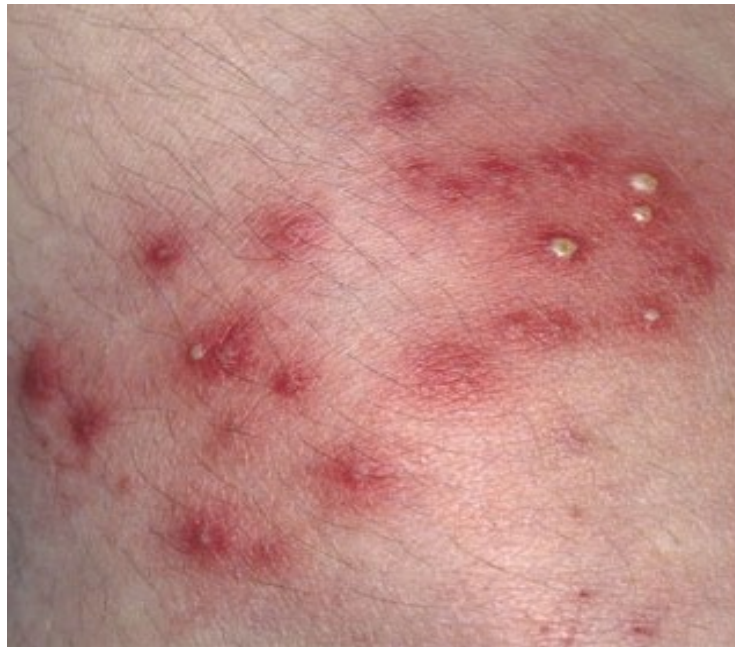Adult facial acne



***Propionibacterium acnes* – acne vulgaris**

***Staphylococcus aureus* - folliculitis**

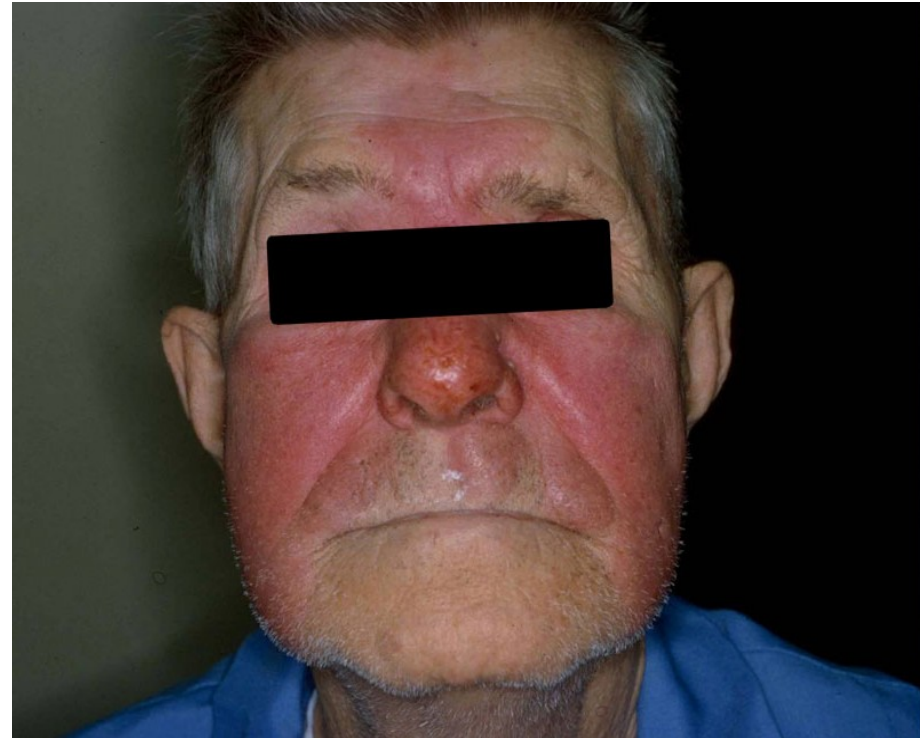ADAM.



Primary acute bacterial skin infections – II

erysipelas – *Streptococcus pyogenes* (GAS)

- local redness, heat, swelling, and a highly characteristic raised, indurated border, **no localized purulence**
- the **legs and face** are the most frequently affected sites
- on the face is a **butterfly distribution** involving the cheeks and the bridge of the nose



Primary acute bacterial skin infections – III

hordeolum (stye)

– *Staph. aureus*

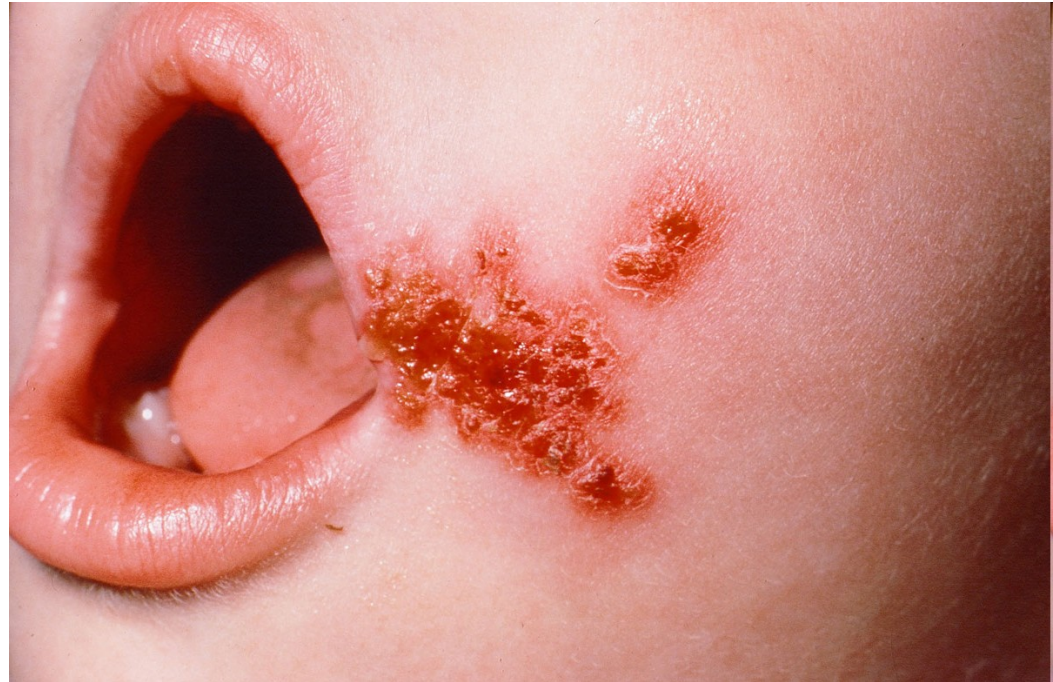Impetigo ! →

- *Staph. aureus*,

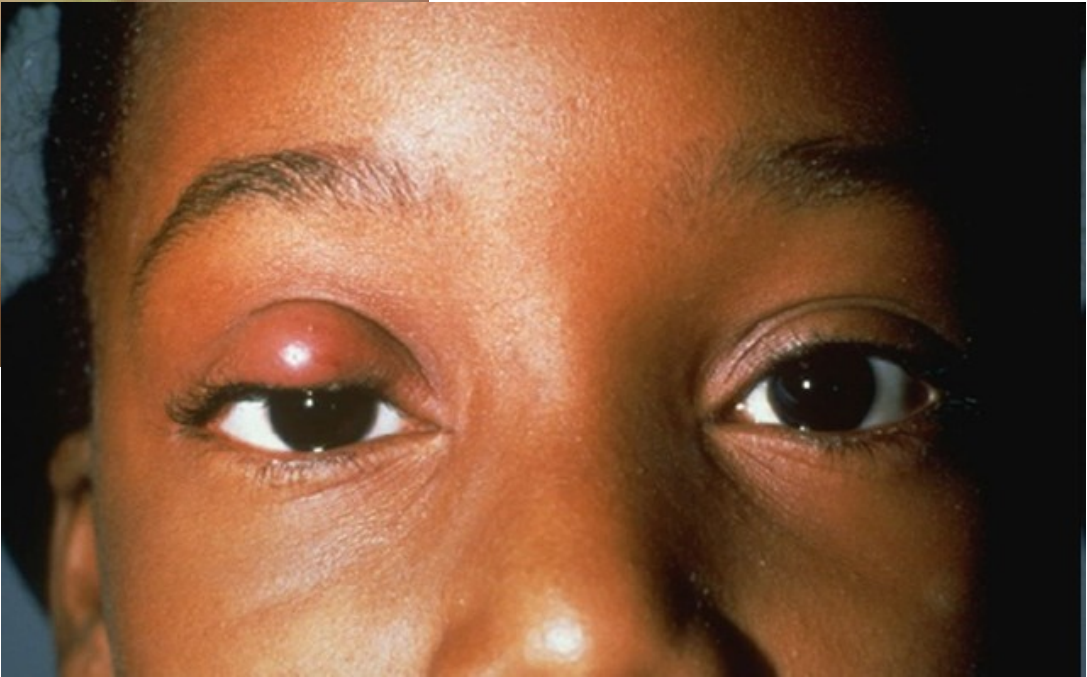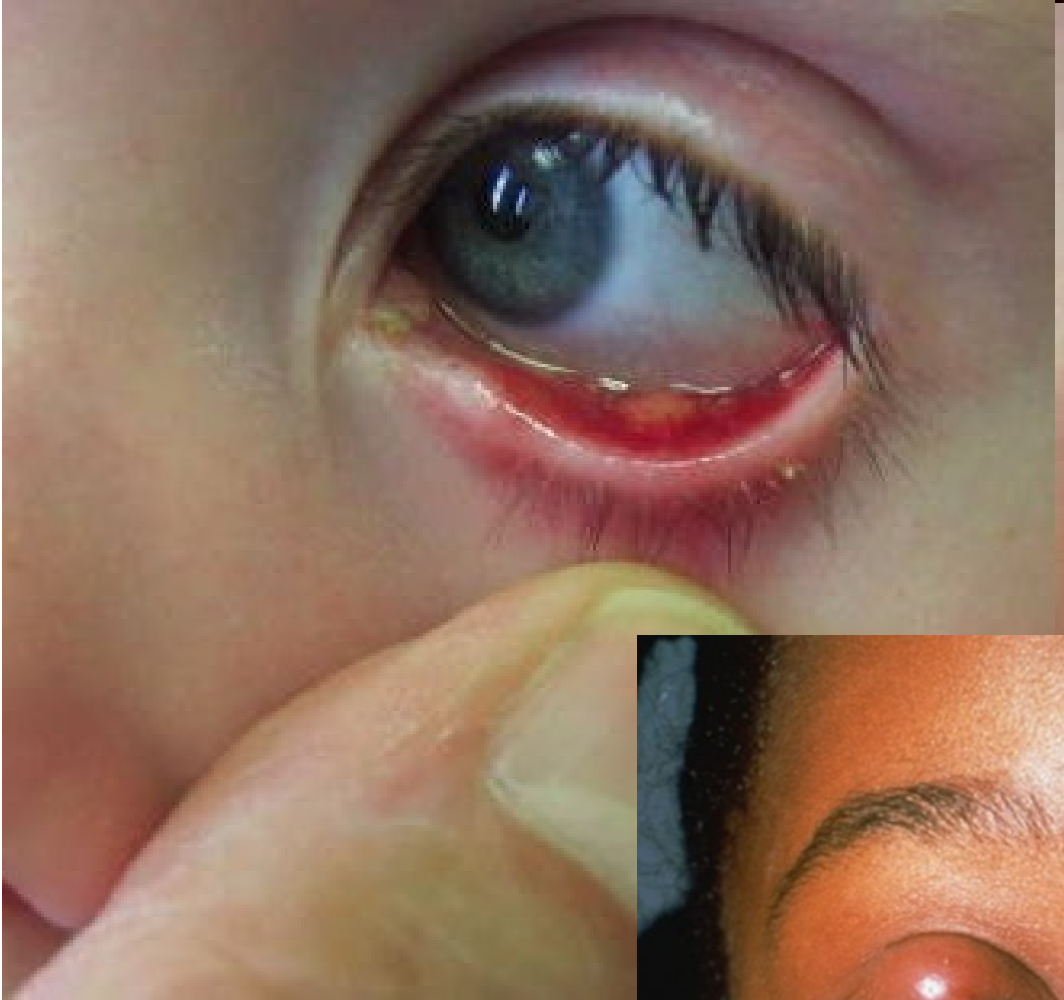- *Str. pyogenes*

lymphangoitis

– *Strept. pyogenes*



Stye



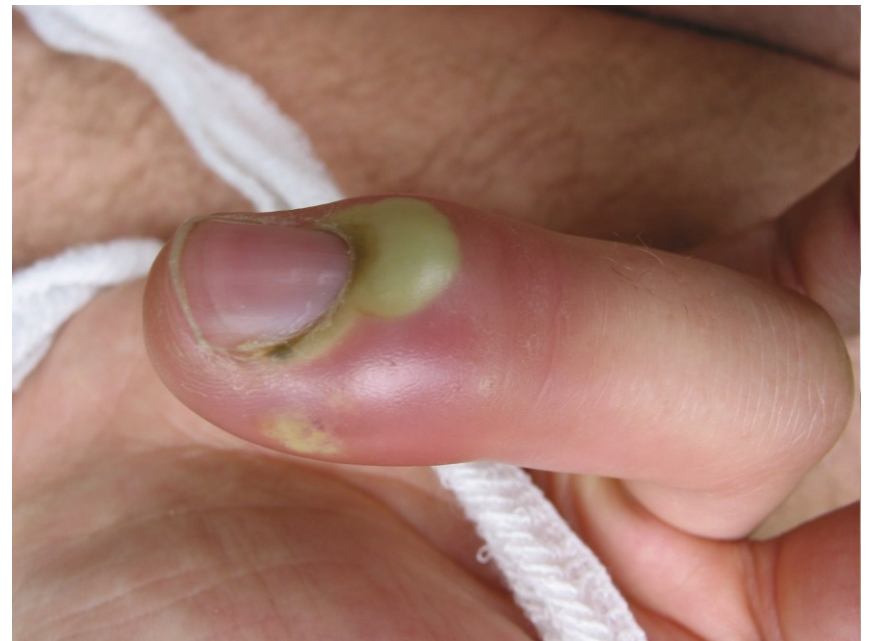Primary acute bacterial skin infections – IV

Panaritium (whitlow)

Staphylococcus aureus

paronychia

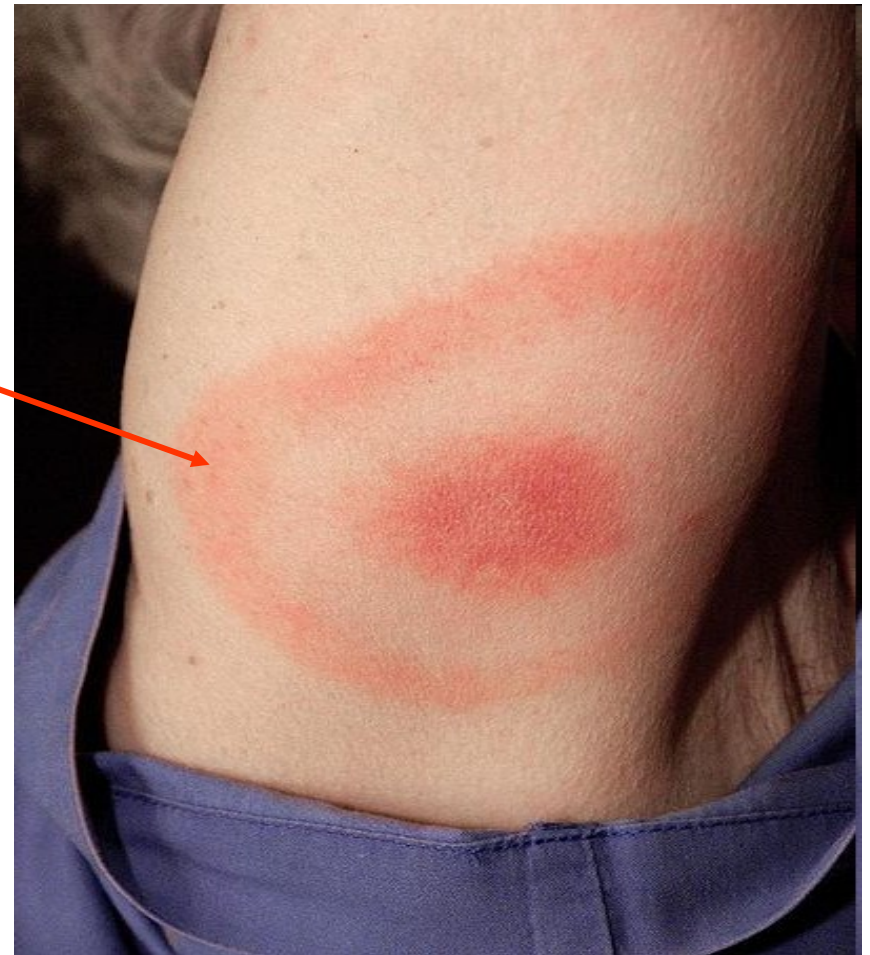Staphylococcus aureus



Primary acute bacterial skin infections – V

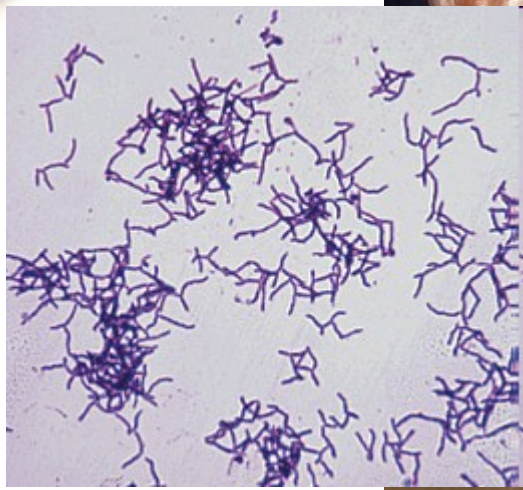
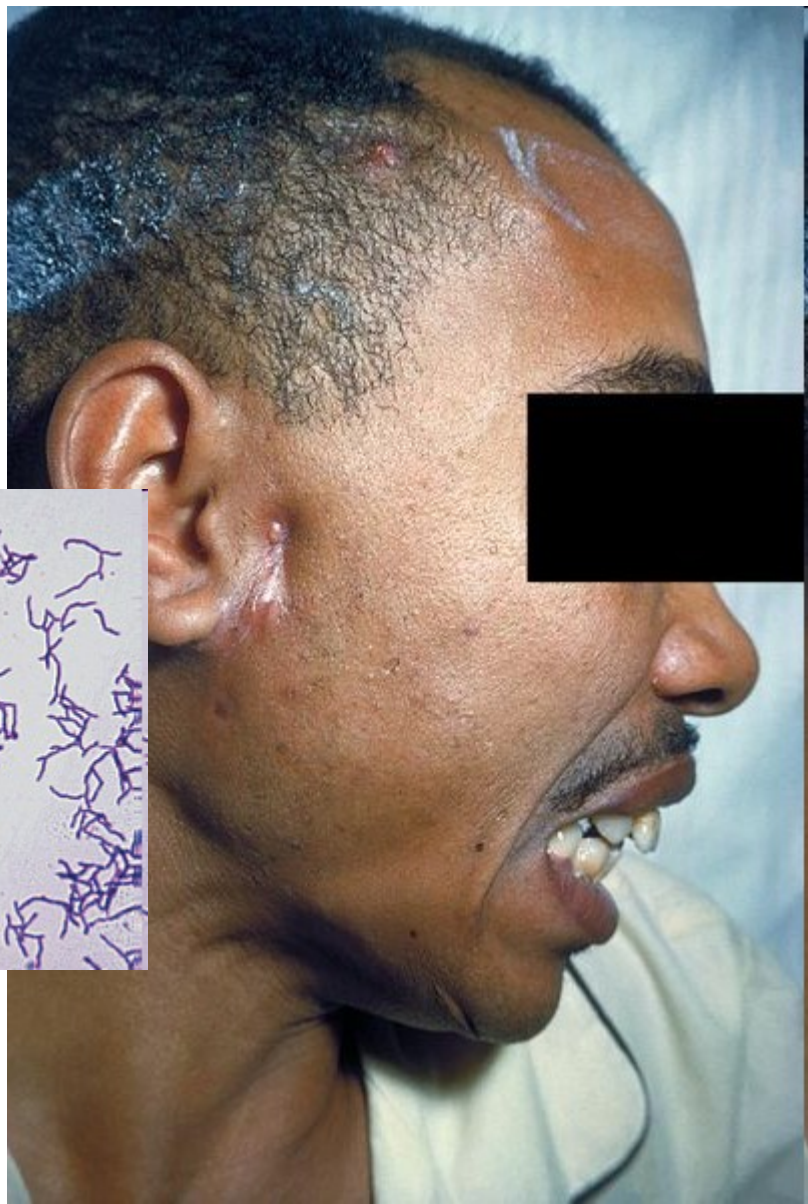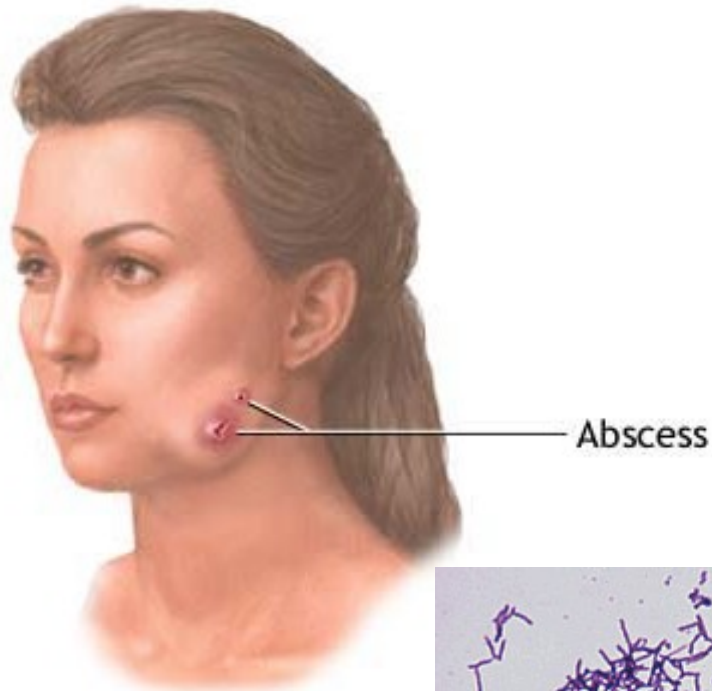
erythema migrans – *Borrelia burgdorferi*

- ticks (*Ixodes ricinus*)
- serology, PCR
- doxycycline in adults



Primary chronic bacterial skin infections

- actinomycosis ! - *Actinomyces israelii*
- **chronic subcutaneous abscesses** -
A. israelii, Nocardia asteroides, Rhodococcus equi
- **skin granulomas** -
Mycobacterium marinum, M. haemophilum, M. chelonae
- **leprosy** - *Mycobacterium leprae*
- *Mycobacterium tuberculosis* – lupus vulgaris



actinomycosis – *Actinomyces israelii*

Skin symptoms of systemic bacterial infections

roseola (rash in typhoid fever) – *Salmonella Typhi*

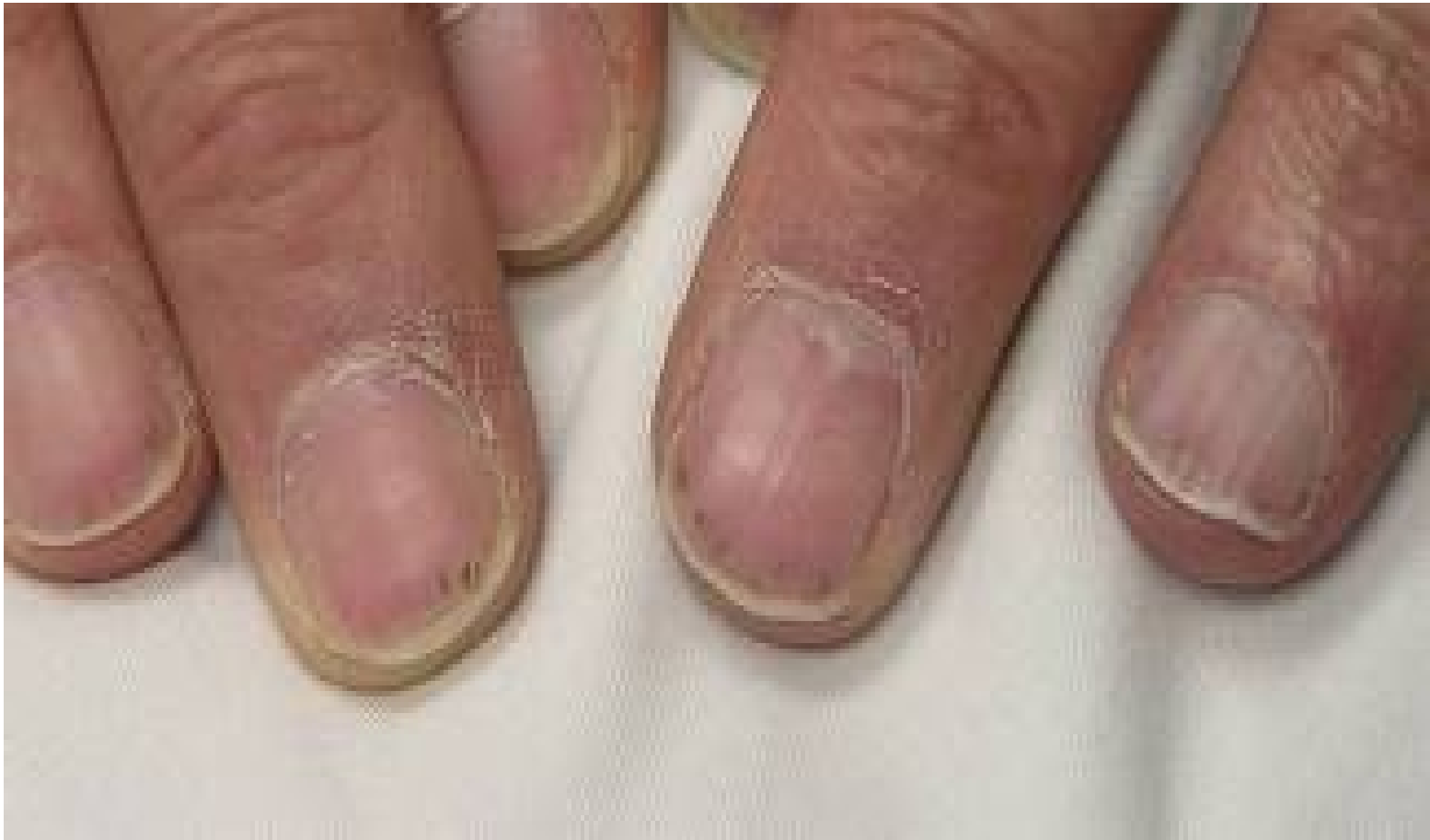disseminated gonorrhoea – *Neisseria gonorrhoeae*

meningococemia – *Neisseria meningitidis*

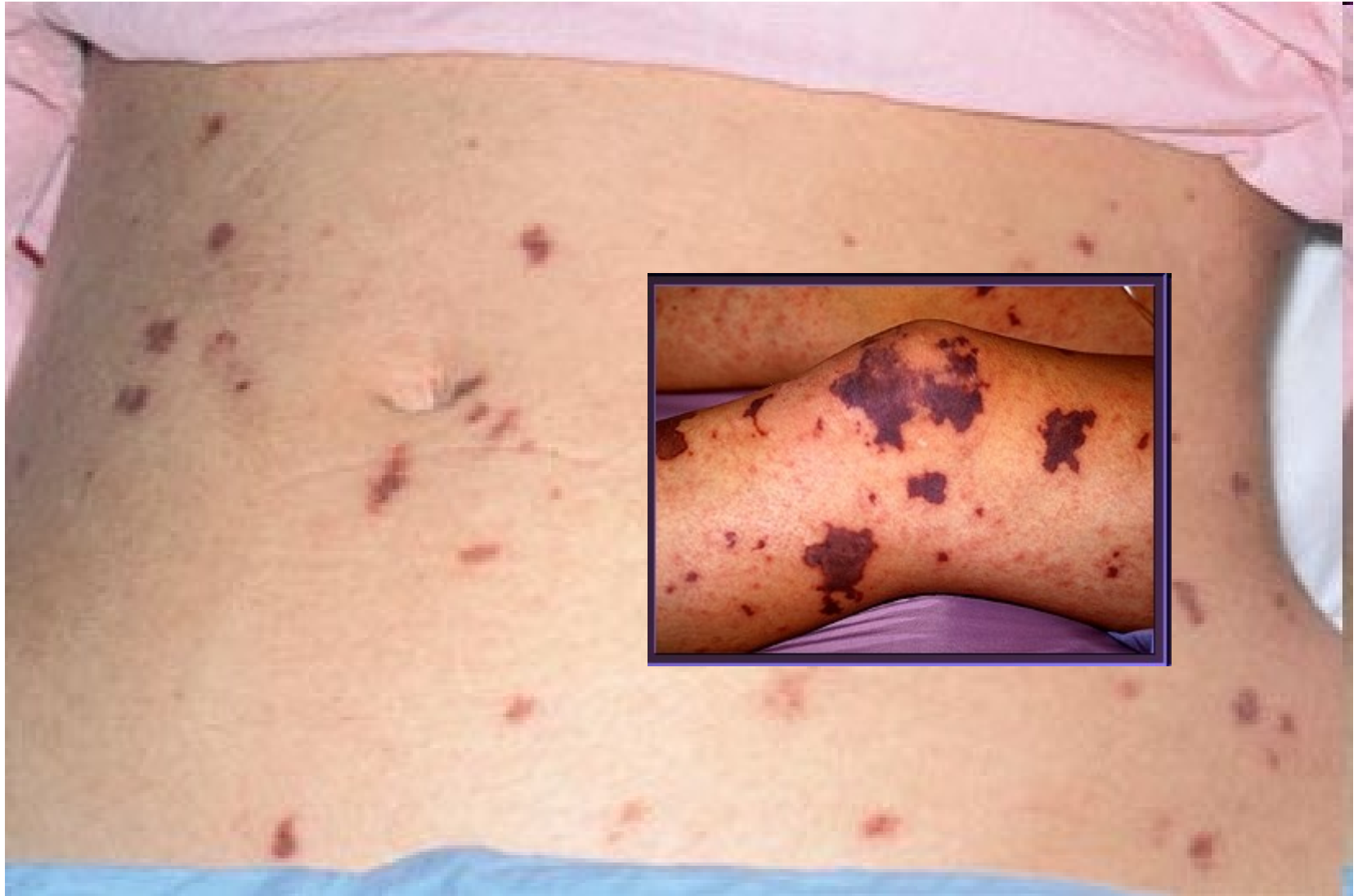scarlatina (scarlet fever) – *Streptococcus pyogenes*

syphilis – *Treponema pallidum*

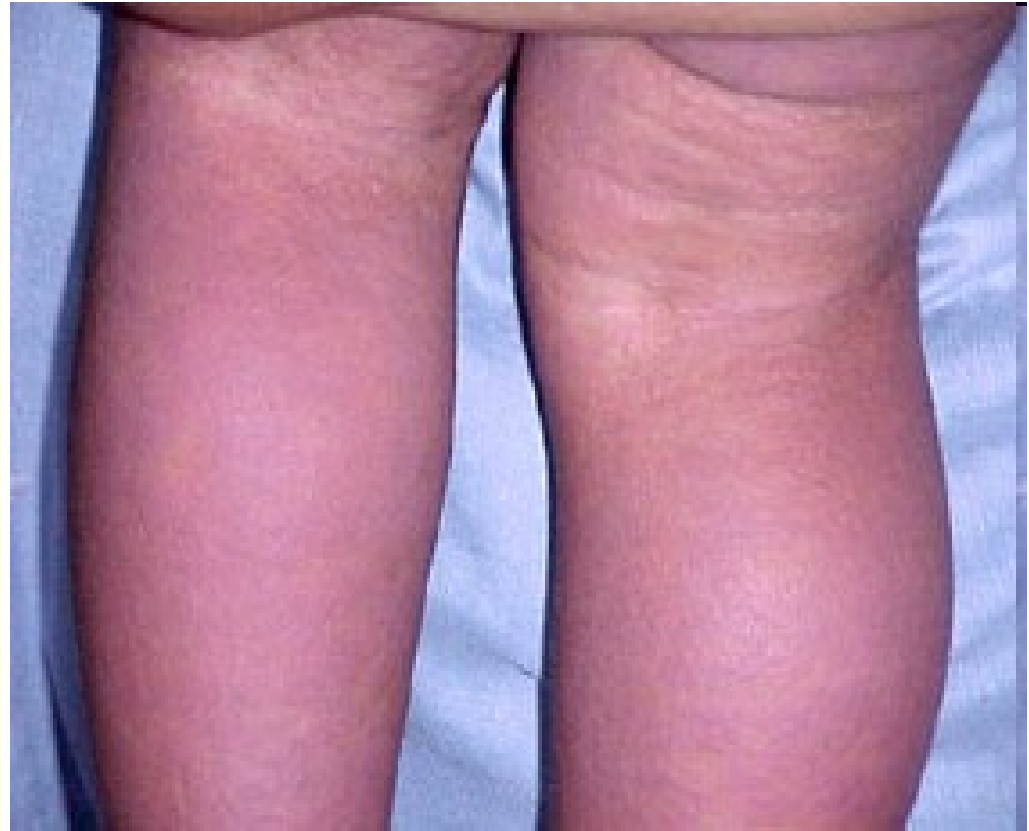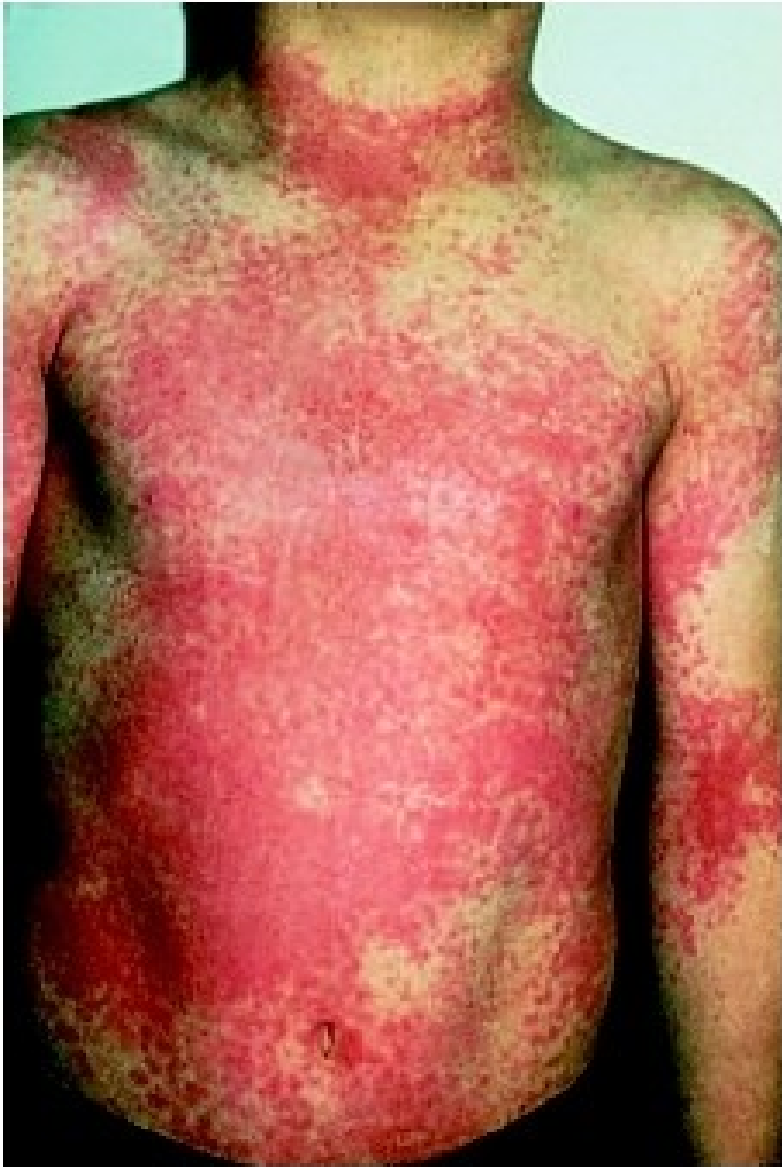Infective endocarditis – splinter haemorrhages



hopkinsvasculitis.org
g

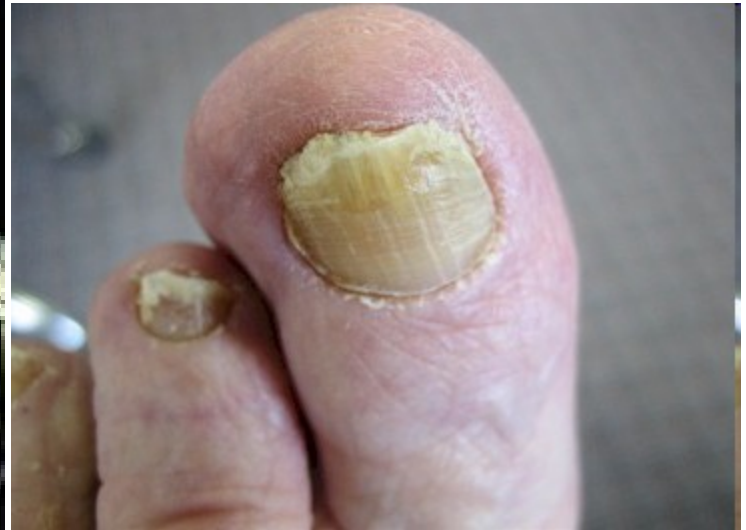
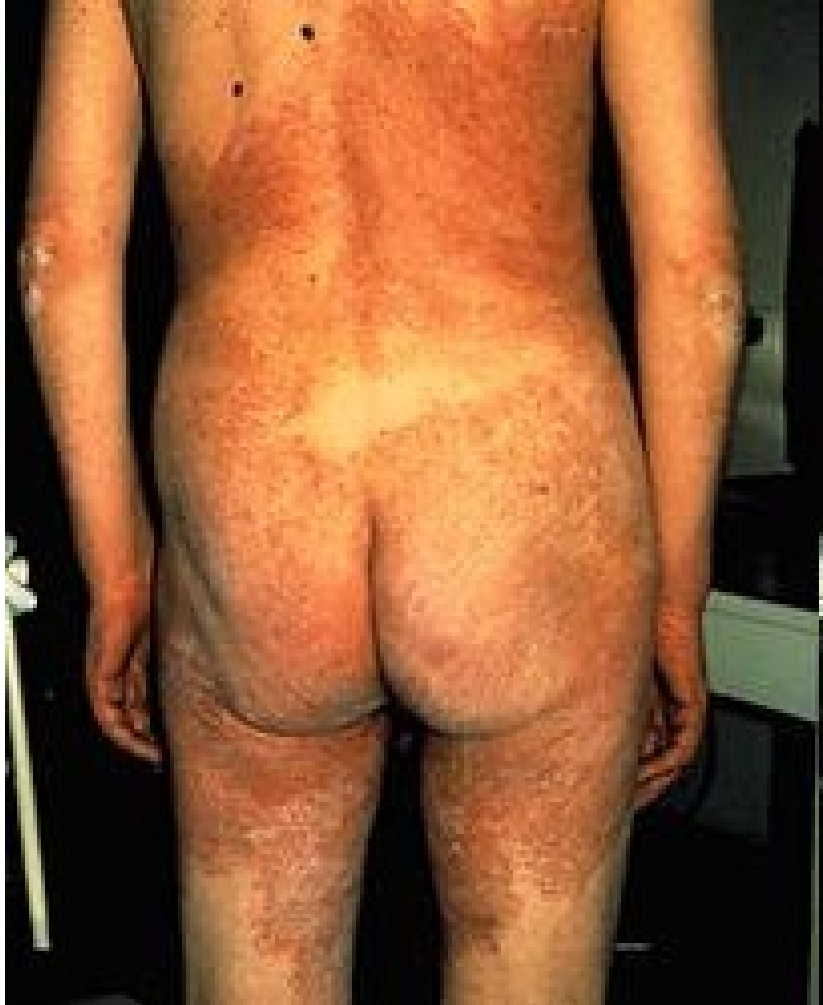
Rash - meningococemia – *Neisseria meningitidis*



scarlatina (scarlet fever) – *Streptococcus pyogenes*

Fungal infections



cutaneous mycoses

Etiology of cutaneous mycoses

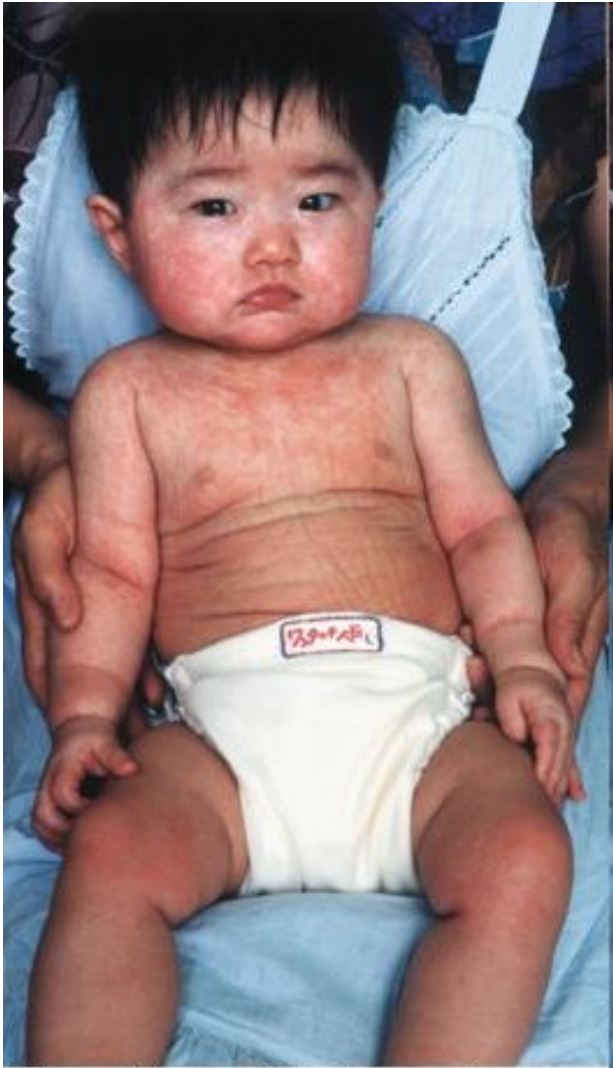Tinea pedis – *Trichophyton rubrum*,
Trich. mentagrophytes var. *interdigitale*,
Epidermophyton floccosum

Onychomycosis – *T. rubrum*, *E. floccosum*

Tinea corporis – *T. rubrum*, *Microsporum canis*,
M. gypseum, *E. floccosum*

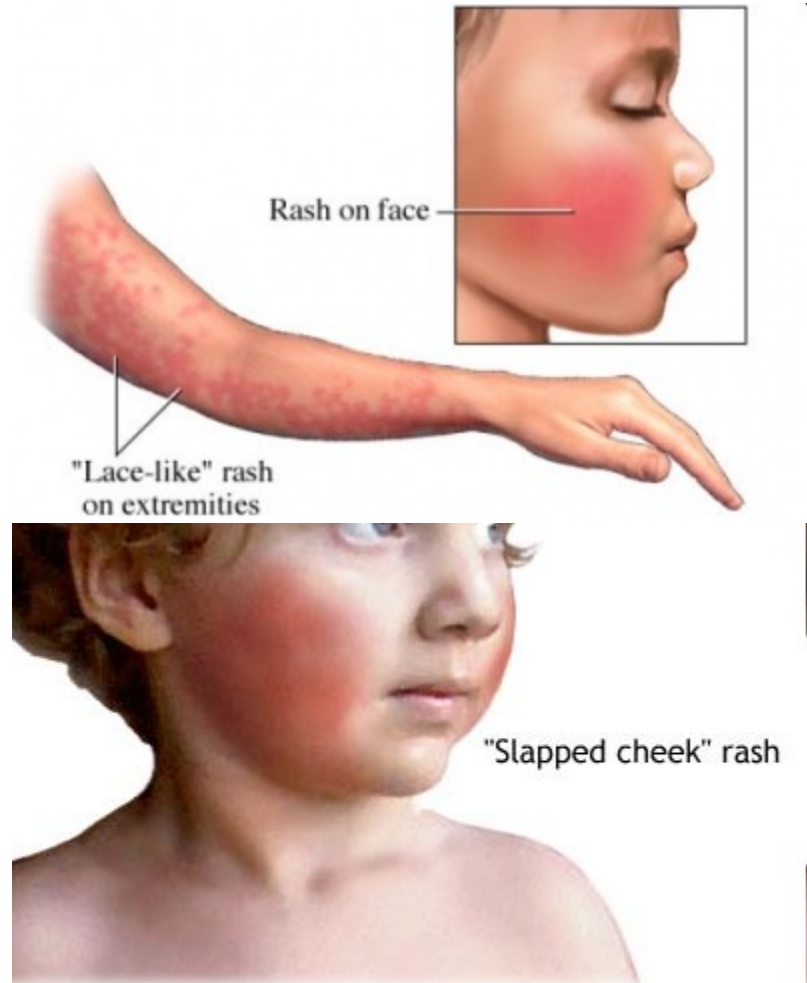
Tinea capitis – *M. gypseum*, *M. canis*, *M. audouinii*

Viral infections



Medscape® <http://www.medscape.com>

Sixth Disease/ Exanthem subitum, Roseola infantum, "Sudden Rash", rose rash of infants, 3-day fever



ADAM.

Fifth Disease/Erythema infectiosum - Erythrovirus (Parvovirus) B19

Skin symptoms in viral diseases – I

Macular (spotted) exanthem:

morbilli – morbilli virus, *Morbillivirus* genus

rubella – rubella virus, *Rubivirus* genus

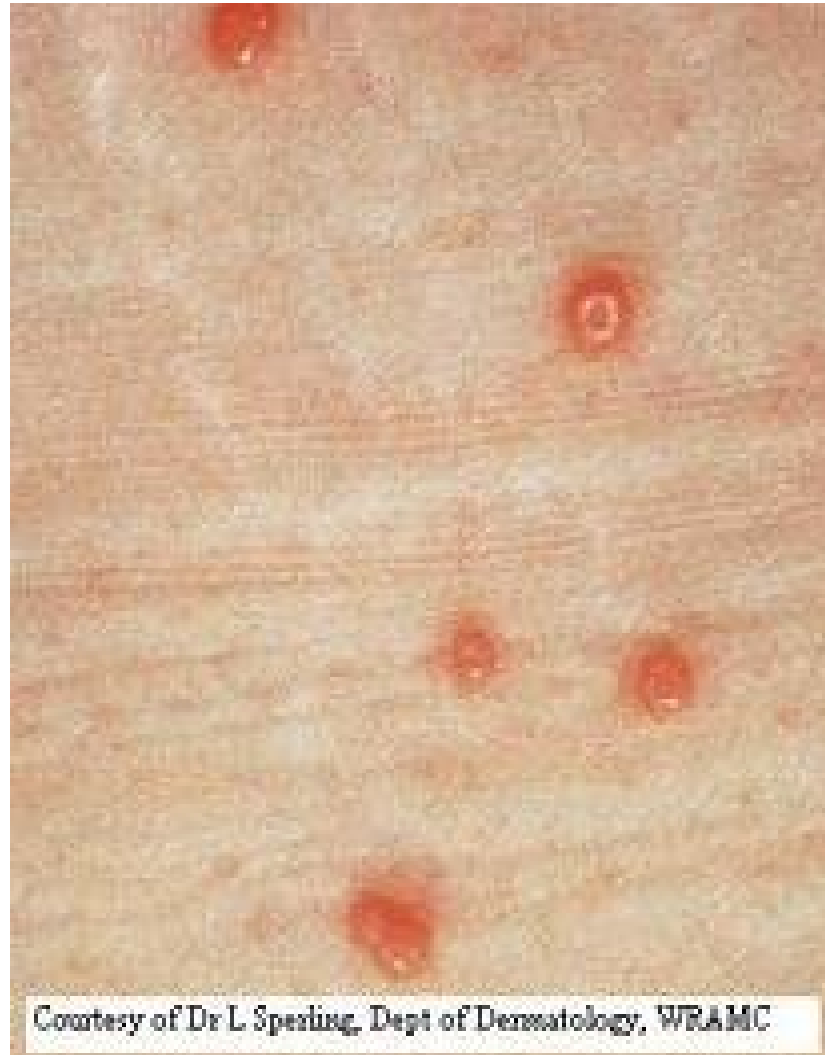erythema infectiosum (the **fifth** disease) –
parvovirus B19, *Erythrovirus* genus

exanthema subitum (roseola infantum, the **sixth**
disease) – HHV 6, *Roseolovirus* genus

Umbiliform papulae:

molluscum contagiosum – molluscum
contagiosum virus, *Molluscipoxvirus* genus

Typical molluscum bumps. Note the pearly appearance and the dimple in the center of the bumps.

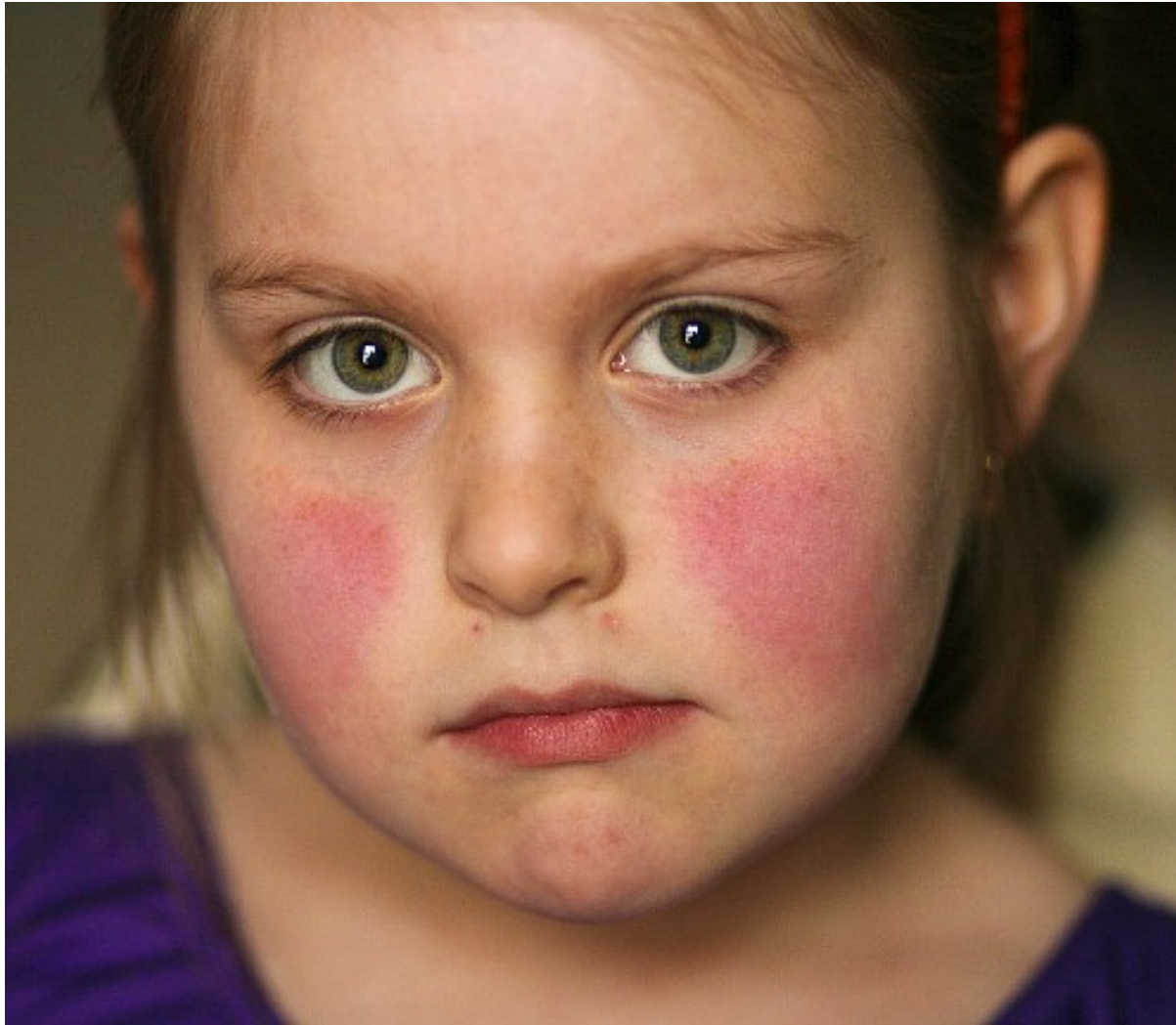

Courtesy of Dr L. Sperling, Dept of Dermatology, WRAMC

[cdc.gov](https://www.cdc.gov)

v

Fifth Disease/Erythema infectiosum



<http://img405.imageshack.us>

Skin symptoms in viral diseases – II

Vesicles:

herpes simplex (cold sore) – HSV 1

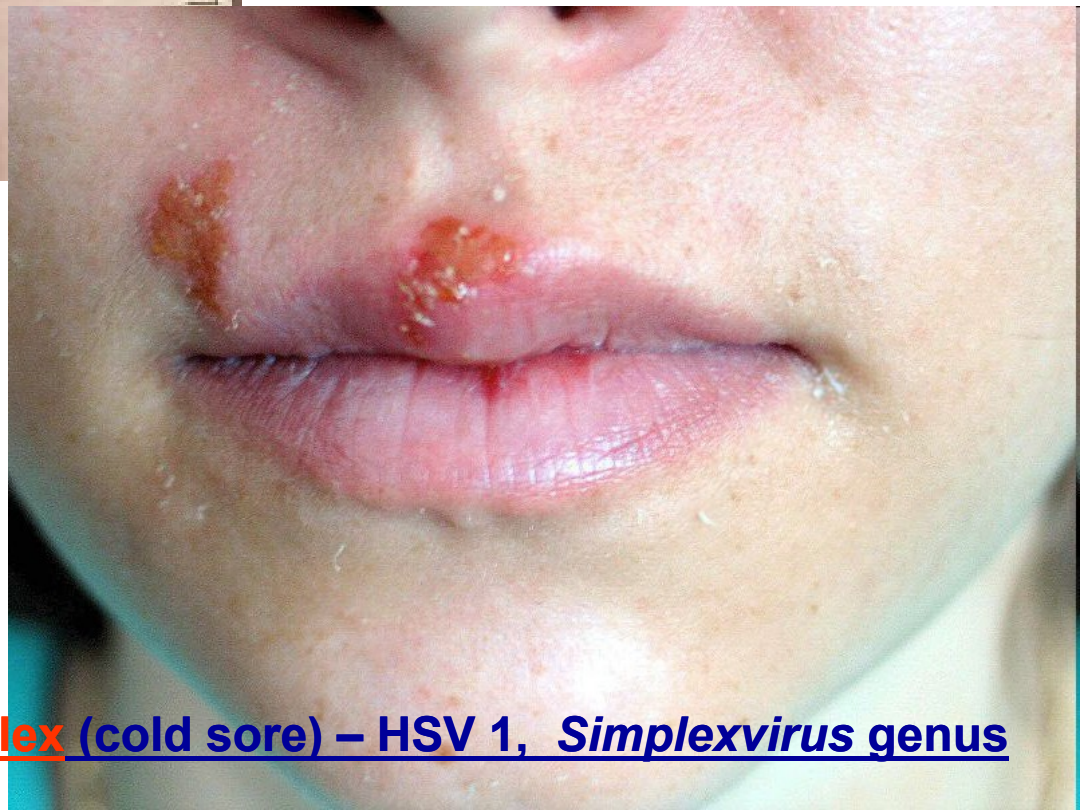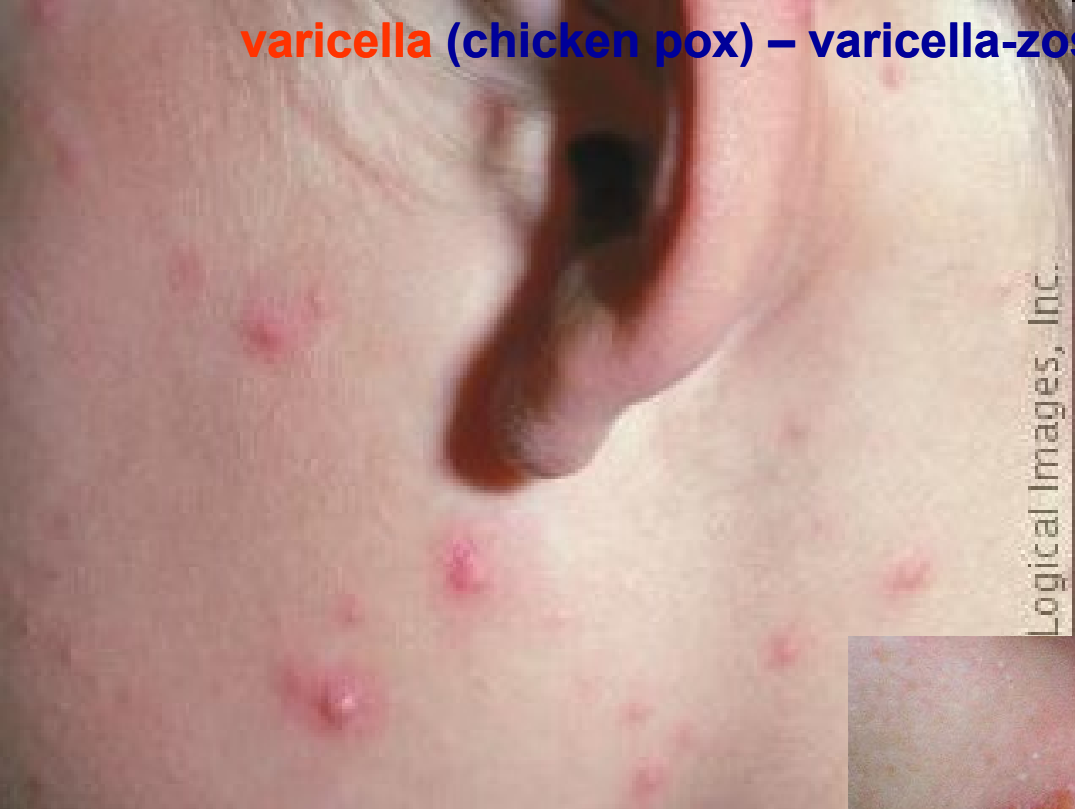herpes genitalis – HSV 2

varicella (chicken pox) – varicella-zoster virus, VZV

herpes zoster (shingles) – VZV

hand, foot and mouth disease – coxsackievirus

varicella (chicken pox) – varicella-zoster virus, VZV, *Varicellovirus* genus



herpes simplex (cold sore) – HSV 1, *Simplexvirus* genus

Skin symptoms in viral diseases – III

Petechiae:

Hemorrhagic fevers –

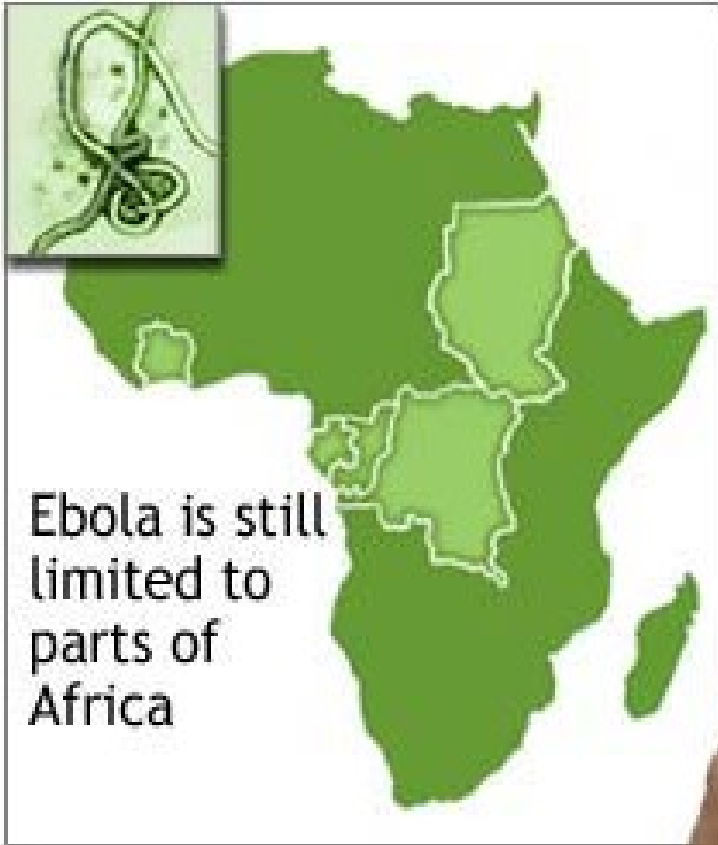Ebola fever, Ebola virus

Marburg disease, Marburg virus

Lassa fever, Lassa virus

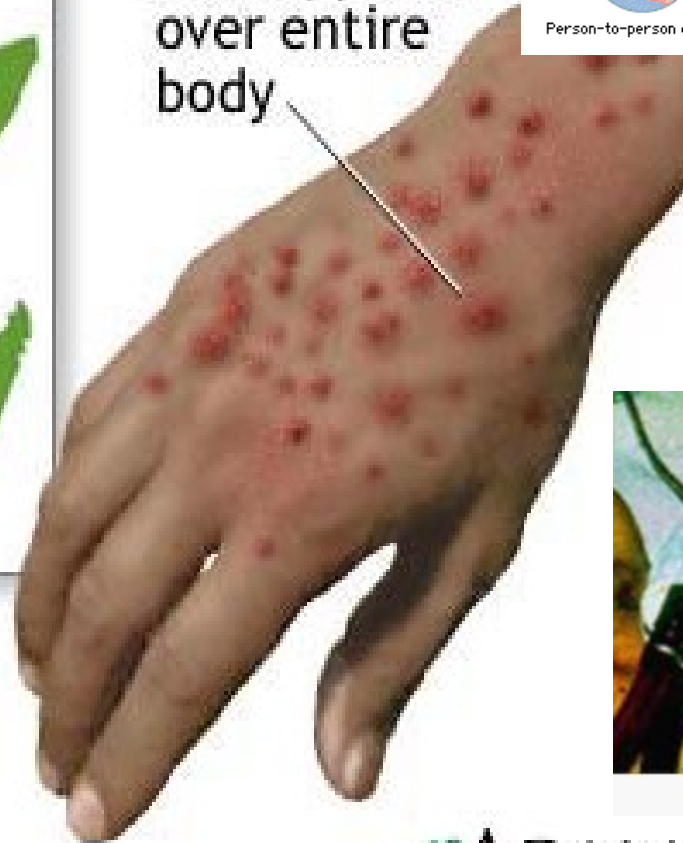Generalized congenital cytomegalic disease –

cytomegalovirus, CMV

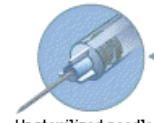

Ebola is still limited to parts of Africa

A hemorrhagic rash appears over entire body



Modes of Infection



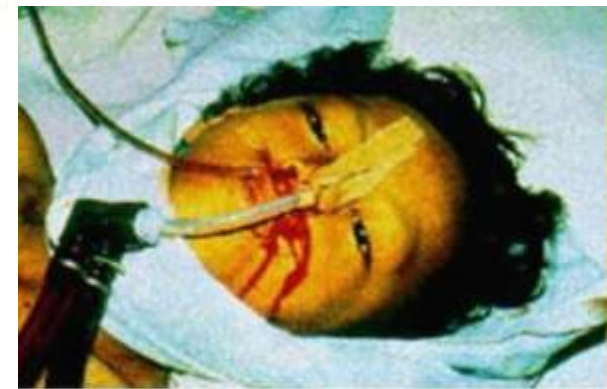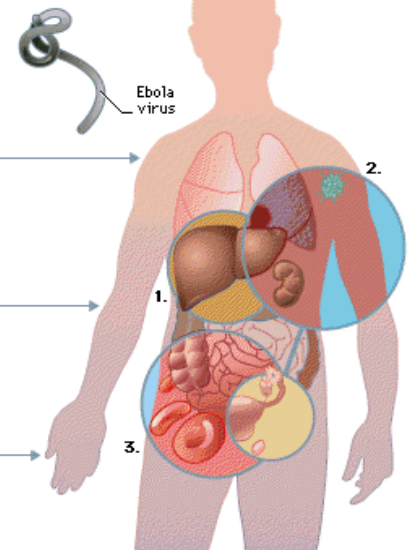
Unsterilized needles



Hospital contagion



Person-to-person contact



Ebola Patient (Intensive Care)

Parasitic infections

Skin symptoms in parasitoses – I

Domestic parasitoses:

scabies – itch mite, *Sarcoptes scabiei*

pediculosis capitis – head louse, *Pediculus capitis*

pediculosis corporis – body louse, *Pediculus humanus* (syn. *Pediculus corporis*)

pediculosis pubis (phthiriasis) – pubic (crab) louse, *Phthirus pubis*

Skin symptoms in parasitoses – II

Infestation by native ectoparasites:

cimicosis – bites by bedbug *Cimex lectularius*

pulicosis – bites by human flea *Pulex irritans*,
dog flea *Ctenocephalides canis*,
cat flea *Ctenocephalides felis*,
chicken flea *Ceratophyllus gallinae*

Skin symptoms in parasitoses – III

Tropical parasitoses:

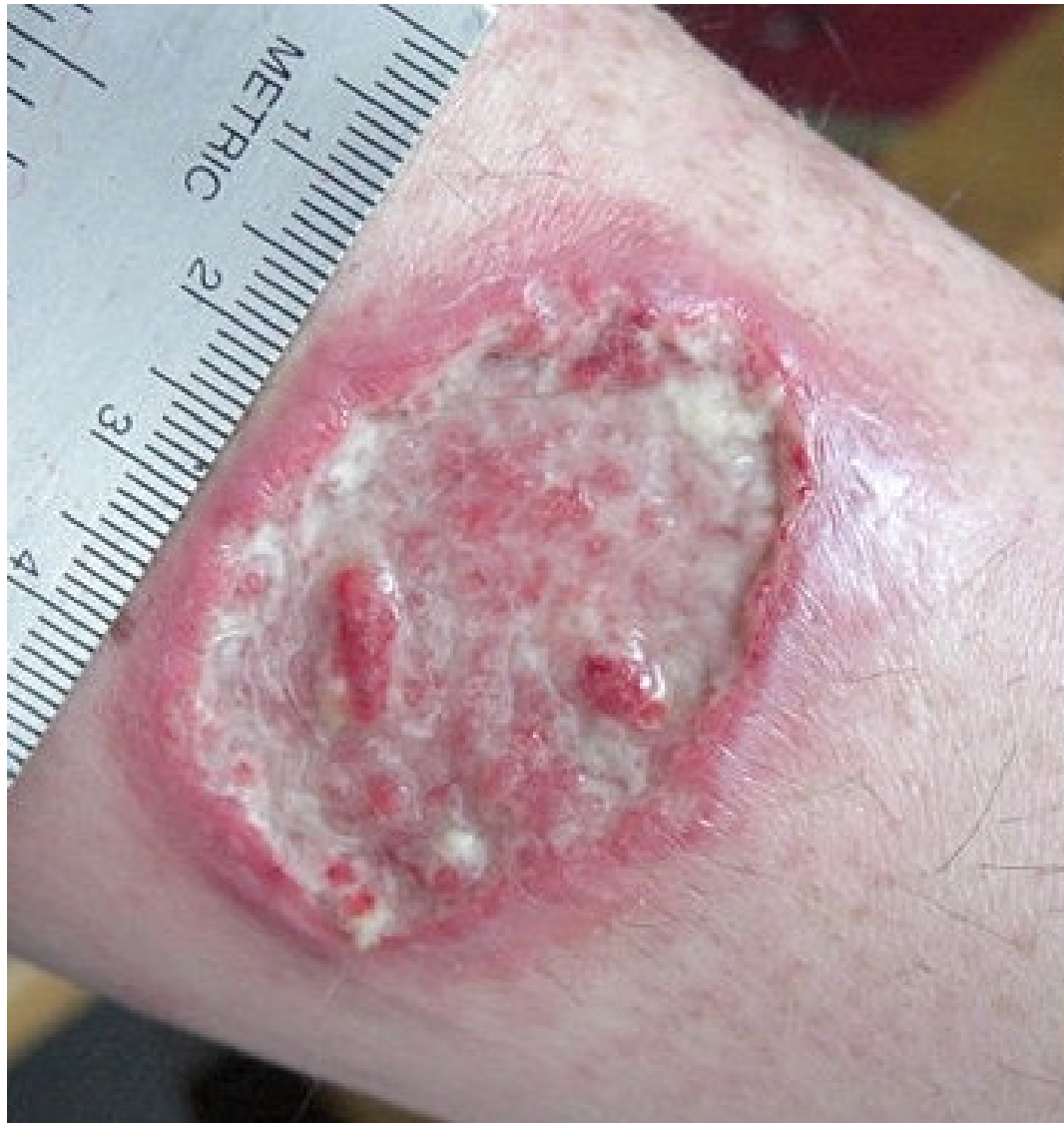ulcus humidum (humid ulcer) – *Leishmania major*

ulcus siccum (dry ulcer) – *Leishmania tropica*

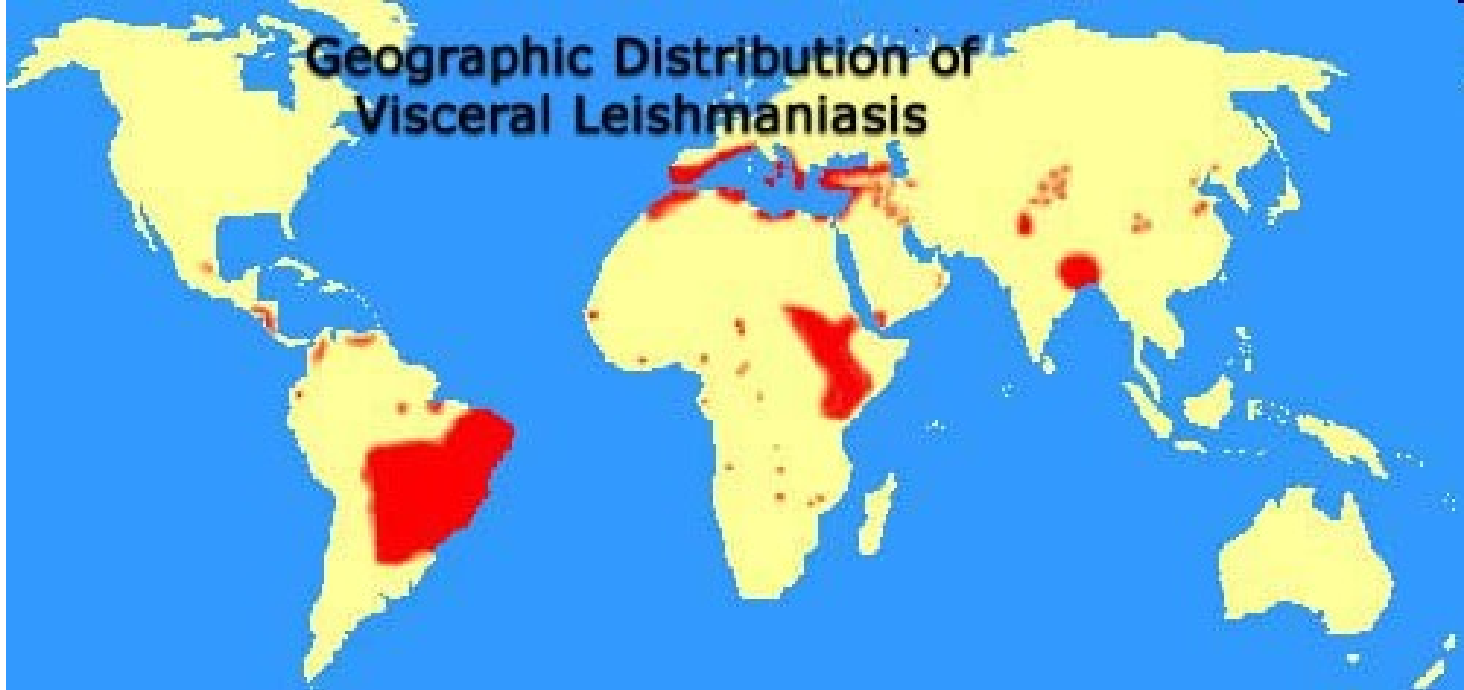dermatitis cercariosa – cercariae of *Schistosoma*,
Bilharziella and *Trichobilharzia* genera

dracunculosis – *Dracunculus medinensis*

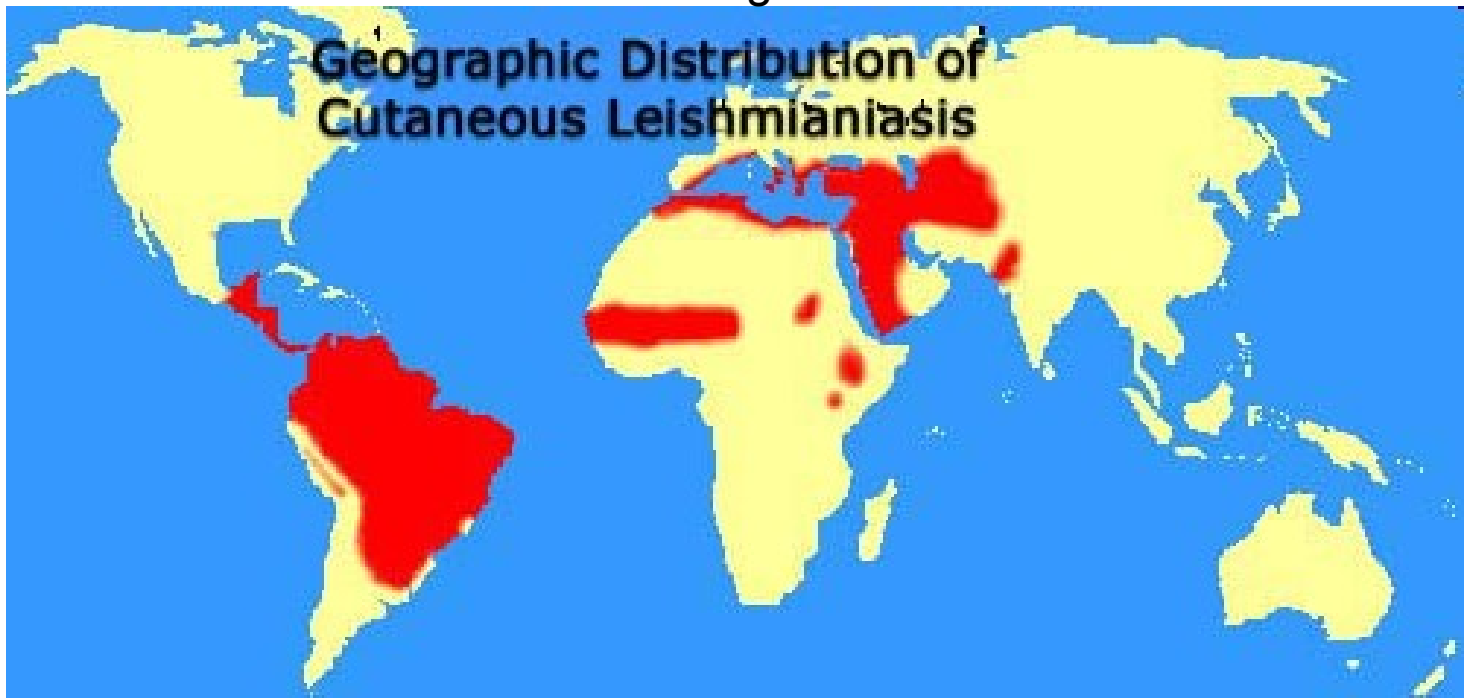
filariosis – filariae *Loa loa* and *Onchocerca volvulus*



Leishmaniasis



www.vet.uga.edu



Edvard Munch (1863-1944): Death in a Room

