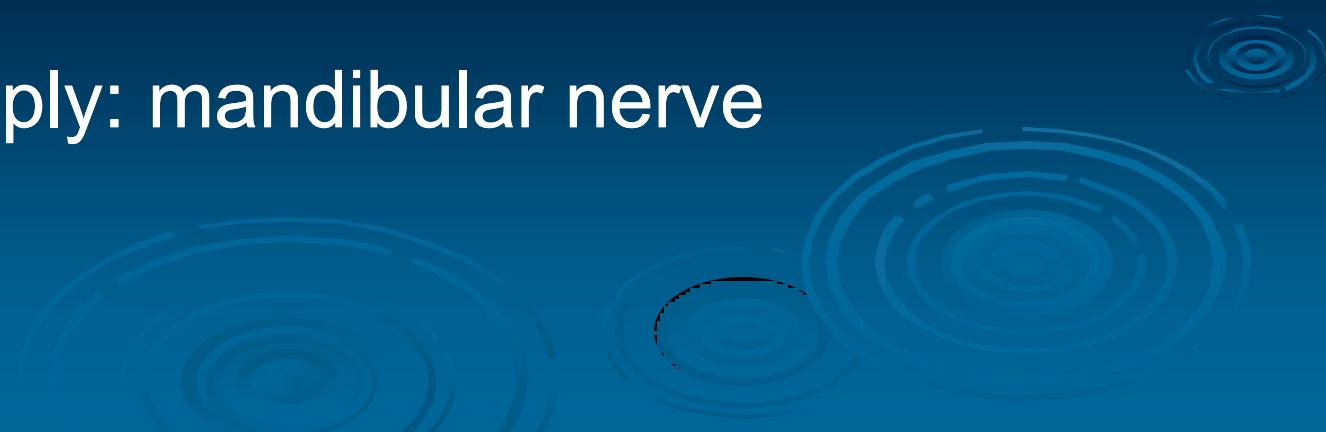


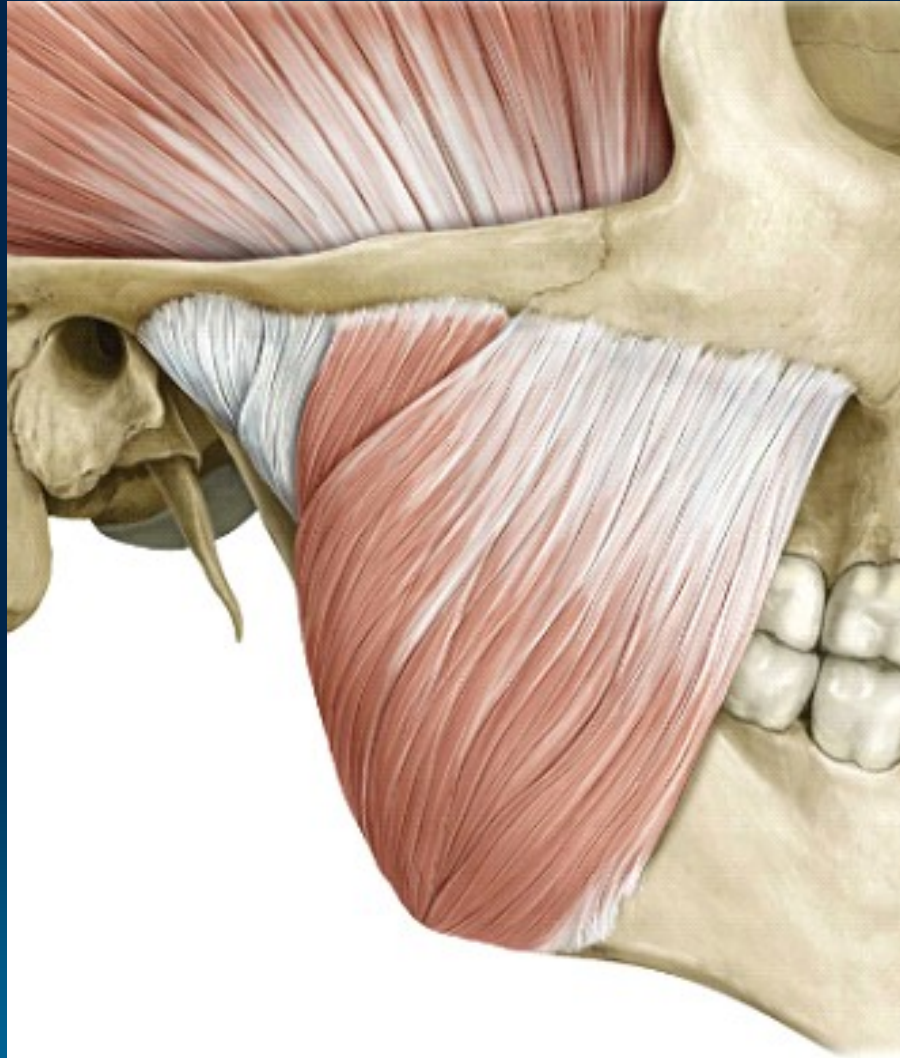MUSCULI MASTICATORII

Muscles of mastication



- 4 pairs of muscles attached to the mandible
 - Movement of temporomandibular joint
 - Arise from the bones of the neurocranium
 - Pennate structure
 - Fasciae
 - Blood supply: maxillary artery
 - Nerve supply: mandibular nerve
- 

Masseter muscle



Thick, quadrilateral muscle
Superficial and deep portion:

The Superficial Portion

Origo: maxillary process of zygomatic bone and the anterior $\frac{2}{3}$ of the lower border of the zygomatic arch

Fibers pass downward and backward

Insertion: *tuberositas masseterica*
(the angle and lower $\frac{1}{2}$ of the lateral surface of the ramus of the mandible)

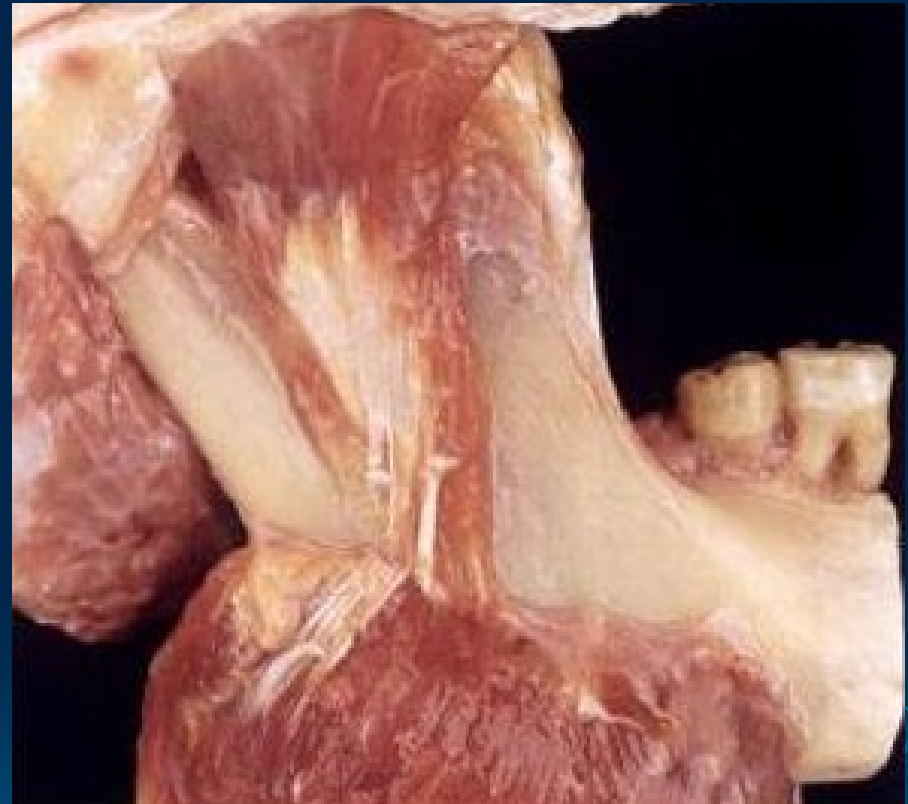
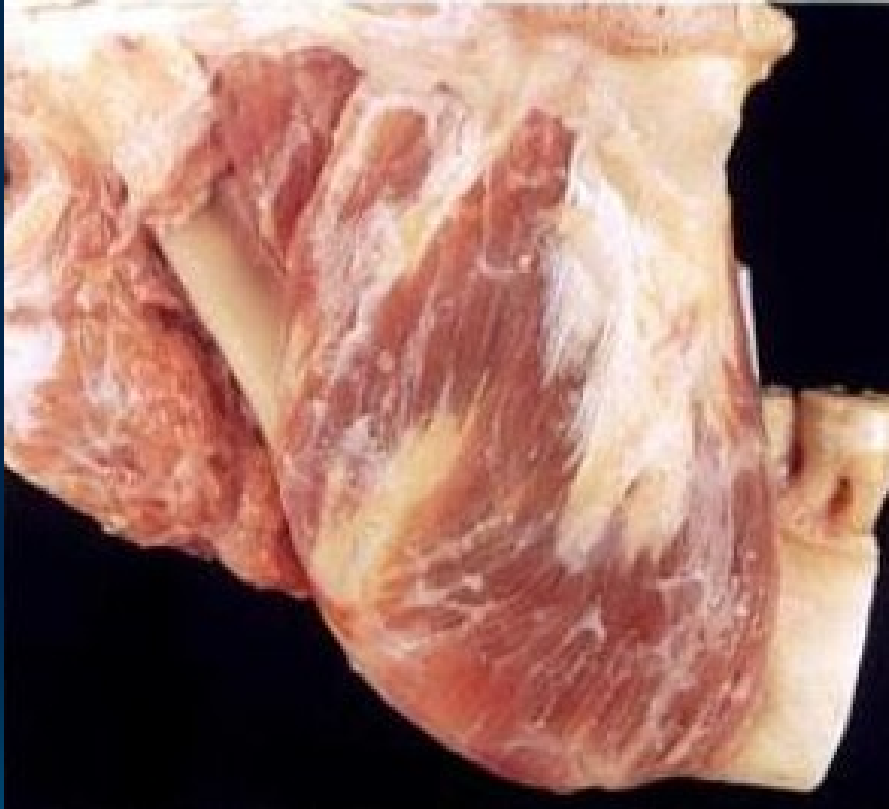The Deep Portion

Smaller and more muscular in texture

Origo: posterior $\frac{1}{3}$ of lower border and the whole of the medial surface of **the zygomatic arch**

Fibers pass downward and forward

Insertion: the upper $\frac{1}{2}$ of **the lateral surface of the ramus mandible**



Functional organization of the human masseter muscle
www.springerlink.com/index/U007G453650W2163.pdf

Function

Bilateral contraction:

The superficial part:

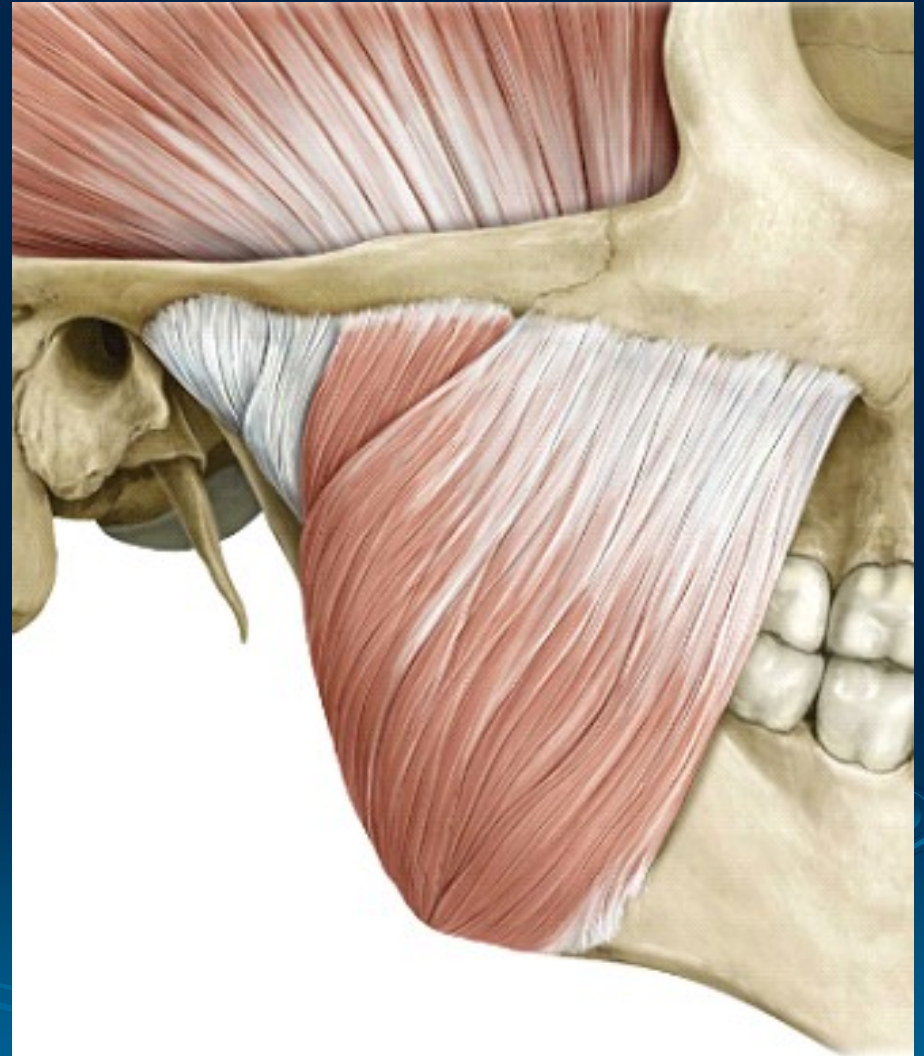
elevation
propulsion

The deep portion:

elevation

Unilateral contraction:

lateropulsion



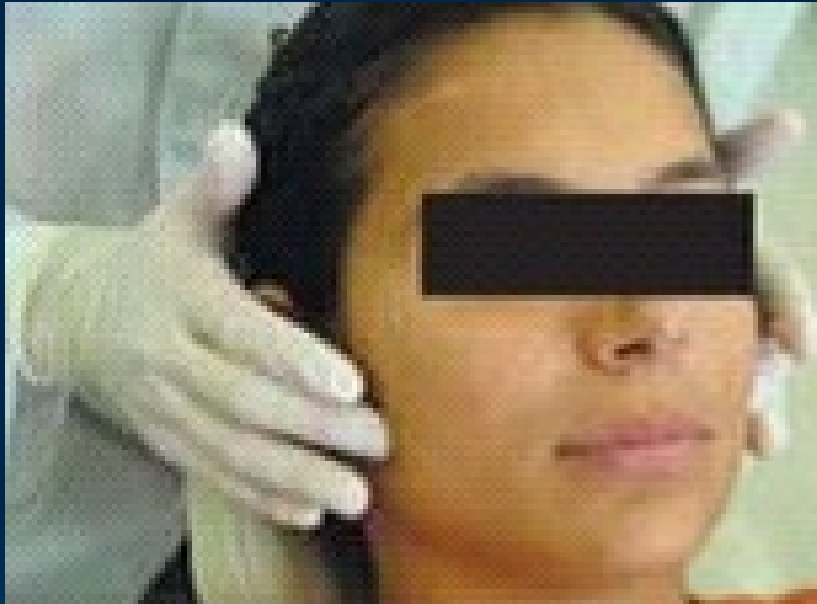The Architecture

- The typical pennate structure - zones of muscular and aponeurotic attachments
- The pennate structure allows spread the infection (**submasseteric abscess**)
- The differential activity of the muscular planes during masticatory function makes it necessary to respect the anatomic and functional individuality in the diagnosis and treatment of dysfunctional disorders of the masticatory apparatus

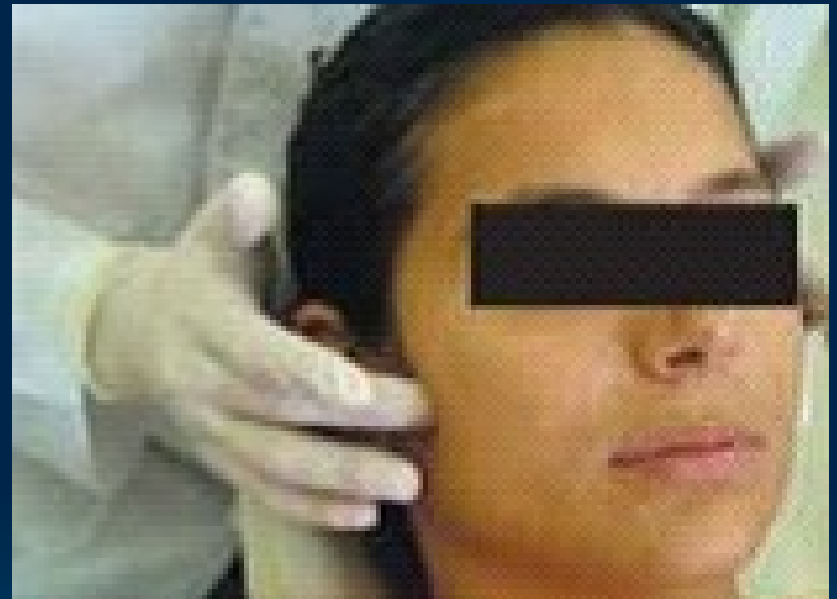The Masseteric Fascia

- Firmly connected with the muscle
- From arcus zygomaticus to basis mandibulae
- Dorsally merge with fascia parotis (fascia parotideomasseterica)

Palpation

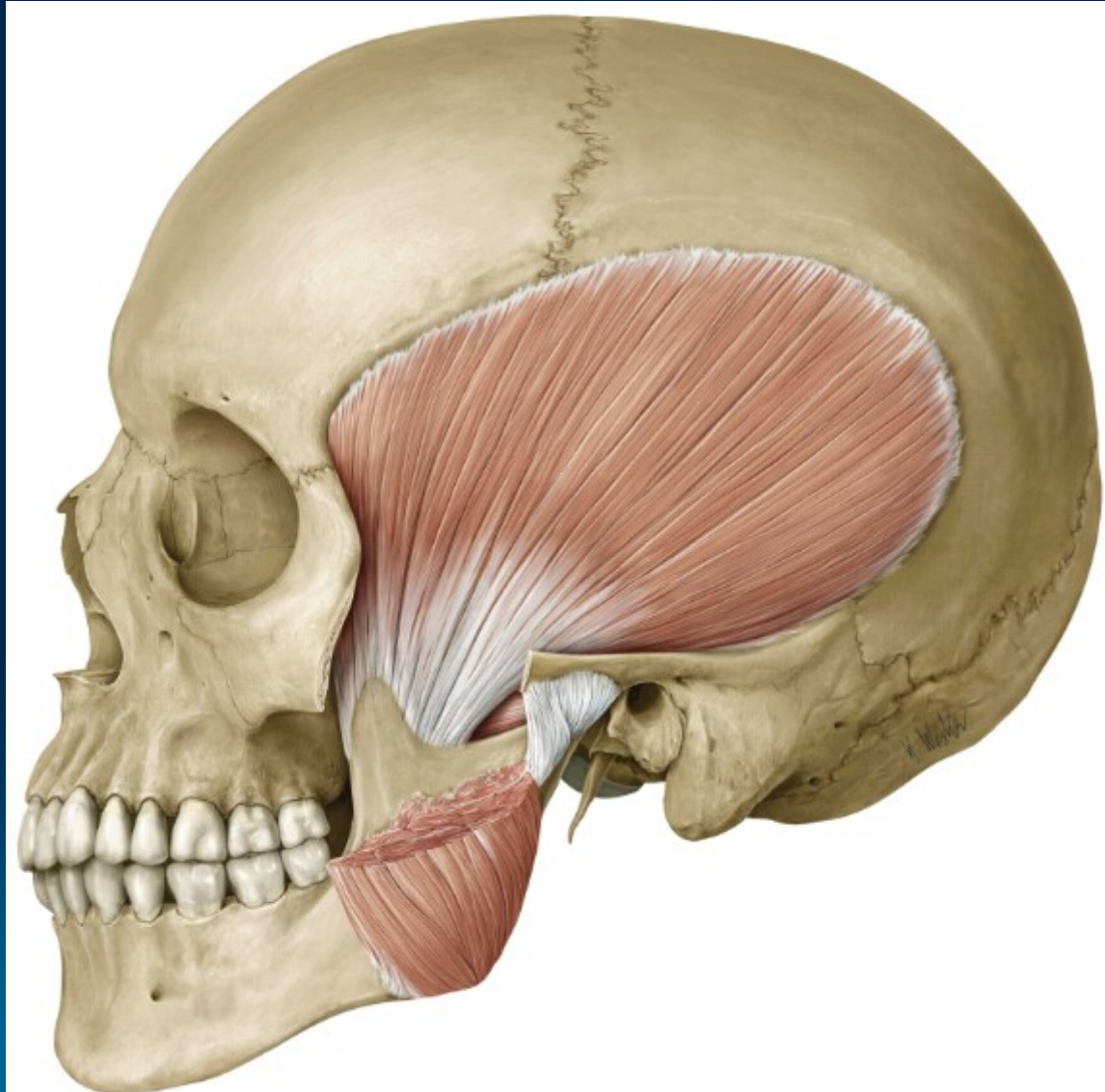


The Superficial Portion



The Deep Portion

Temporalis muscle



Broad, triangular muscle
Localized in the temporal fossa

Origo:

- the whole of **the temporal fossa**
- the deep surface of **the temporal fascia**

Fibers converge as they descend, and end in a tendon, which passes deep to the zygomatic arch

Insertion: apex and medial surface of the **coronoid process** (crista temporalis) and the anterior border of the **ramus of the mandible** to retromolar triangle

Detailed description

The temporalis muscle consists of three parts:

superficial

zygomatic

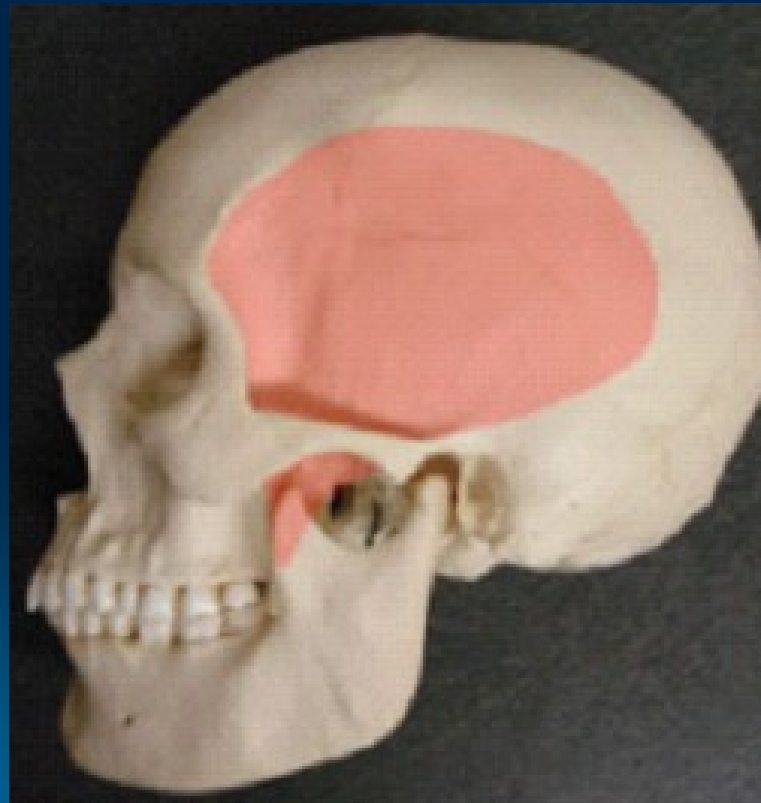deep portion

[The human temporalis muscle: Superficial, deep, and zygomatic ...](#)
[onlinelibrary.wiley.com](#) › ... › [Journal Home](#) › [Vol 22 Issue 6](#)

The Superficial Portion

Origo: temporal aponeurosis, temporal line

Insertion: the coronoid process of the mandible



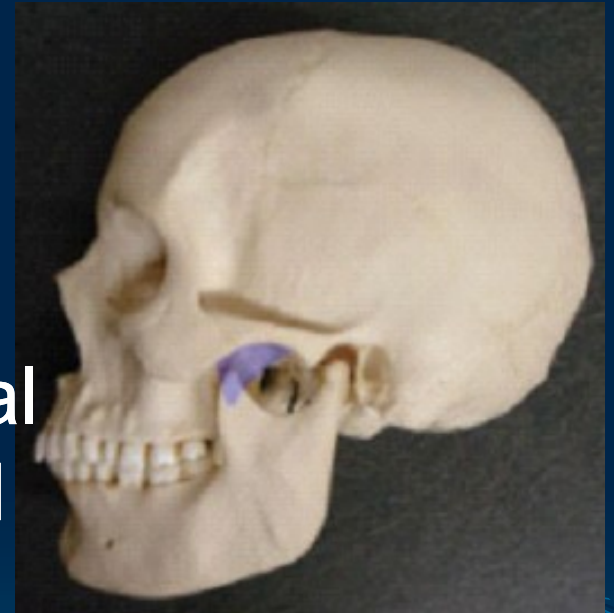
The Zygomatic Portion

Origo: superior and medial zygoma and zygomatic arch

Insertion: coronoid process

Fuse with tendon of the superficial part of the temporalis muscle and with the deep masseter portion.

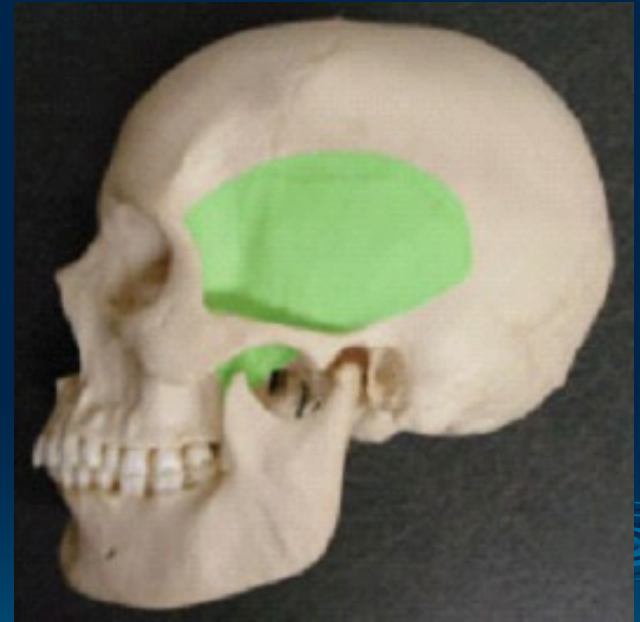
Rostrally interdigitated with the portion of the deep temporalis part



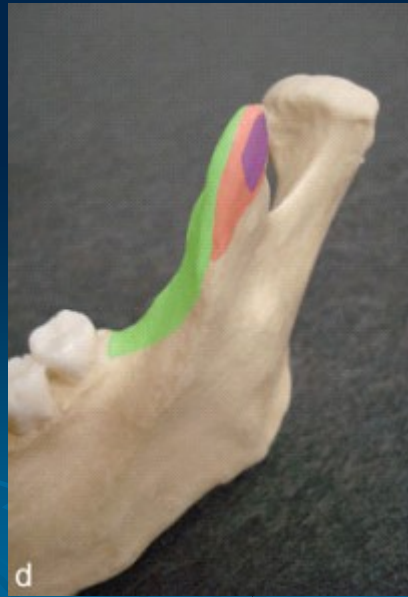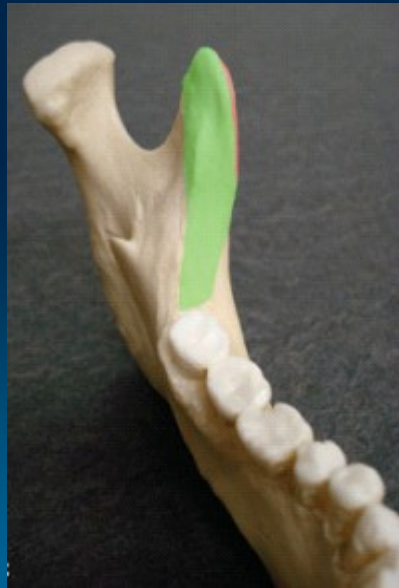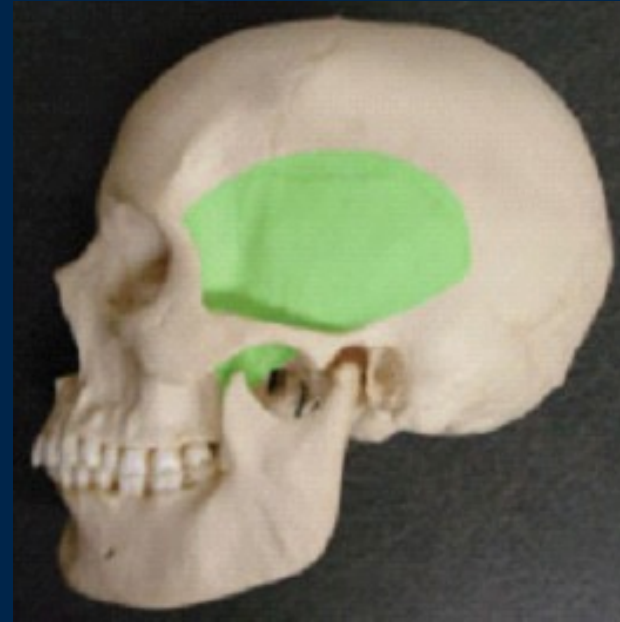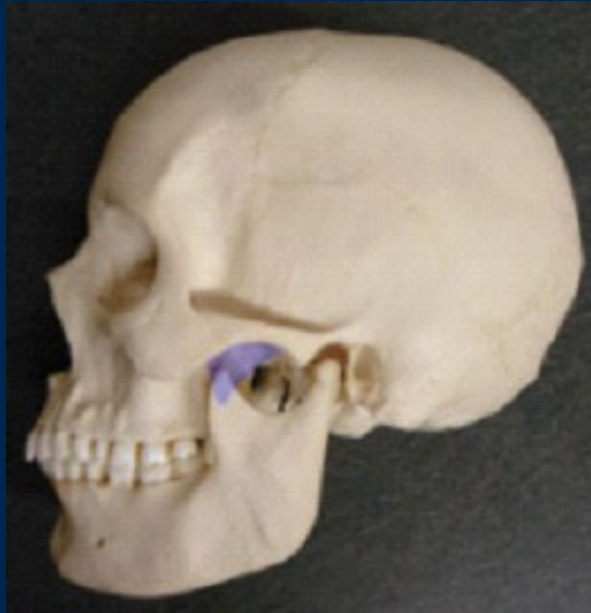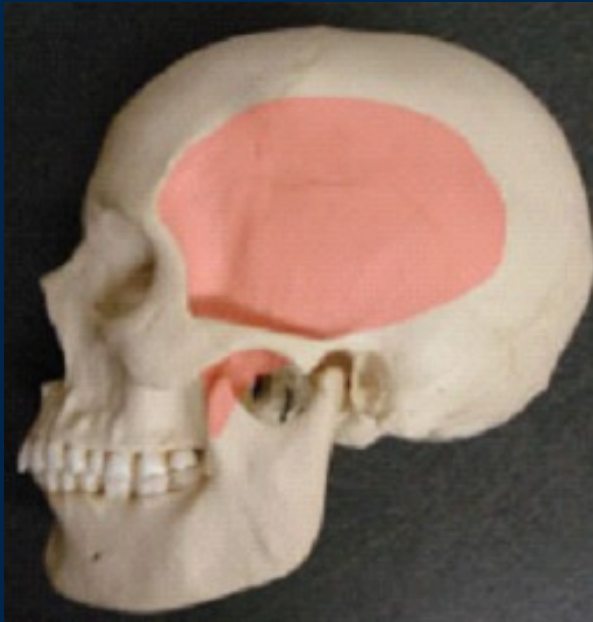The Deep Portion

Origo: bony surface of the frontal, sphenoid, parietal and temporal bones

Insertion: coronoid process and the ramus of the mandible, just caudal to the last molar (retromolar triangle)



Fibers from deep part interdigitated with the buccinator and the superior pharyngeal constrictor



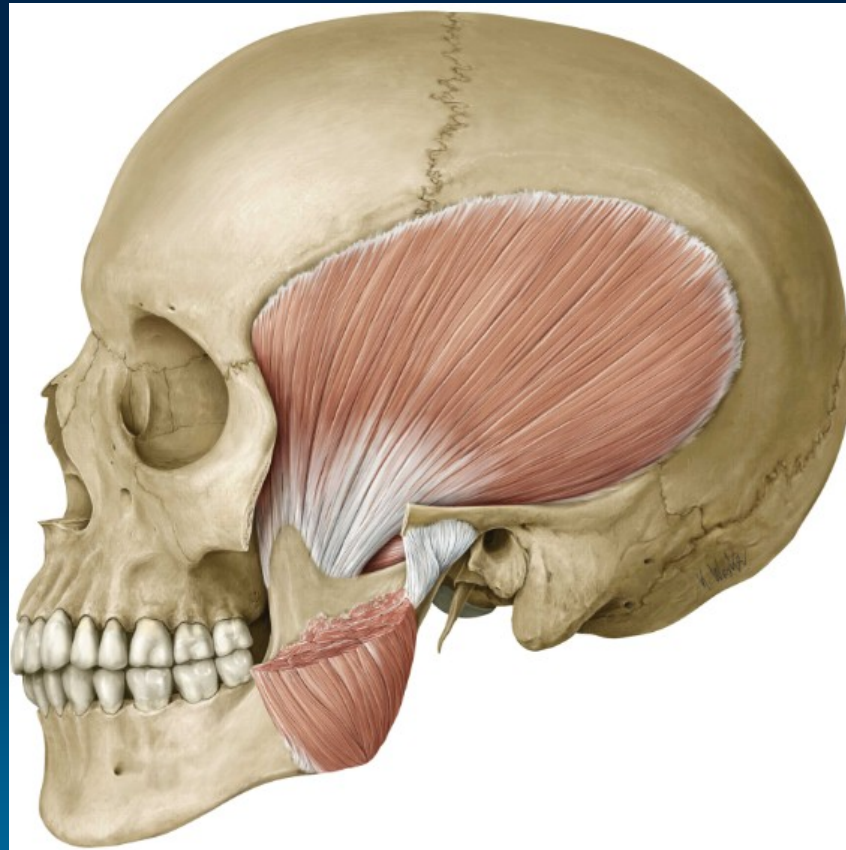
d



Function

Elevation (anterior part)

Retropulsion (posterior part)



The Temporal Fascia

Covers the temporal muscle

Origo: superior temporal line

Insertion: zygomatic arch

Has two layers:

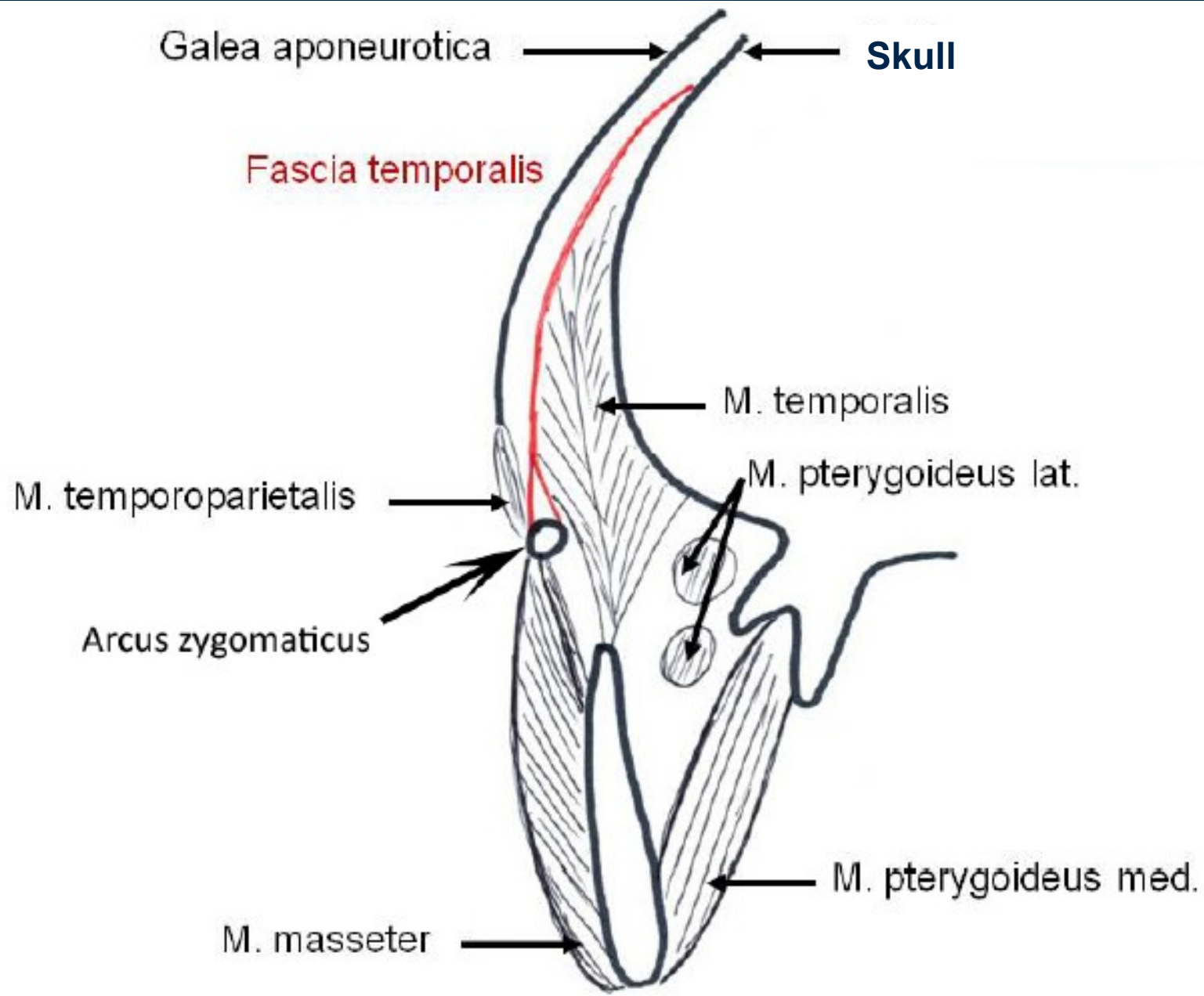
1. superficial

inserted into **the lateral border of the arch**

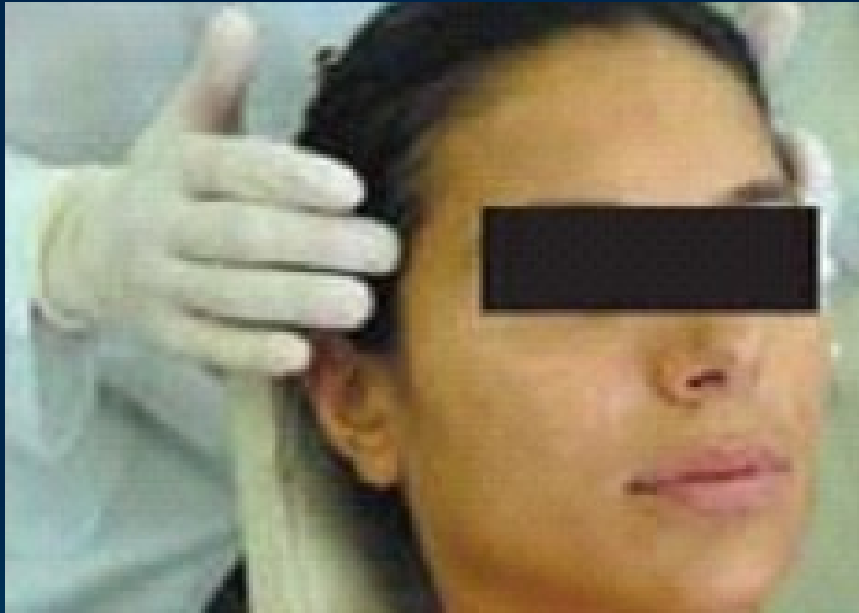2. deep

inserted into the **medial border of the arch**

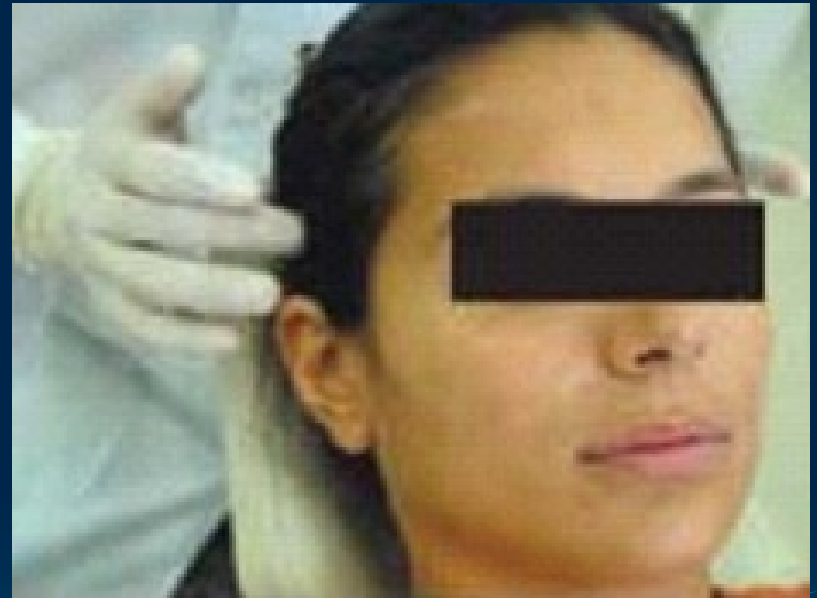Between these layers is a small quantity of fat and attachment of the superficial fibres of the temporal muscle



Palpation

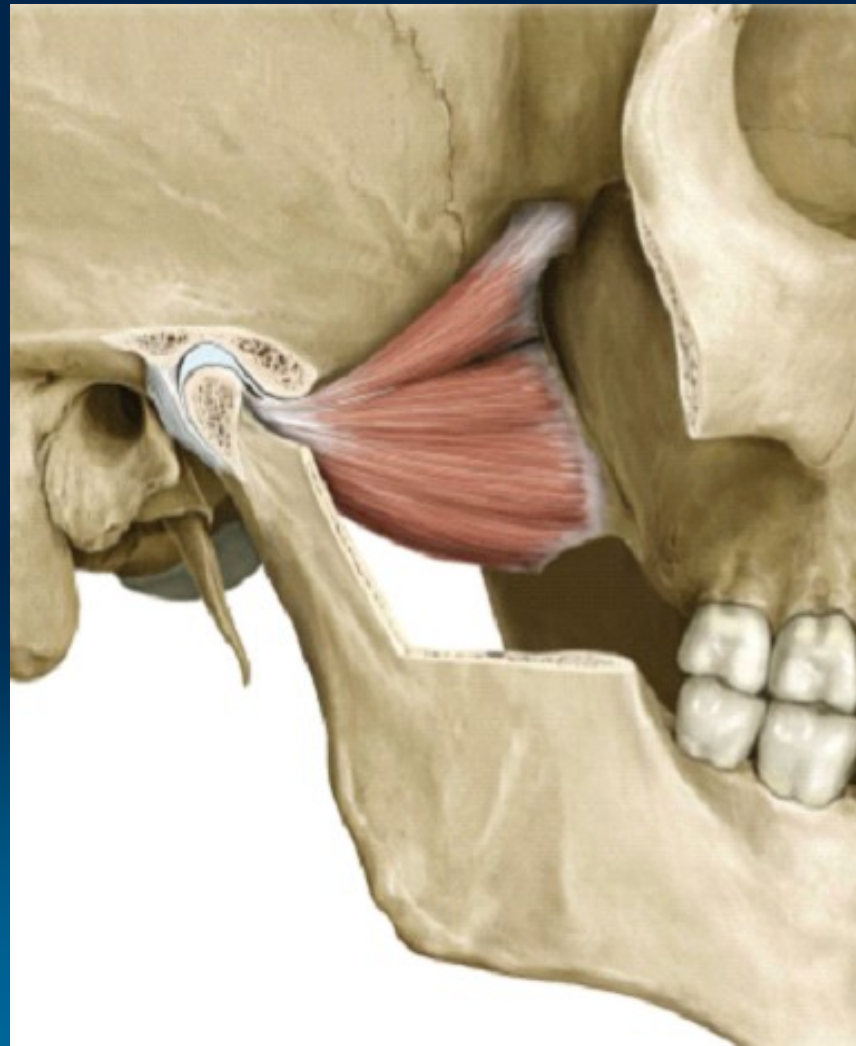


The Anterior Part



The Posterior Part

Lateral (Externus) Pterygoid Muscle



Short, thick muscle, conical in form
Located in the infratemporal fossa
Two heads: upper and lower

The Upper/Sphenoid Head:

Origo: infratemporal facies of **the great wing of the sphenoid bone**

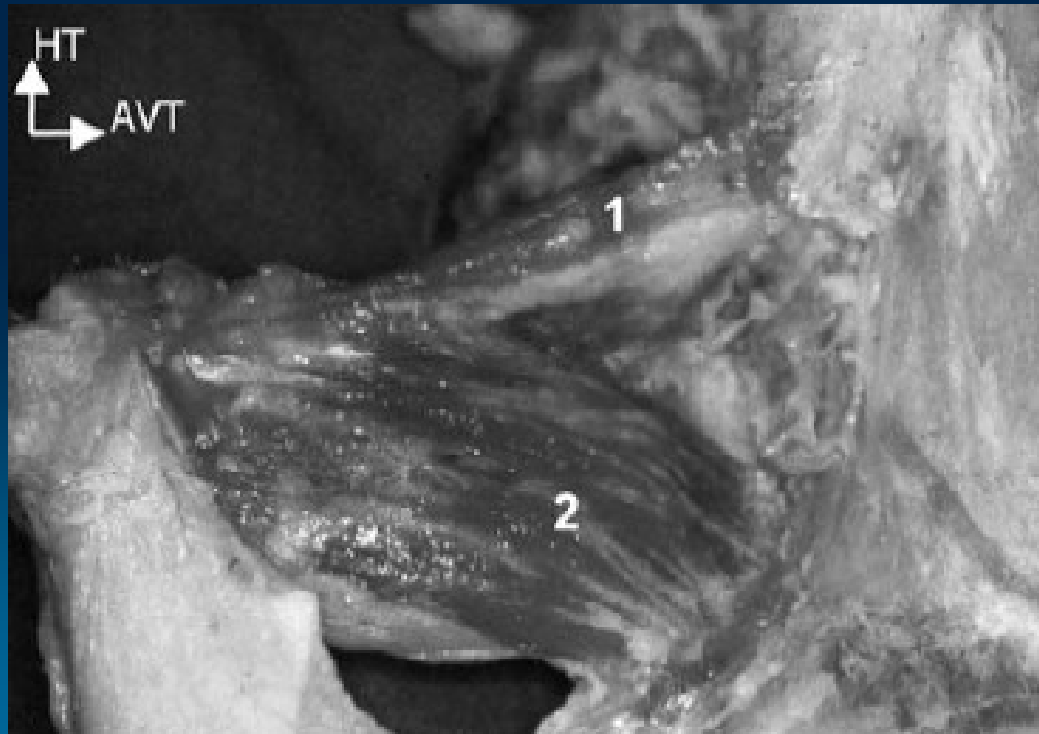The Lower/Pterygoid Head:

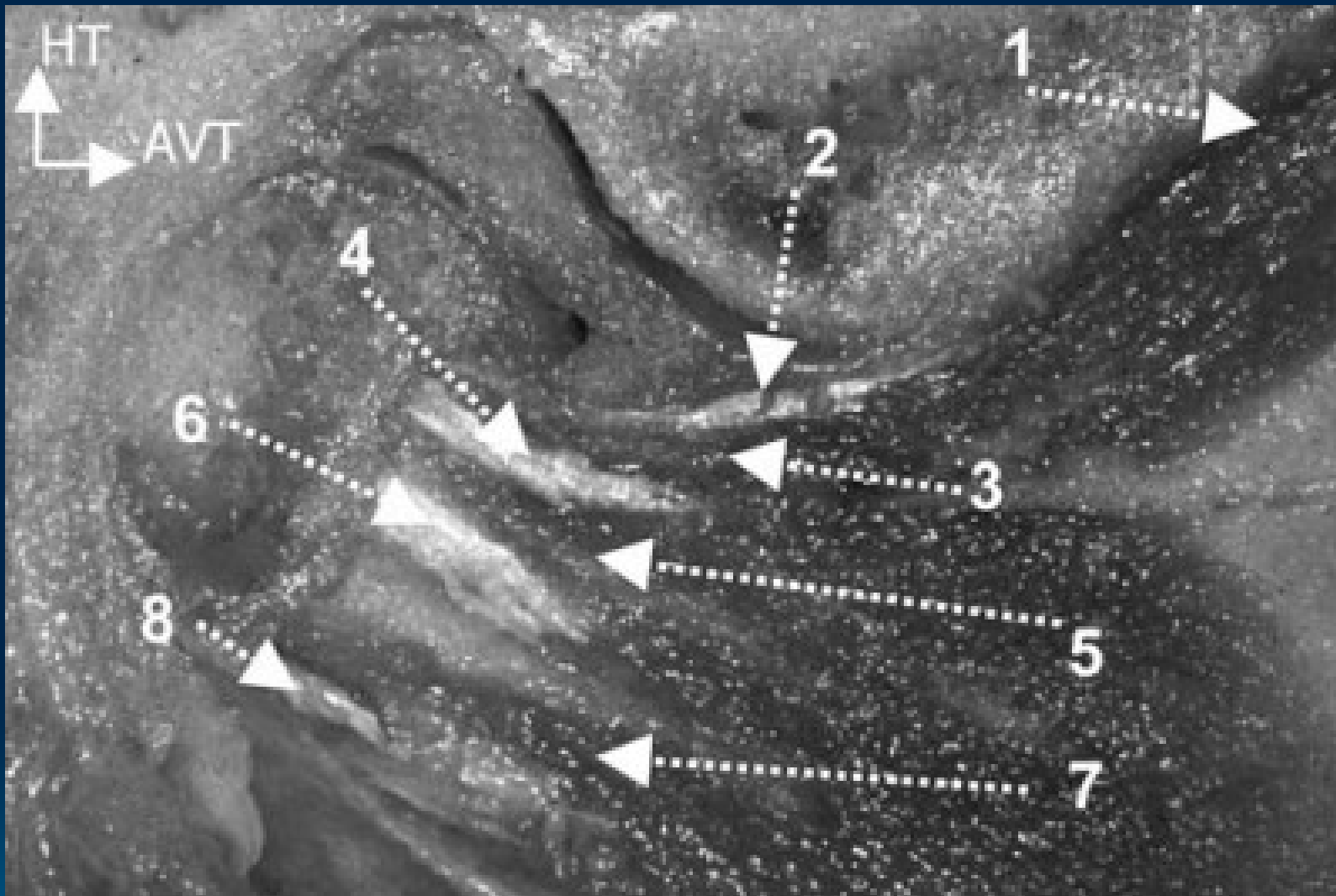
Origo: lateral surface of **the lateral pterygoid plate**

Fibres pass horizontally backward and lateralward

Insertion:

- **fovea pterygoidea** (depression in front of the neck of the condyle)
- **joint capsule** and **articular disc of the TMJ** (front margin)



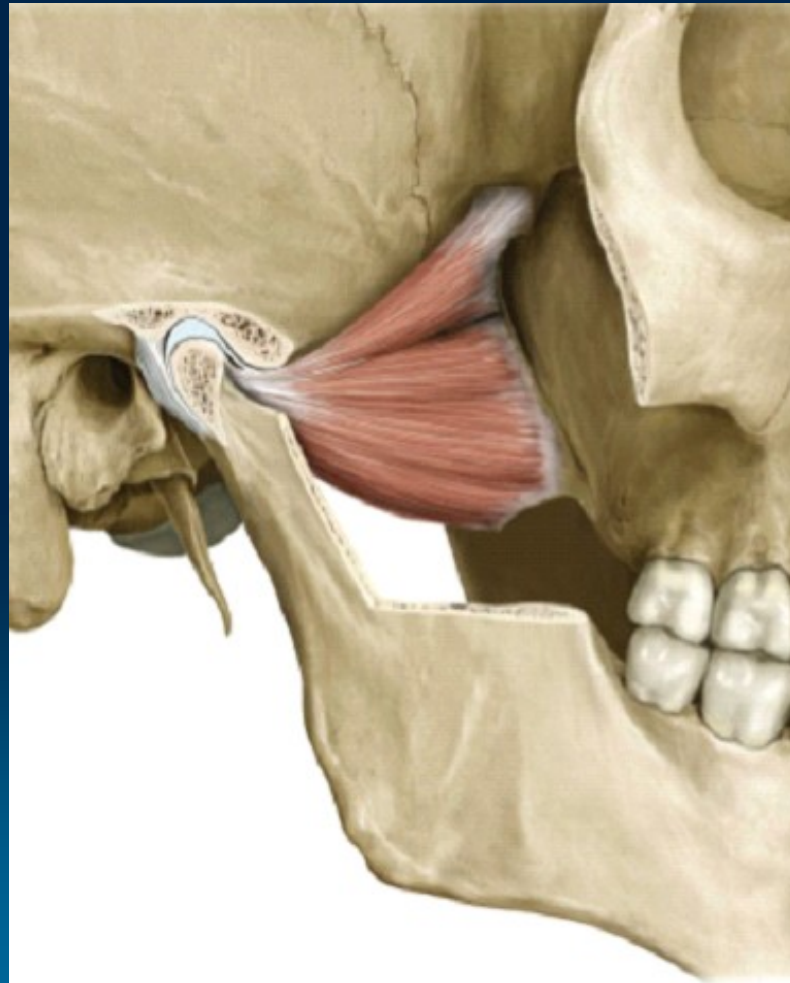


Alternating tendinous sheets characteristic of a penniform structure

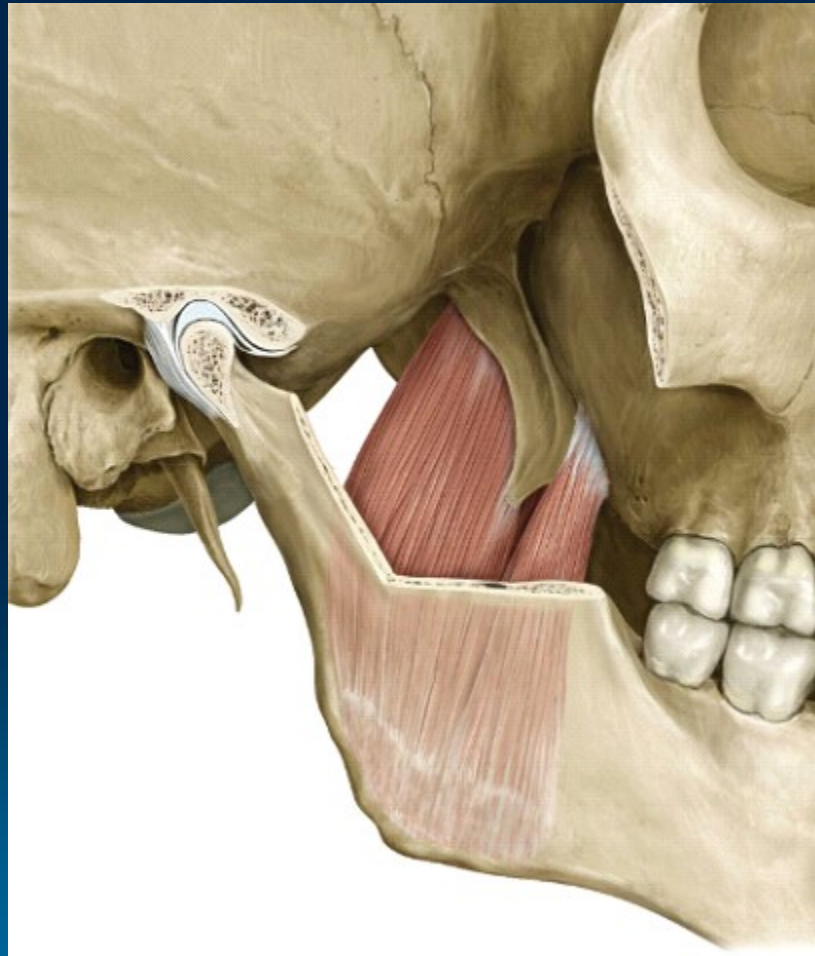
Function

Bilateral contraction: **propulsion**

Unilateral contraction: **lateropulsion**



Medial (Internus) Pterygoid Muscle



Thick, quadrilateral

Located in the infratemporal fossa

Two heads:

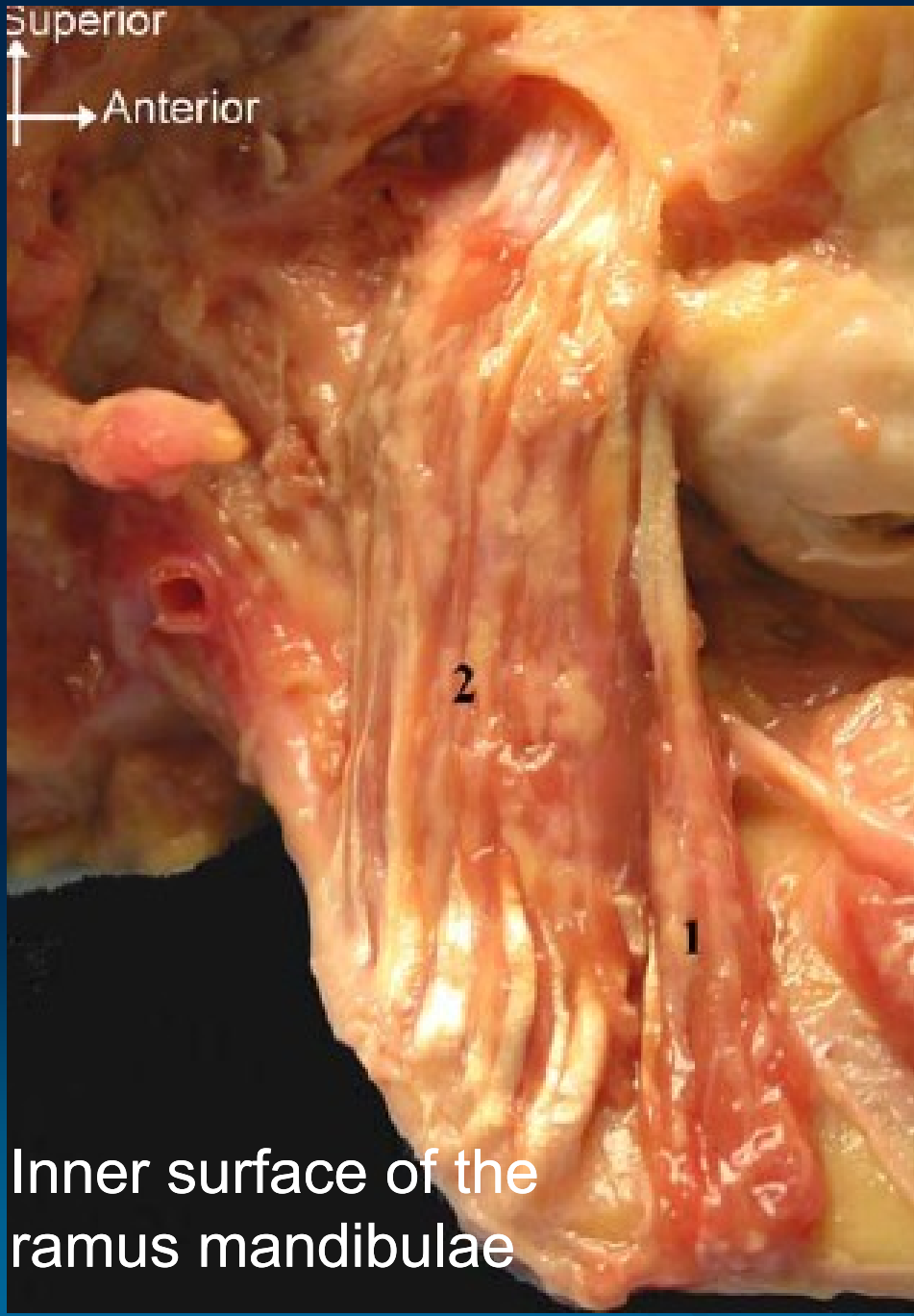
Origo:

- **tuberosity of the maxilla** (lateralis)
- medial surface of **the lateral pterygoid plate** (medialis)

Fibers pass downward, lateralward and backward

Insertion: tuberositas pterygoidea

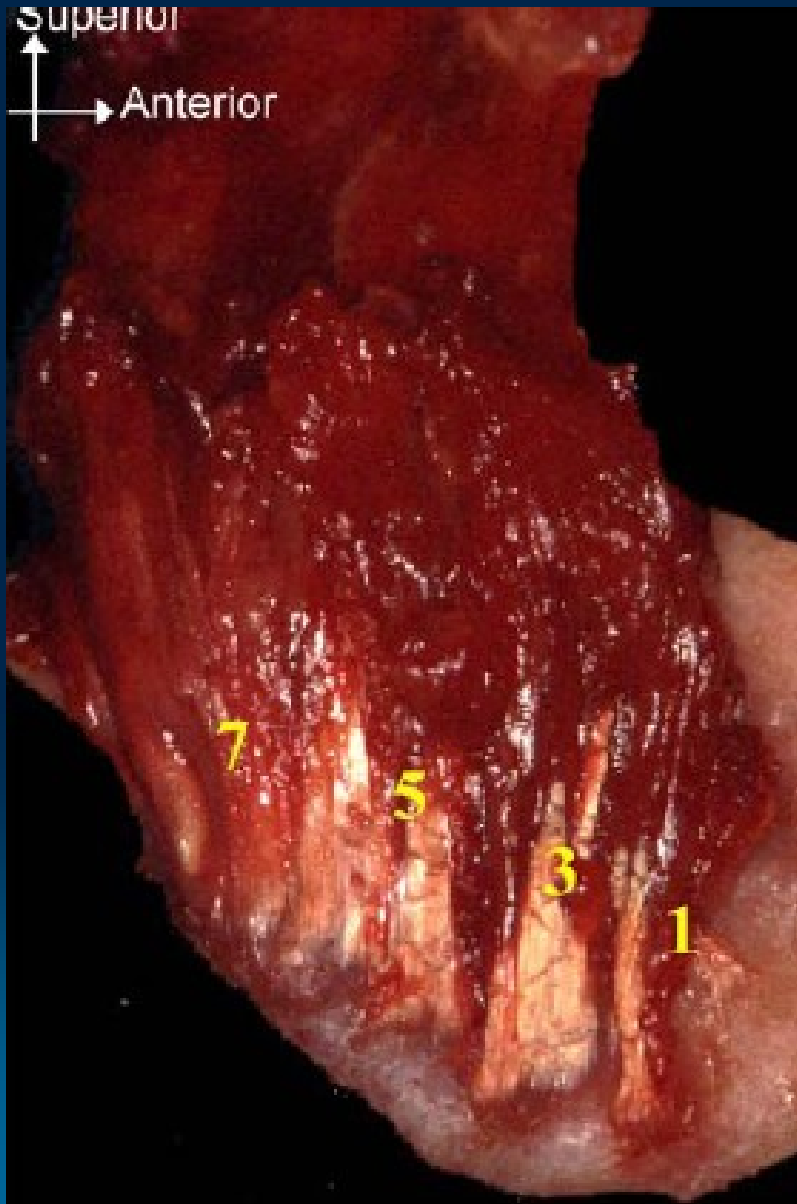
(lower and back part of the medial surface of the ramus and angle of the mandible)



- 1 - lateral part
- 2 - medial part

Inner surface of the ramus mandibulae

The Architecture



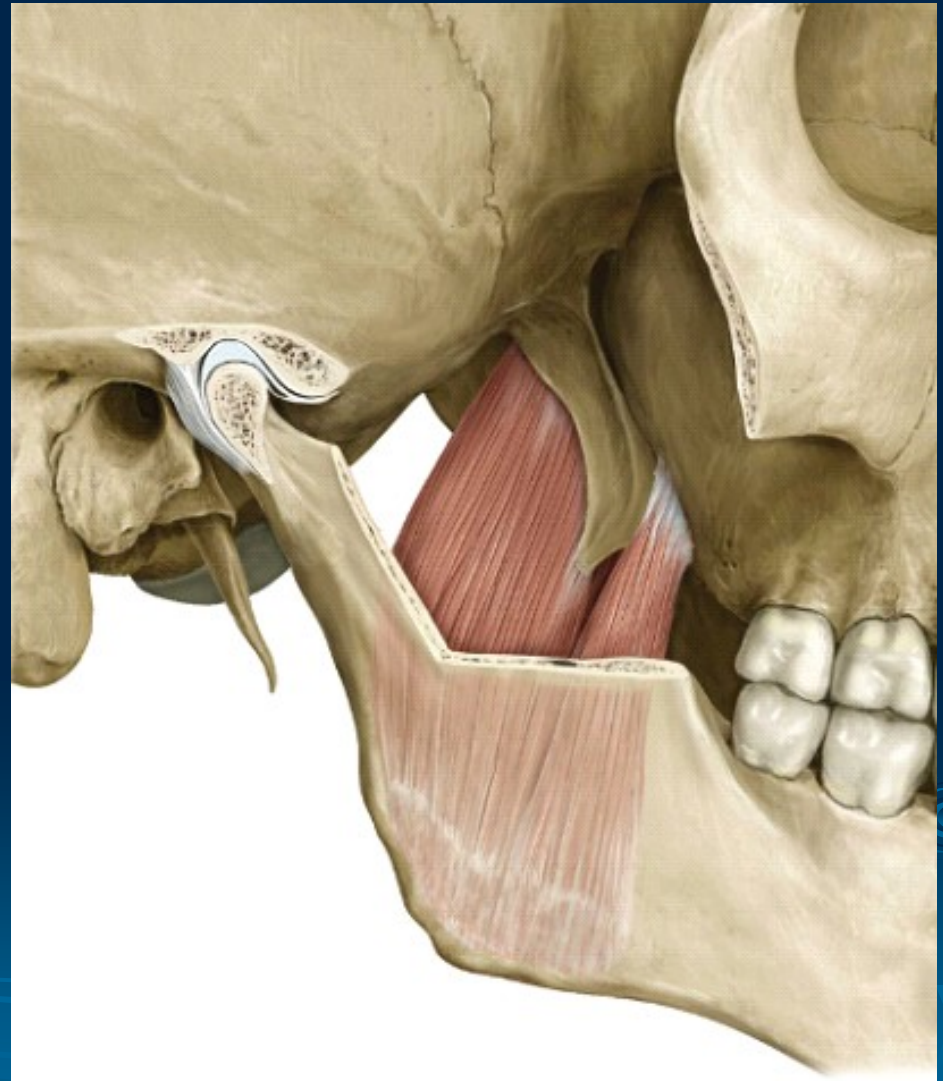
7 musculo-aponeurotic layers are making up a penniform structure



Function

Bilateral contraction:
propulsion
elevation

Unilateral contraction:
lateropulsion



The Interpterygoid Fascia

Between the medial and lateral pterygoid muscles

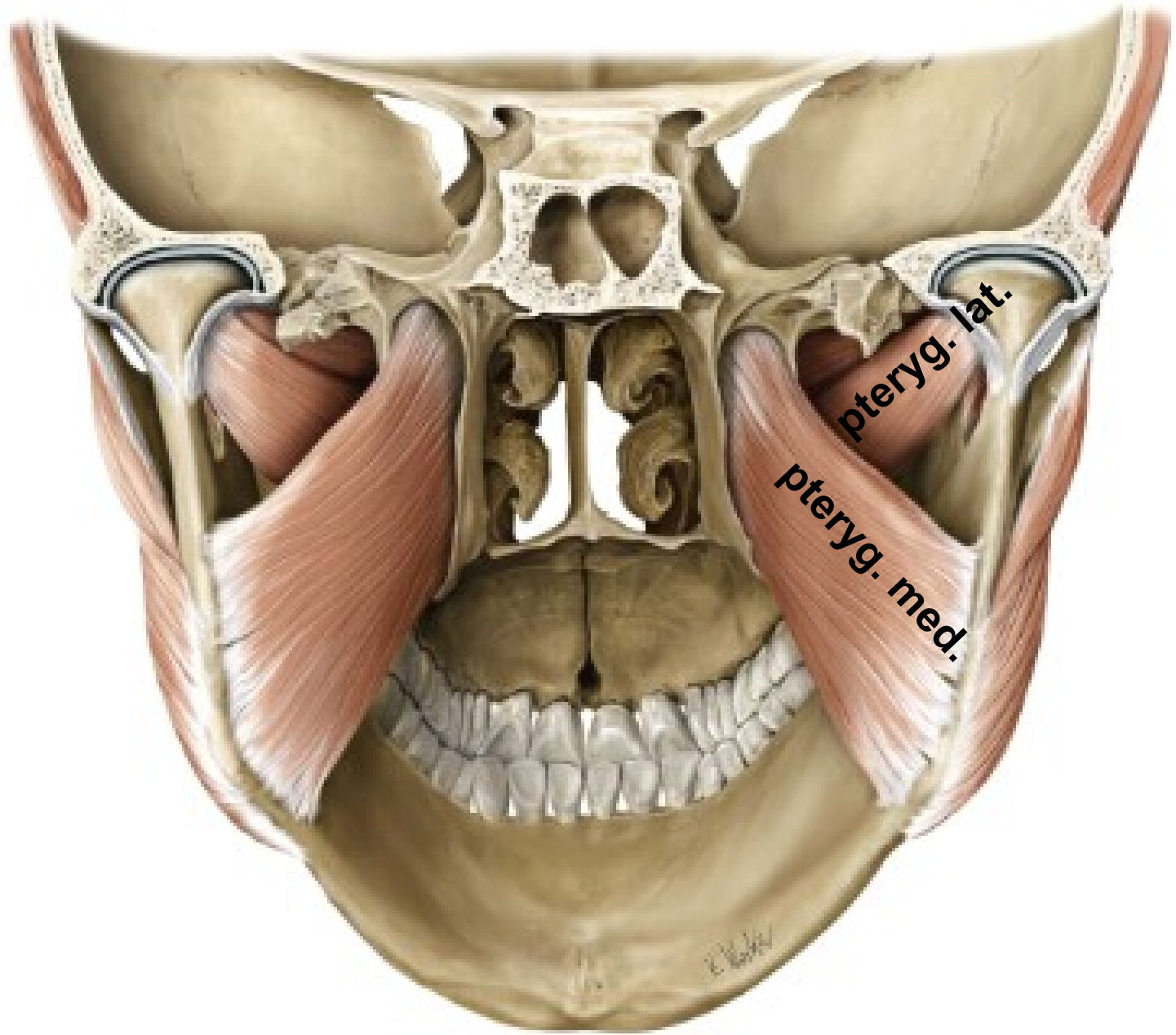
Origo: the base of the skull

Insertion: inner surface of the mandible

The border is reinforced by sphenomandibular ligament

Contain nerves and vessels

Allow spread of infection



pteryg. lat.

pteryg. med.



