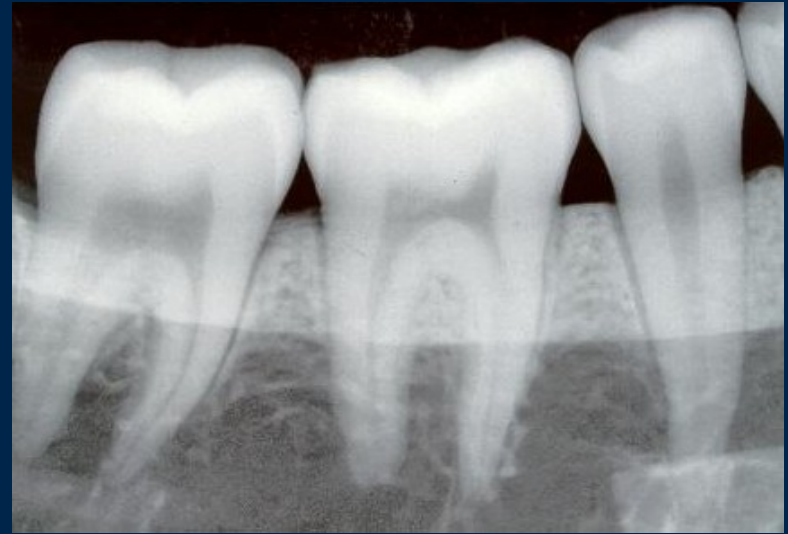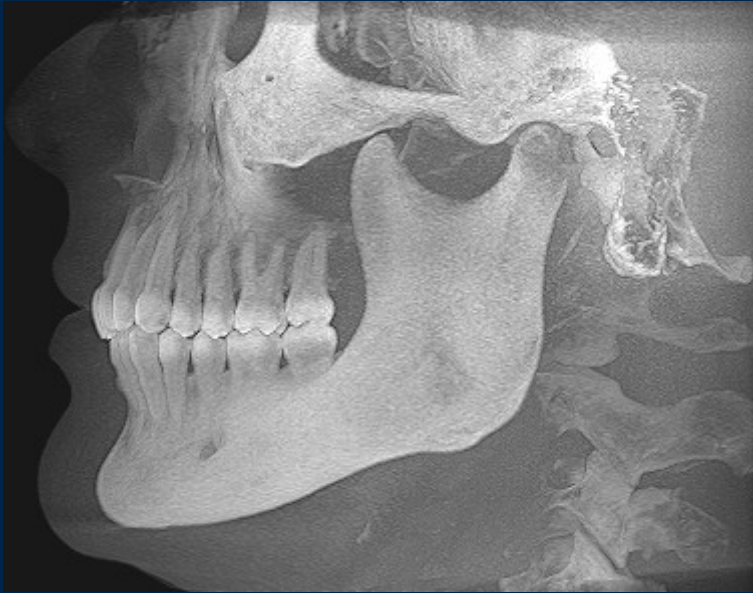


IMAGING METHODS IN DENTISTRY

Radiography

Magnetic Resonance Imaging

Ultrasonography



Summation imaging

- X ray (RTG)

Creating 3D images as 2D photography

Storeyed imaging

- CT, MRI, Ultrasonography (USG)

2D image, third dimension is width of layer

Radiography

Conventional x digital radiography

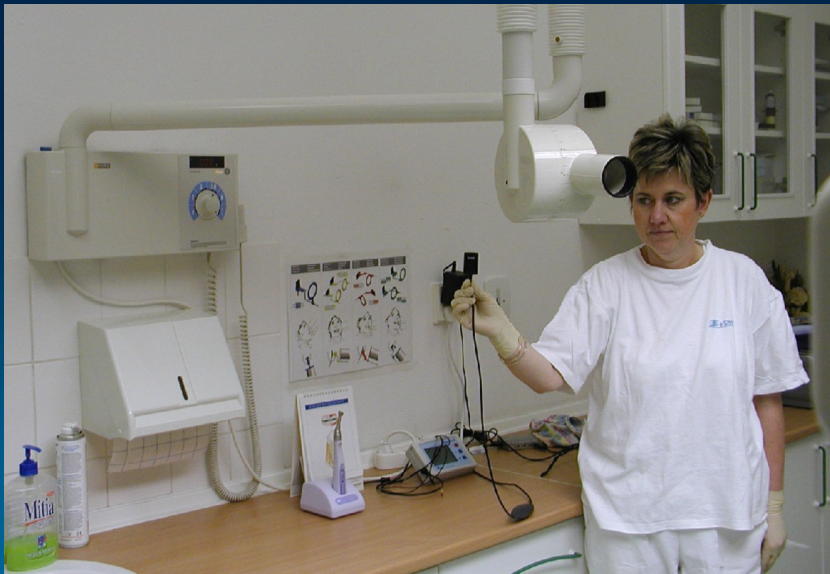- I.** Intraoral
 - II.** Extraoral
 - III.** Specific
 - IV.** Contrast imaging
 - V.** CT diagnostic
- 

Conventional Radiography

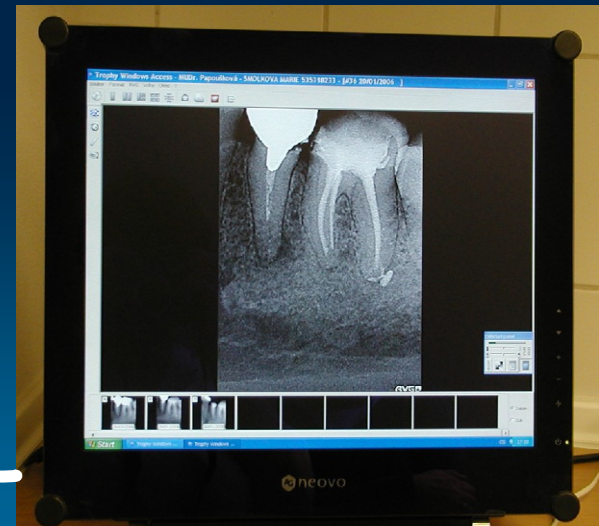- Conventional intra-oral radiographic film consists of silver halide grains in a gelatine matrix
- When this film is exposed to X-ray photons the silver halide crystals are sensitized and are reduced to black during the developing process
- The film acts as both the radiation detector and the image display

Digital Radiography

- Using pixels or small light sensitive elements, can be a range of shades of grey depending on the exposure, and are arranged in grids and rows on the sensor
- The sensors are only the radiation detector and the image is displayed on a monitor



www



Advantages of digital imaging:

- Dose reductions of up to 90%
- The greatest advantage of digital imaging over conventional film is image manipulation
- Contrast enhancement can effectively compensate for over or under exposure of the digital image
- Other advantages: 3D reconstruction, time, storage, environmentally friendly

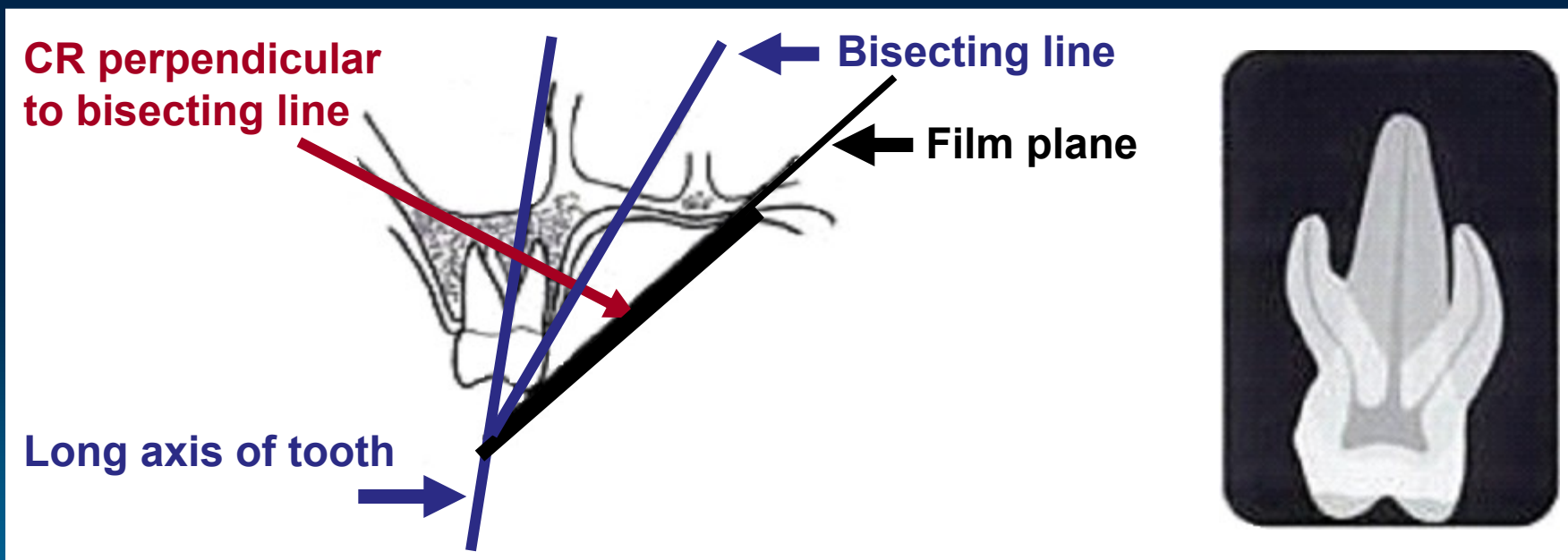
I. INTRAORAL RADIOGRAPHY

Gives graphic information about the alveolar bone, periodontal areas and the hard tissues of the tooth

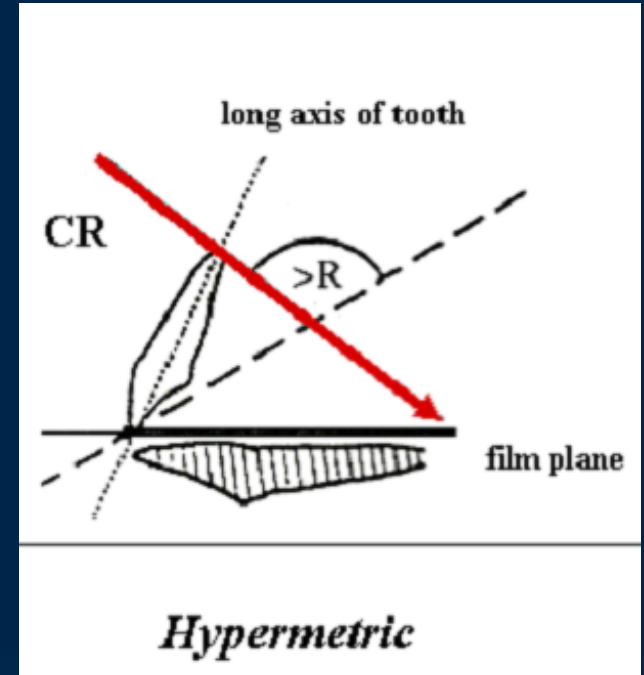
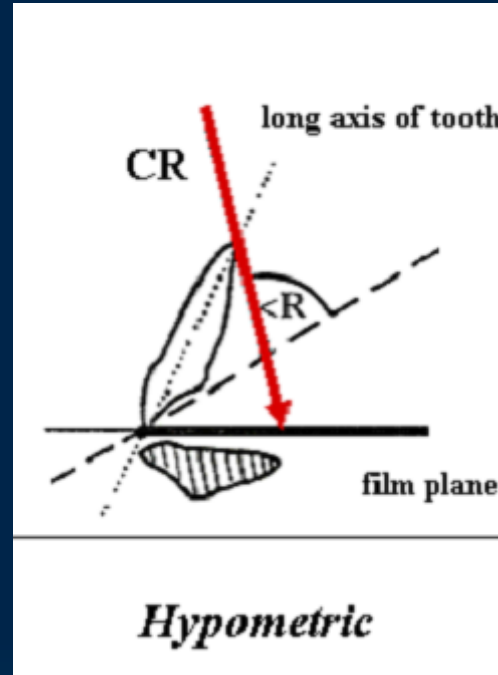
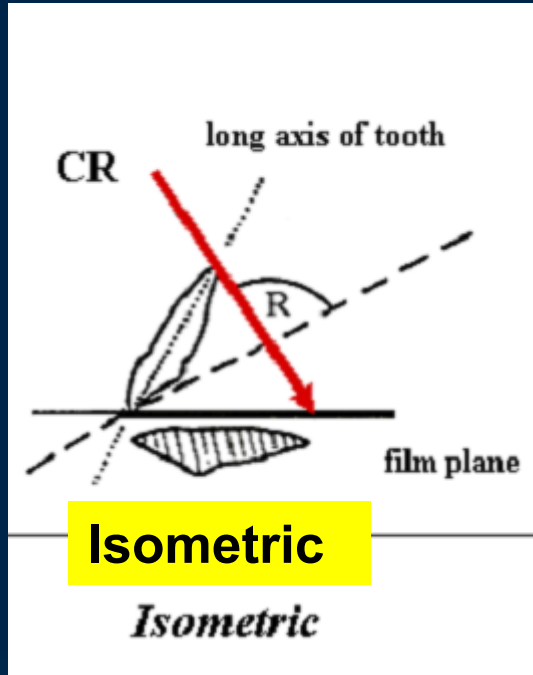
- 1. Bisecting technique**
- 2. Paralleling technique**
- 3. Bitewing technique**
- 4. Occlusal radiograph**

1. Bisecting Technique

Central ray is directed at an imaginary line that bisects the angle created by the long axis of the tooth and the film



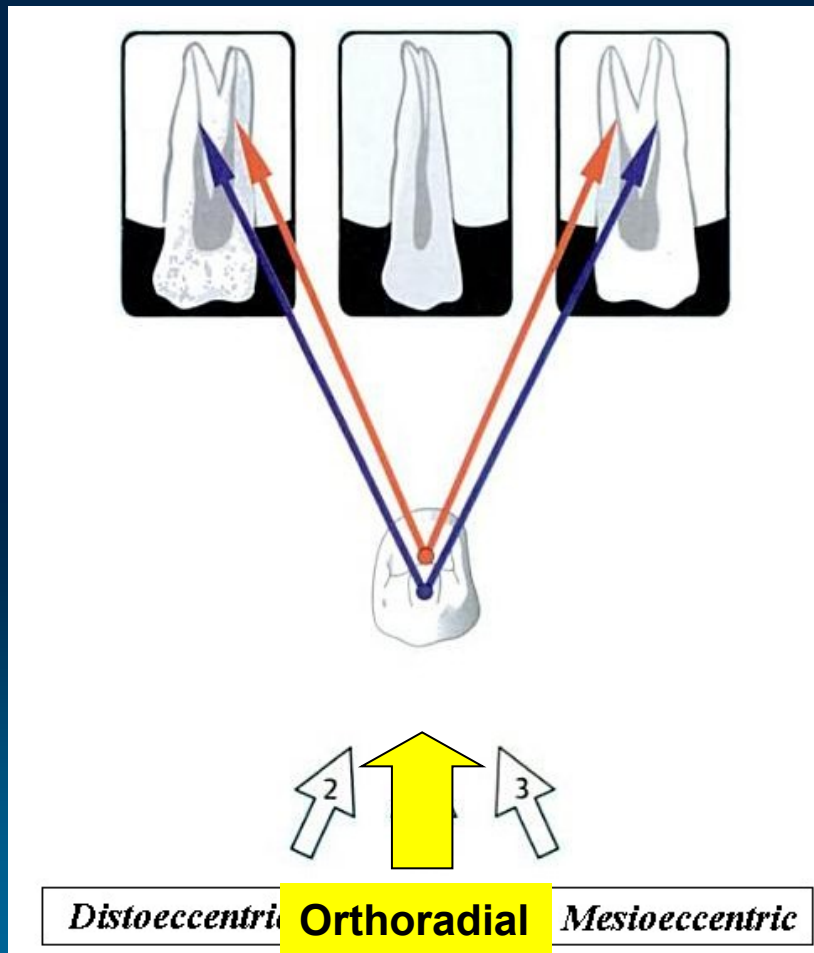
Film will be in right angles to the beam → **isometric**



An acute angle → hypometric (teeth shortened)

An obtuse angle → hypermetric (teeth elongated)

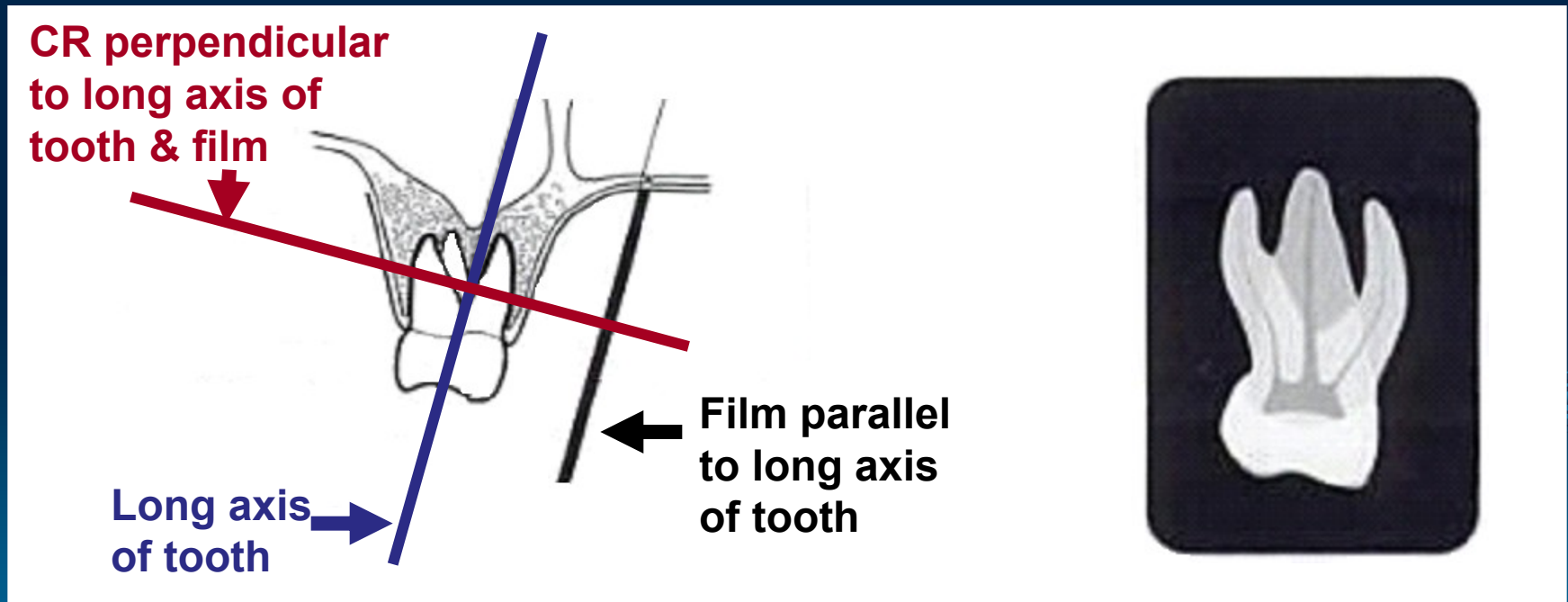
Horizontal angulation - the central ray must be directed through the interproximal space between the teeth under examination → **ortoradial picture**

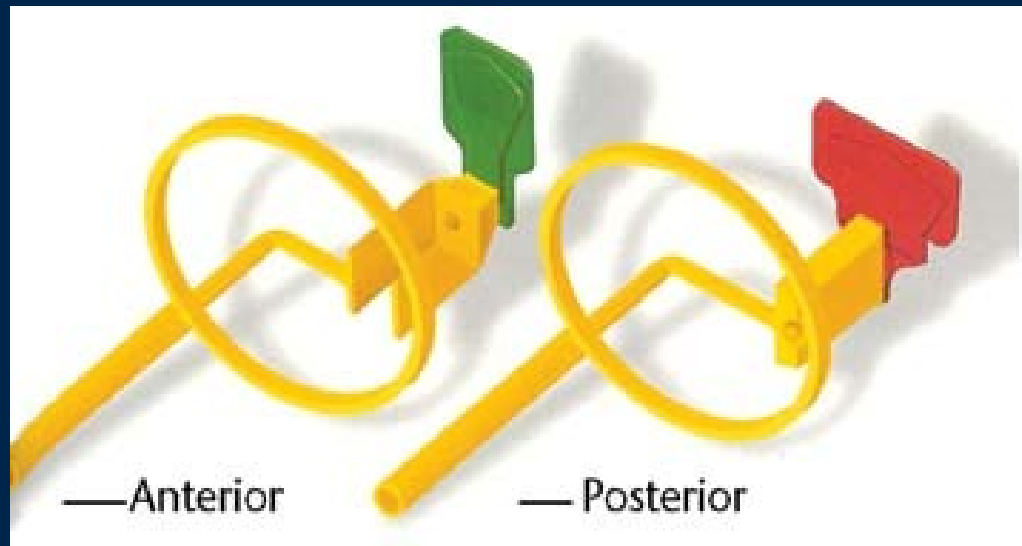


Eccentric projection (mesio- or disto-) is useful for information about shape and length of the root canals

2. Paralleling Technique

Position of the film: **the long axis of the film is parallel with the long axis of the teeth**

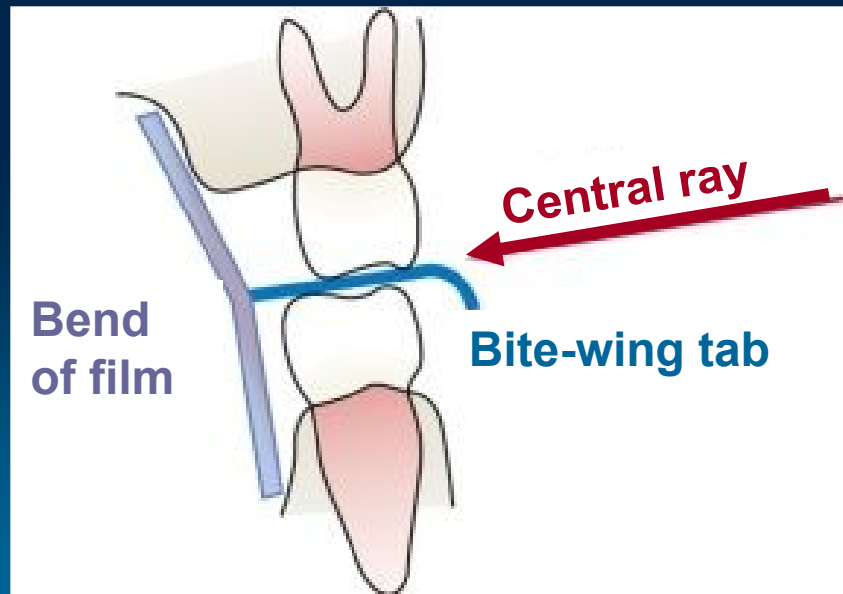




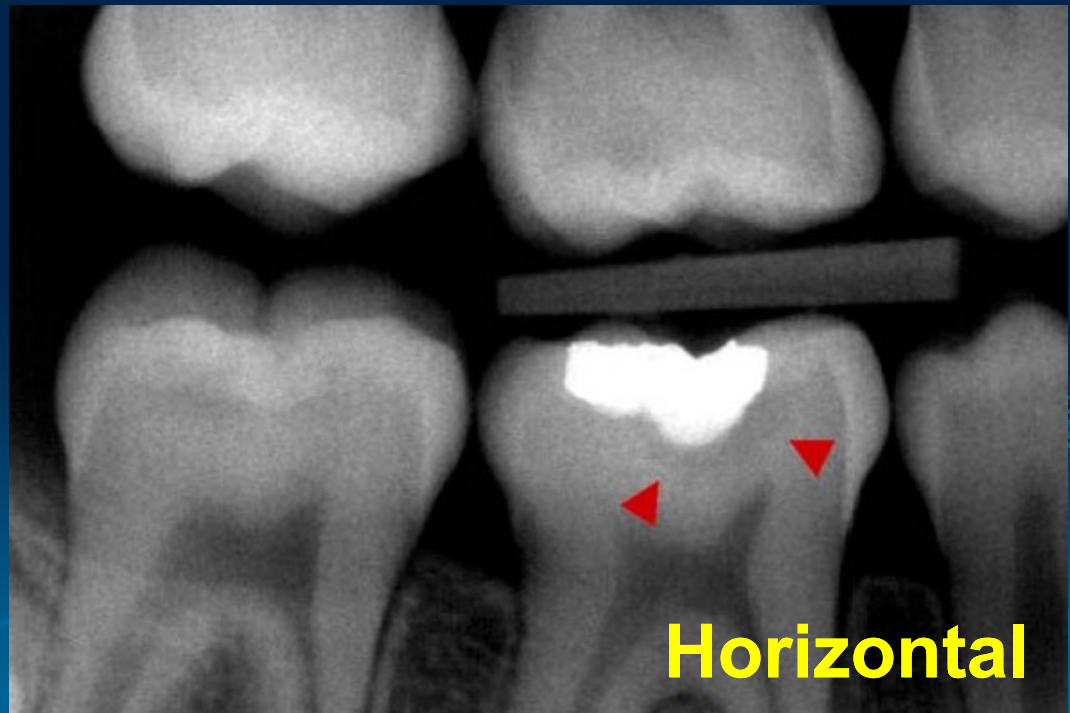
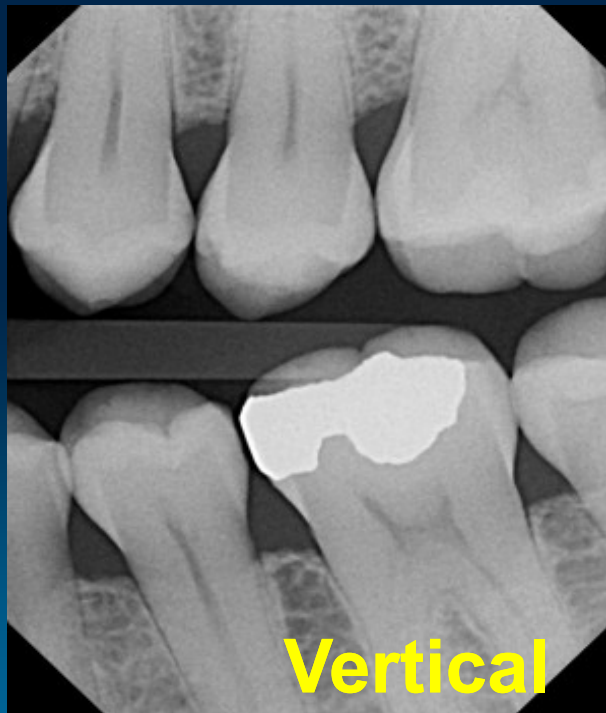
The X-ray film is placed into a X-ray film holder

3. Bite Wing Technique

- Examine the interproximal surfaces of teeth
- The film is placed parallel to the crowns of both teeth and stabilized by film holder or by bite wing tab

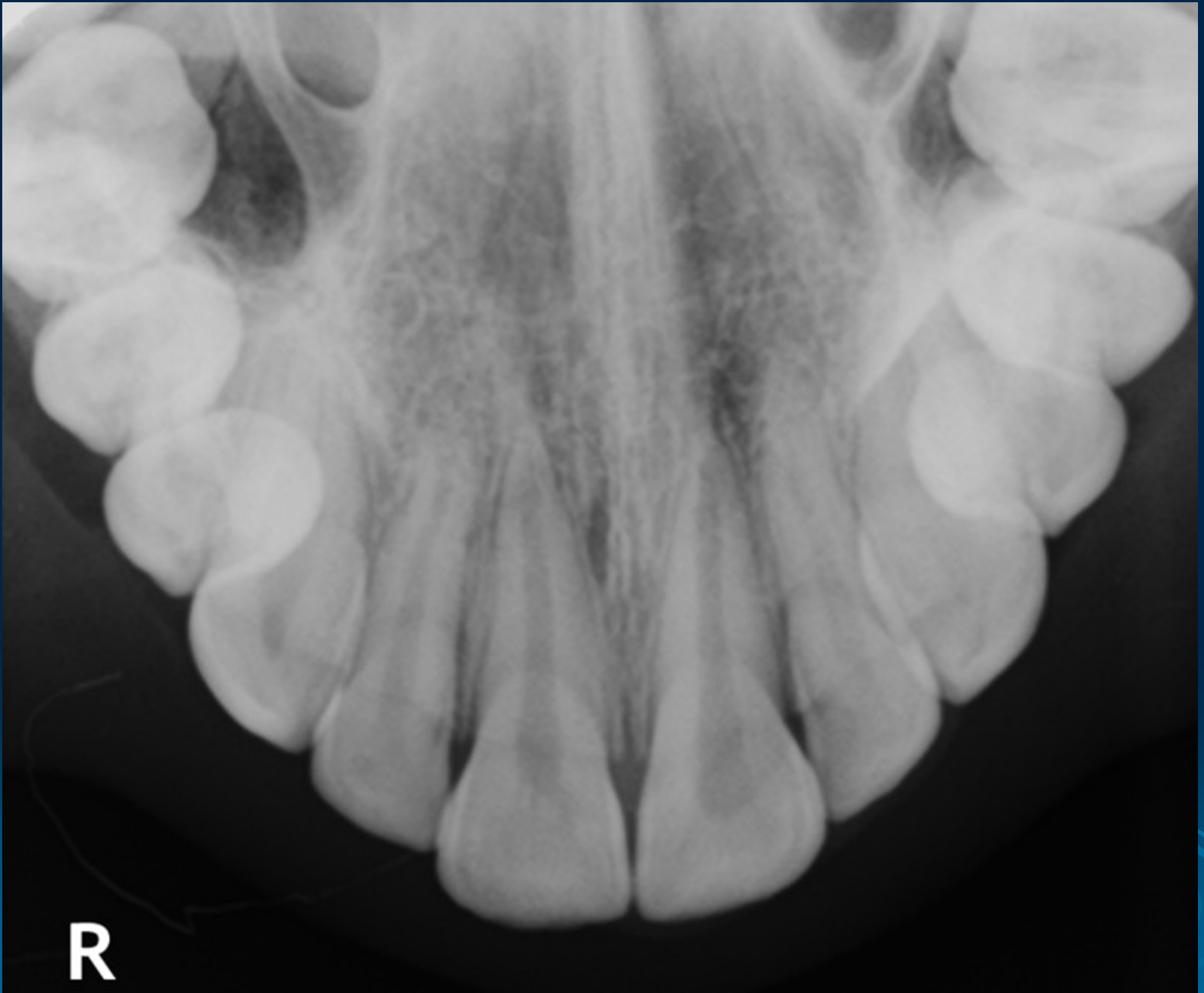

- Horizontal × Vertical bite wing
- Vertical bite wing generally more informative than horizontal in detecting moderate to severe periodontal disease and can also be taken in anterior region

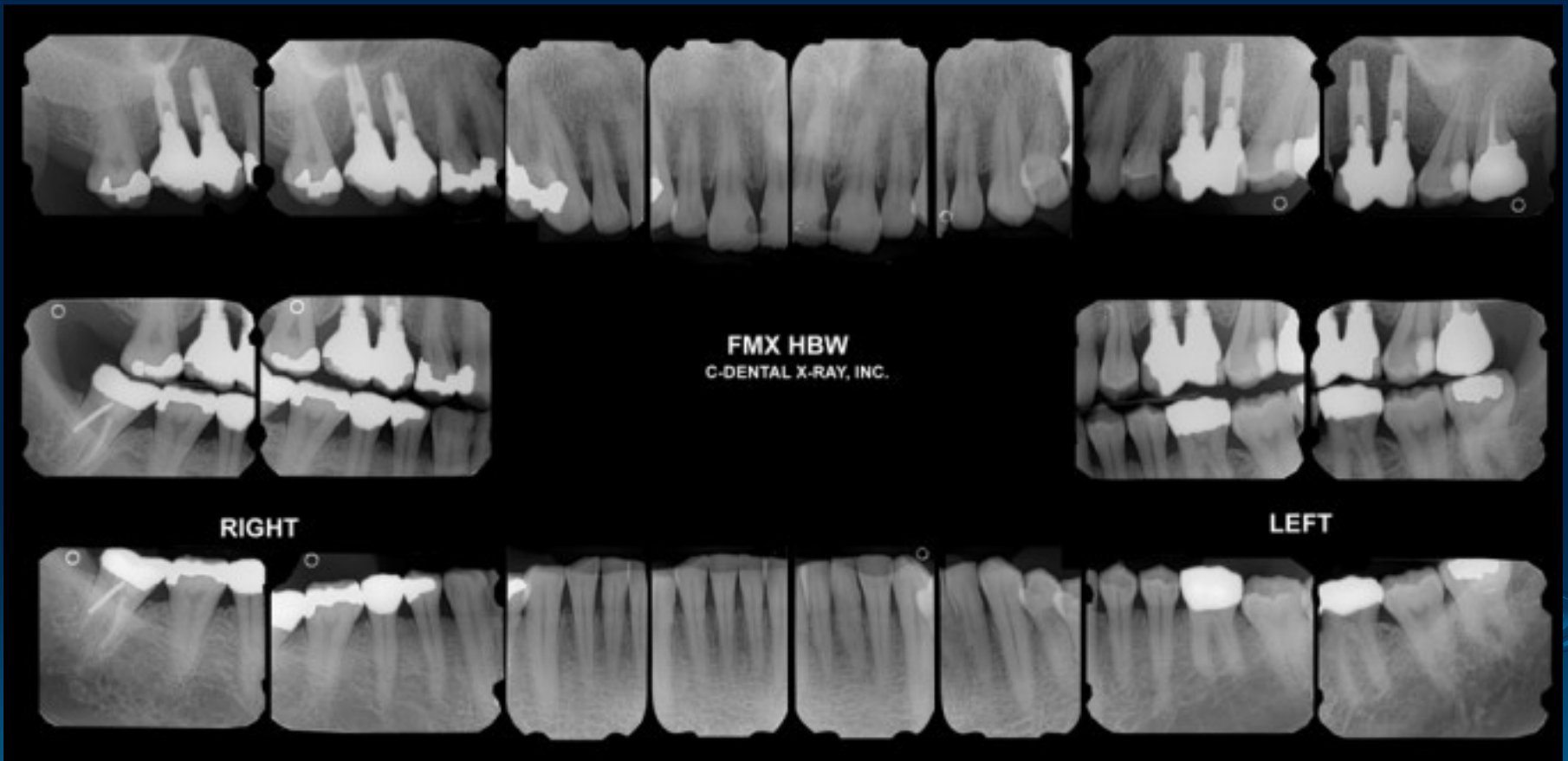


4. Occlusal Radiograph

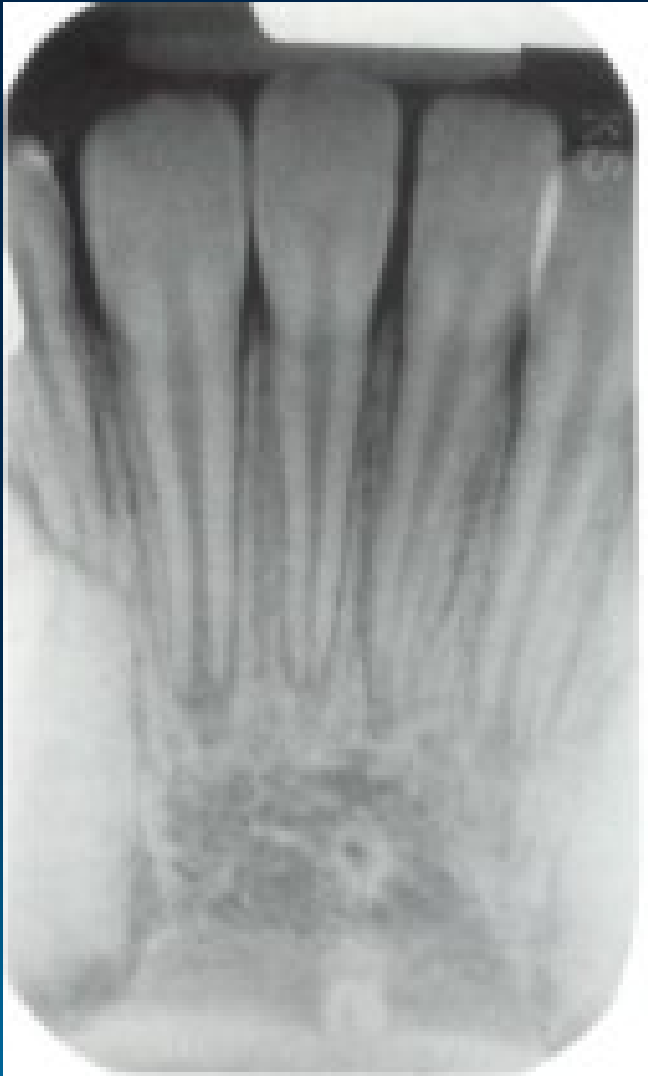- A highly detailed x-ray taken with the x-ray plate placed between your teeth
- It is useful to look closely at the front teeth (top or bottom) to check for any extra teeth or pathology
- A special type of occlusal radiography technique can help demonstrate stones in the salivary glands in the floor of the mouth



Full-Mouth X-Ray



Reading of x ray picture



Compact bone (lamina dura)
thin radiopaque (white) area
around tooth

Spongy bone
netting structure

Enamel

A radiopaque (white) area on the crown of the teeth

Dentine, Cementum

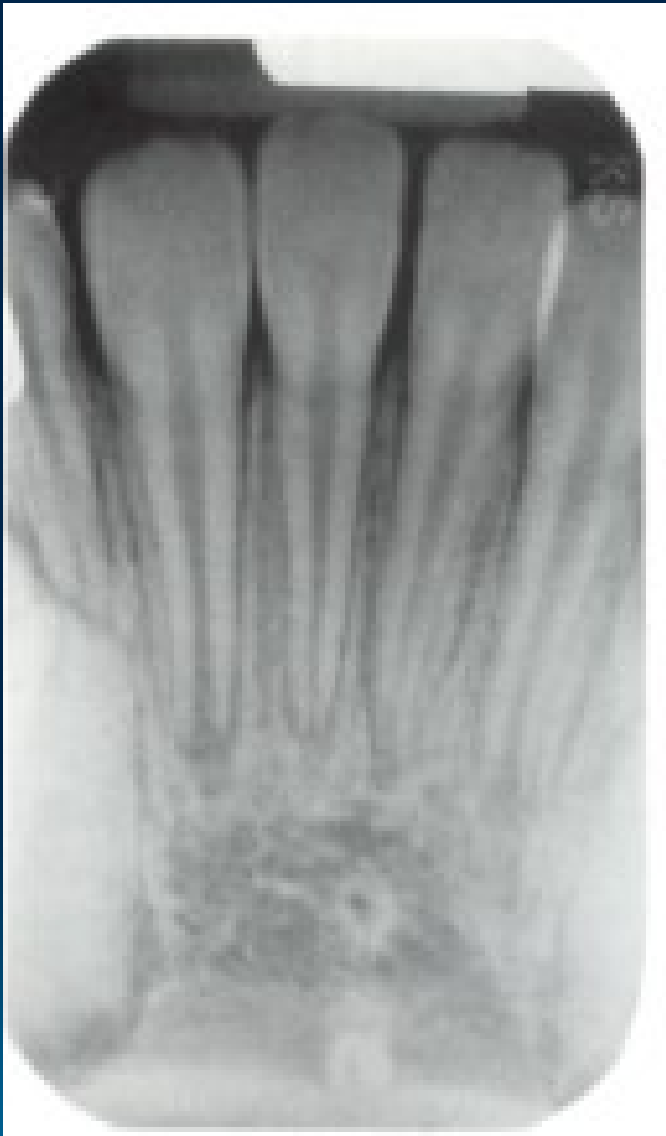less radiopaque than enamel, just inferior to it

Pulp chamber


A radiolucent (dark) area surrounded by dentin

Periodontal slit

A radiolucent area that surrounds the root(s)

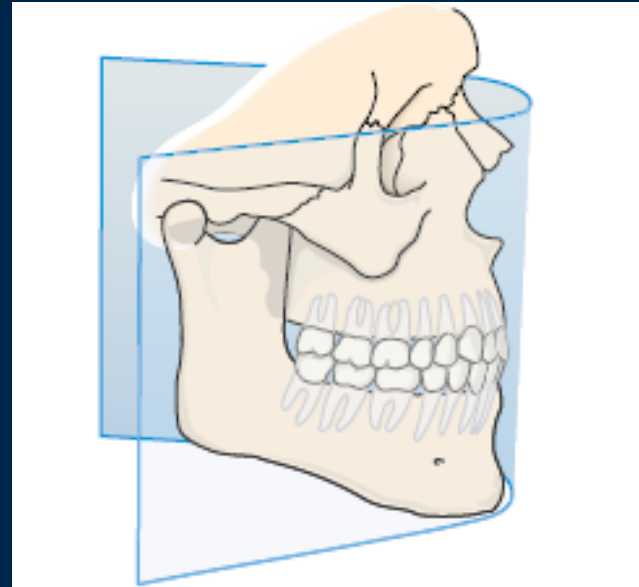


II. EXTRAORAL RADIOGRAPHY

- 1. Orthopantomography**
 - 2. Cephalometry**
 - 3. Conventional**
- 
- The background features several decorative, semi-transparent blue concentric circles of varying sizes, resembling ripples in water, scattered across the lower right portion of the slide.

1. Orthopantomography (OPG)

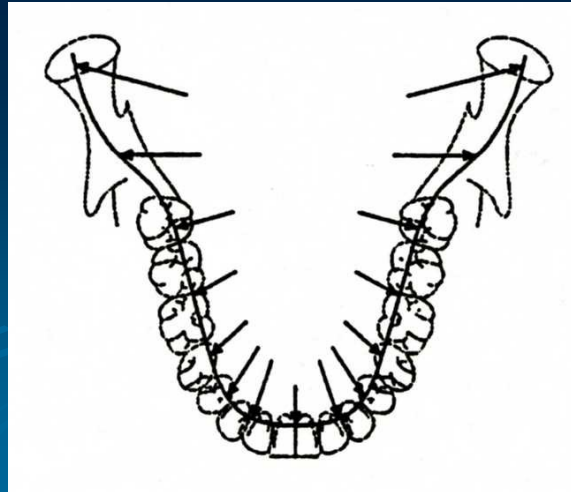
- Panoramic **extraoral** technique



- Used to examine both jaws, TMJ, maxillary sinuses and the teeth on a single image
- Convenient and inexpensive method with low radiation exposure

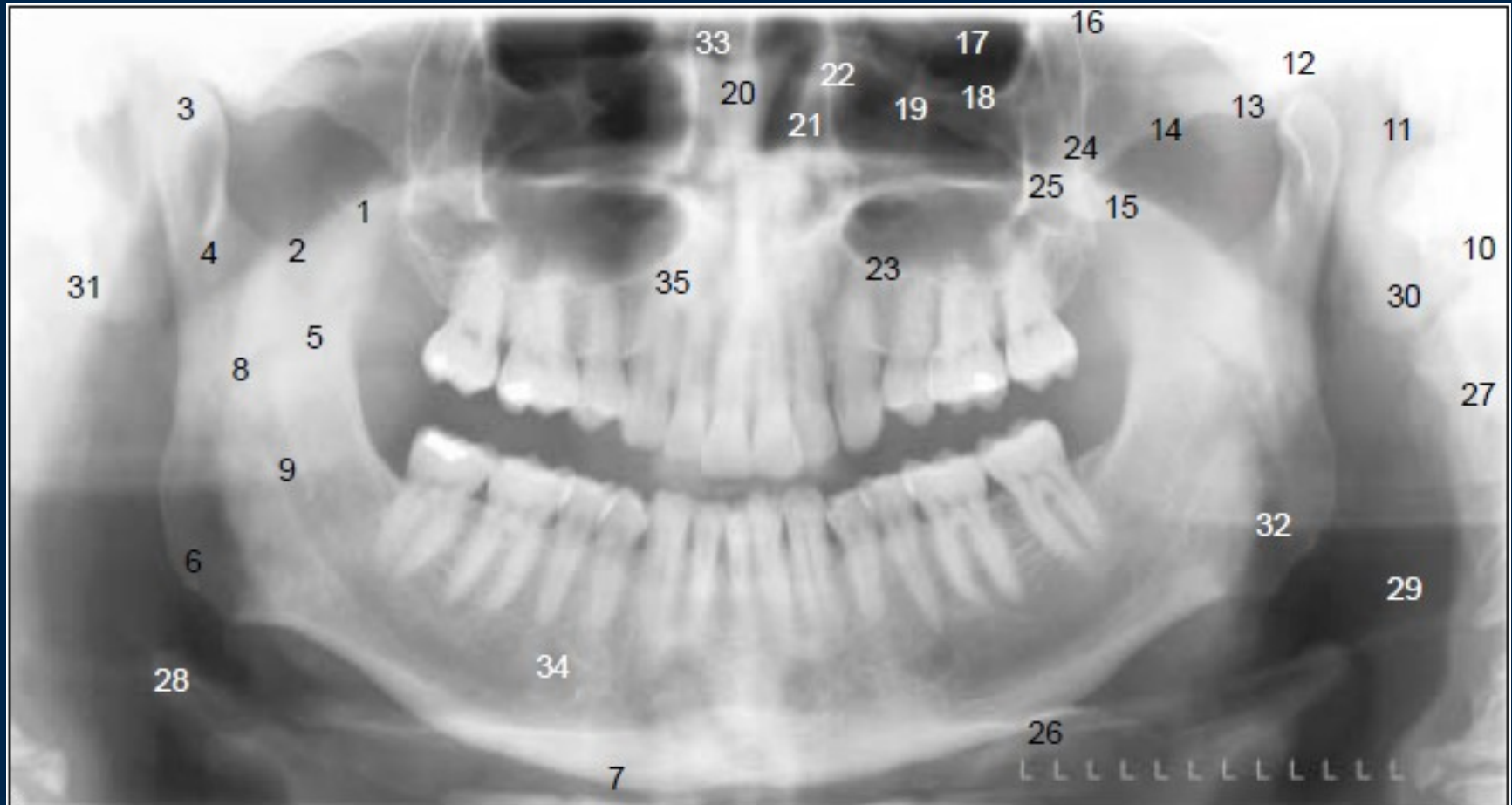
Extraoral film = indirect exposure type film

- The energy of the x-ray beam is converted into light by intensifying screens (the film is sandwiched between two screens) and this light is used to expose photographic type film
- **Orthoradial projection** – minimizes crown overlapping



- Patient is positioned with the Frankfort plane horizontal, bite peg between the anterior teeth and the chin positioned on the chin support
- The film and the tubehead rotate around the patient and produce a series of individual images in a single film






1. Coronoid Process
2. Sigmoid Notch
3. Mandibular Condyle
4. Condylar Neck
5. Mandibular Ramus
6. Angle of Mandible
7. Inferior Border of Mandible
8. Lingula
9. Mandibular Canal
10. Mastoid Process
11. External Auditory Meatus
12. Glenoid Fossa

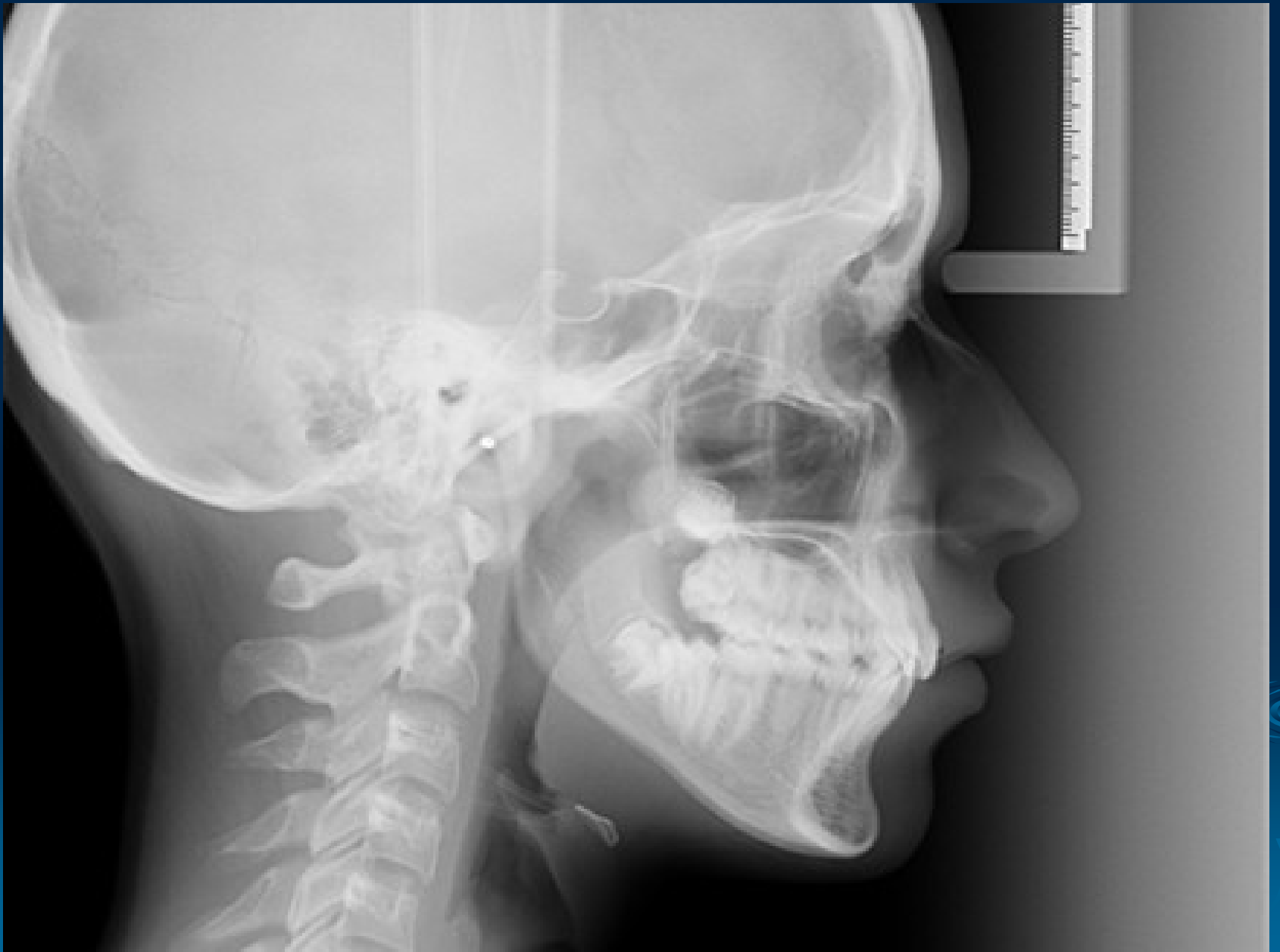13. Articular Eminence
14. Zygomatic Arch
15. Pterygoid Plates
16. Pterygomaxillary Fissure
17. Orbit
18. Inferior Orbital Rim
19. Infraorbital Canal
20. Nasal Septum
21. Inferior Turbinate
22. Medial Wall of Max. Sinus
23. Inferior Border of Max. Sinus
24. Posterolateral Wall of Max. Sinus

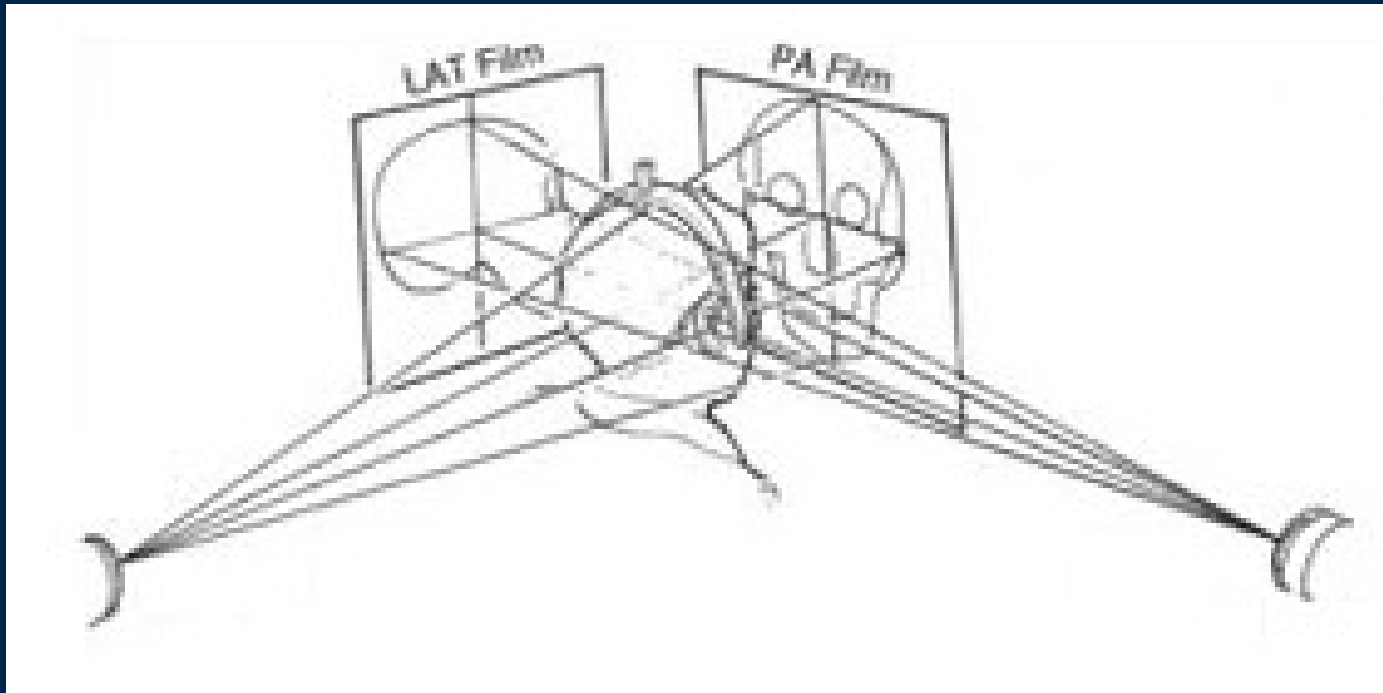
25. Malar Process
26. Hyoid Bone
27. Cervical Vertebrae 1- 4
28. Epiglottis
29. Soft Tissues of Neck (Look Vertically For Corotid Artery Calcifications Here)
30. Auricle
31. Styloid Process
32. Oropharyngeal Air Space
33. Nasal Air Space
34. Mental Foramen
35. Hard Palate

2. Cephalometry

- A standardized and reproducible form of skull radiography used extensively **in orthodontics** to assess the relationships of the teeth to the jaws and the jaws to the rest of the facial skeleton
- Main indications - monitoring treatment progress, preoperative evaluation of skeletal and soft tissue patterns, postoperative appraisal of the results of surgery and long-term follow-up studies

- The patient is positioned within the **cephalostat** with the Frankfort plane horizontal, teeth should be in maximum intercuspation
 - The head is immobilized within the apparatus with the plastic ear rods being inserted into the external auditory meati
 - The x-ray beam is horizontal and centred on the ear rods
 - Soft x-rays
- 





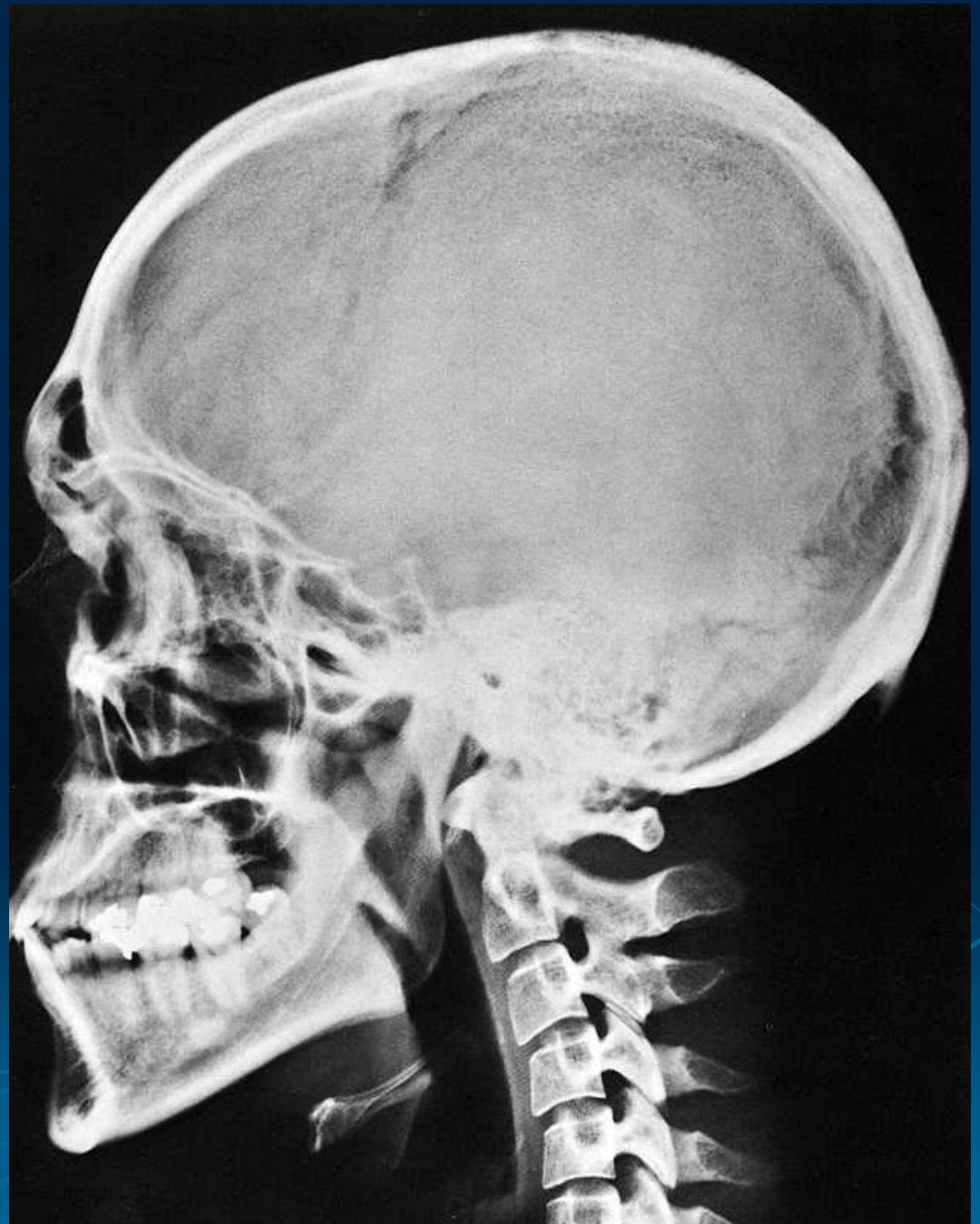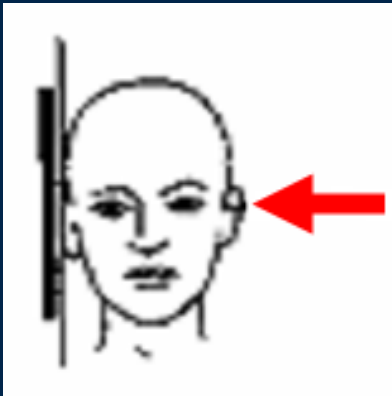
Main radiographic projections: **lateral**
PA jaws

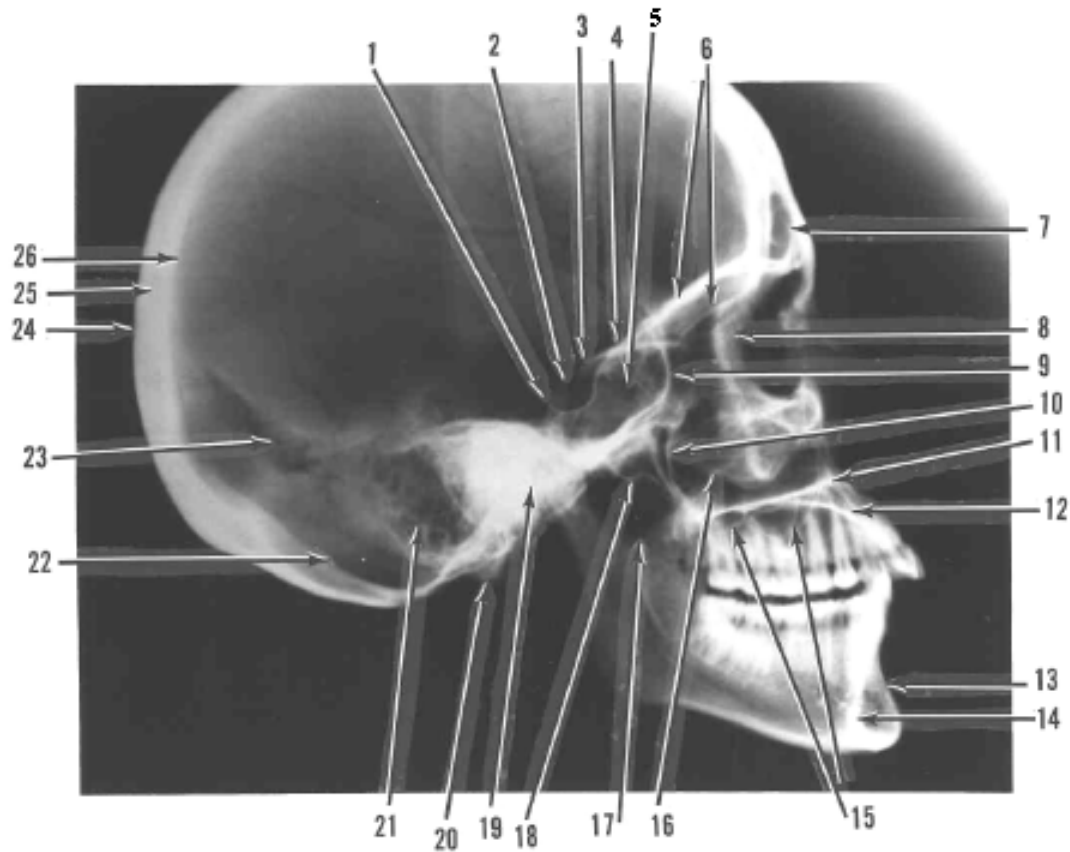
3. Conventional Radiography

Skull projection: Lateral
Postero-anterior

Facial projection: Submento-vertical
Hirtz
Waters
Clementsich

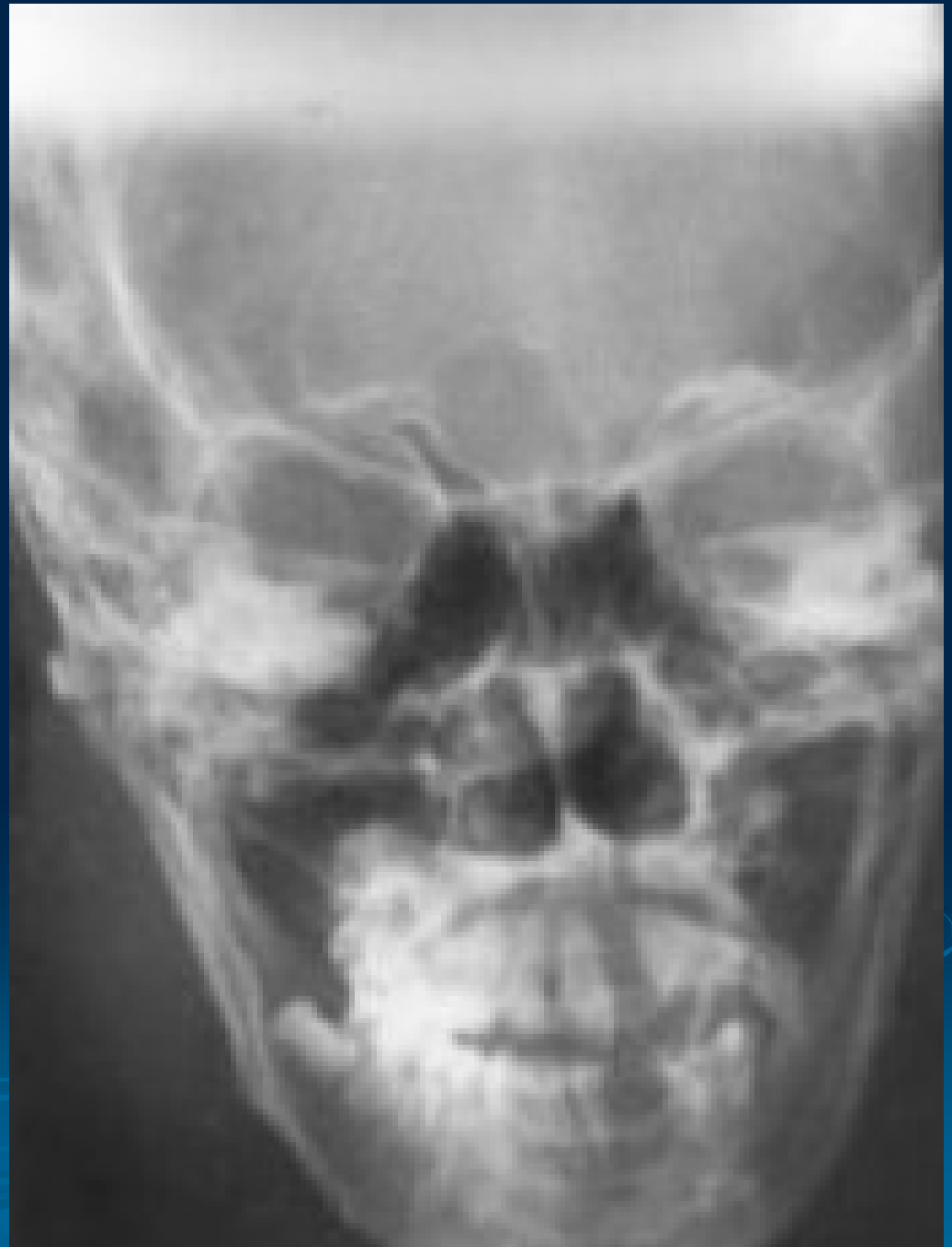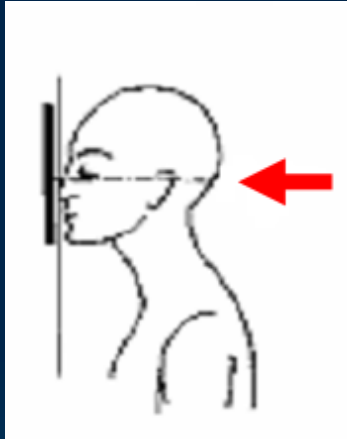
Lateral Projection

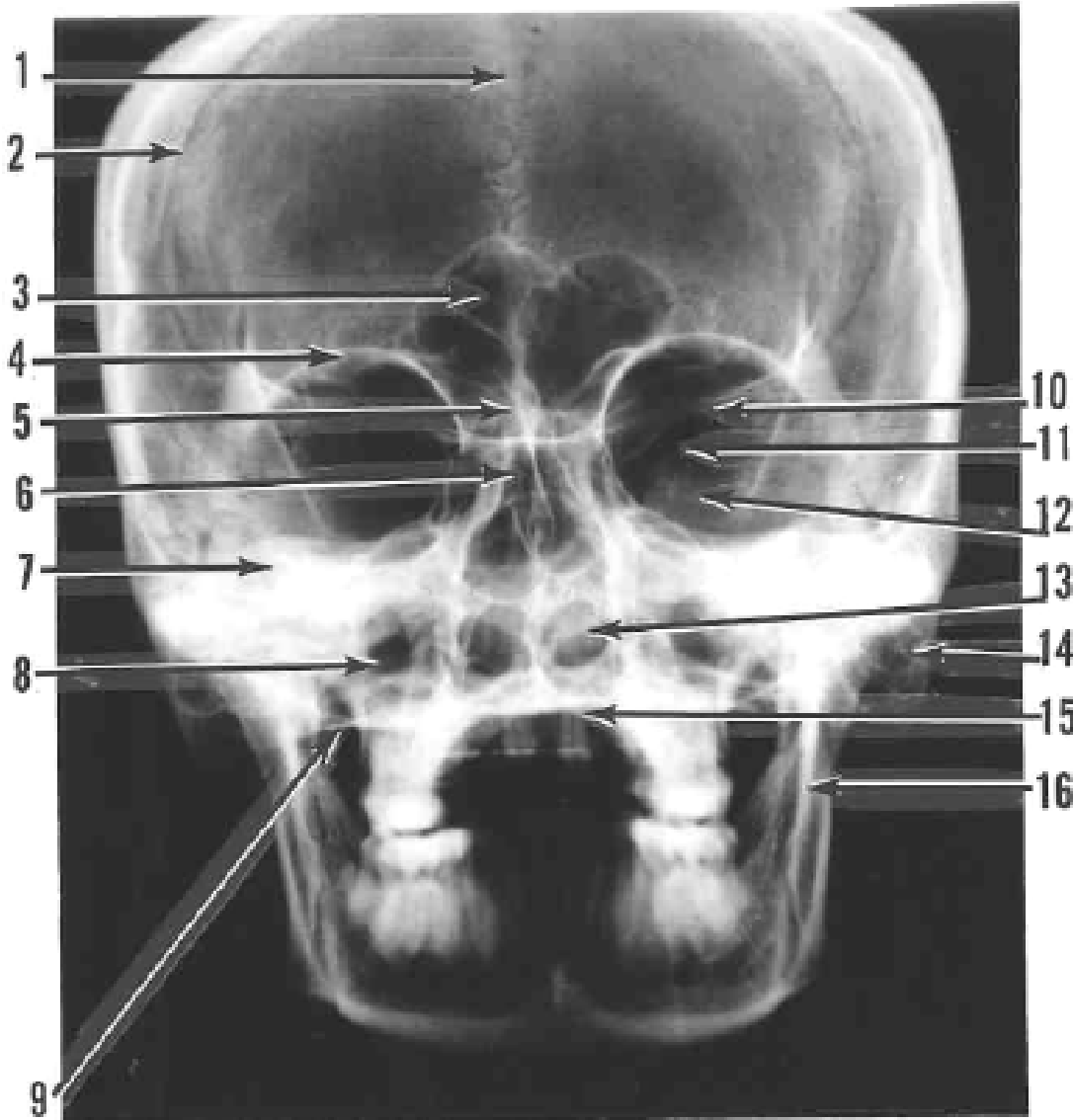




1. Posterior clinoid process
2. Sella turcica (pituitary fossa)
3. Anterior clinoid process
4. Floor of anterior cranial fossa in the midline
5. Sphenoid sinus
6. Orbital plates of frontal bone
(Roof of orbit and floor of anterior cranial fossa lateral to midline)
7. Frontal sinus
8. Lateral border of orbit (formed by frontal process of zygoma, and zygomatic process of frontal bone)
9. Greater wing of the sphenoid bone forming the anterior wall of the middle cranial fossa
10. Pterygomaxillary fissure
11. Hard palate forming floor of nasal fossa
12. Roof of palate (midline)
13. Buccal cortical plate of anterior portion of mandible
14. Lingual cortical plate of anterior portion of mandible
15. Floor of maxillary sinus
16. Zygoma (arrow points at lower border of zygoma)
17. Sigmoid notch (mandibular notch)
18. Lateral pterygoid plate
19. Petrous portion of temporal bone
20. Mastoid process of temporal bone
21. Mastoid air cells
22. Lambdoid suture
23. Outer table of bone
24. Diploe
25. Inner table of bone
26. Inner table of bone

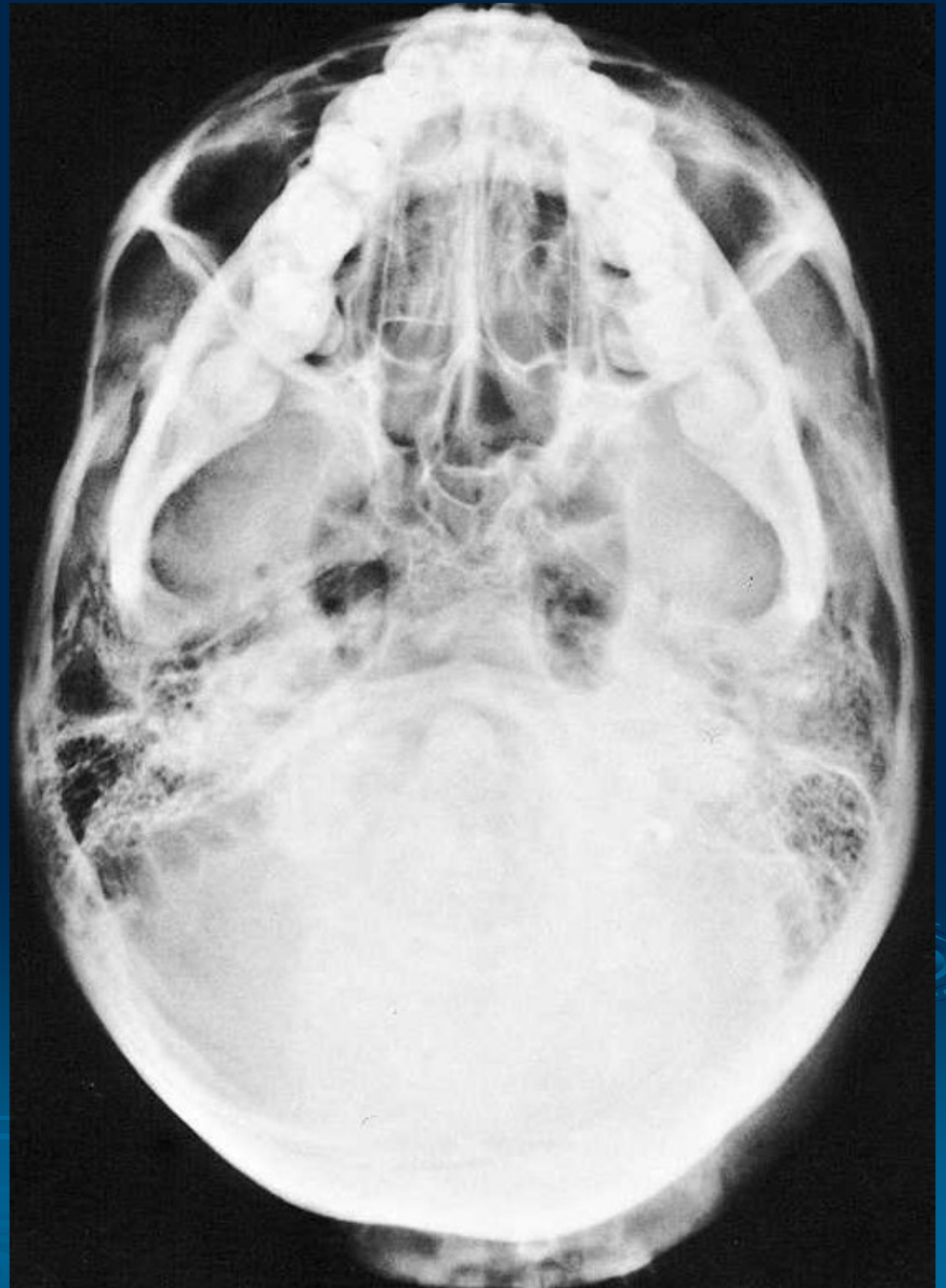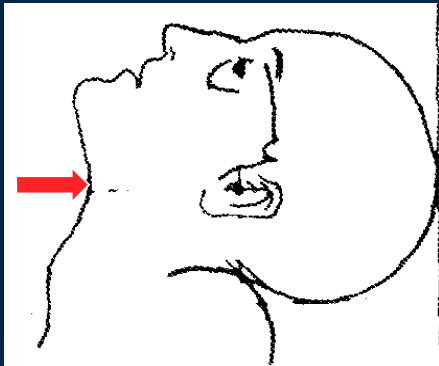
Postero-Anterior Projection

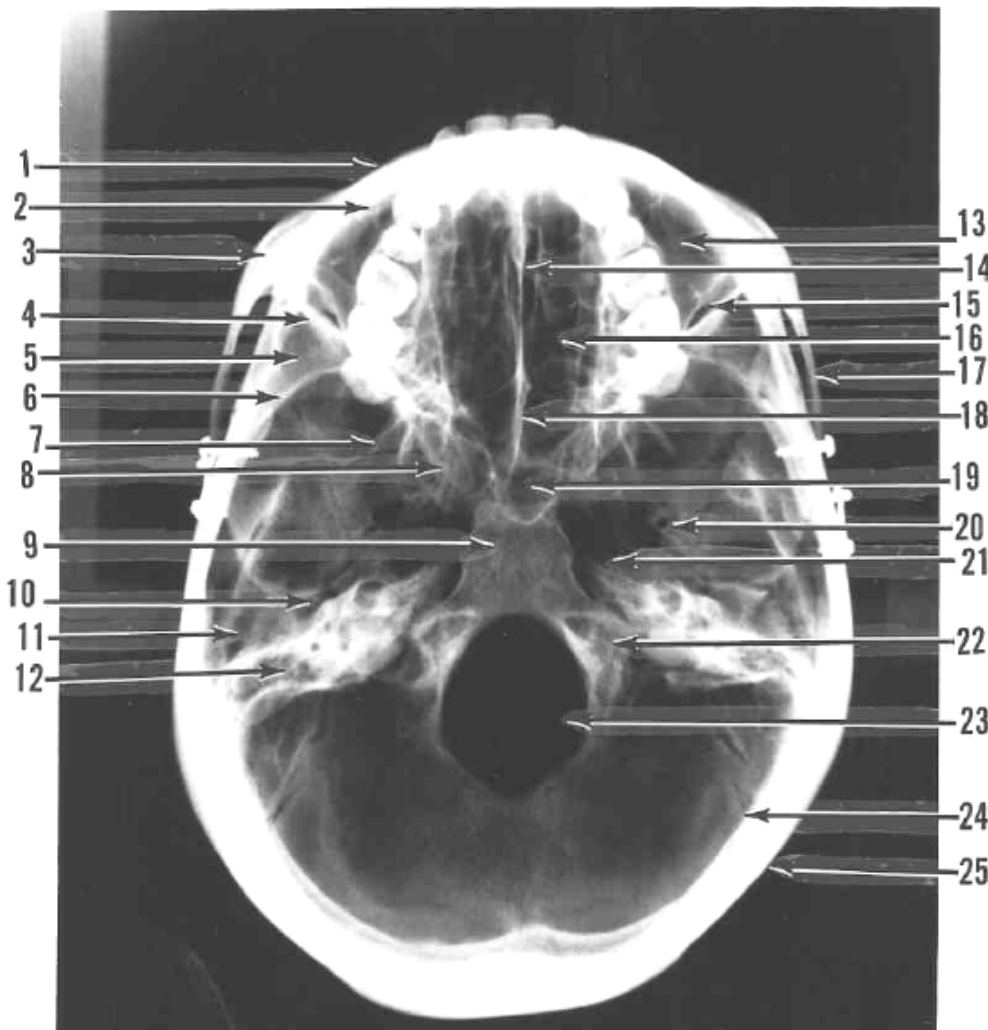




1. Sagittal suture
2. Coronal suture
3. Frontal sinus
4. Superior border of orbit
5. Crista galli
6. Sphenoid sinus
7. Petrous portion of temporal bone
8. Maxillary sinus
9. Floor of posterior cranial fossa
10. Lesser wing of sphenoid
11. Superior orbital fissure
12. Greater wing of sphenoid
13. Nasal cavity
14. Mastoid process and mastoid air cells
15. Floor of nasal fossa (hard palate)
16. External oblique ridge

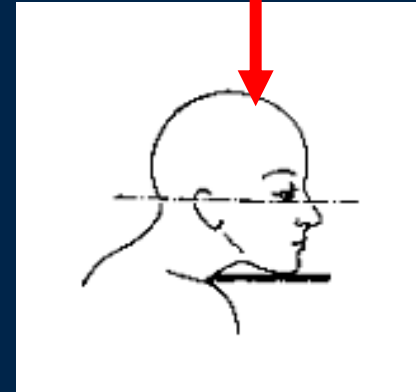
Submento-Vertical Projection



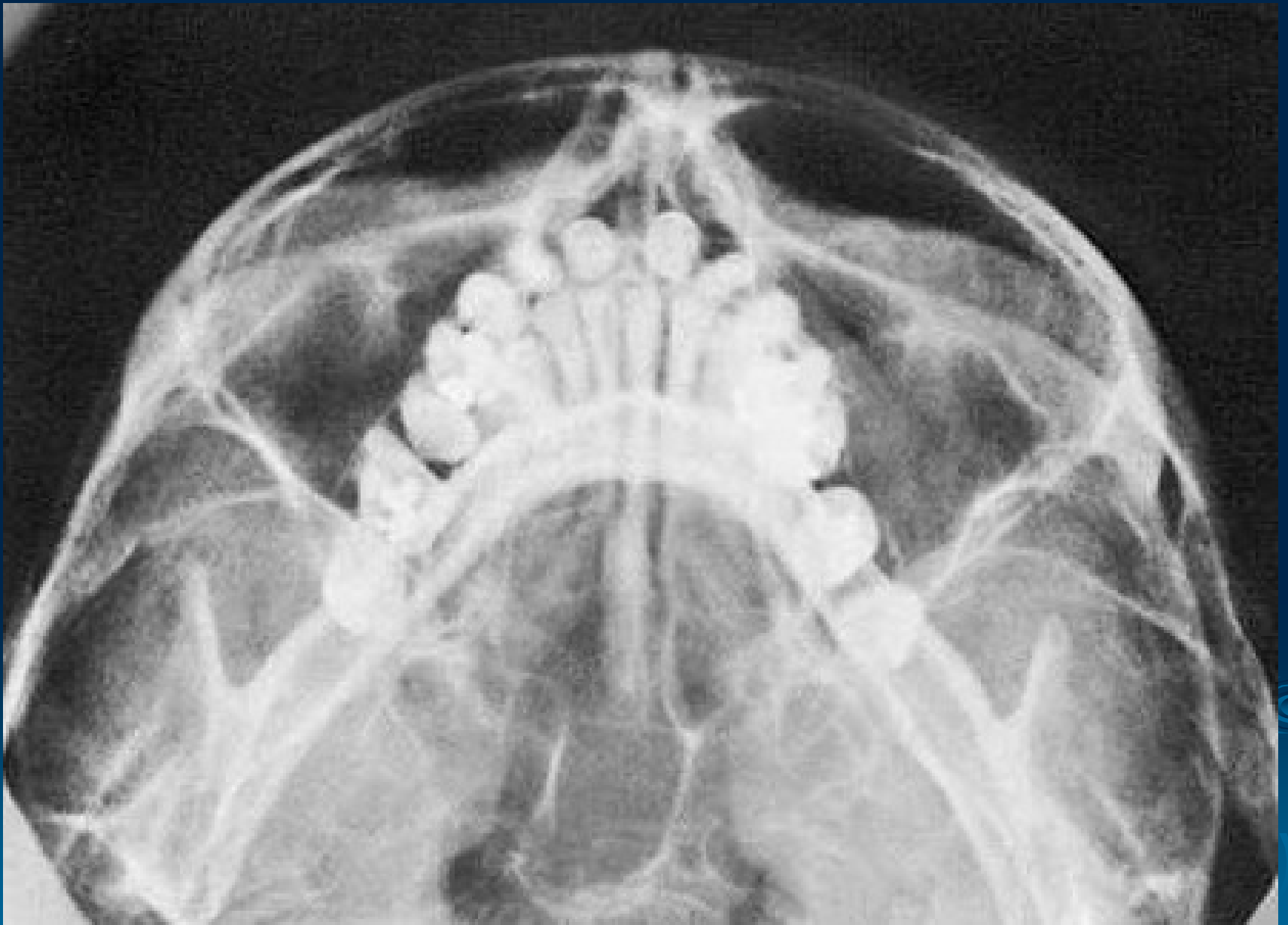

1. Outer cortical plate of frontal bone
2. Inner cortical plate of frontal bone
3. Body of zygoma
4. Lateral wall of orbit (greater wing of sphenoid)
5. Infratemporal surface of greater wing of sphenoid
6. Anterior wall of middle cranial fossa formed by the greater wing of sphenoid
7. Lateral pterygoid plate
8. Medial pterygoid plate
9. Clivus
10. Eustachian canal (internal auditory canal)
11. External auditory canal
12. Petrous portion of temporal bone
13. Maxillary sinus (superimposed on orbit)
14. Nasal septum (perpendicular plate of ethmoid)
15. Inferior orbital fissure
16. Ethmoid air cells opening into nasal fossa
17. Zygomatic arch
18. Posterior border of vomer (part of nasal septum)
19. Sphenoid sinus
20. Foramen spinosum
21. Foramen lacerum
22. Occipital condyle
23. Foramen magnum
24. Inner cortical plate of occipital bone
25. Outer cortical plate of occipital bone

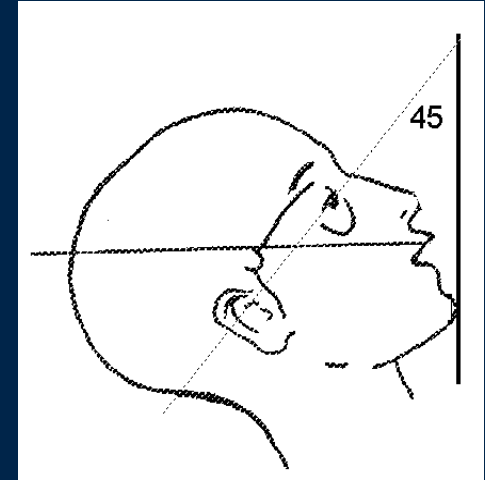
Hirtz' Projection



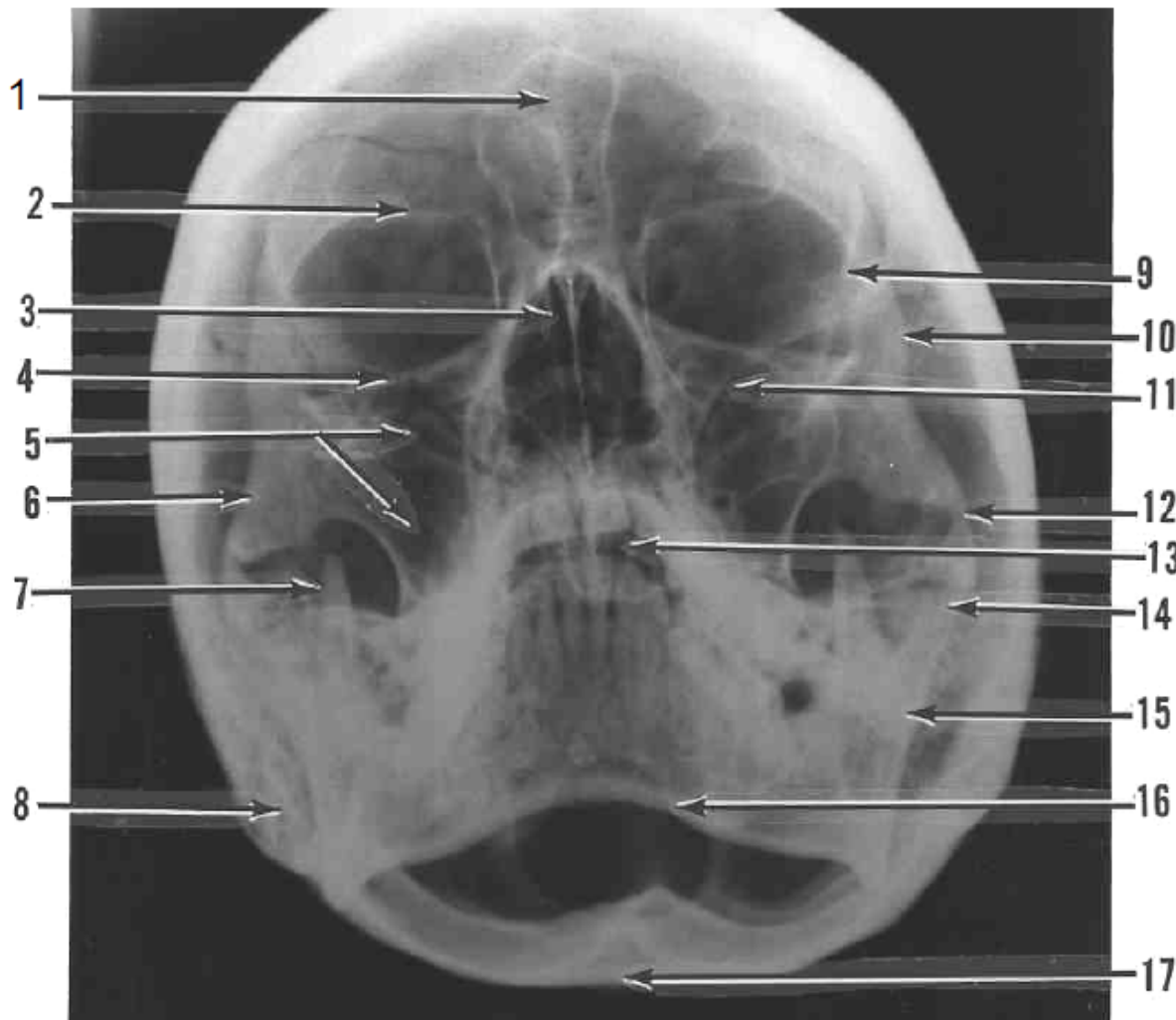
- The vertical submental projection
- The central ray is centred between the angles of the jaw the mandibular arch and condyles, the skull base, sphenoid sinus and the posterior ethmoid cells



Waters Technique

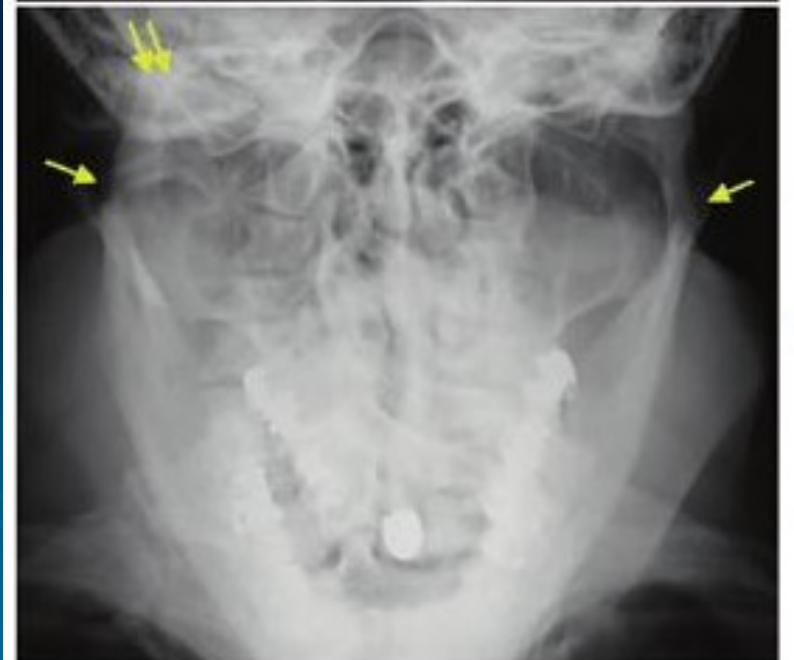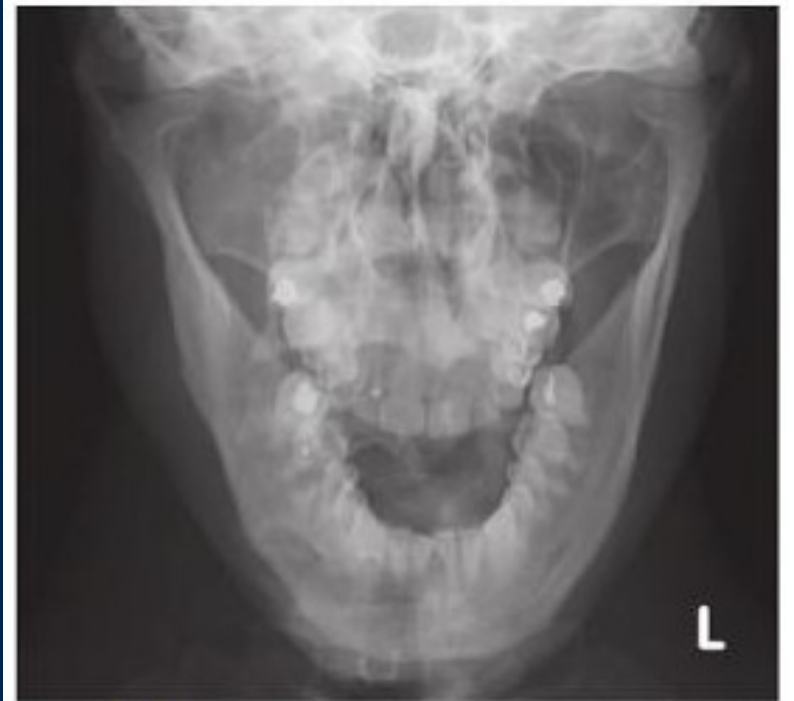
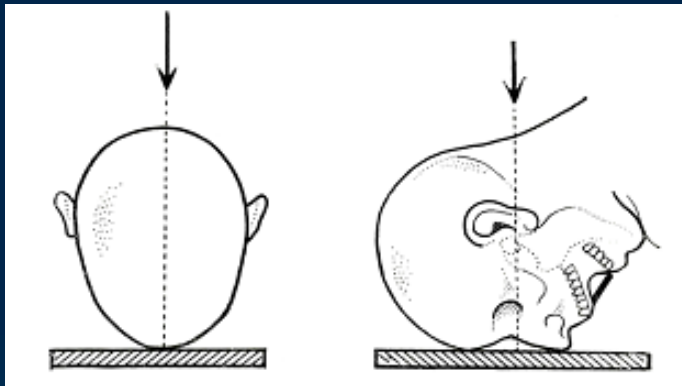


- Postero-anterior projection
- The paranasal sinuses, orbital floor, orbital rim, mandible zygomatic arch and temporal line determine a possible fluid level indicative of sinusitis or soft tissue proliferations within sinus



1. Frontal sinus
2. Supraorbital notch
3. Ethmoid sinus
4. Anterior margin of orbital floor
5. Maxillary sinus
6. Body of zygoma
7. Coronoid process
8. Mastoid air cells
9. Squamozygomatic surface of greater wing of sphenoid (innominate line)
10. Frontal process of zygoma (joins the zygomatic process of frontal bone)
11. Lesser wing of sphenoid (the radiolucent line is the superior orbital fissure)
12. Zygomatic arch
13. Sphenoid sinus
14. Condyle
15. Ramus of mandible
16. Inferior border of body of mandible
17. Inferior aspect of base of skull

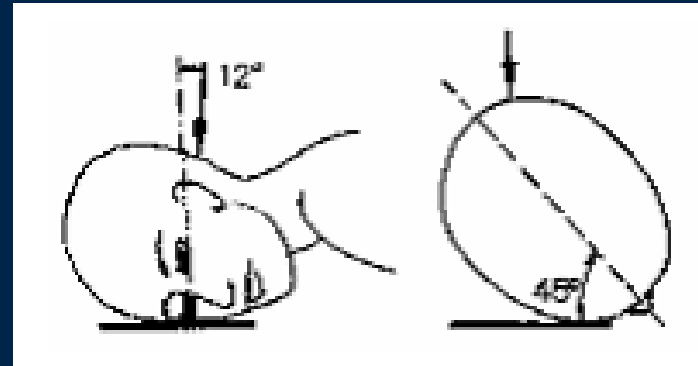
Clementschitsch View



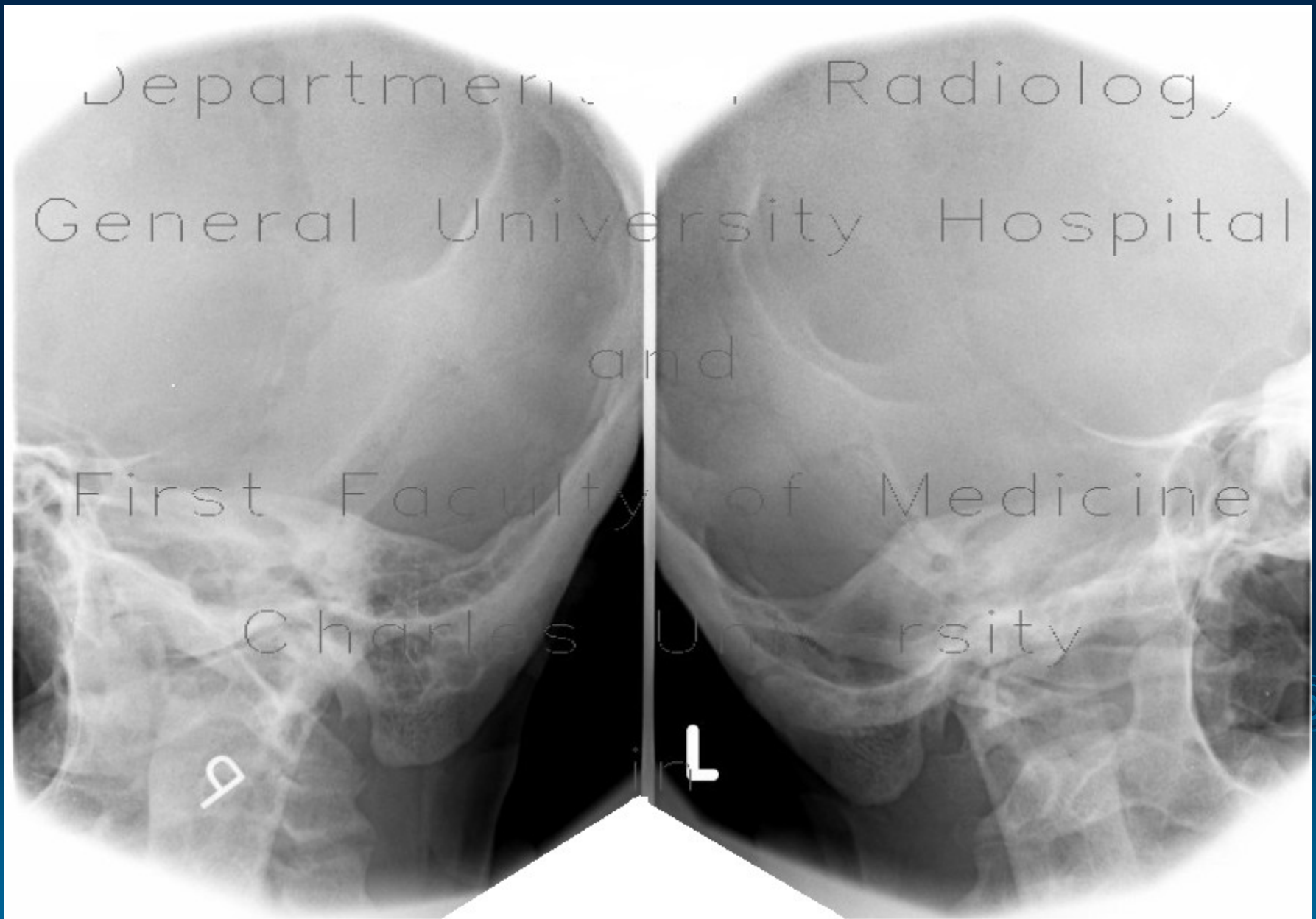
III. SPECIFIC RADIOGRAPHY

- **Stenvers projection**
- **Schullers projection**
- **Alber-Schonberg view**

Stenvers Projection

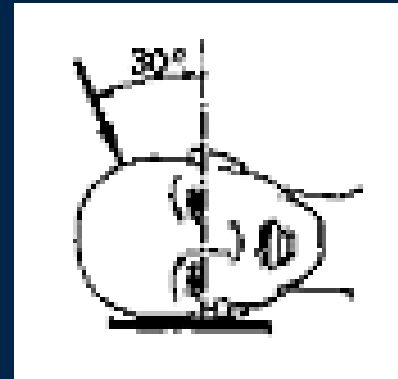


- Position with the head rotated 45° toward the opposite side to the side under examination
- The central X-ray beam passes between the orbit and external auditory canal 12° caudad
- General overview of the petrous bone



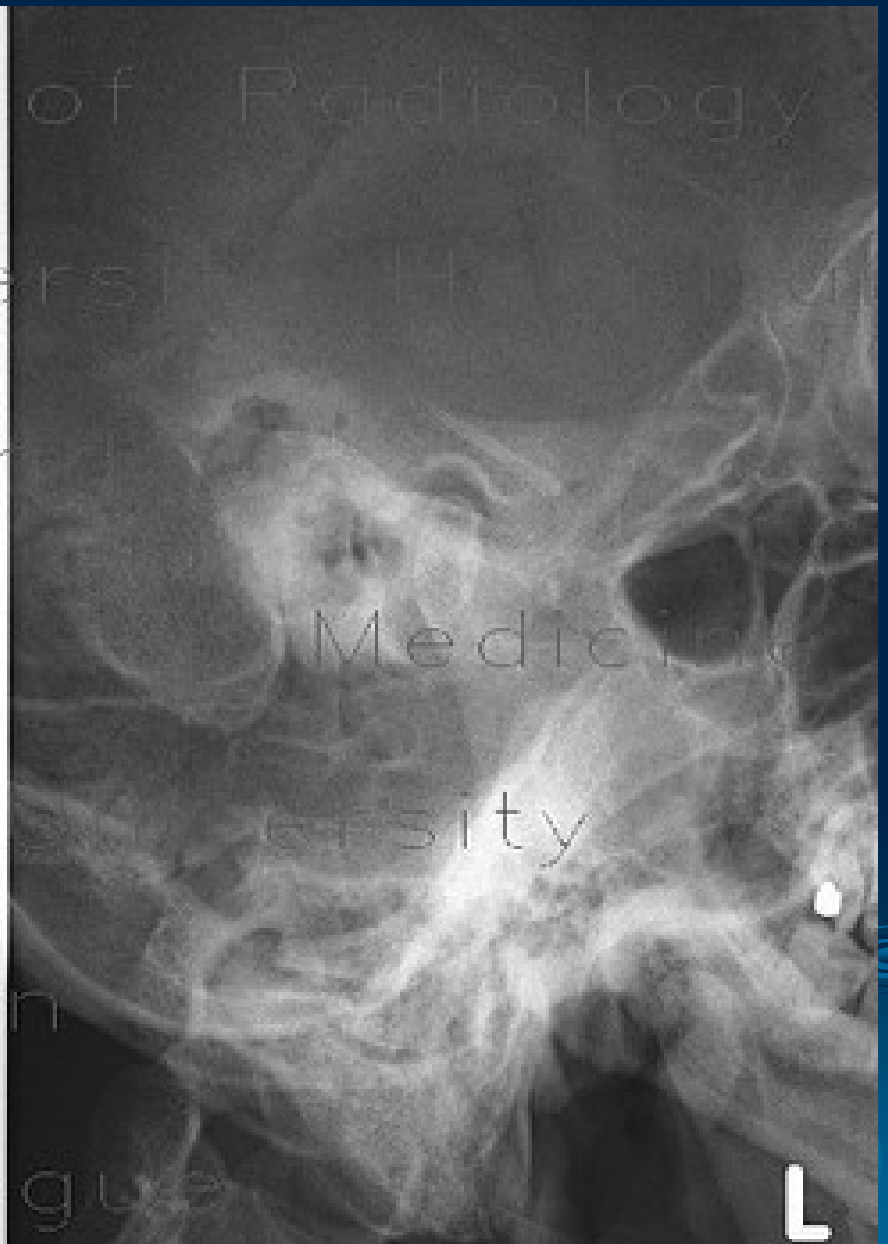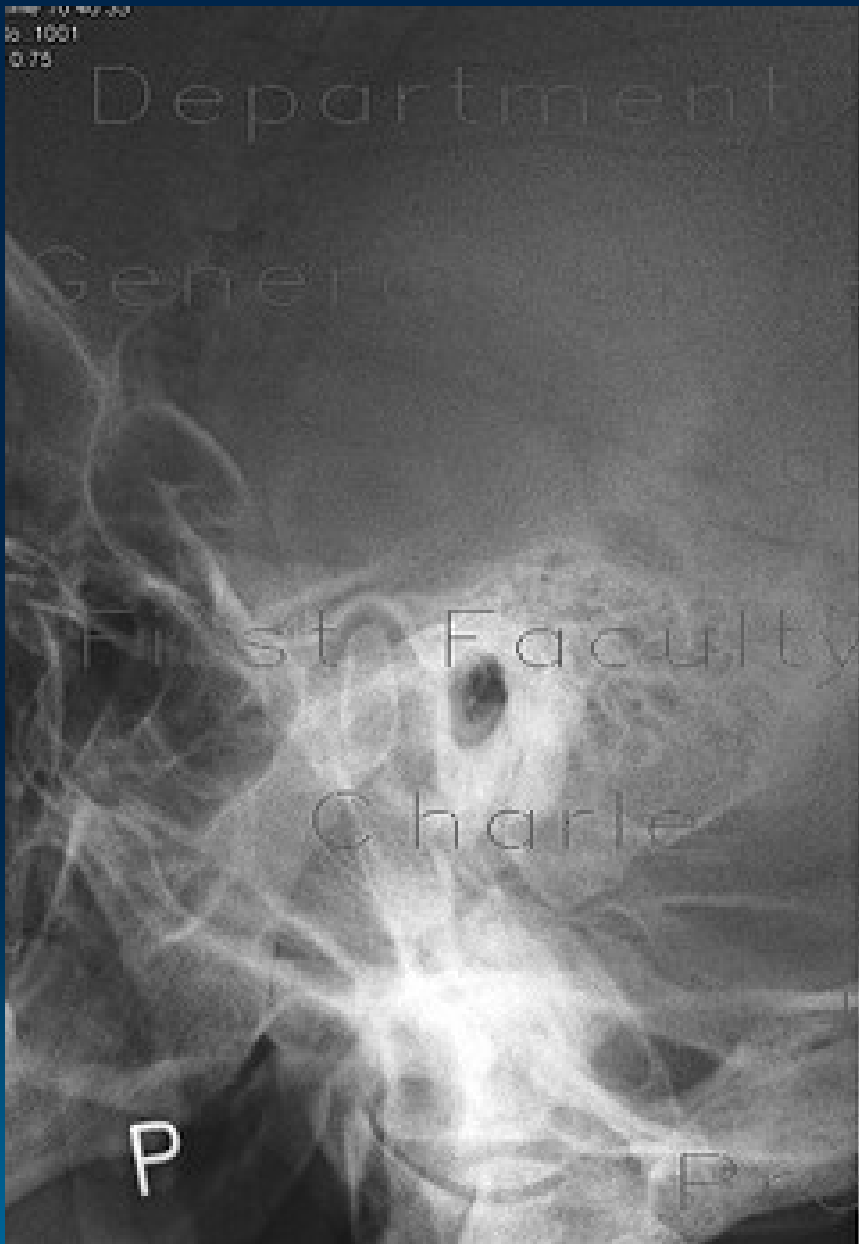
Department of Radiology,
General University Hospital
and
First Faculty of Medicine
Charles University

Schuller's Projection



- Position with the head turned laterally on the side to be examined
- The X-ray tube is angled craniocaudally (about 25°); the central X-ray exits the external auditory canal to be examined view with the mouth closed and opened allows appreciation of the temporomandibular joint dynamics

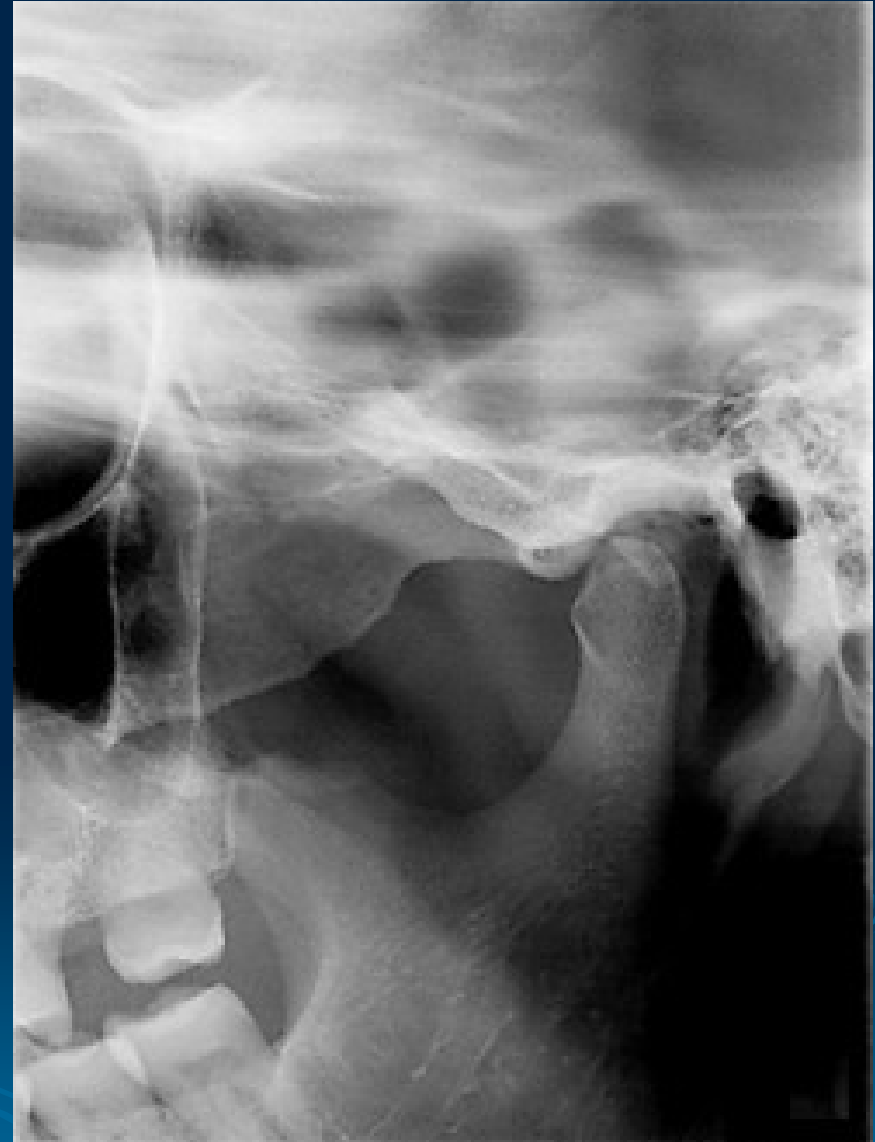0000-0000-0000
00-0001
0.75



Albers-Schonberg View

**Lateral transfacial
position**

- demonstrated in open
and closed positions (both
sides are examined
for comparison)



IV. CONTRAST IMAGING

- **Sialography**
 - **Arthrography**
 - **Antrography**
 - **Cystography**
 - **Fistulography**
 - **Angiography ...**
- 

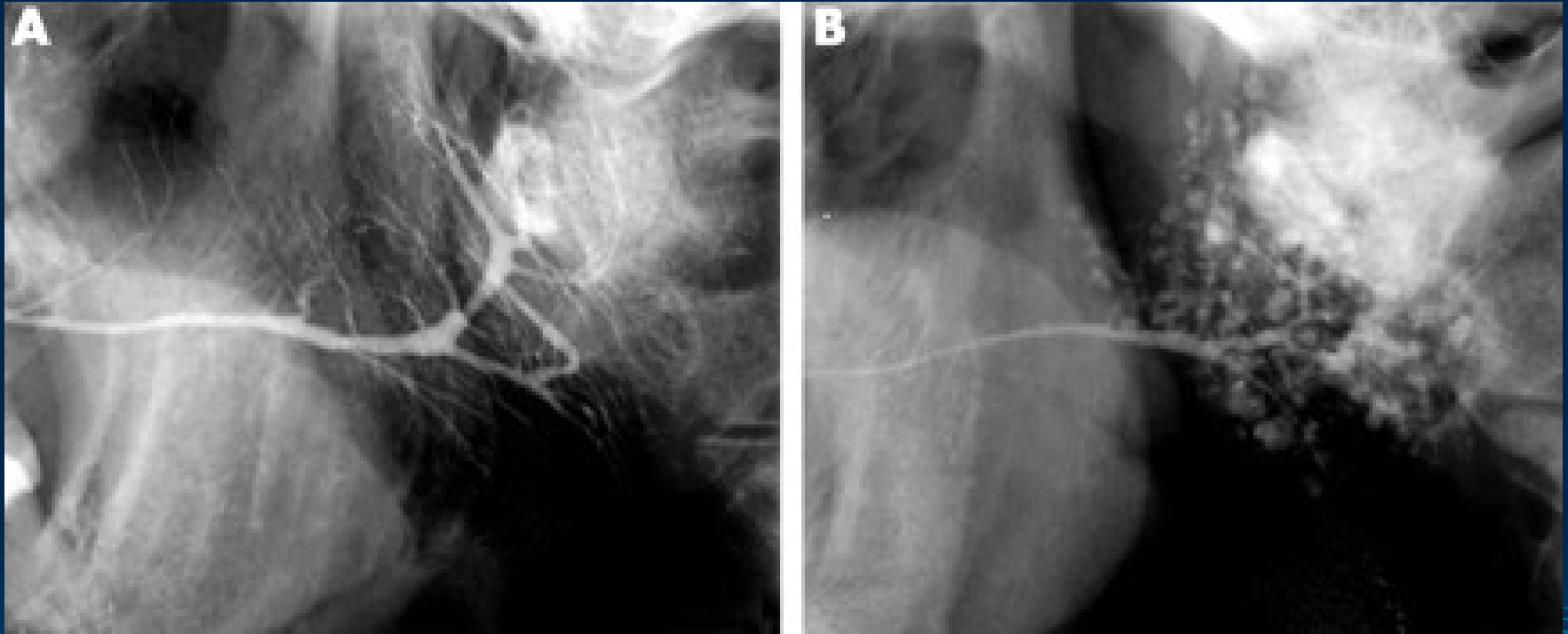
Contrast Medium

- any substance that is used to enhance the visibility of structures or fluids within the body

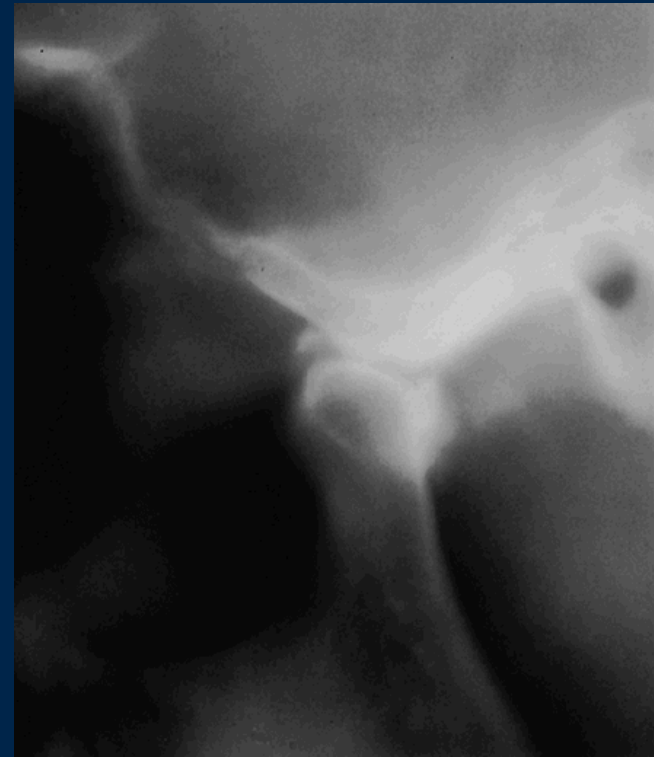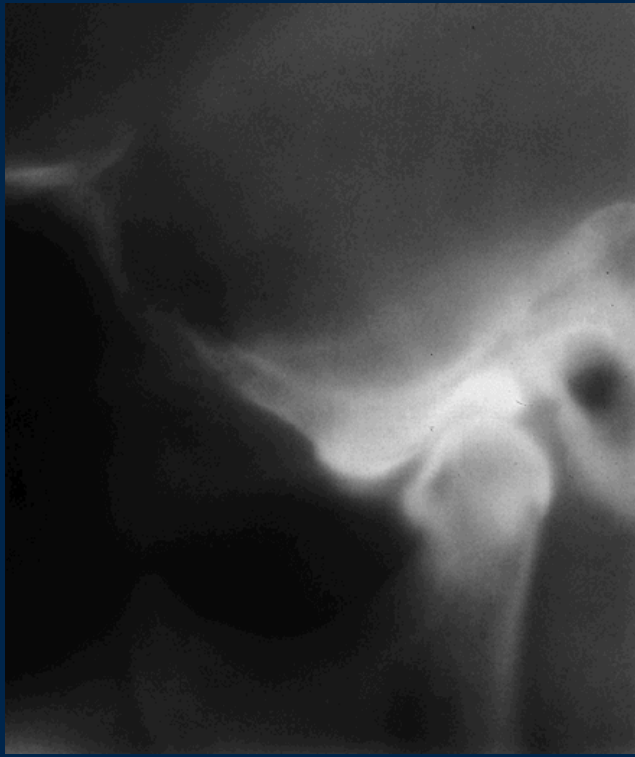Negative contrast media - gas - air, CO₂, oxygen (contrast looks less opaque than the surrounding tissue)

Positive contrast media - iodine, technecium

Double contrast media - iodine + gas



Sialogram with Sjögren's syndrome



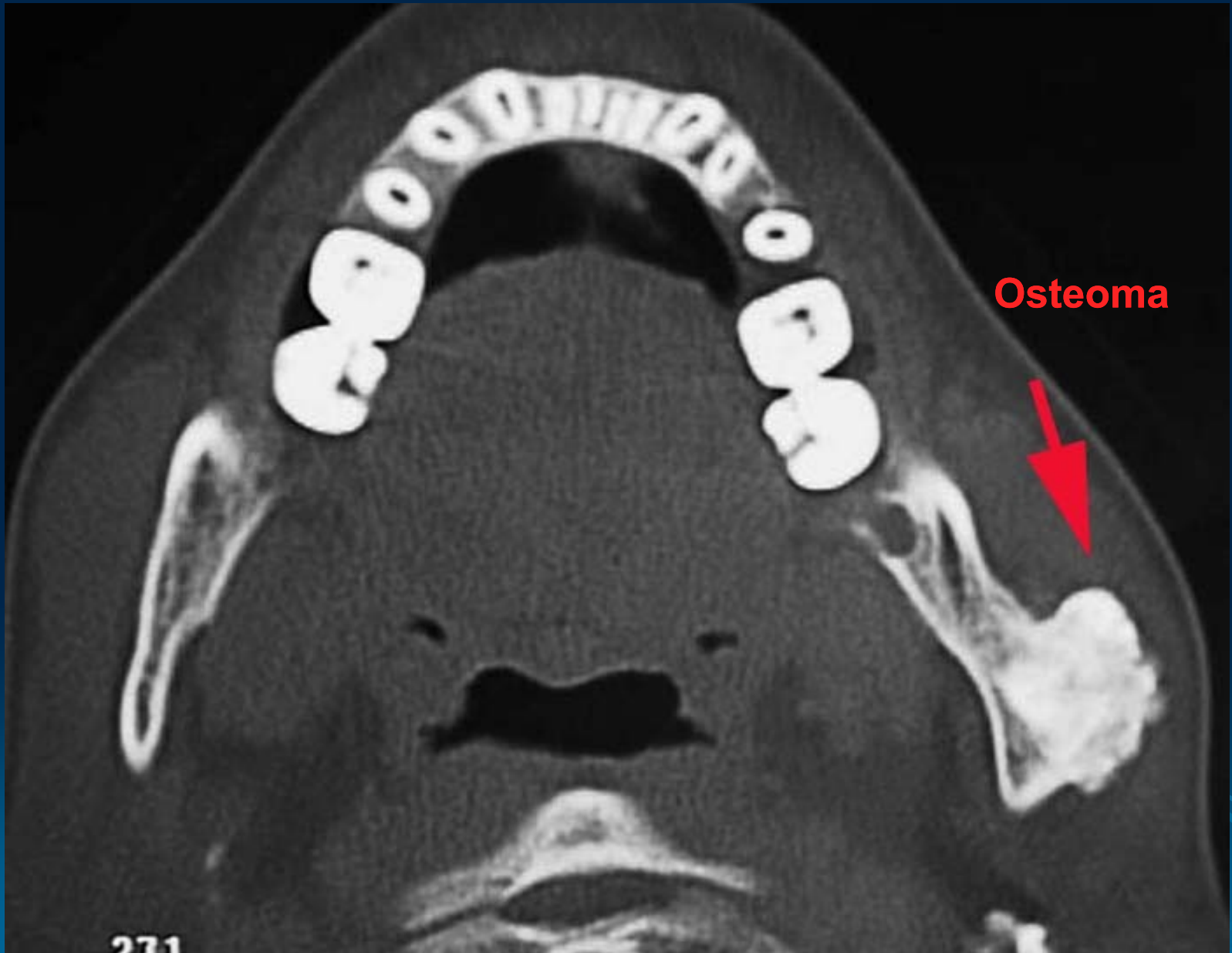Arthrography:

single-contrast arthrography - injection of contrast medium

double-contrast arthrography - injection of contrast medium and injection of air

V. COMPUTERIZED TOMOGRAPHY

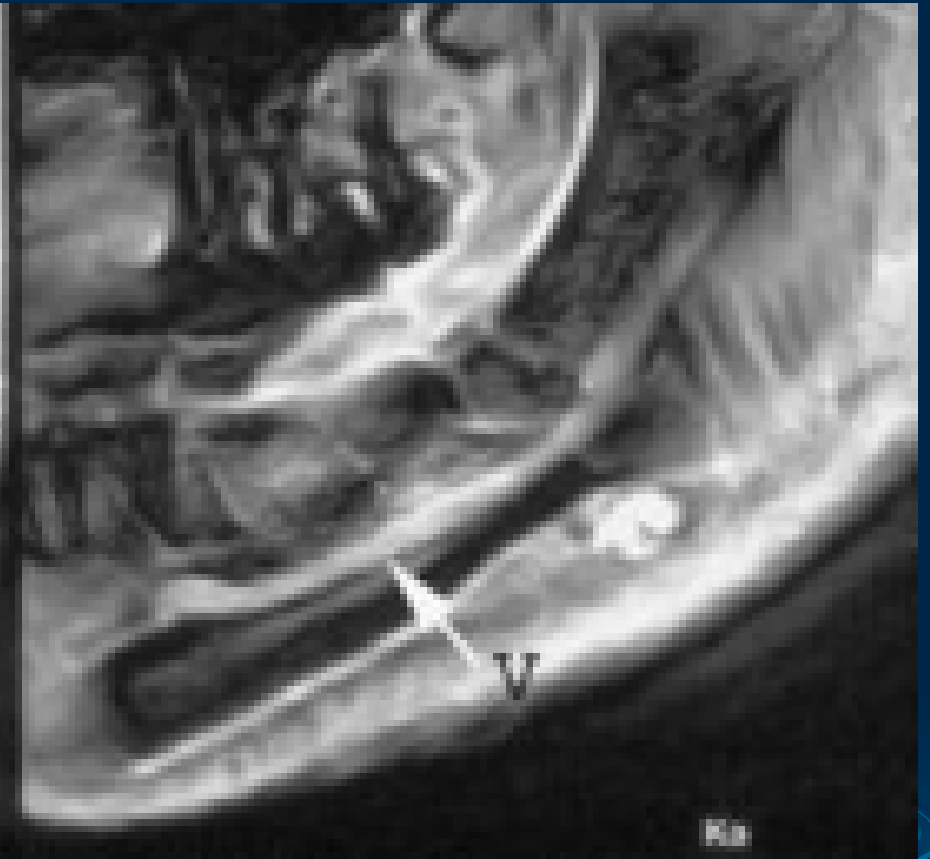
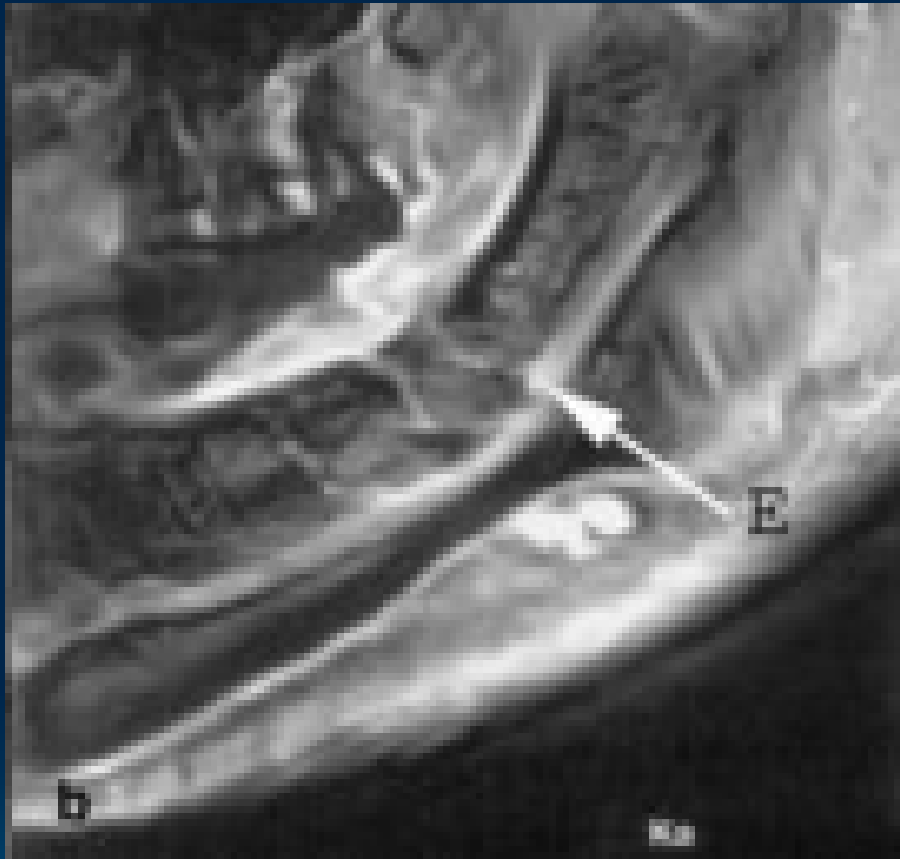
- A non-invasive **x-ray technique**
- More sensitive than conventional x-rays
- Creating 2 or high-quality 3 dimensional images, scanning in seconds
- Abnormal findings can reveal tumors, nodules, cysts, enlarged lymph nodes, and pleural effusions



Osteoma

Magnetic Resonance Imaging

- MRI allows visualization of soft tissue (muscles, fat, and internal organs) without the use of x-rays
- Using two natural, safe forces, **magnetic fields and radio waves**
- Can look “through” hard bones to examine soft tissue



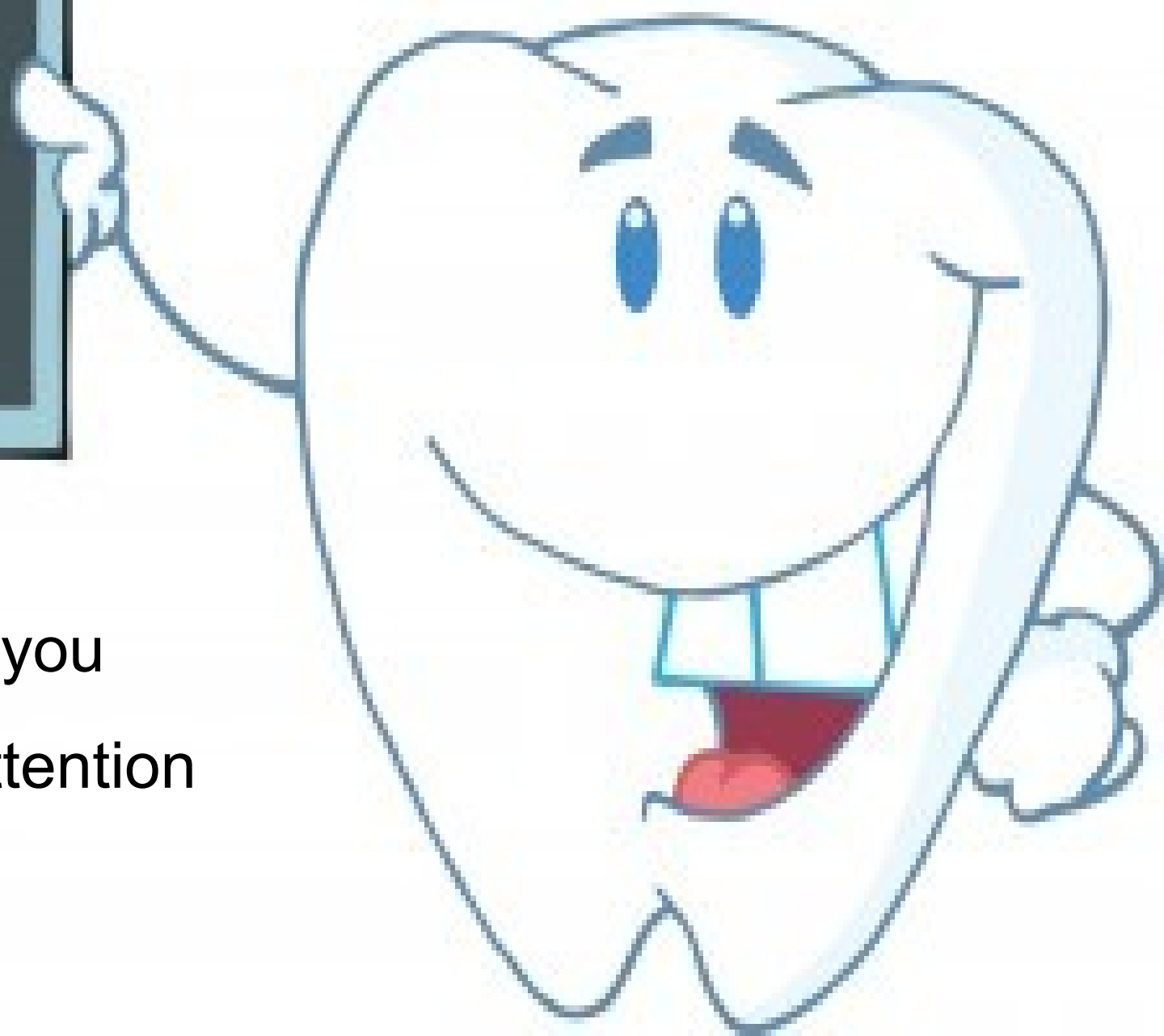
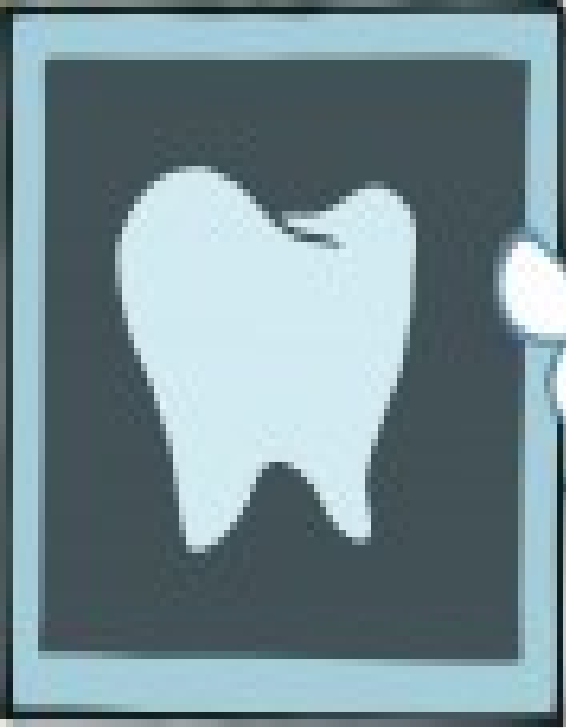[Redacted text]



Ultrasonography

- A noninvasive procedure
- High frequency **sound waves** are emitted from the transducer and received by the transducer, forming an image that is displayed on the monitor





Thank you
for your attention