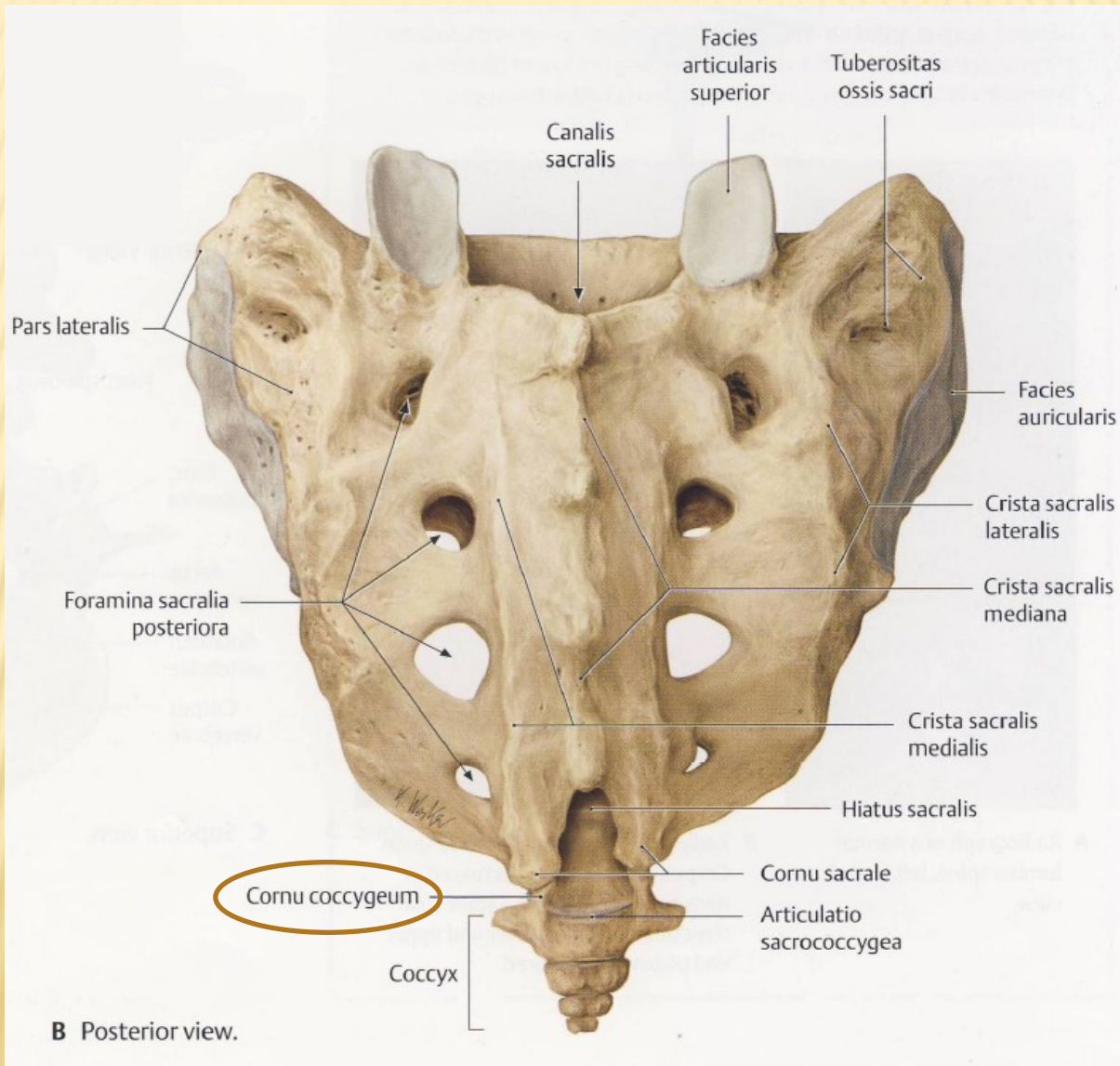
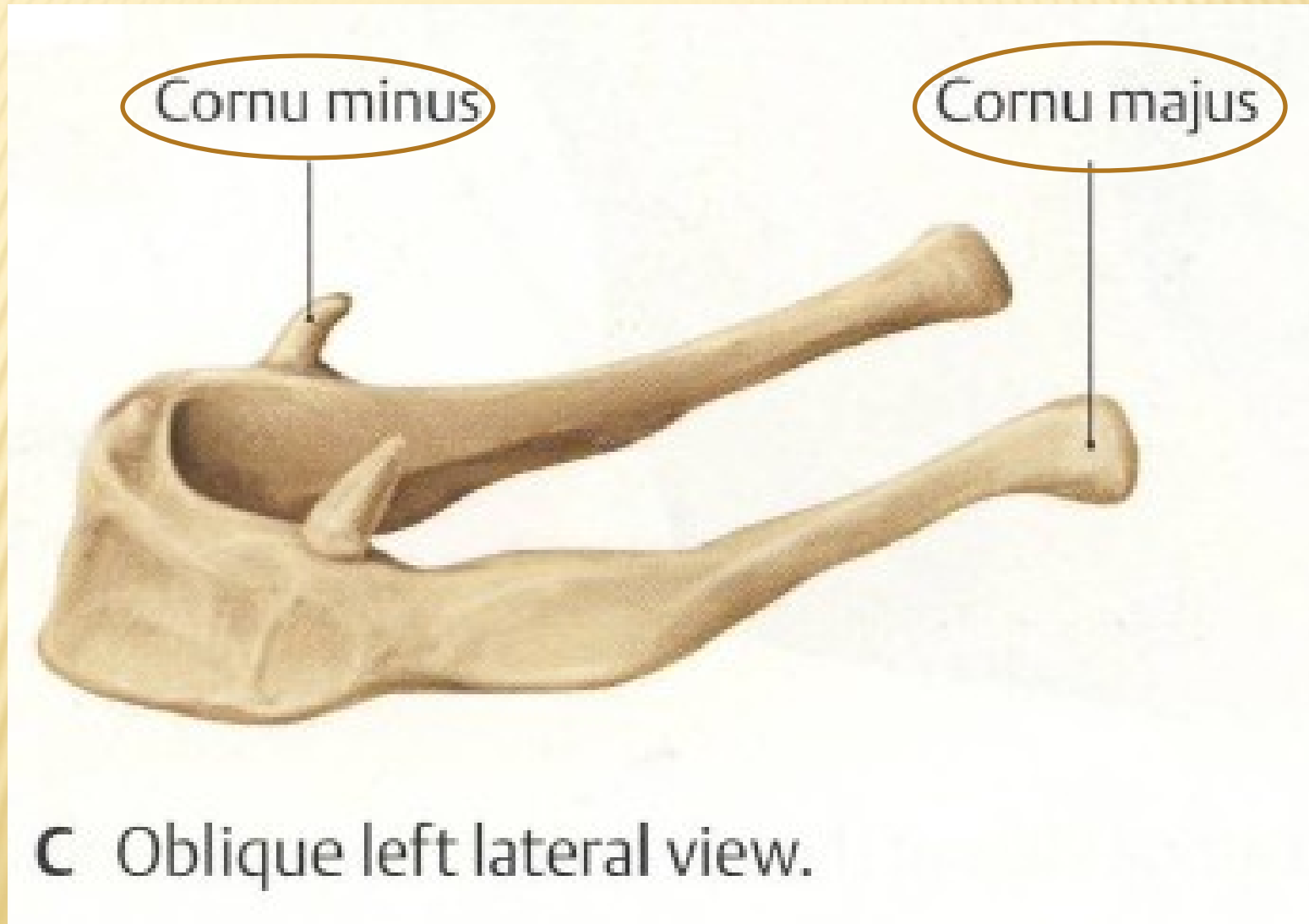


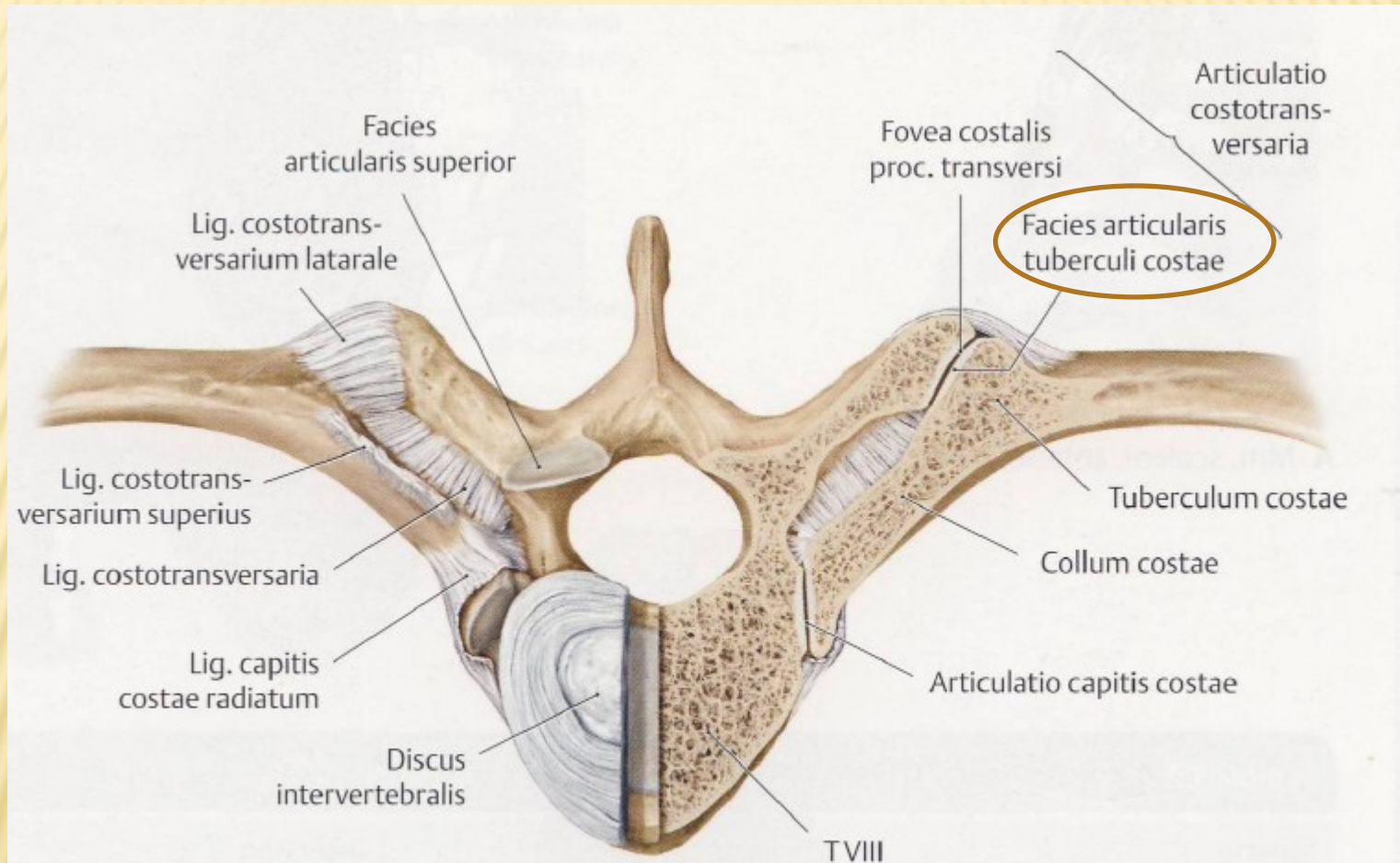
CORNU COCCYGEUM



CORNUA MAJORA ET MINORA OSSIS HYOIDEI

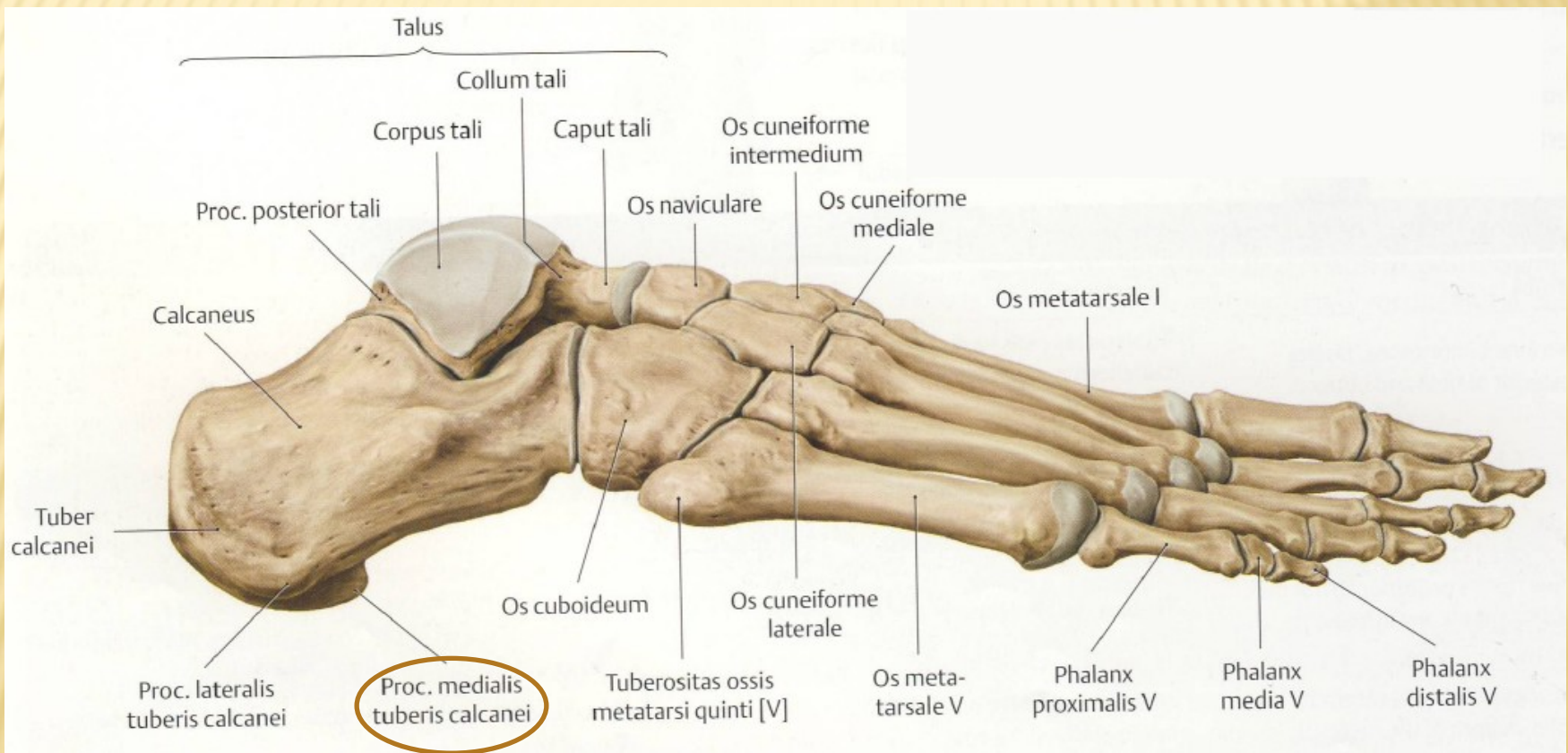


FACIES ARTICULARIS TUBERCULI COSTAE



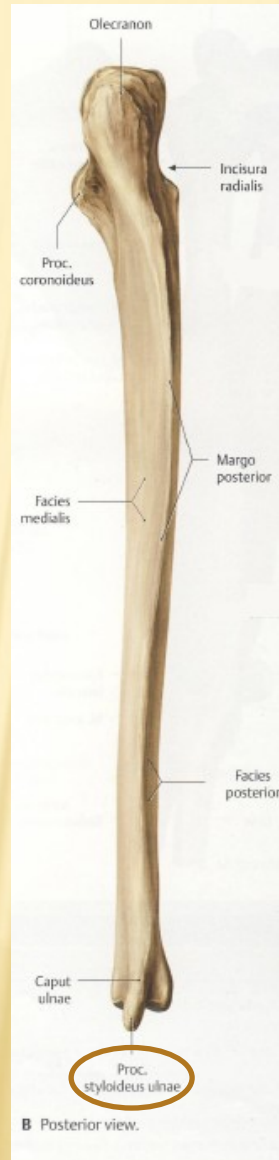
A *Articulatio costotransversaria*. Superior view with joints of the left rib transversely sectioned.

PROCESSUS MEDIALIS TUBERIS CALCANEI

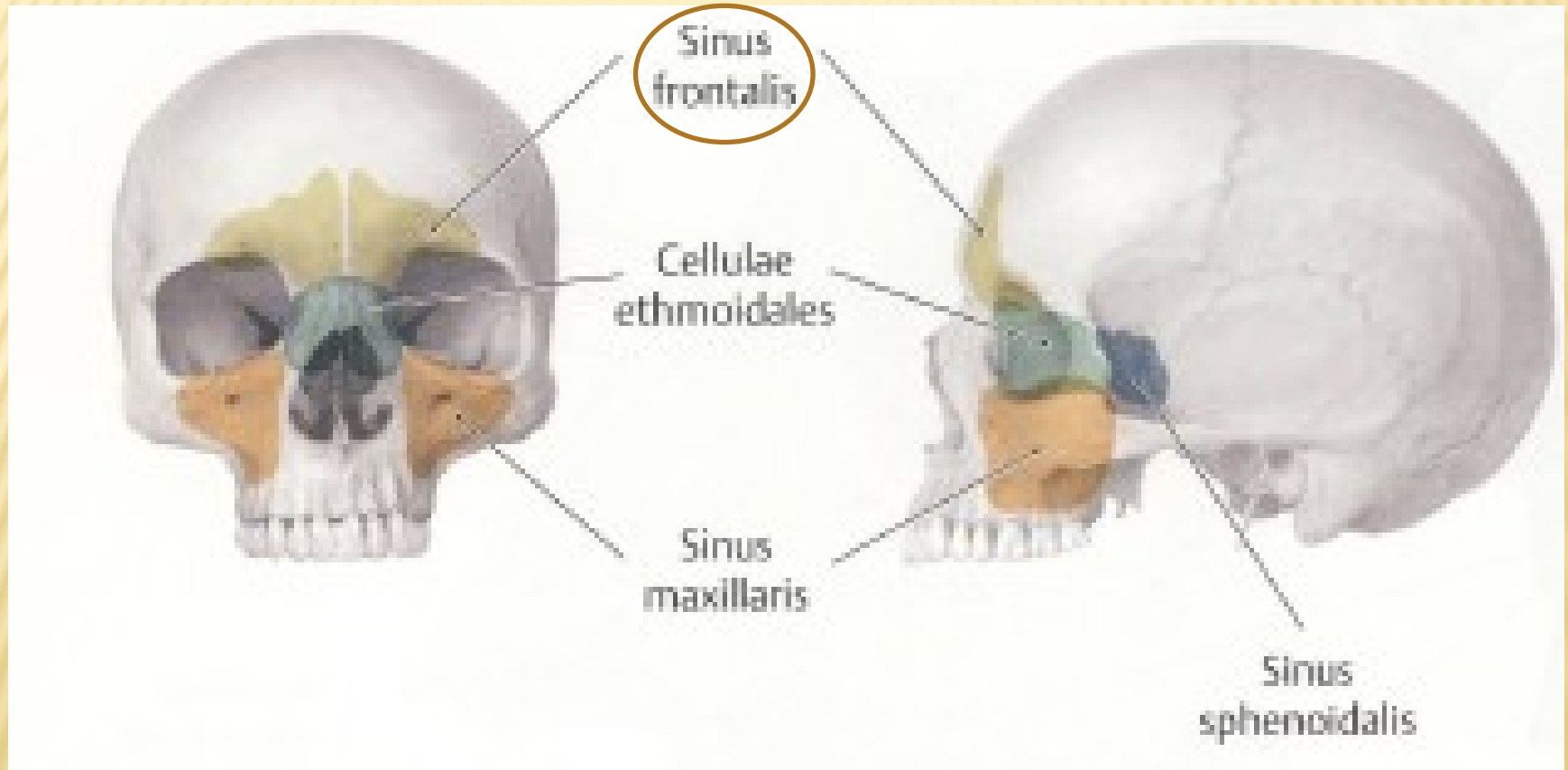


B Lateral view.

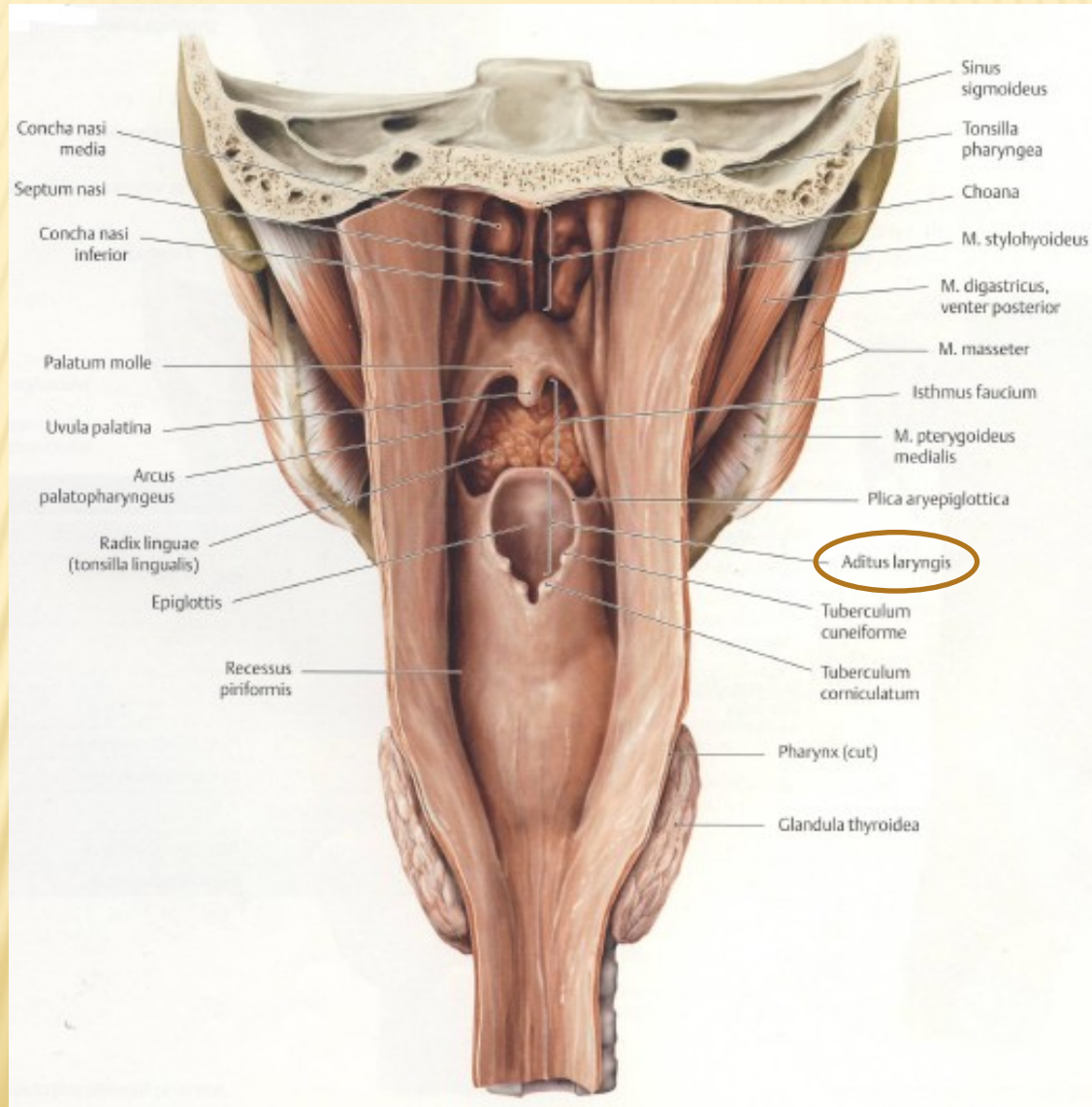
PROCESSUS STYLOIDEUS ULNAE



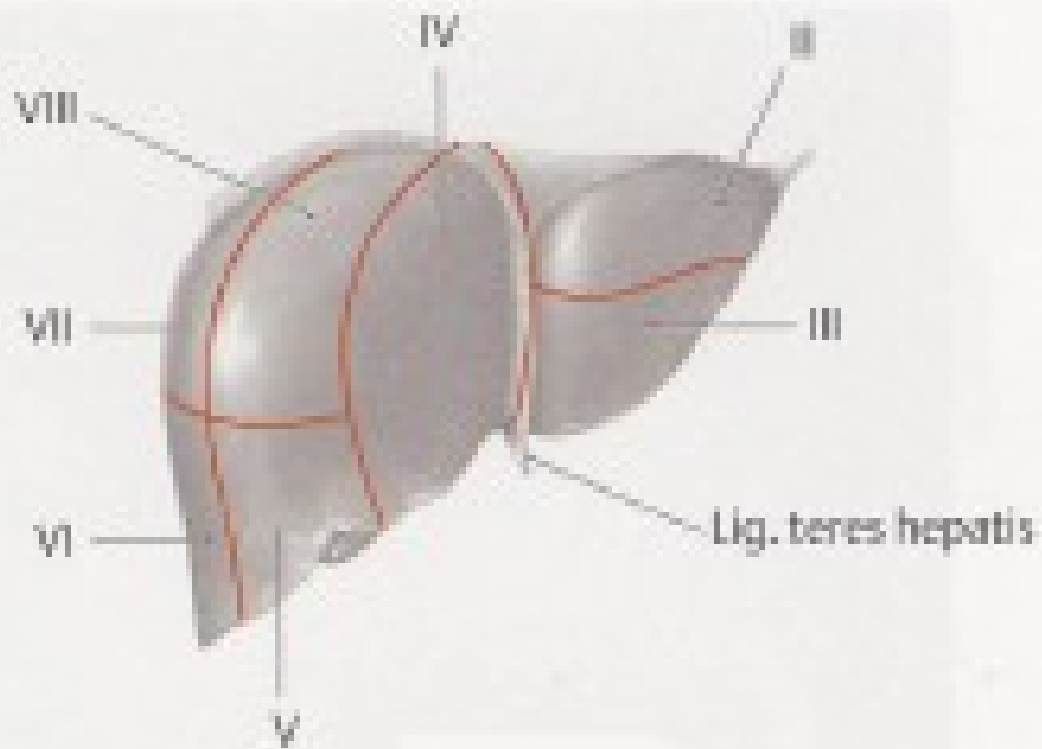
SINUS FRONTALIS



ADITUS LARYNGIS

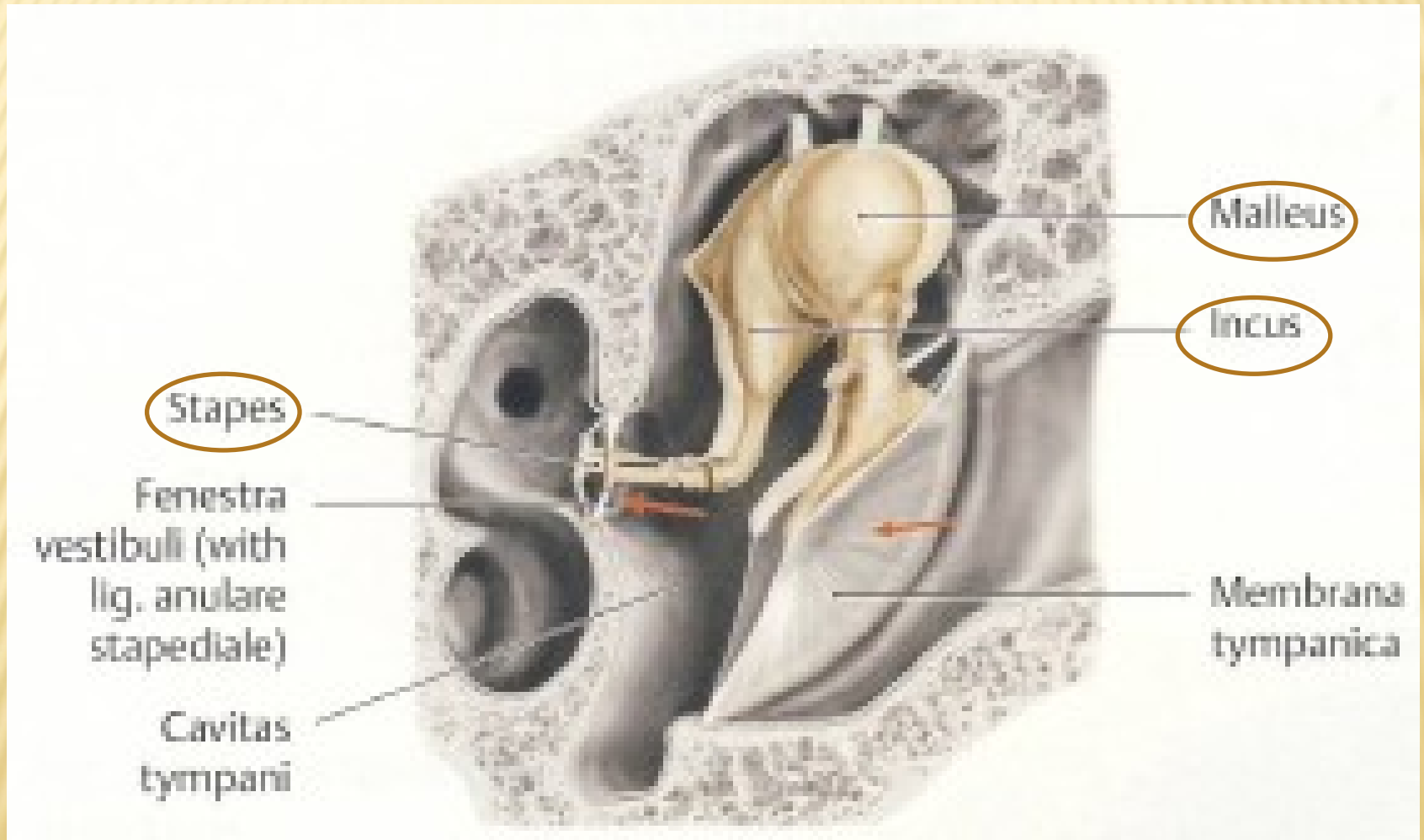


FACIES DIAPHRAGMATICA HEPATIS

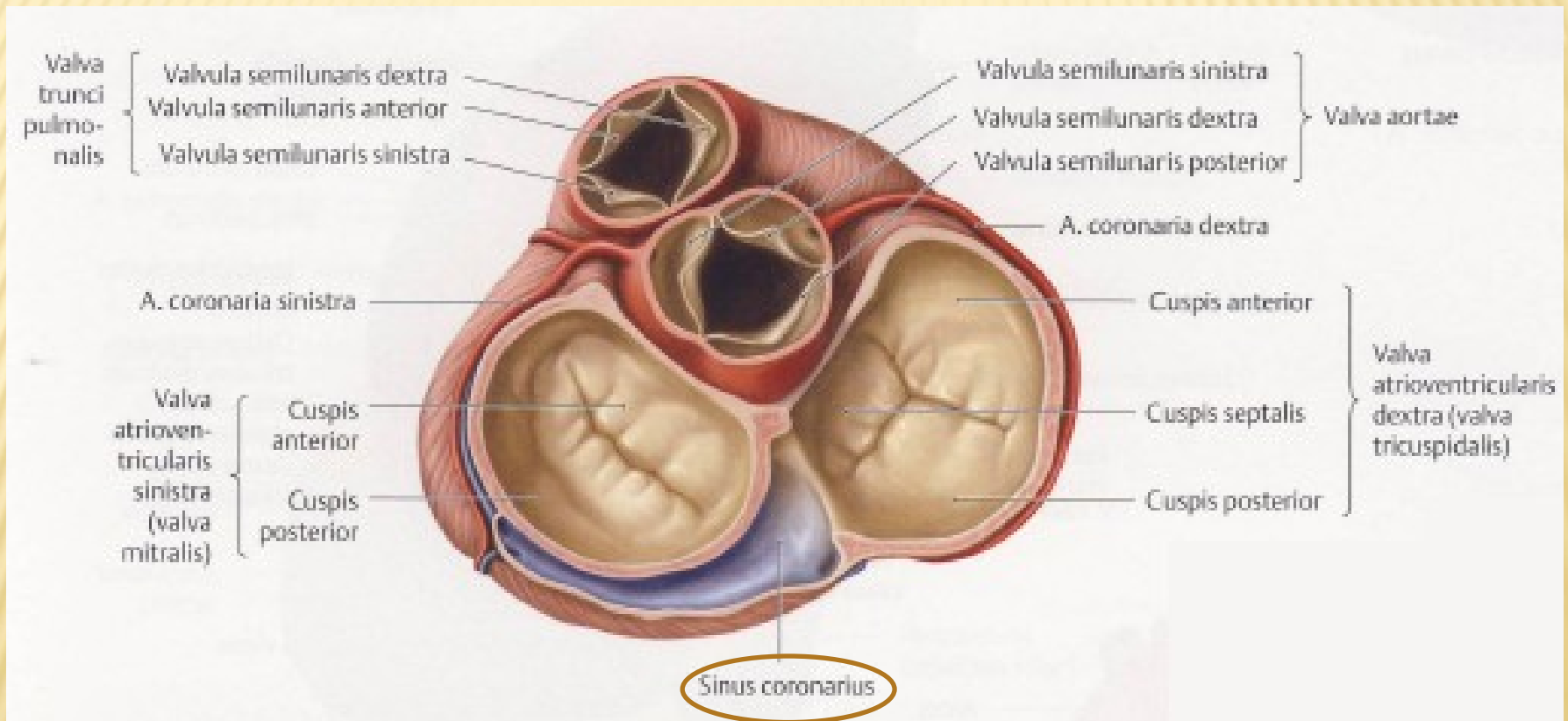


A Diaphragmatic surface, anterior view.

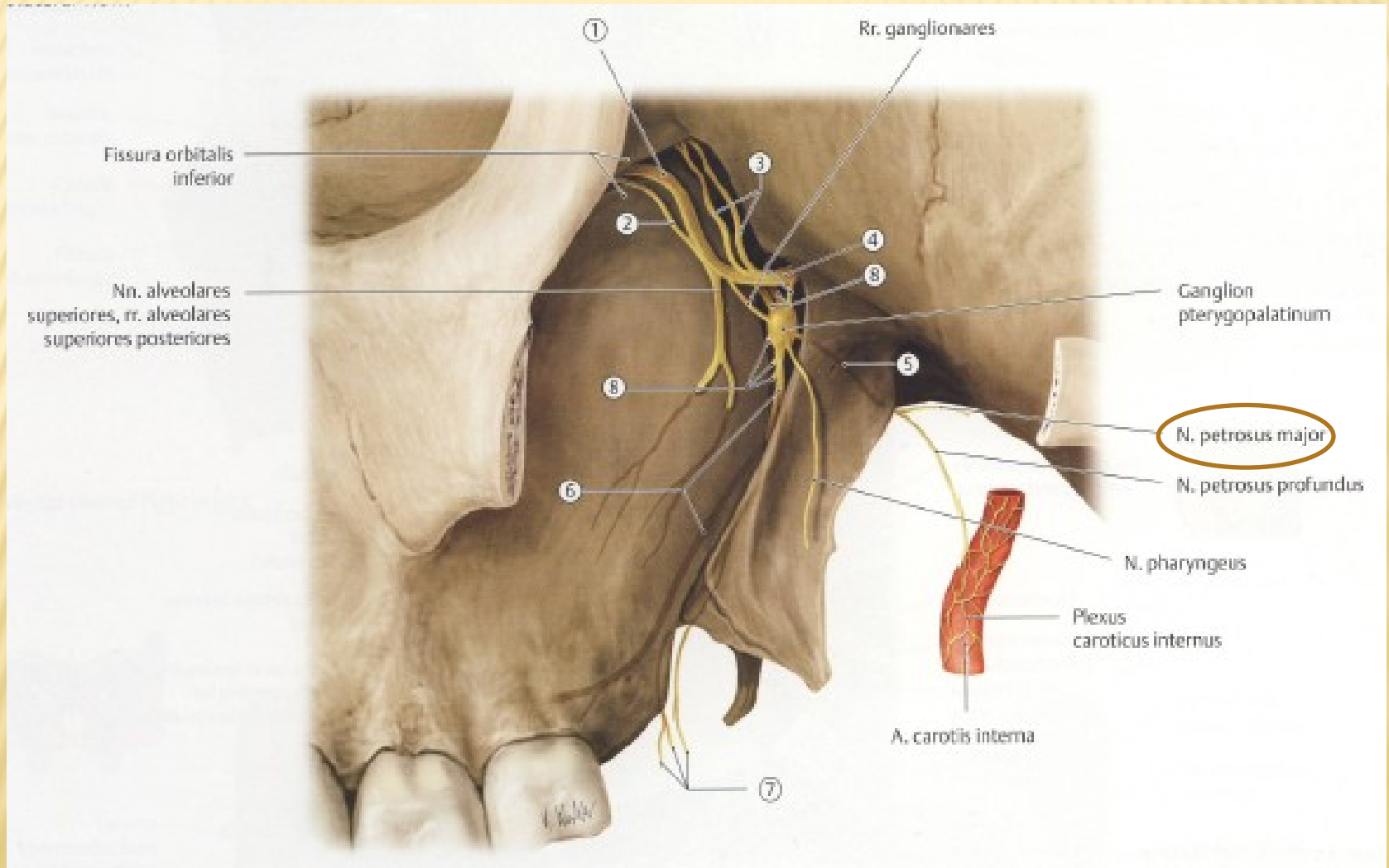
OSSICULA AUDITUS



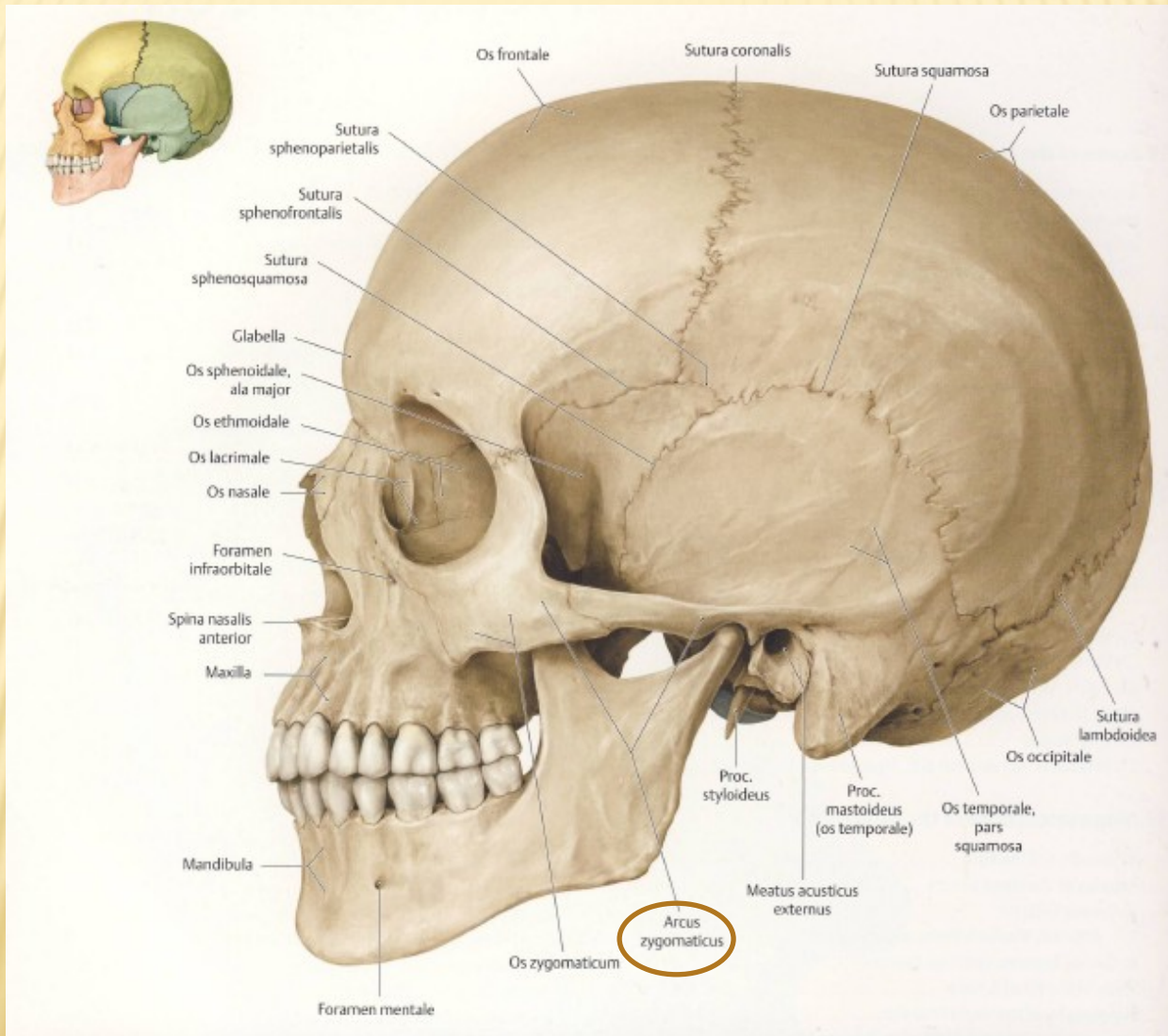
SINUS CORONARIUS



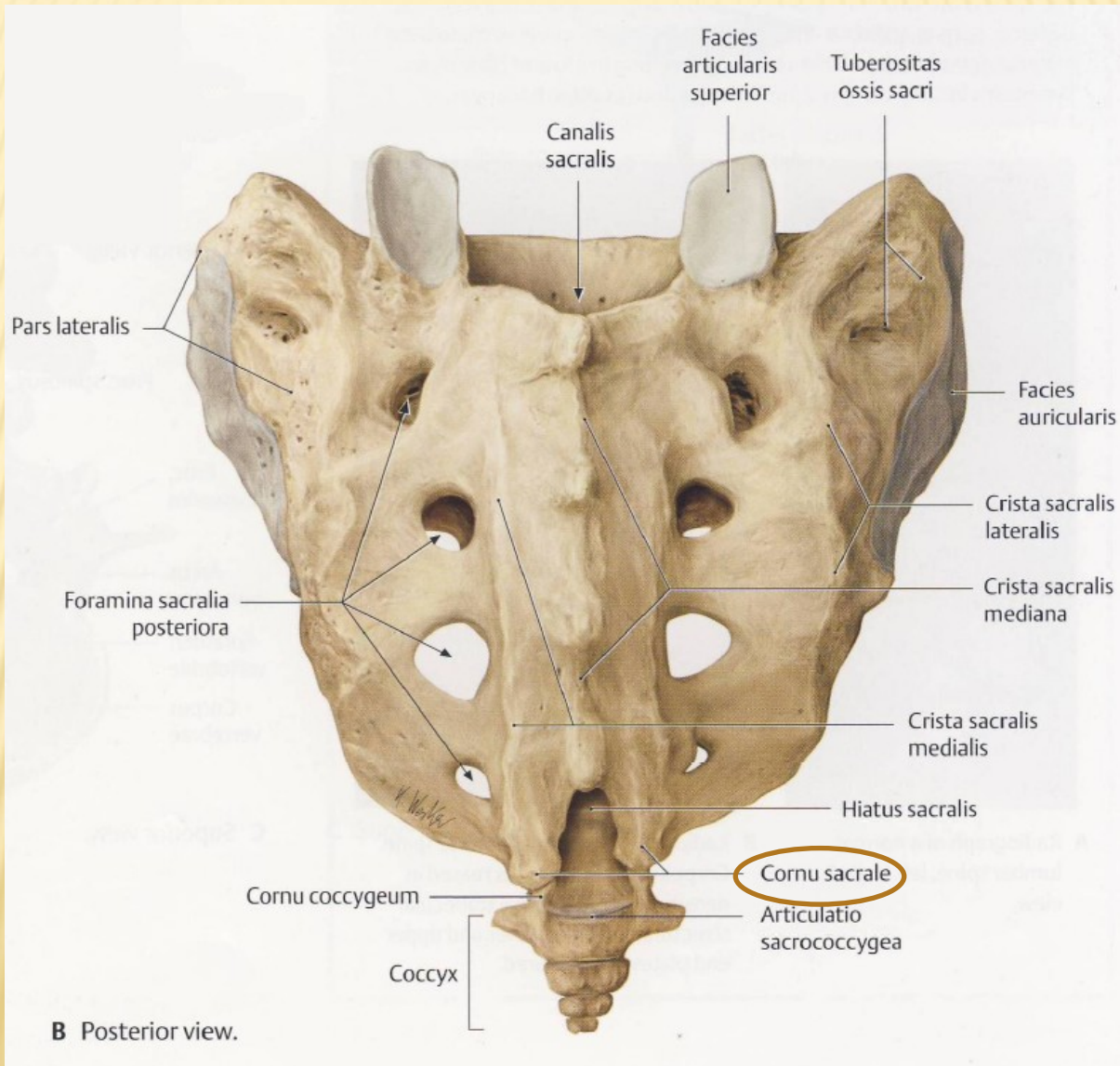
NERVUS PETROSUS MAJOR



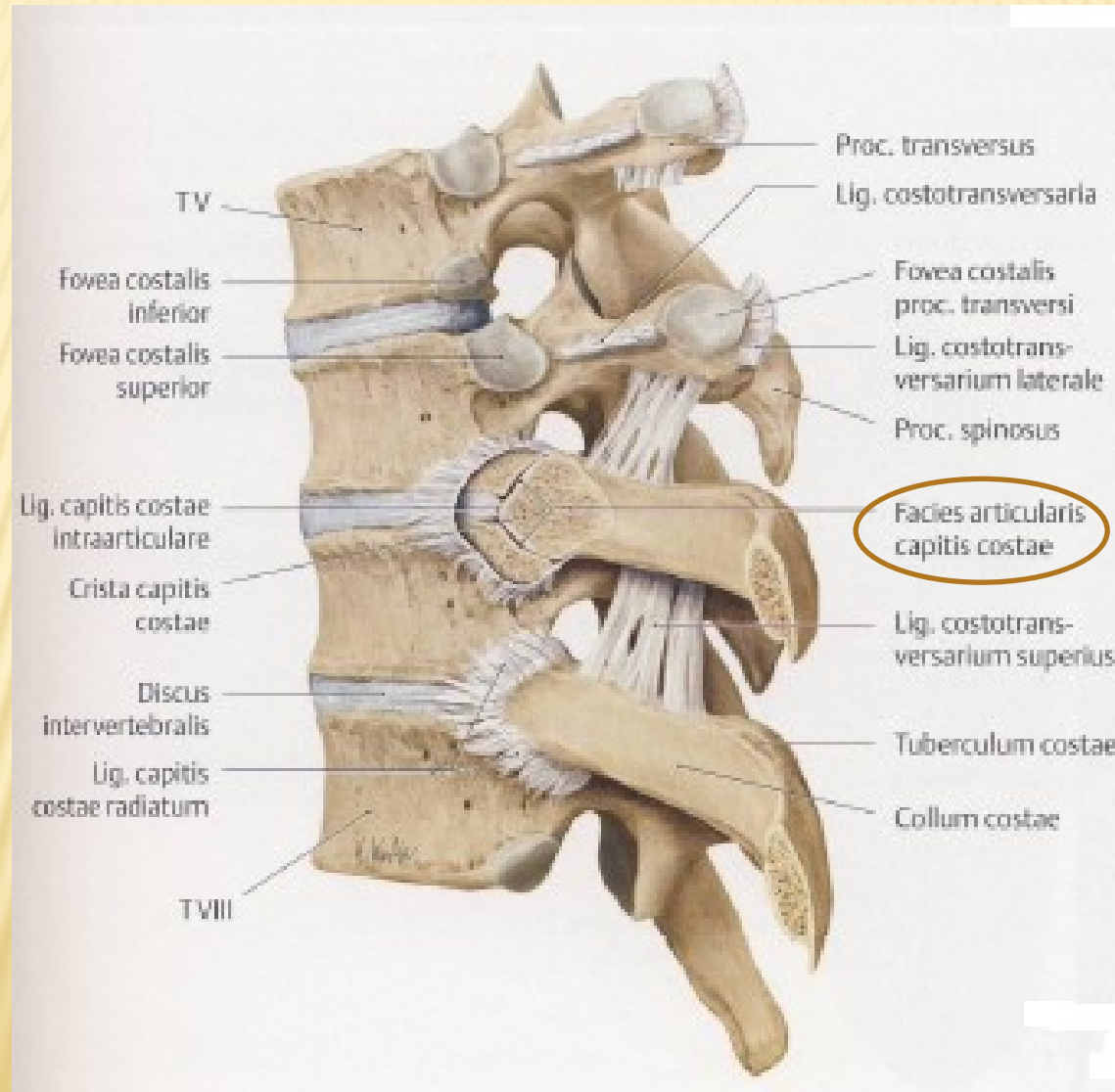
ARCUS ZYGOMATICUS



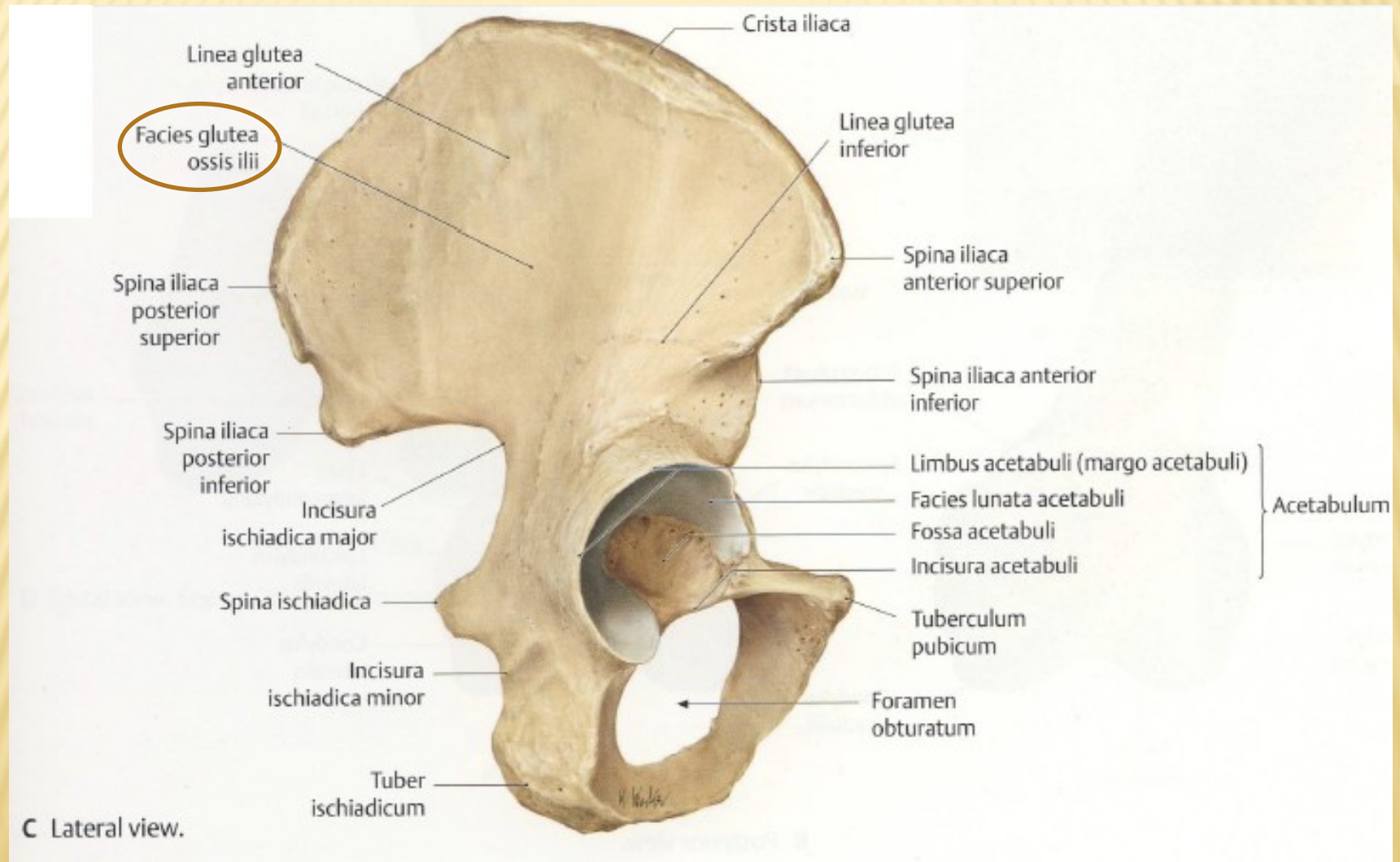
CORNUA SACRALIA



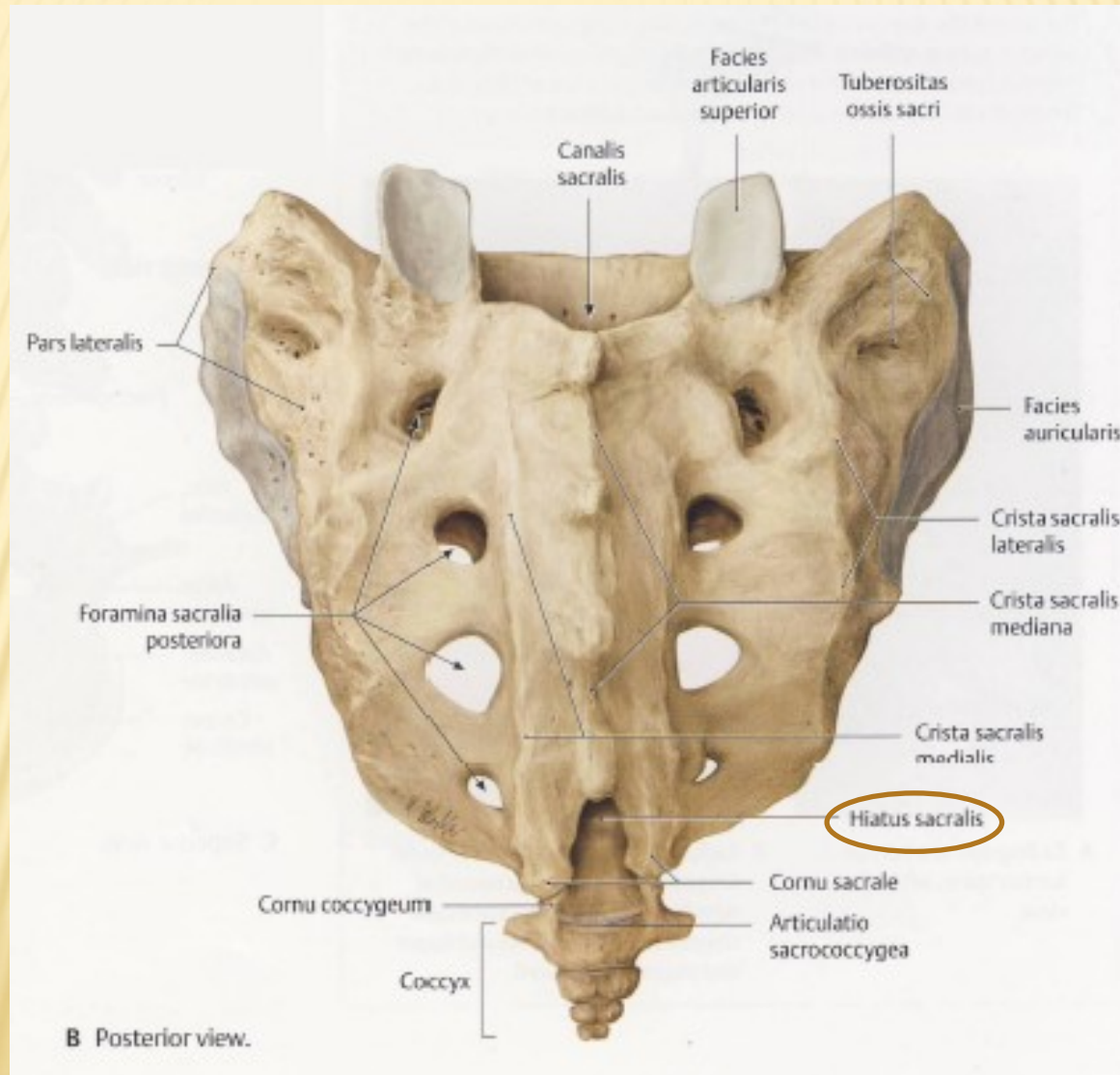
FACIES ARTICULARIS CAPITIS COSTAE



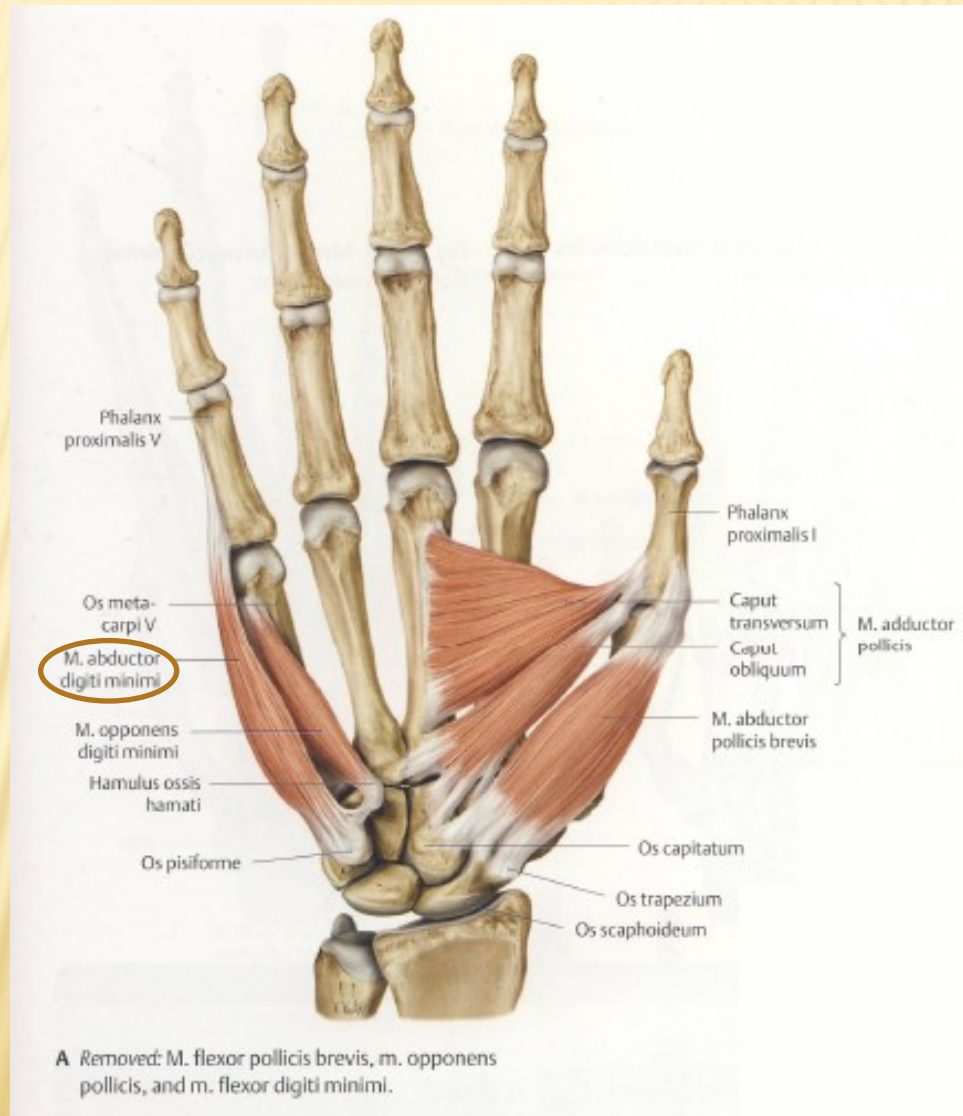
FACIES GLUTEA OSSIS ILII



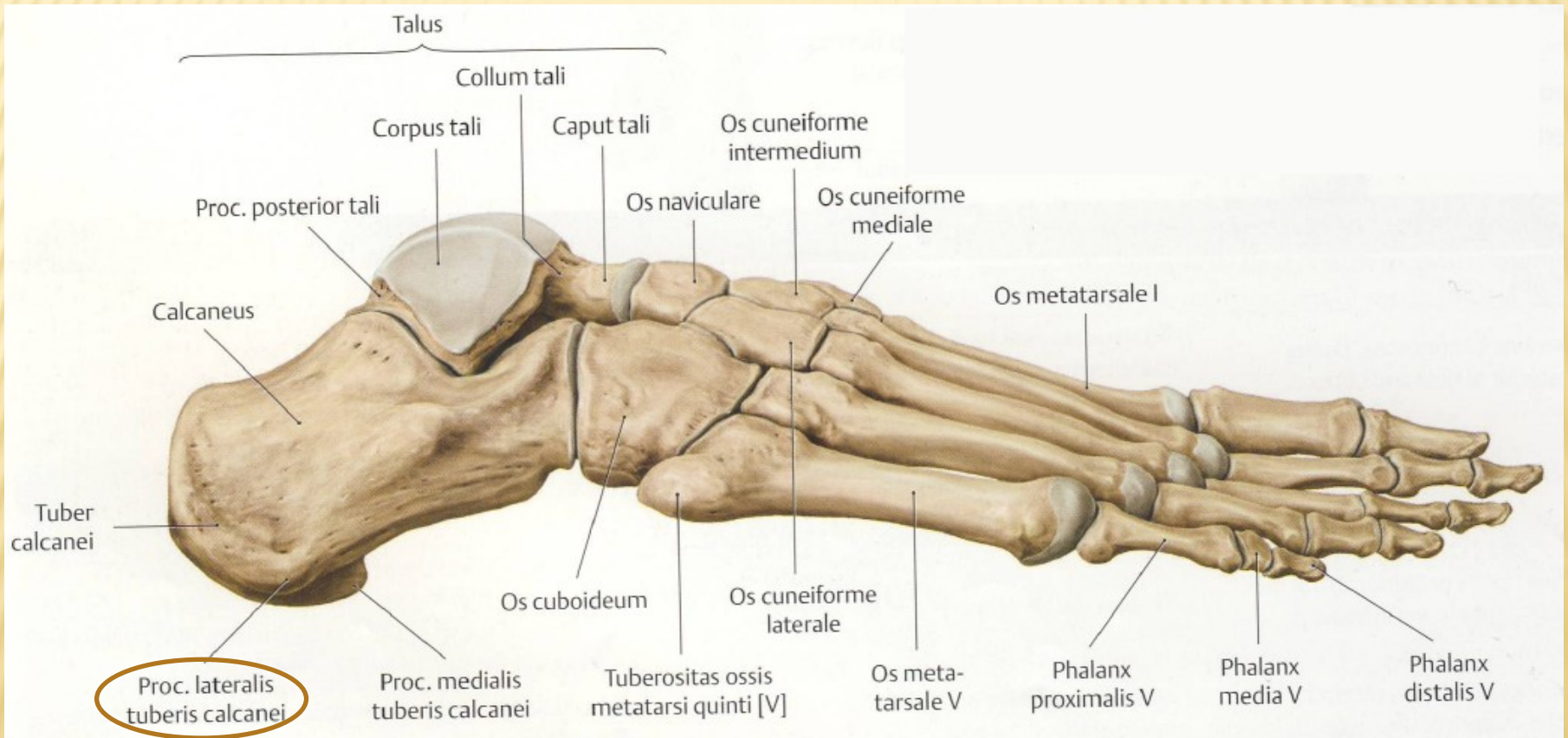
HIATUS SACRALIS



MUSCULUS ABDUCTOR DIGITI MINIMI MANUS

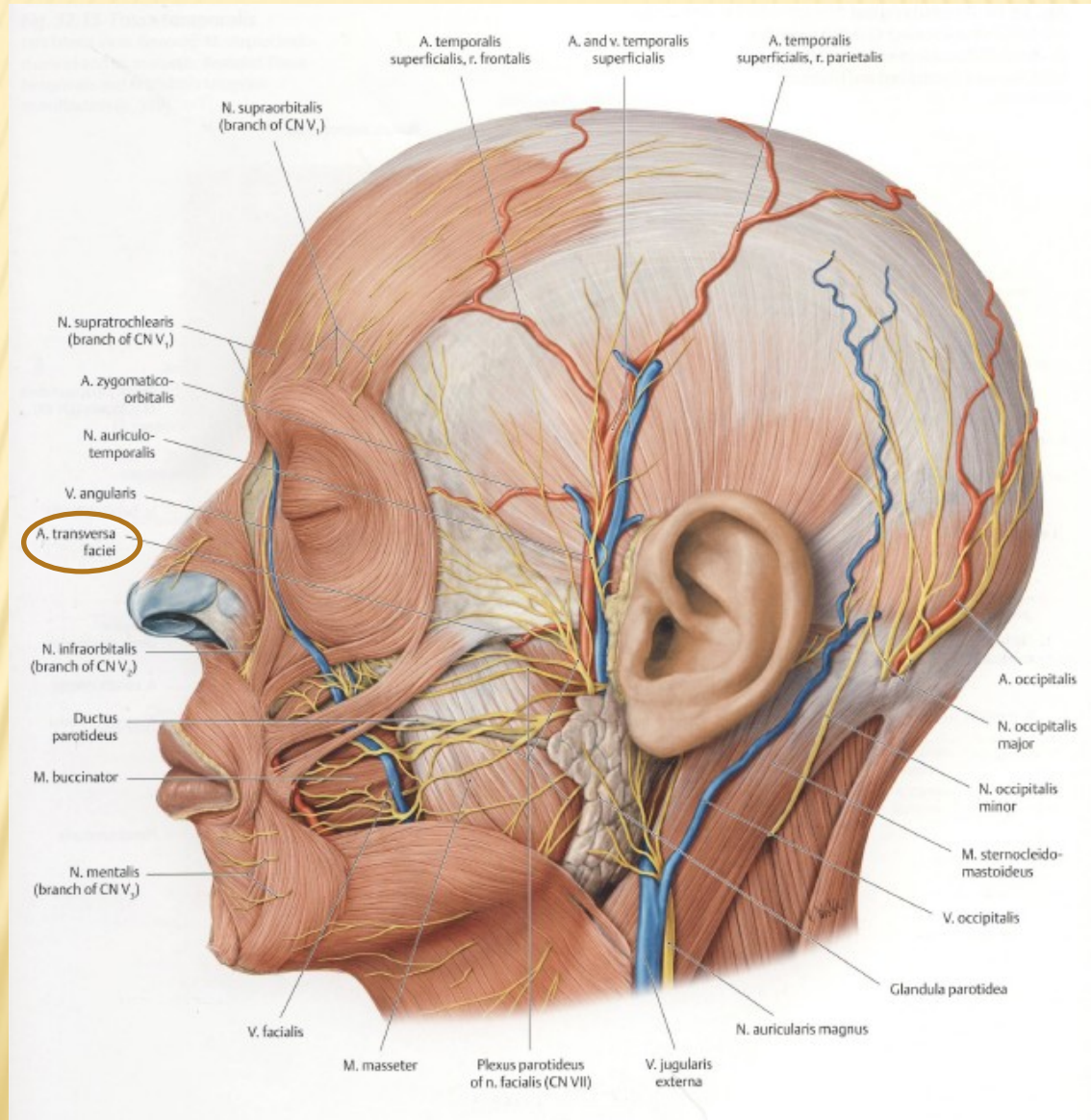


PROCESSUS LATERALIS TUBERIS CALCANEI

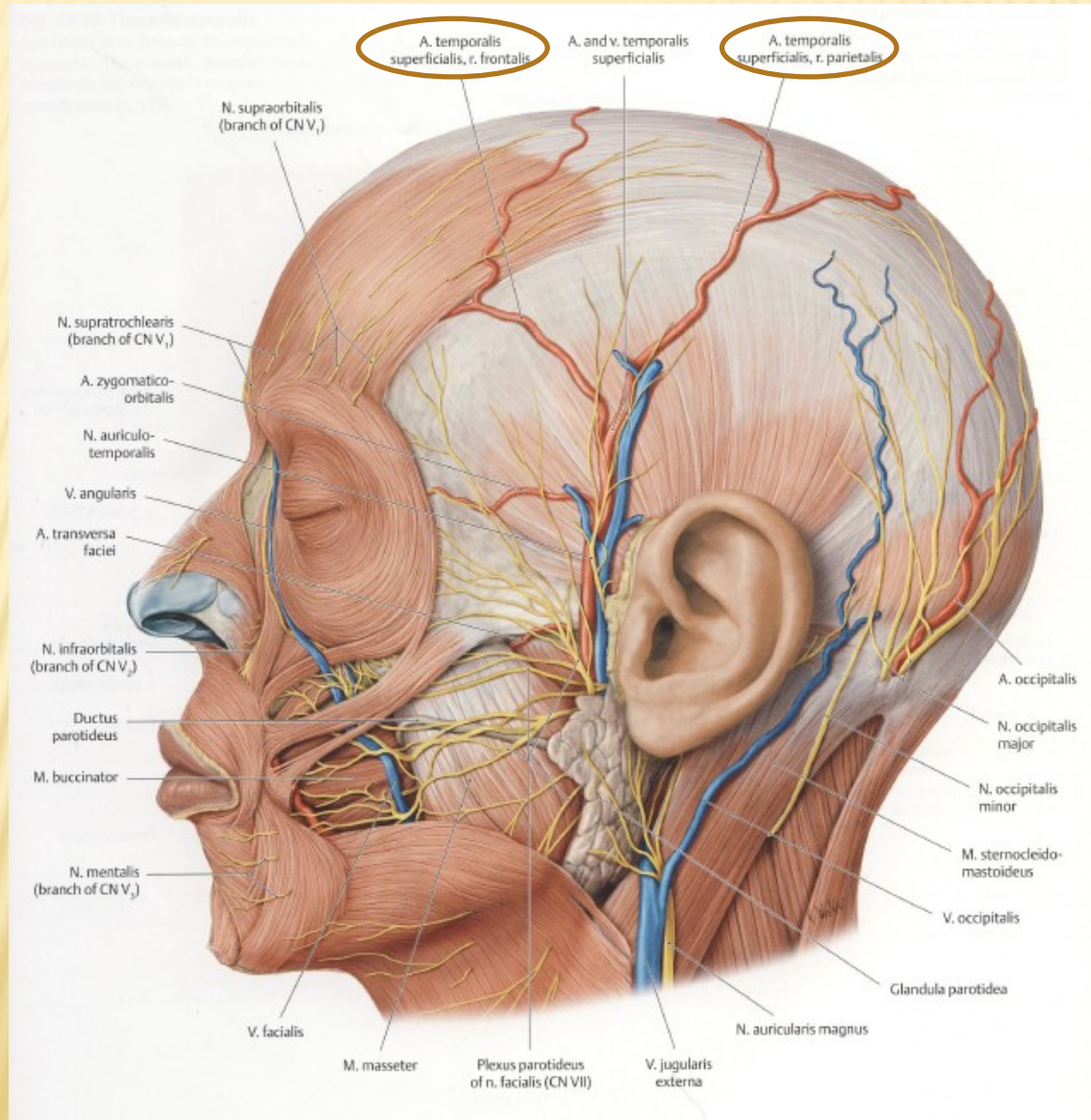


B Lateral view.

ARTERIA TRANSVERSA FACIEI



ARTERIA TEMPORALIS SUPERFICIALIS



SINUS SPHENOIDALIS

