


Institute of Microbiology shows:



# TRACING THE CRIMINAL

Part two: Streptococcus

# Most important streptococci

Story	On BA	Name of the criminal
4.	viri- dation (alpha)	<i>Streptococcus pneumoniae</i>
5.		Group of „oral streptococci“
1.	(beta) hemo- lysis*	<i>Streptococcus pyogenes</i>
2.		<i>Streptococcus agalactiae</i>
3.		Group of „non-A-non-B“ streptococci
—	none	Ahemolytical streptococci

*\*in S. agalactiae partial haemolysis only*

# Survey of topics

Clinical characteristics: Haemolytical streptococci

Clinical characteristics: Viridating streptococci

Therapy of streptococcal diseases

Diagnostics of streptococci

Differential diagnostics of streptococci

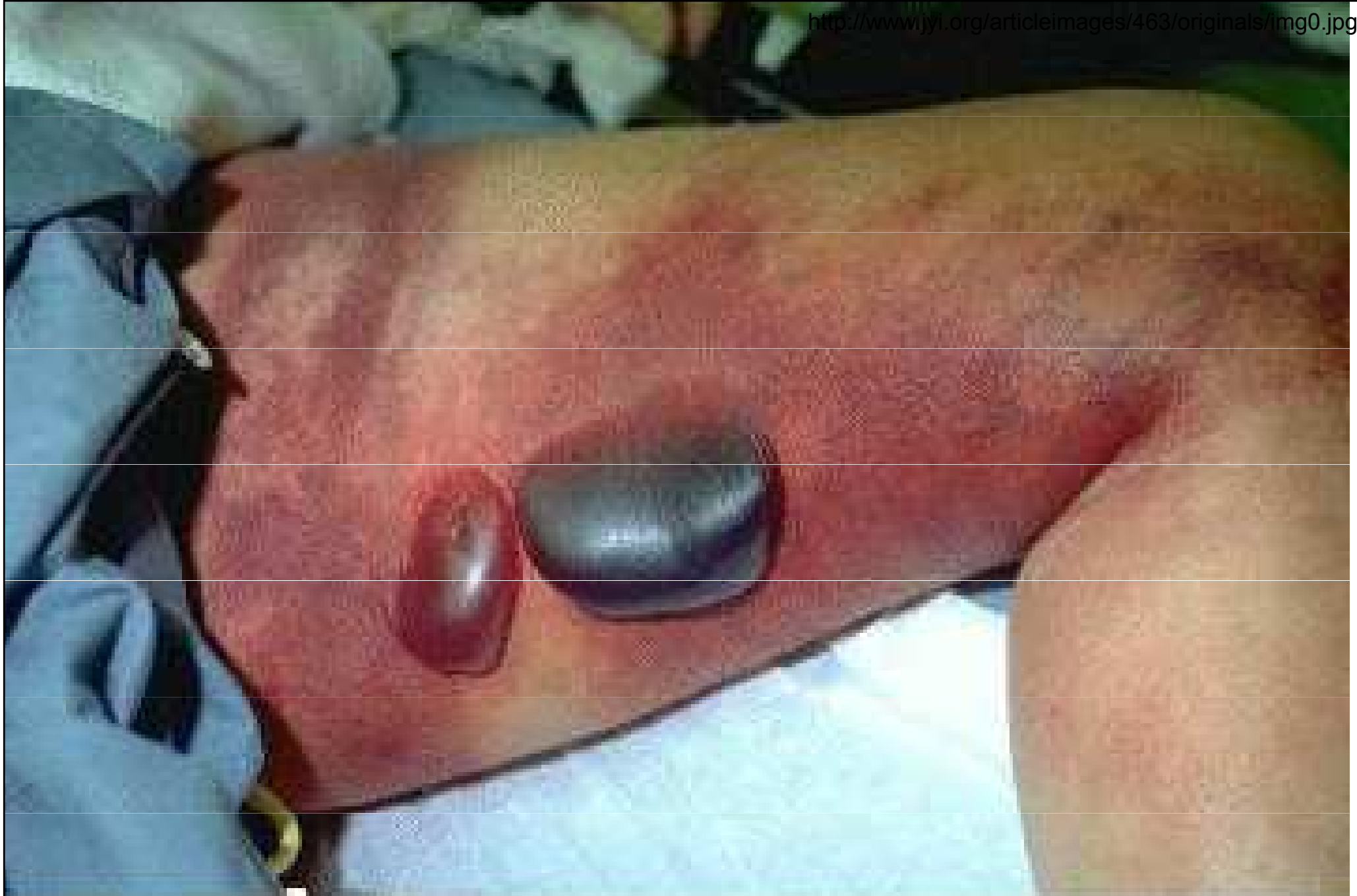Late sequellae of streptococcal diseases

Clinical  
characteristics:  
 $(\beta-)$  haemolytical  
streptococci  
(with partial or total haemolysis)

# Story One



- Mr Hobby likes to work with wood. He worked at his workshop, when a large wood has fallen on his foot. A large lacerated wound emerged, and even dirty. Mr Hobby was taken to a hospital. The wound was sewed by a surgeon, but high fever and signs of sepsis were found. At reoperation, necrotizing inflammation of fascia with necrosis was found. Unfortunately, the care did not help: the leg had to be taken away.



**These large, dark, boil-like blisters are a diagnostic symptom of necrotizing fasciitis (also known as flesh-eating disease).**


(Source: EMBBS, 1996 <http://mdchoice.com/>)

# Who is guilty?

- It is *Streptococcus pyogenes*

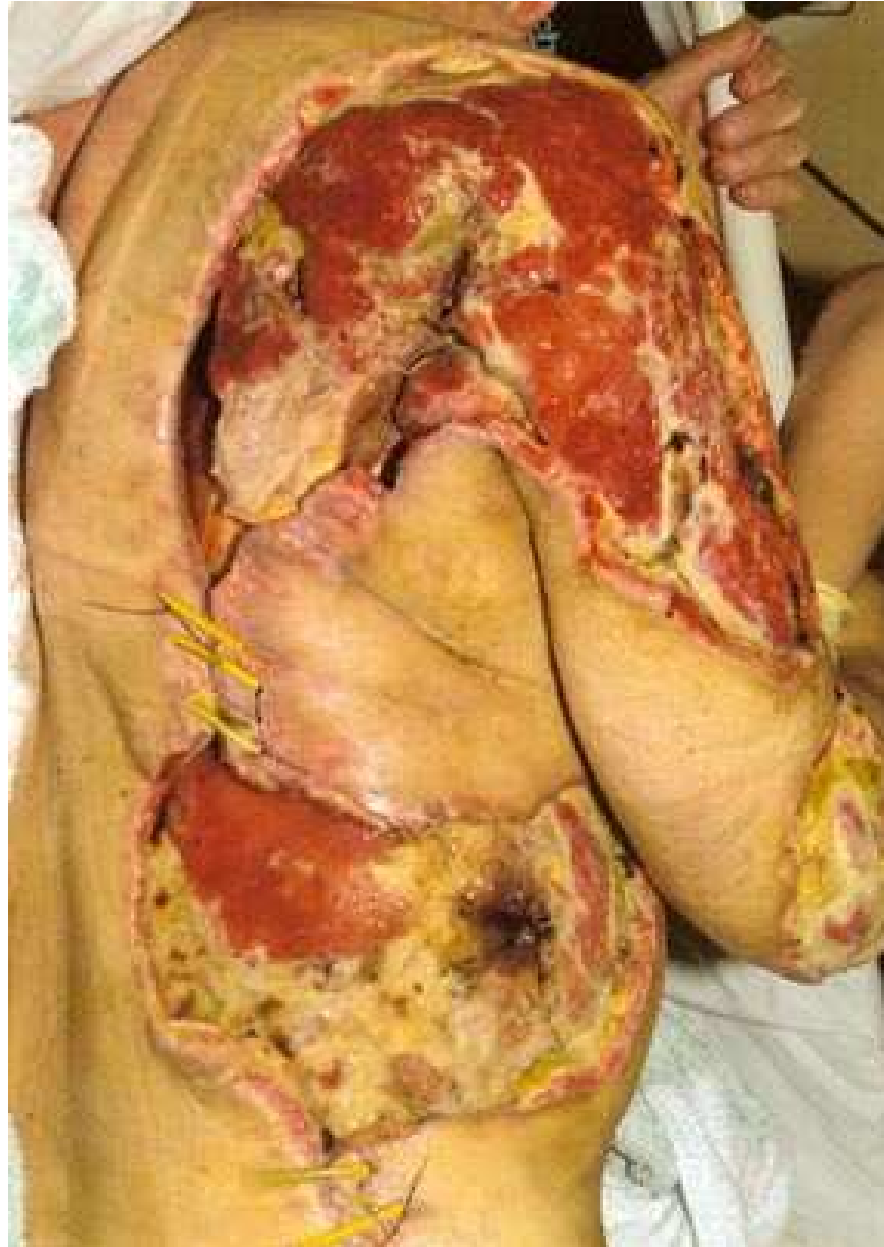*strepto* = in chains, *pyo-genes* = making pus

- *Streptococcus pyogenes* is known as causative agent of acute tonsillitis. Nevertheless, it causes pyogenic tissue inflammations, too. Unlike staphylococci, causing abscesses, here flegmonae are rather common.
- Besides tonsillitis, it causes also scarlatina, scarlatiniform tonsillitis and erysipelas. There are strains producing erythrogenous toxin (erythros = red)
- When the bacterium itself is infected by a bacteriophage, it is even more virulent and becomes a „meat eating bug“ – our case.



# Necrotising fasciitis („flesh eating bacteria“)

In fact, it is extremely rare, only in streptococcal strains infected by a phagus. Other infections are much more common.





# Typical youngsters disease: tonsillitis

## Bacterial

**Come to the  
Health Center**

Swollen  
uvula

Whitish  
spots

Red swollen  
tonsils

Throat  
redness

Gray  
furry  
tongue

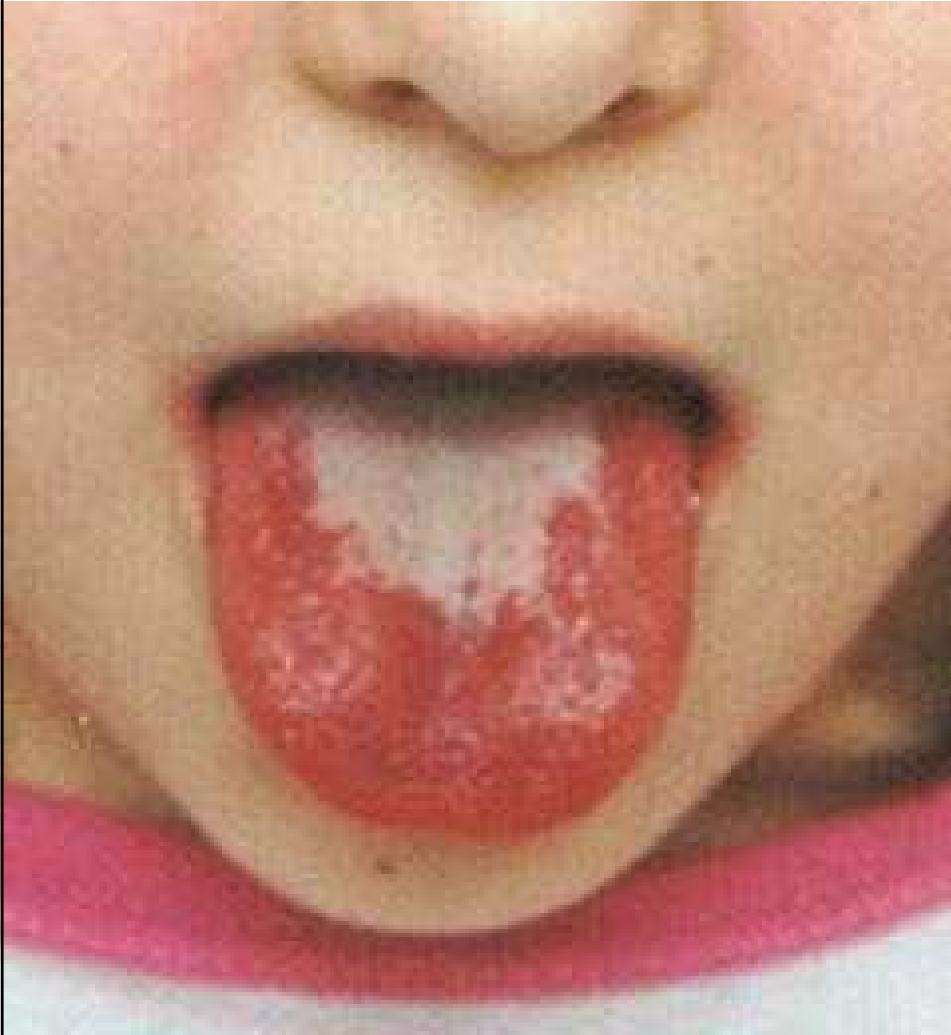## Nonbacterial/Viral

**Monitor at home,  
gargle with salt  
water**

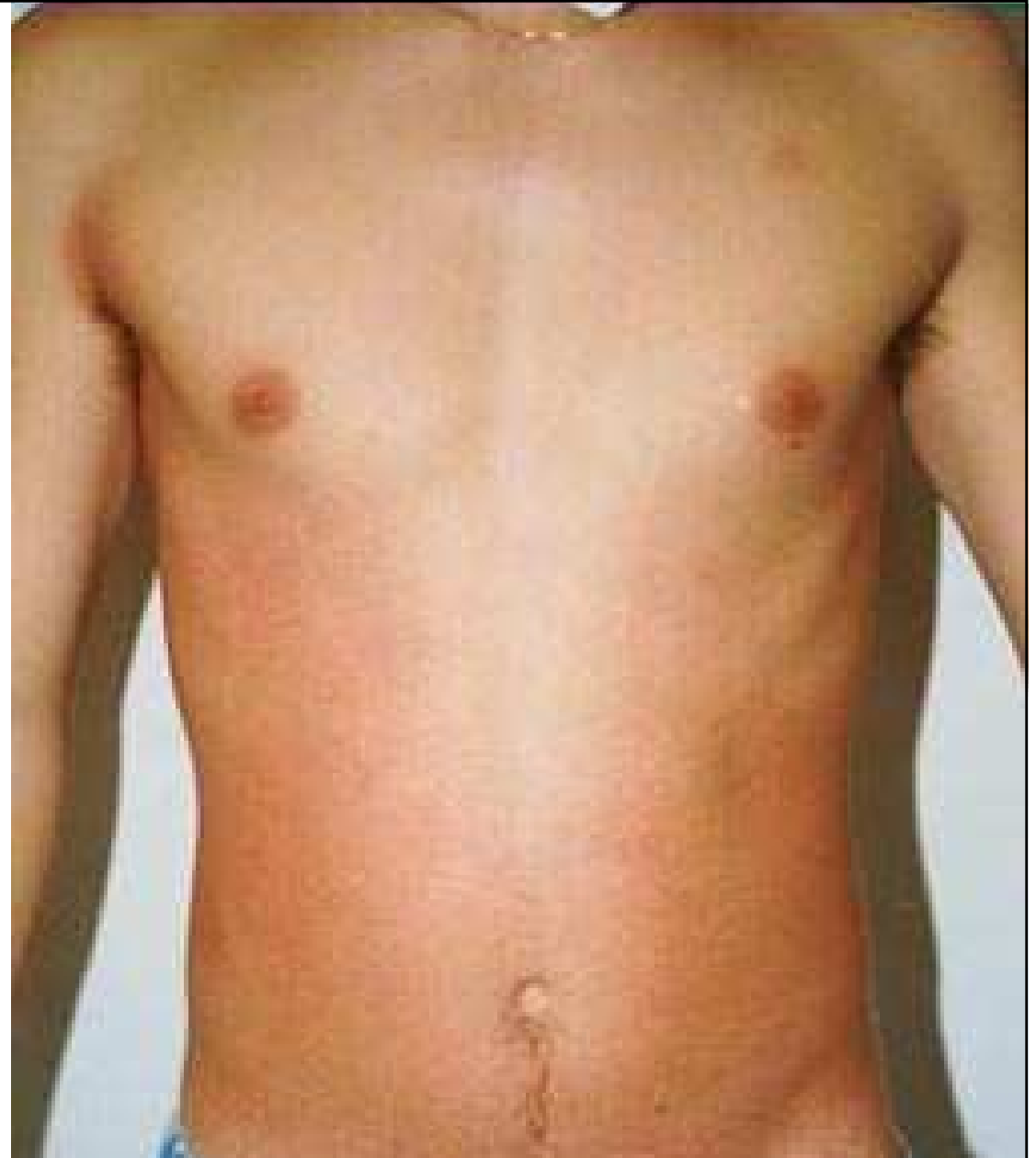
Red  
swollen  
tonsils

Throat  
redness

# Scarlet fever

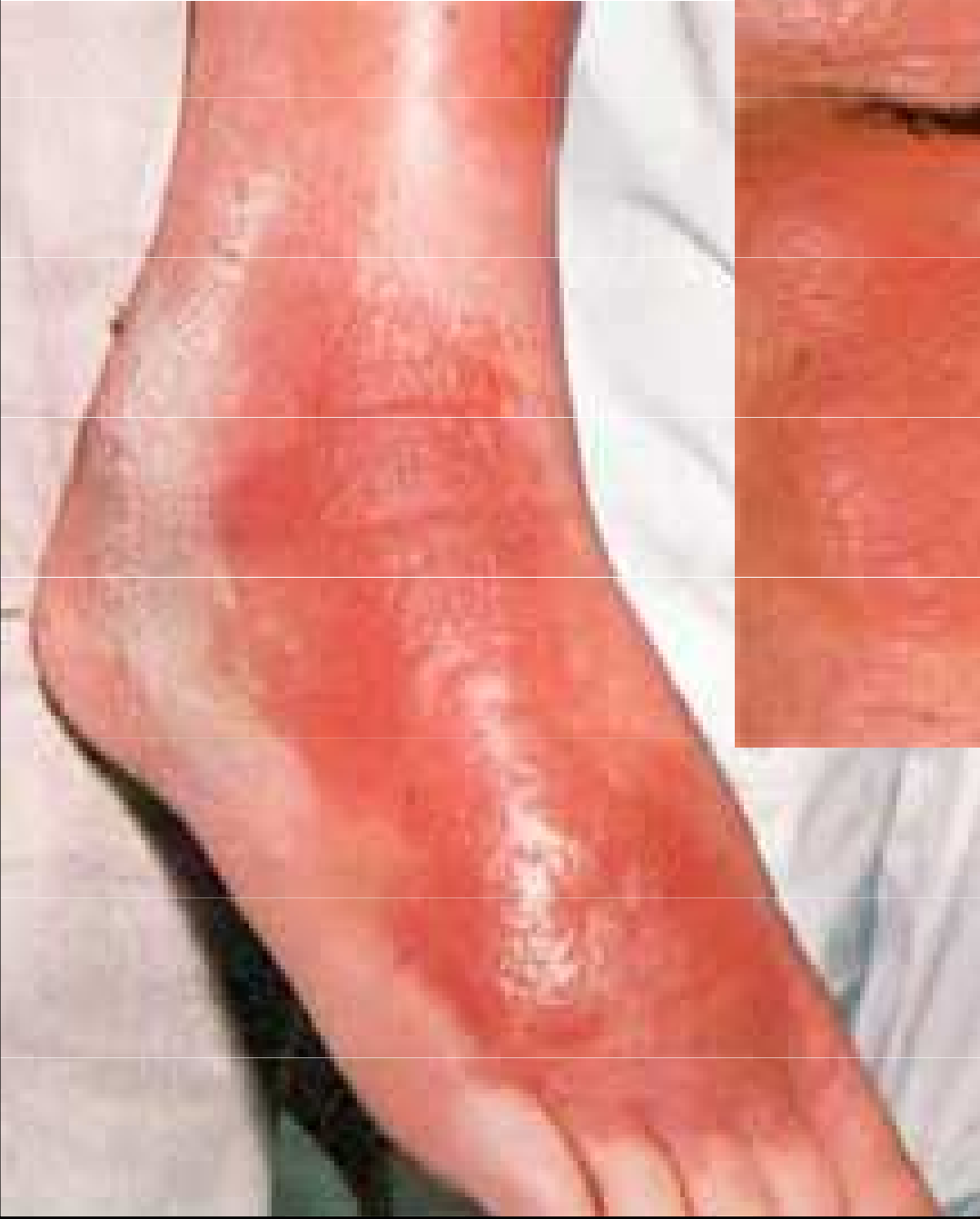
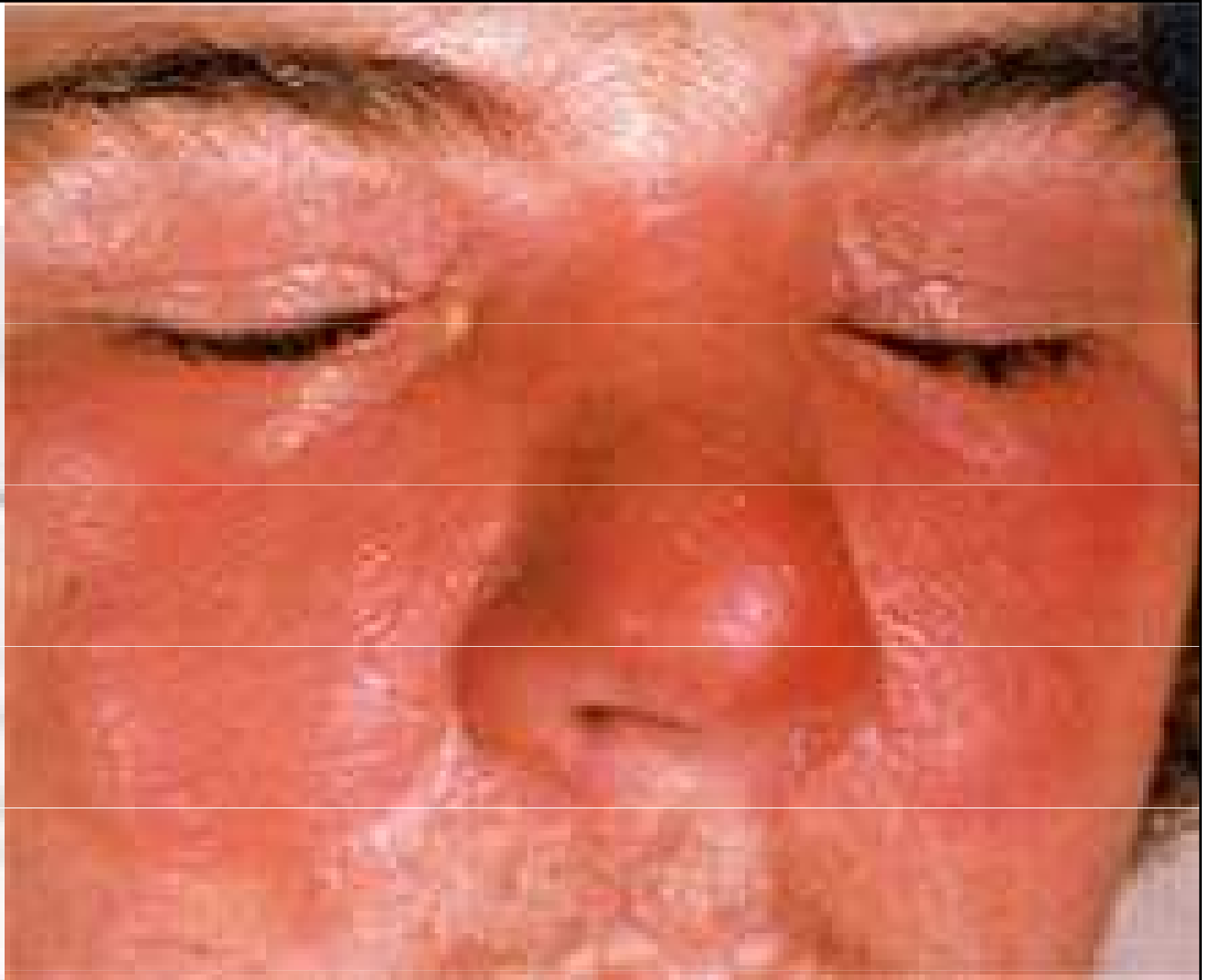
<http://www1.lf1.cuni.cz>



Scarlet fever = heavy tonsillitis + exanthema (on skin) + features on mucous membrane. Streptococcus must produce an erythrogenous toxin.

# Erysipelas

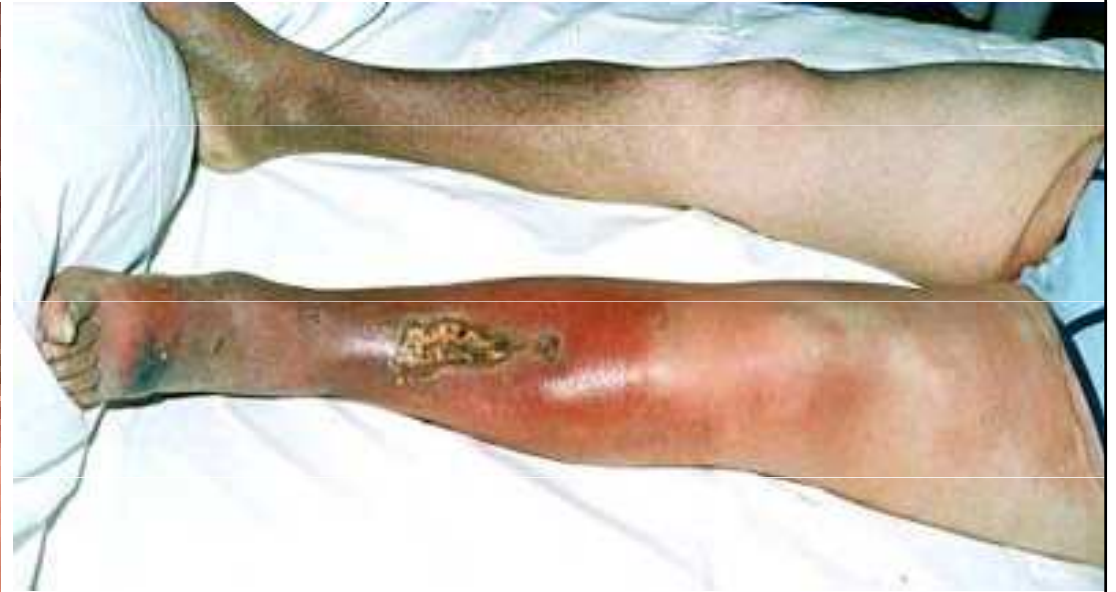
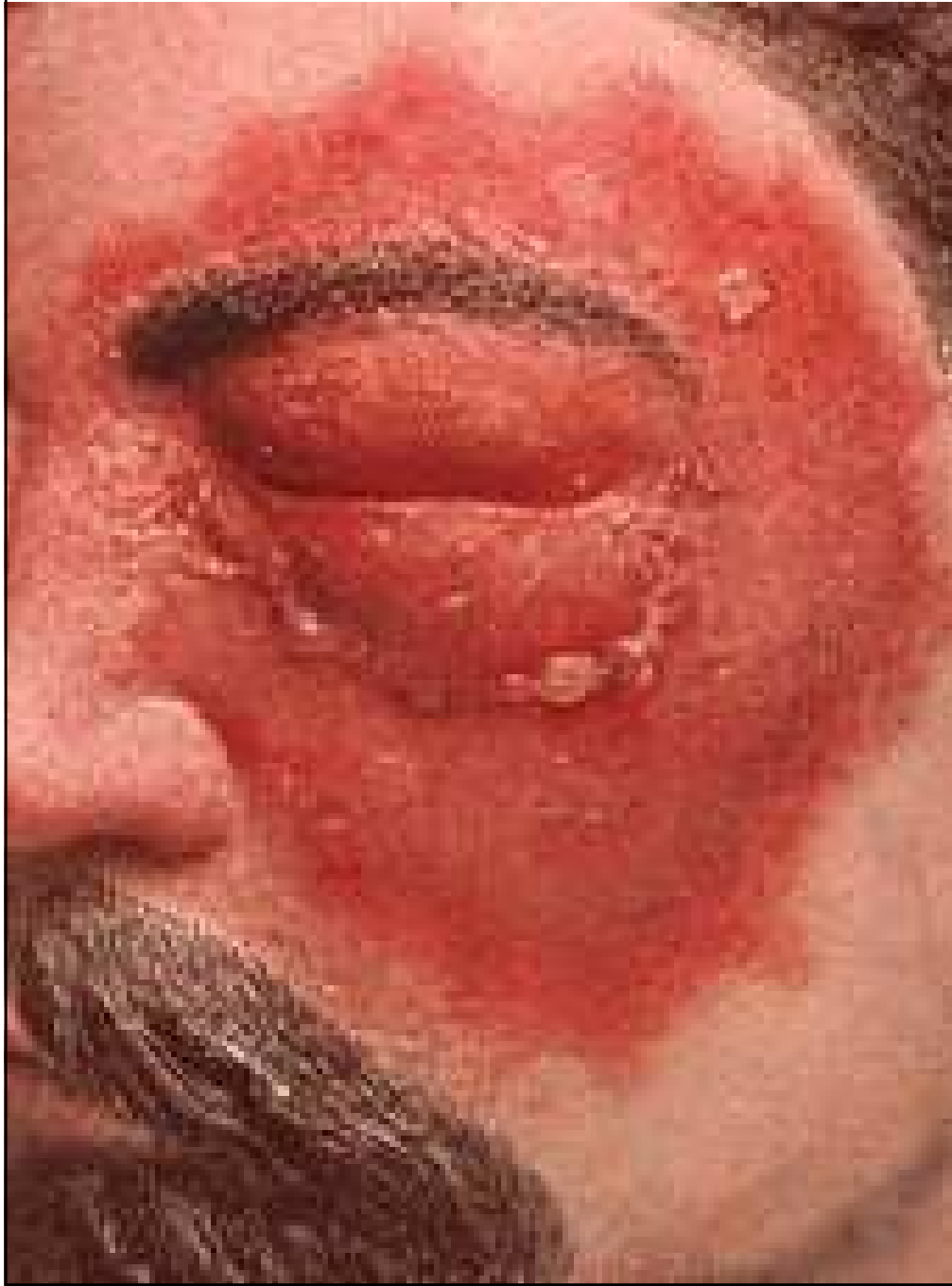
[www.infektionsnetz.at](http://www.infektionsnetz.at)

It is a superficial skin infection that characteristically extends into the cutaneous lymphatics

([Greek](#) *έρυσίπελας*—red skin; also known as "Ignis sacer", "holy fire", and "St. Anthony's fire"<sup>l</sup> in some countries – source: Wikipedia)

# Erysipelas with phlegmona



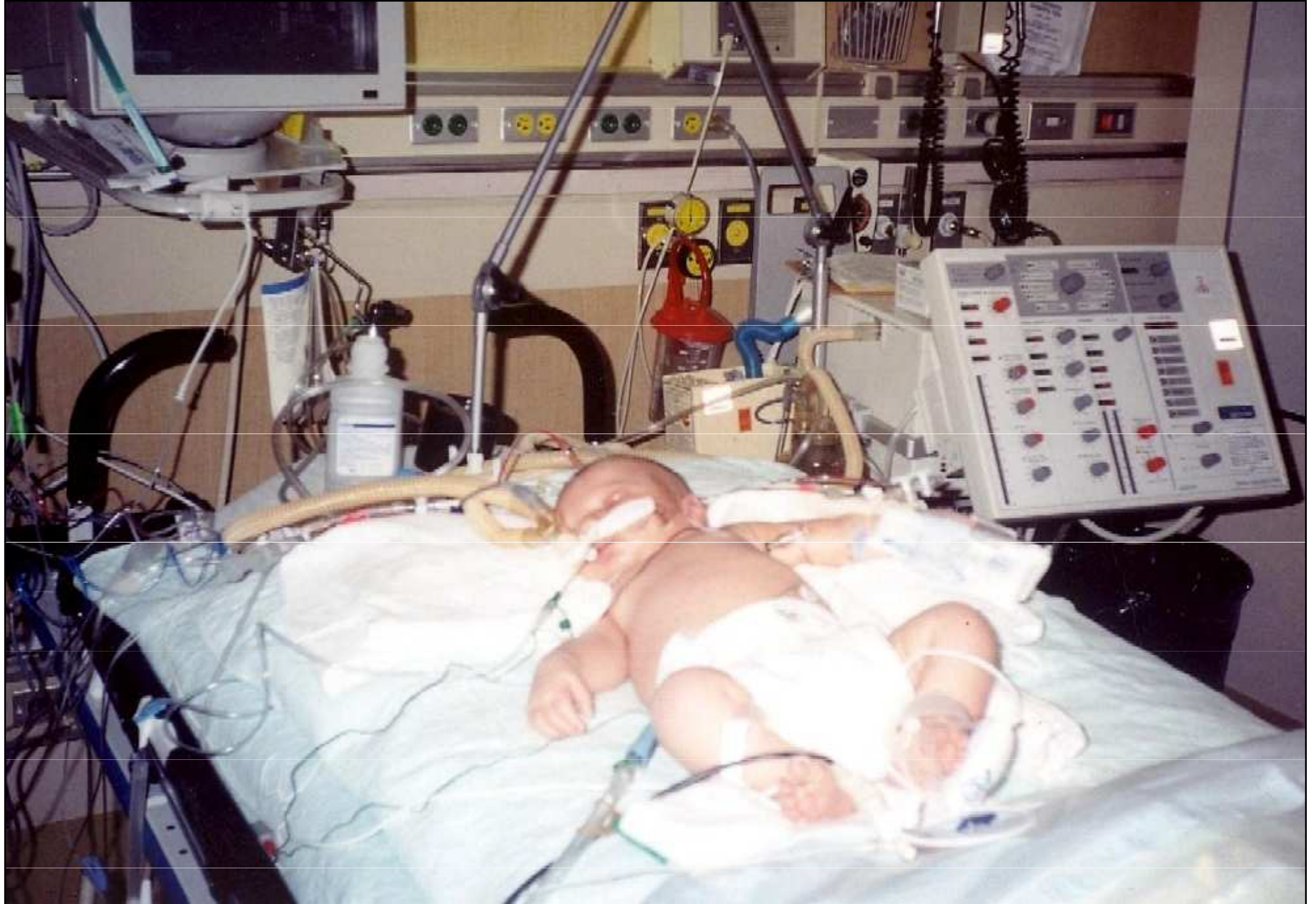<http://www.megru.unizh.ch>

More complications:  
Repeated erysipelas may also damage lymphatic vessels, leading to chronic lymphedema.

<http://homepage.univie.ac.at>

# Story Two

- Young lady Erika was not too often present at **preventive controls** during pregnancy. Few days before delivery she found herself in a birthhouse. **Delivery itself did not bring any complications.** Soon the child started to have **signs of sepsis and respiratory failure.** Quick treatment saved the child's life, and also prevented **progression to meningitis** that is, unfortunately, quite common here.
- Later Mrs. Erika was shown to be a **carrier of a bacteria**, that was shown to be guilty.



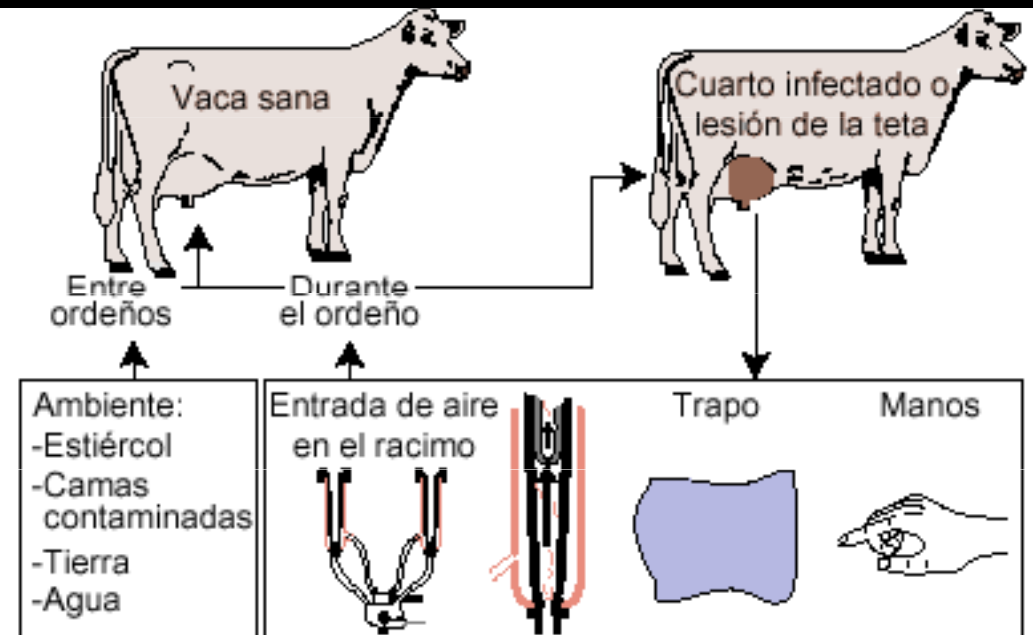
<http://home.cc.umanitoba.ca/~soninr/Dylan%20in%20hospital.JPG>

# Who is guilty now?

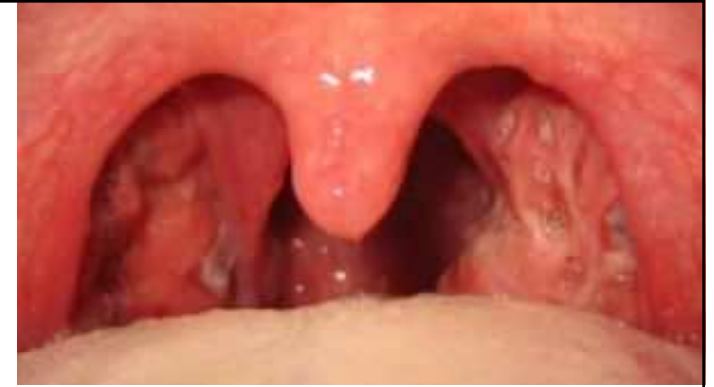- Bacterium ***Streptococcus agalactiae*** is a *Streptococcus*, too. In humans, it rather infects lower parts of body (**urogenital infections**) with risk of newborn infection

*Clever students should mention species name **a-galactiae**, i. e. „milk-less“. This bacterium really causes also milk gland inflammation with damaged milk production; these features, nevertheless, are seen in cattle, not humans*

Scheme of transmission of *S. agalactiae* in cattle (from a veterinary website) <http://www.infocarne.com>

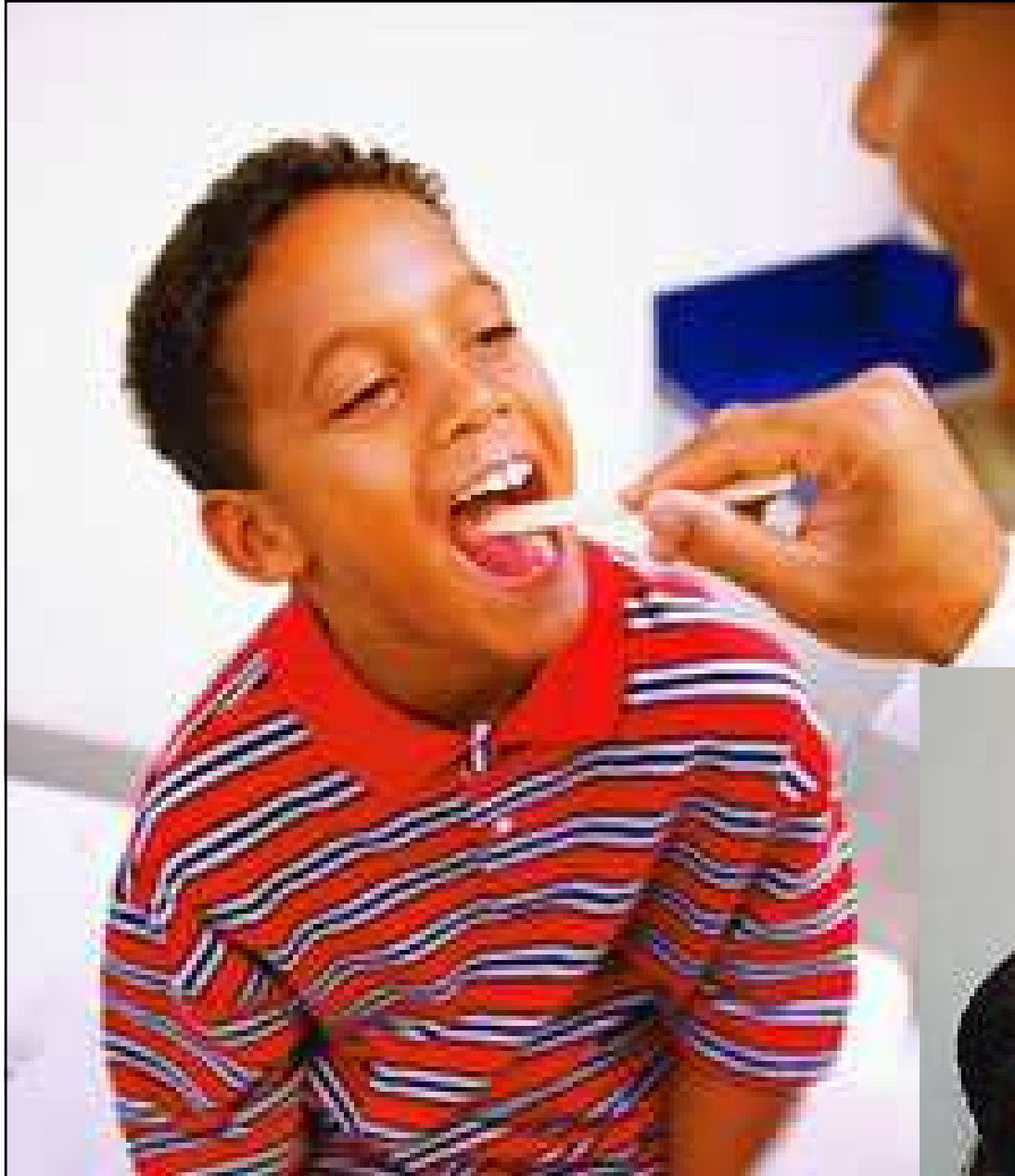

# Story Three



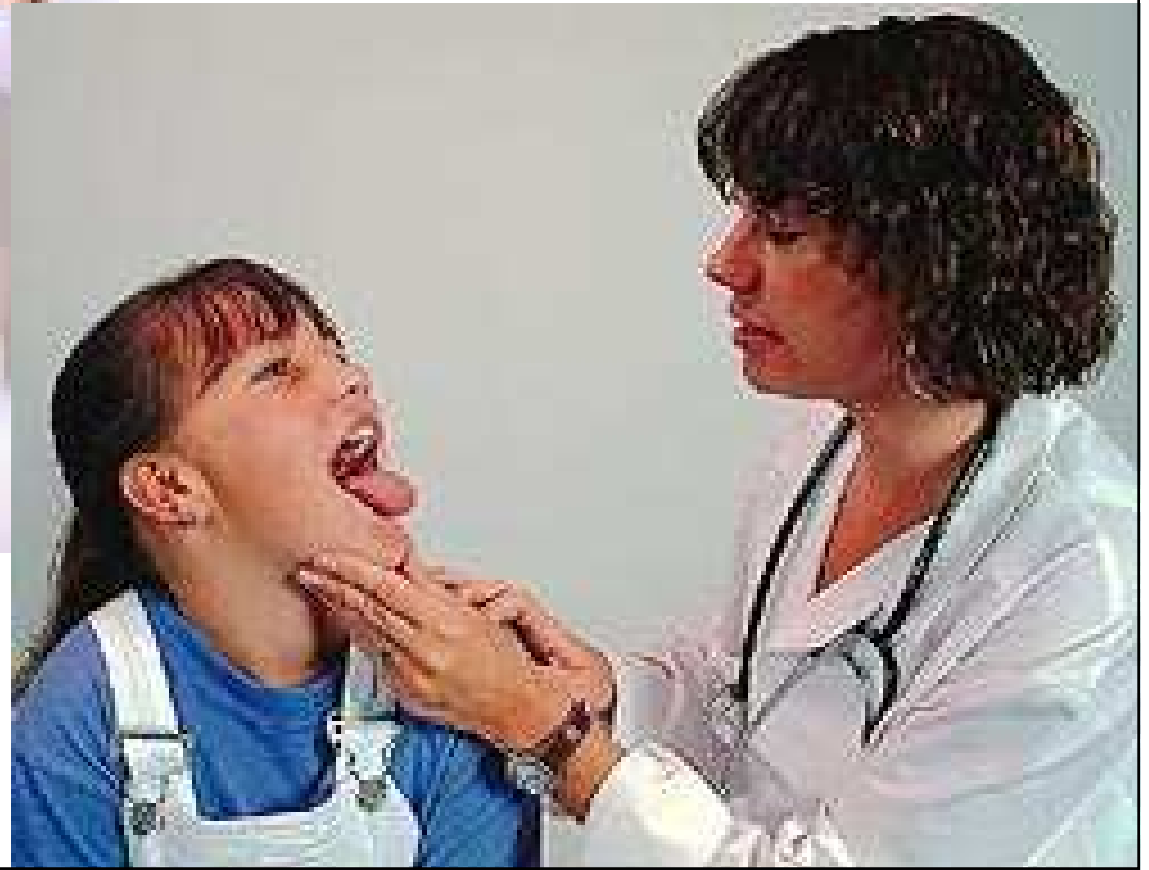- **Harry the boy** has a sore throat. It looks like tonsillitis, but he already had both adenectomy and tonsilectomy.
- Parents went with Harry to see a doctor, to prescribe him some antibiotics. But the doctor said – **first throat swab, and then maybe antibiotics**. She invited Harry in three days. After that, she prescribed **penicillin**, and it started to have effect very soon.






<http://www.stronghealth.com>

<http://www.childrenshospital.org>



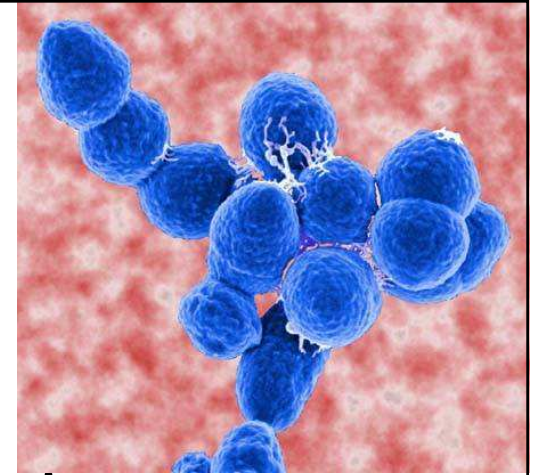
# Who caused Harry's problems?



- So named „non-A-non-B“ streptococci are called so as they do not belong neither to A group (in which *Streptococcus pyogenes* is the only one) nor to B group (where *S. agalactiae* is the most important one).
- They do not cause so often tonsillitis, but rather pharyngitis – inflammations of pharynx. Nevertheless, they are often present in healthy persons' throats.
- The same as in tonsillitis, in susceptible strains the first antibiotic to be used is penicilin; macrolids in allergic persons only.

Clinical  
characteristics:  
viridating ( $\alpha$ -haemolytical)  
streptococci

# Story Four

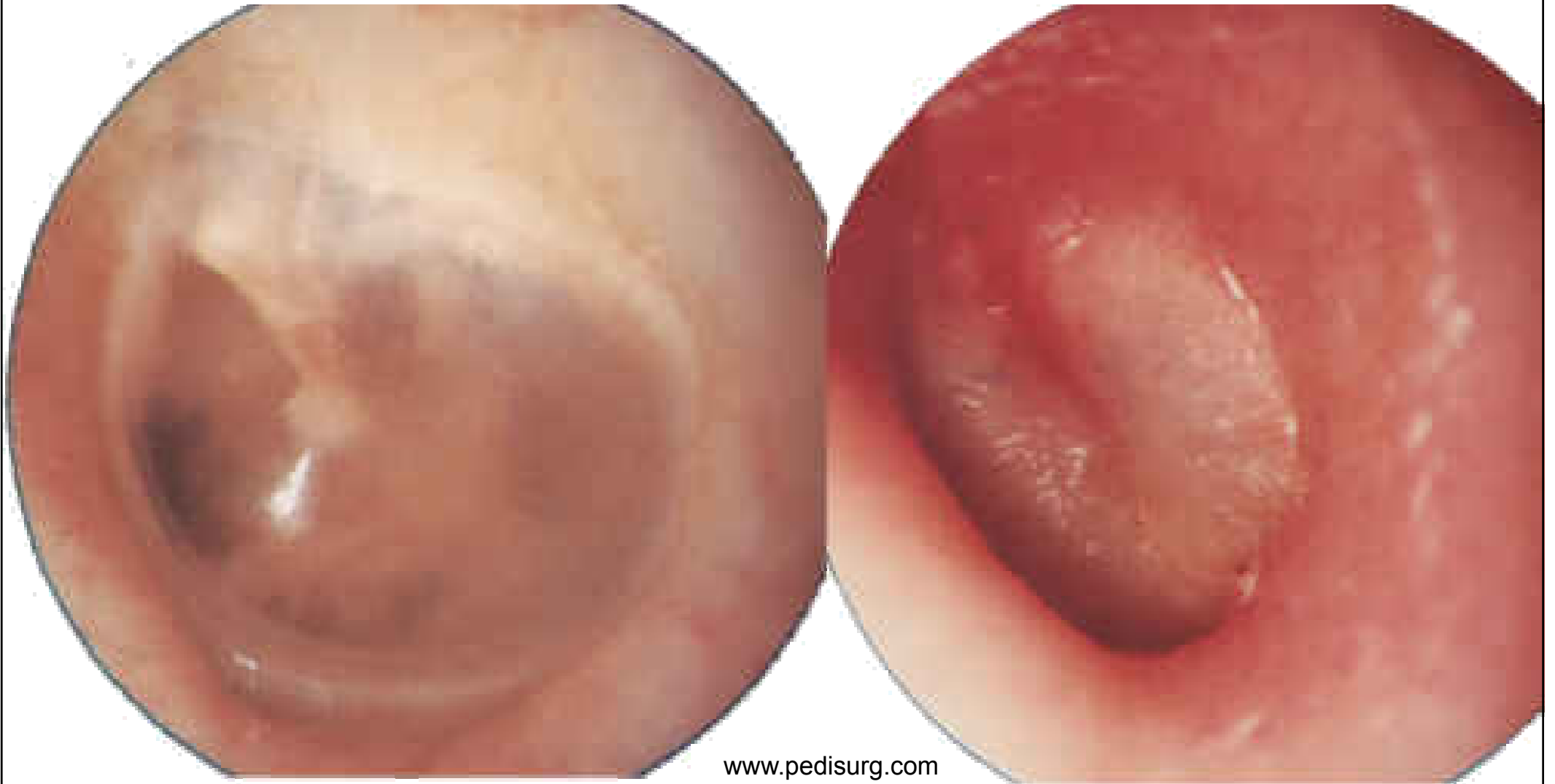

- Missis Evelyn, retreated, has her spleen let extracted long ago after a car accident.
- Several days ago, she caught a „common cold“, she did not pay attention to this, but later her status worsened, so her daughter drove her to a hospital, where she was hospitalized on infectious diseases department with suspicious meningitis
- Grace to soon antibiotic treatment her status became better and she got back her health.

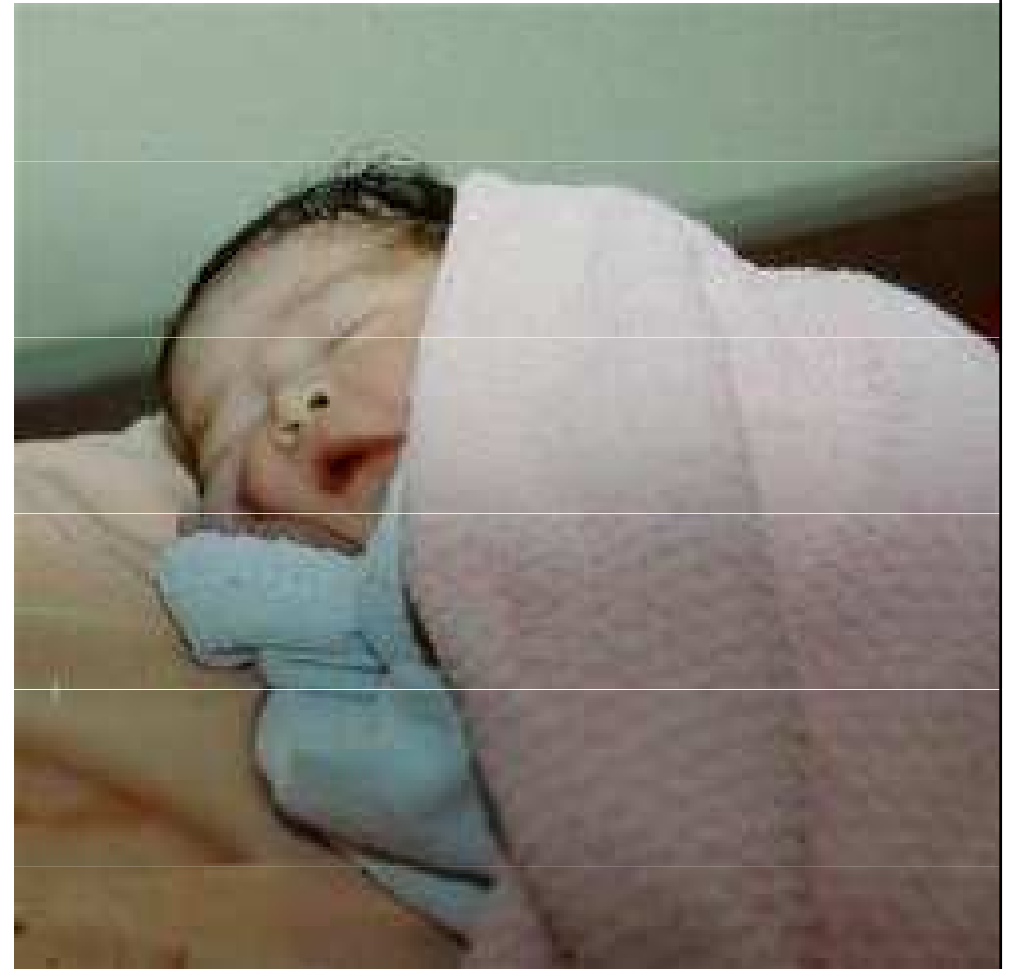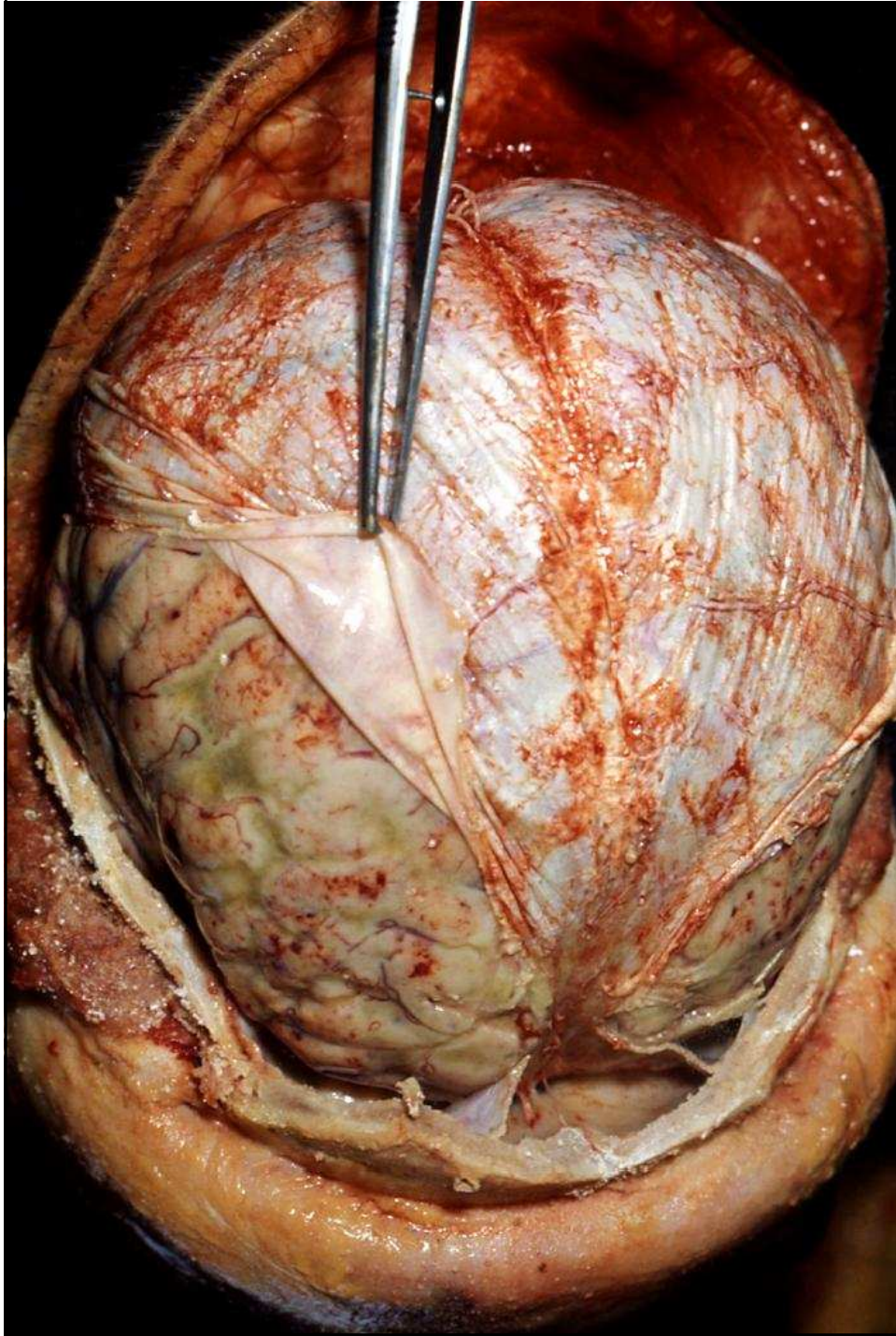
## This time criminal is:

- ***Streptococcus pneumoniae***, or „pneumococcus“. It was also called *Diplococcus pneumoniae*, as it does not form chains, but couples. Its shape is not perfectly spherical, but rather lancet shaped.  
(Remember this, examiners might ask you this the examination. 😊)
- In small amount, it is present in healthy persons' pharynx. On the other hand, it causes pneumoniae, sinusitis, otitis media and even sepsis and meningitis.

# Healthy tympanon (left), otitis media (right)



# Pneumococcal meningitis

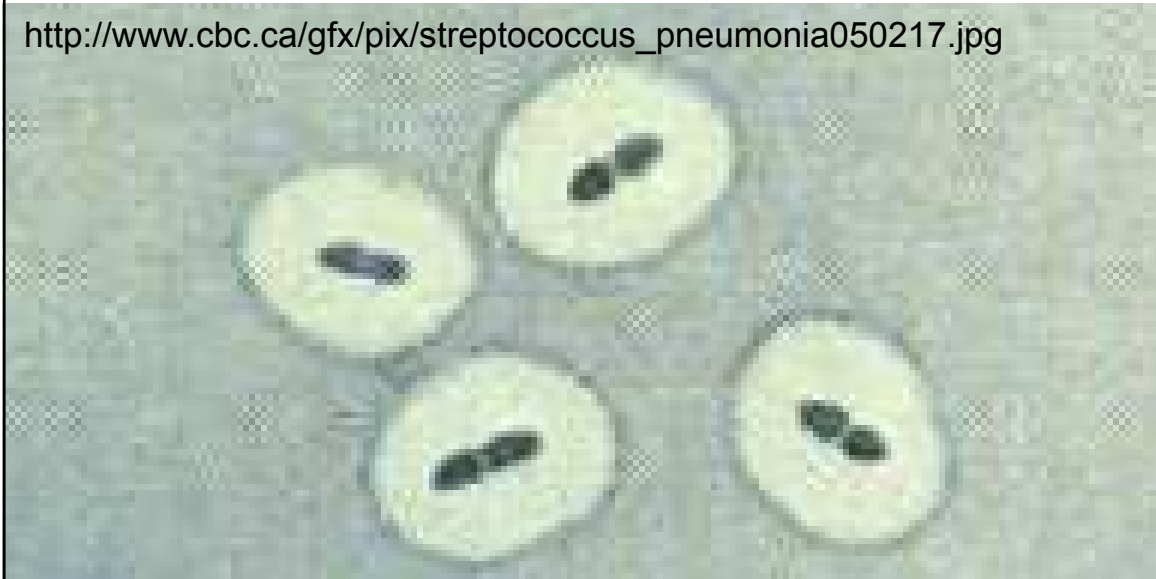


<http://www.meningitis.com.au>

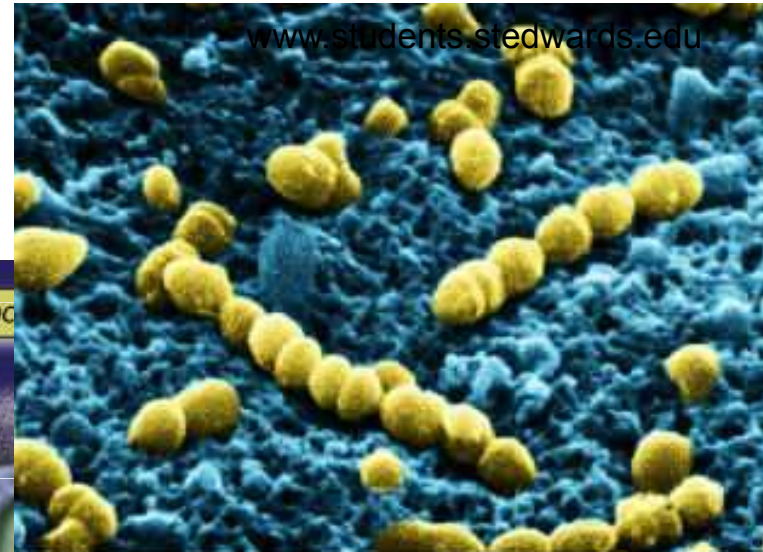
<http://commons.wikimedia.org>

# This is how the criminal looks like:

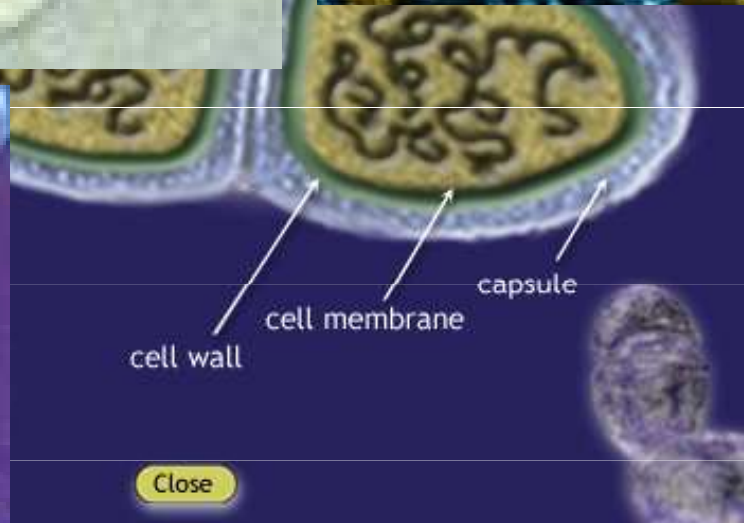
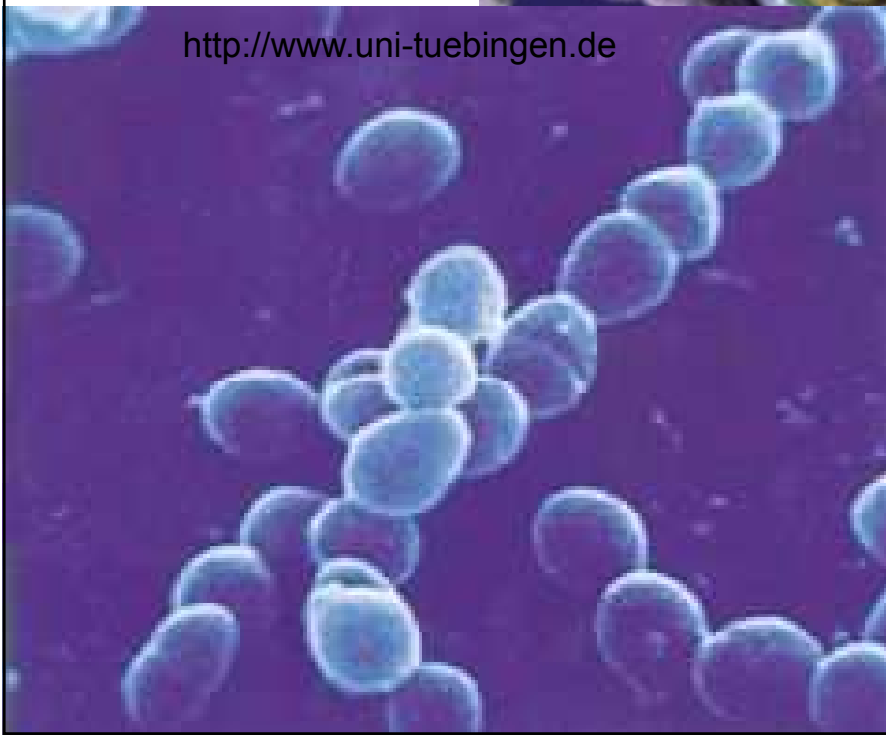[http://www.cbc.ca/gfx/pix/streptococcus\\_pneumonia050217.jpg](http://www.cbc.ca/gfx/pix/streptococcus_pneumonia050217.jpg)



[www.students.stedwards.edu](http://www.students.stedwards.edu)

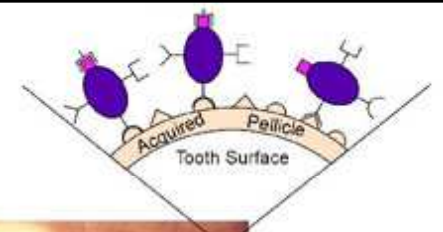


<http://www.uni-tuebingen.de>

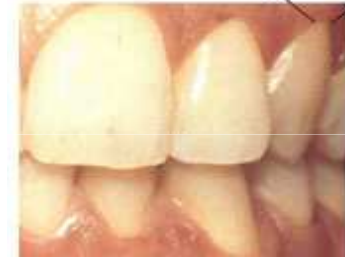

<http://www.uni-tuebingen.de>





# Story Five



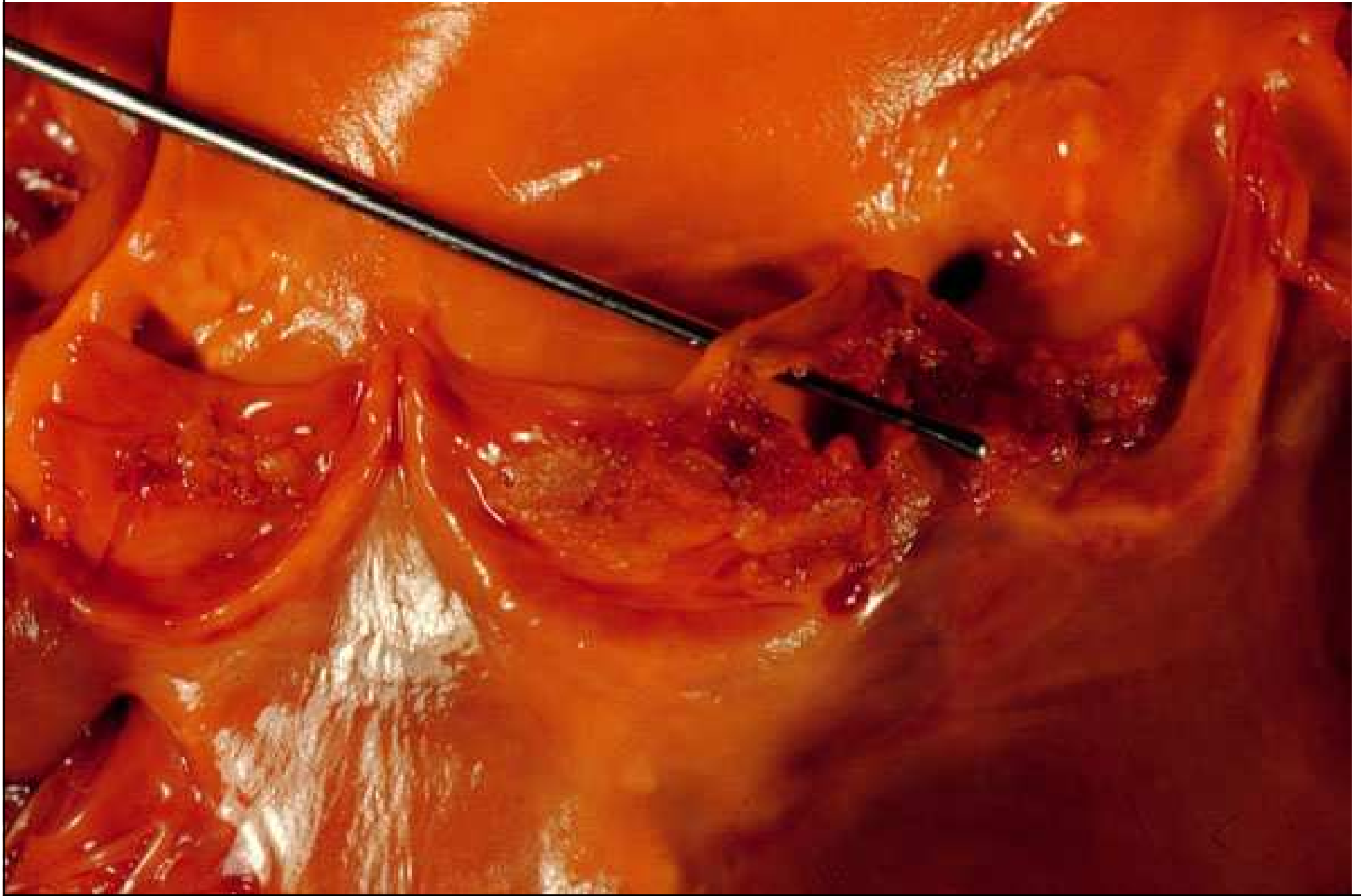
- **Mr. Hearty** has long duration heart problems. Even the **artificial heart valvula** had to be installed into his body.
- One month ago, he had an awful **dental caries**, and it lasted long time before he came to see a stomatologist.
- Now his heart problems worsened so that he had to be hospitalised. Diagnosis **endocarditis lenta** was set down.

# Who is the criminal in this crime?

- Oral streptococci, viridans streptococci, alpha streptococci, all these names describe streptococci viridating on blood agar; usually we mean „viridans streptococci, but not pneumococcus“
- They are part of normal oral and pharyngeal flora. Even at physiological conditions, all the time some streptococci penetrate in small amounts into the bloodstream. The problem starts, when they come there too many together, and when they meet a suitable terrain.

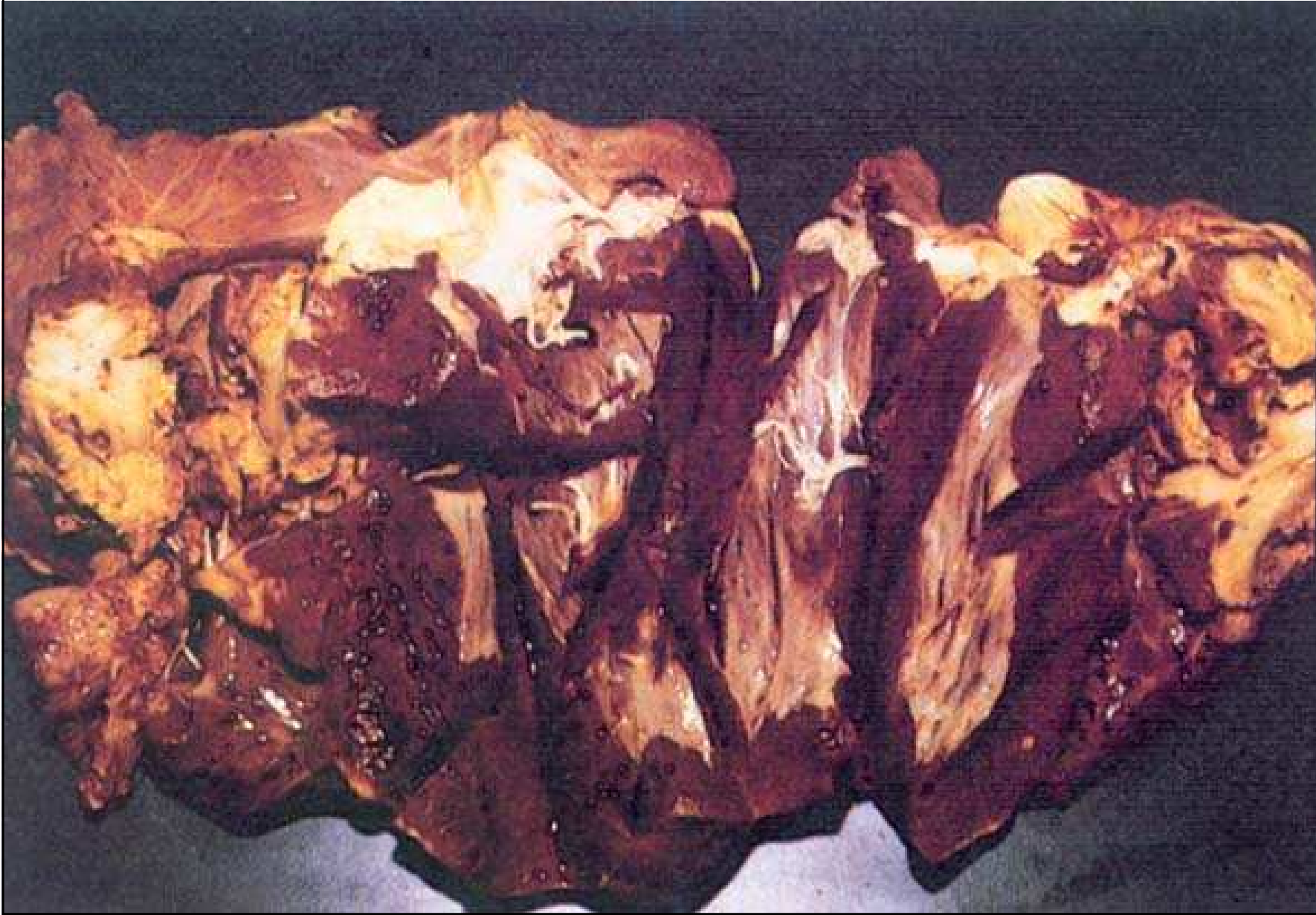
# Vegetation on a valve

<http://www.pathguy.com>



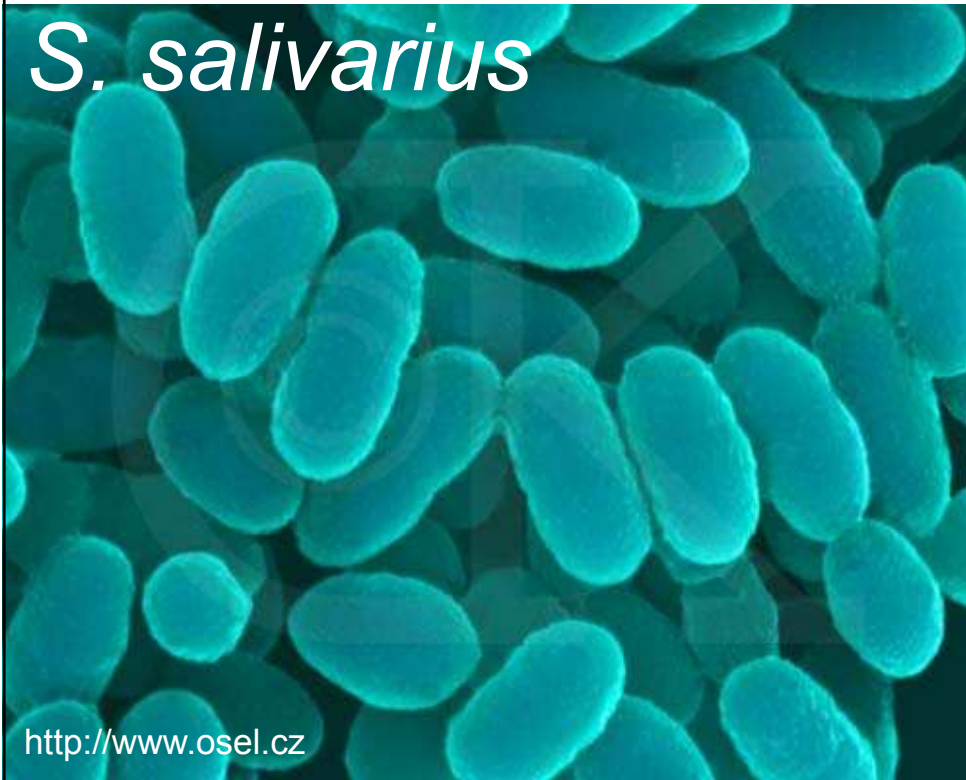# Diseased heart

<http://www.fao.org/docrep/003/t0756e/T0756E83.jpg>

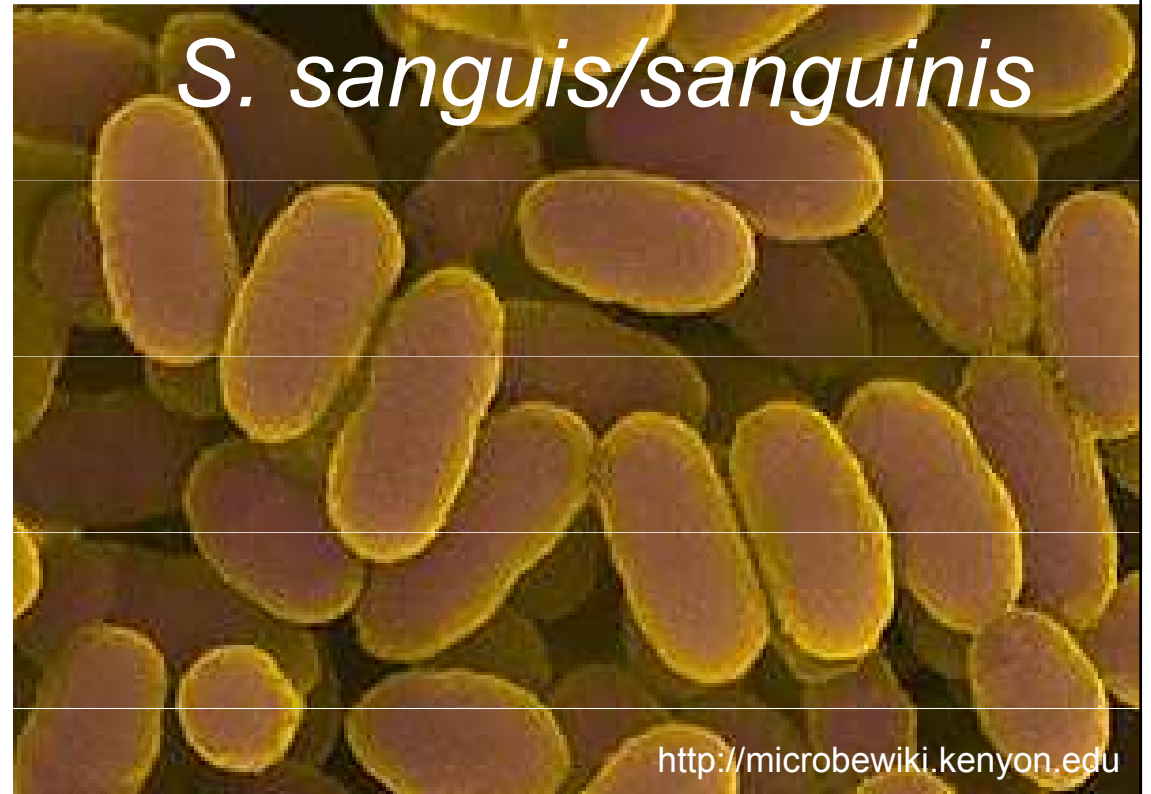

# Some possible criminals

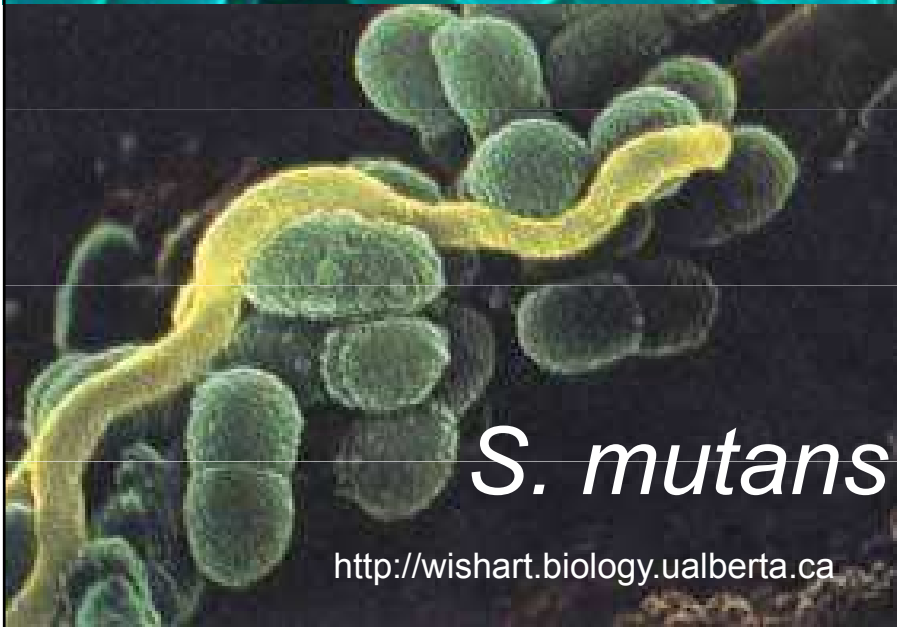*S. salivarius*




*S. sanguis/sanguinis*



*S. mutans*



Among „oral“ streptococci, *S. mutans* has probably the highest relation to dental caries.

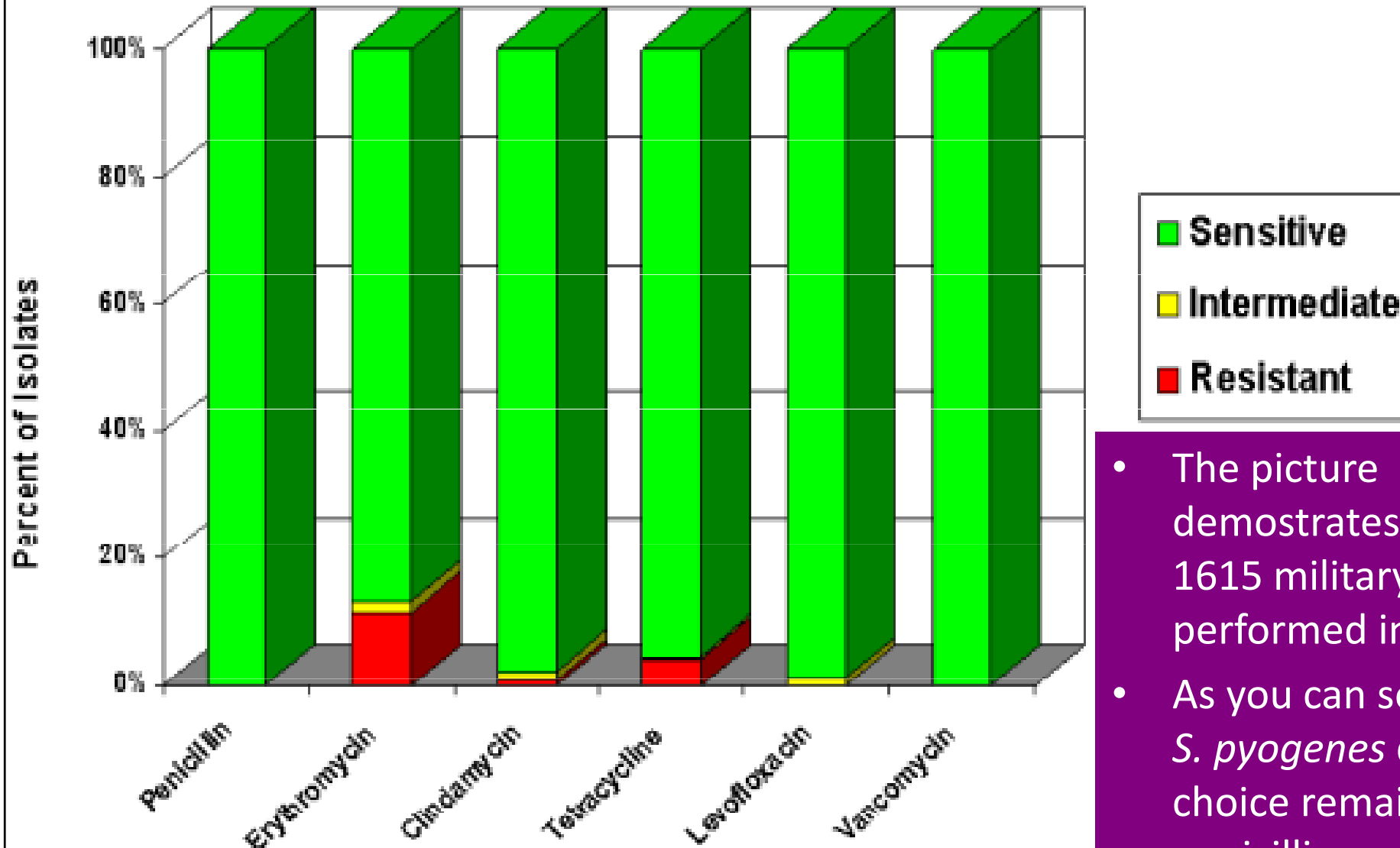


# Therapy of streptococcal diseases

# Treatment: the criminal should be punished

- Guilty Streptococci will be punished by a suitable antibiotic. In Streptococci the No. 1 drug is the classical Fleming's penicillin (either G-penicillin for parenteral use or V-penicillin for oral use). Macrolides should be used in PNC-allergic persons only. Doxycycline, co-trimoxazole, ampicillin and others might be used. Vancomycin is a reserve, 100% effective antibiotic (no zone = a mistake, it is not a streptococcus)

# Susceptibility of streptococci to atb



- The picture demonstrates a study in 1615 military addicts performed in 2003
- As you can see, in *S. pyogenes* drug of choice remains penicillin




# Susceptibility testing

- Usually we read the **diffusion disk test** by measuring the zones and comparing with the reference zones
- Again: the worse pathogen (pyogene streptococcus) is **more susceptible than milder pathogens**
- The tests are performed on **MH agar with blood** or on **blood agar**. On the MH agar without blood streptococci grow poorly, or do not grow at all.

*Nevertheless, we cannot utilise this fact in diagnostic – some streptococci are able to grow there!*

# Streptococcal susceptibility test



Antibiotic	Abbr.	Reference zone
Penicilin (basic penic.)	P	28 mm
Cefalotin (cefalosp. 1. g.)	KF	18 mm
Erytromycin (makrolid)	E	23 mm
Clindamycin (linkosamid)	DA	19 mm
Chloramphenicol	C	21 mm
Doxycyklin (tetracyclin)	DO	19 mm
Vancomycin (glycopeptid)	VA	17 mm

Clindamycin: Usually tested, but not in our practical session

# Diagnosatics of streptococci

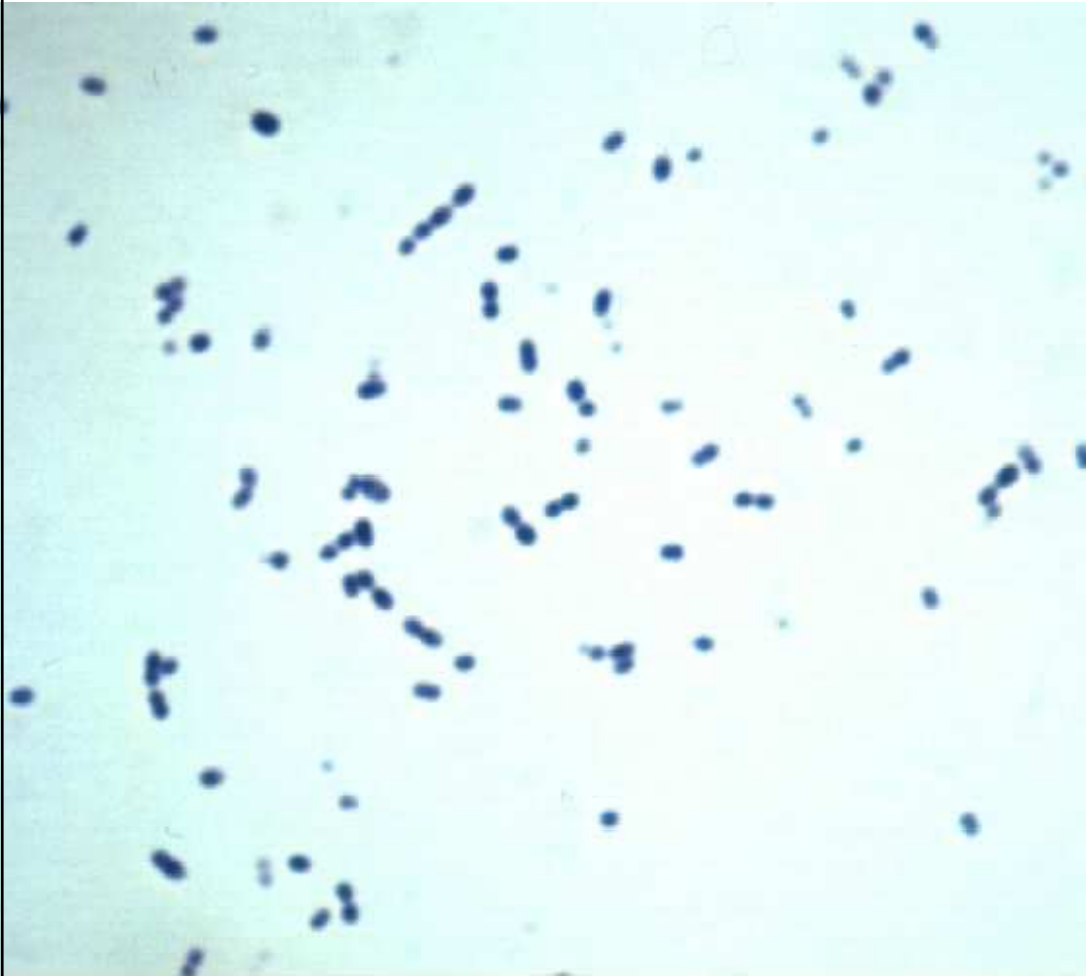
# Description of criminals (diagnostics) 1

- **Microscopy:** grampositive cocci
- **Cultivation:** on BA grey to colorless colonies, usually small, larger colonies has only *Streptococcus agalactiae*
- **Hemolytical properties:** some viridate, some partially or totally hemolyze
- **They do not grow** neither on BA with 10 % NaCl, nor on Slanetz-Bartley or Bile aesculin medium.
- Together with enterococci, they are **resistant to aminoglykosides**, so medium with amikacin is used as a selective medium.

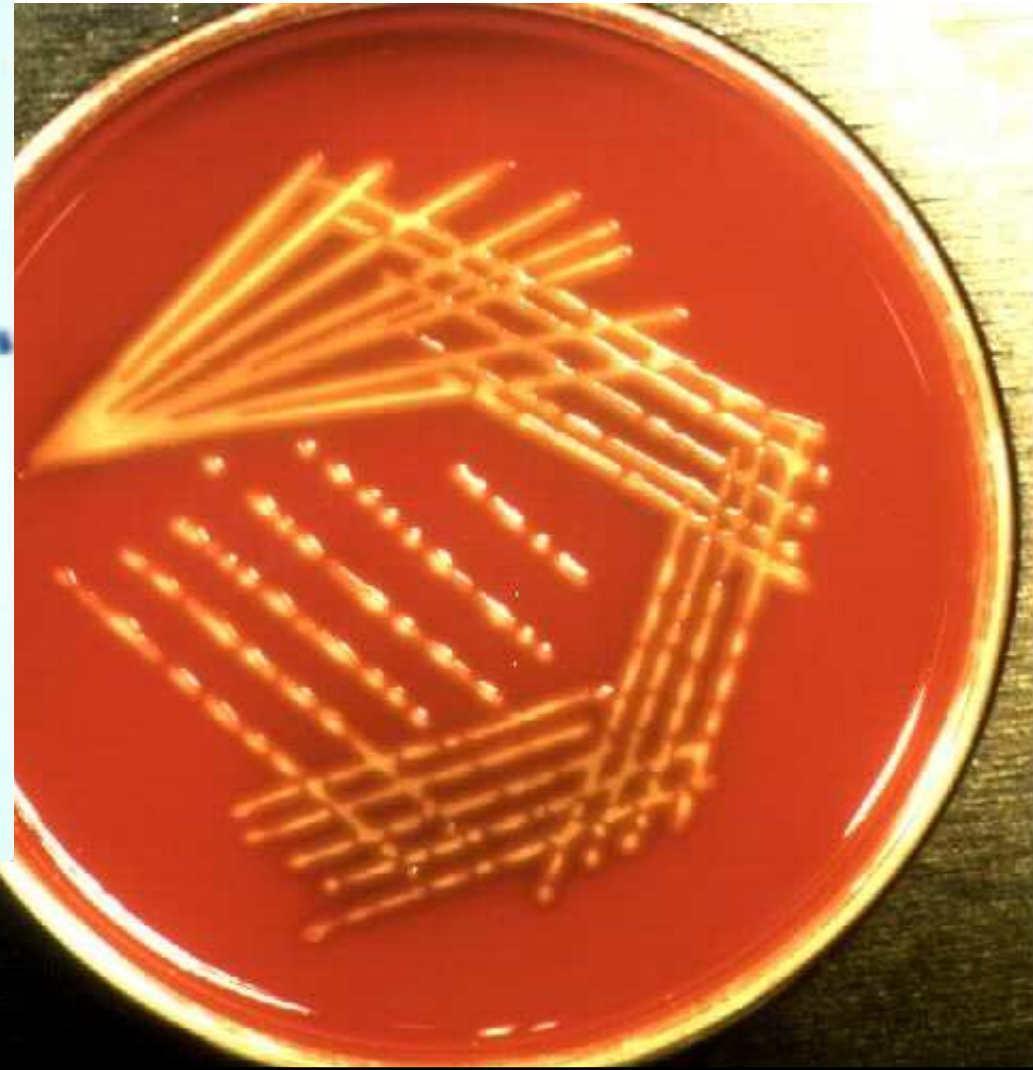
# Description of criminals (diagnostics) 2

- **Biochemical tests:** both catalase and oxidase negative, biochemical differentiation of individual species possible especially in viridating streptococci
- **Antigen analysis** helps rather in haemolytical streptococci. **Lancefield** system is used – theoretically all streptococci are involved, but many viridans streptococci have no antigen in this system. Groups are labelled by letters **A, B, C, E, F, G** etc.

# Photos of criminal database



Source: Archive of  
Institute for  
microbiology



# Differential diagnostics of streptococci

# Differentiation from other suspects (diferencial diagnostics 1)

<http://memiserf.medmikro.ruhr-uni-bochum.de>

- Gram stain show all bacteria, that do not belong among grampositive cocci.
- Negative catalase test differentiates streptococci from staphylococci
- Growth on SB and BE media differentiates enterococci. All of them are also positive in so named PYR-test, while among streptococci only one of them is positive, and that one is rarely confused because of its very strong haemolysis and other properties



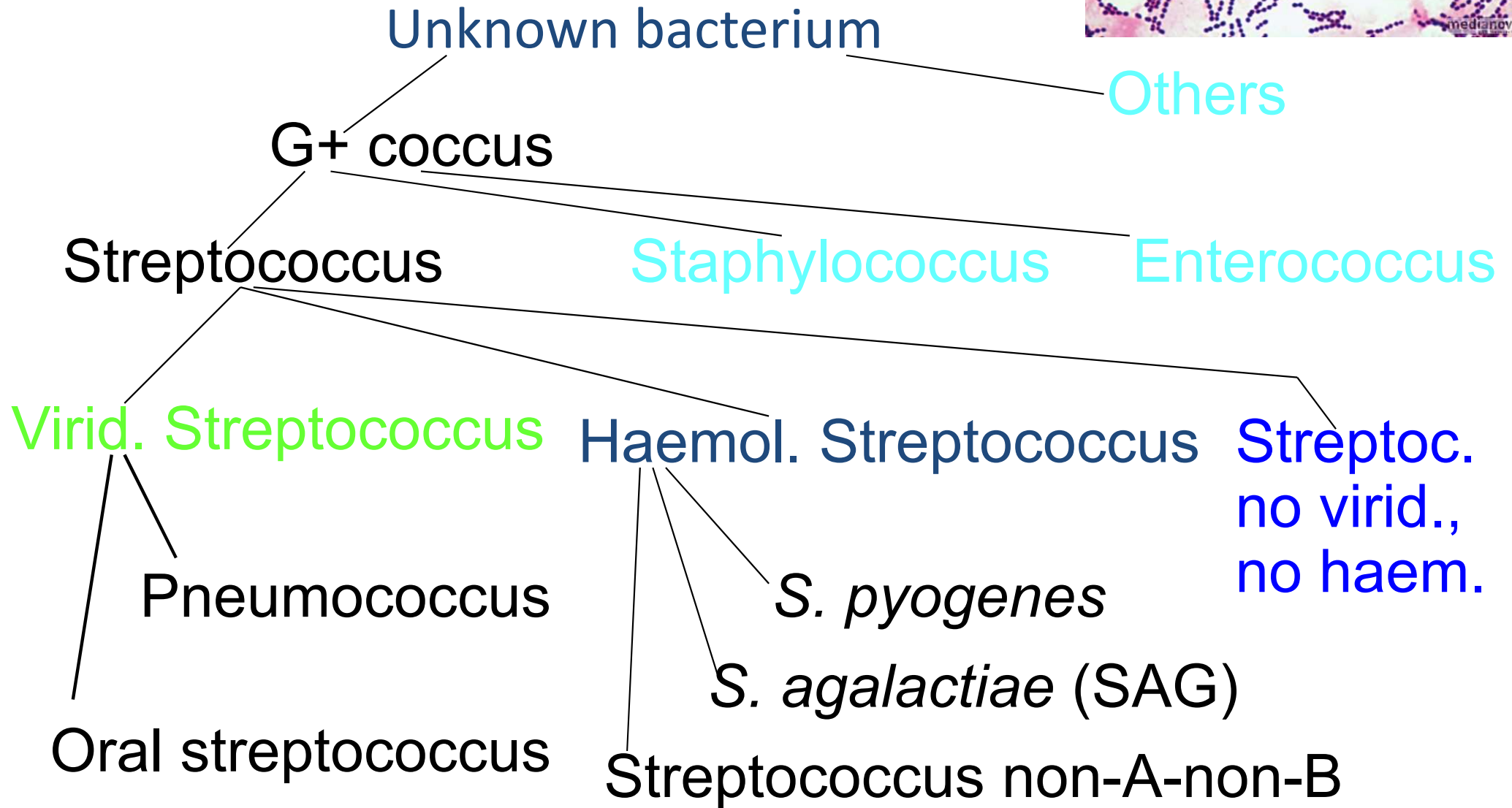
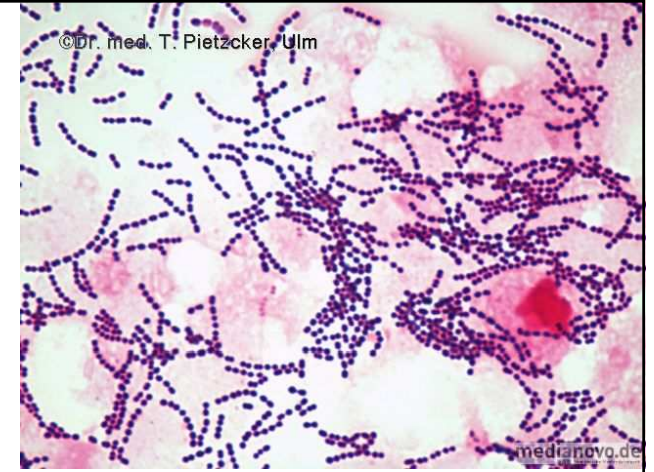


# Differentiation from other suspects (diferencial diagnostics 2)

- Hemolysis should be observed now – it clasiffies streptococci into haemolytical, viridating and others
- Pneumococcus vs. other viridans streptococci:  
Pneumococcus has positive optochin test, test of solubility in powder bile etc.
- *S. pyogenes* vs. other haemolytic streptococci:  
Both Bacitracin and PYR test are ⊕ in *S. pyogenes*
- *S. agalactiae* vs. other haemolytic streptococci:  
CAMP test is ⊕ in *S. agalactiae*

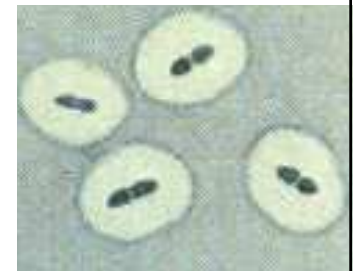
*About all these tests – more info later*

# Schematically:



# Pneumococcus: How to become suspicious

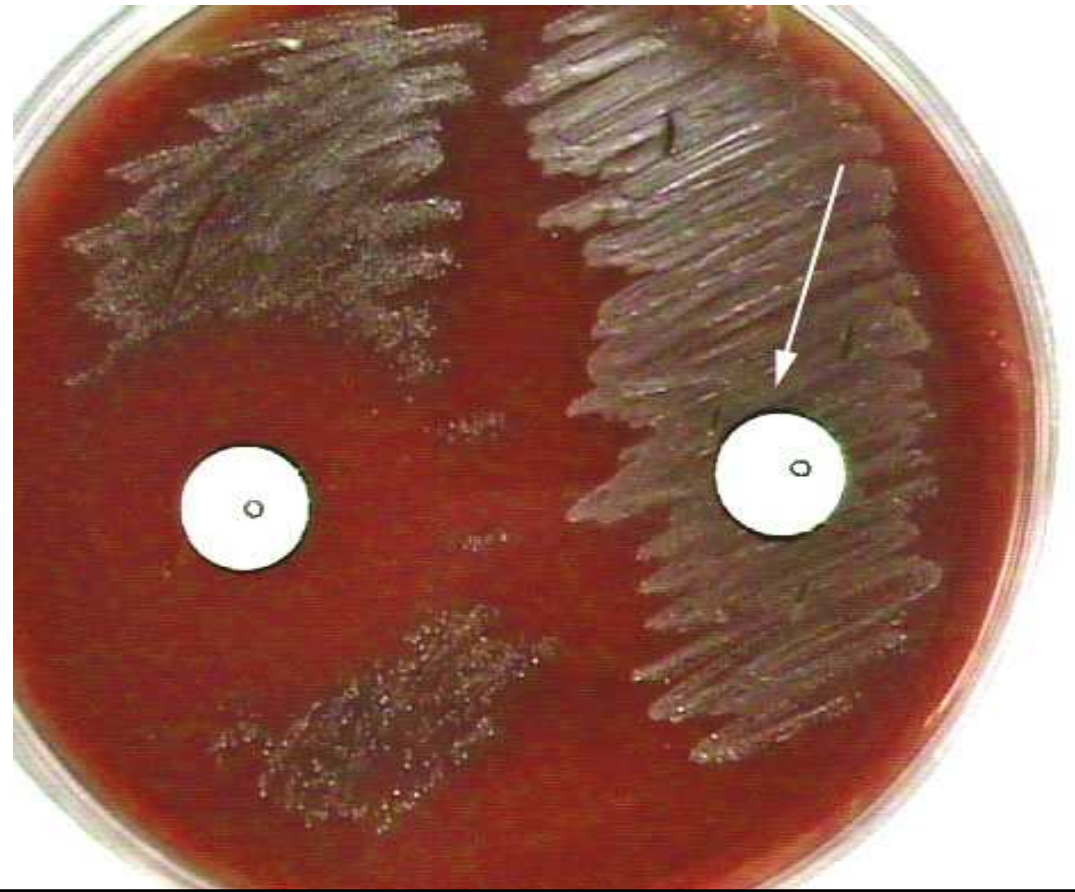
- Pneumococcus can be differentiated by the optochin test – see following slide.
- Suspicion maybe taken, when:
  - microscopically lancet-shaped diplococci can be seen
  - cultivation: colonies flat, coin-shaped to dish-shaped, sometimes with a central elevation
  - on the other hand, sometimes the colonies are large and mucoid: those are strains with a strong capsula production (usually highly virulent)



# Optochin test

- Classical test to differentiate pneumococcus from oral streptococci. Pneumococcus is susceptible to optochin (antibiotic), oral streptococci are resistant. (Optochin is not used therapeutically today, it remained in diagnostics only)

- Sometimes, the test of solubility in powder bile is used. Test of mouse pathogenicity is today considered to be historical



# Species determination of oral *Streptococcus*























































- Only someone mad (or a researcher – sometimes it is the same) would differentiate an oral streptococcus to species level, when the strain is from oral cavity of pharynx. Why to do it, when we consider it to be a part of normal flora?
- On the other hand, in strains from blood cultures, differentiation is logical. In viridating streptococci, it has no sense to attempt the antigen analysis, but, as we know already, biochemical tests are very useful.
- In Czech conditions, it is mainly STREPTOtest 16

# STREPTOtest 16 – how to read it

*Three musketeers were four.* STREPTOtest 16 (and STAPHYtest 16 and ENTEROtest 16) use 17 reactions.

- **First reaction** is again VPT (D'Artagnan!)
- **2<sup>nd</sup> to 9<sup>th</sup> reaction** is again the first strip in the double-strip
- Similarly, **10<sup>th</sup> to 17<sup>th</sup> reaction** is the second strip in the couple strip

An example of result of Streptotest 16: Code  
 511 420 *Streptococcus salivarius*  
 % probab. 97.19 Typicity index 1.00

	1	2	3	4	5	6	7	8	9	10	11	12	13	14	15	16	17	
Tube	H	G	F	E	D	C	B	A		H	G	F	E	D	C	B	A	
	Panel – first row									Panel – second row								
+																		
-																		
?																		
	+	-	+	+	-	-	+	-	-	-	-	+	-	+	-	-	-	
	1	<del>2</del>	4	1	<del>2</del>	<del>4</del>	1	<del>2</del>	<del>4</del>	<del>1</del>	<del>2</del>	4	<del>1</del>	2	<del>4</del>	<del>1</del>	<del>2</del>	
	5			1			1			4			2			0		

# Especially dangerous criminal: the pyogene *Streptococcus*. What to do?

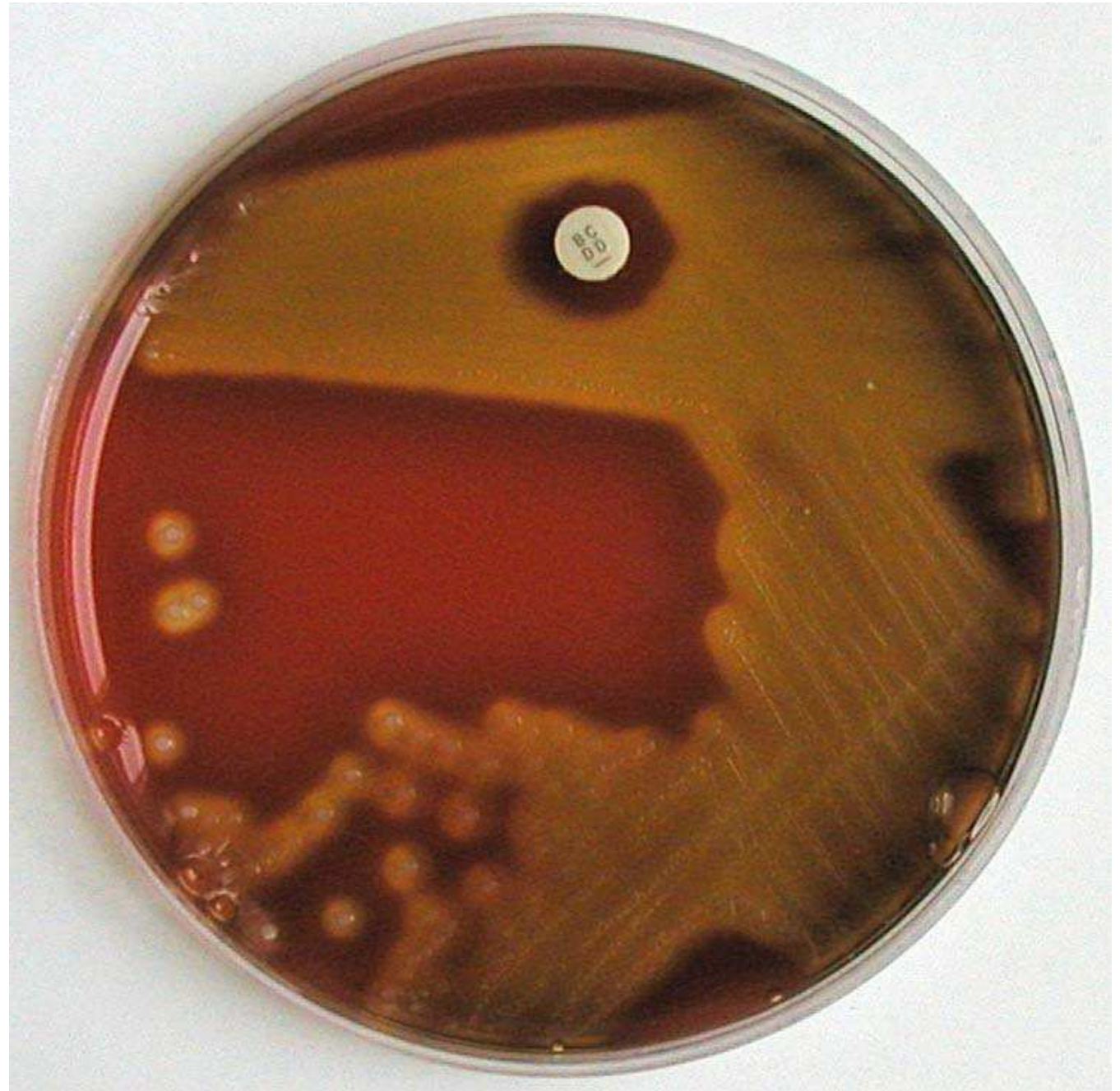
## PYR test

- **PYR test** is performed similarly as oxidase test. We touch by the strip (its reaction square) the colonies. Then we wait ten minutes. A reagent is added, one more minute of waiting follows. Red = positive
- *Bacitracin test* was used sooner. It had the same principle as the *Optochin test*, only an other antibiotic was used.



# Bacitracin test

Photo: Archive of Institute for Microbiology



# And now the second: *Streptococcus agalactiae* – 1

- Many bacteria produce haemolysins
- When two bacteria produce haemolysins, their co-operation may be either synergic or antagonistic.
- An example of a synergism is CAMP factor of *Str. agalactiae* and beta lysin of *Staph. aureus*
- It is not possible to use it for *Staphylococcus* diagnostics – not all strains of Staphylococci produce the beta lysin! So, the test is used in *Streptococcus* diagnostics only.

# *Streptococcus agalactiae* – 2

## CAMP test

- TESTED strain of a *Streptococcus* and TESTING strain of beta-lysin producing *Staphylococcus* are inoculated on the blood agar
- In case of positivity, we see stronger haemolysis in shape of two triangles, or, more poetically, butterfly wings


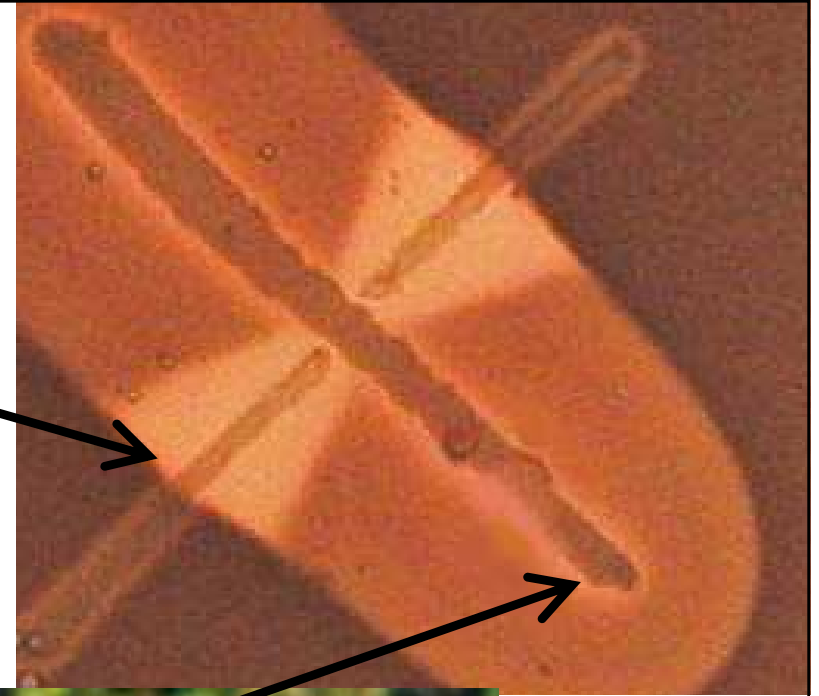


Photo O. Z.

CAMP test –  
another picture



# Haemolytical criminals – conclusion

Bacitracin and PYR test	CAMP test	<i>Streptococcus</i>
positive	negative*	<i>S. pyogenes</i>
negative	positive	<i>S. agalactiae</i>
negative	negative	non-A-non-B <i>Streptococcus</i> **
positive	positive	a nonsens, a bad test, mix of two strains etc.

\*sometimes weak synergism, not having the proper size and shape

\*eventually more detailed diagnostic using antigen analysis

# Latex agglutination

Latex agglutination is used for detailed diagnostics of non-A-non-B streptococci, if necessary, according to Lancefield scheme. However, conclusion „it is a non-A-non-B strep“ is usually sufficient. The principle of latex agglutination is showed on the pictures. Agglutination of streptococci with the antibody is helped by latex particles

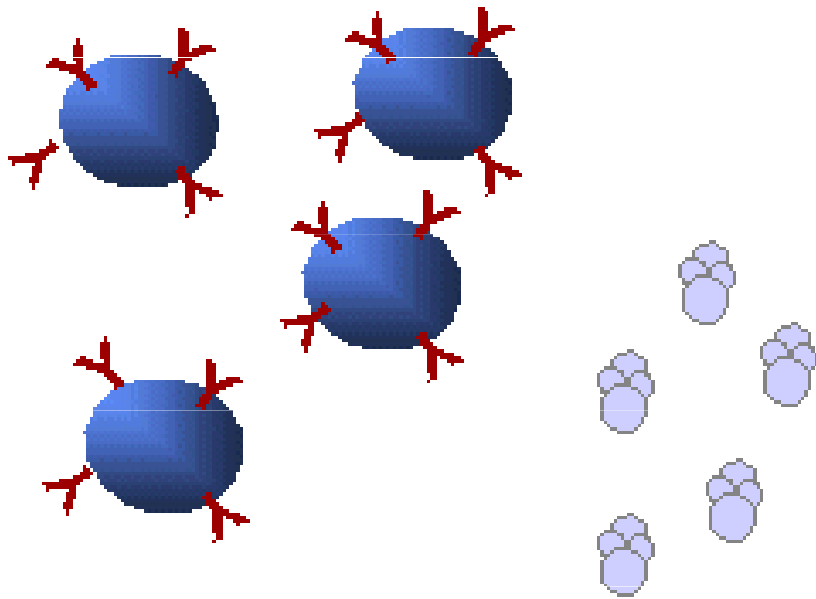


Figura 2a

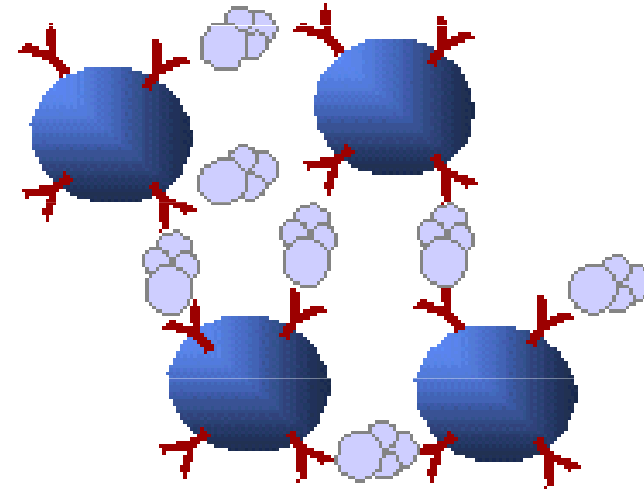


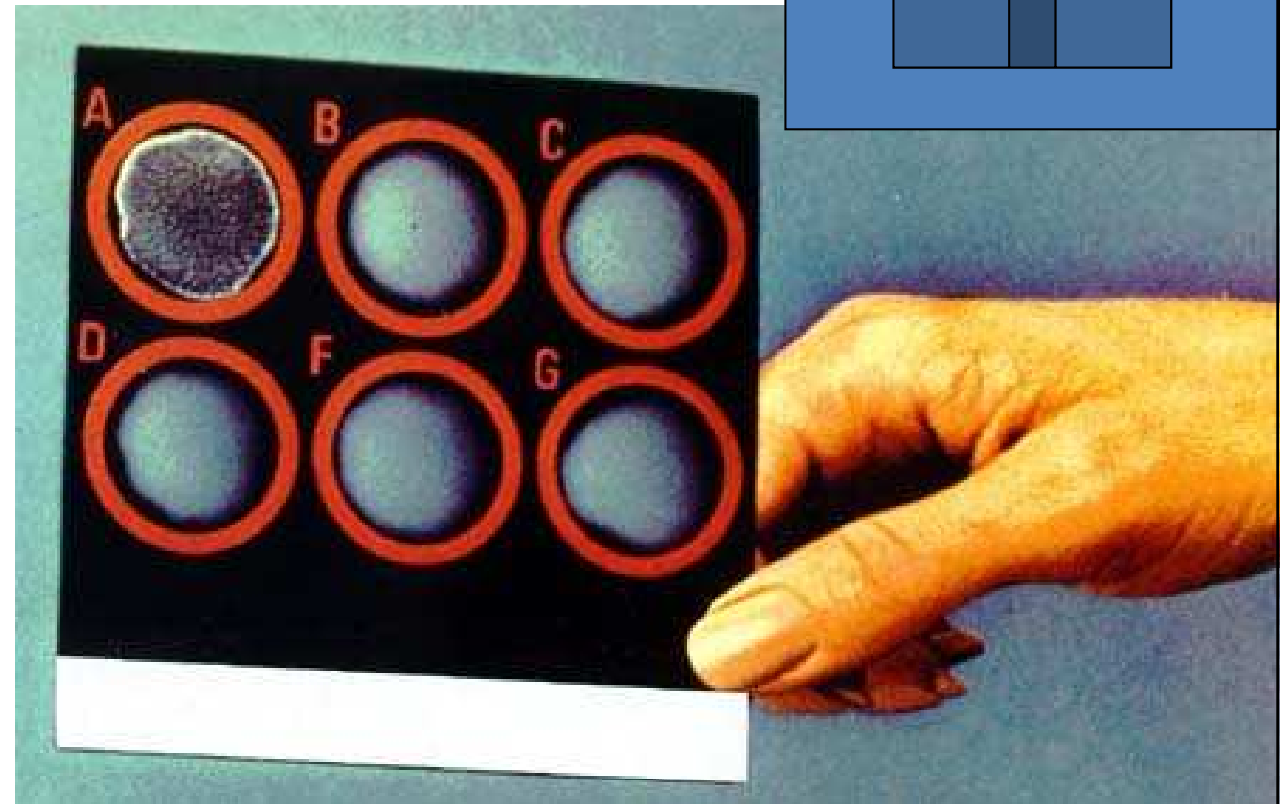

Figura 2b

# Remember:

- **Streptococci with haemolysis** (total or partial), but also streptococci with no haemolysis at all can be usually determined using **latex agglutination** (if necessary). Their biochemical activity uses to be poor.
- **Streptococci with viridation** (alpha-streptococci) can be usually determined using **biochemical testing** (if necessary). Their antigen determinants use to be poor.

# Latex agglutination – practically

- Practical test: the vessels with mixtures of antibodies and latex particles, result (positive in the first circle)



<http://www.medicine.uiowa.edu>

<http://www.pro-lab.com>



Late sequelae of  
streptococcal  
diseases

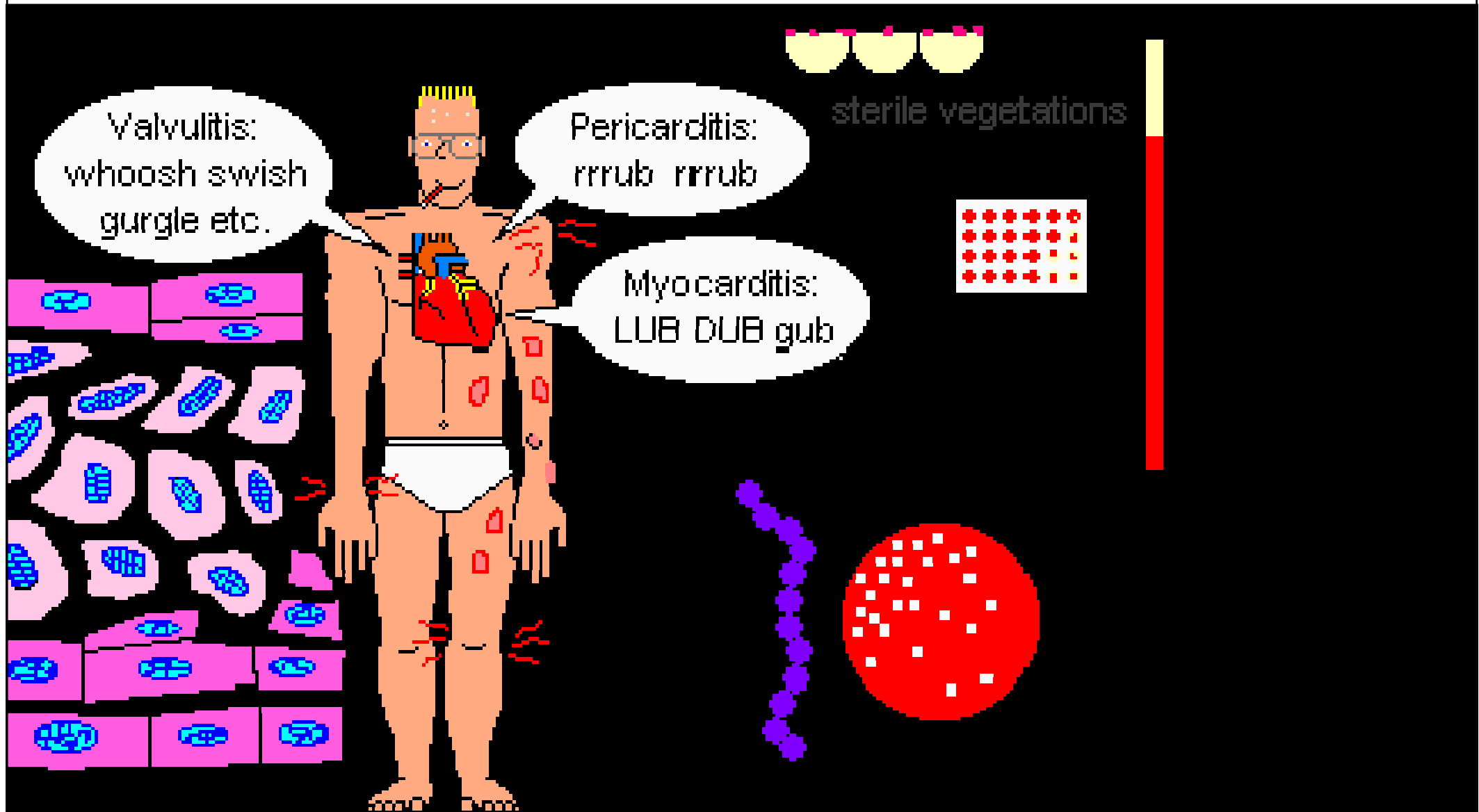
# *Streptococcus pyogenes* is even worse than we already knew

- You know that *S. pyogenes* causes tonsillitis, scarlatina, erysipelas. But the worst still waits: Even after being flown out from the organism, a terrible sequelae may occur! Antibodies circulate in the blood... and mistakenly, instead of being bound to streptococci, they bind to some structures of the organism. So, acute glomerulonephritis or rheumatic fever occurs.

*You may mention, that we have had this already once in the spring semester...*

# Rheumatic Fever

<http://mednote.co.kr>

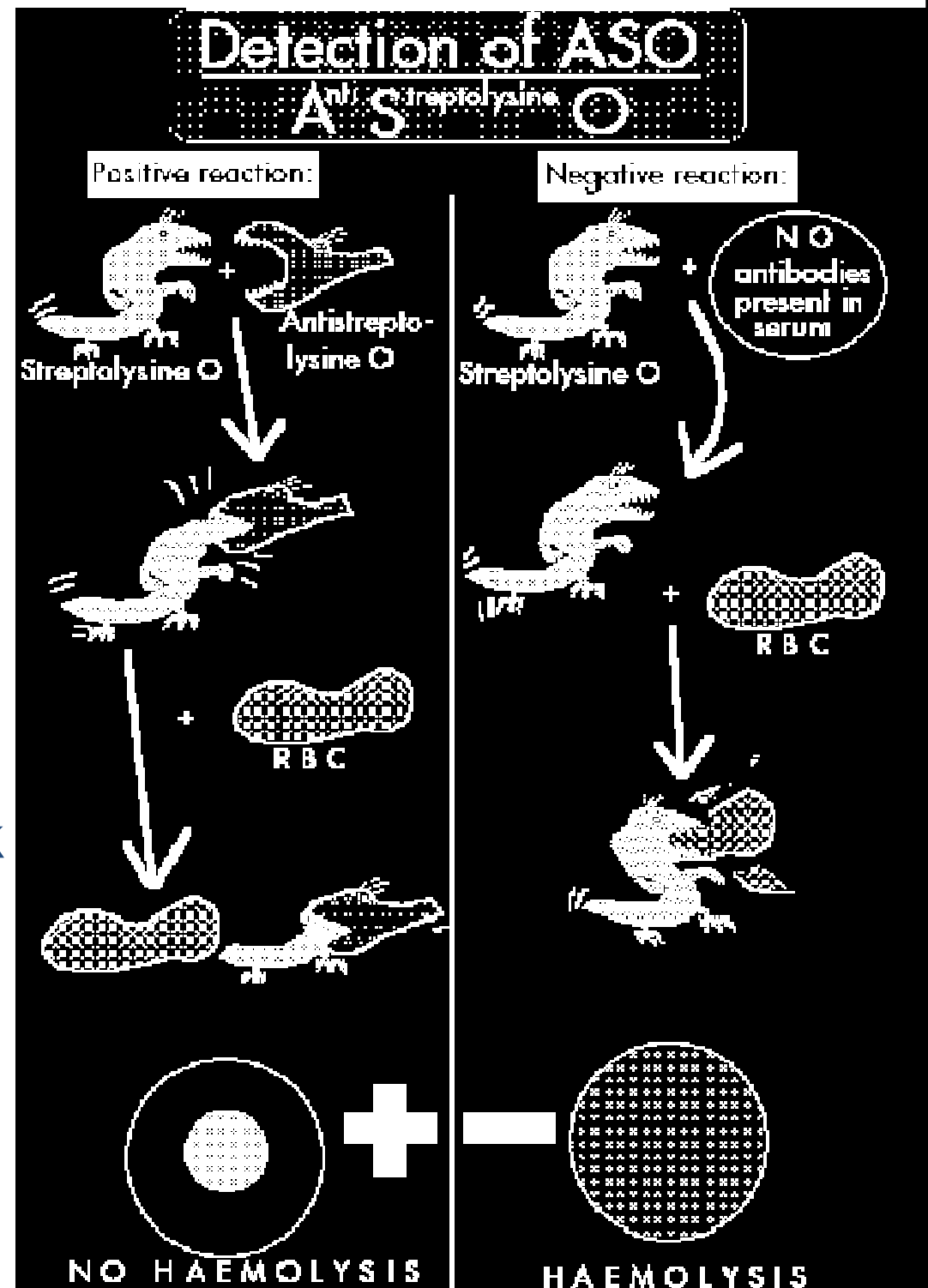


# ASO: how to see, if the risk exists

- Using ASO test you will see, if a normal antibody response is formed, or an autoimmunity over-response with risk of development of glomerulonephritis/rheum. fever
- ASO test is usually performed after a streptococcal infection. By the antibody detection, we do not try to detect the infection (we know about it), but to clarify, whether autoimmunity response is developed. So it is NOT an indirect diagnostic, although antibodies are measured.

# ASO: principle (repeating)

- The antibody blocks the haemolytic effect of the toxin (streptolysin O) on a RBC.
- In ASO, we do not use the geometrical row. The values of dilution are in a table.
- Titre over cca 250 means a risk of antibody response
- In Czech, abbreviation ASLO is used instead of ASO in English.



# How to read an ASO panel

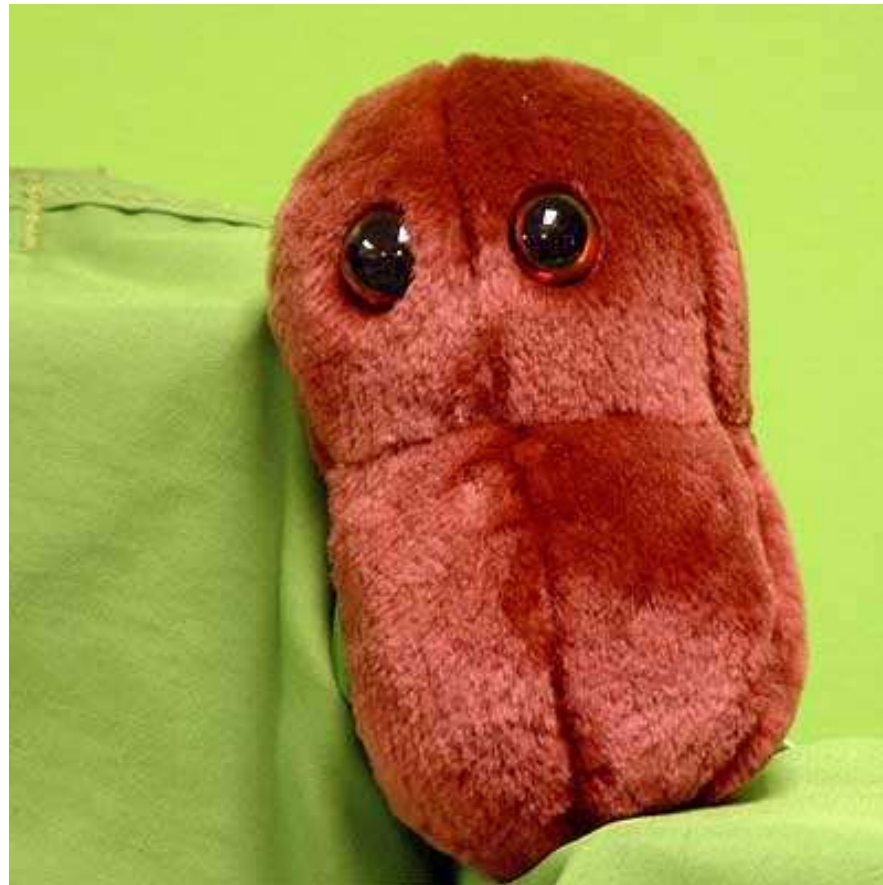

- Each patient has one row. The dilutions are here and in tables on your working tables.

## Hodnocení výsledků ASLO

žád ku č. troj nás ř. mL	1	2	3	4	5	6	7	8	9	10	11	12
	100	120	150	180	225	270	337	405	506	607	759	911

- Panel has a positive control and five patients

# Goodbye at the next part!



[www.giantmicrobes.cz](http://www.giantmicrobes.cz)

Soft toy-*Streptococcus*