

# Male reproductive system

# Male reproductive system

## Gonads

- testes

## Ducts

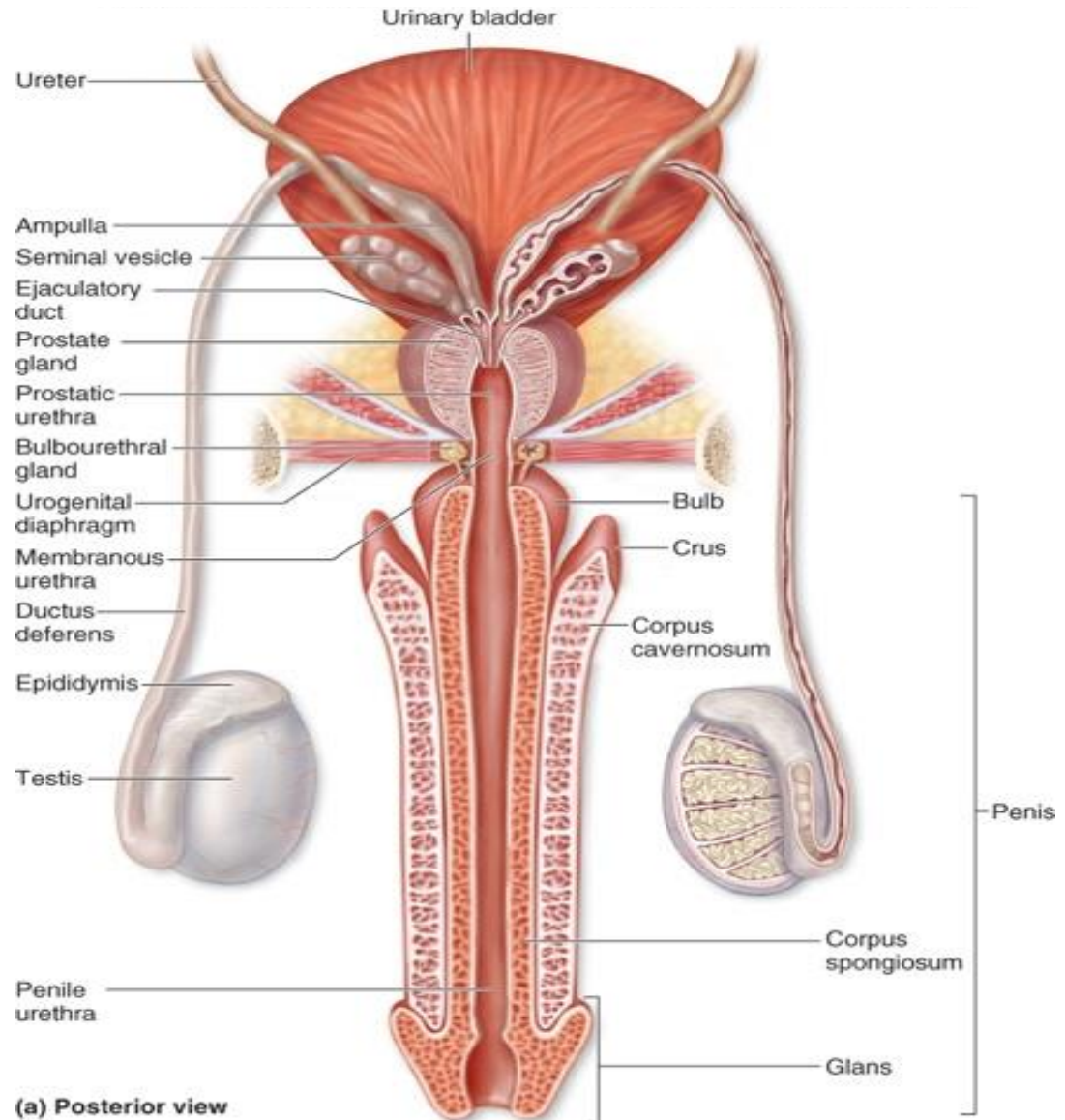
- epididymis
- ductus deferens
- ductus ejaculatorius
- male urethra

## Glands

- prostate
- vesiculæ seminales  
(gll. vesiculosae)
- gll. bulbourethrales

## External genitalia

- penis
- scrotum



# Testis

## tunica vaginalis (epiorchium)

- Serous membrane

## tunica albuginea testis

- Dense collagen connective tissue

## mediastinum

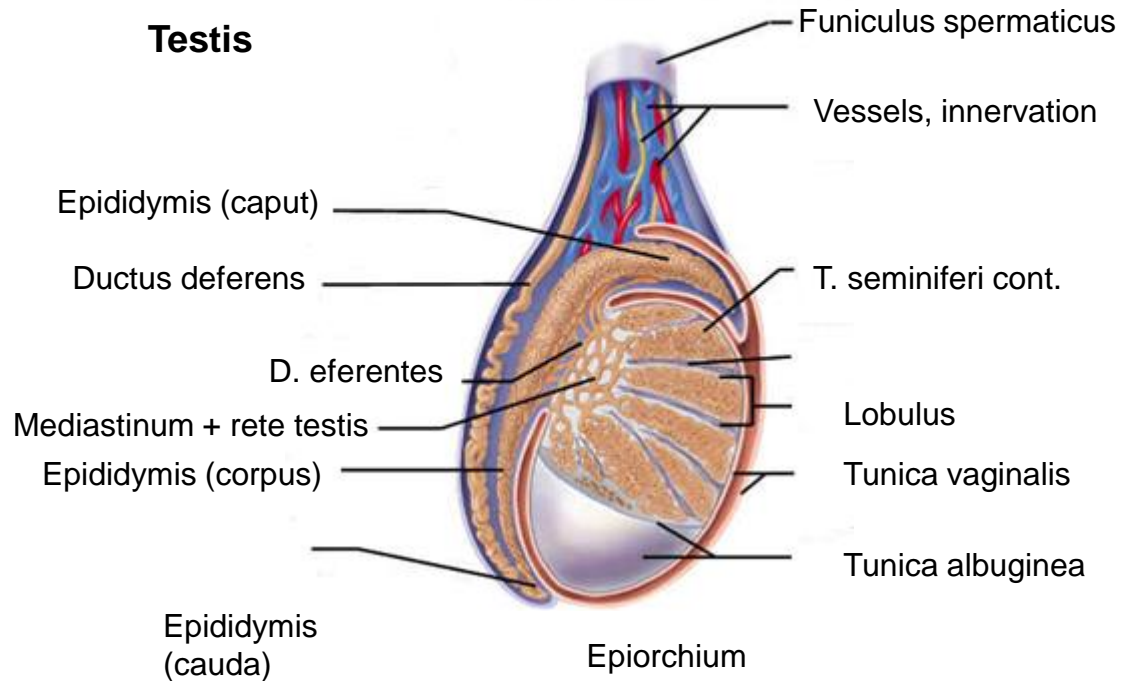
- Rete testis

## septula testis

- Lobuli testis

## Interstitial connective tissue

- Loose collagen connective tissue
- Tubuli seminiferi contorti
- Vessels, nerves, Leydig cells



Periorchium

Fascia spermatica interna

M. cremaster

Fascia spermatica externa

Connective tissue

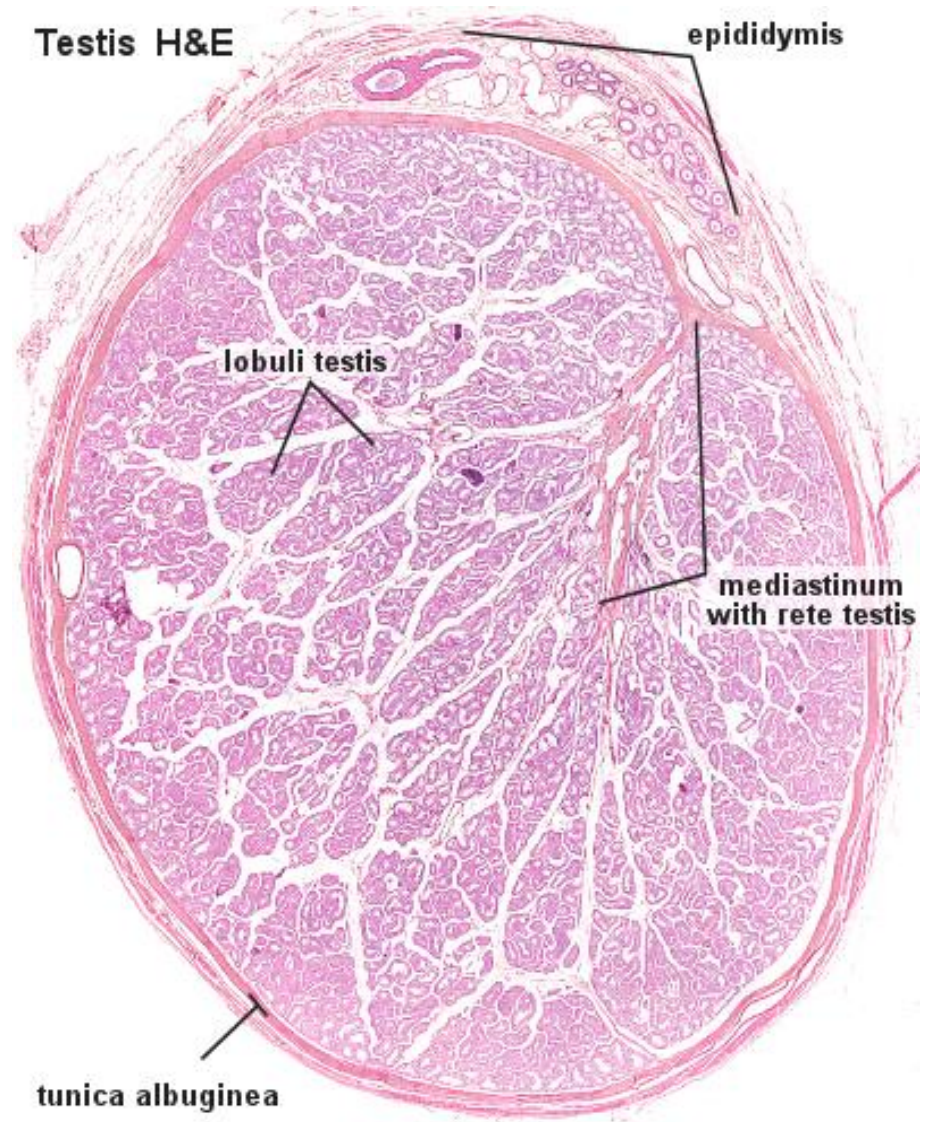
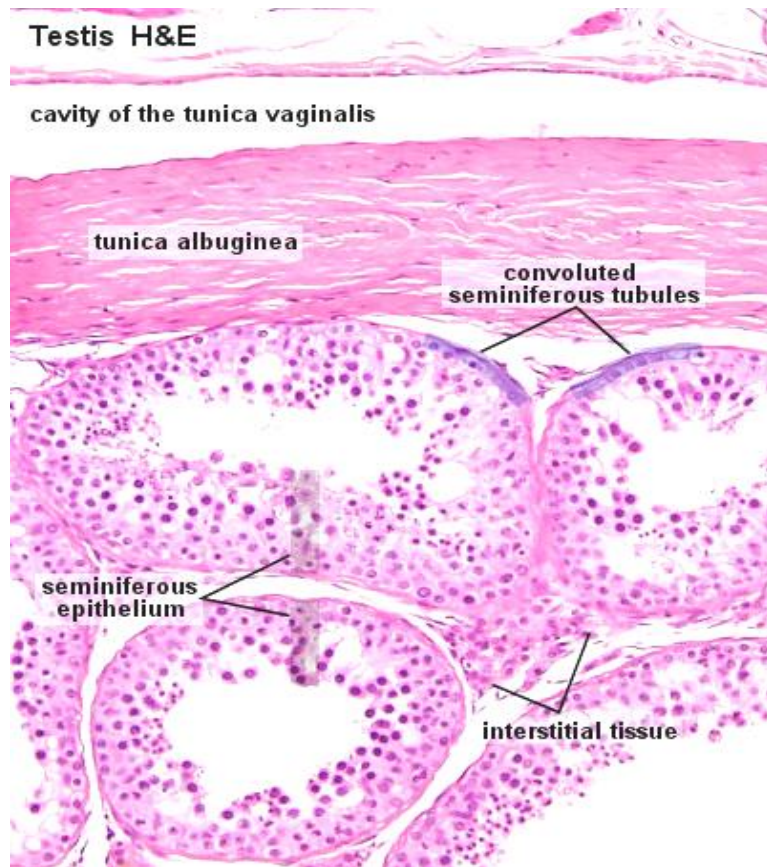
Skin

**Scrotum**

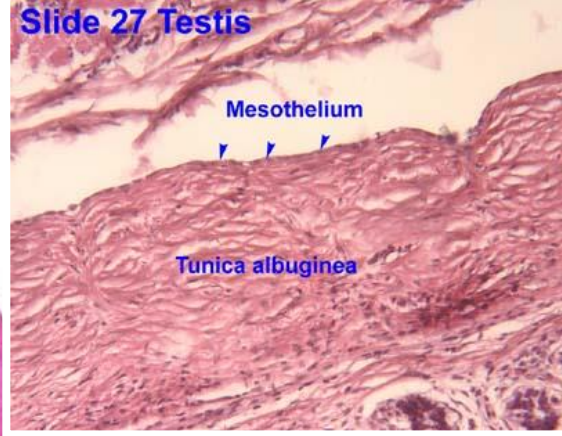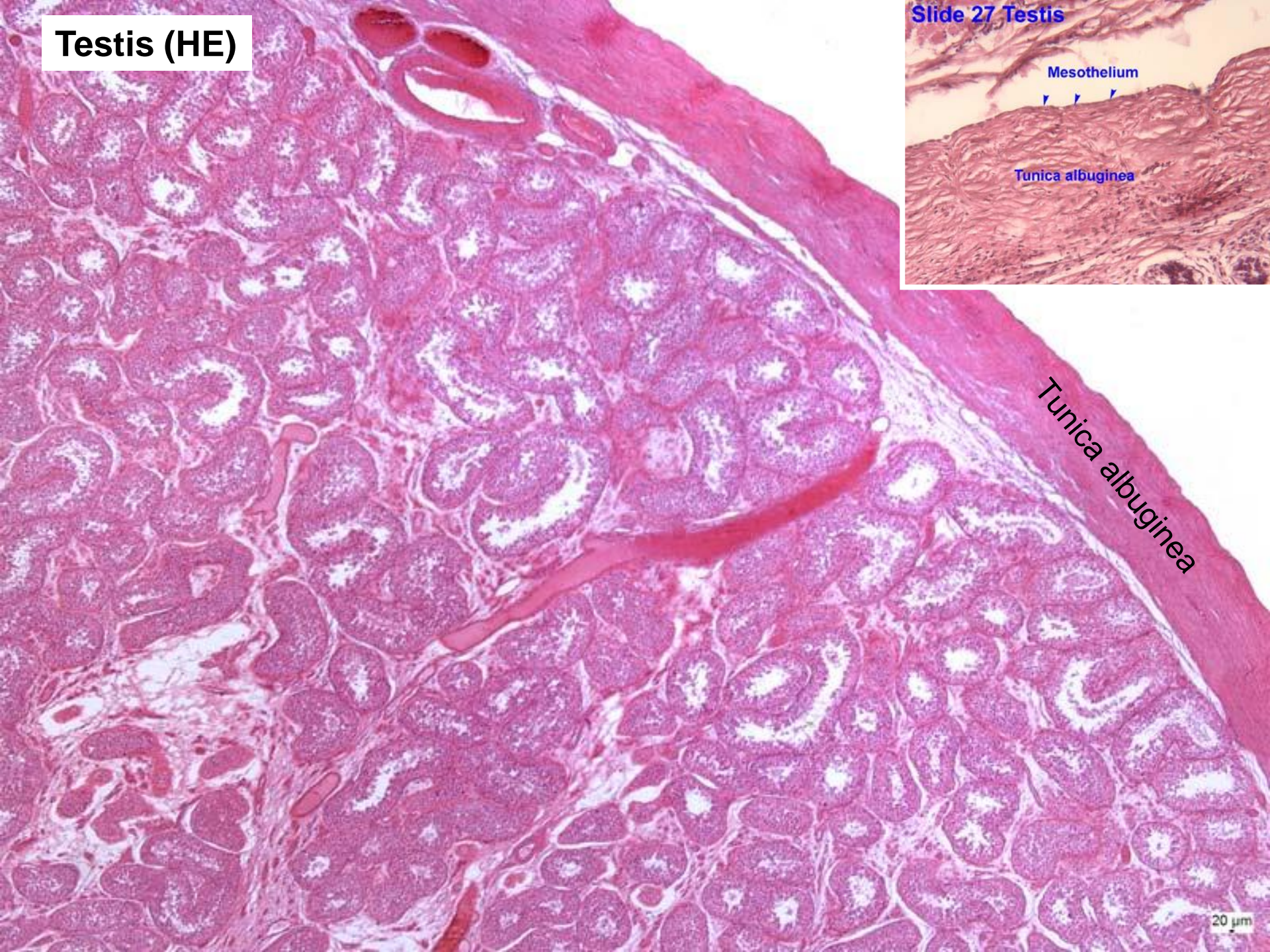
# Testis

## Parenchym

- tubuli seminiferi contorti



# Testis (HE)

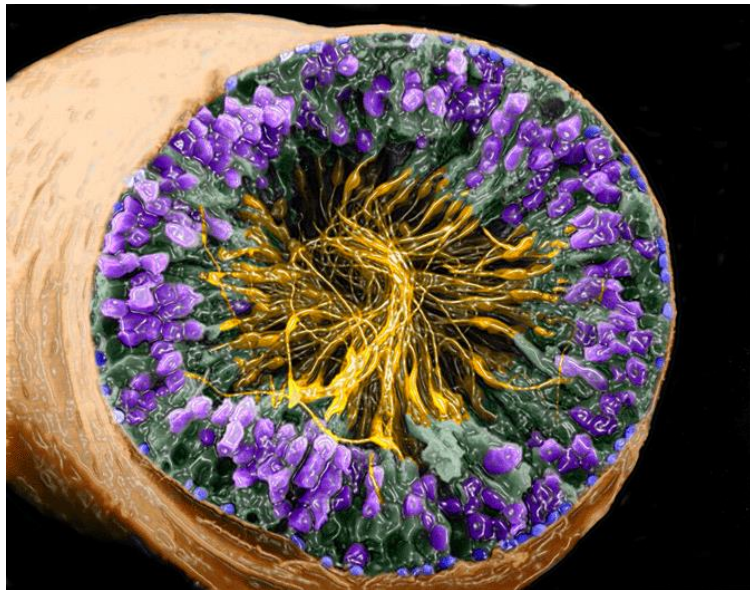


Tunica albuginea

**tubuli seminiferi contorti:**

- spermatogenic epithelium:
  - Sertoli cells
  - semen cells
- membrana propria

**interstitium:** Leydig cells



**Testis H&E**

Leydig cells

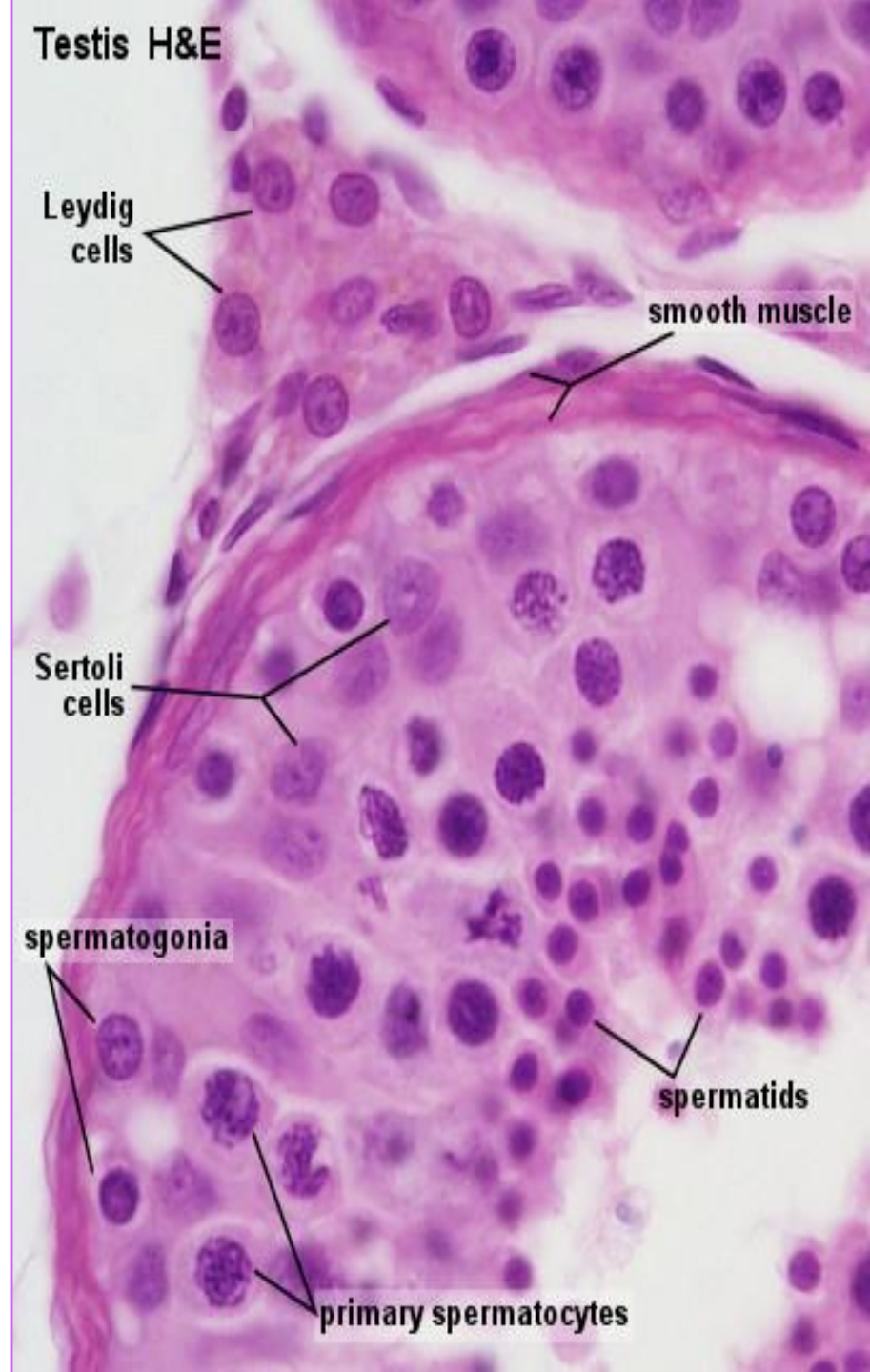
smooth muscle

Sertoli cells

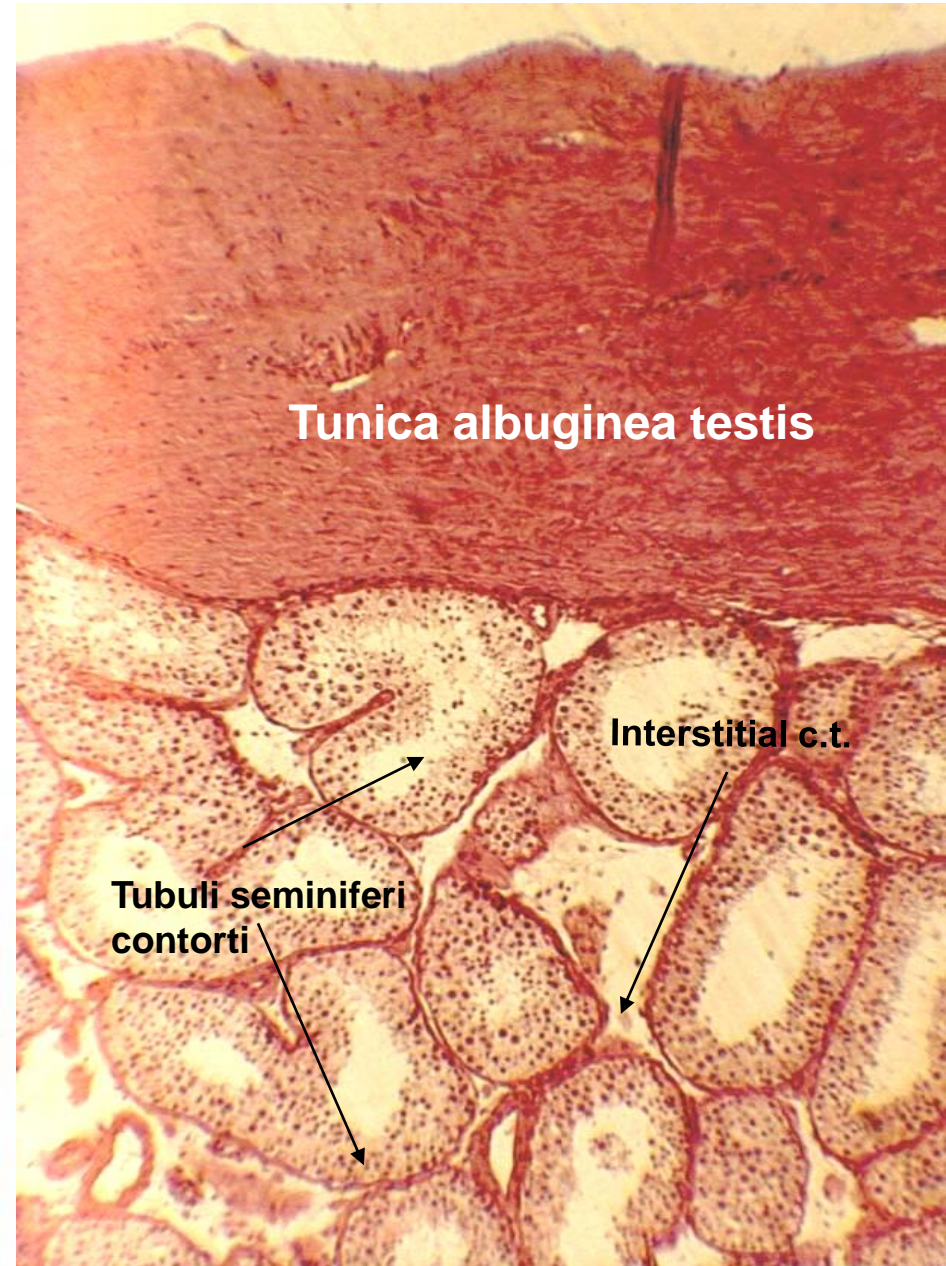
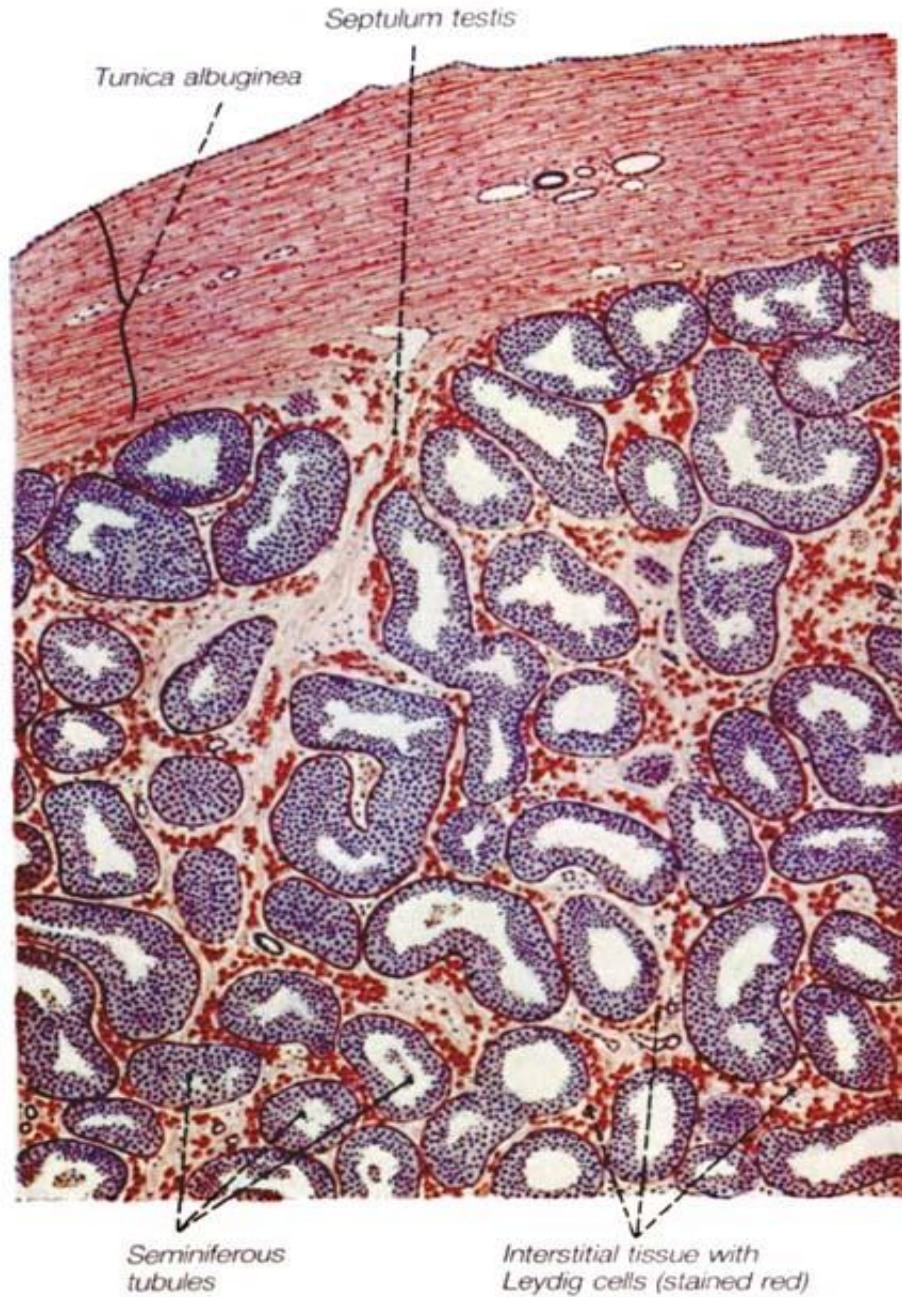
spermatogonia

spermatids

primary spermatocytes



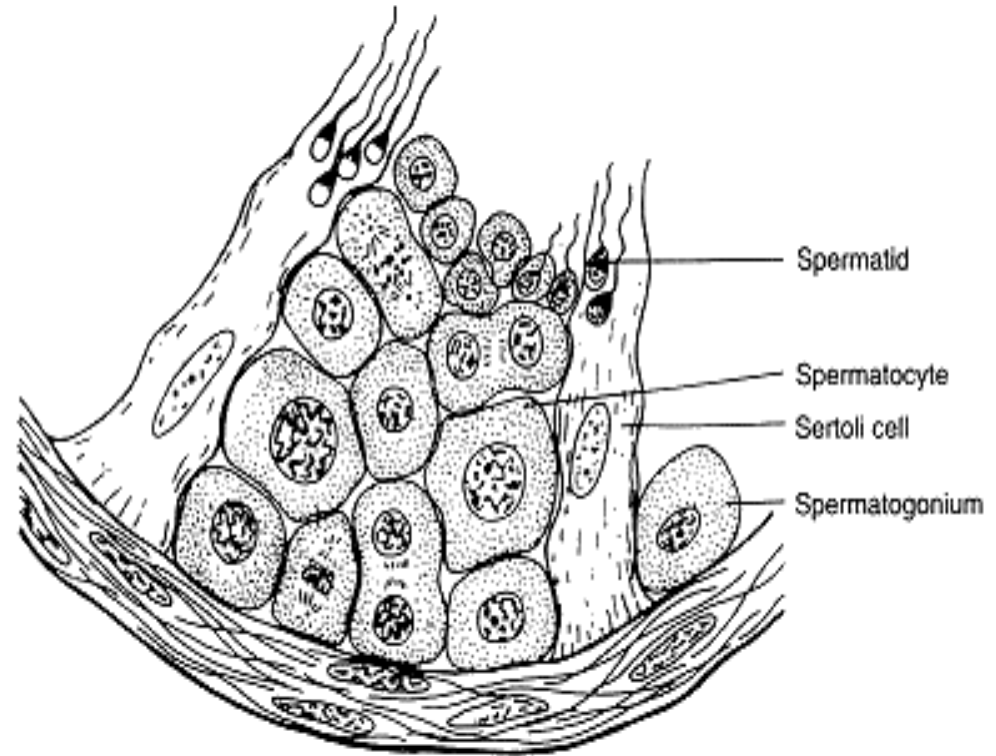
mesothelium



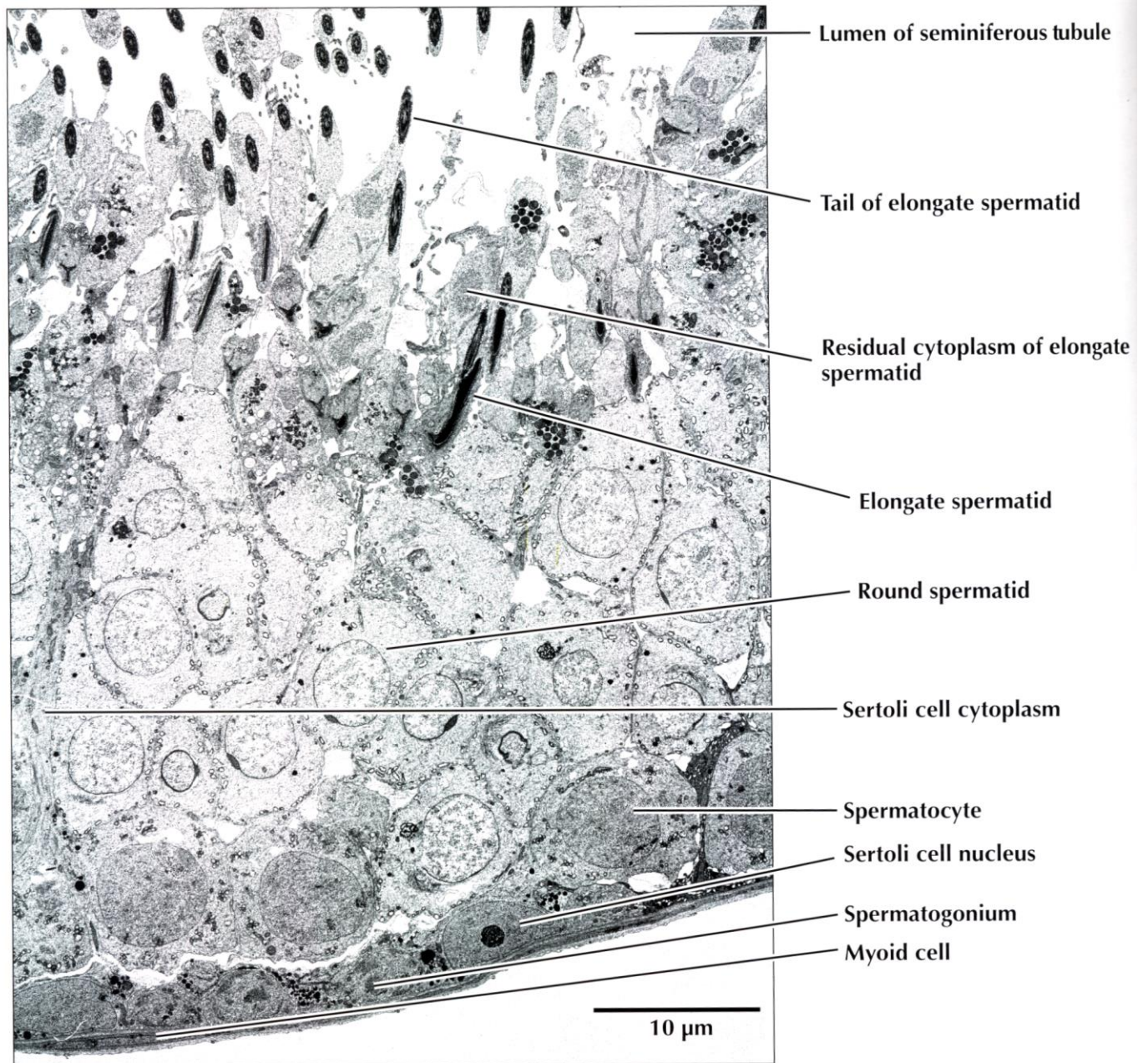
# Tubuli seminiferi contorti

150-250 $\mu$ m; 30-70cm

- spermatogenic epithelium,
  - Two cell populations
    - Germ cells in spermatogenesis
    - Sertoli cells
- tunica propria
  - loose network of elastic and collagen fibers and cells

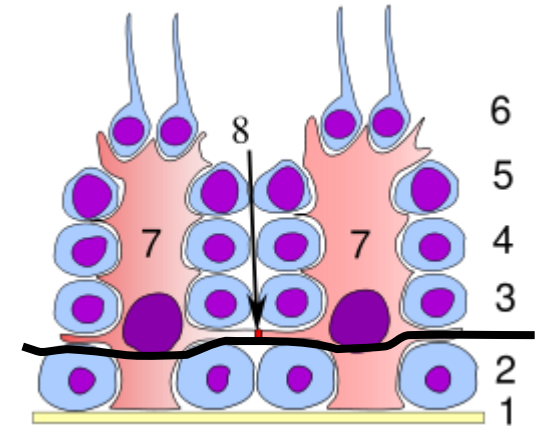
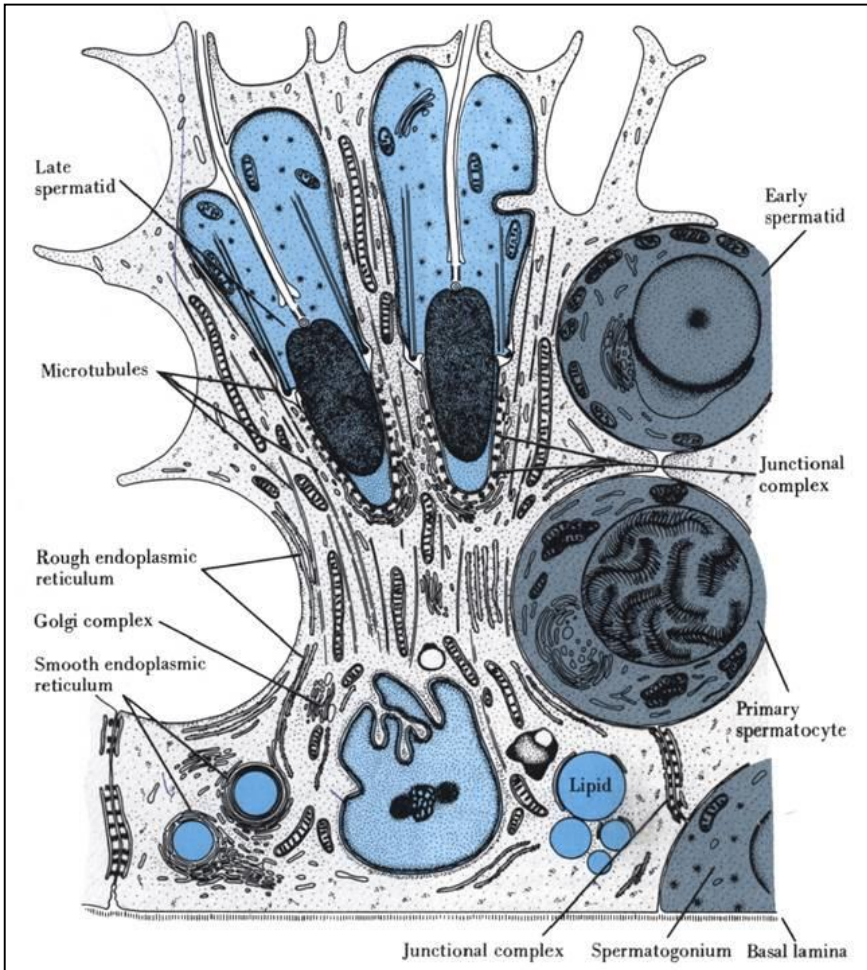






▲ **Panoramic electron micrograph (EM) of the seminiferous epithelium.** Ultrastructural features of germ cells at different stages of development and their relationship to Sertoli cells in the wall of the seminiferous tubule are clear. Myoid cells surround a thin outer capsule. 2500×. (Courtesy of Dr. B. J. Crawford)

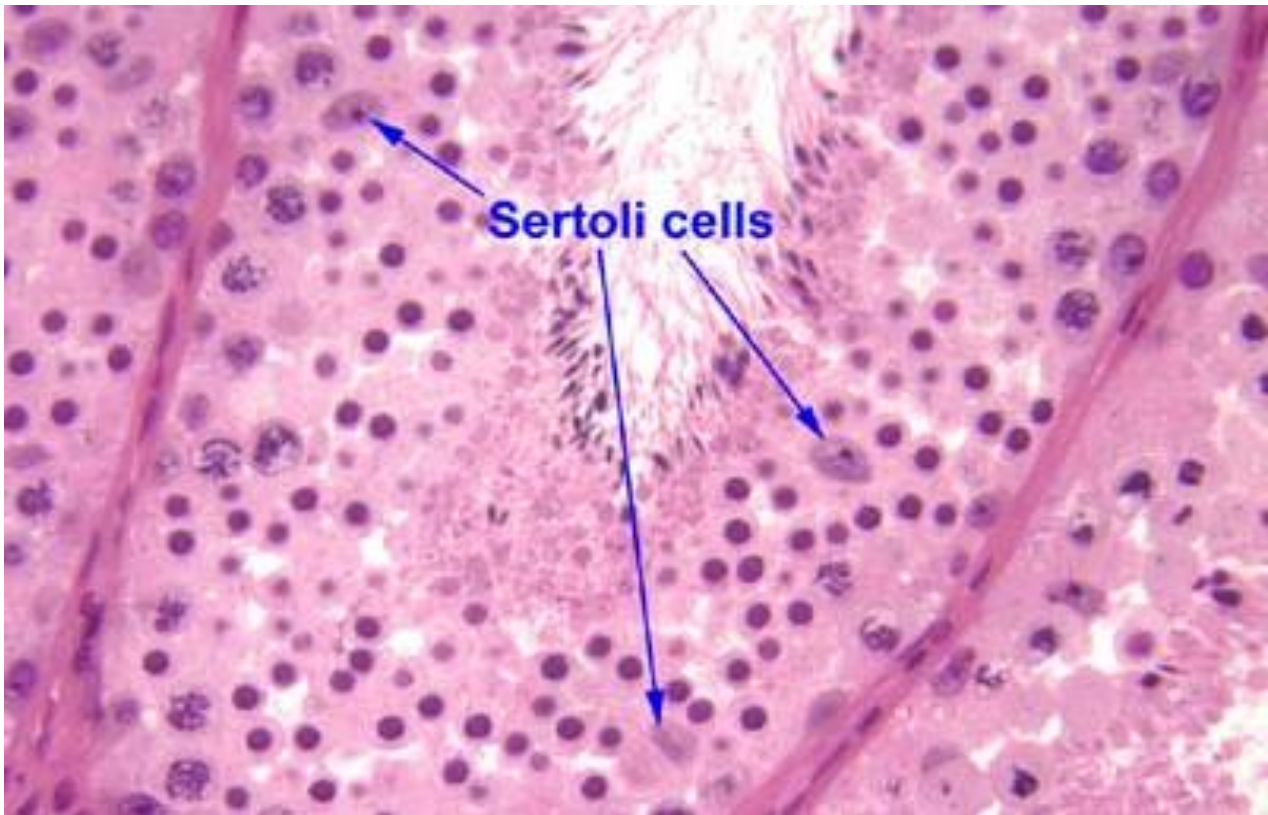
# Sertoli cells:



- Tubular epithelium
- Microenvironment for spermat- and spermiogenesis
- Complex 3D architecture
- Hematotesticular barrier - basal and adluminal compartment

## Function:

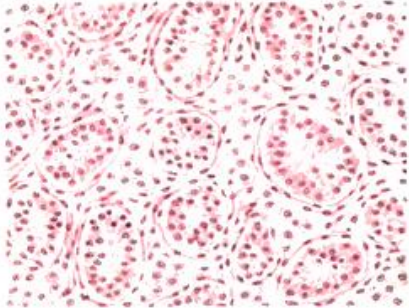
- support
- nutritive
- secretion + endocrine (anti-Müllerian hormon, inhibin, androgen-binding protein)
- phagocytosis



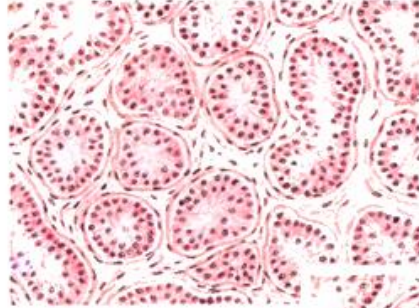
Sertoli cells

Oval nucleus, nucleolus  
Basal part of spermatogenic  
epithelium

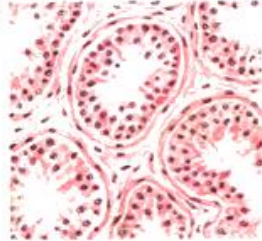
Neonatal testis



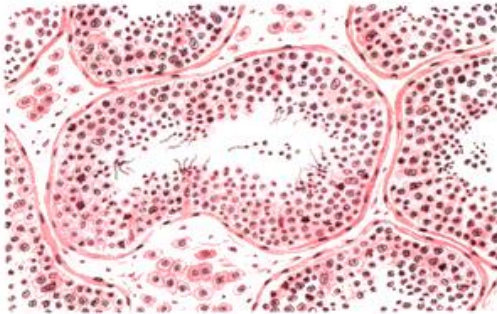
Infantile testis



Late prepubertal testis

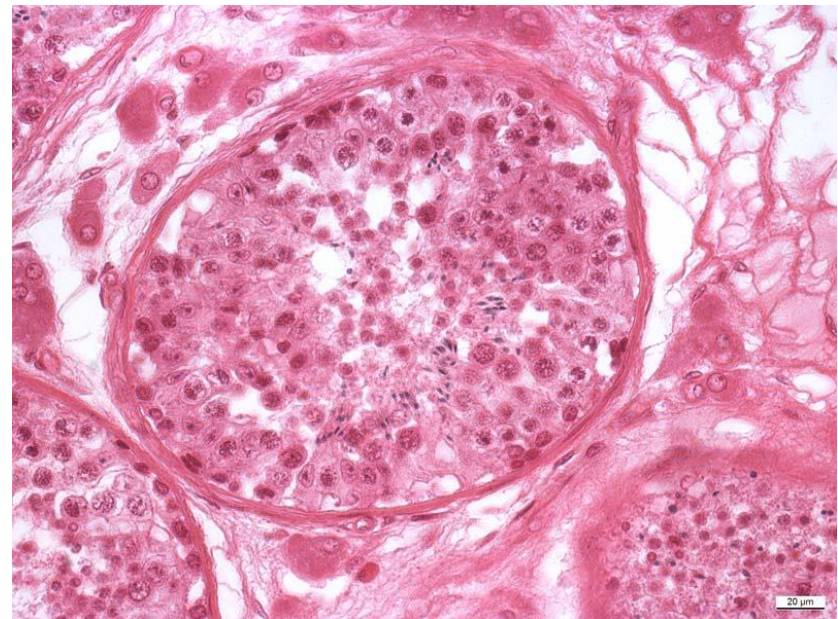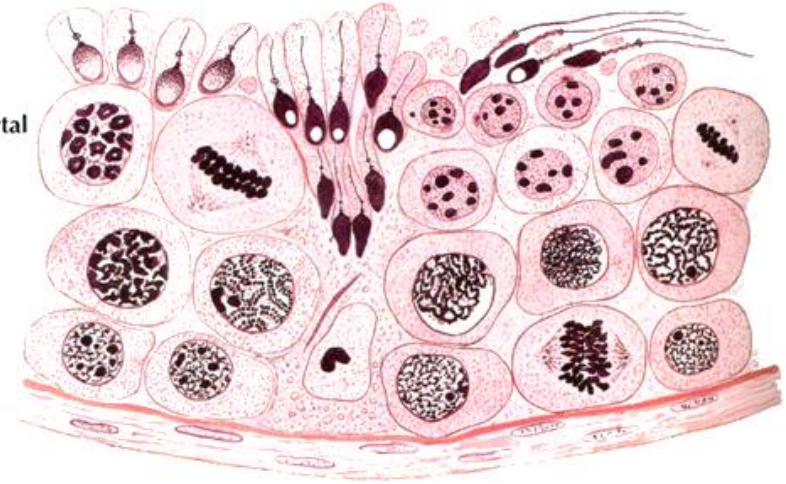


Adult testis



*F. Netter M.D.*

Seminiferous epithelium



20 µm

Genital ridge – colonized by primordial germ cells (gonocytes, epiblast)

Medullary cords (coelomic epithelium, mesonephros)

Lumen, tubuli s. contorti

Sertoli cells - epithelium of medullary cords

SRY

AMH

Androgens

# Spermatogenesis:

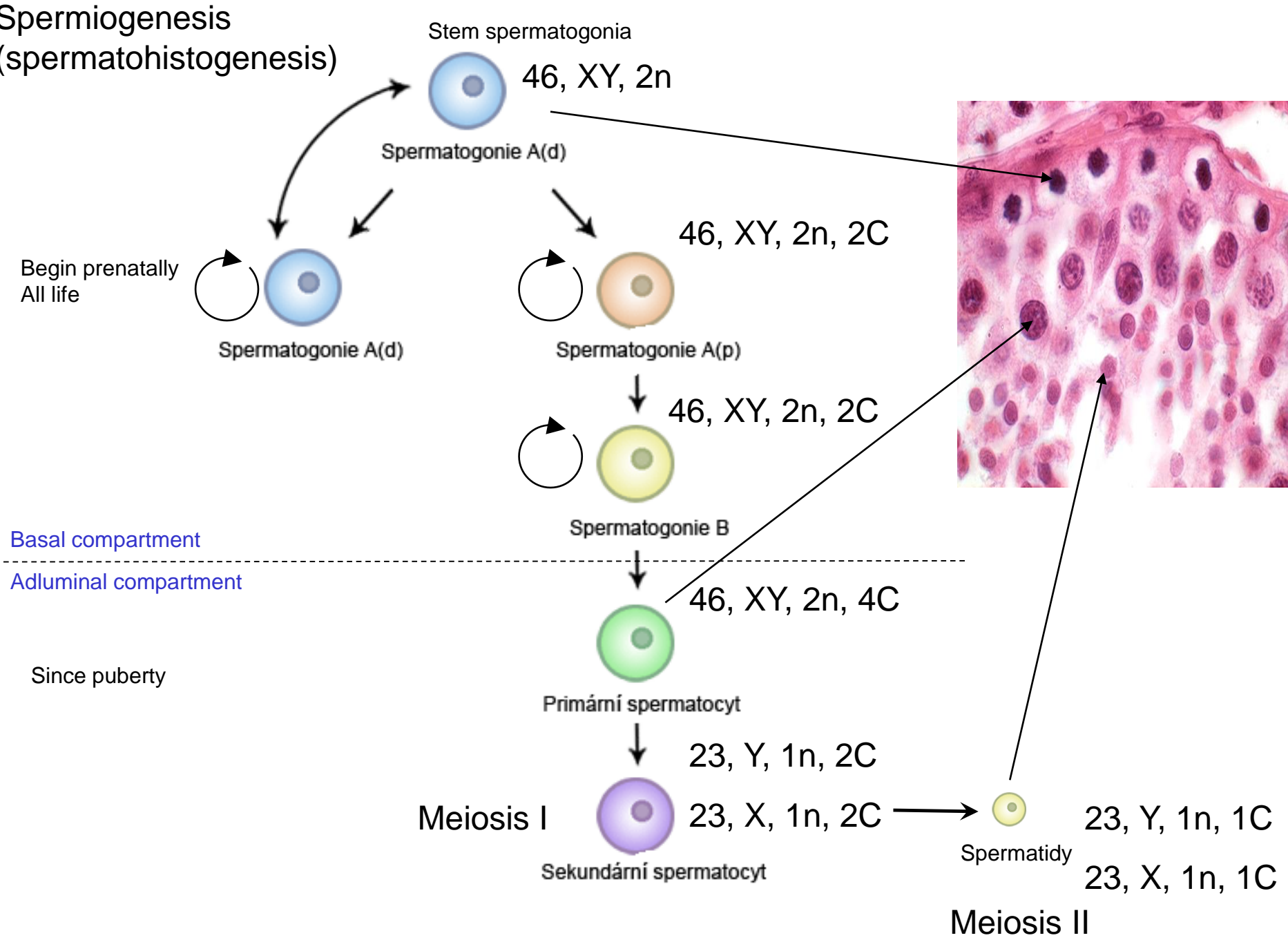
- spermatogenesis (spermatocytogenesis)

spermatogonia (type A / B) **diferentiation** of primary spermatocytes

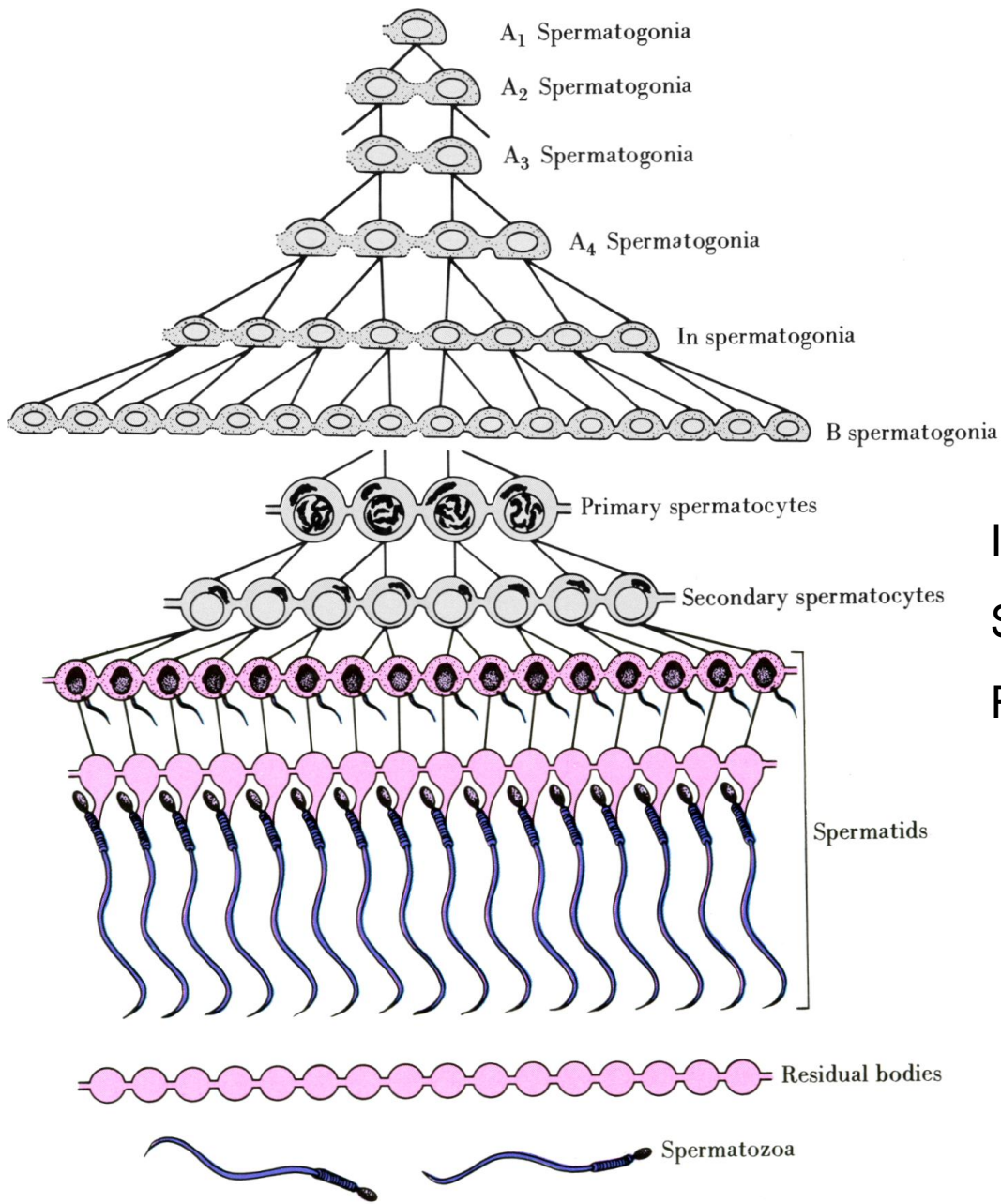
- meiosis I → secondary spermatocytes, meiosis II → spermatids

- spermiogenesis (spermatohistogenesis) **maturation** – morfological maturation of spermatids to sperms

# Spermiogenesis (spermatohistogenesis)

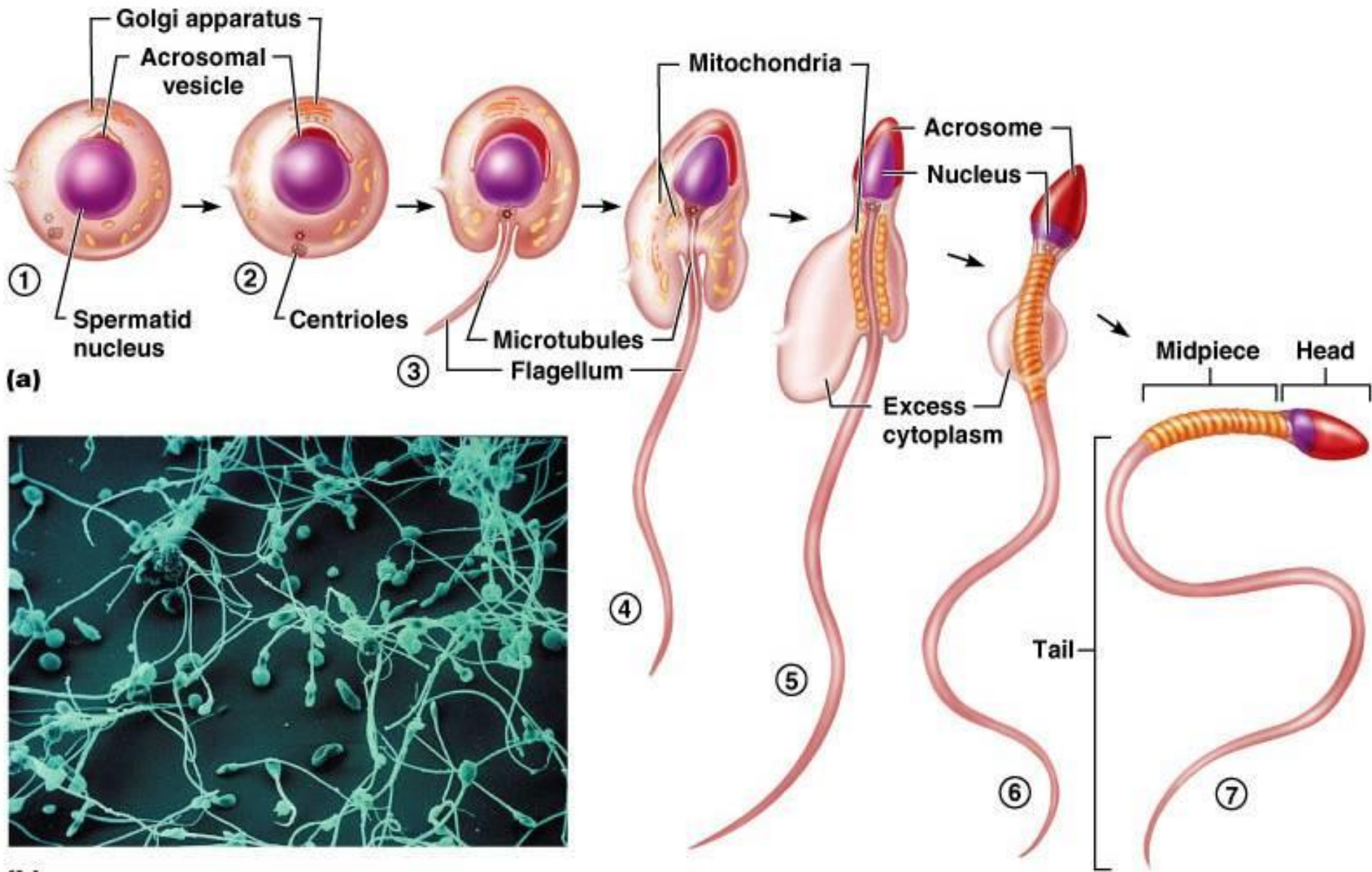


# Spermatogenesis (spermatocytogeneze)



Intercellular bridges  
Spermiation  
Residual bodies

# Spermiogenesis: spermatids to *sperms*



**(b)**



## Spermatogenesis

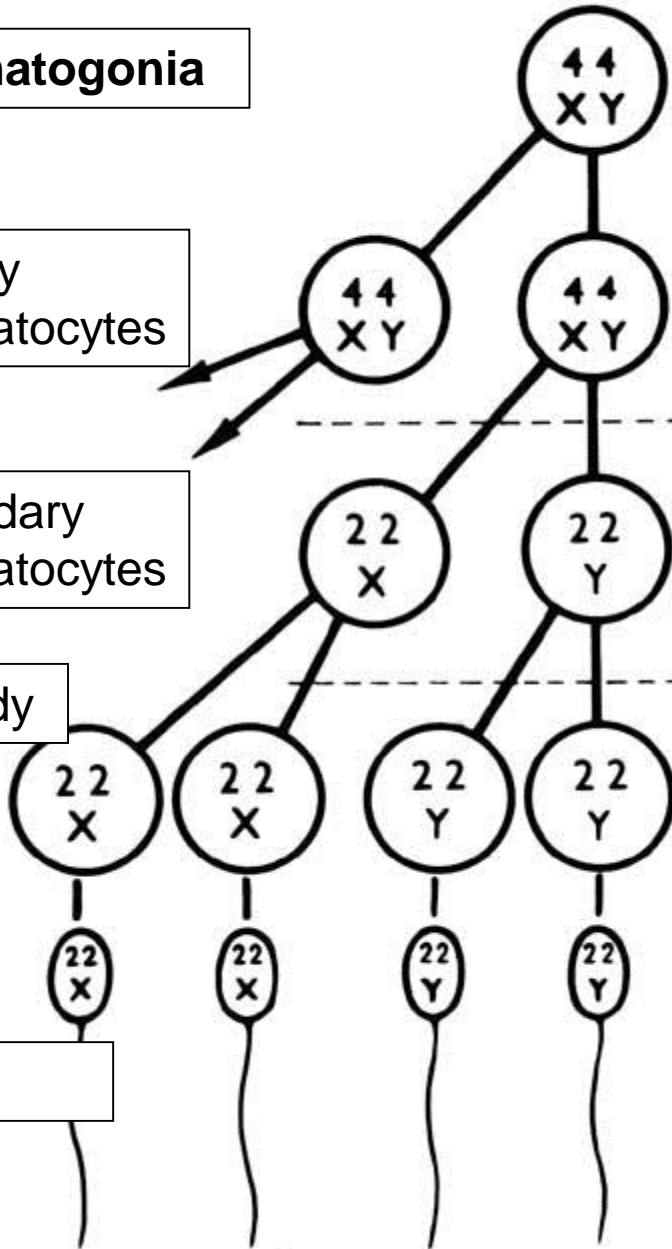
Spermatogonia

Primary spermatocytes

Secondary spermatocytes

Spermatidy

Sperm



## Oogenesis

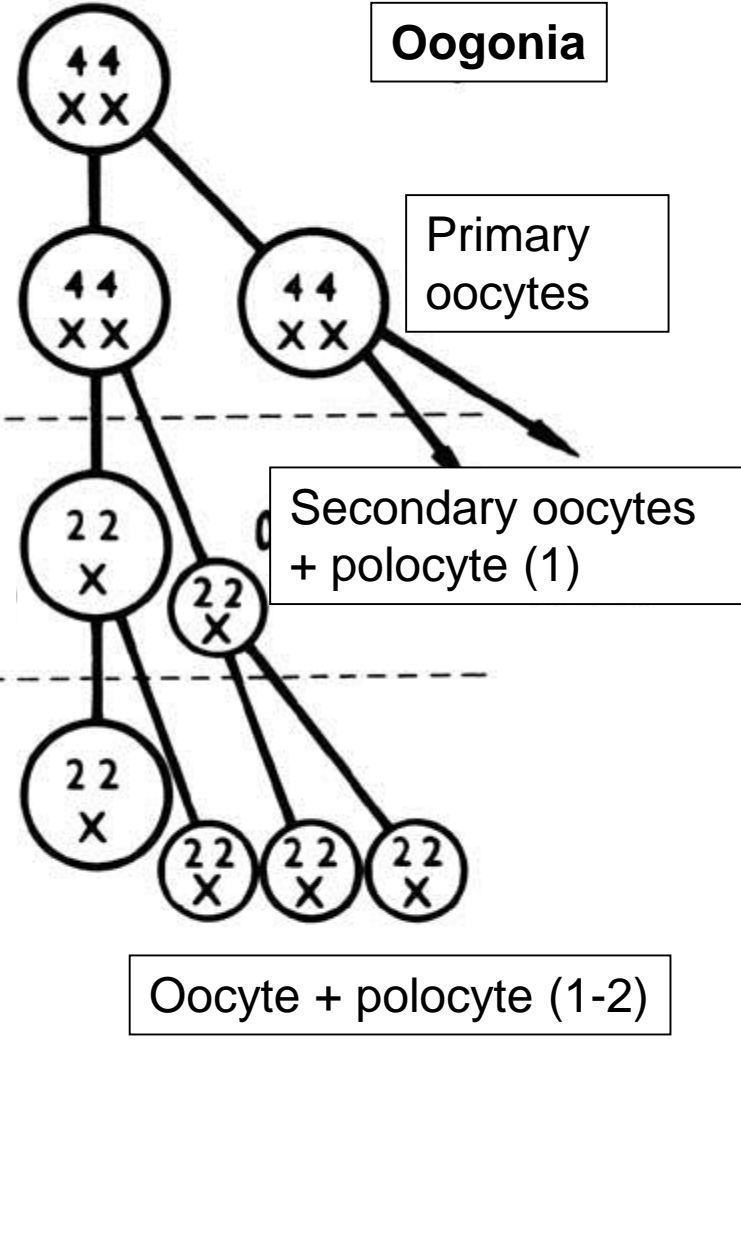
Oogonia

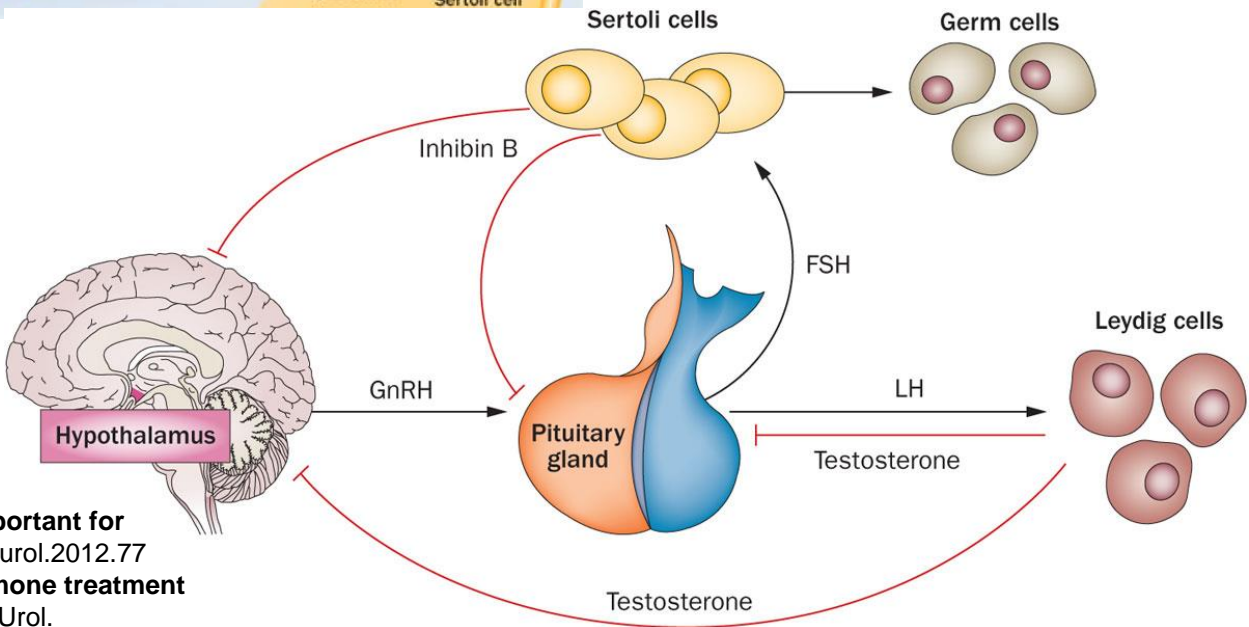
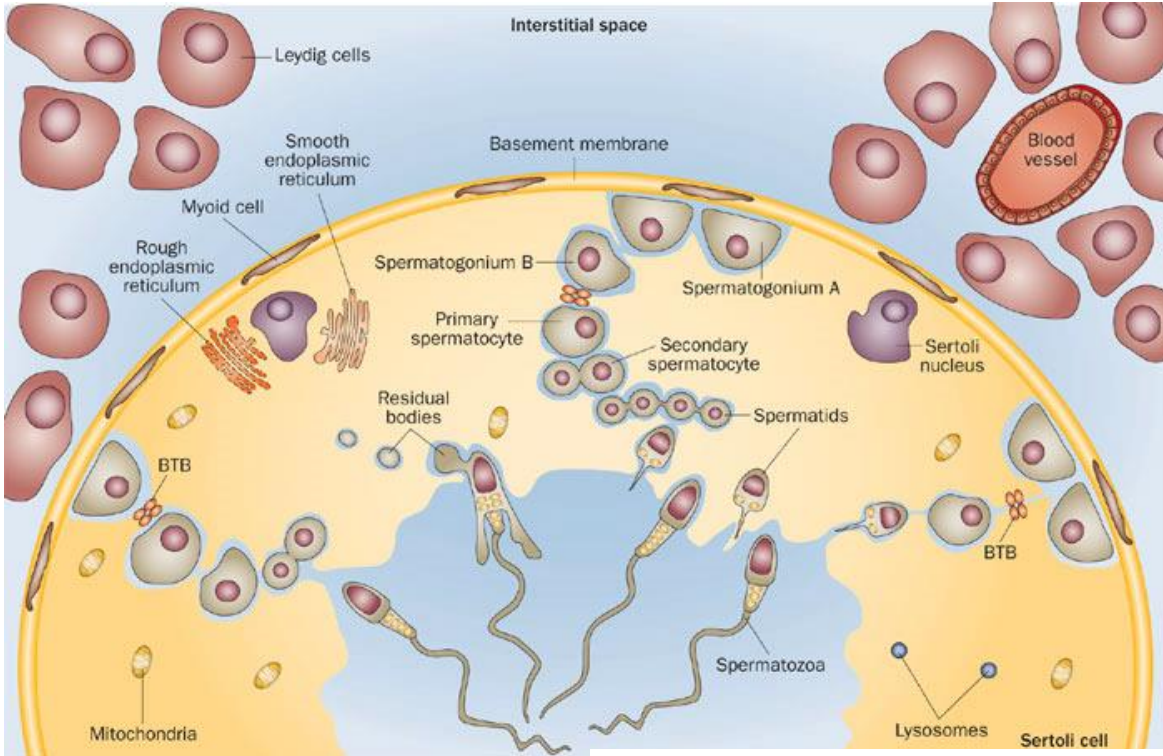
Primary oocytes

Secondary oocytes + polocyte (1)

Oocyte + polocyte (1-2)

MEIOSIS

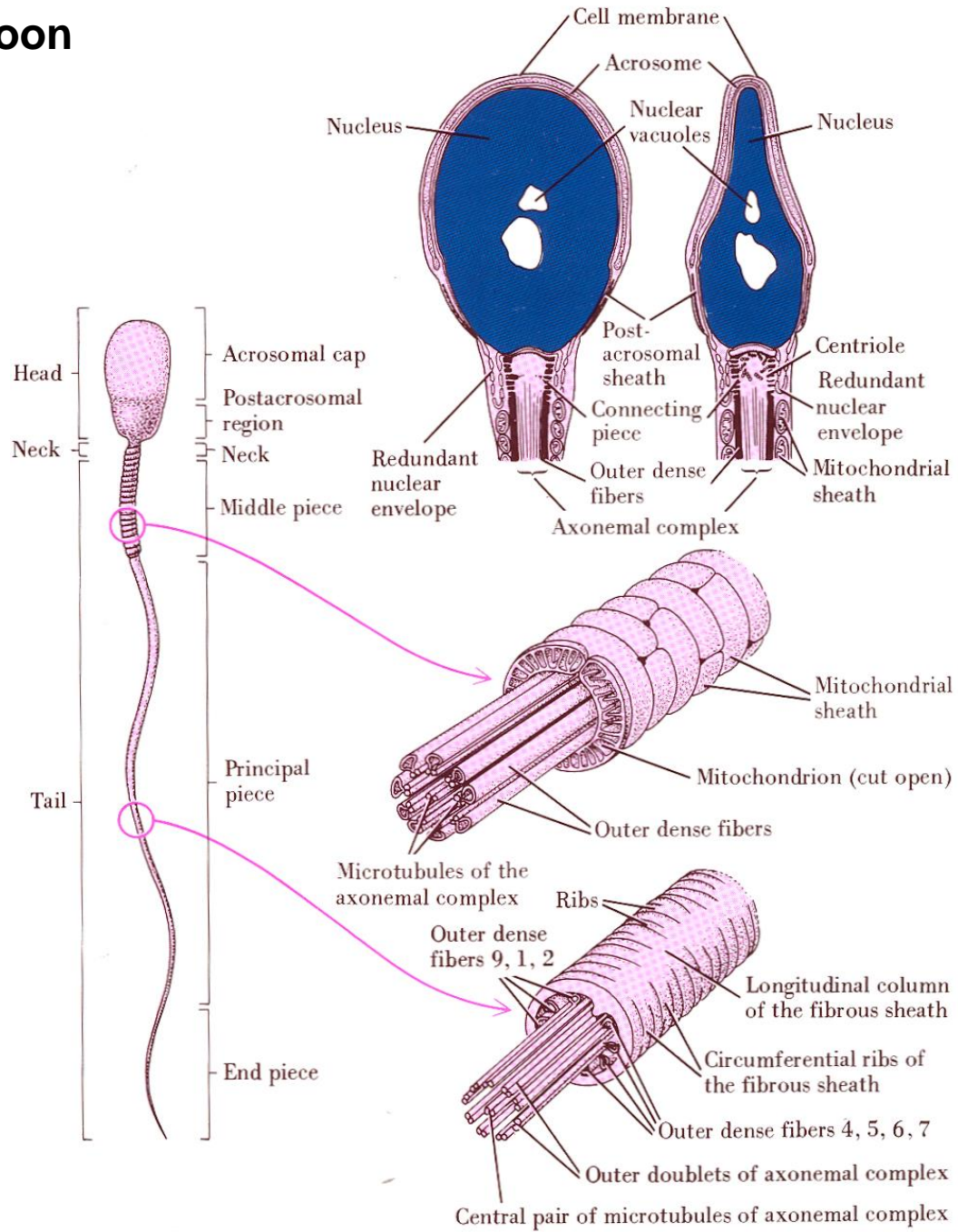


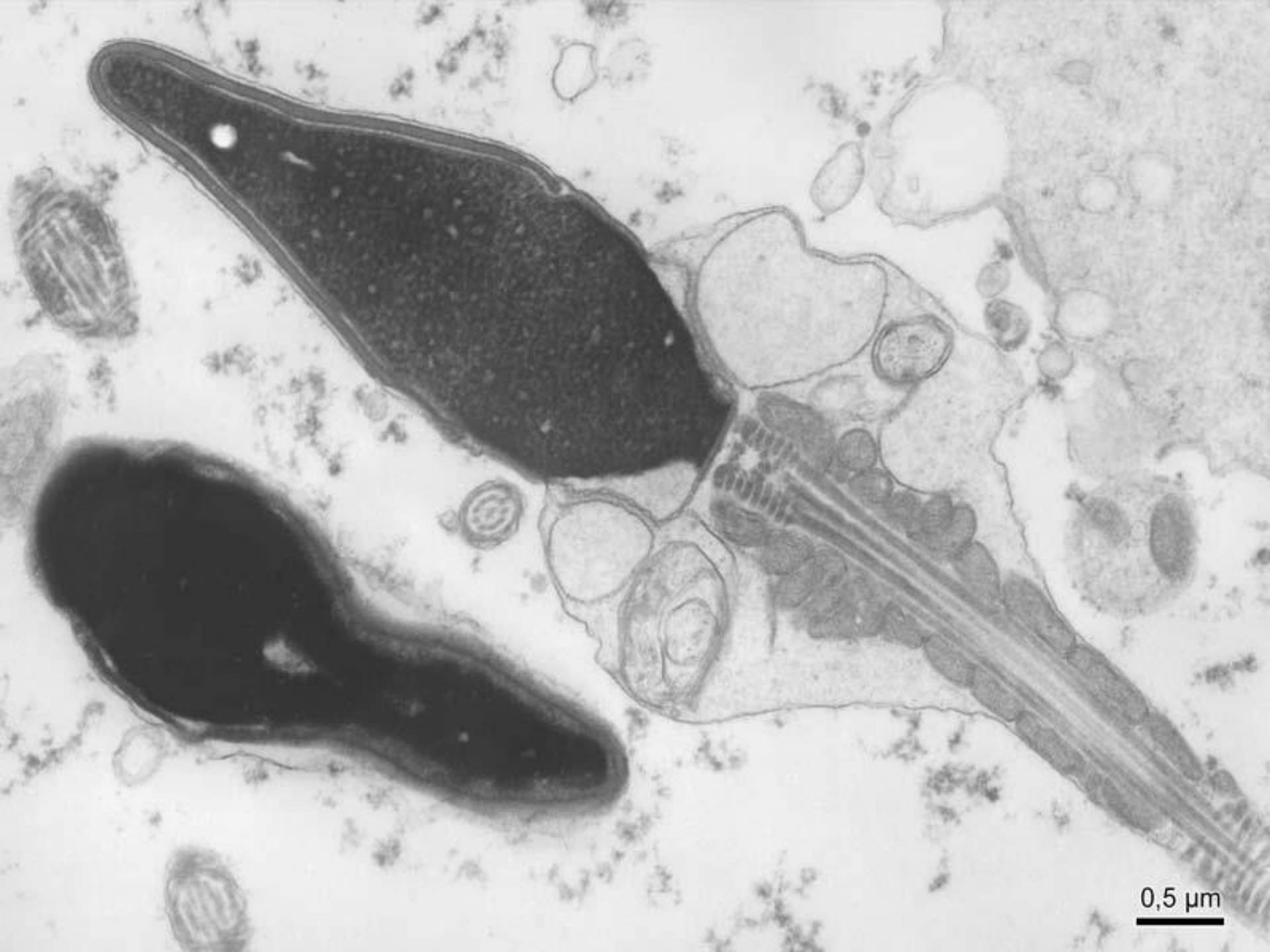


Rato, L. *et al.* (2012) **Metabolic regulation is important for spermatogenesis.** *Nat. Rev. Urol.* doi:10.1038/nrurol.2012.77

Valenti, D. *et al.* (2012) **Follicle-stimulating hormone treatment in normogonadotropic infertile men.** *Nat. Rev. Urol.* doi:10.1038/nrurol.2012.234

# Human spermatozoon

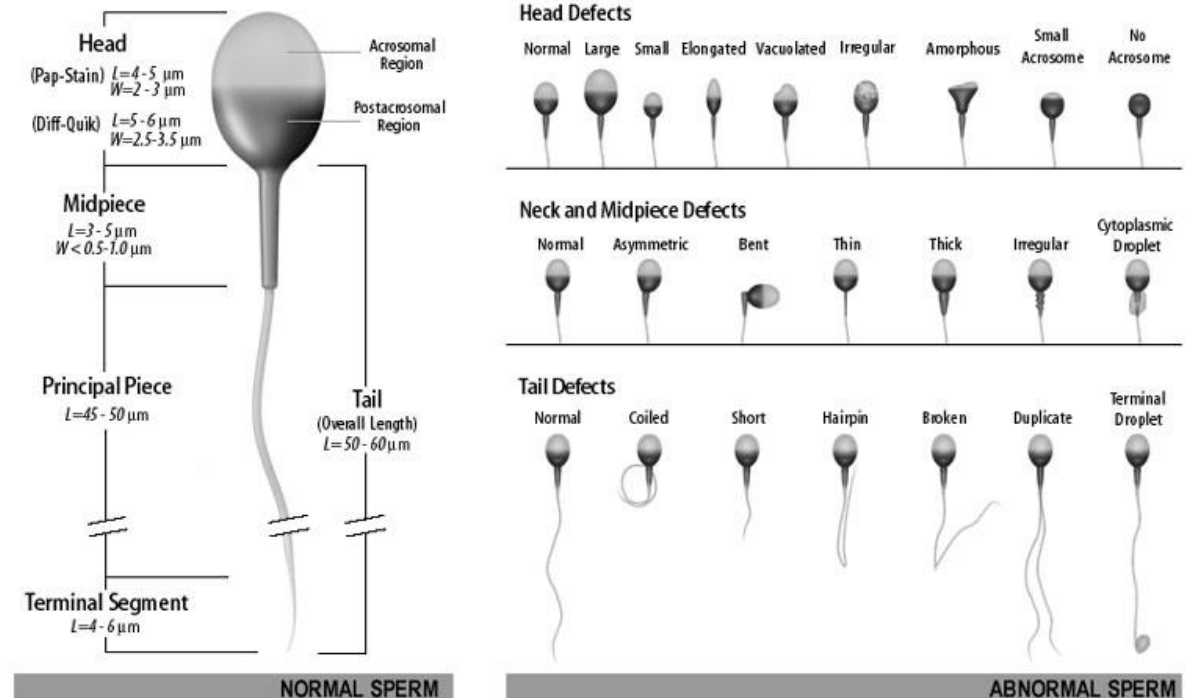




0,5 μm

# Normal values of spermogram (normospermy) according WHO

- Volume of ejaculate: 2 - 4 ml
- pH: 7,2-7,8
- concentration: min. 20 mil. sperms/1ml ejaculate
- motility: min. 50 % motile, - 25 % quick and progressive
- morphology: min. 30 % of normal sperms
- viability: min. 50 %

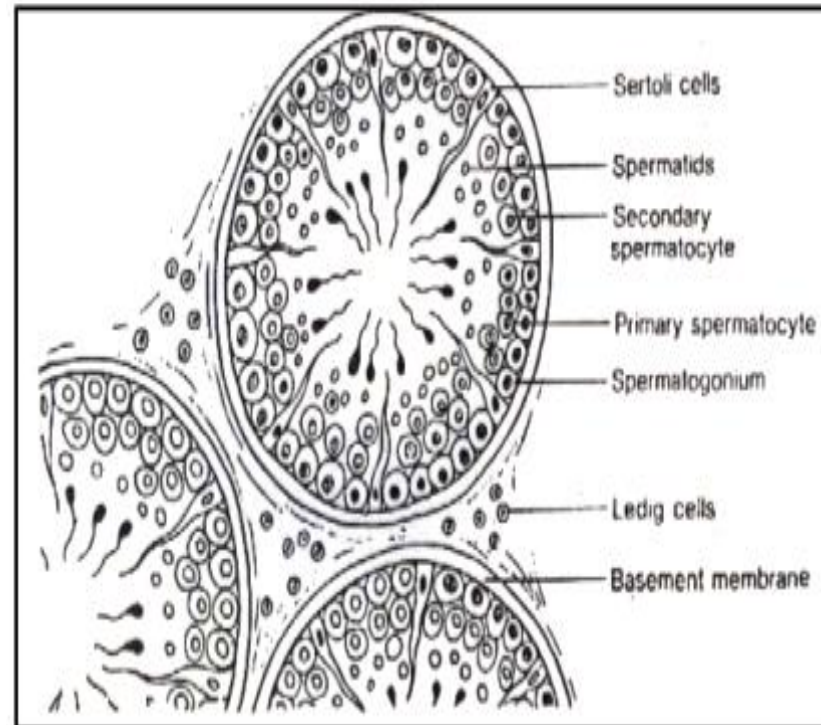


# Leydig cells

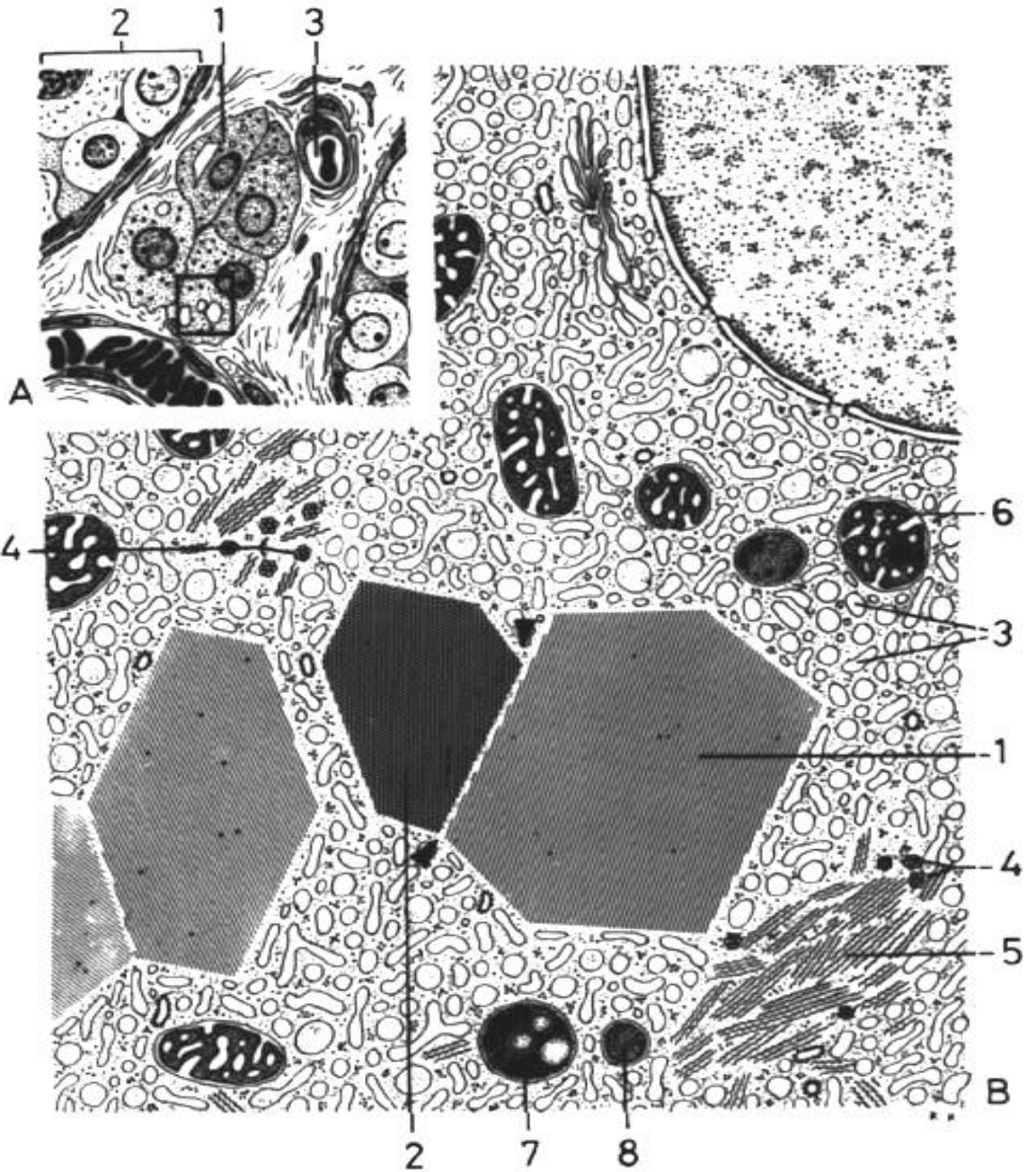
- *Steroidogenic cells*

Round- oval, large, acidophilic, mitochondria with tubular crists, AER, lipid droplets

- Synthesis and secretion of testosterone
- Interstitial connective tissue
- Reinke crystals



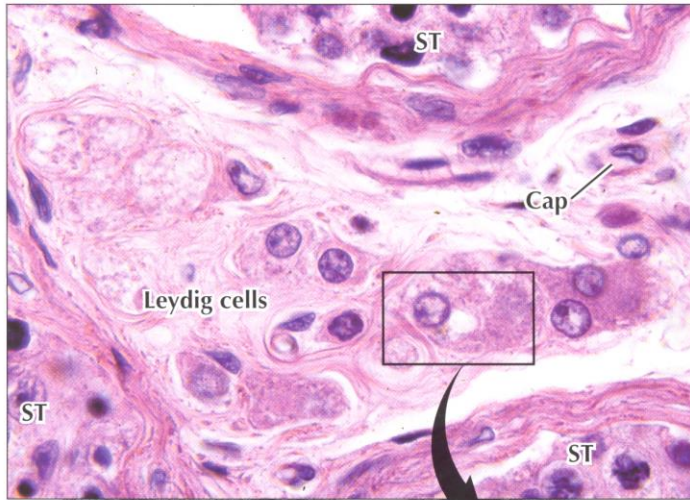
# Ultrastructure of a Leydig cell



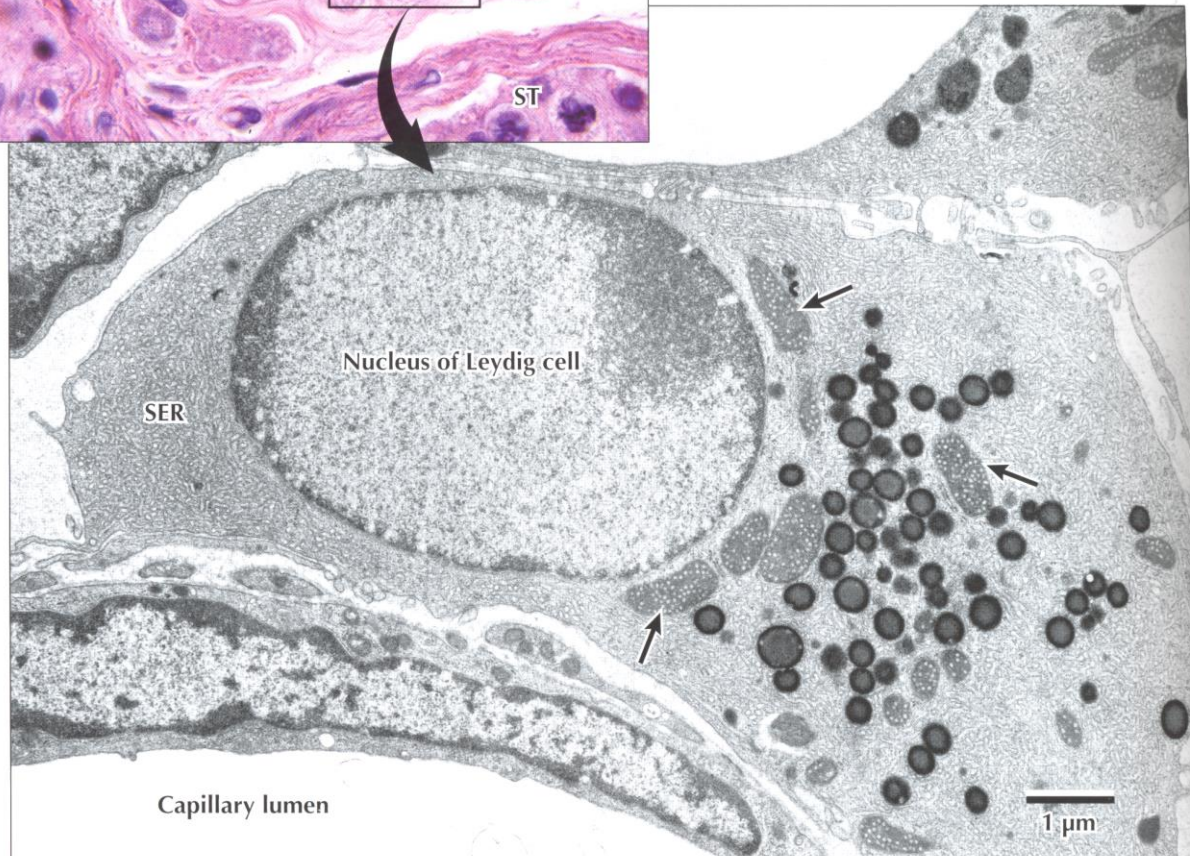
## Typical steroidogenic cell:

- mitochondria with tubules
- AER
- Lipid droplets

(inclusion - crystals)



◀ **LM of a clump of Leydig cells.** Cells are lightly eosinophilic and have a foamy cytoplasm. Some cells are intimately associated with capillaries (**Cap**); others lie close to outer capsules of neighboring seminiferous tubules (**ST**), 625 $\times$ . *H&E*.





# Genital duct system

## Testes:

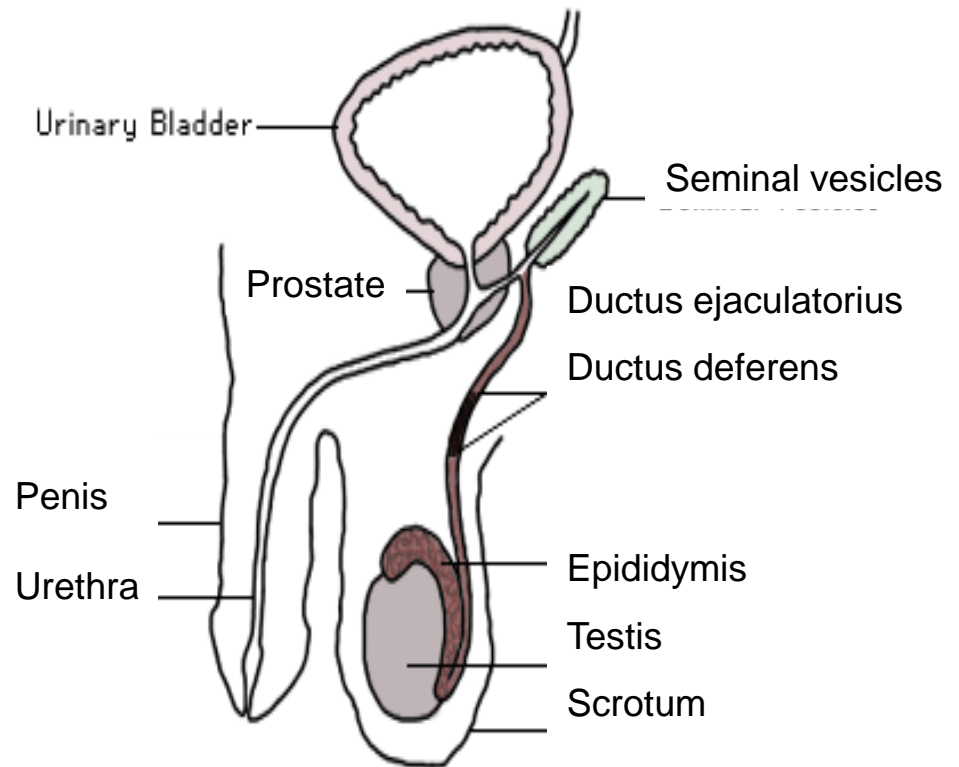
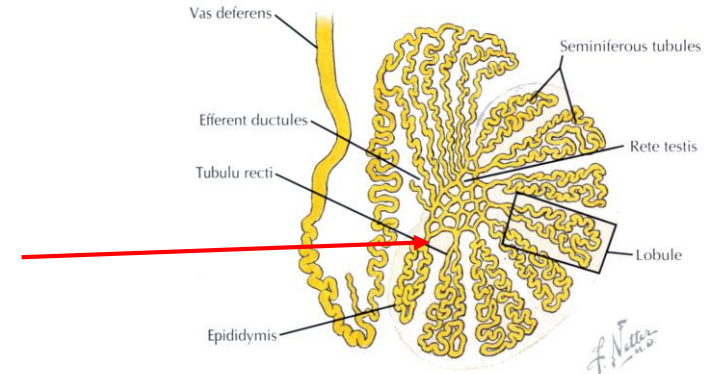
- tubuli recti
- rete testis

## Epididymis:

- ductuli efferentes
- ductus epididymidis

## Other:

- ductus deferens
- ductus ejaculatorius
- male urethra



# Epididymis

maturation (~ 2 weeks)

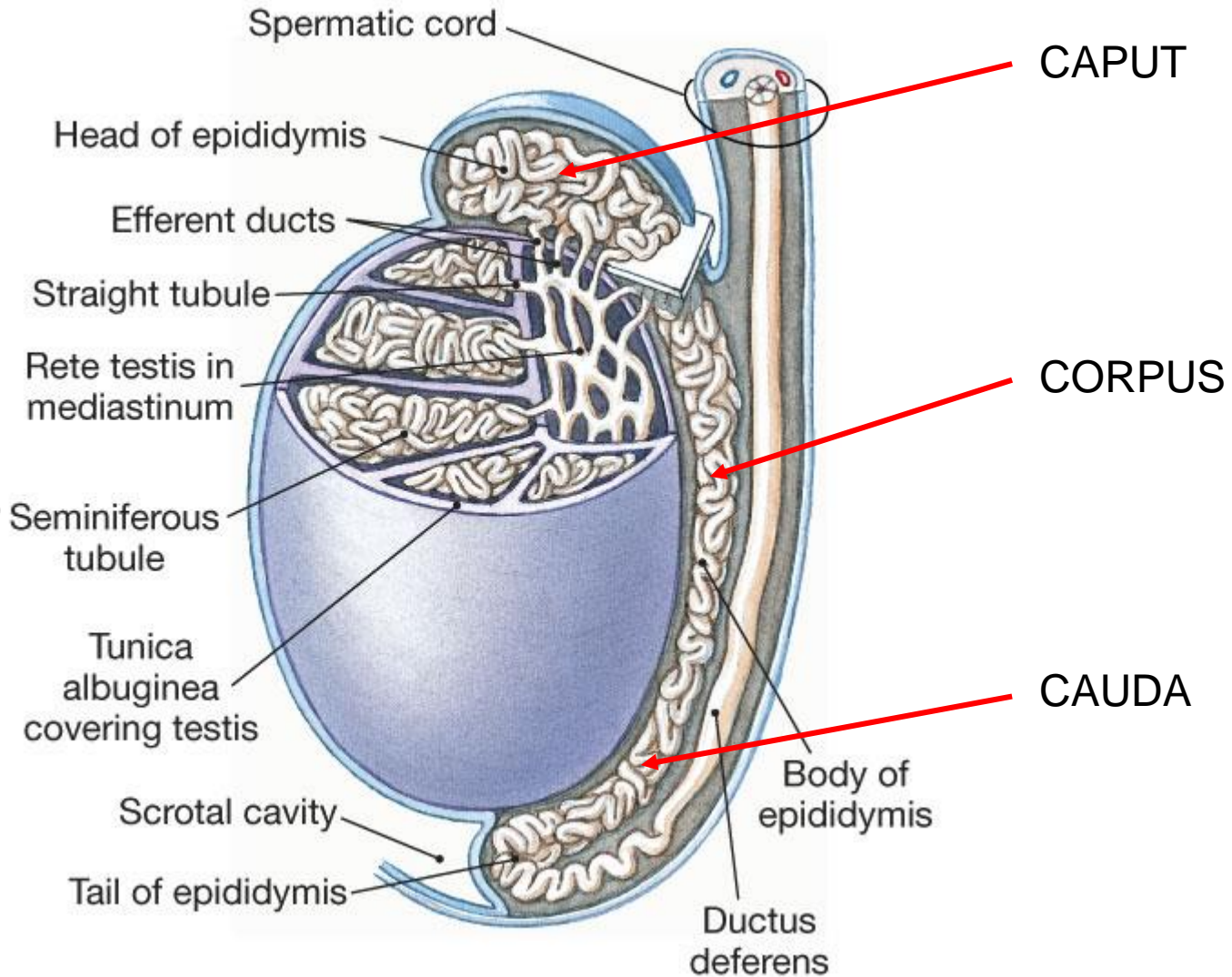
Epithelium – various morphology (cilia, microvilli)

High metabolic activity

(H<sup>+</sup> pumps, secretion of proteins, prevention of capacitation)

Myofibroblasts (caput, corpus)

Leiomyocytes (cauda)

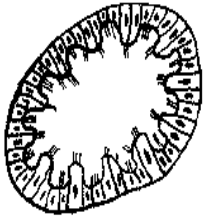

# Epididymis

connective tissue:


- capsula + septula (*caput epididymidis*),
- Interstitial connective tissue surrounding ducts.

ducts:



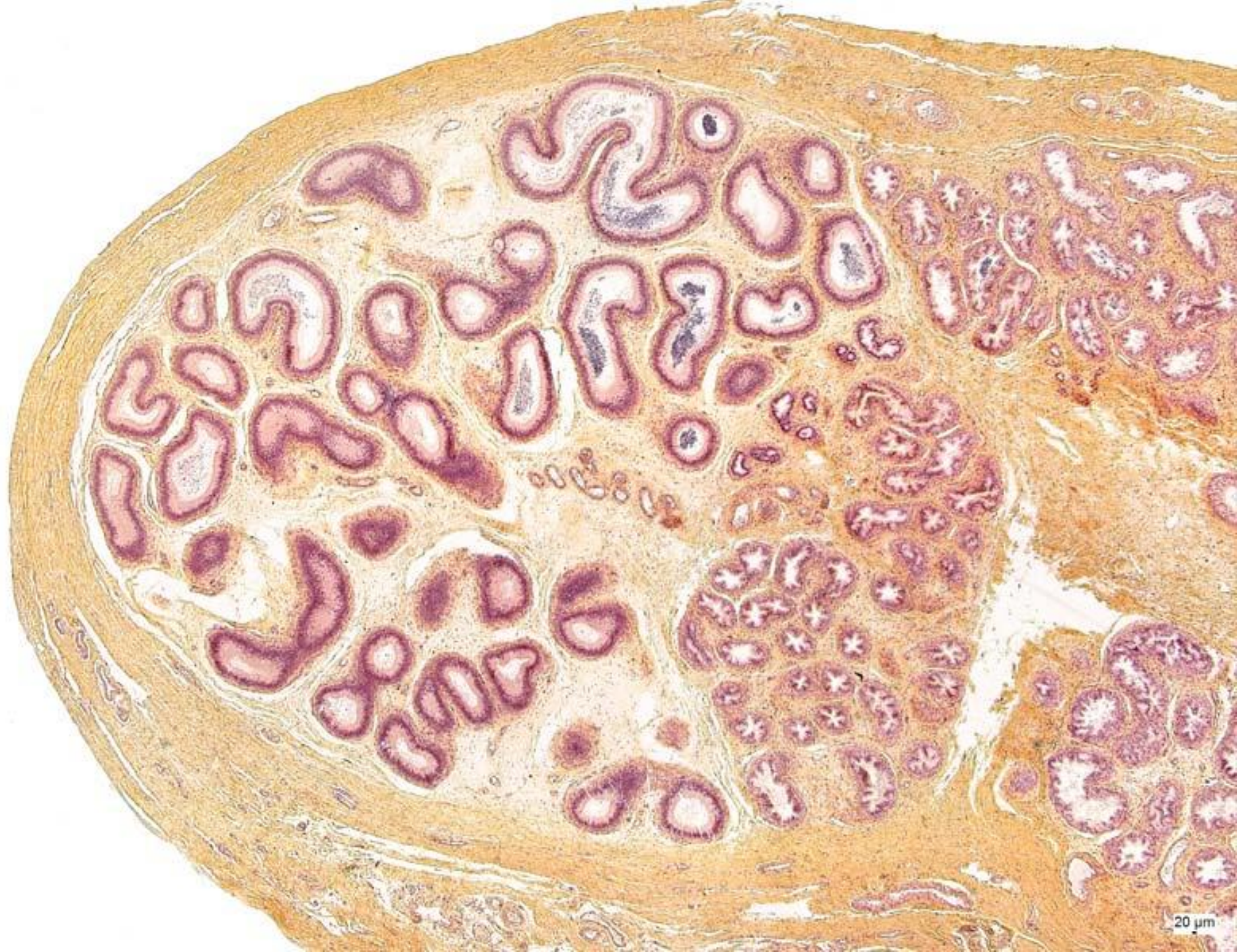ductuli efferentes - caput; irregular lumen:

- lamina epithelialis – simple cubic epithelium – occasionally ciliated
- membrana propria – loose collagen connective tissue

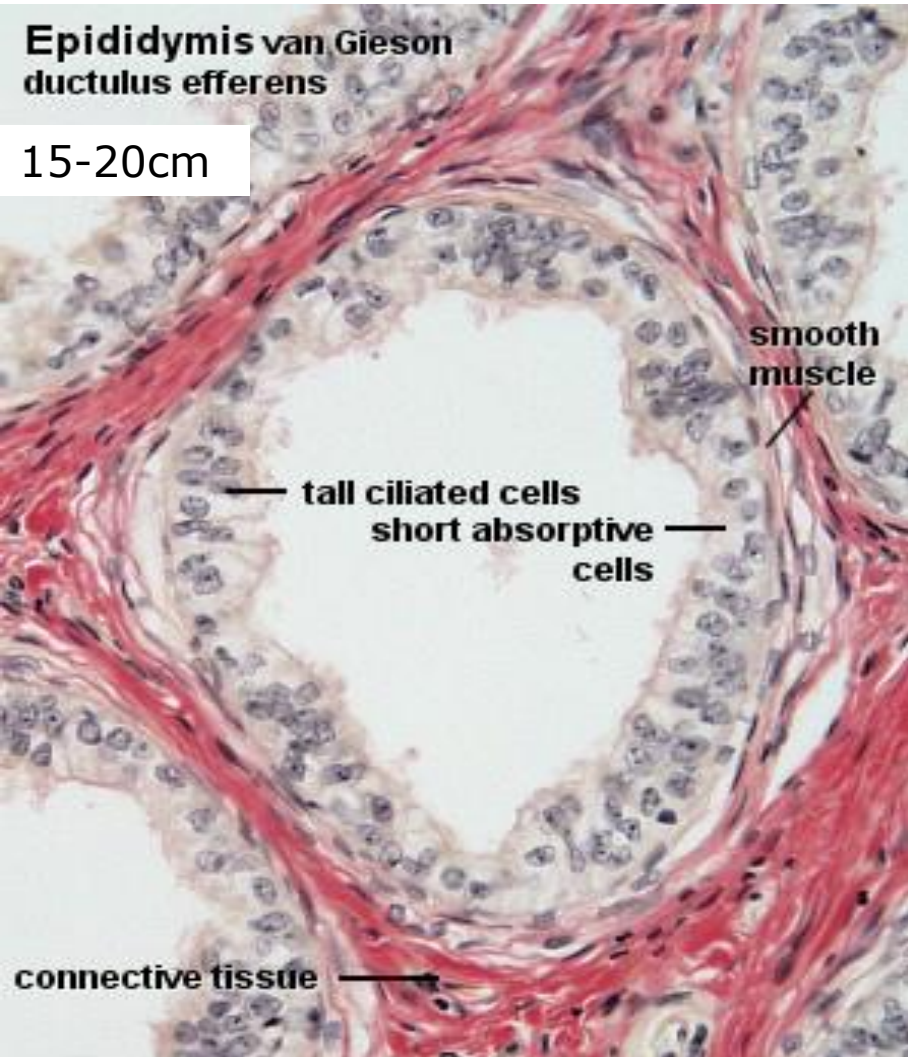


ductus epididymidis - corpus et cauda epididymidis;

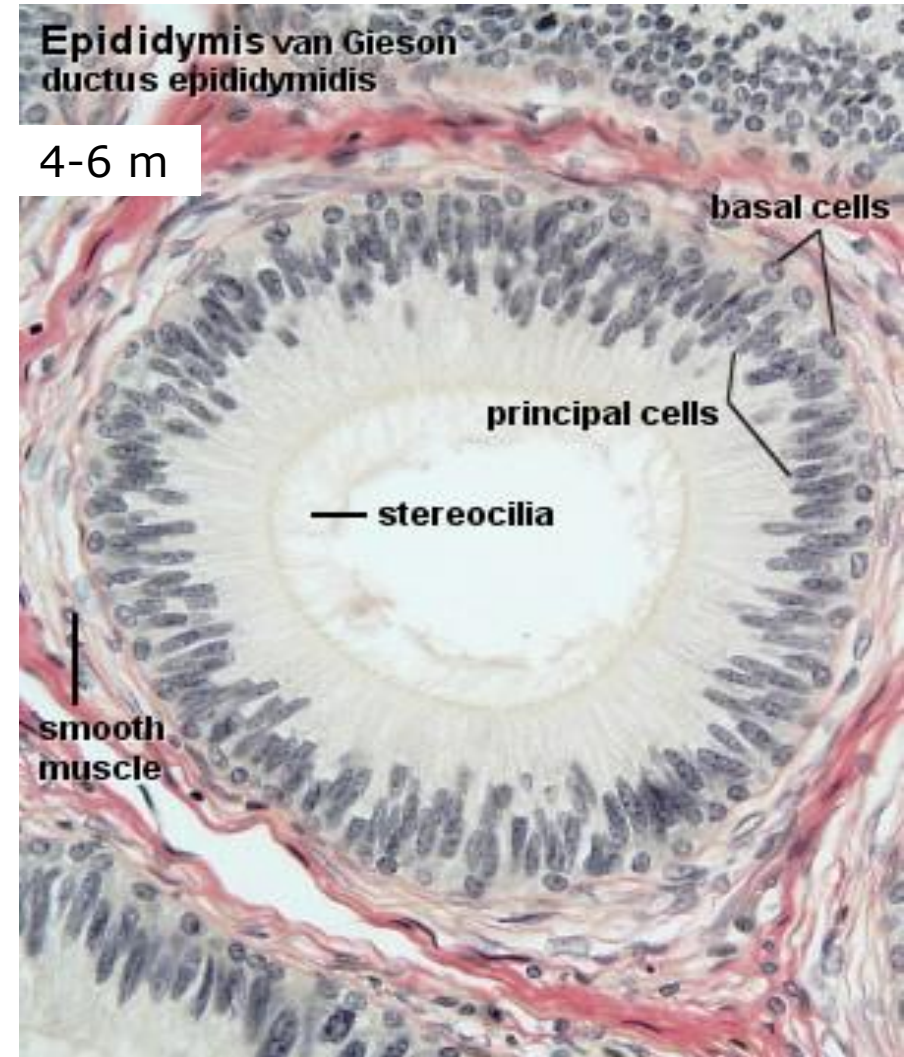
- lamina epithelialis – pseudostratified columnar epithelium + stereocilia
- membrana propria



# Epididymis



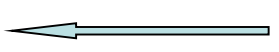Simple cubic epithelium



Pseudostratified columnar epithelium

# Epididymis (homo) [HE]:

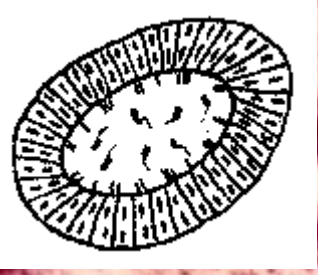
CAUDA



CORPUS

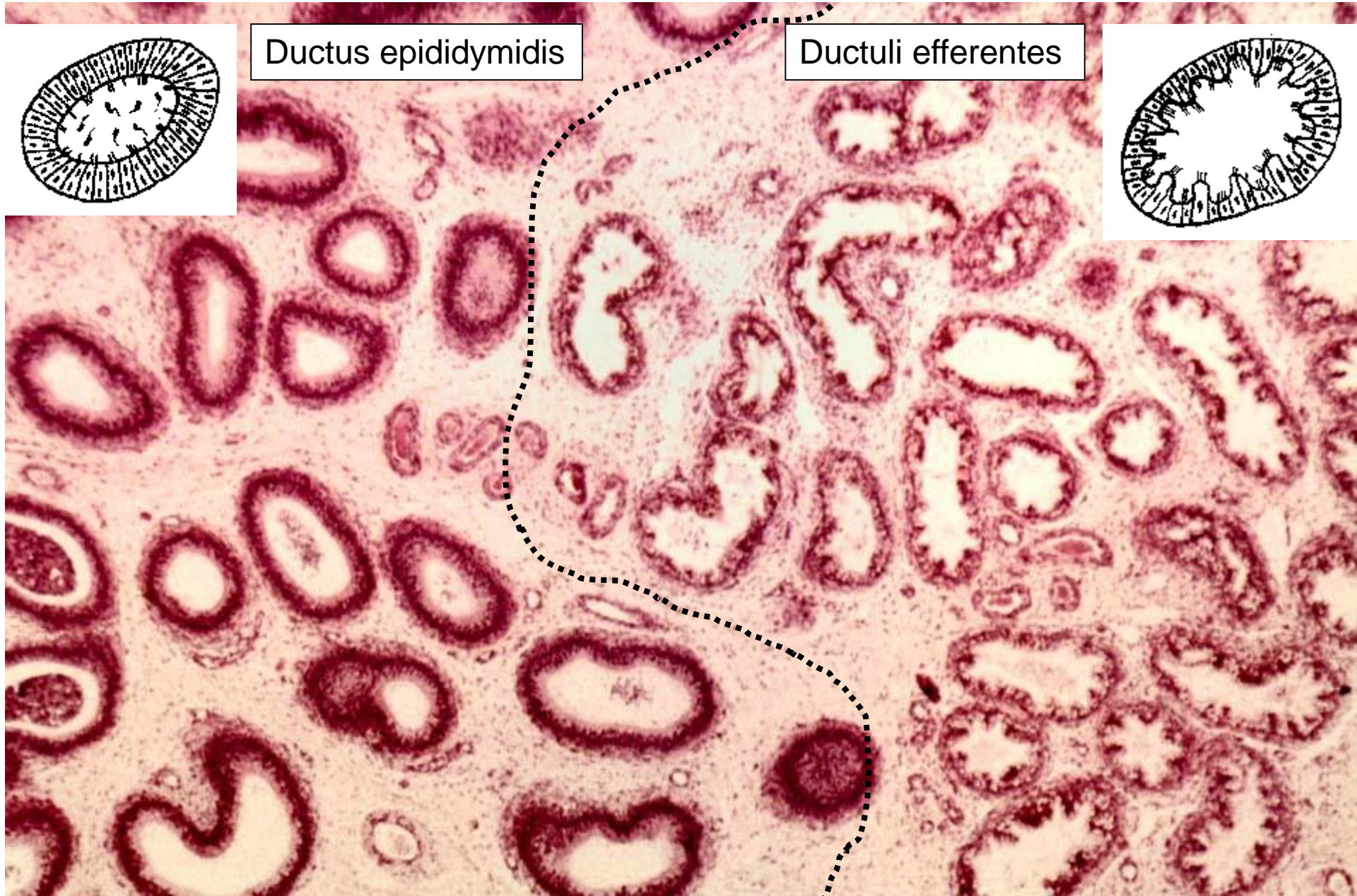
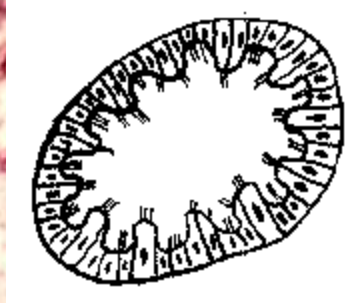et

CAPUT

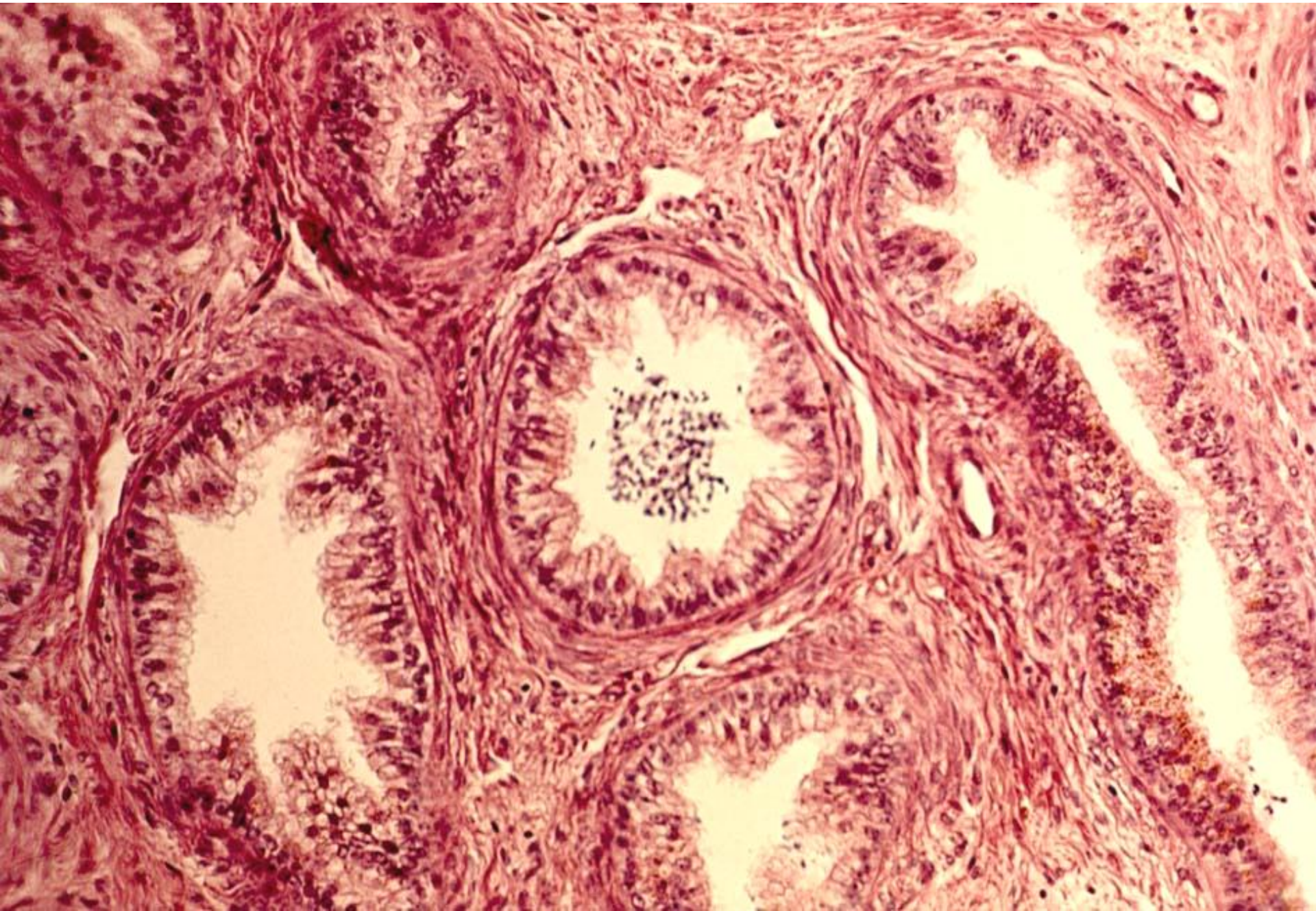


Ductus epididymidis

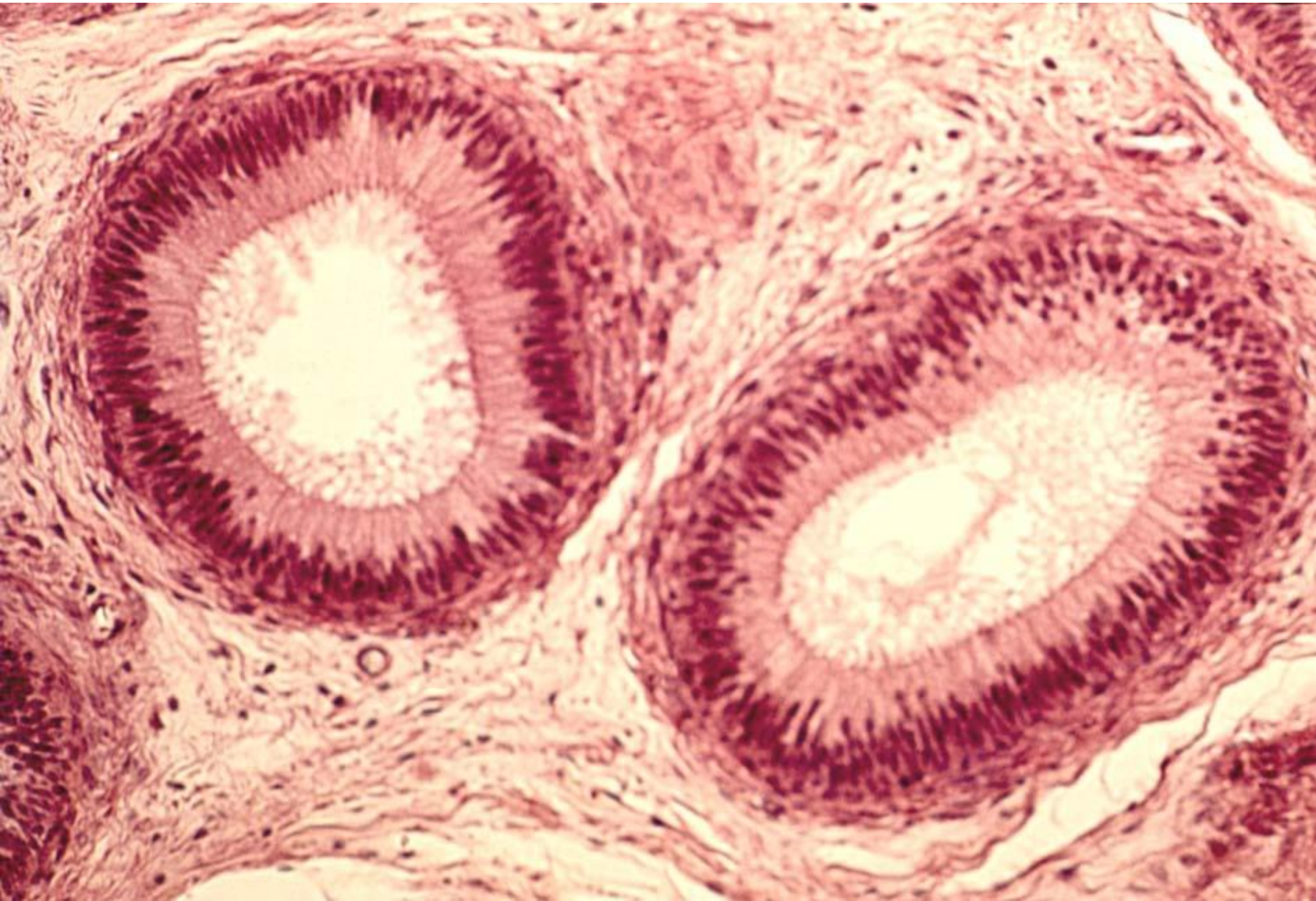
Ductuli efferentes



Epididymis [HE]: ductuli efferentes



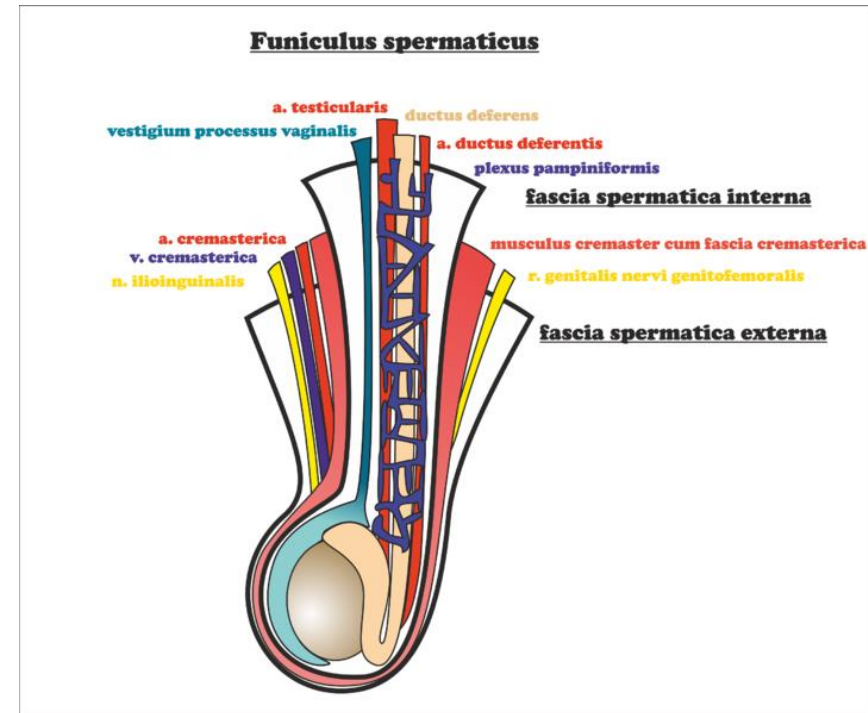
Epididymis [HE]: ductus epididymidis



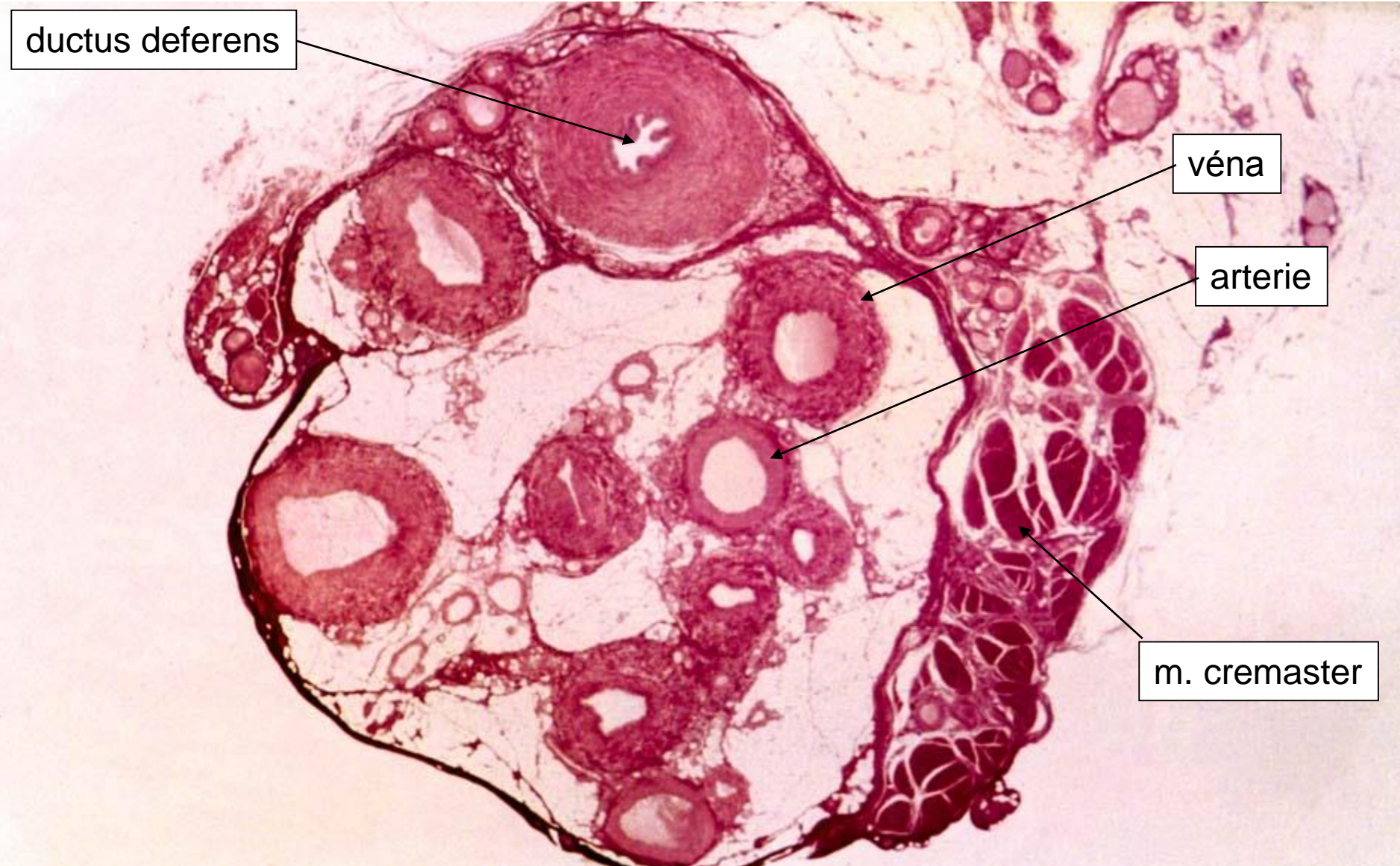

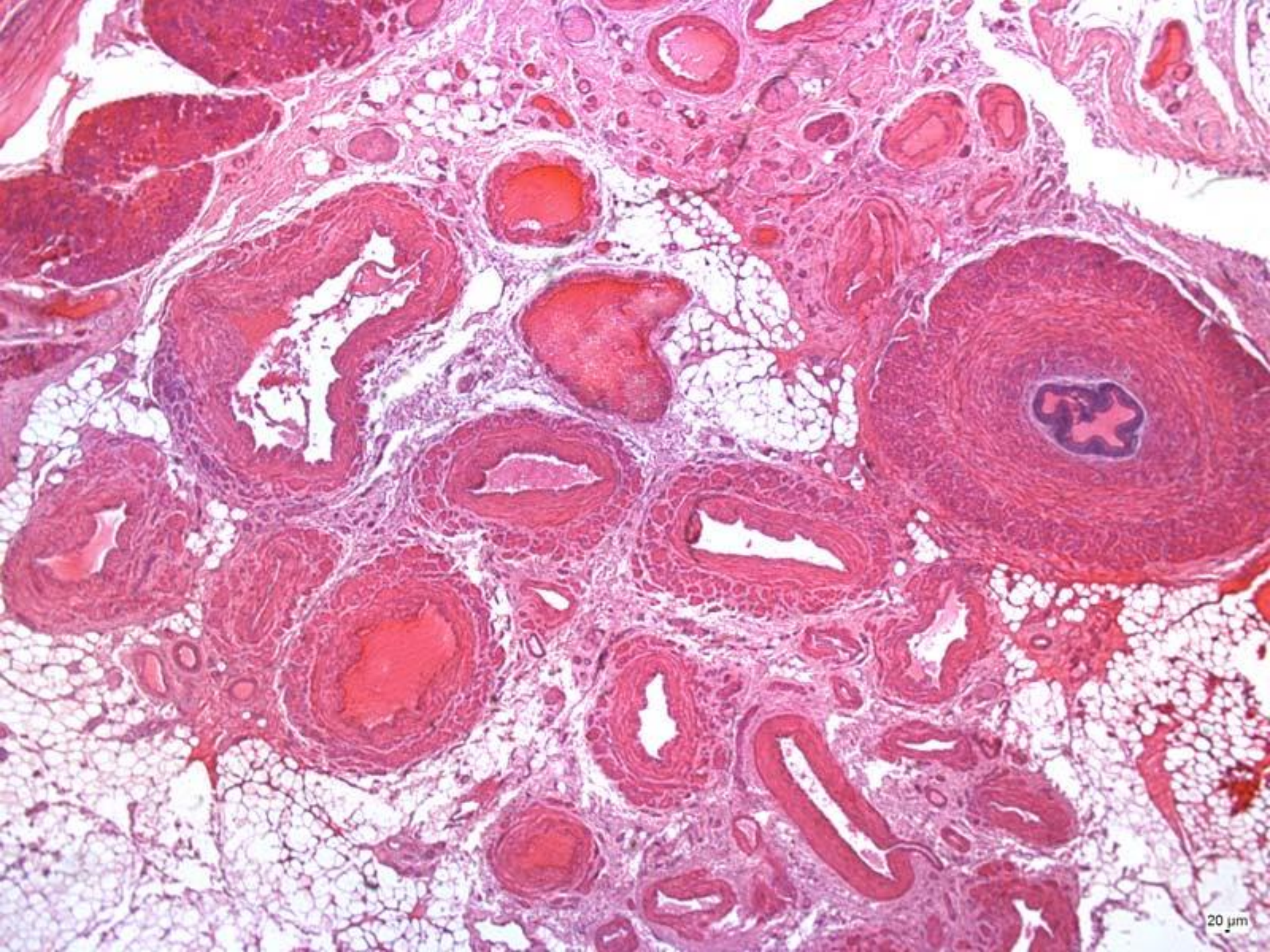
# Funiculus spermaticus

- ductus deferens
- Veins of plexus pampiniformis
- arteries (cremasterica, testicularis)
- nerves
- musculus cremaster
- loose collagen connective tissue

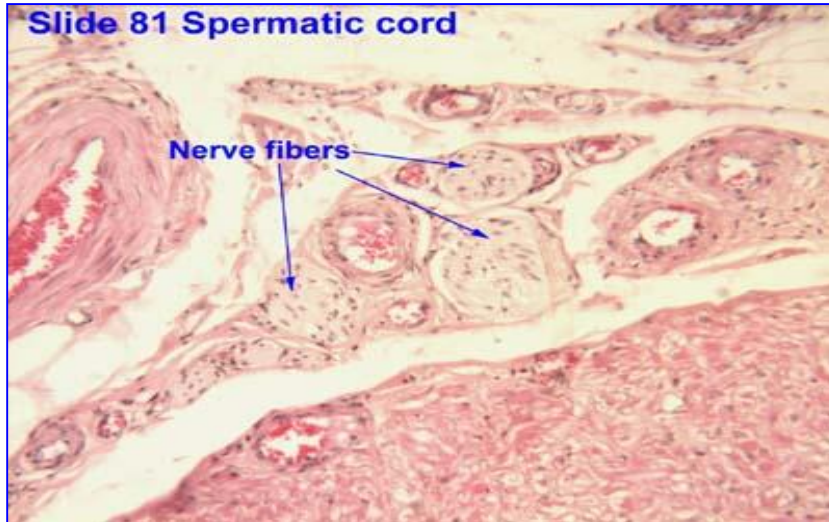


## Funiculus spermaticus [HE]:

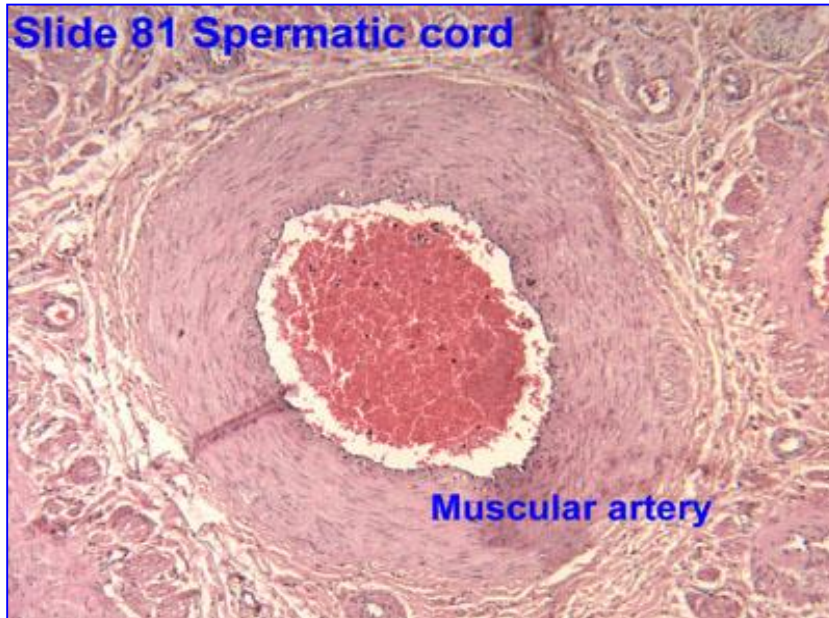




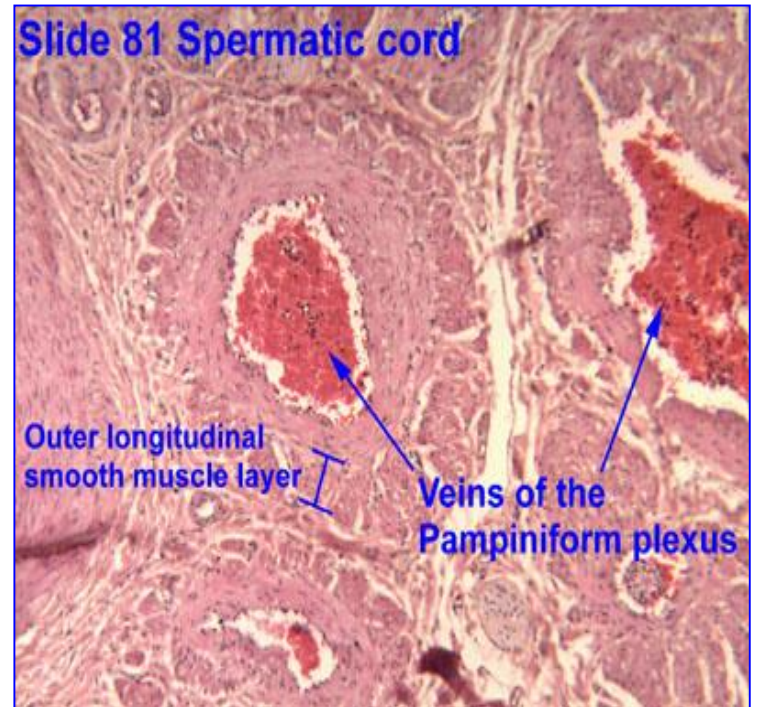
**Slide 81 Spermatic cord**



**Slide 81 Spermatic cord**



**Slide 81 Spermatic cord**



# Ductus deferens

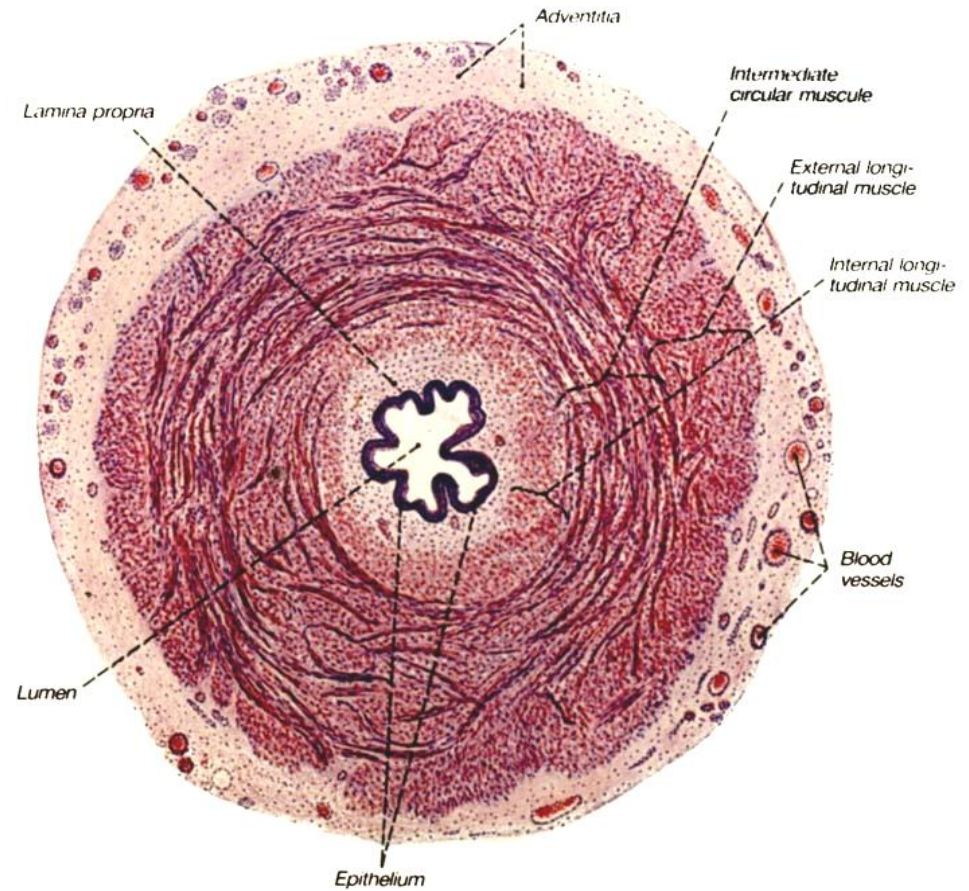
## Mucosa:

- folds
- pseudostratified columnar epithelium + stereocilia
- thin lamina propria
- regional changes of epithelium type (funiculus, ampula, d. ejaculatorius)

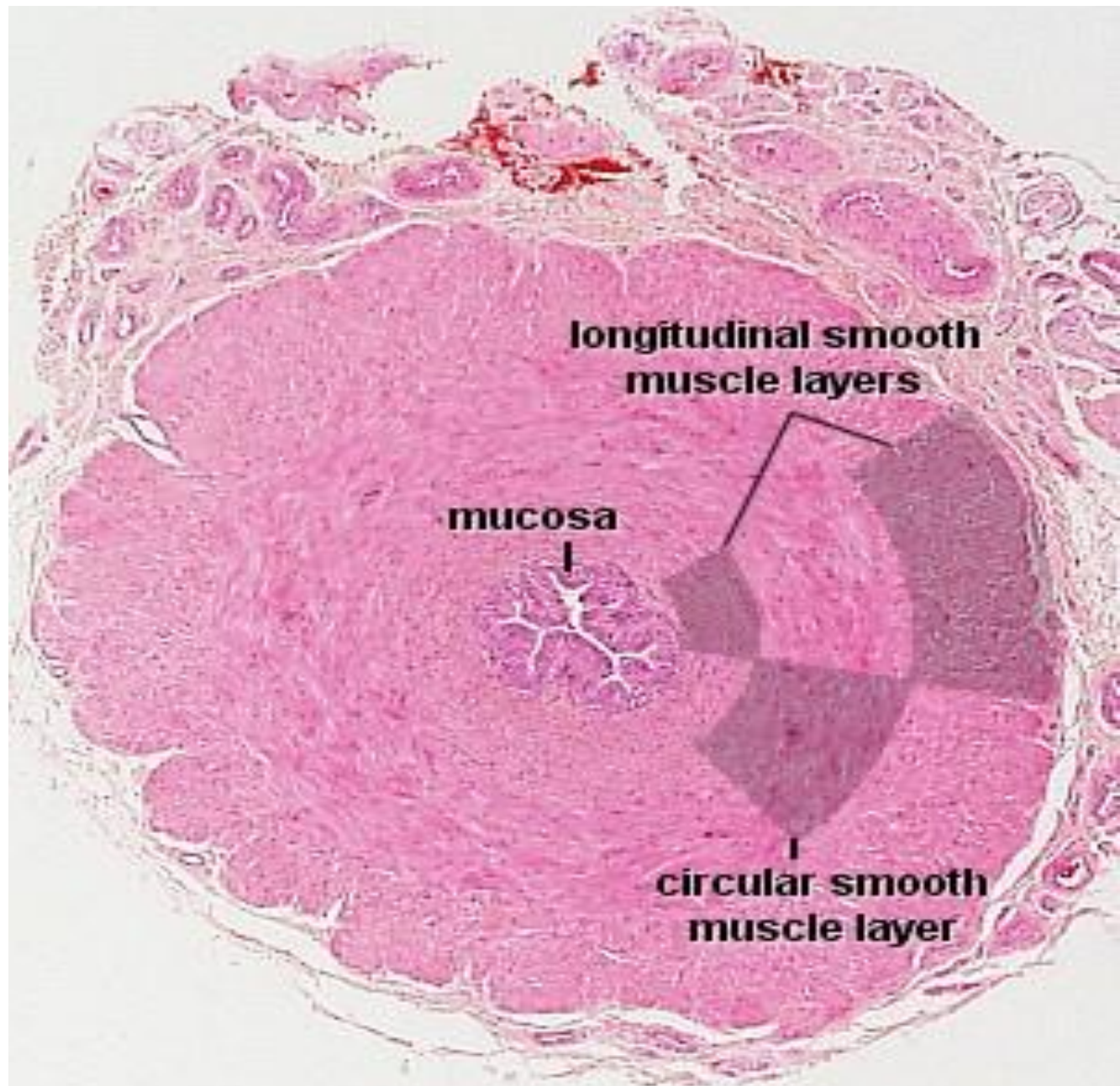
## Muscularis externa

- spirally oriented (longitudinal-circular-longitudinal)
- rich innervations (noradrenergic)

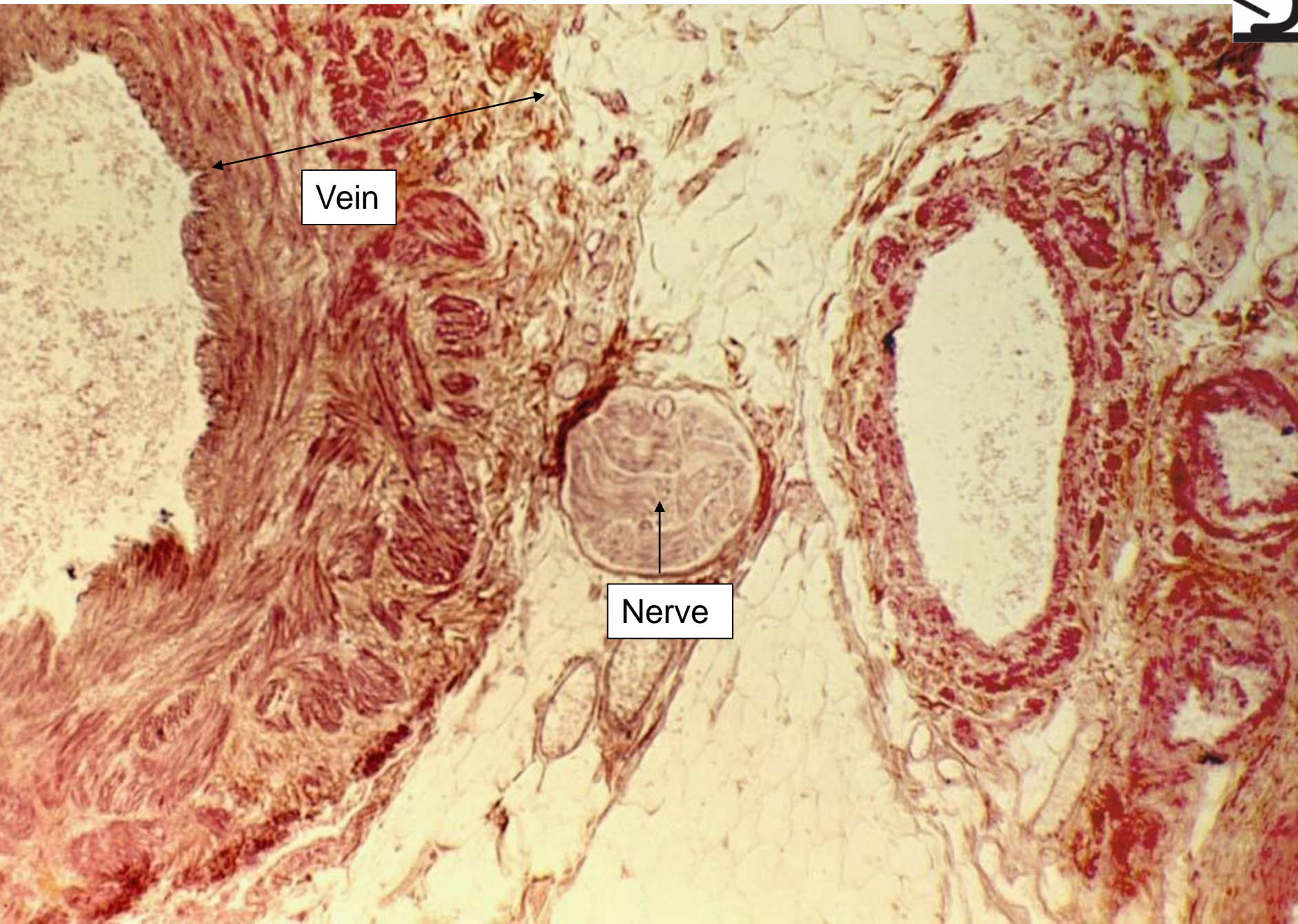
## Adventitia



# Ductus deferens [HE]



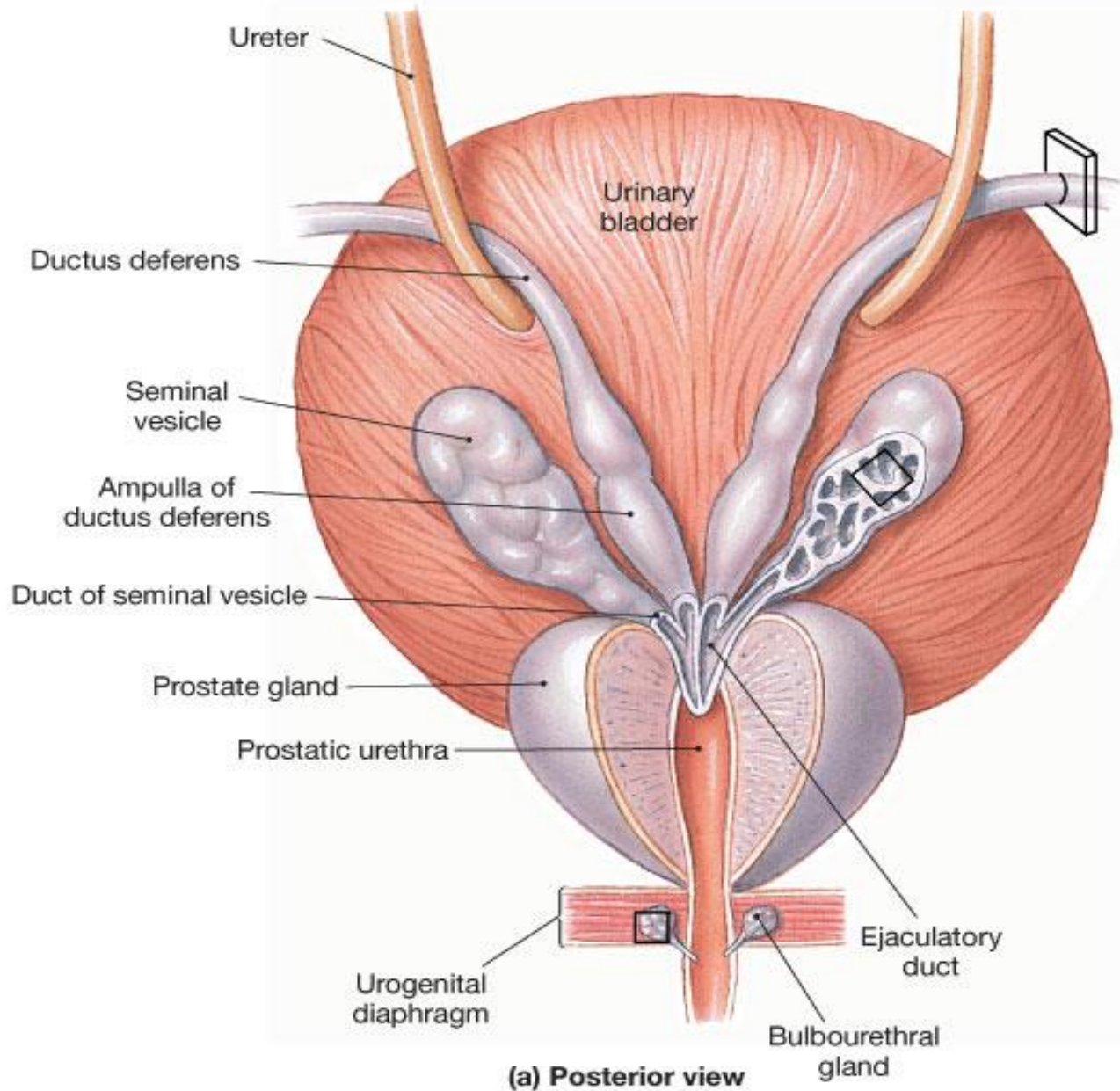
**Funiculus spermaticus [HE]:**



Vein

Nerve

# Glands: vesicula seminalis a prostata





# Vesicula seminalis (gl. vesiculosa)

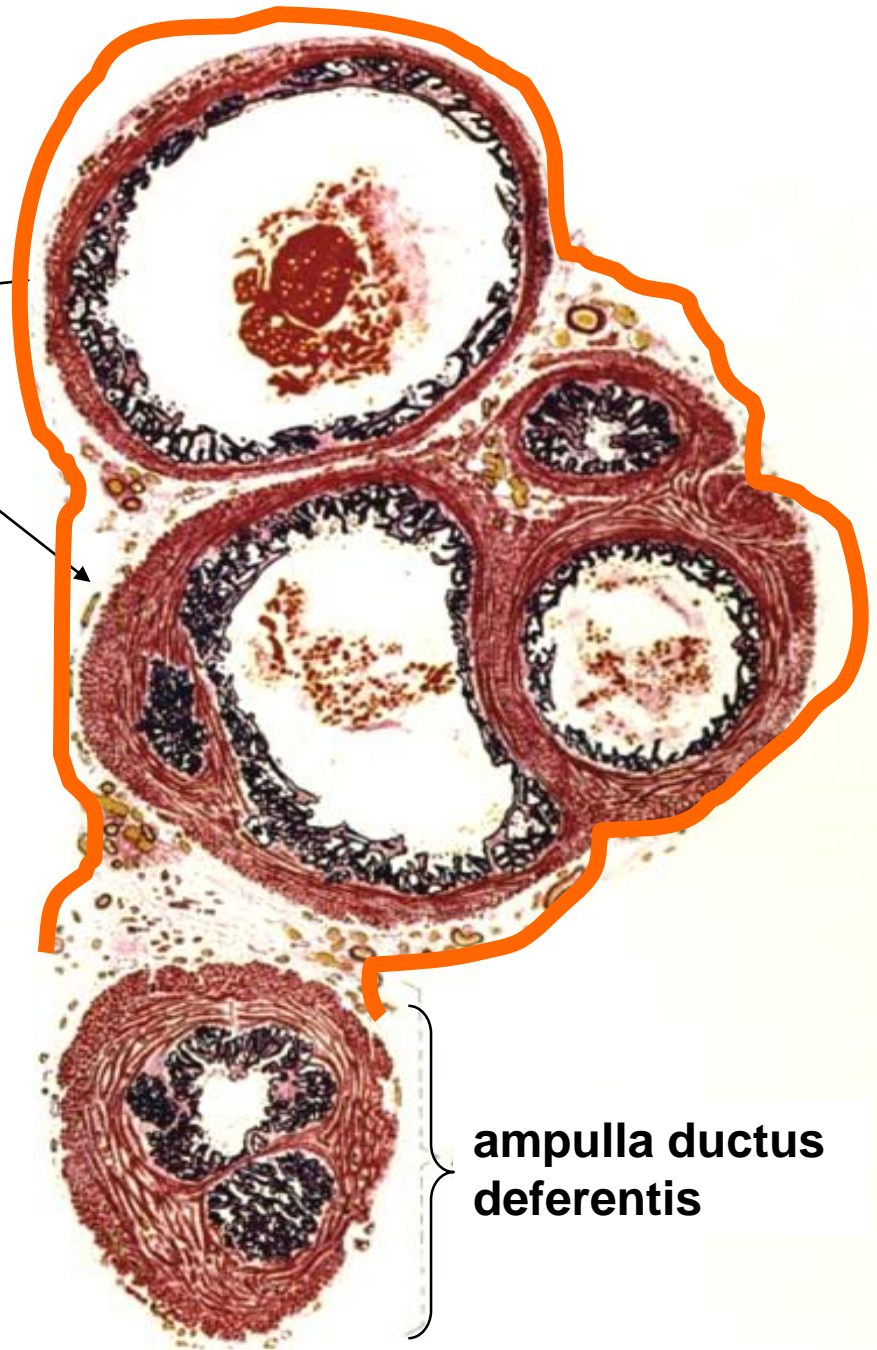Cross sections

## Mucosa

- epithelium – simple cubic – pseudostratified columnar epithelium
- lamina propria
- fructose rich, semenogelin, pH 7.6

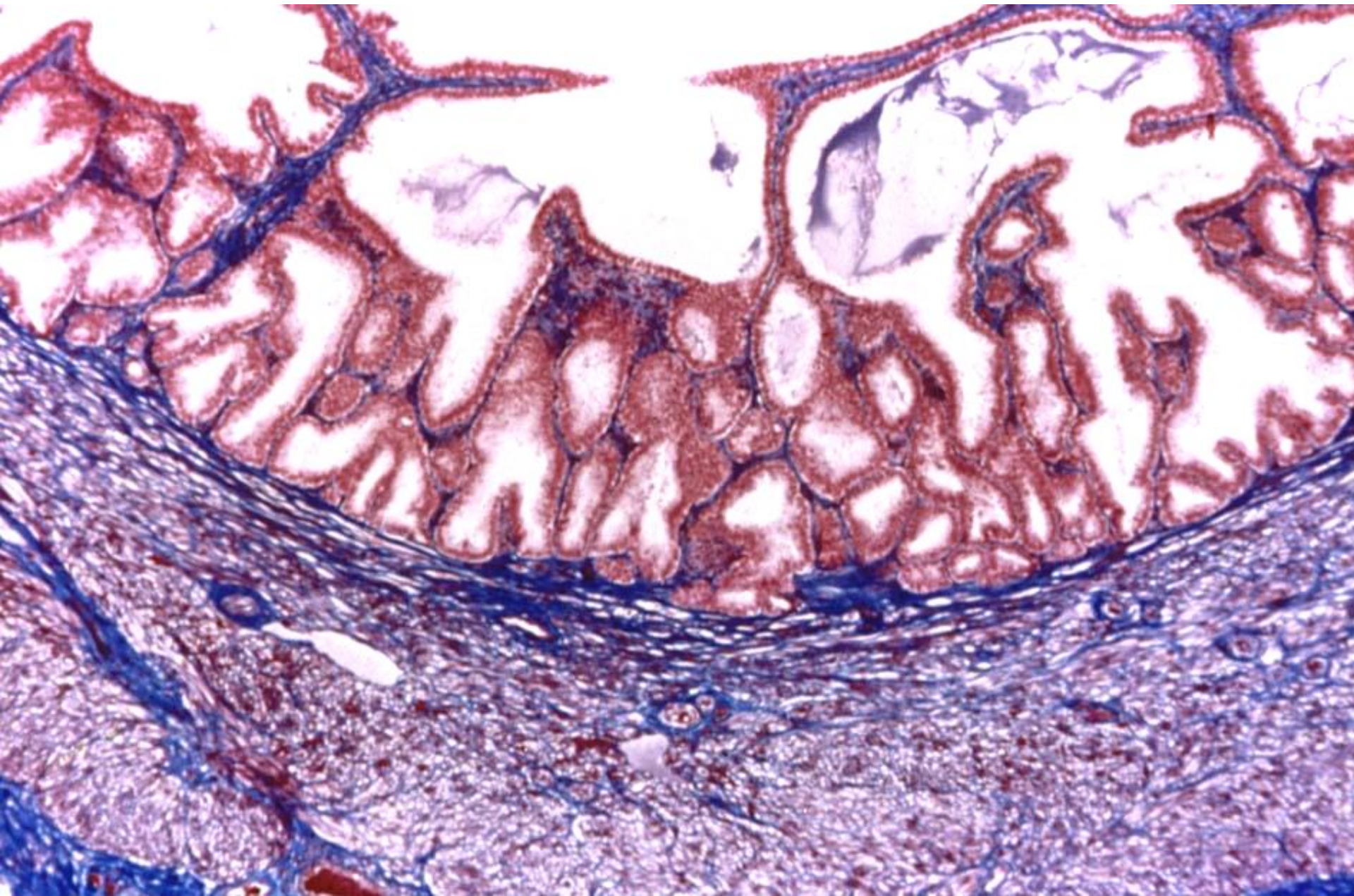
Muscularis externa. (circular + longit.)

Adventitia



ampulla ductus  
deferentis

# Vesicula seminalis [Azan]

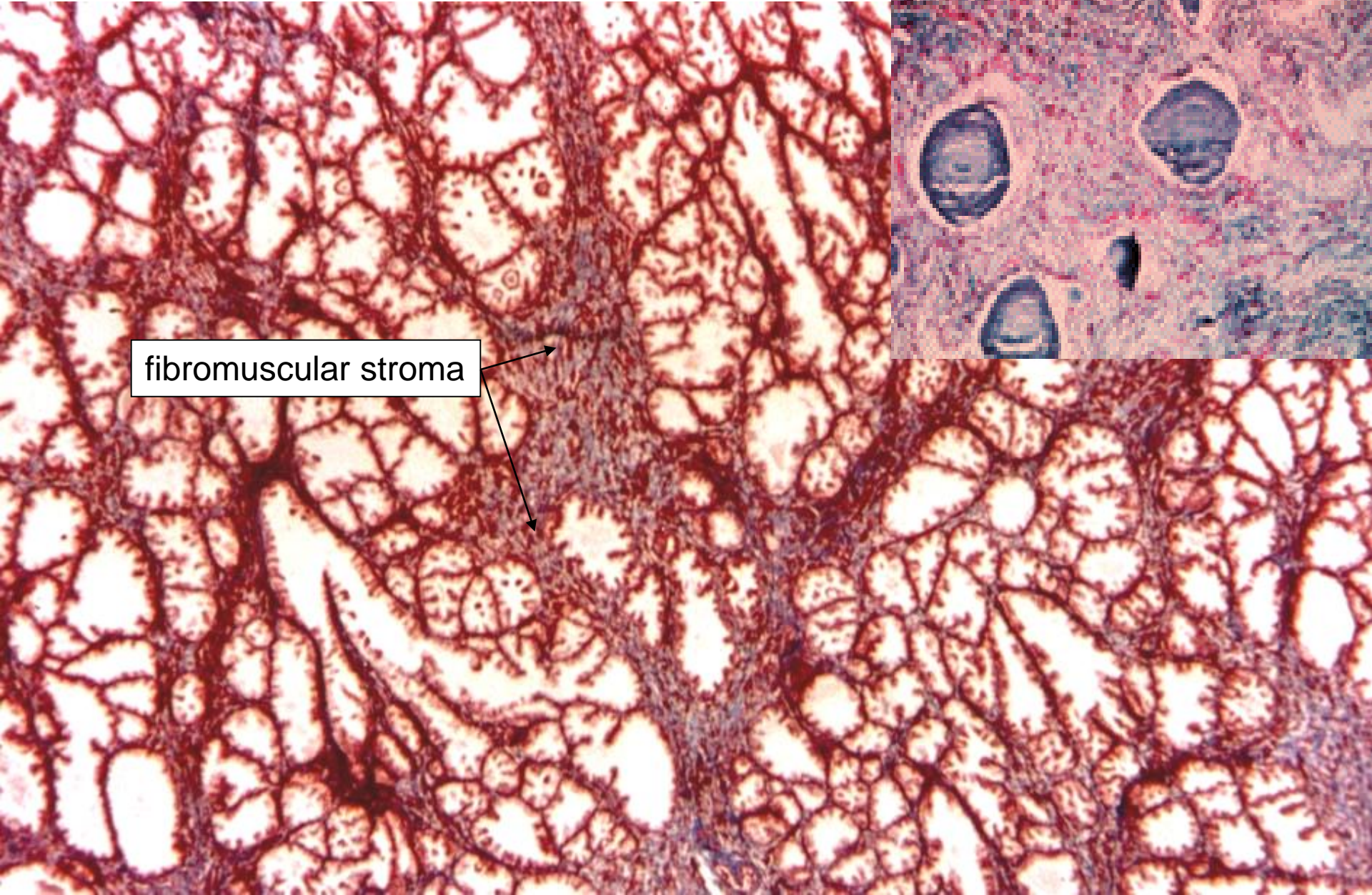


# Prostate

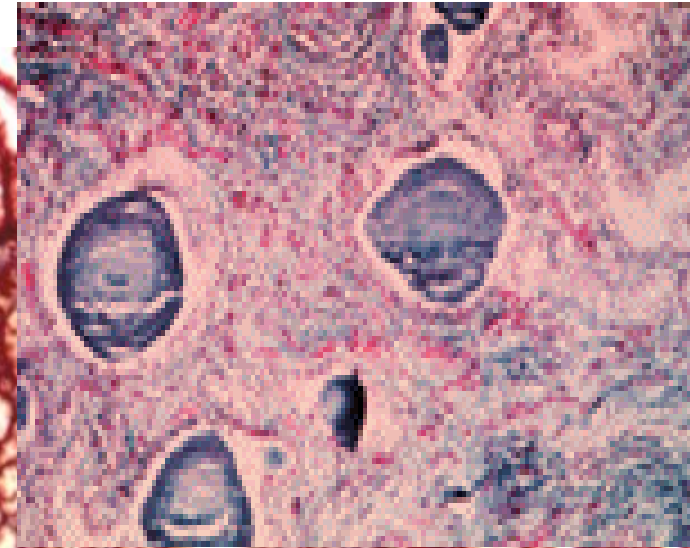
- 30 – 50 tubuloalveolar glands → 15 – 30 ducts do pars prostatica urethrae masculinae
- Connective tissue:
  - capsula
  - fibromuscular stroma
- Glands – irregular lumen; epithelium – simple cubic – pseudostratified columnar
- ***prostatic concretions - corpora amylacea***
- **PSA**

# Prostate [Azan]

# prostatic concretions (corpora amylacea)

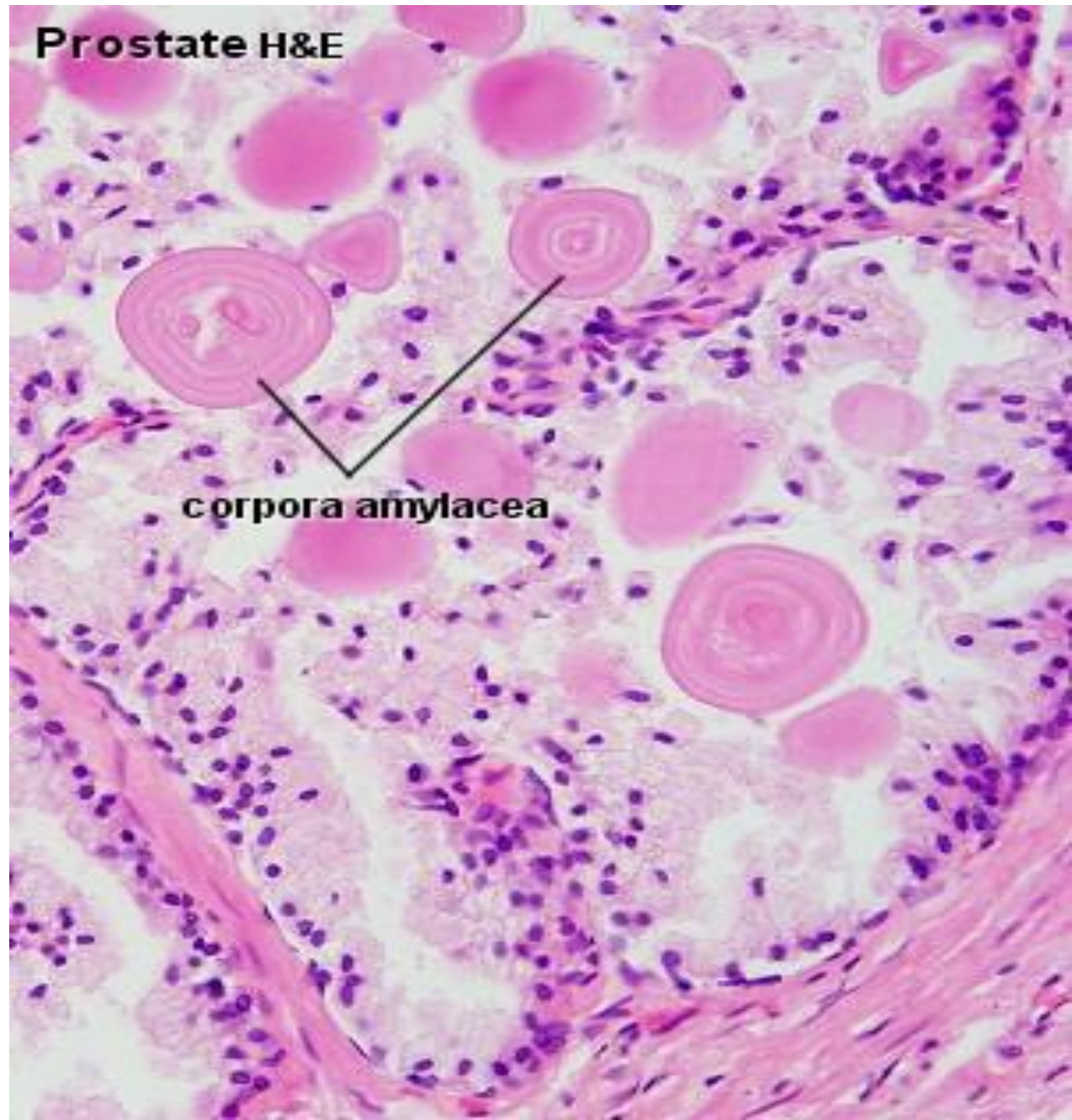


fibromuscular stroma

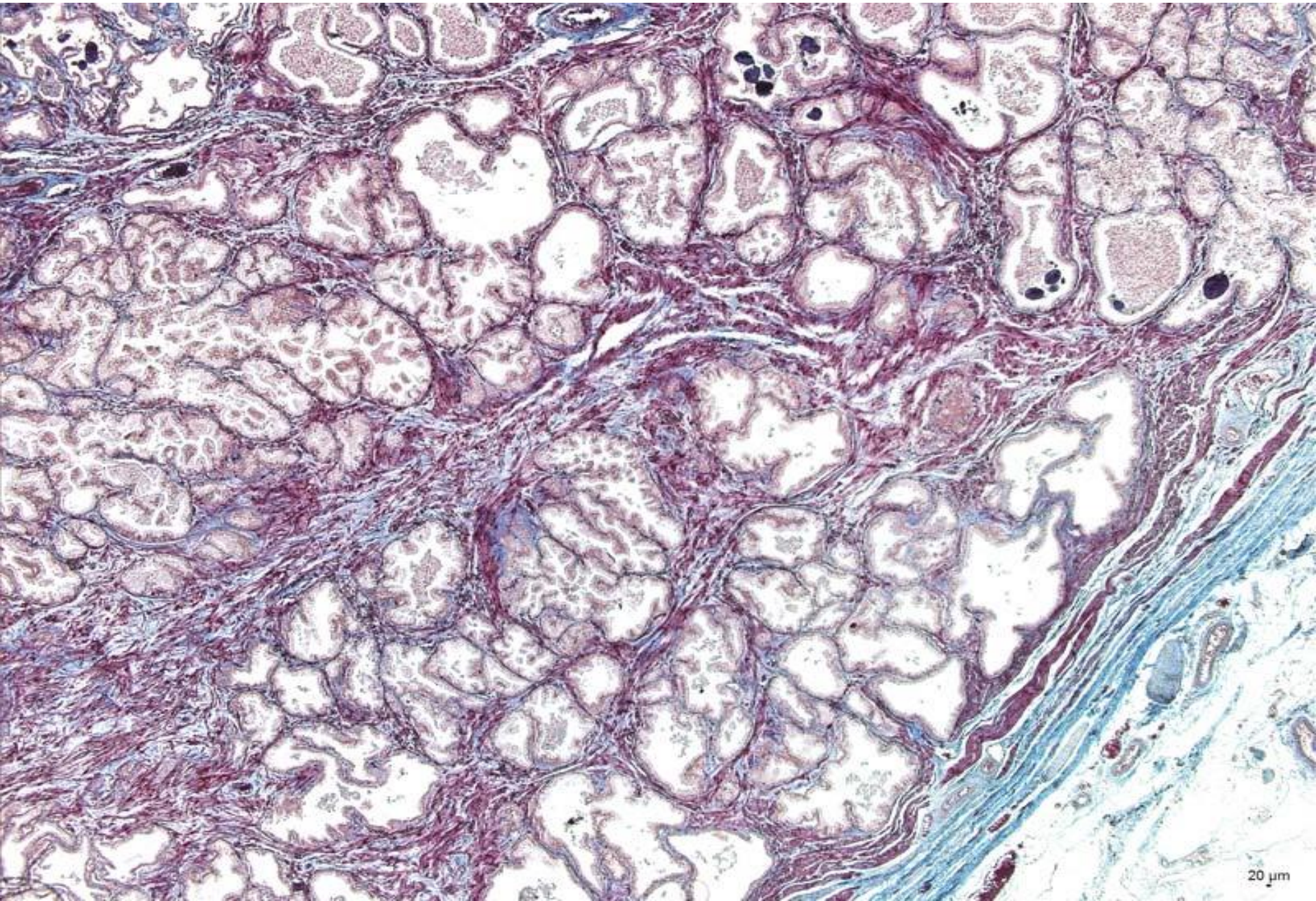


## Prostatic concretions - *corpora amylacea*

- eosinophilic bodies (Ø0.25 mm – 2 mm)
- lamellar structure
- calcifications

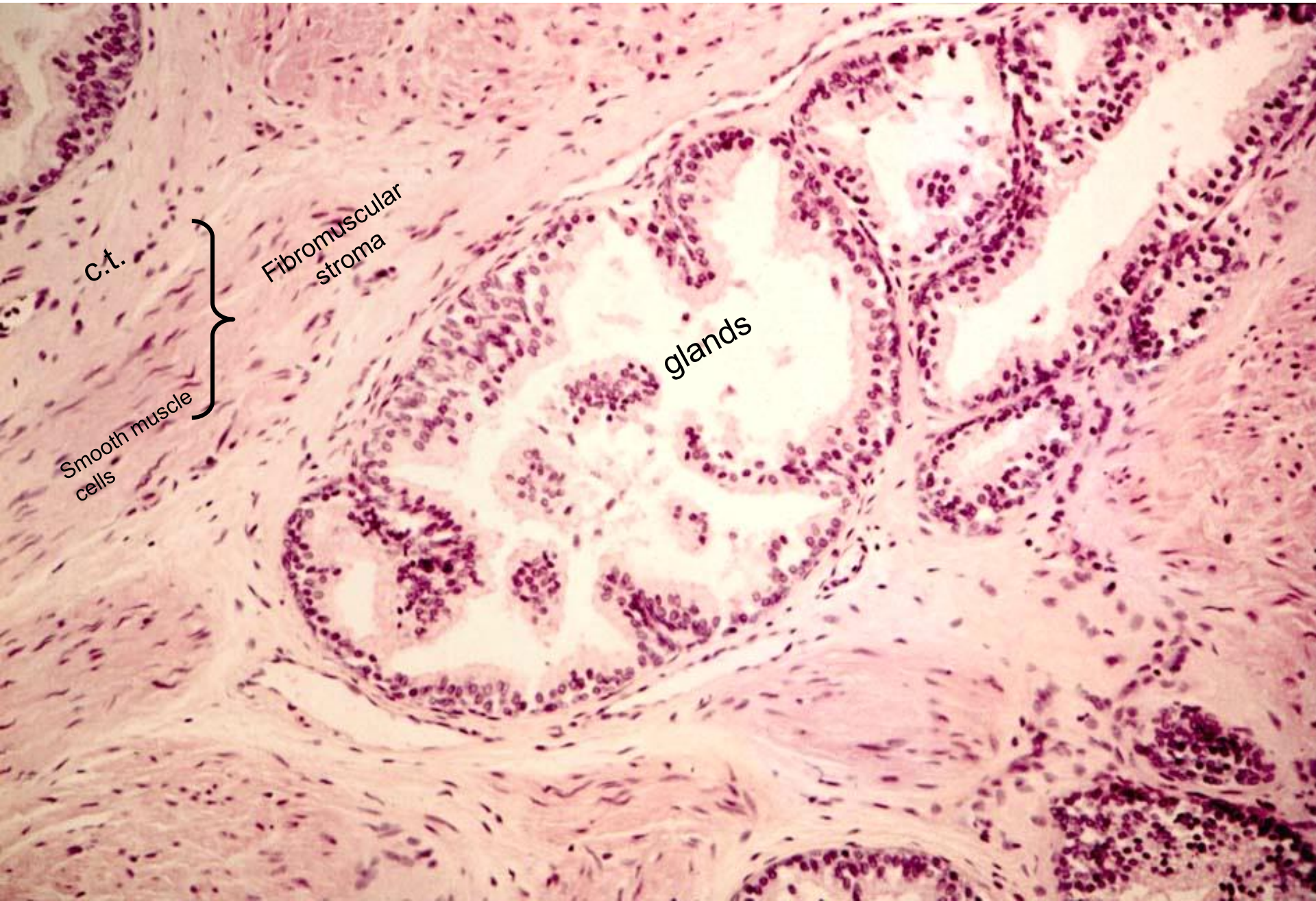


**Prostate (Azan)**



20 μm

# Prostate [HE]



C.t.

Fibromuscular  
stroma

glands

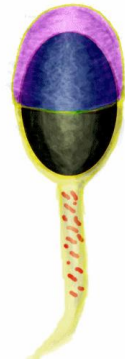Smooth muscle  
cells

# Ejaculate

- **seminal plasma:**  
testicular fluid, secretions – vesicae seminales, prostate, gll. bulbourethrales and paraurethral glands (Littré)
- **cells:**  
sperms, epithelia, migratory cells, residual bodies, prostatic concretions

## Capacitation of sperms

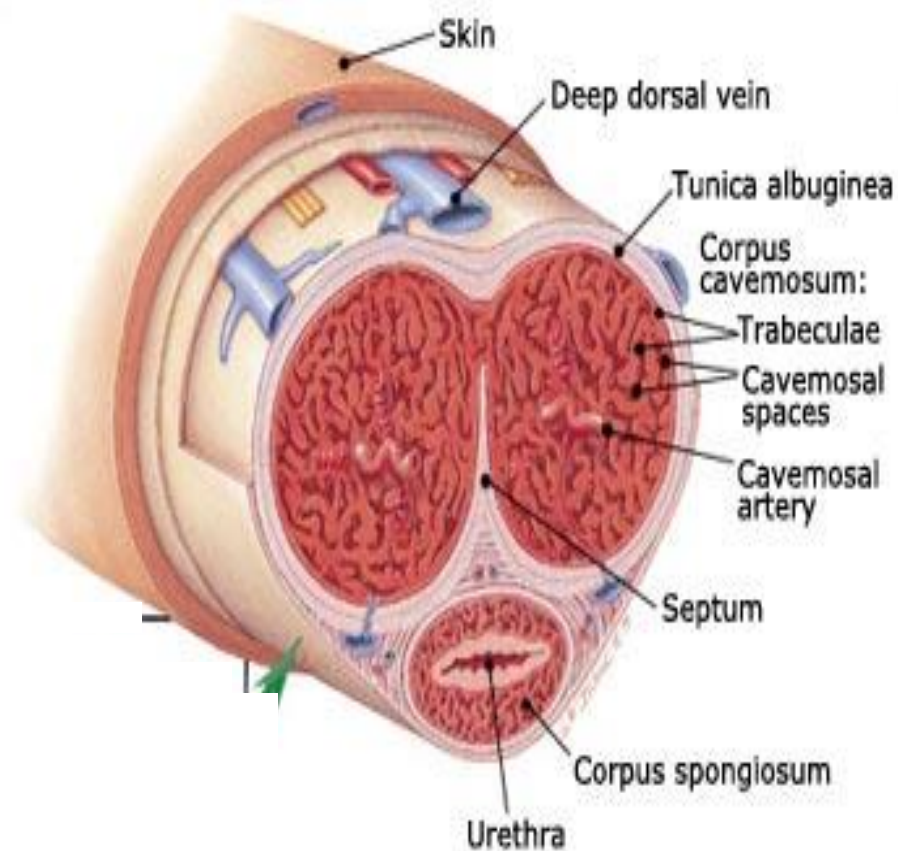
- Reaction of sperms with oviductal fluid
- Hyperactivation of sperms
- Changes in surface coating of sperms (ion channels, membrane fluidics)
- Acrosomal reaction



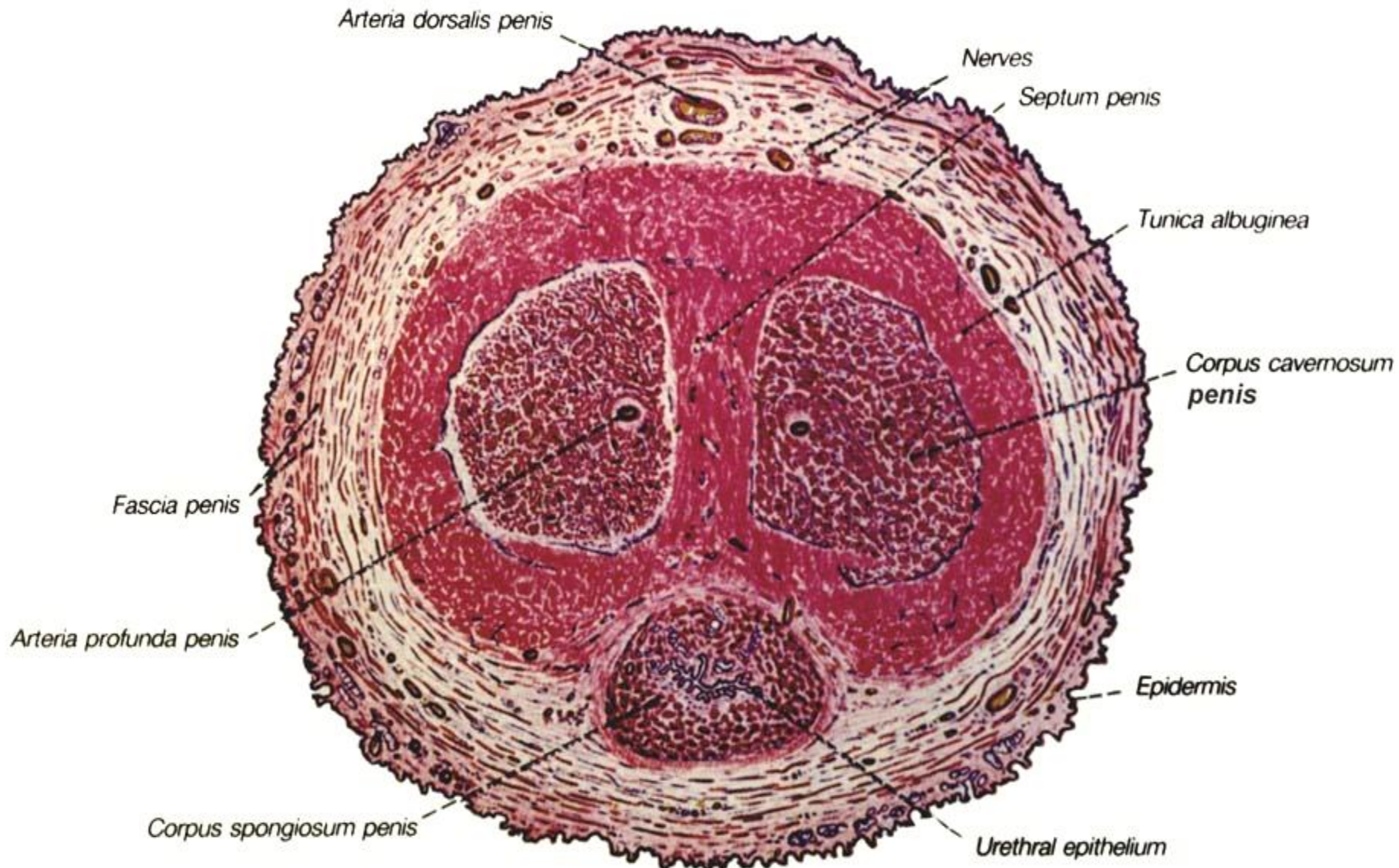


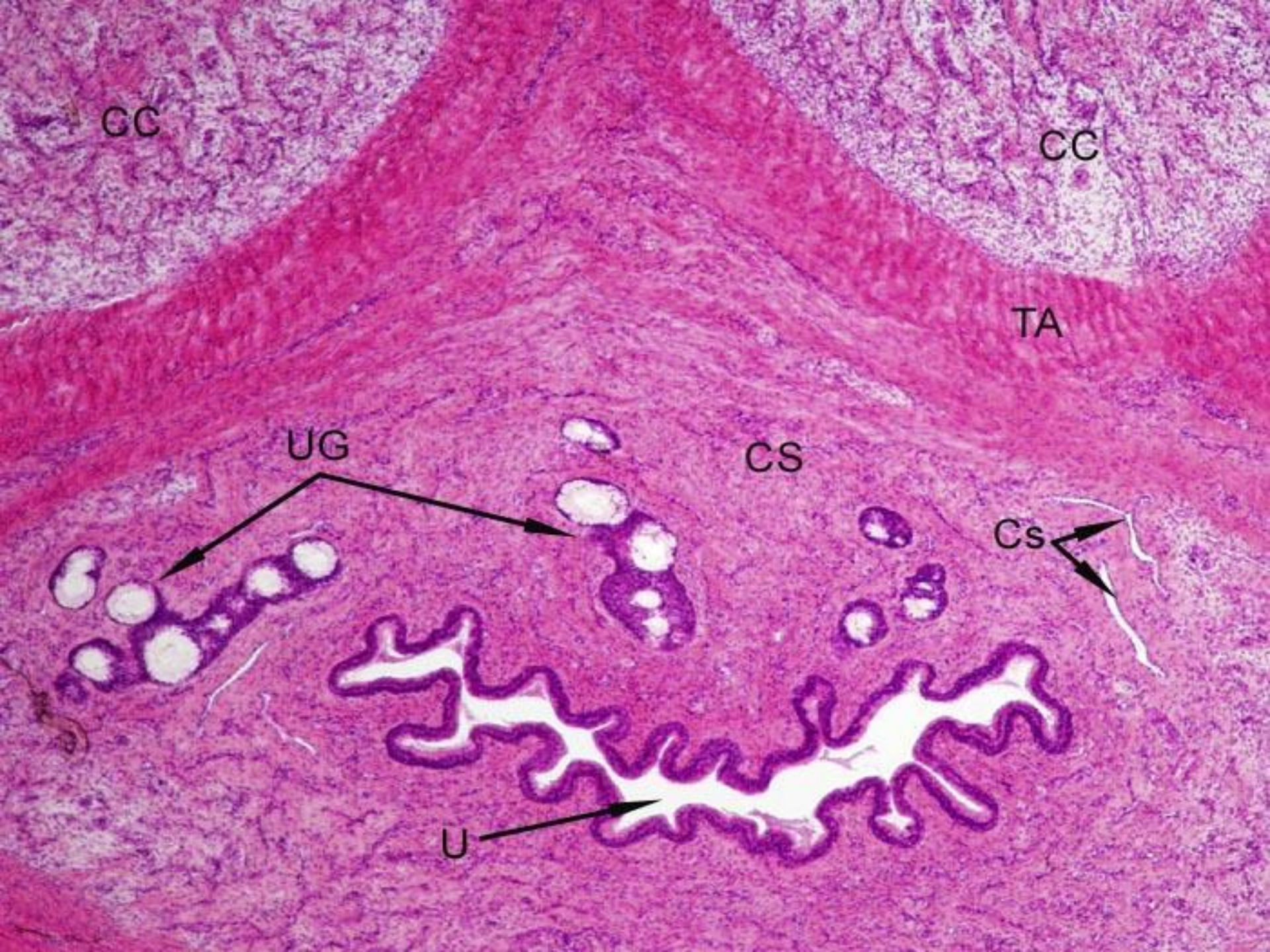# Penis

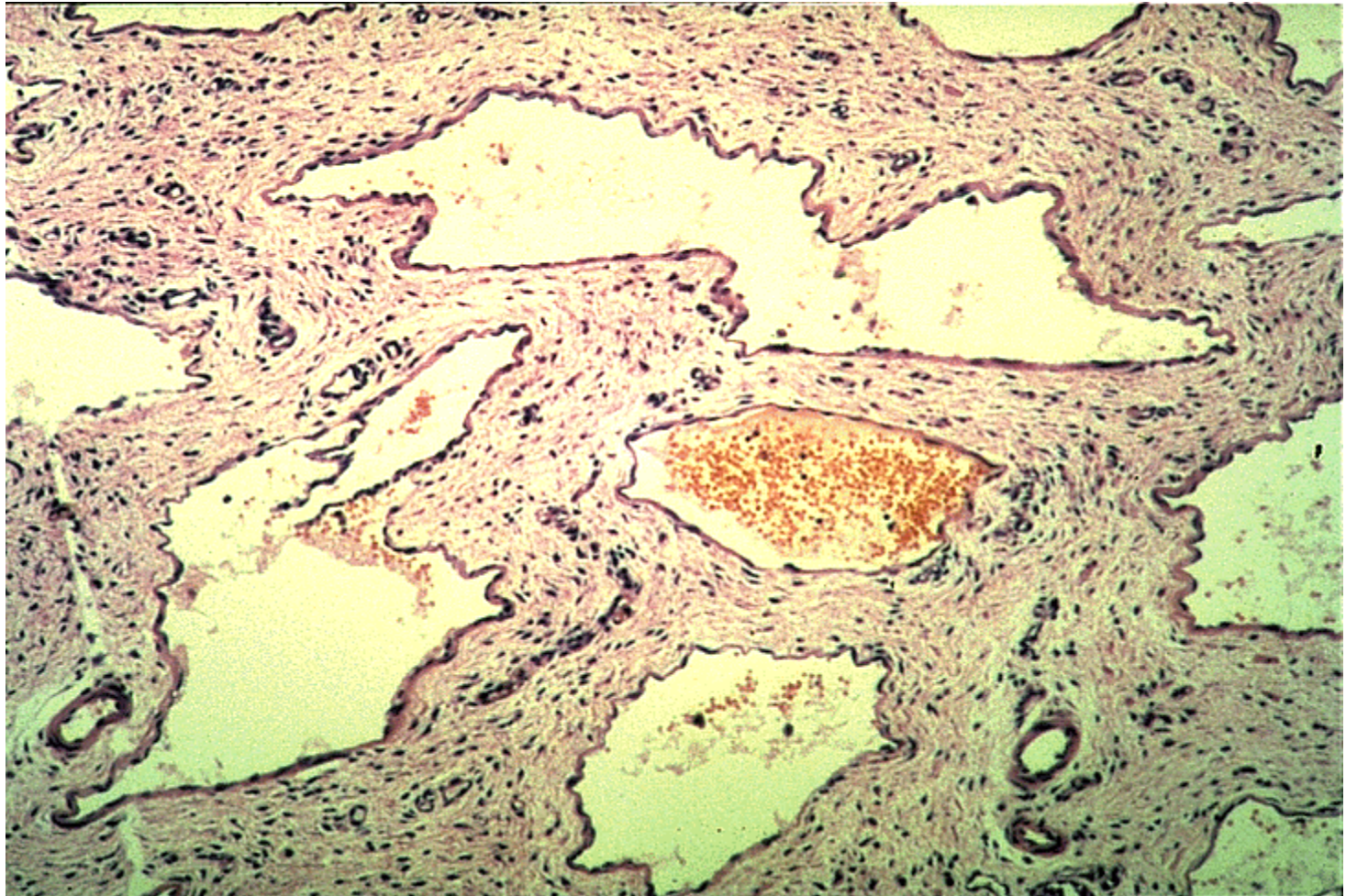
- **Skin** – thin, demis – sweat and sebaceous glands
- **Corpora cavernosa:**
  - Corpus cavernosum penis (pair):
    - tunica albuginea,
    - erectile bodies – venous lacunes (endothelium, leiomyocytes, elastic fibers)
  - Corpus spongiosum urethrae (single):
    - pars spongiosa urethrae



# Cross section







# 5.

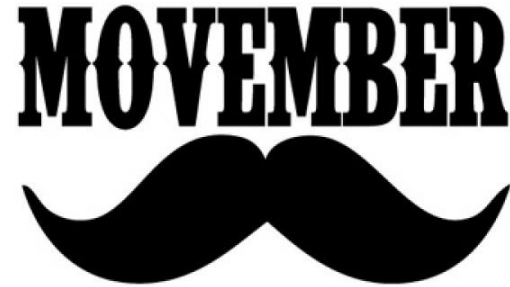## Male reproductive system

### Slides:

- 36. Testis (HE)
- 37. Epididymis (HE)
- 38. Funiculus spermaticus (HE)
- 39. Glandula vesiculosa (HE)
- 40. Prostate (HE)
- 41. Penis (HE)

### Atlas EM:

- 1. Leydig cells (23)
- 2. Human sperm (31)



**SUPPORT**  
**WWW.MOVEMBER.COM**