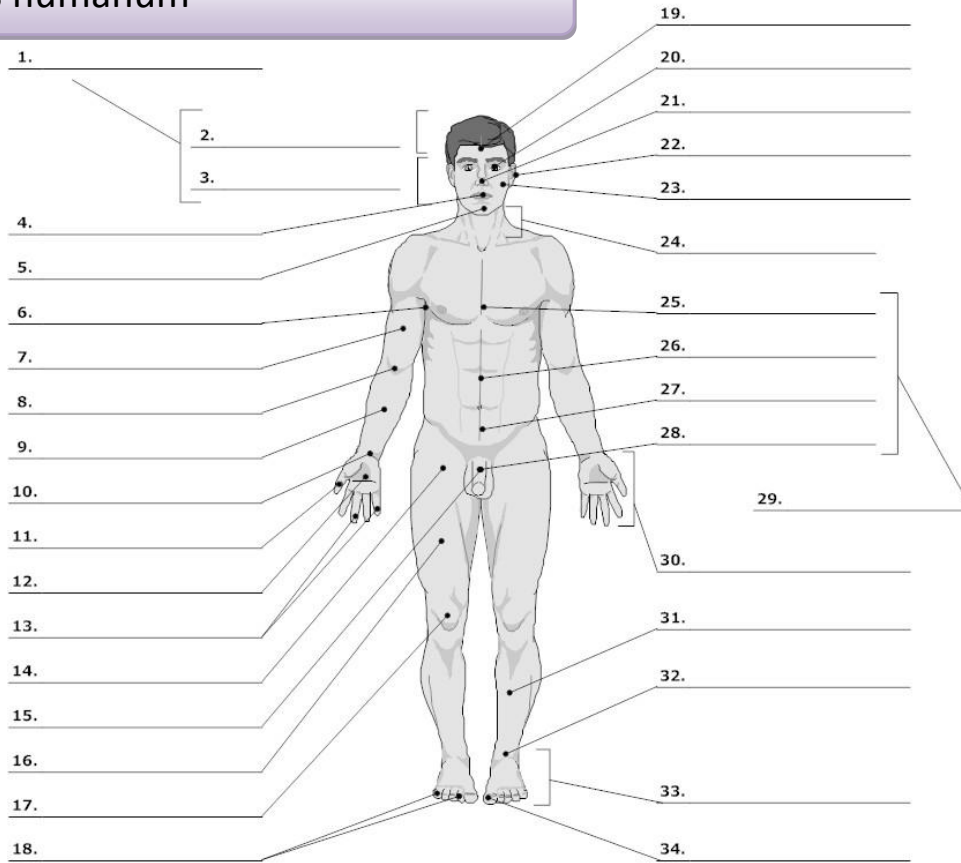


**PART I : EXERCISES/VOCABULARY**

**Corpus humanum**

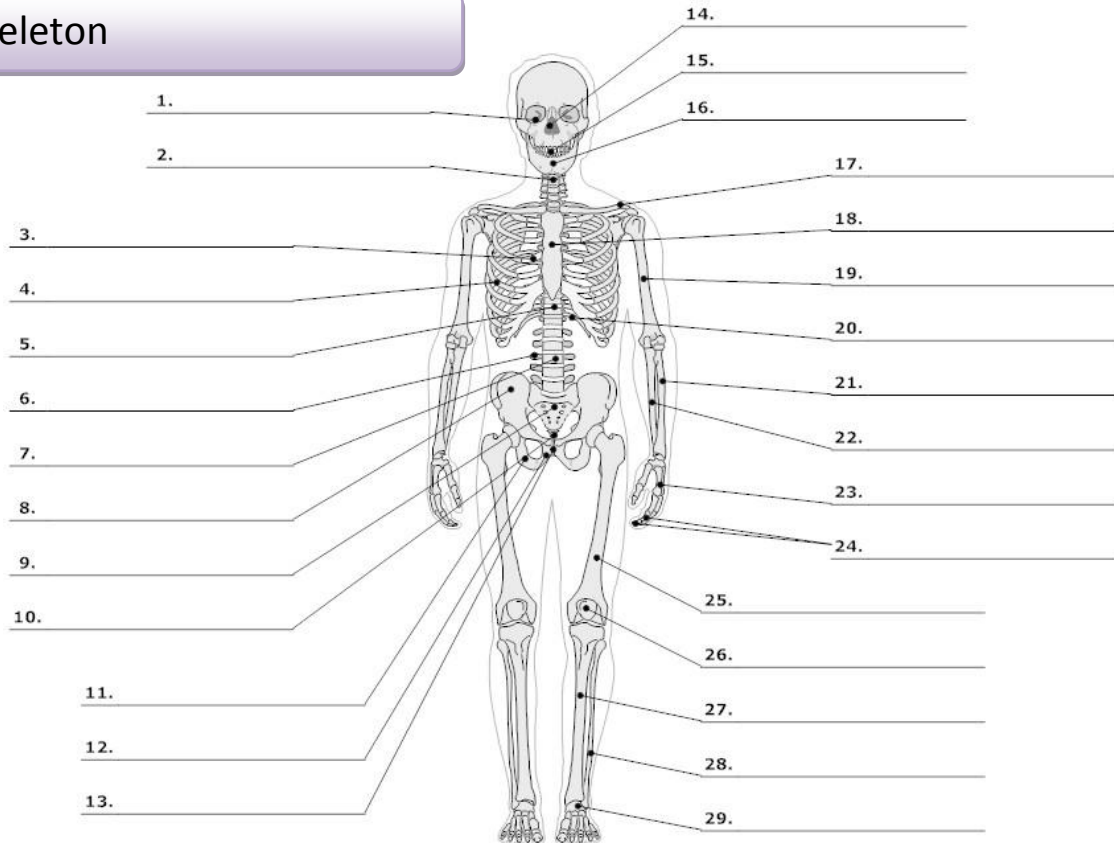


LIFEART Collection Images Copyright © 1999-2001. By Lippincott Williams & Wilkins, Baltimore, MD

- |                                                    |                     |                                                     |                                                                      |
|----------------------------------------------------|---------------------|-----------------------------------------------------|----------------------------------------------------------------------|
| 0. <b>corpus, oris, n.</b><br><b>cutis, is, f.</b> | body<br>skin        | 16. <b>femur, oris, n.</b>                          | thigh, femur                                                         |
| 1. <b>caput, itis, n.</b>                          | head                | 17. <b>genu, us, n.</b>                             | knee                                                                 |
| 2. <b>capilli, orum, m.</b>                        | hair                | 19. <b>frons, frontis, f.</b>                       | forehead                                                             |
| 3. <b>facies, ei, f.</b>                           | face                | 20. <b>oculus, i, m.</b>                            | eye                                                                  |
| 4. <b>os, oris, n.</b><br><b>lingua, ae, f.</b>    | mouth<br>tongue     | 21. <b>nasus, i, m.</b>                             | nose                                                                 |
| 5. <b>mentum, i, n.</b>                            | chin                | 22. <b>auris, is, f.</b>                            | ear                                                                  |
| 6. <b>axilla, ae, f.</b>                           | armpit, axilla      | 23. <b>bucca, ae, f.</b>                            | cheek                                                                |
| 7. <b>brachium, ii, n.</b>                         | upper arm, brachium | 24. <b>collum, i, n.</b><br><b>cervix, icis, f.</b> | neck (mainly on bones)<br>neck, cervix (mainly on soft parts/organs) |
| 8. <b>cubitus, i, m.</b>                           | elbow               | 25. <b>pectus, oris, n.</b>                         | chest                                                                |
| 9. <b>antebrachium, ii, n.</b>                     | forearm             | 26. <b>abdomen, inis, n.</b>                        | belly, abdomen                                                       |
| 10. <b>carpus, i, m.</b>                           | wrist               | 27. <b>hypogastrium, ii, n.</b>                     | hypogastrium                                                         |
| 11. <b>pollex, icis, m.</b>                        | thumb               | 29. <b>truncus, i, m.</b>                           | trunk                                                                |
| 12. <b>palma, ae, f.</b>                           | palm (of the hand)  | 30. <b>manus, us, f.</b>                            | hand                                                                 |
| 13.,18. <b>digitus, i, m.</b>                      | finger              | 31. <b>crus, cruris, n.</b>                         | lower leg, shank                                                     |
| 14. <b>sulcus, i, m.</b> <sup>1</sup>              | fold, groove        | 32. <b>tarsus, i, m.</b><br><b>talus, i, m.</b>     | tarsus<br>anklebone, talus                                           |
| 15.,28. <b>penis, is m.</b>                        | penis               | 33. <b>pes, pedis, m.</b>                           | foot                                                                 |
|                                                    |                     | 34. <b>hallux, ucis, m.</b>                         | big toe                                                              |

<sup>1</sup> sulcus glutealis

**Skeleton**



LifeART Collection Images Copyright © 1989-2001 by Lippincott Williams & Wilkins, Baltimore, MD

- |     |                                    |                                            |                                      |                                   |
|-----|------------------------------------|--------------------------------------------|--------------------------------------|-----------------------------------|
| 0.  | <b>skeleton, i, n.</b>             | skeleton                                   | <b>scapula, ae, f.</b>               | shoulder blade, scapula           |
|     | <b>os, ossis, n.</b>               | bone                                       | 18. <b>sternum, i, n.</b>            | breastbone, sternum               |
|     | <b>cranium, ii, n.</b>             | skull                                      | 19. <b>humerus, i, m.</b>            | arm bone, humerus                 |
| 1.  | <b>orbita, ae, f.</b>              | orbit                                      | 20. <b>arcus, us, m.<sup>2</sup></b> | arch                              |
| 2.  | <b>collum, i, n.</b>               | neck (mainly on bones)                     | 21. <b>radius, ii, m.</b>            | radial bone, radius               |
|     | <b>cervix, icis, f.</b>            | neck, cervix (mainly on soft parts/organs) | 22. <b>ulna, ae, f.</b>              | elbow bone                        |
| 3.  | <b>thorax, acis, m.</b>            | thorax (chest with ribs)                   | 23. <b>metacarpus, i, m.</b>         | metacarpus                        |
| 4.  | <b>costa, ae, f.</b>               | rib                                        |                                      | wrist                             |
| 5.  | <b>discus, i, m.</b>               | disc                                       | 24. <b>phalanx, gis, f.</b>          | one of the finger bones, phalange |
| 6.  | <b>processus, us, m.</b>           | process (an outgrowth of tissue)           | 25. <b>femur, oris, n.</b>           | thighbone, femur                  |
| 7.  | <b>vertebra, ae, f.</b>            | vertebra                                   | 26. <b>patella, ae, f.</b>           | kneecap, patella                  |
| 8.  | <b>pelvis, is, f.</b>              | pelvis                                     | 27. <b>tibia, ae, f.</b>             | shinbone, tibia                   |
|     | <b>coxa, ae, f.</b>                | hip, hip joint                             | 28. <b>fibula, ae, f.</b>            | calf bone, fibula                 |
|     | <b>os ilii (ilium, ii, n.)</b>     | ilium                                      | 29. <b>metatarsus, i, m.</b>         | metatarsus                        |
| 9.  | <b>os sacrum (sacer, a, um)</b>    | sacral bone                                |                                      |                                   |
| 10. | <b>coccyx, gis, f.</b>             | tailbone, coccyx                           |                                      |                                   |
| 11. | <b>os ischii (ischium, ii, n.)</b> | ischium                                    |                                      |                                   |
| 12. | <b>os pubis (pubes, is, f.)</b>    | pubis                                      |                                      |                                   |
| 13. | <b>symphysis, is, f.</b>           | symphysis                                  |                                      |                                   |
| 14. | <b>nasus, i, m.</b>                | nose                                       |                                      |                                   |
| 15. | <b>dens, dentis, m.</b>            | tooth                                      |                                      |                                   |
| 16. | <b>mandibula, ae, f.</b>           | jawbone                                    |                                      |                                   |
| 17. | <b>clavicula, ae, f.</b>           | collar bone, clavicula                     |                                      |                                   |

<sup>2</sup> arcus costalis

