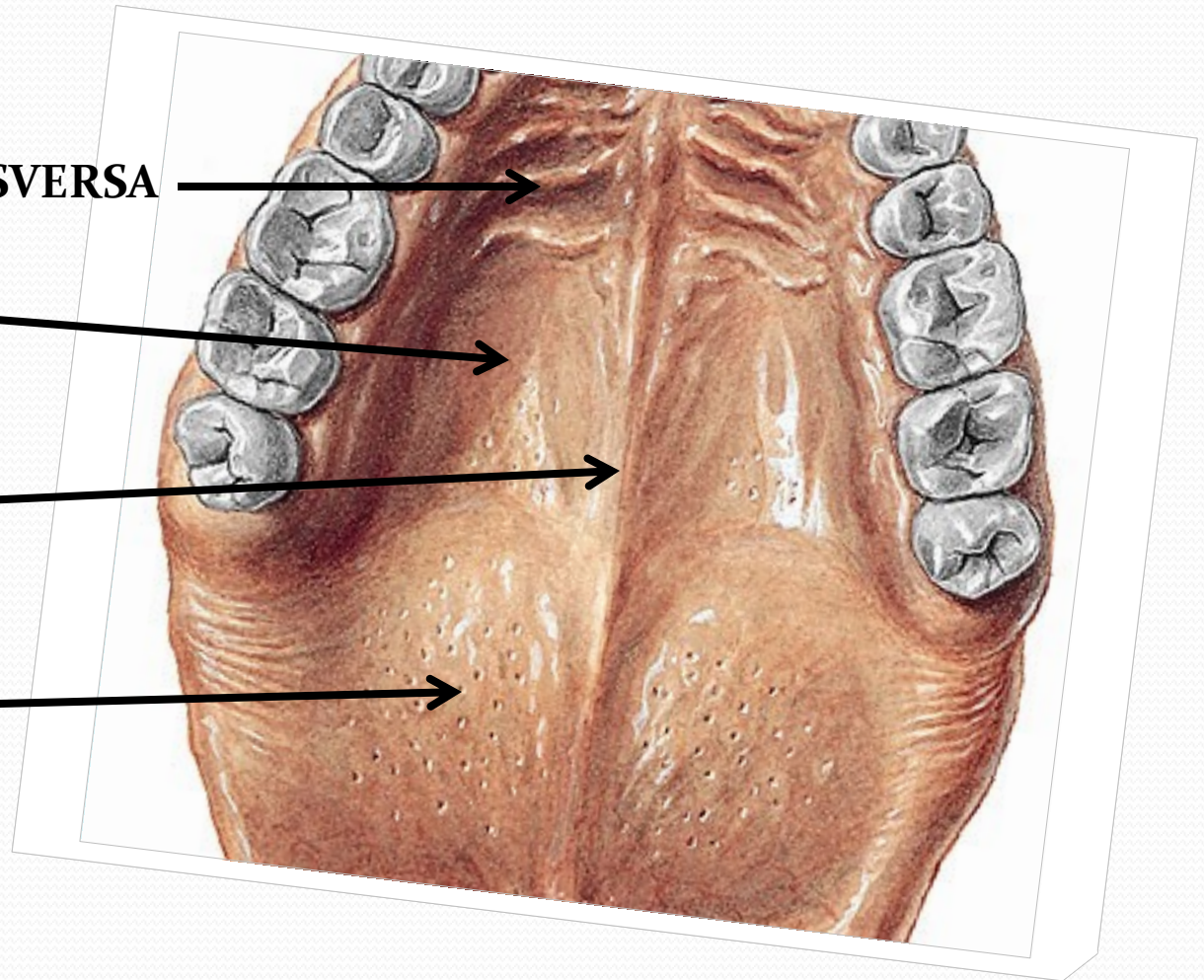


PLICA PALATINA TRANSVERSA

PALATUM DURUM

RHAPHE MEDIANA

VELUM



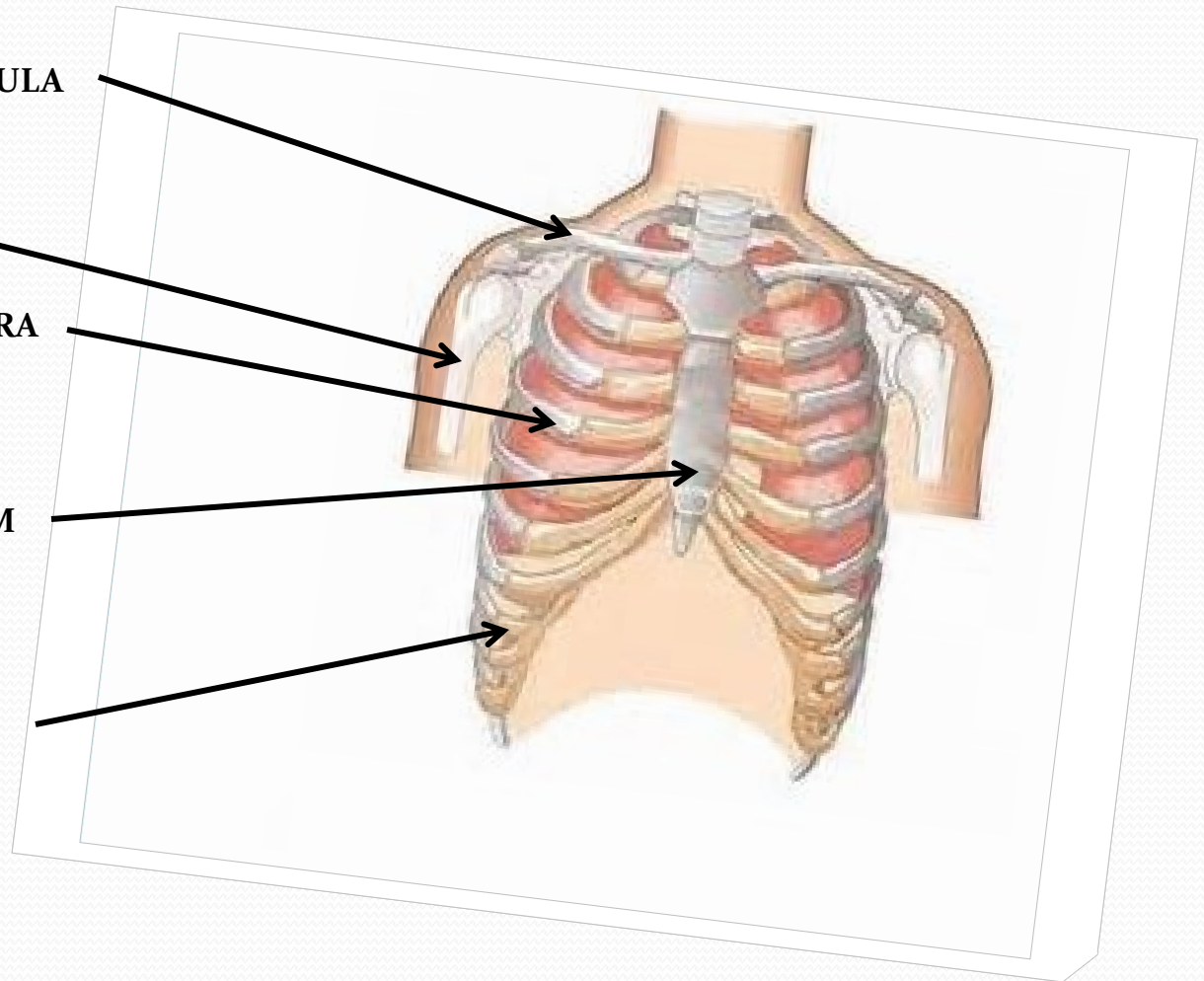
HUMERUS

CLAVICULA

COSTA VERA

STERNUM

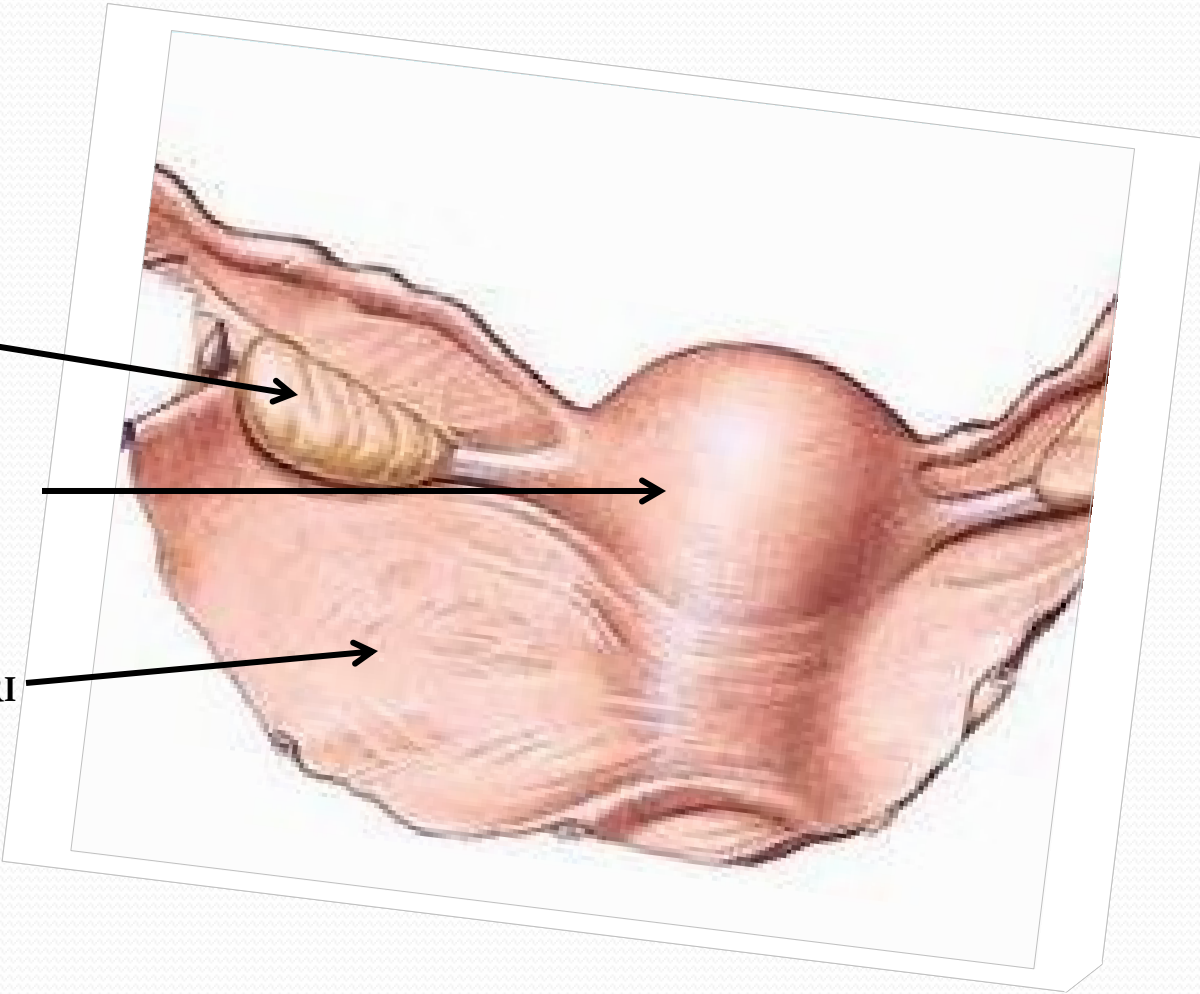
COSTA SPURIA



OVARIIUM

UTERUS

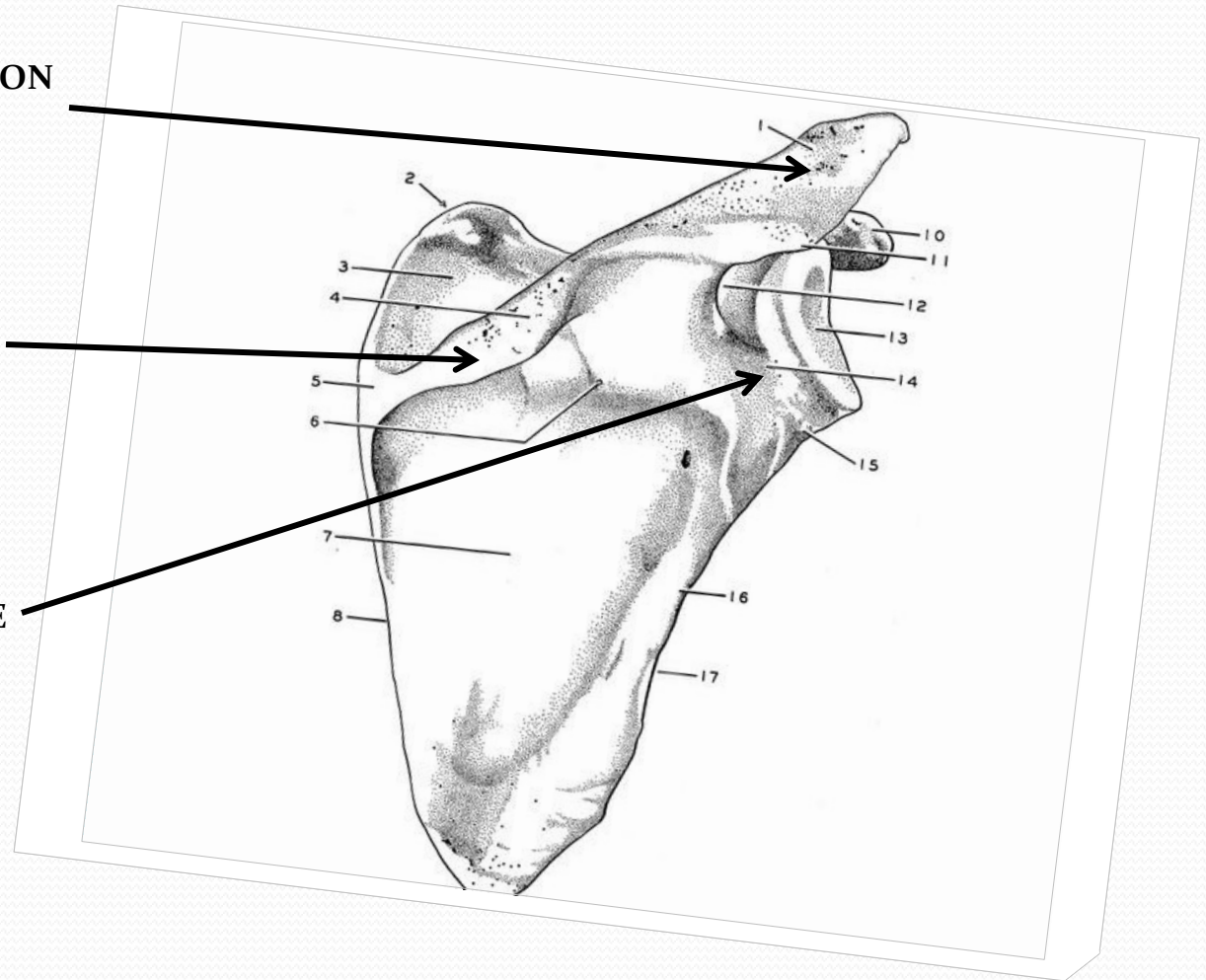
LIGAMENTUM LATUM UTERI



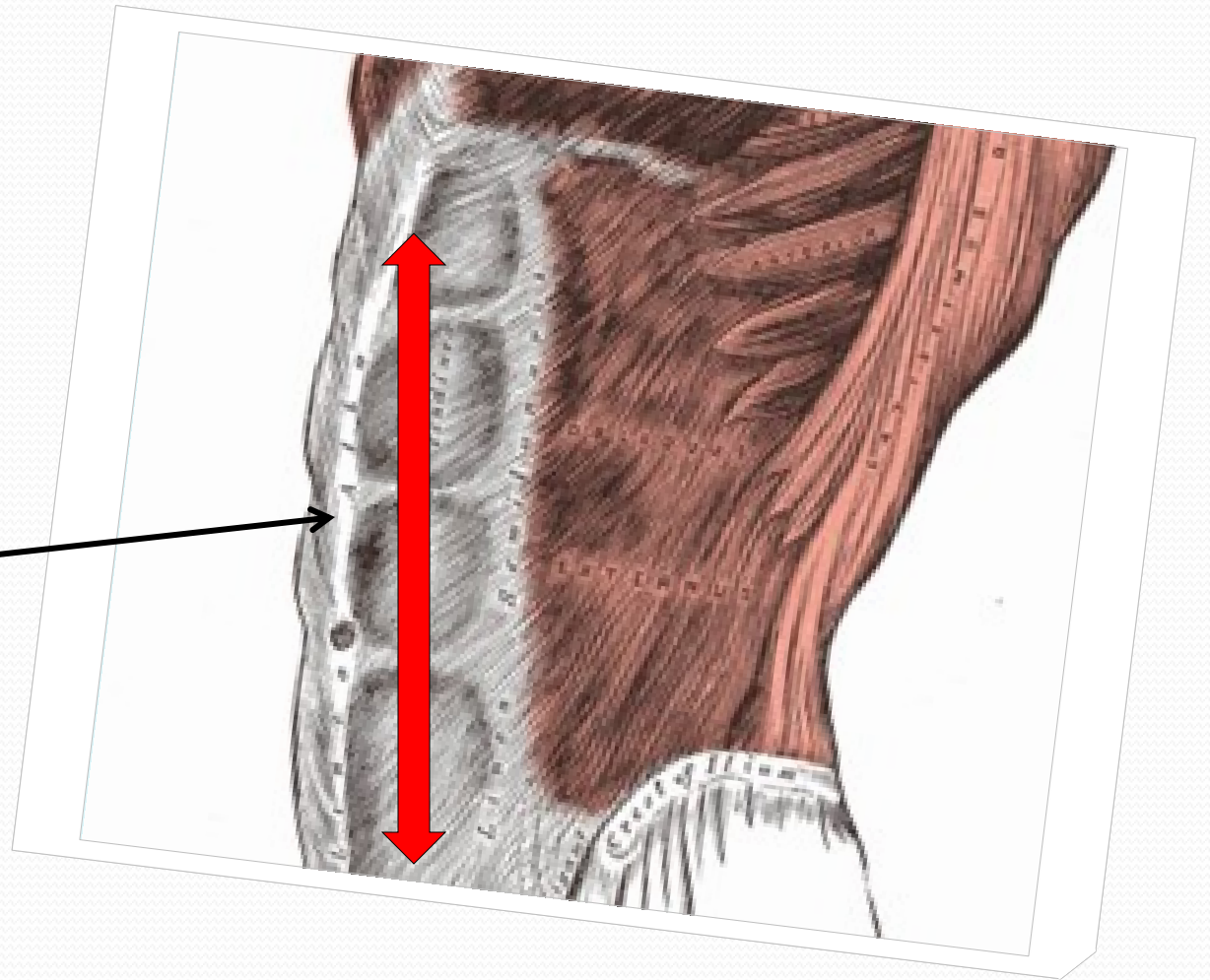
ACROMION

SPINA SCAPULAE

FOSSA SCAPULAE



LINEA ALBA

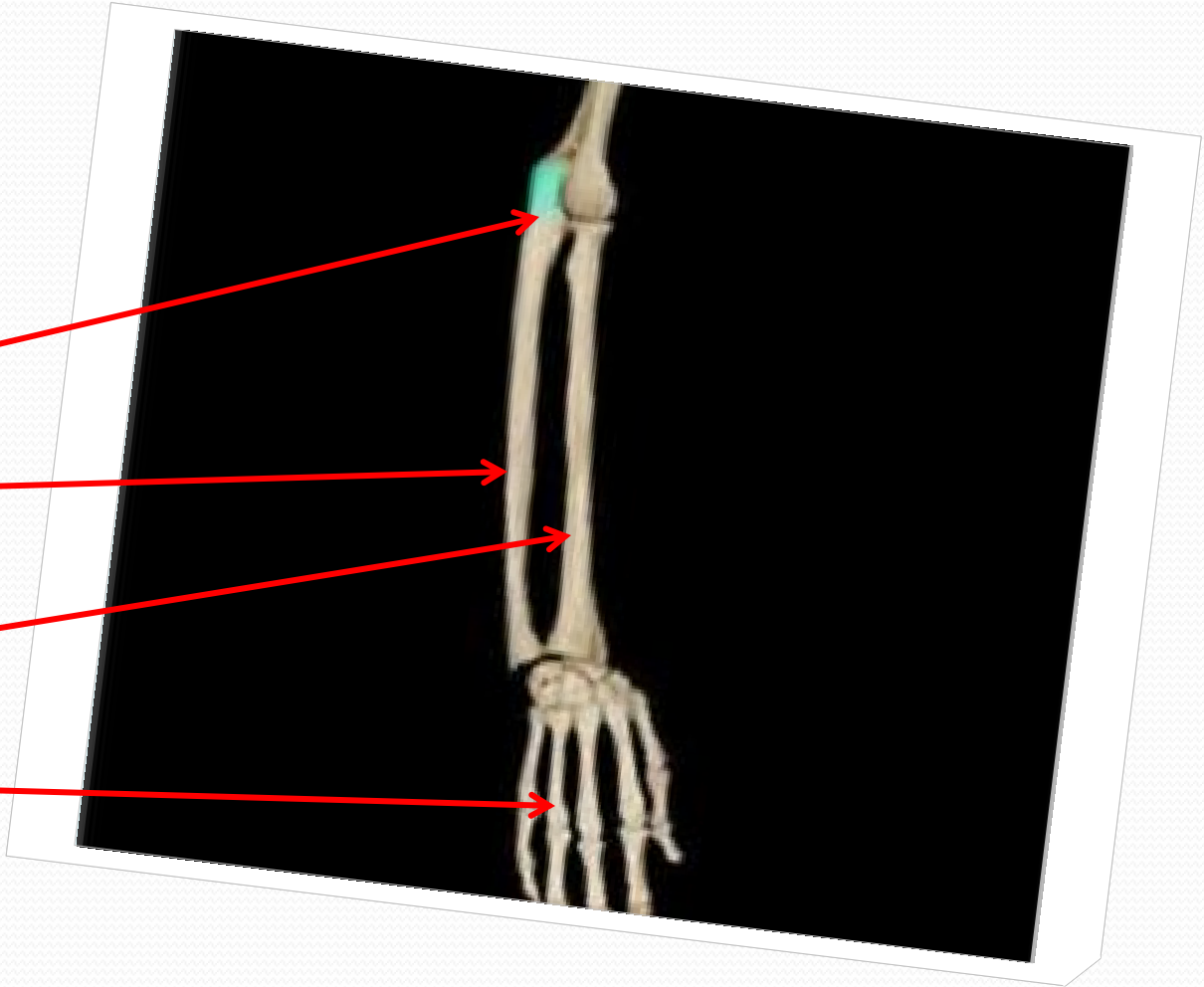


OLECRANON ULNAE

ULNA

RADIUS

DIGITI

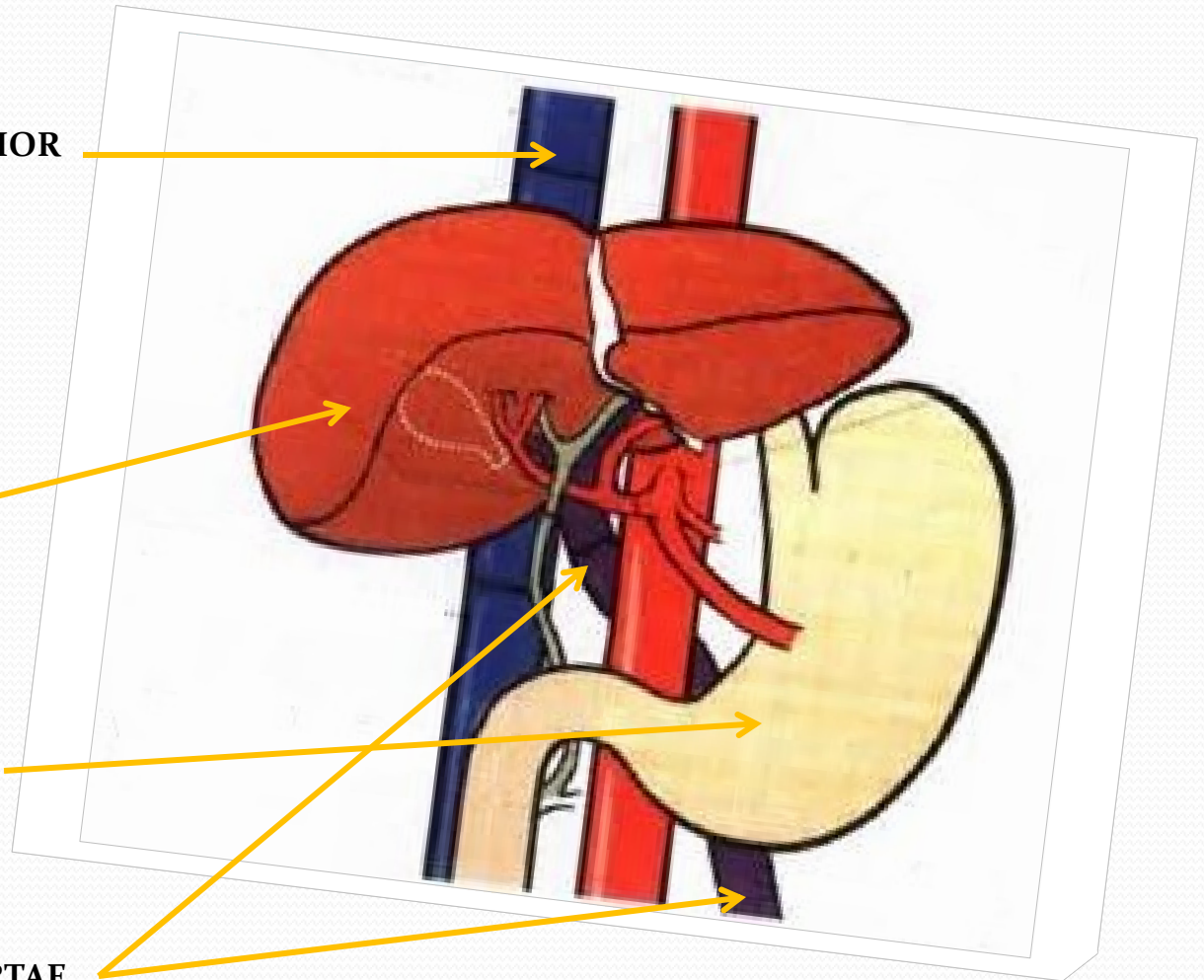


VENA CAVA INFERIOR

IECUR/HEPAR

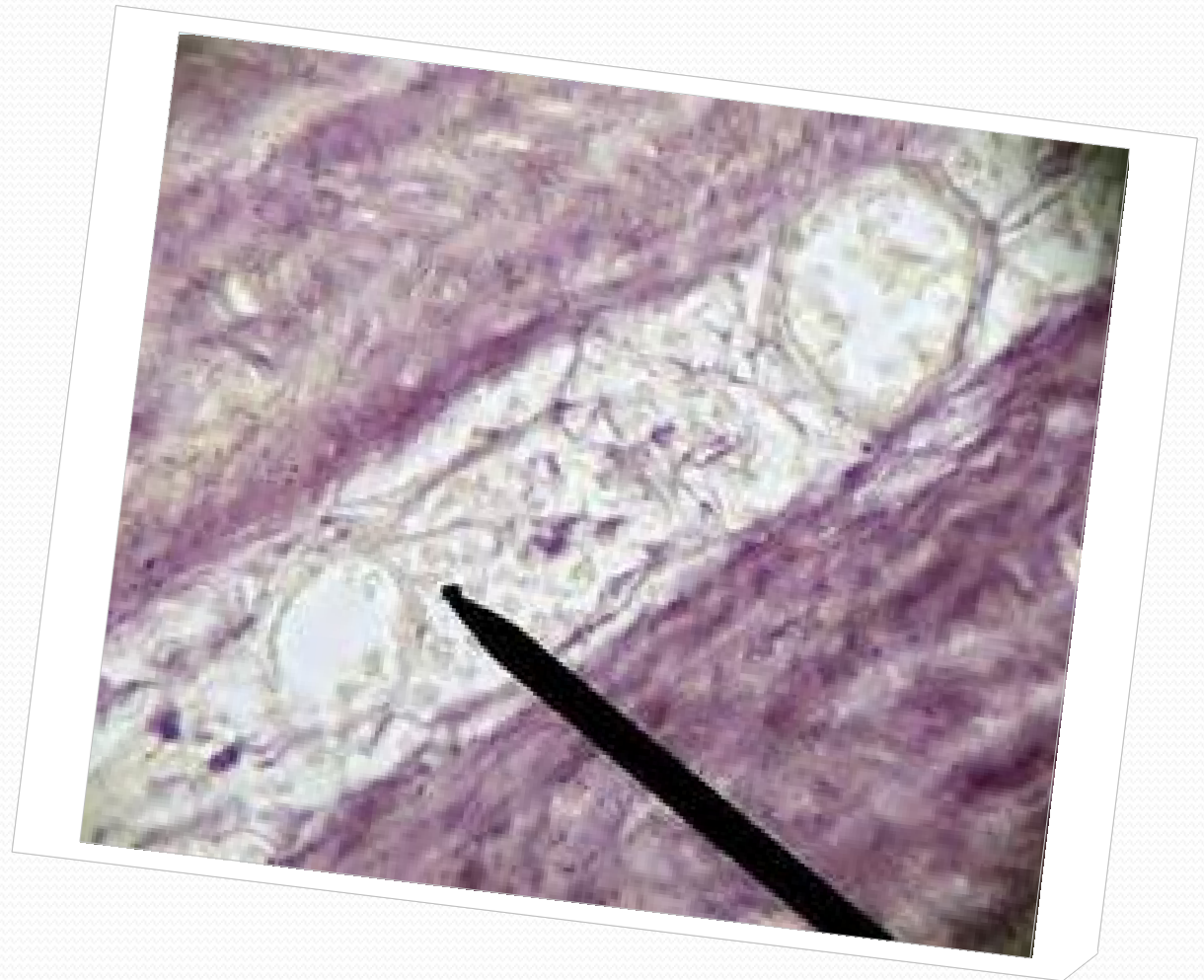
VENTRICULUS

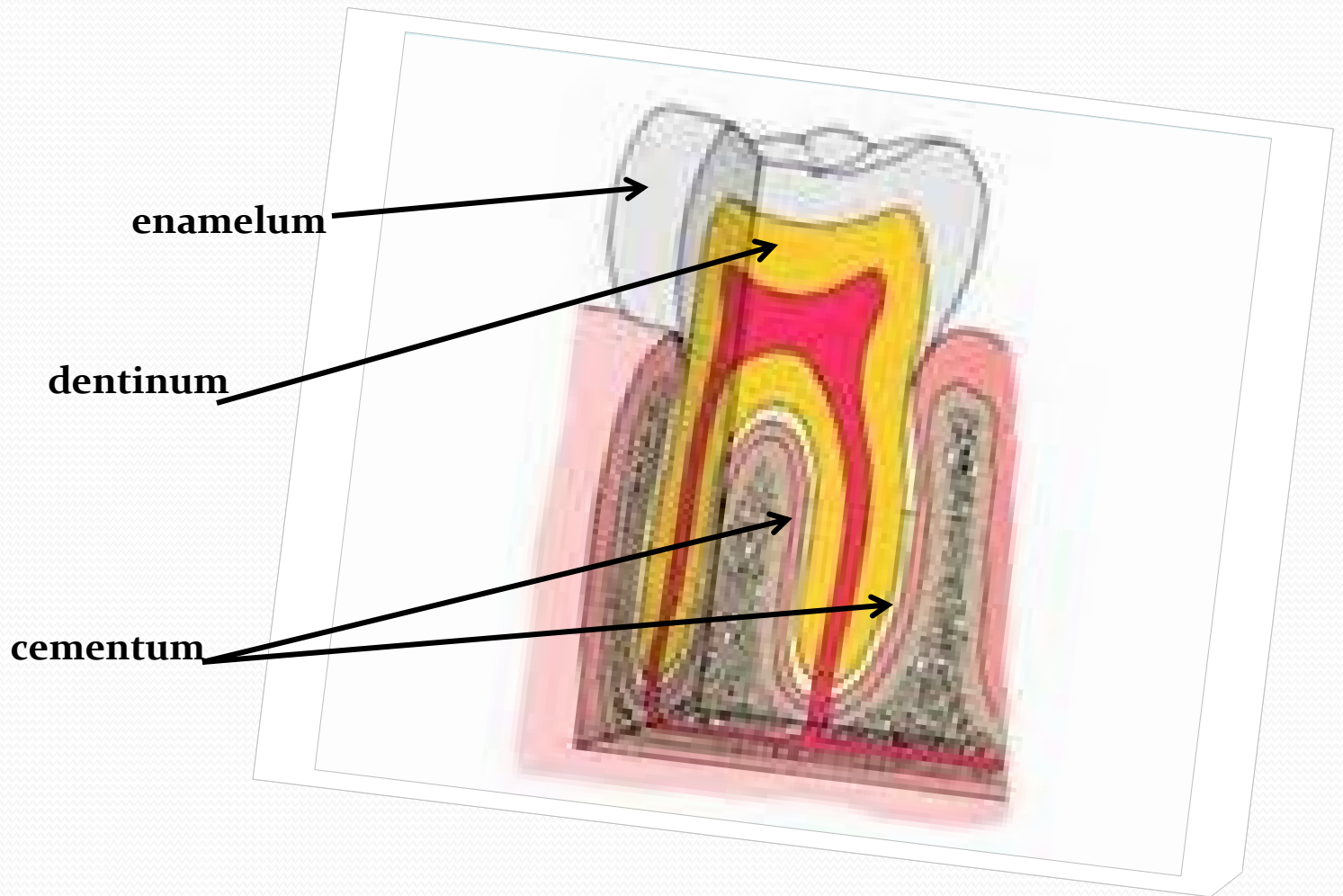
VENA PORTAE

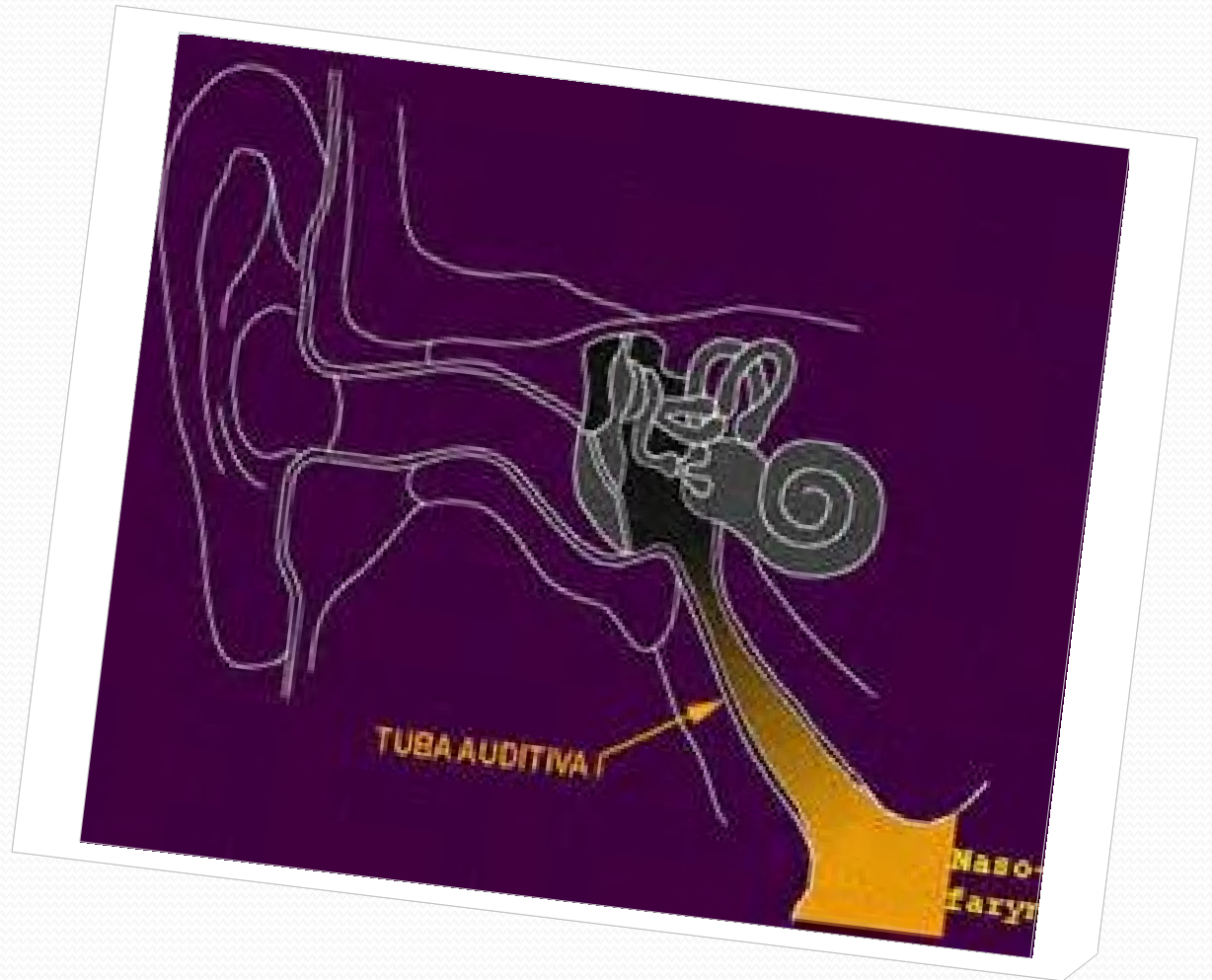


VASA VASORUM

small blood vessels that supply or drain the walls of the larger arteries and veins and connect with a branch of the same vessel or a neighboring vessel







medulla oblongata

