

**Institute for Microbiology, Medical Faculty of Masaryk University  
and St. Anna Faculty Hospital in Brno**

**Miroslav Votava, Vladana Woznicová**

# **Skin infections**

# Infections with skin symptoms

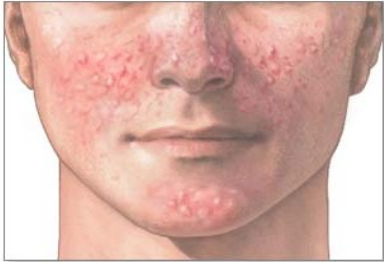
- **primary skin infections**
- **secondary infections of already diseased skin**
- **skin symptoms of systemic infections**

**Etiology:** - bacterial  
- viral  
- fungal  
- parasitic

# **Bacterial skin infections**

# Primary acute bacterial skin infections – I

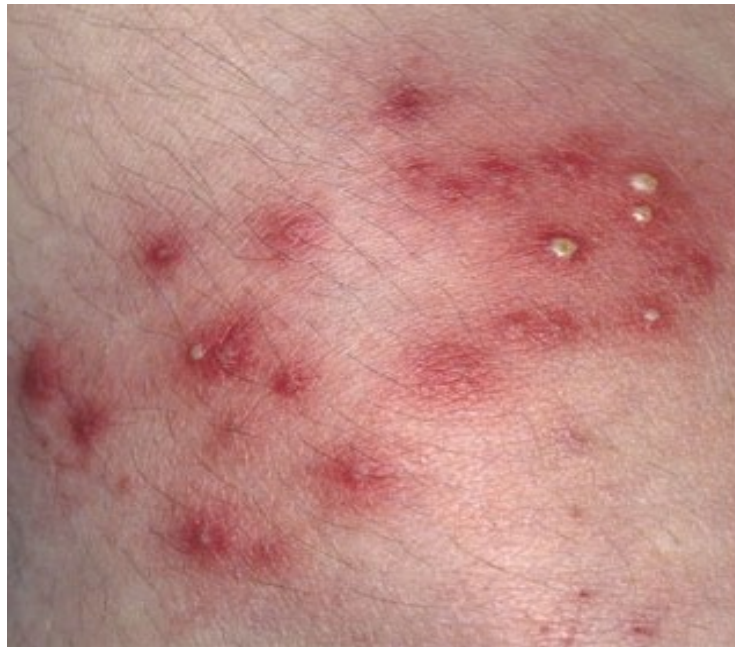Adult facial acne



***Propionibacterium acnes* – acne vulgaris**

***Staphylococcus aureus* - folliculitis**

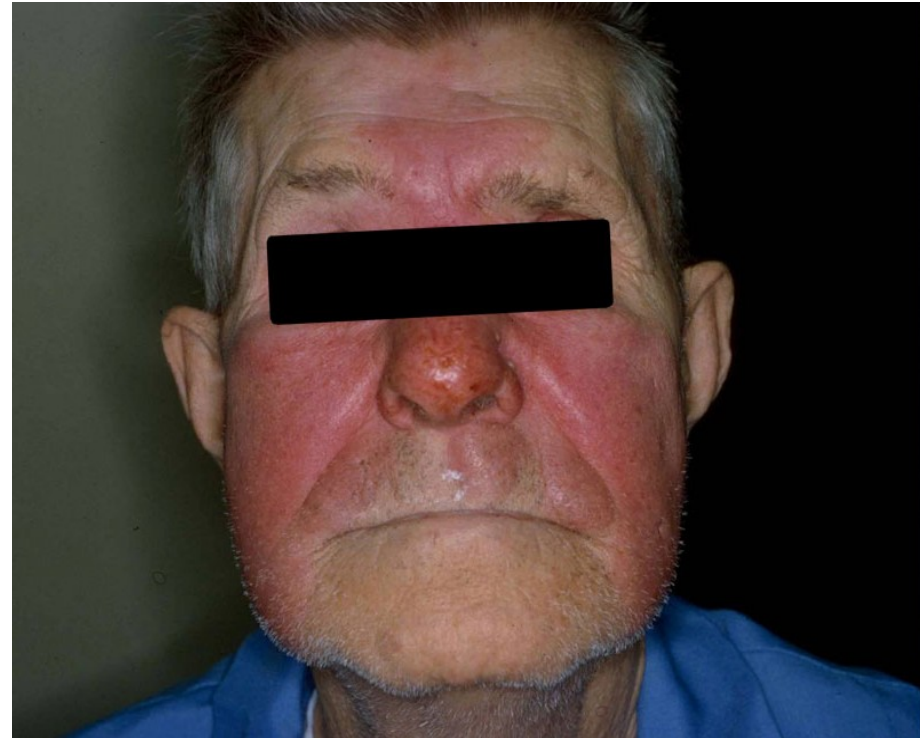ADAM.



# Primary acute bacterial skin infections – II

## erysipelas – *Streptococcus pyogenes* (GAS)

- local redness, heat, swelling, and a highly characteristic raised, indurated border, **no localized purulence**
- the **legs and face** are the most frequently affected sites
- on the face is a **butterfly distribution** involving the cheeks and the bridge of the nose



# Primary acute bacterial skin infections – III

**hordeolum (stye)**

– *Staph. aureus*

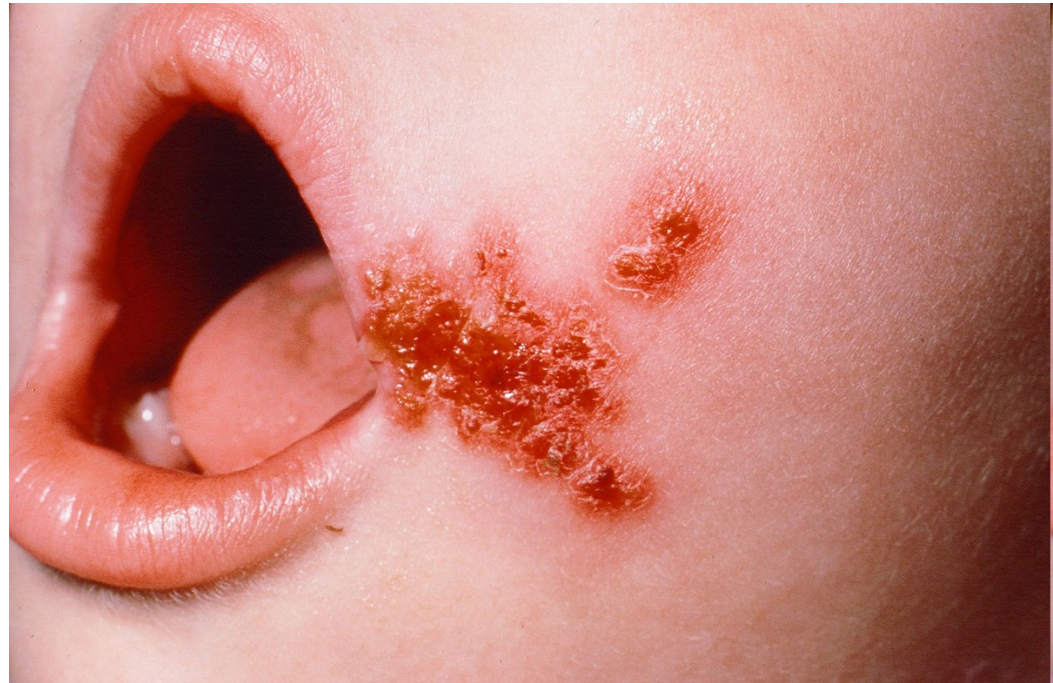**Impetigo !** →

- *Staph. aureus*,

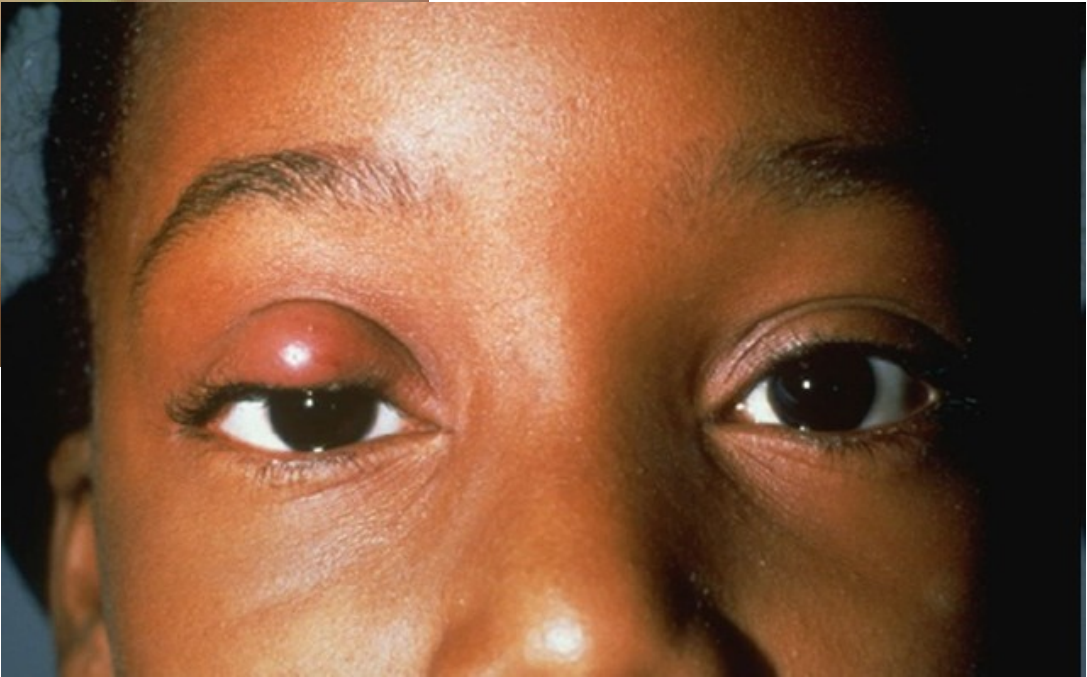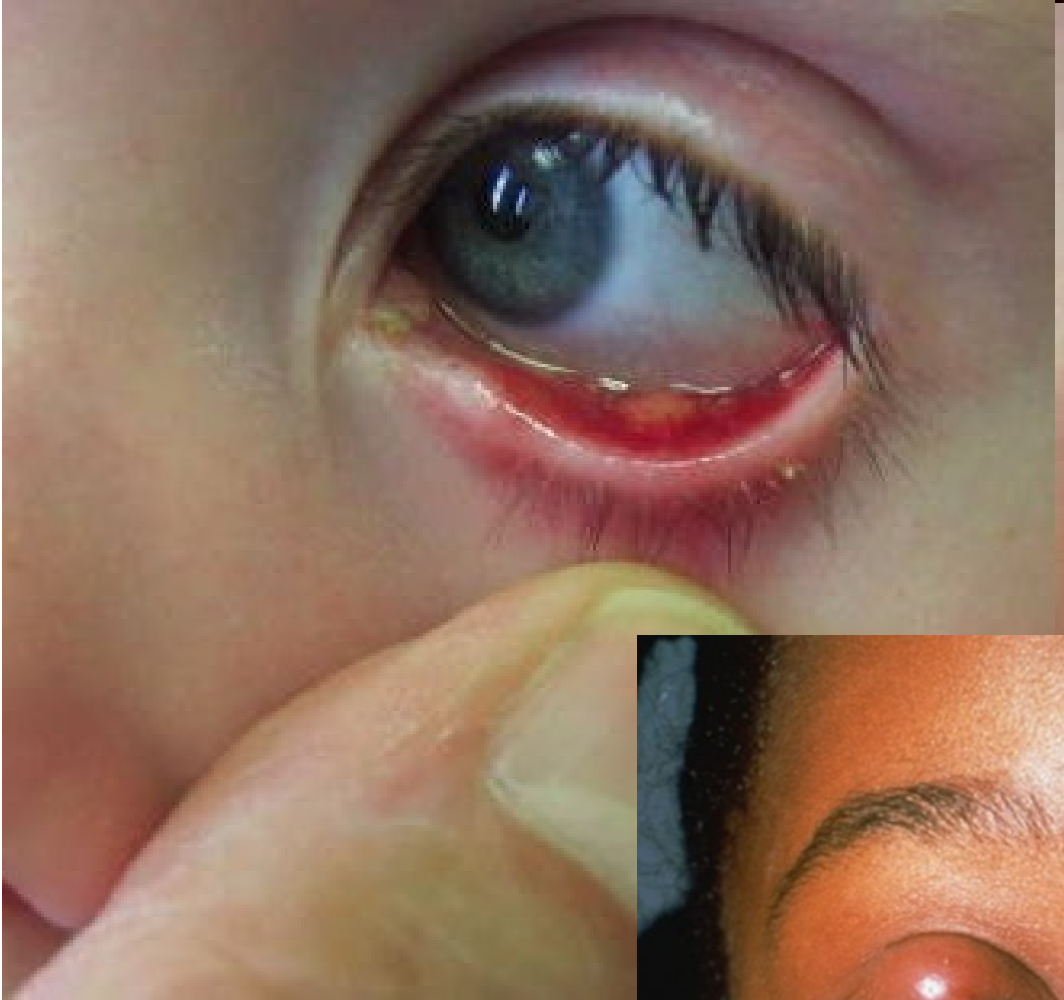- *Str. pyogenes*

**lymphangoitis**

– *Strept. pyogenes*



**Stye**



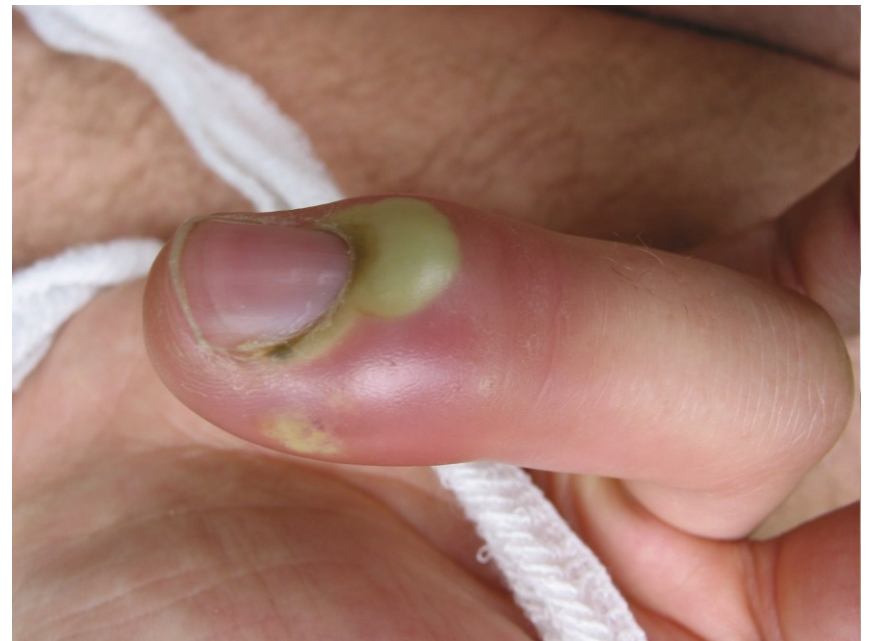# Primary acute bacterial skin infections – IV

**Panaritium (whitlow)**

***Staphylococcus aureus***

**paronychia**

***Staphylococcus aureus***

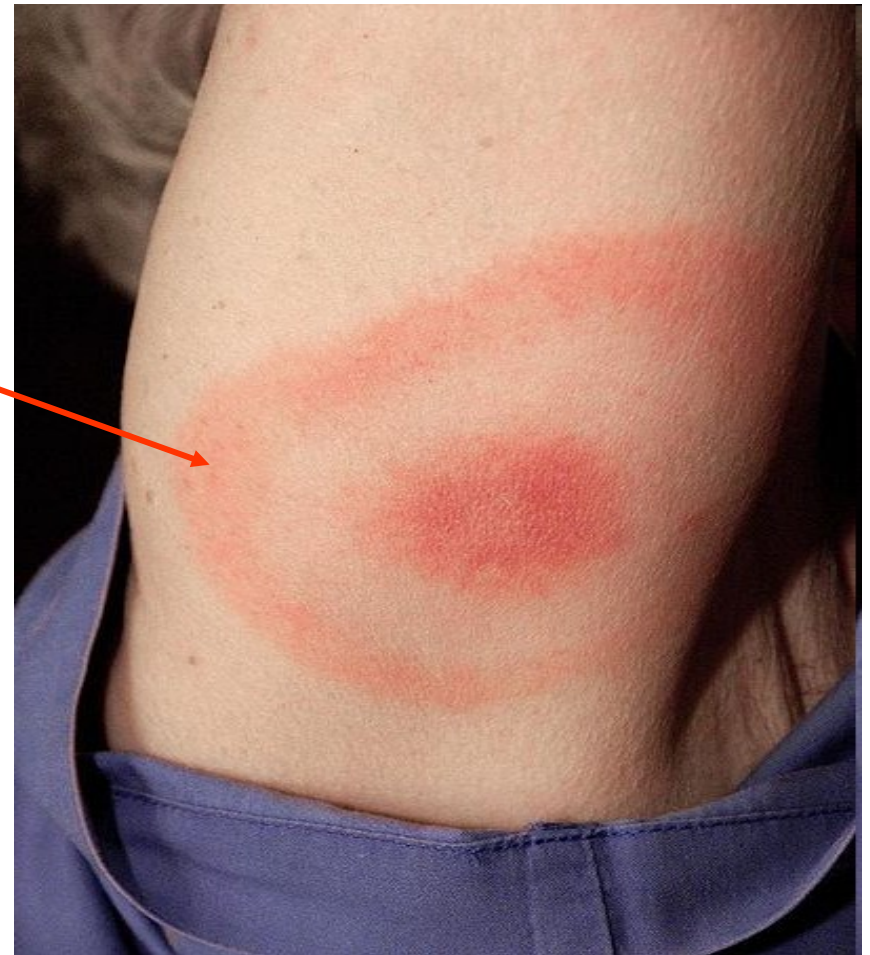



# Primary acute bacterial skin infections – V

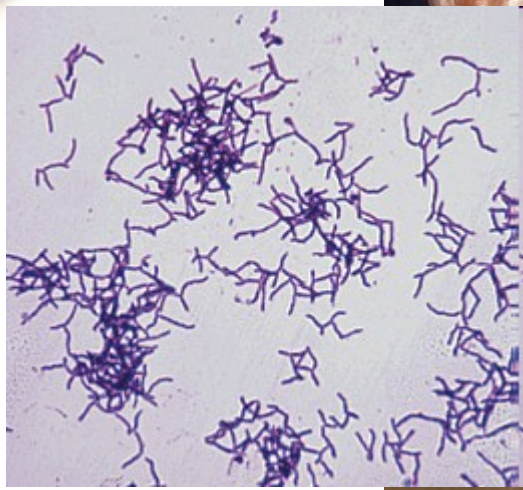
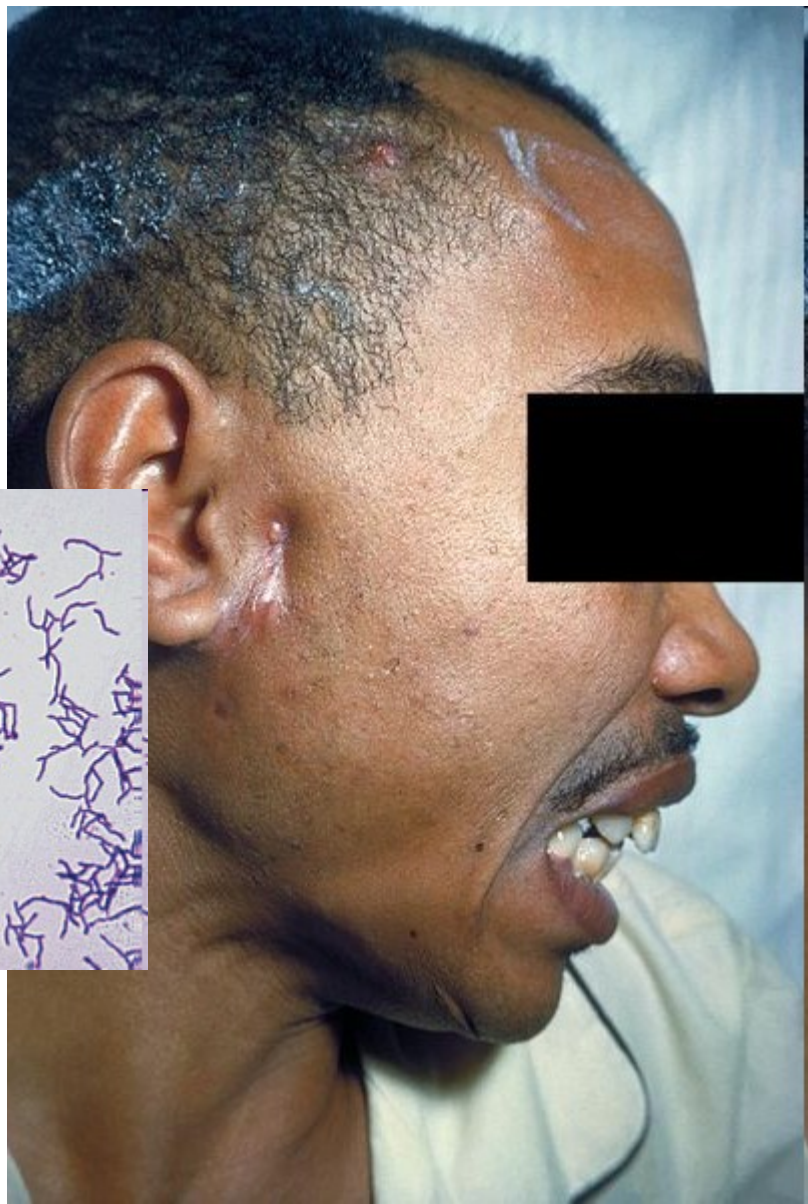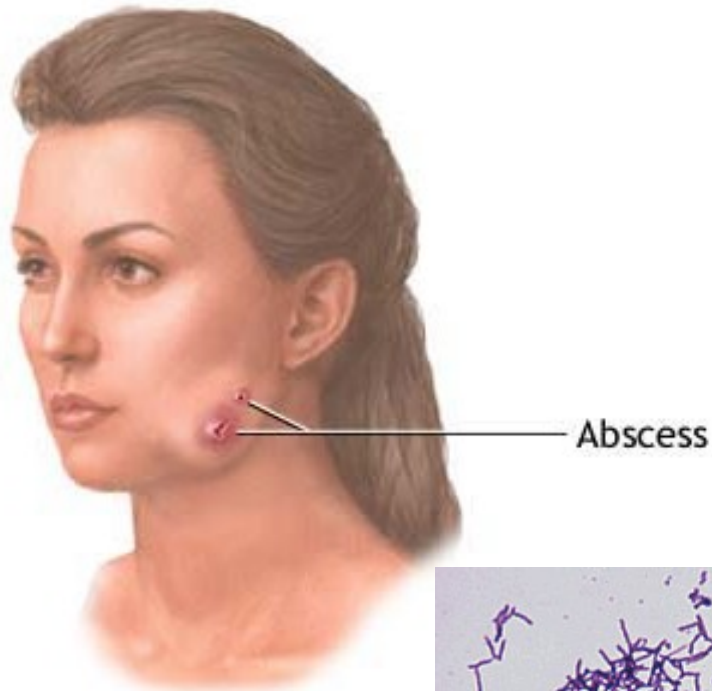
## **erythema migrans –** *Borrelia burgdorferi*

- ticks (*Ixodes ricinus*)
- serology, PCR
- doxycycline in adults



# Primary chronic bacterial skin infections

- actinomycosis ! - *Actinomyces israelii*
- **chronic subcutaneous abscesses** -  
*A. israelii, Nocardia asteroides, Rhodococcus equi*
- **skin granulomas** -  
*Mycobacterium marinum, M. haemophilum, M. chelonae*
- **leprosy** - *Mycobacterium leprae*
- *Mycobacterium tuberculosis* – lupus vulgaris



**actinomycosis** – *Actinomyces israelii*

# Skin symptoms of systemic bacterial infections

**roseola** (rash in typhoid fever) – *Salmonella Typhi*

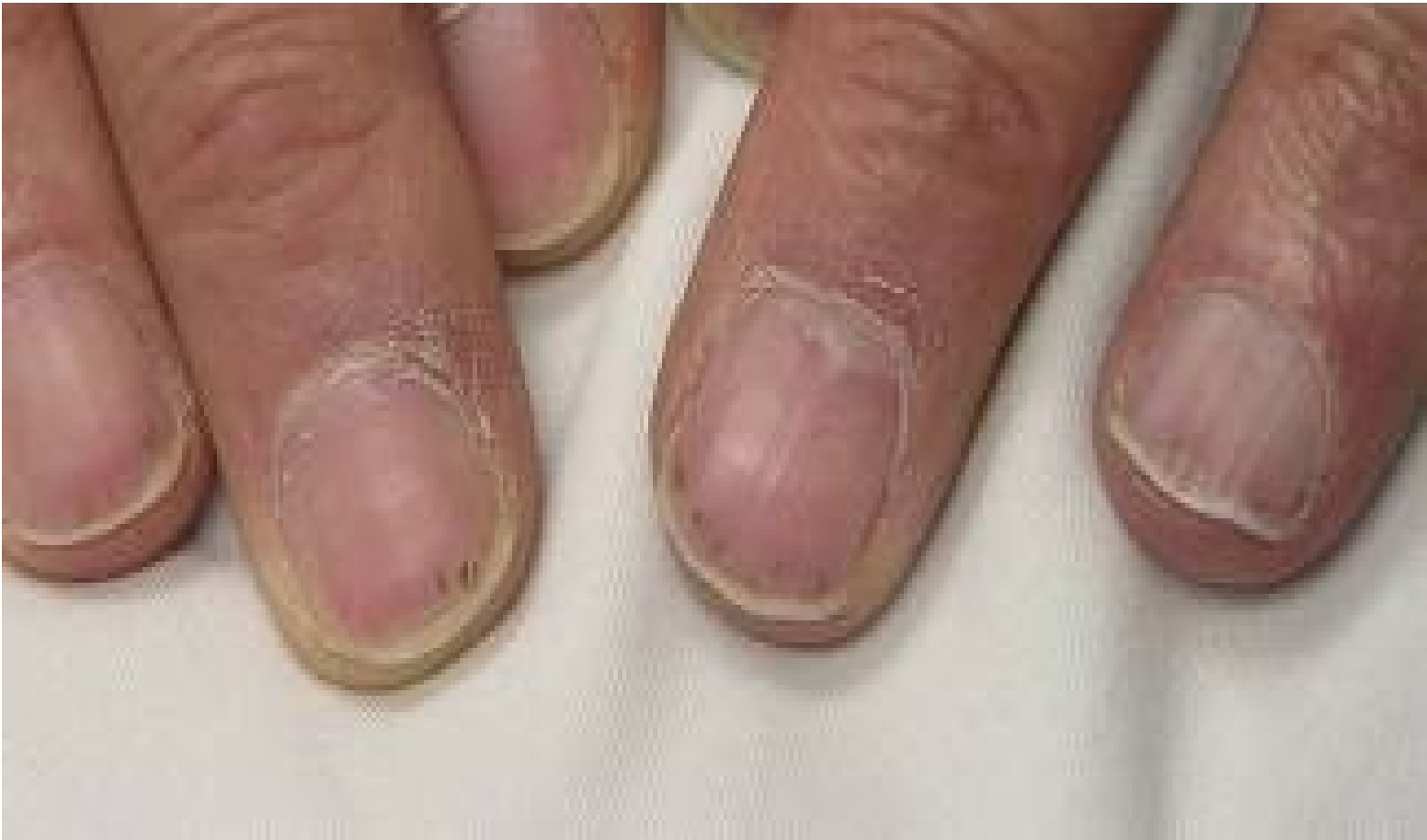**disseminated gonorrhoea** – *Neisseria gonorrhoeae*

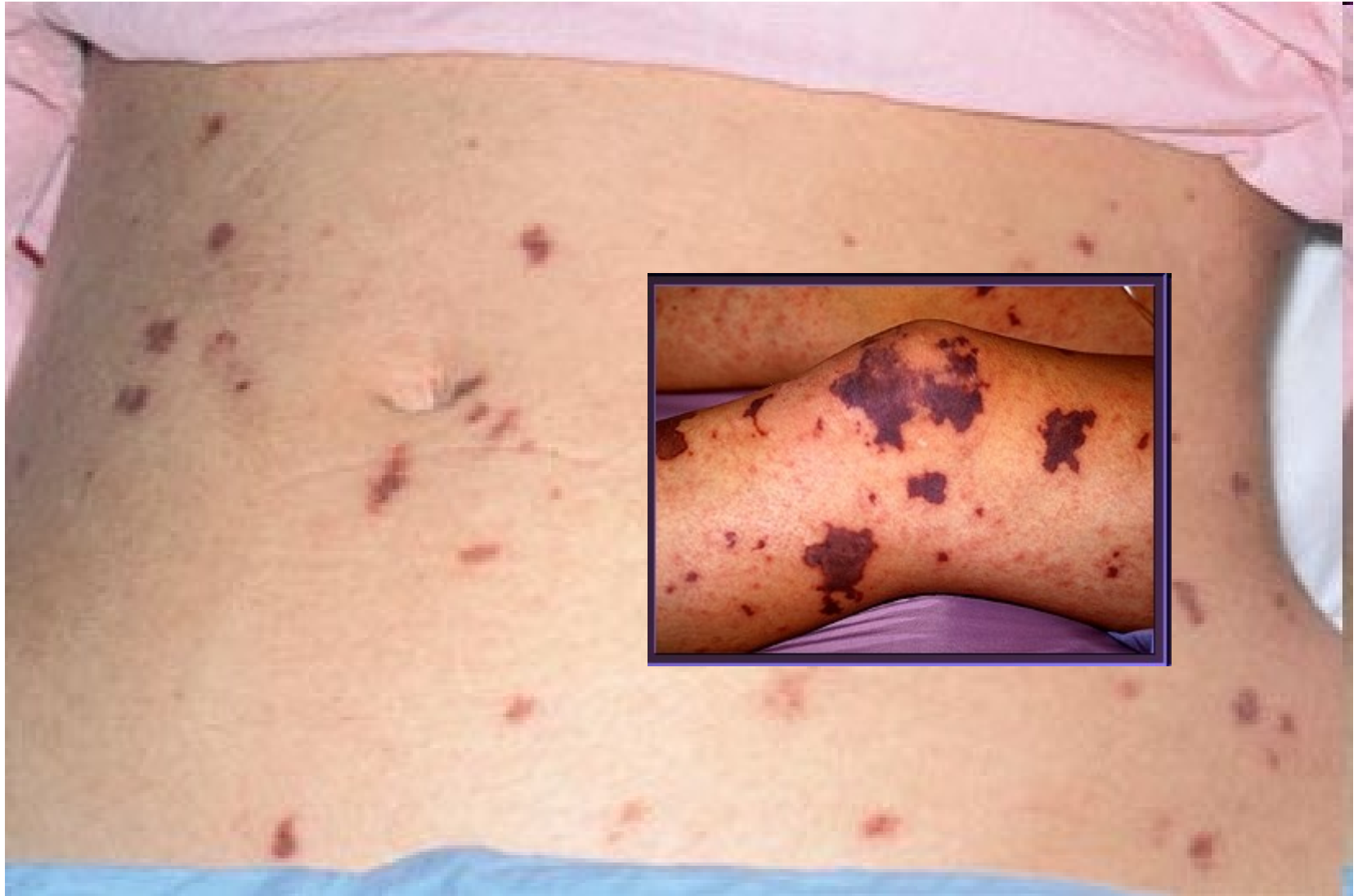**meningococemia** – *Neisseria meningitidis*

**scarlatina** (scarlet fever) – *Streptococcus pyogenes*

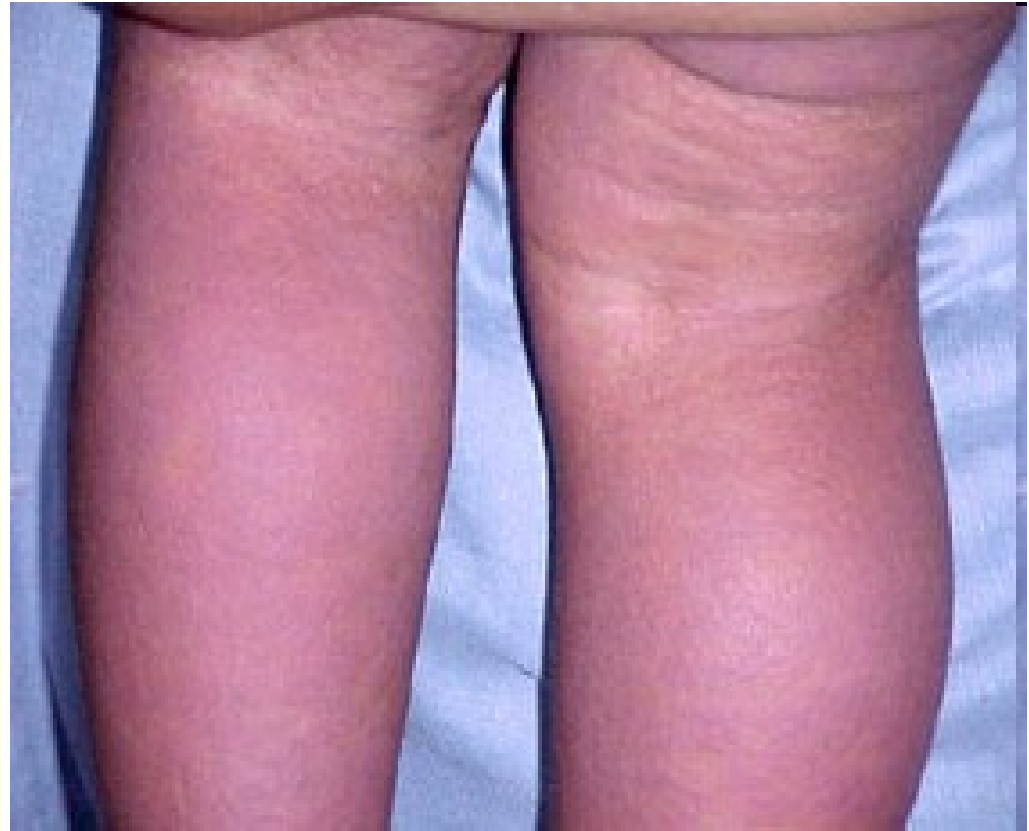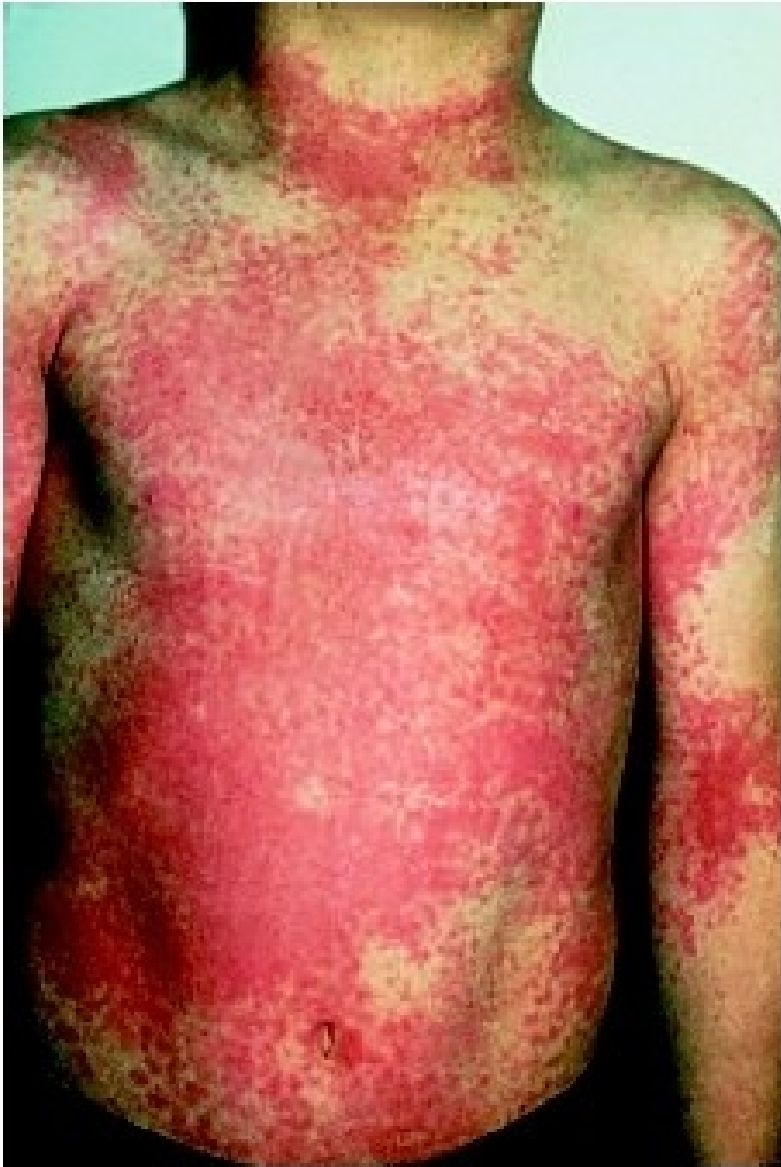**syphilis** – *Treponema pallidum*

## Infective endocarditis – splinter haemorrhages





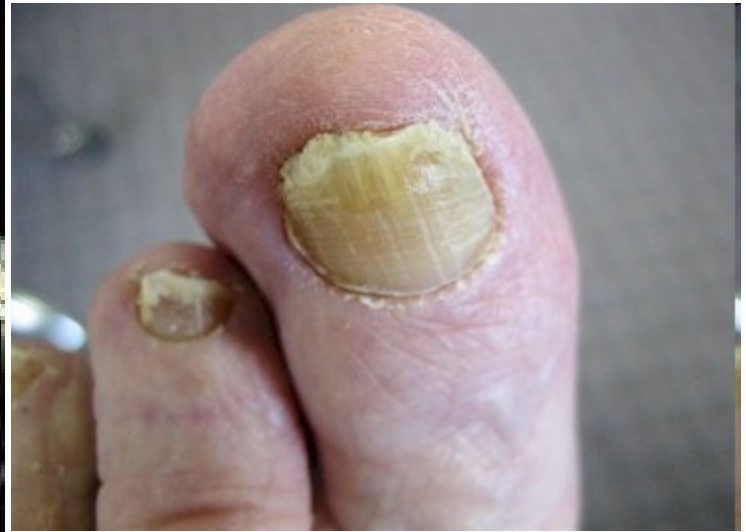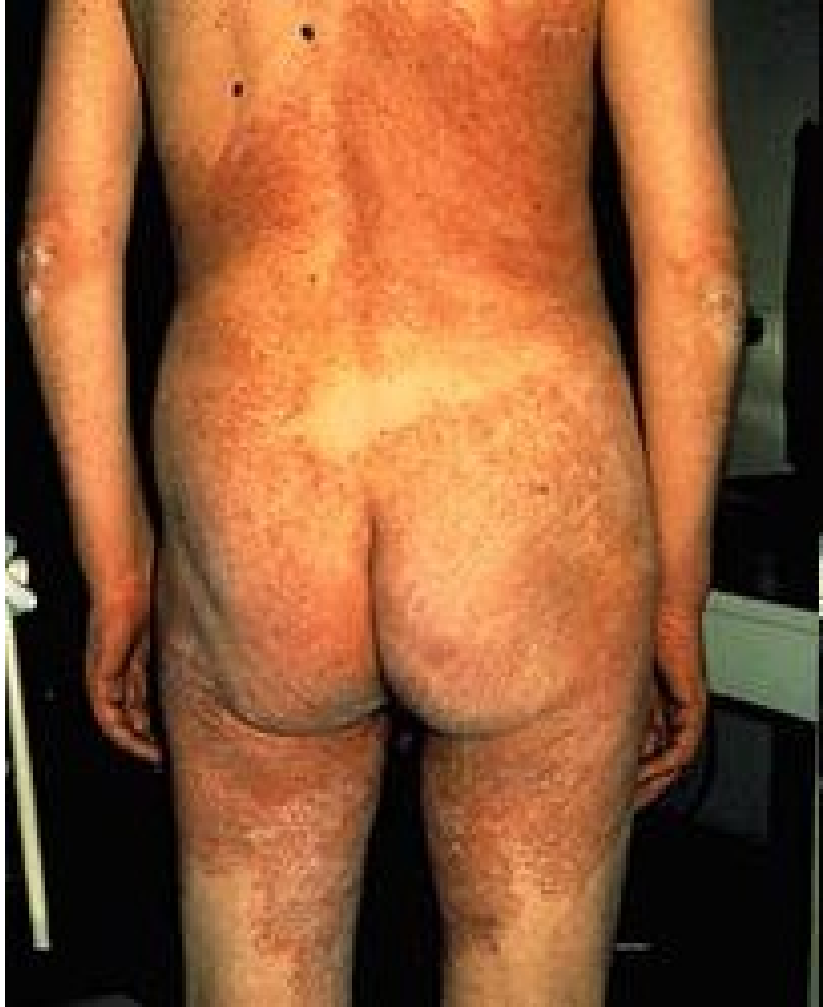**Rash - meningococemia – *Neisseria meningitidis***



**scarlatina** (scarlet fever) – *Streptococcus pyogenes*

# Fungal infections





**cutaneous mycoses**

# Etiology of cutaneous mycoses

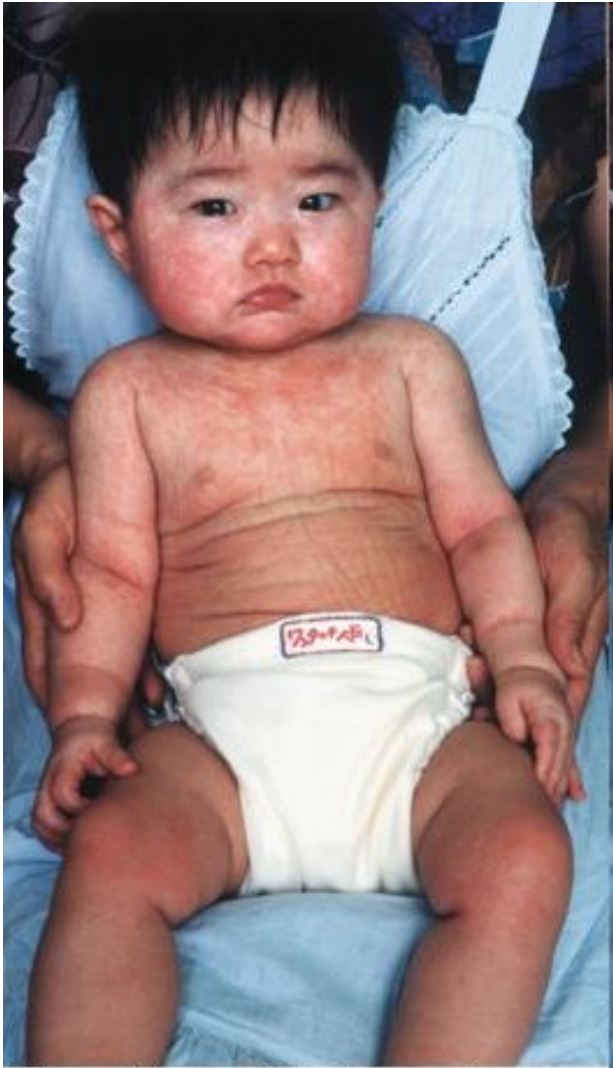**Tinea pedis** – *Trichophyton rubrum*,  
*Trich. mentagrophytes* var. *interdigitale*,  
*Epidermophyton floccosum*

**Onychomycosis** – *T. rubrum*, *E. floccosum*

**Tinea corporis** – *T. rubrum*, *Microsporum canis*,  
*M. gypseum*, *E. floccosum*

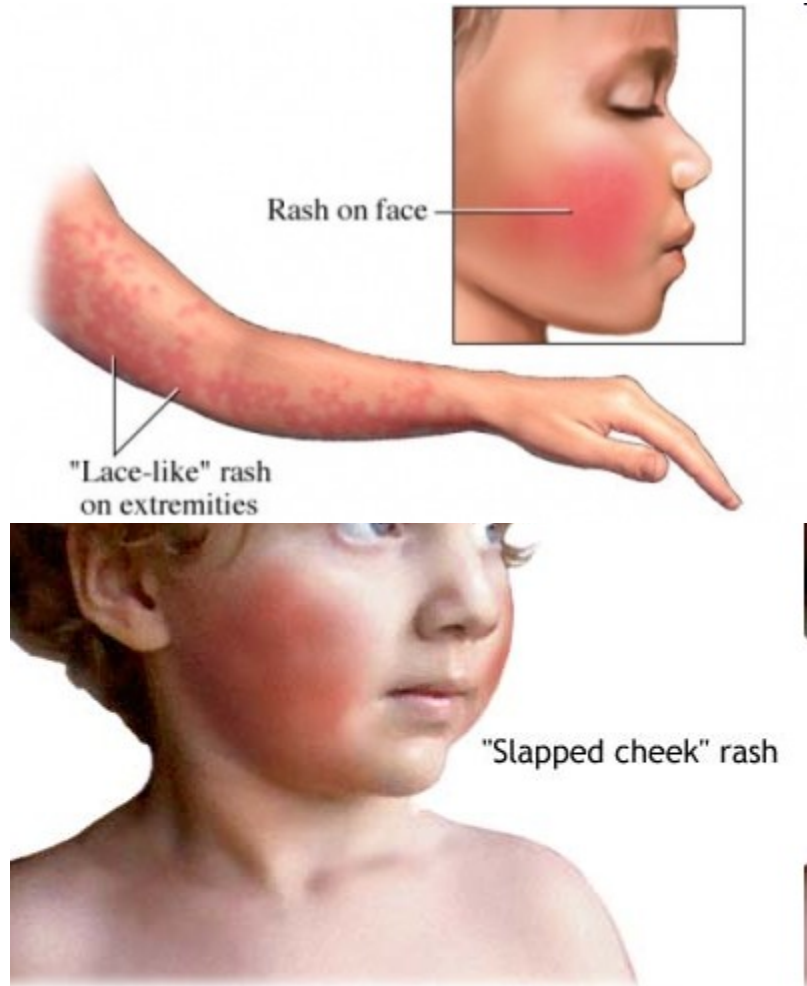
**Tinea capitis** – *M. gypseum*, *M. canis*, *M. audouinii*

# **Viral infections**



Medscape® <http://www.medscape.com>

**Sixth Disease/ Exanthem subitum,**  
**Roseola infantum, "Sudden**  
**Rash", rose rash of infants,**  
**3-day fever**



ADAM.

**Fifth Disease/Erythema**  
**infectiosum - Erythrovirus**  
**(Parvovirus) B19**

# Skin symptoms in viral diseases – I

## *Macular (spotted) exanthem:*

**morbilli** – morbilli virus, *Morbillivirus* genus

**rubella** – rubella virus, *Rubivirus* genus

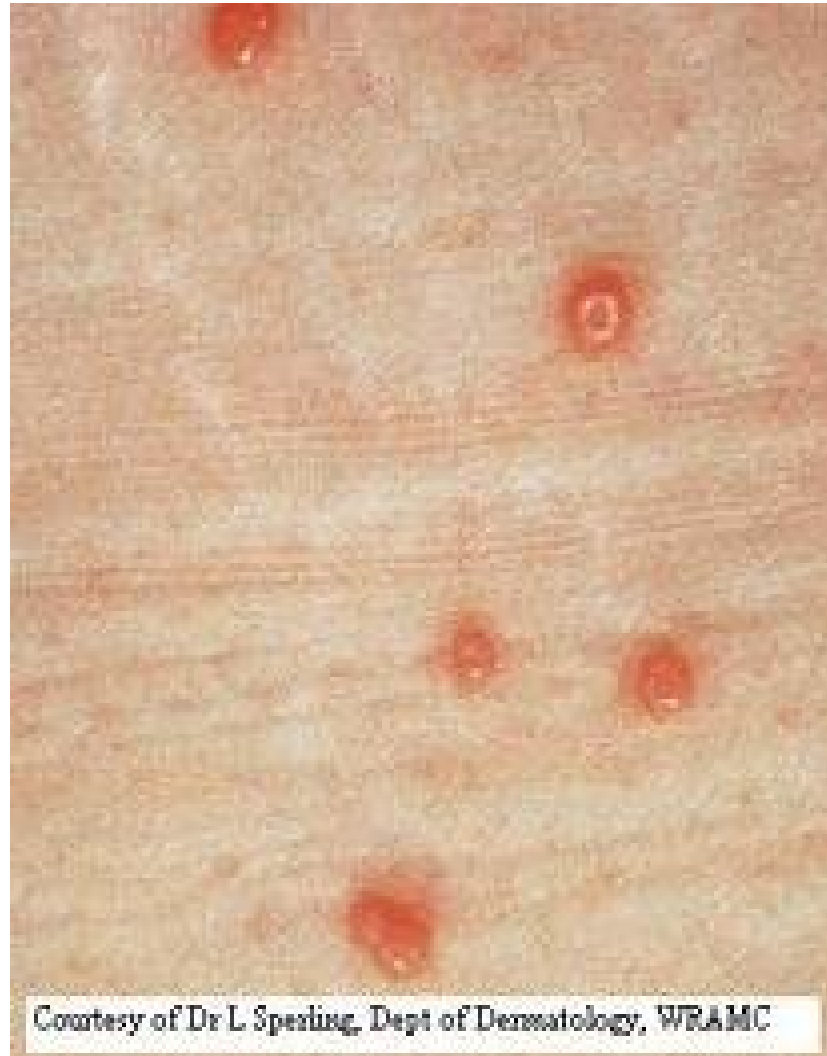**erythema infectiosum** (the **fifth** disease) –  
parvovirus B19, *Erythrovirus* genus

**exanthema subitum** (roseola infantum, the **sixth**  
disease) – HHV 6, *Roseolovirus* genus

## *Umbiliform papulae:*

**molluscum contagiosum** – molluscum  
contagiosum virus, *Molluscipoxvirus* genus

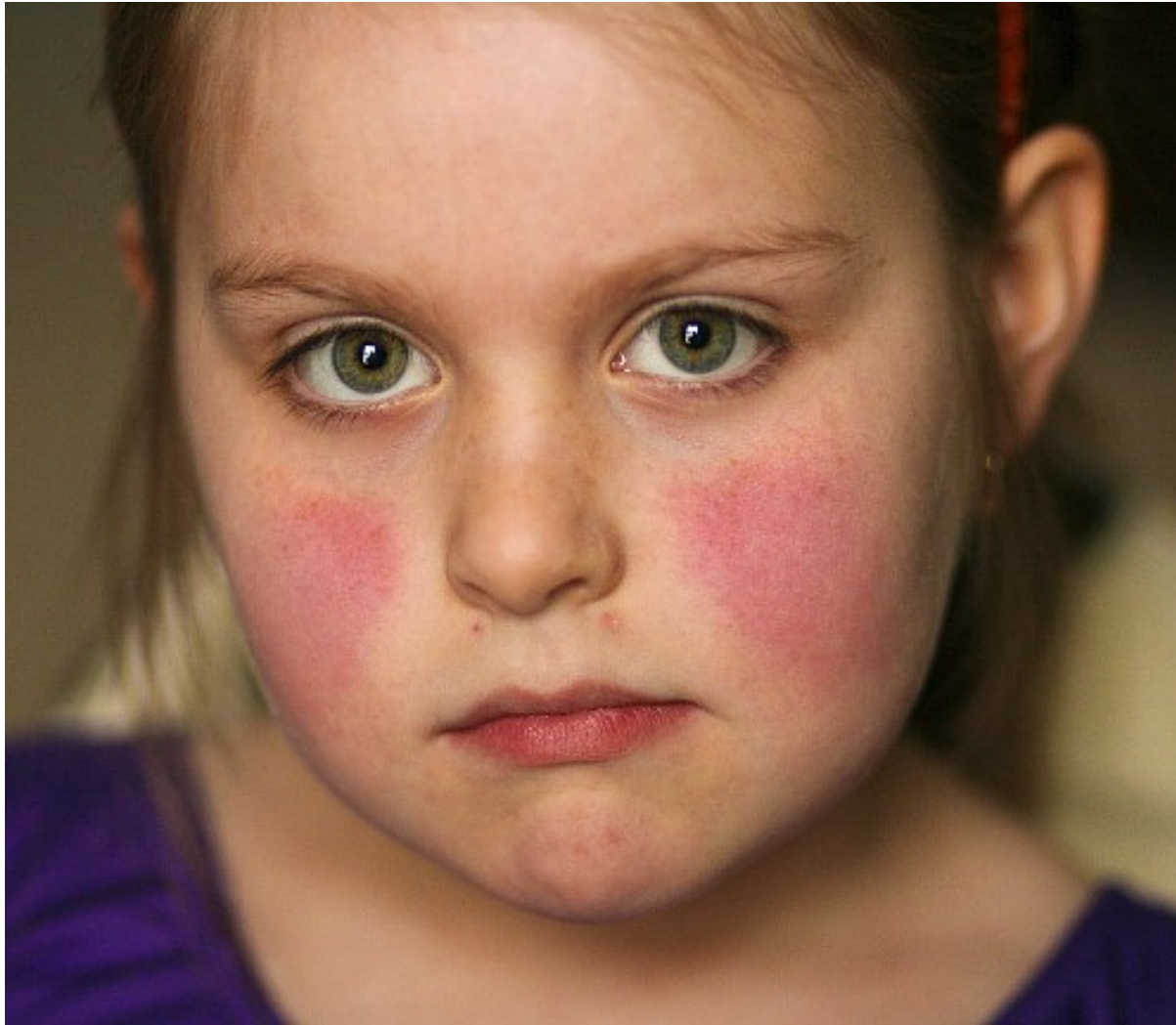**Typical molluscum bumps. Note the pearly appearance and the dimple in the center of the bumps.**



[cdc.gov](http://cdc.gov)

v

# Fifth Disease/Erythema infectiosum



<http://img405.imageshack.us>

# Skin symptoms in viral diseases – II

## *Vesicles:*

**herpes simplex (cold sore) – HSV 1**

**herpes genitalis – HSV 2**

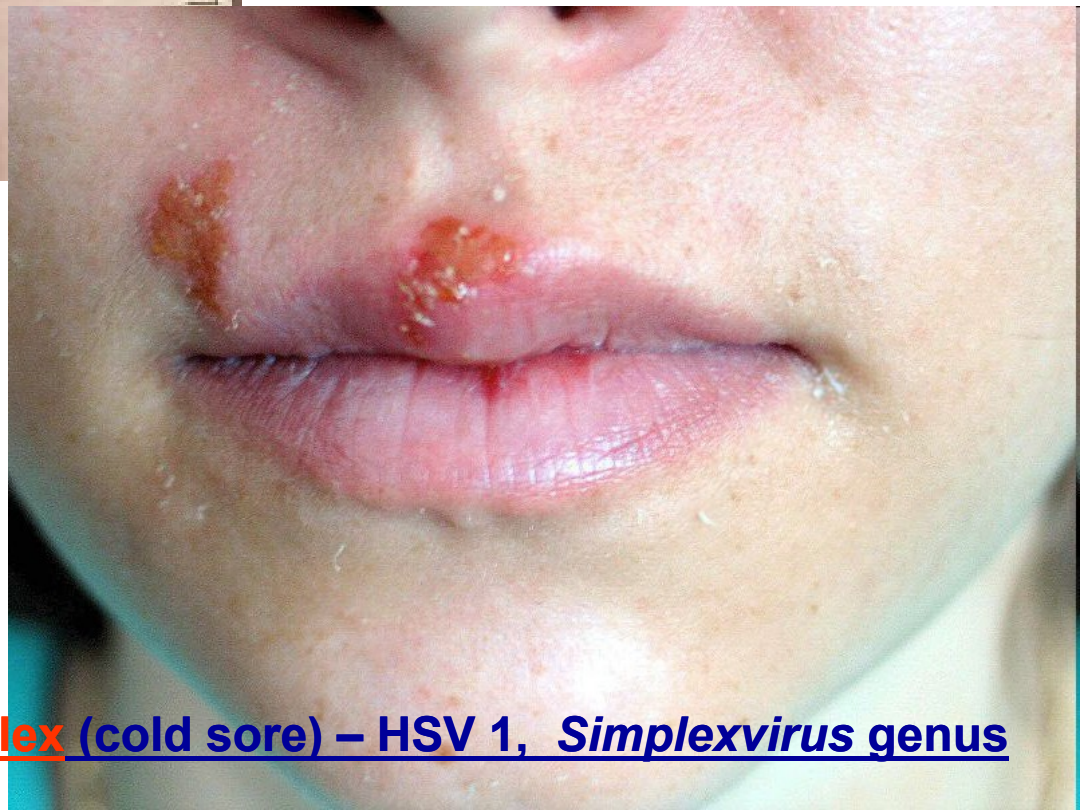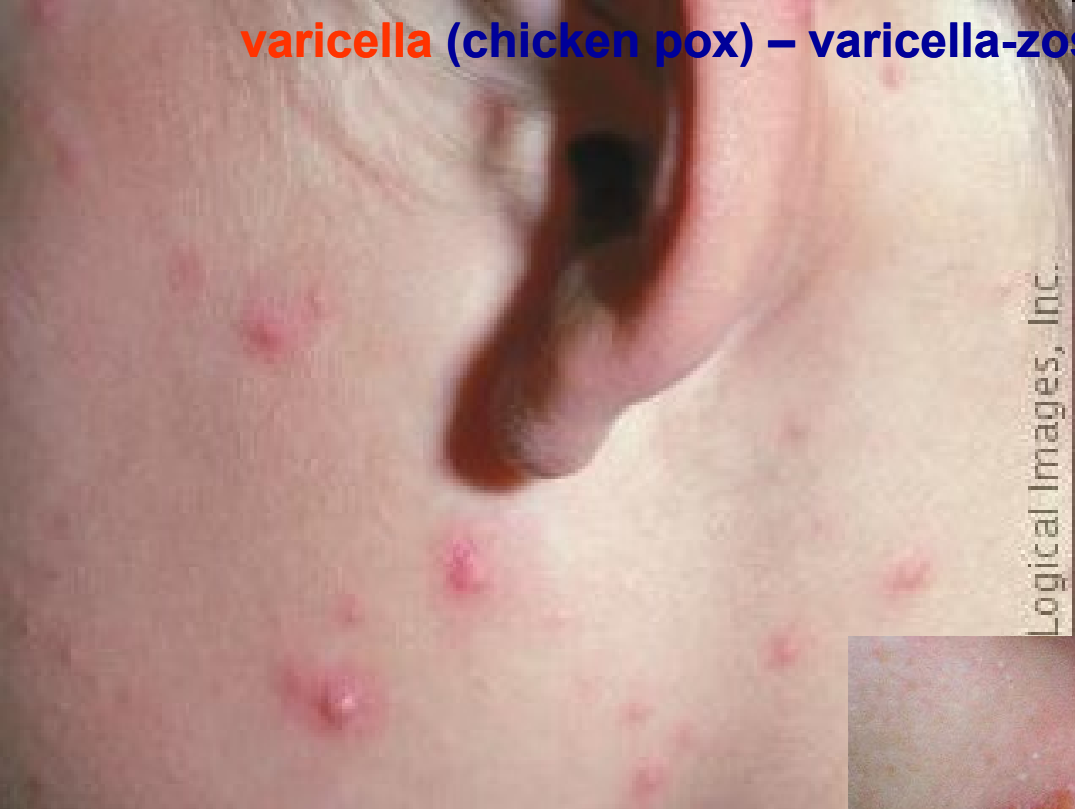**varicella (chicken pox) – varicella-zoster virus, VZV**

**herpes zoster (shingles) – VZV**

***hand, foot and mouth disease – coxsackievirus***



**varicella** (chicken pox) – varicella-zoster virus, VZV, *Varicellovirus* genus



**herpes simplex** (cold sore) – HSV 1, *Simplexvirus* genus

# Skin symptoms in viral diseases – III

## *Petechiae:*

### **Hemorrhagic fevers –**

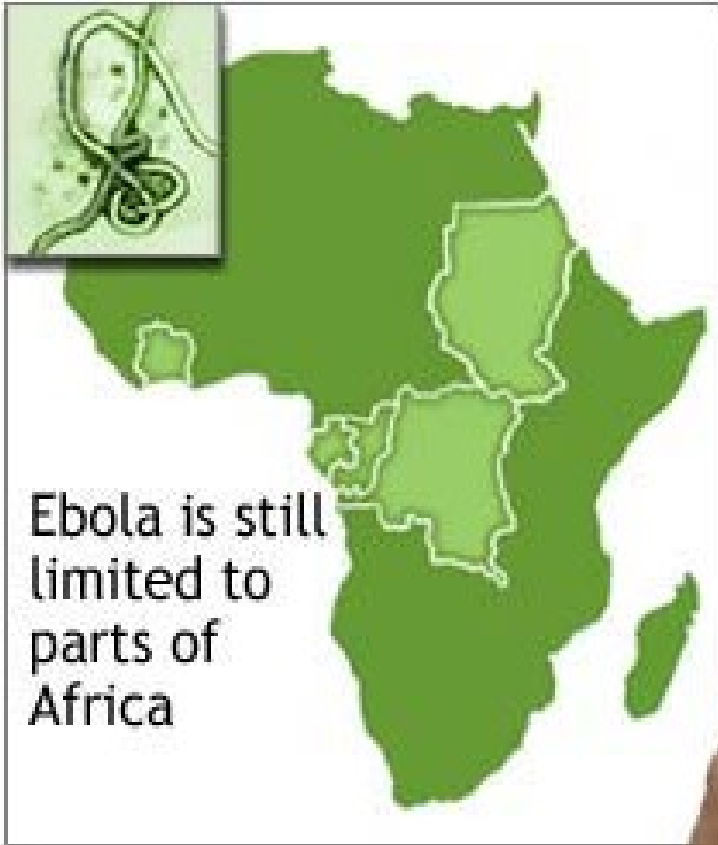**Ebola fever, Ebola virus**

**Marburg disease, Marburg virus**

**Lassa fever, Lassa virus**

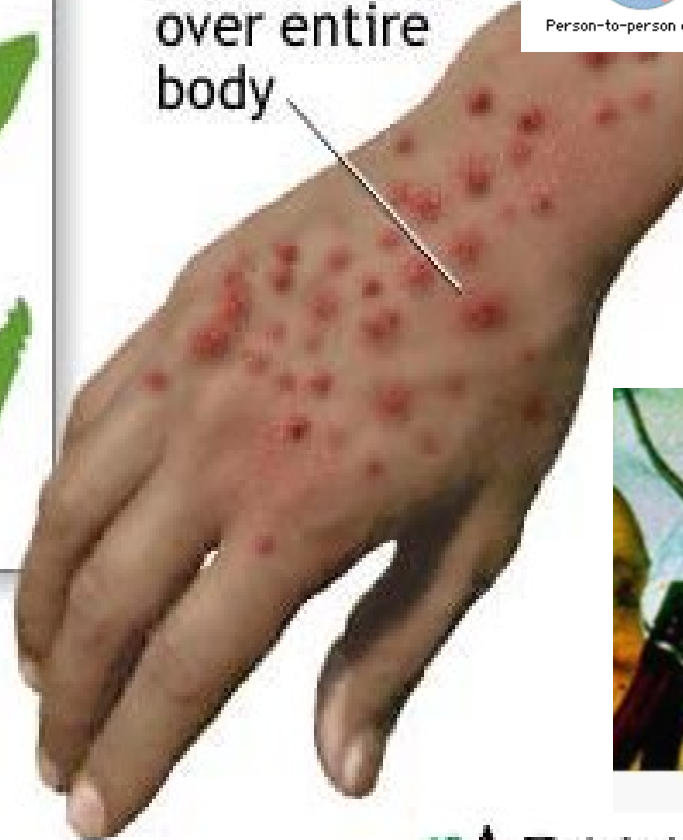### **Generalized congenital cytomegalic disease –**

**cytomegalovirus, CMV**

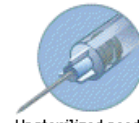

Ebola is still limited to parts of Africa

A hemorrhagic rash appears over entire body



**Modes of Infection**



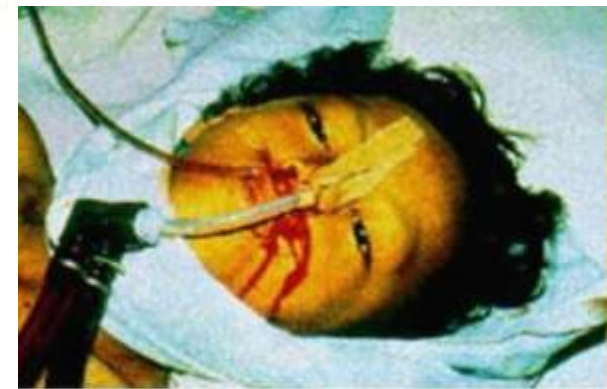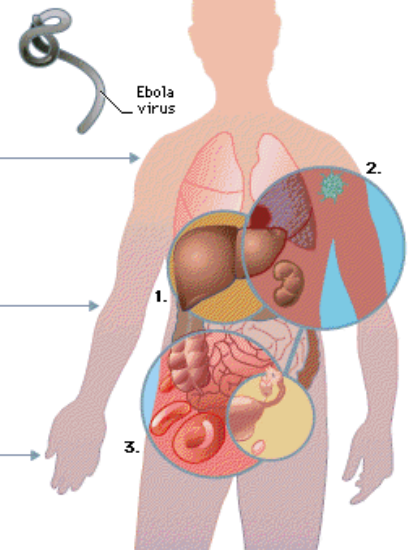
Unsterilized needles



Hospital contagion



Person-to-person contact



Ebola Patient (Intensive Care)

# Parasitic infections

# Skin symptoms in parasitoses – I

## *Domestic parasitoses:*

**scabies** – itch mite, *Sarcoptes scabiei*

**pediculosis capitis** – head louse, *Pediculus capitis*

**pediculosis corporis** – body louse, *Pediculus humanus* (syn. *Pediculus corporis*)

**pediculosis pubis (phthiriasis)** – pubic (crab) louse, *Phthirus pubis*

# Skin symptoms in parasitoses – II

*Infestation by native ectoparasites:*

**cimicosis** – bites by bedbug *Cimex lectularius*

**pulicosis** – bites by human flea *Pulex irritans*,  
dog flea *Ctenocephalides canis*,  
cat flea *Ctenocephalides felis*,  
chicken flea *Ceratophyllus gallinae*

# Skin symptoms in parasitoses – III

## *Tropical parasitoses:*

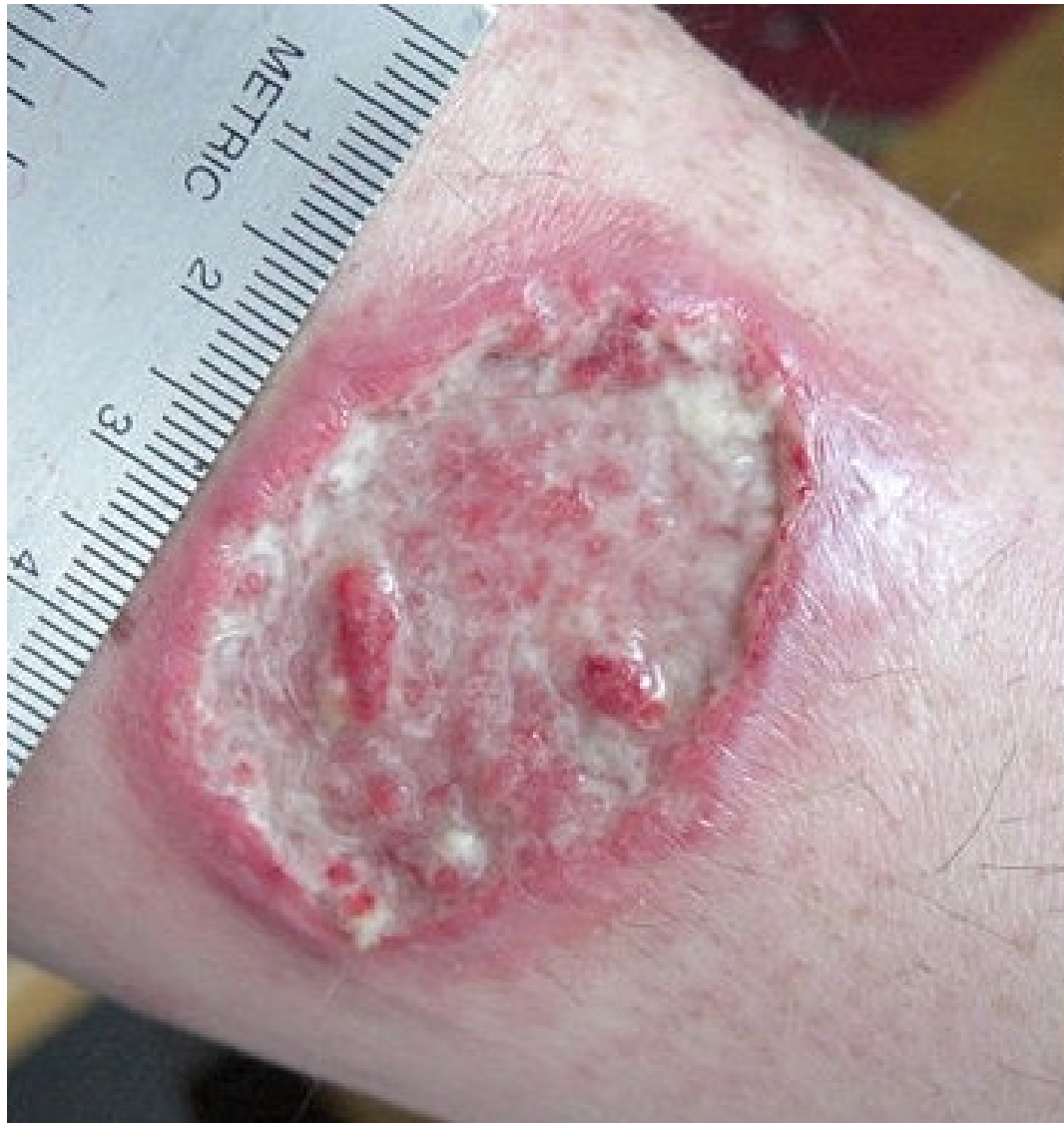**ulcus humidum** (humid ulcer) – *Leishmania major*

**ulcus siccum** (dry ulcer) – *Leishmania tropica*

**dermatitis cercariosa** – cercariae of *Schistosoma*,  
*Bilharziella* and *Trichobilharzia* genera

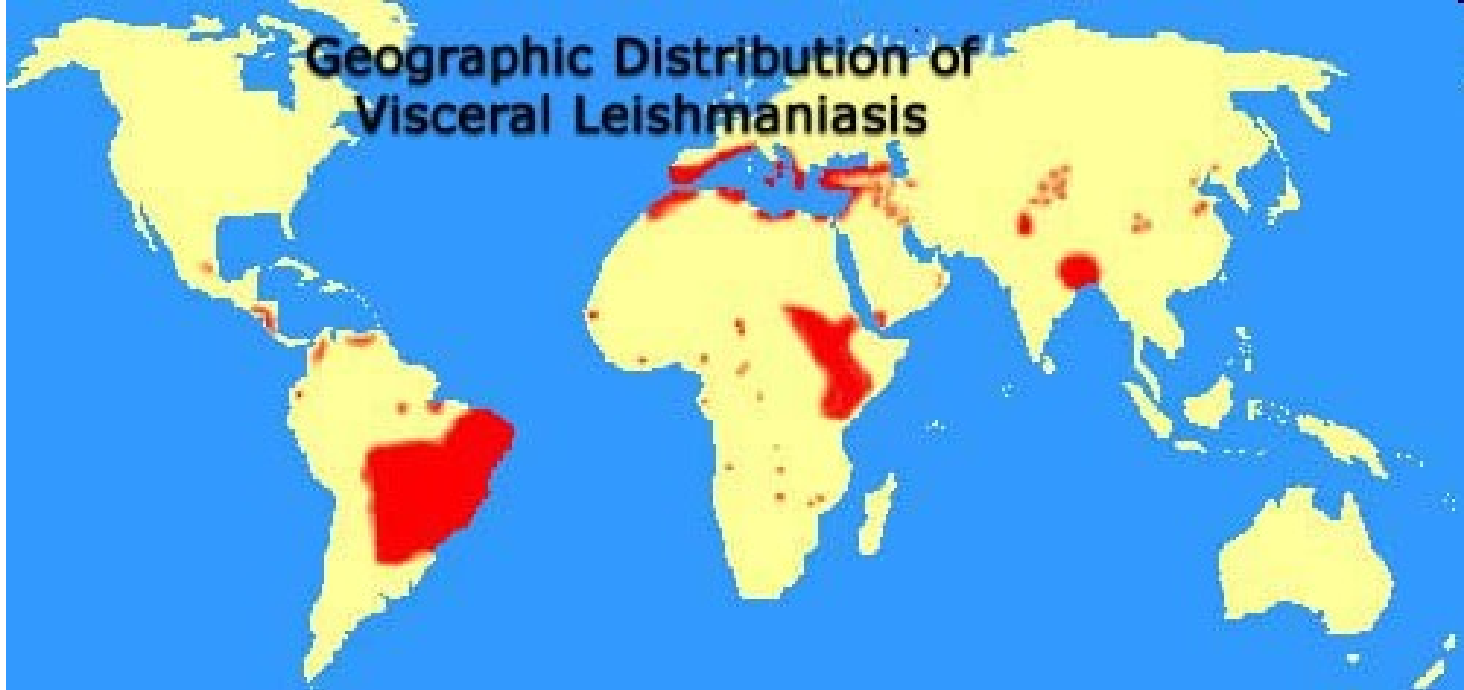**dracunculosis** – *Dracunculus medinensis*

**filariosis** – filariae *Loa loa* and *Onchocerca volvulus*

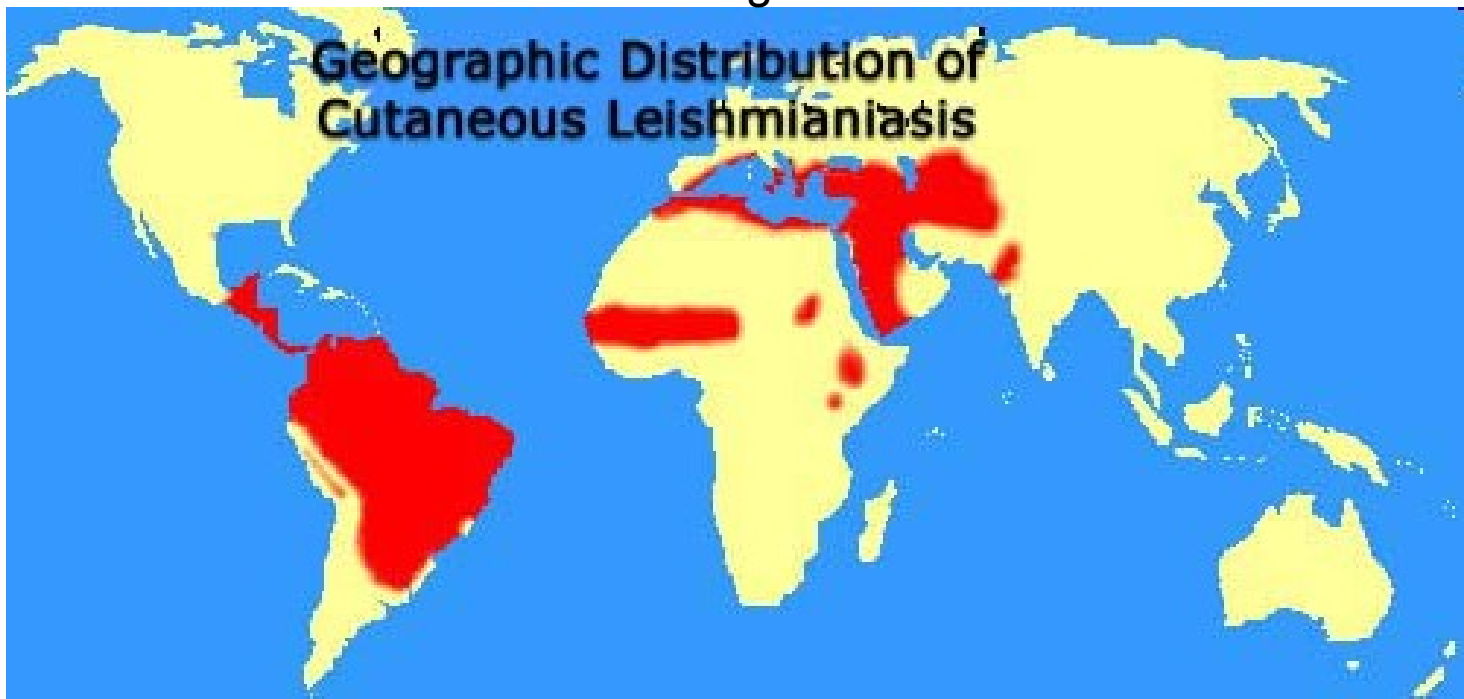


**Leishmaniasis**





[www.vet.uga.edu](http://www.vet.uga.edu)



# Edvard Munch (1863-1944): Death in a Room

