

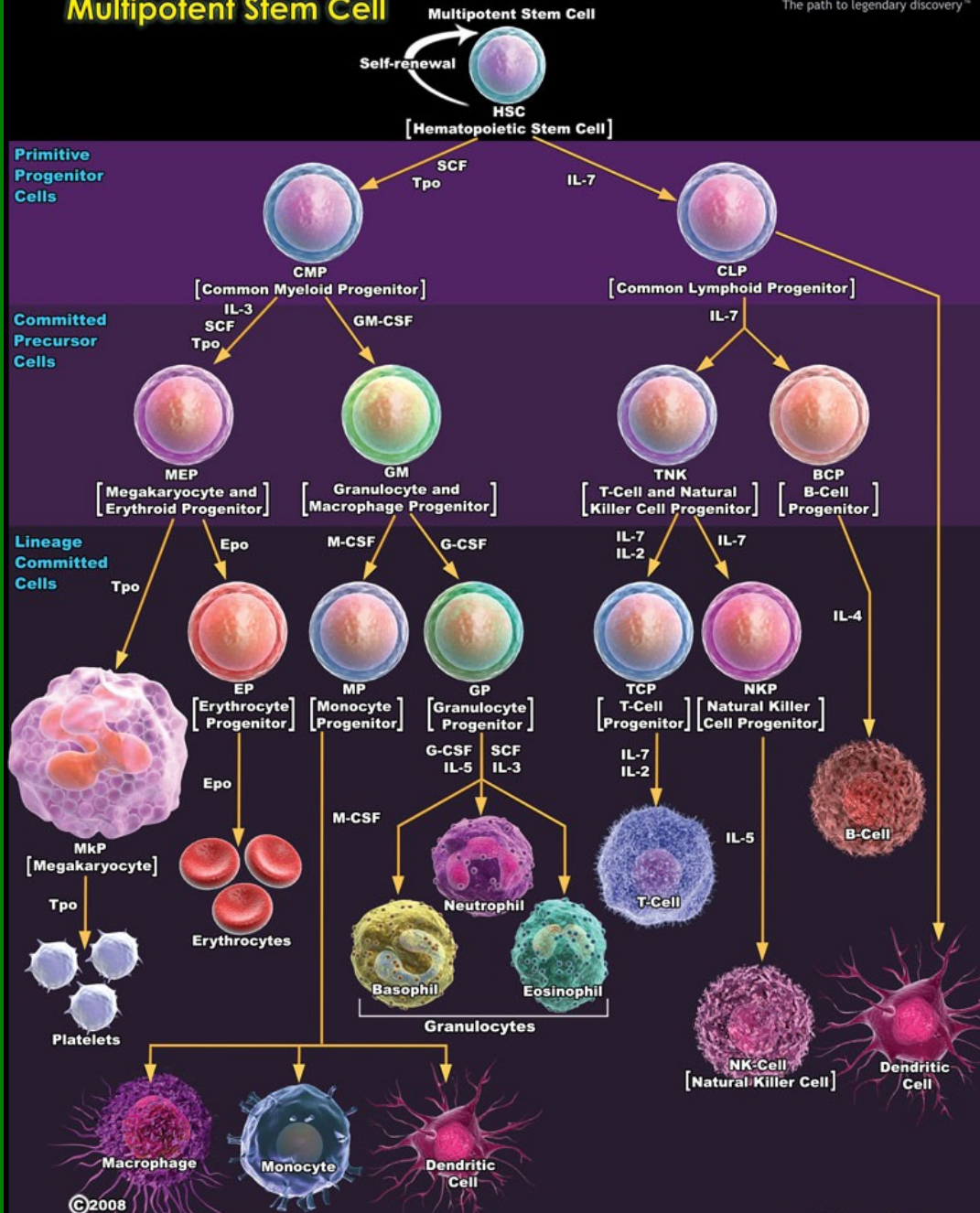
# Hematopoéza

Bourková L., OKH FN Brno

# Hematologické atlasy

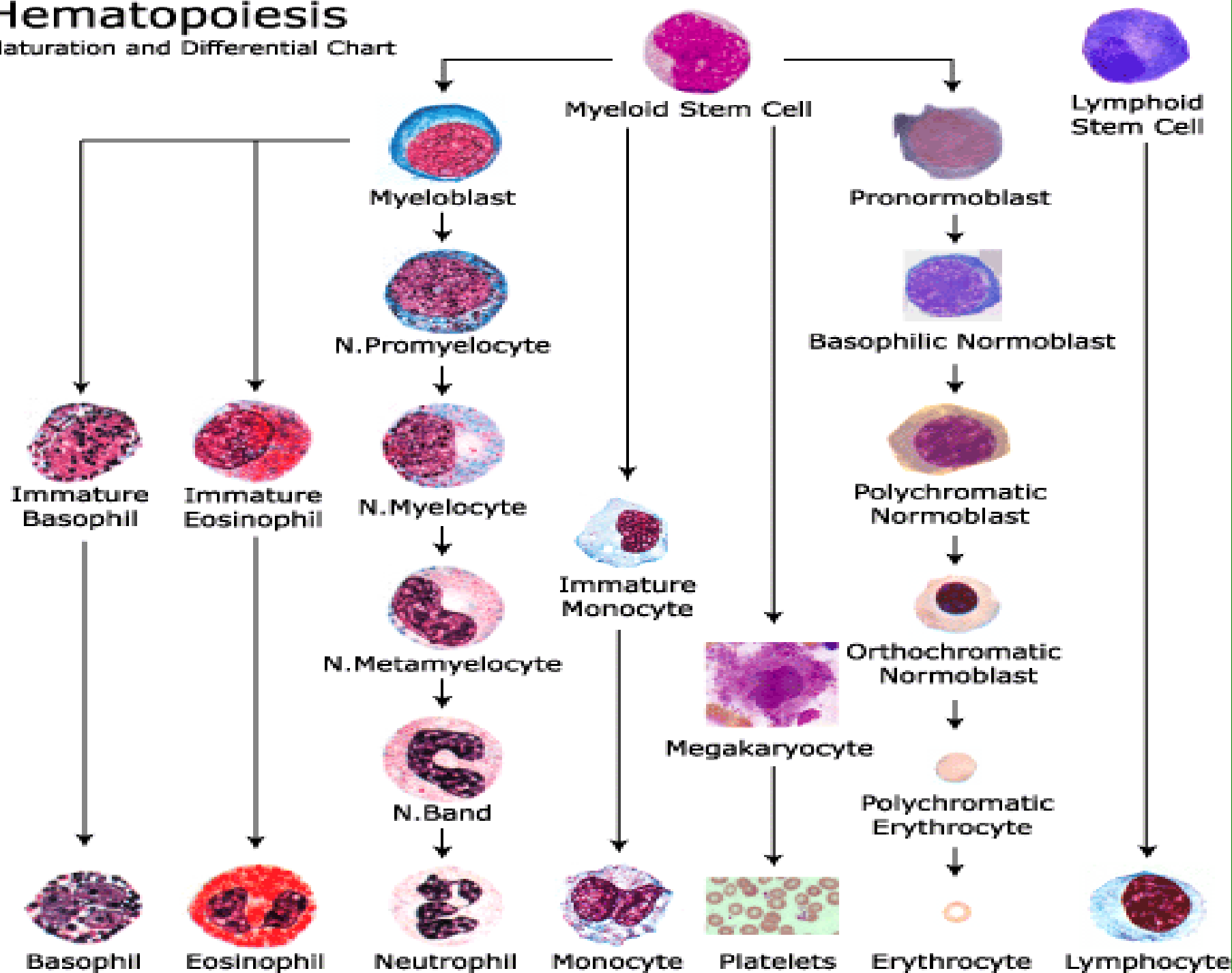
např.: <http://www.hematocytologie.eu/>

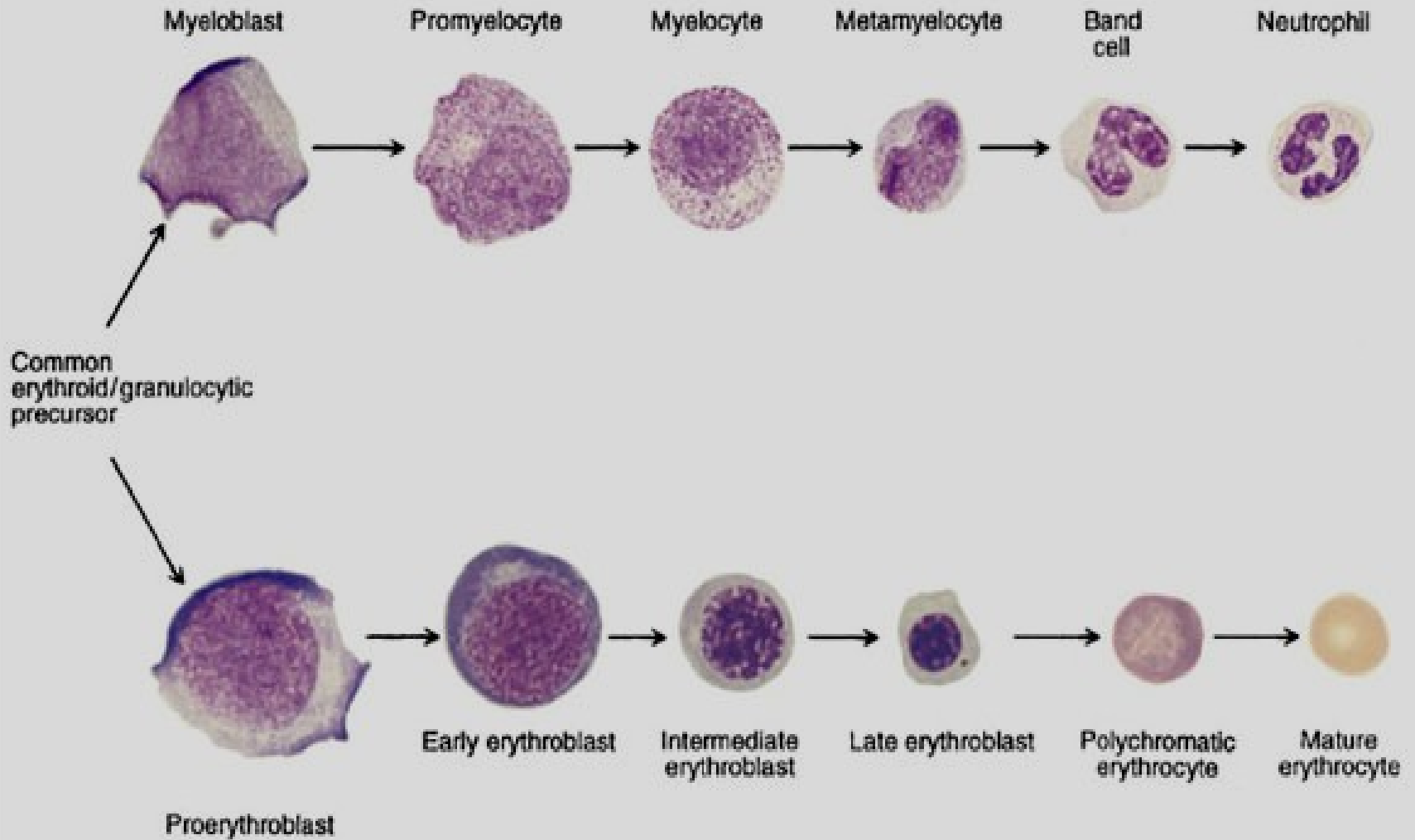
# Hematopoiesis from Multipotent Stem Cell



# Hematopoiesis

Maturation and Differential Chart






# Sledování buněčných morfologických změn



A Cell size and cytoplasm color

zbarvení, obsah  
cytoplazmy



B Nuclear size and color

velikost, tvar  
jádra



C Nuclear chromatin structure

struktura chromatinu,  
jadérka



D Composite (Left to right: Rubriblast, Pro-rubricyte, Rubricyte, Metarubricyte, Diffusely basophilic erythrocyte, Erythrocyte)

komplexní hodnocení

KOSTNÍ DŘEŇ

myeloblast

promyelocyt

neutrofilní myelocyt

eozinofilní myelocyt

bazofilní myelocyt

neutrofilní metamy

eozinofilní metamy

bazofilní metamy

proerythroblast

bazofilní normoblast

polychromní normoblast

oxyfilní normoblast

monoblastt

promonocyt

makrofág

magakaryoblast

promegakaryocyt

megakaryocyt

lymfoblast

prolymfocyt

plazmat. b.

PERIFERNÍ KREV

neutrofilní tyč

eozinofilní tyč

bazofilní tyčí

neutrofilní segment

eozinofilní segment

bazofilní segment

retikulocyt

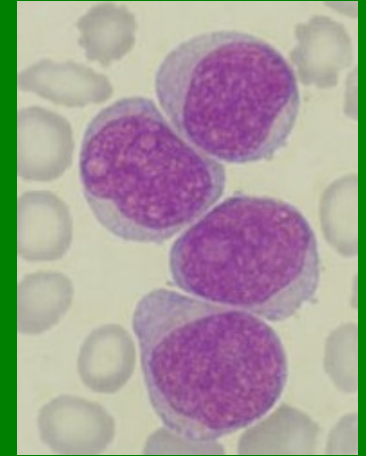
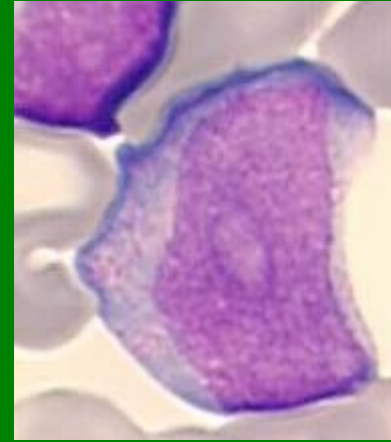
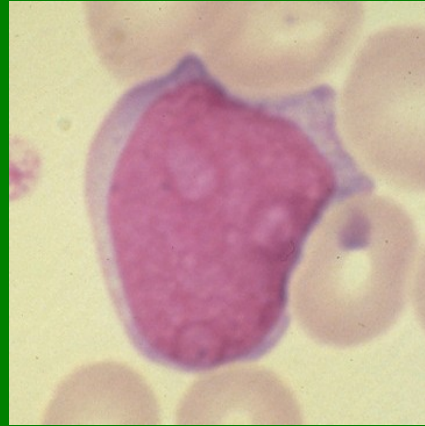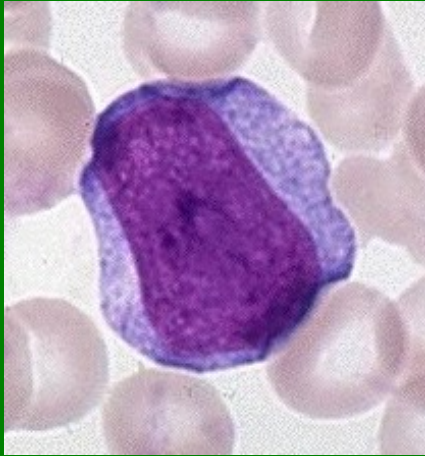
erytrocyt

monocyt

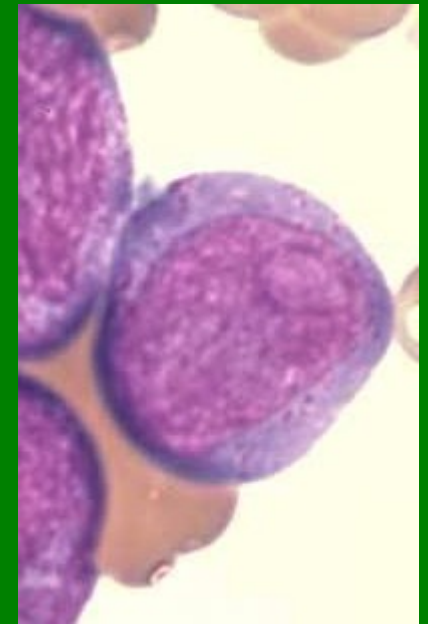
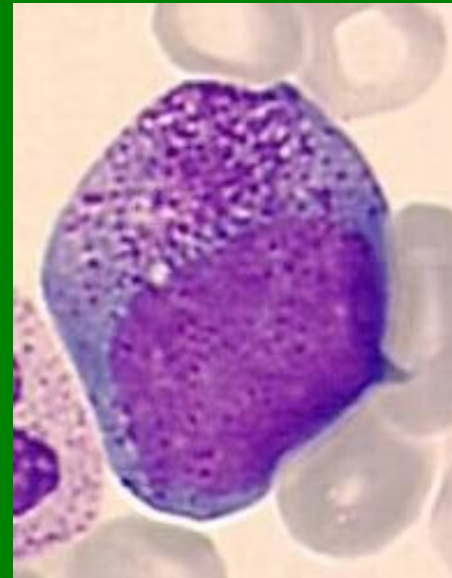
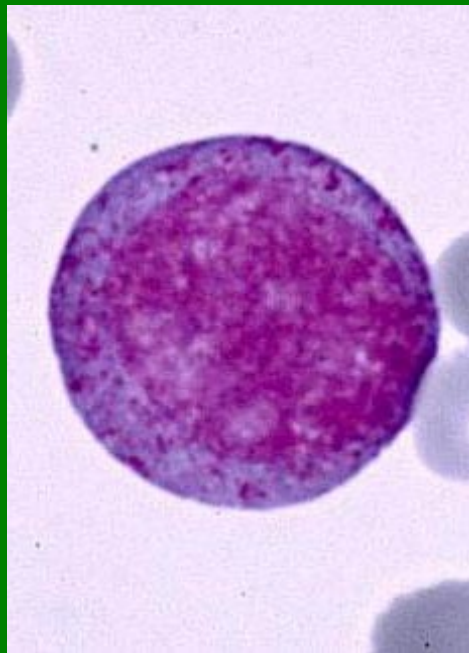
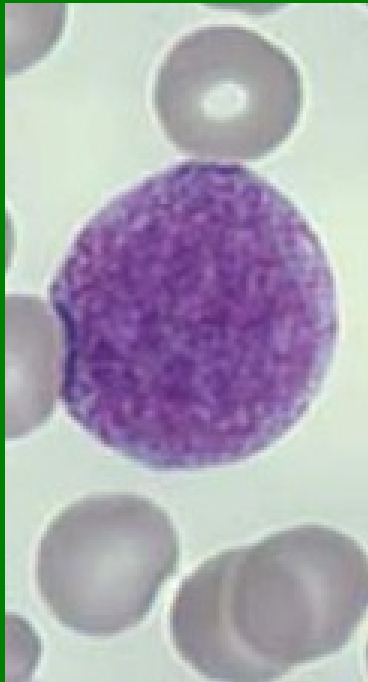trombocyty

lymfocyt

## Myeloblasty

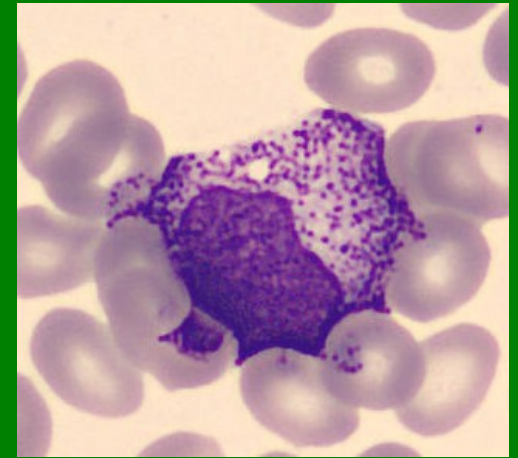
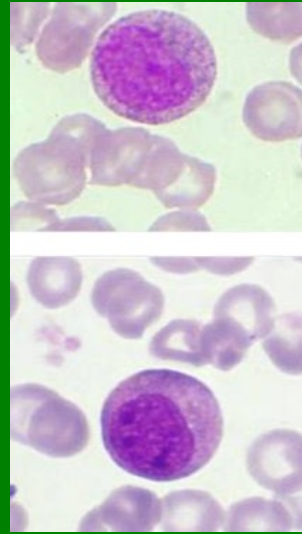
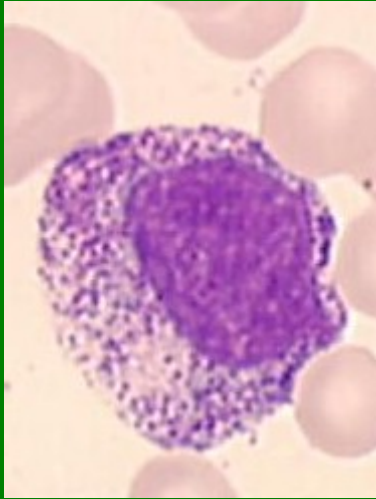
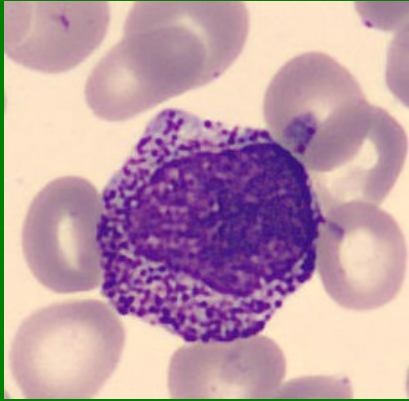


## Promyelocyty

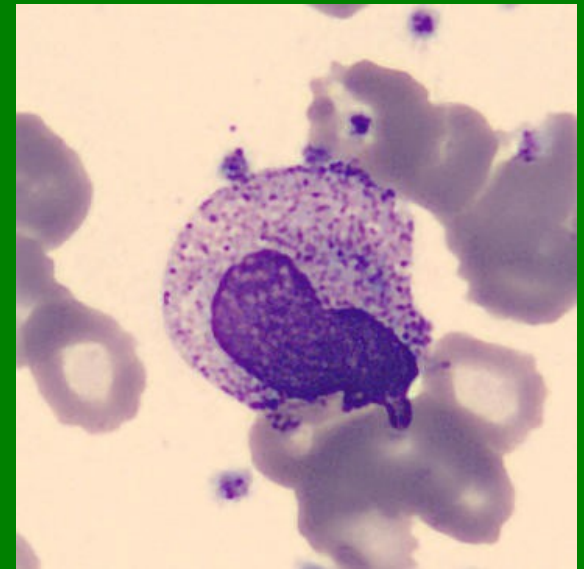
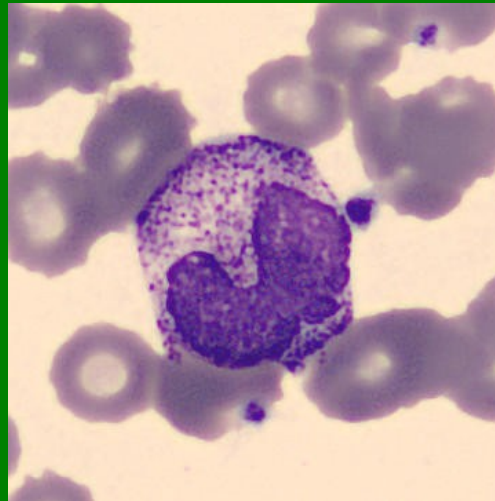
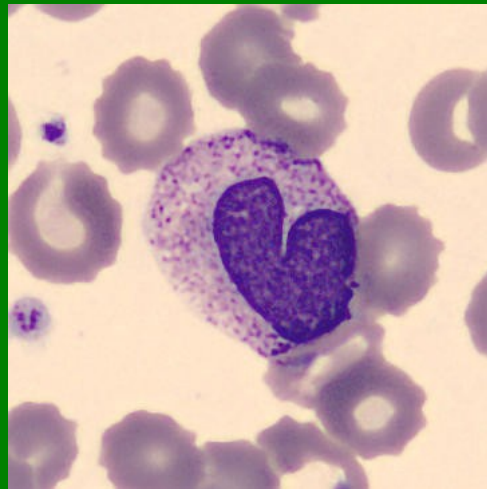




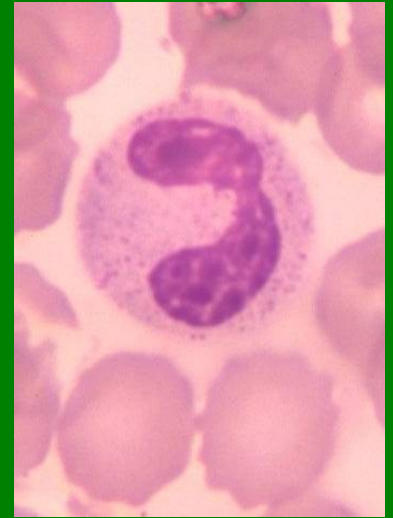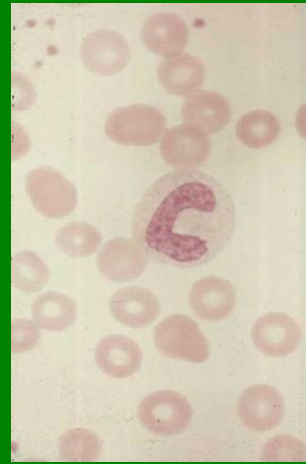
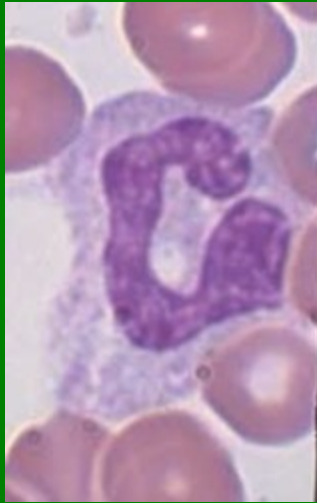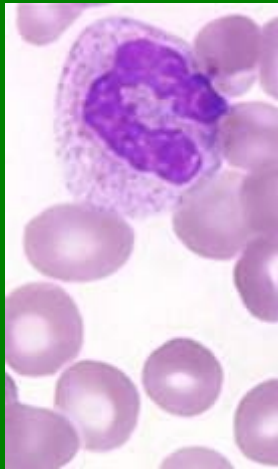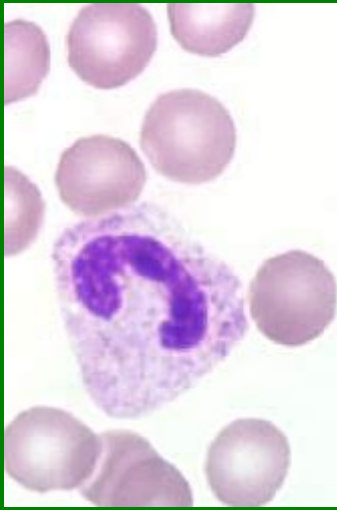## Myelocyty - Ne



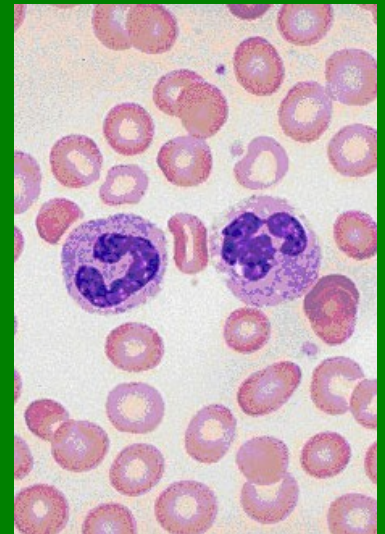
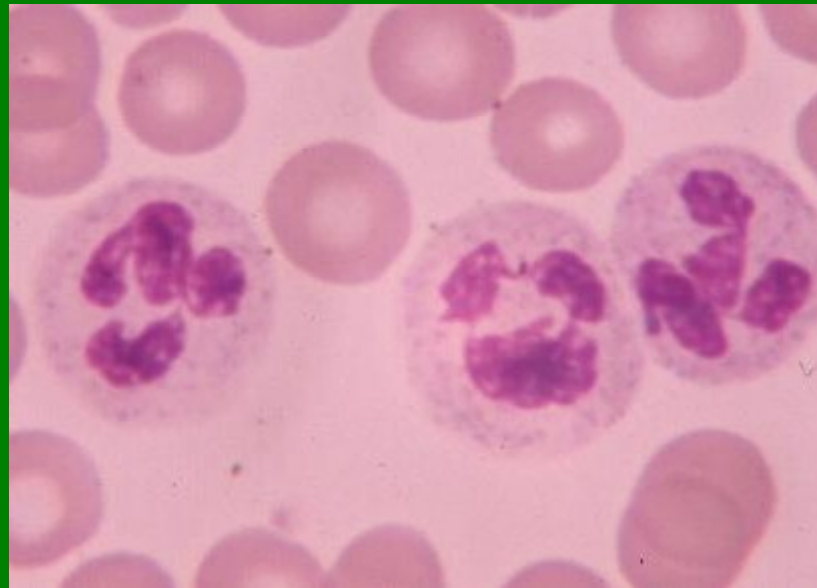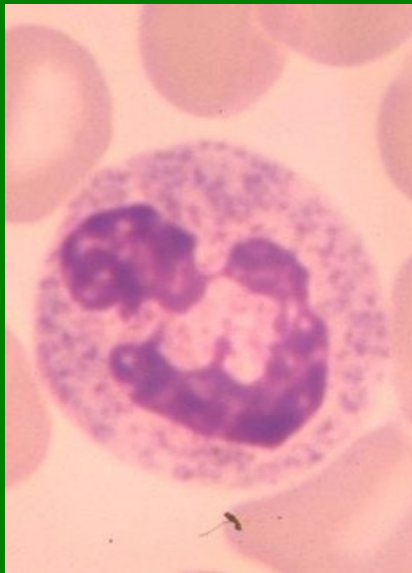## Metamyelocyty - Ne



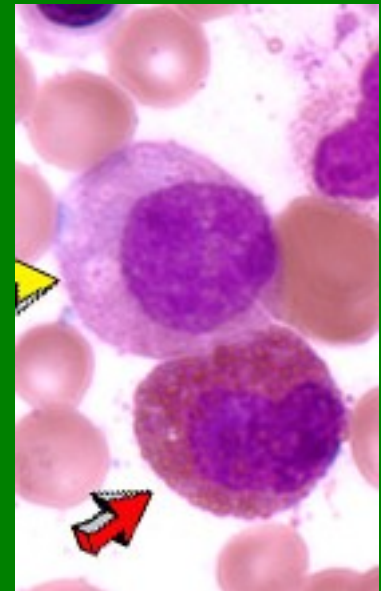
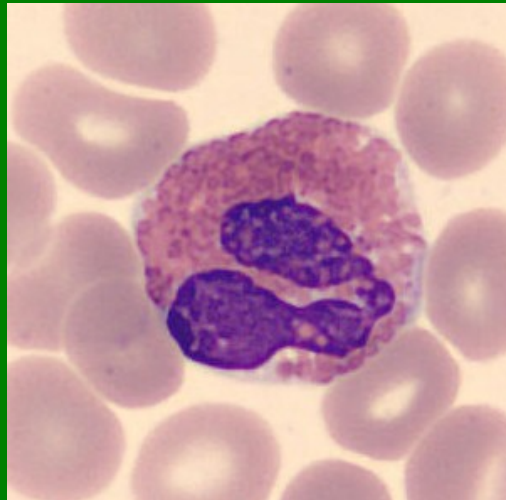
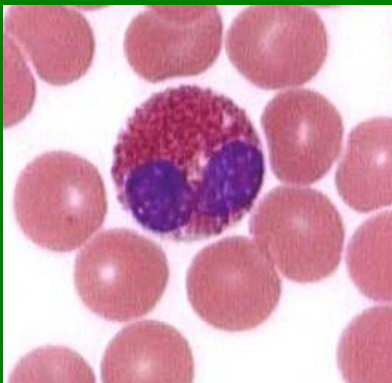
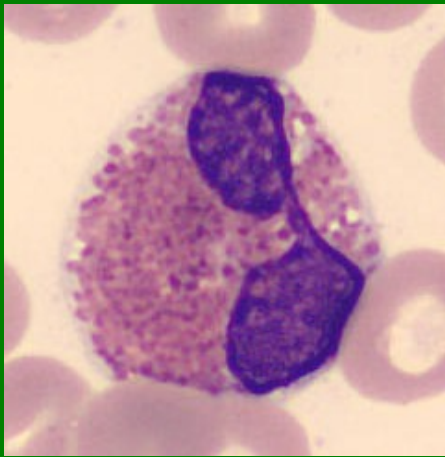
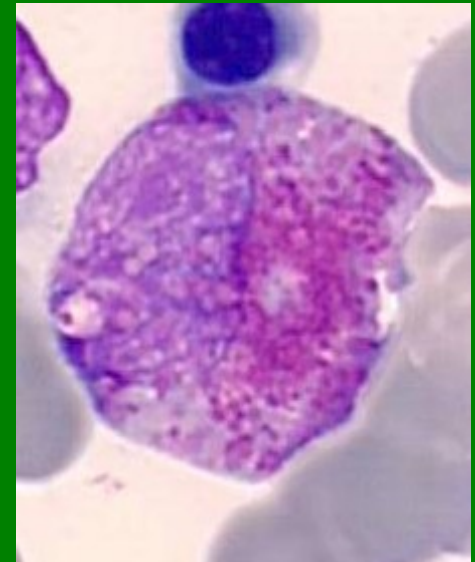
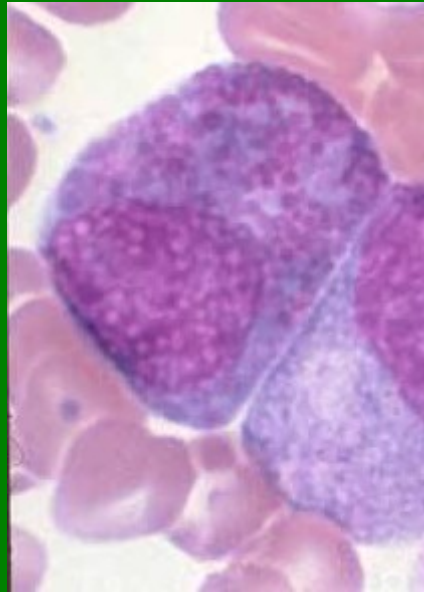
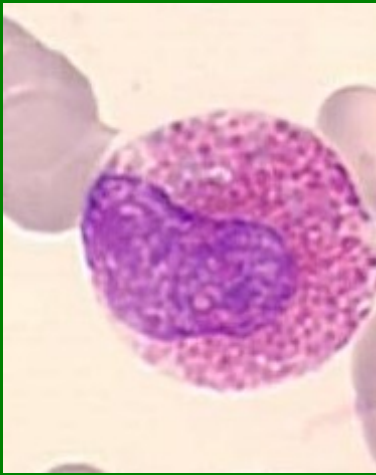
**Tyč – Ne** (rozdíl mezi nejširším a nejužším tvarem jádra je 1/3 až 1/2)



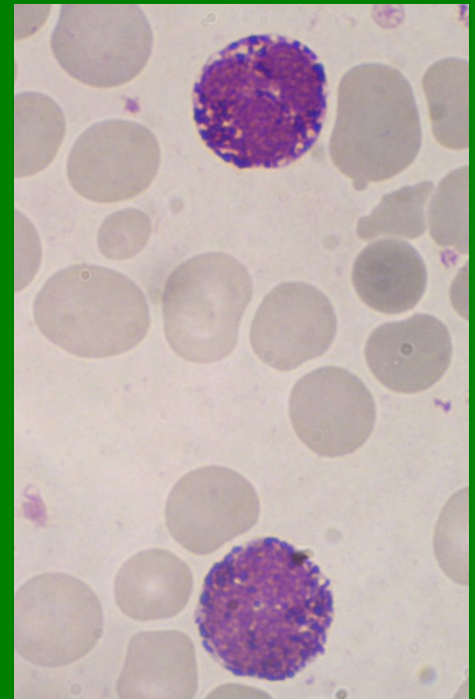
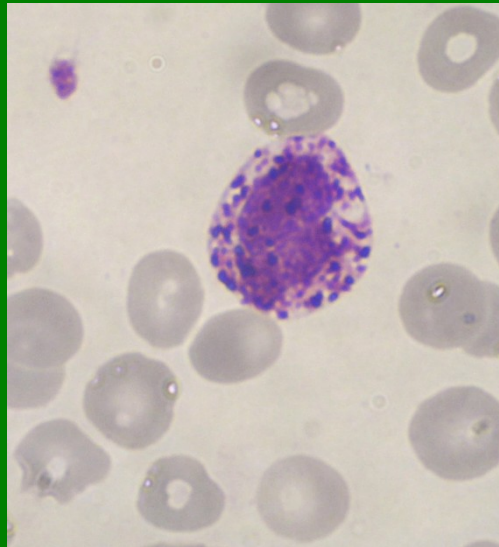
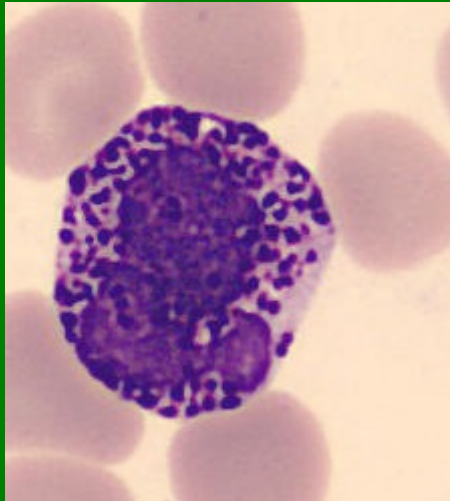
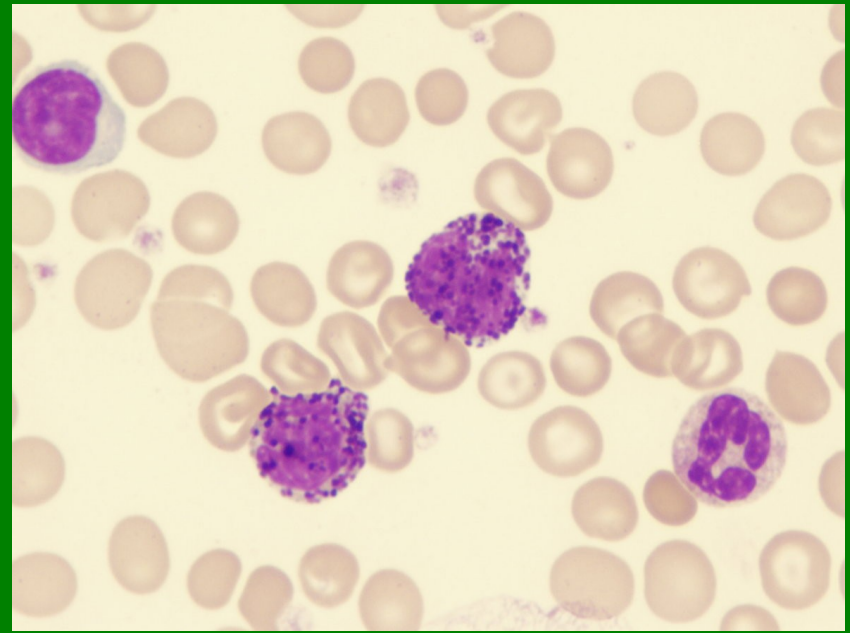
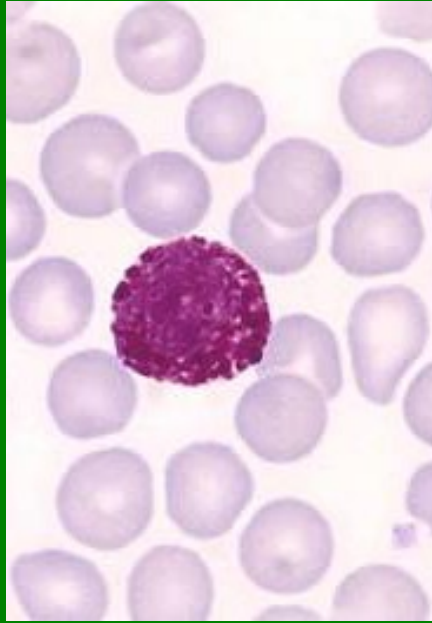
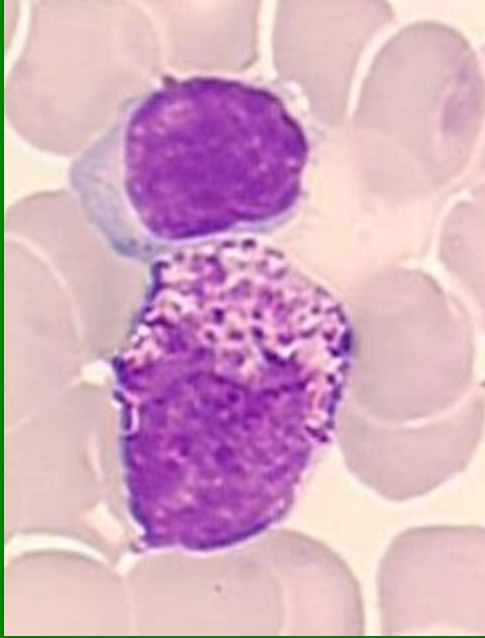
**Segment - Ne**



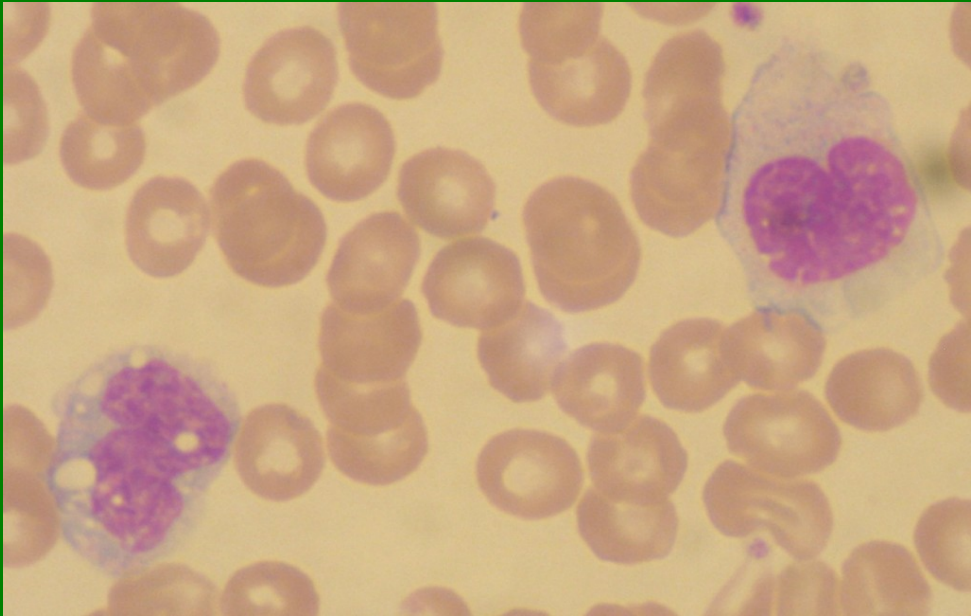
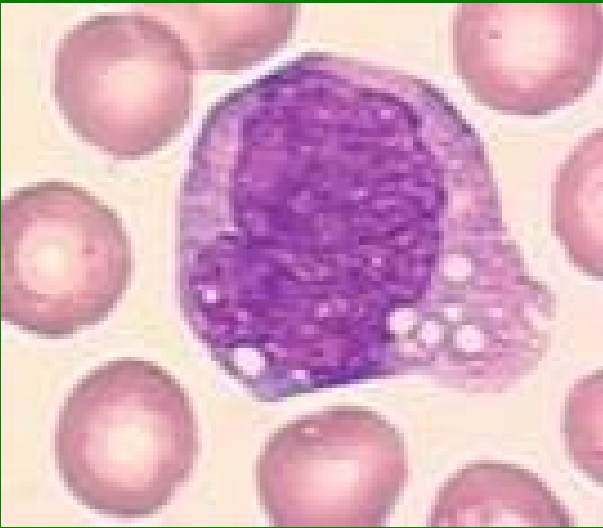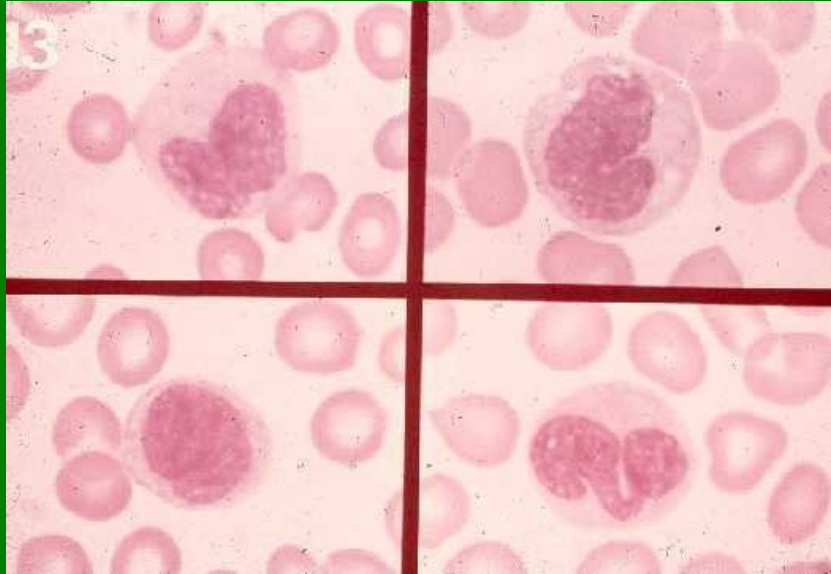
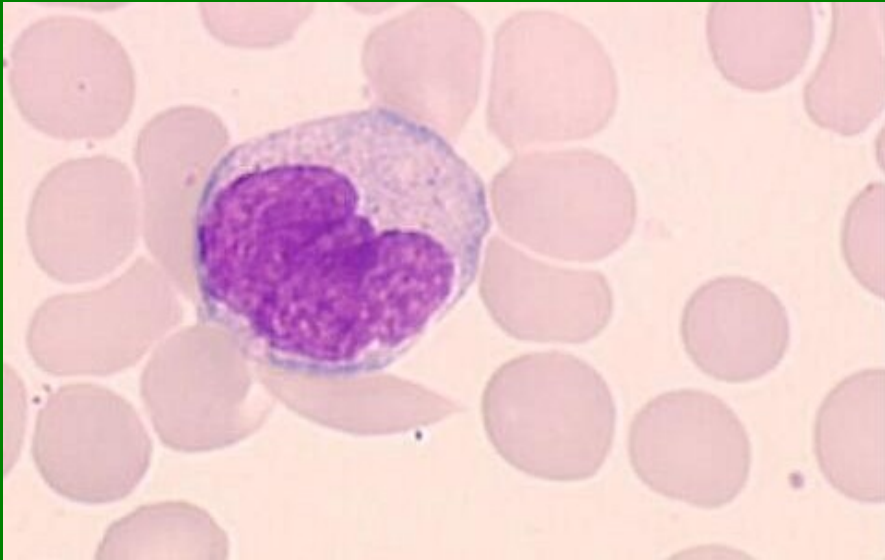
# Eozinofily



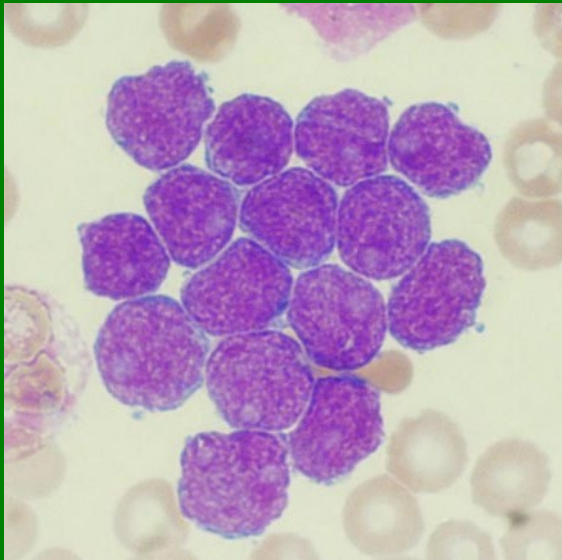
# Bazofily



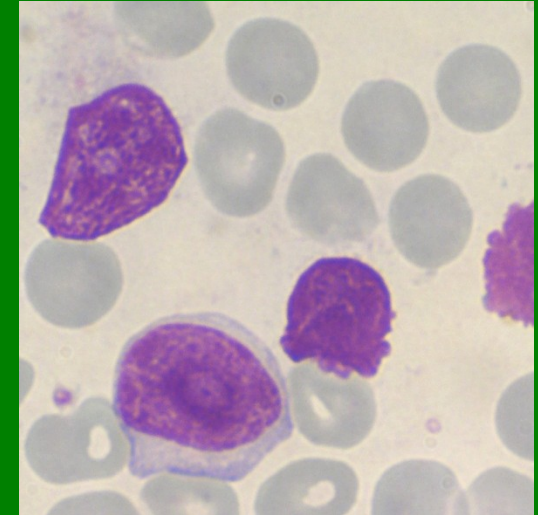
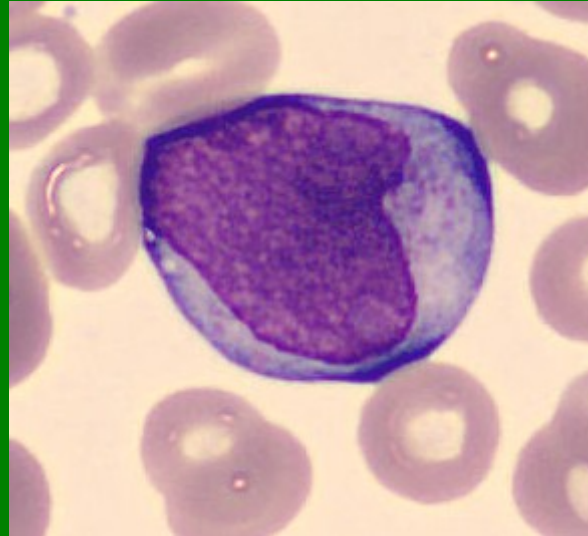
# Monocyty



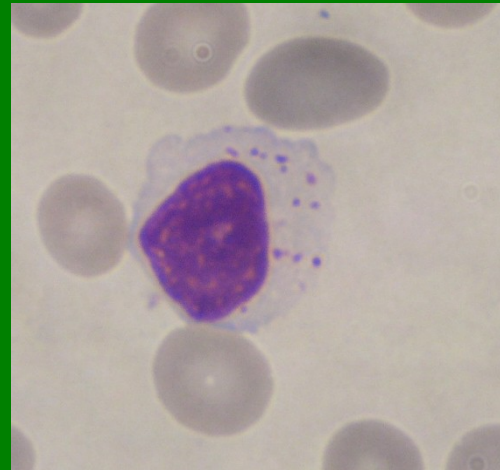
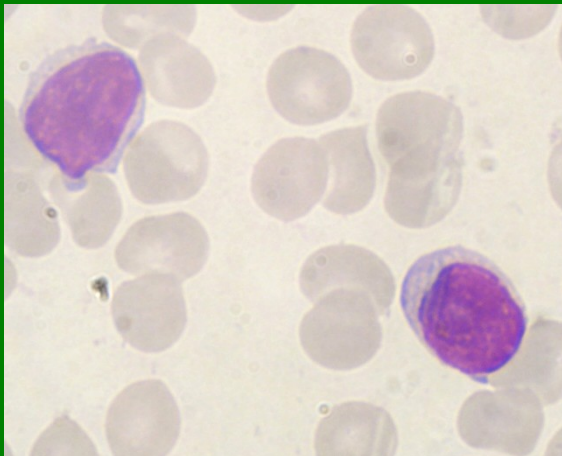
**Lymfoblasty**



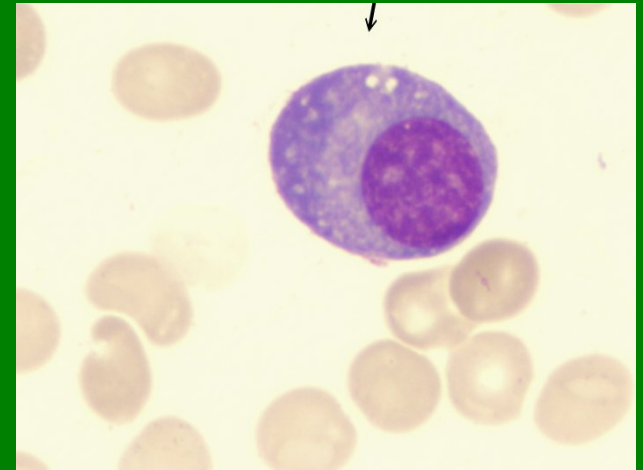
**Prolymfocyt**



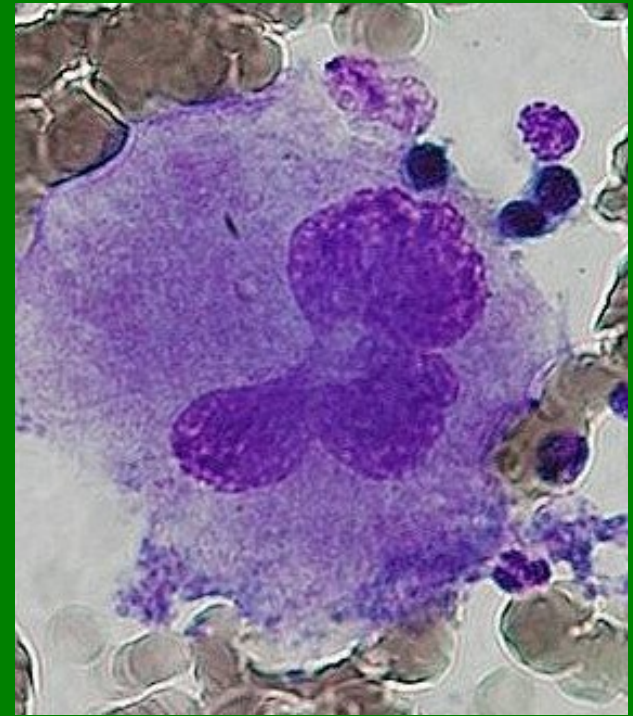
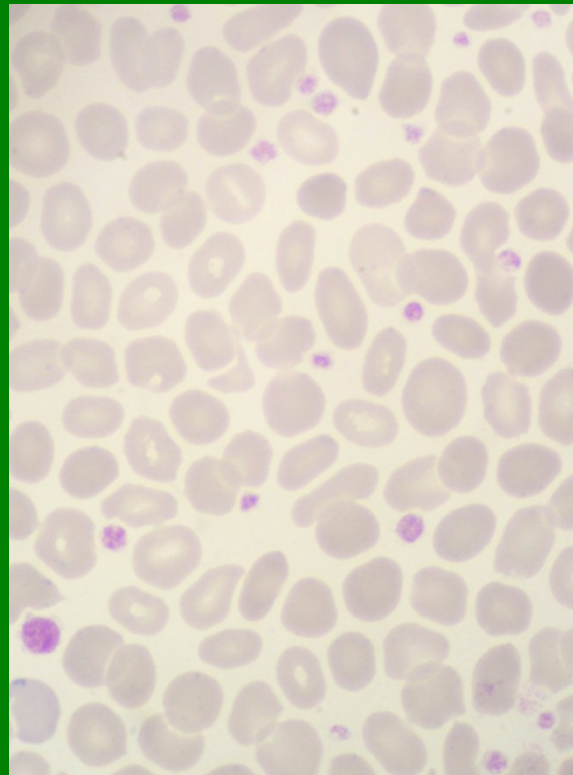
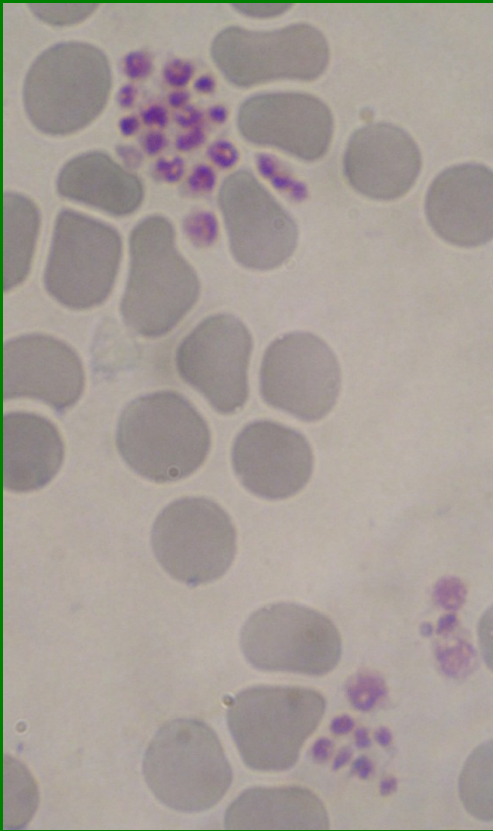
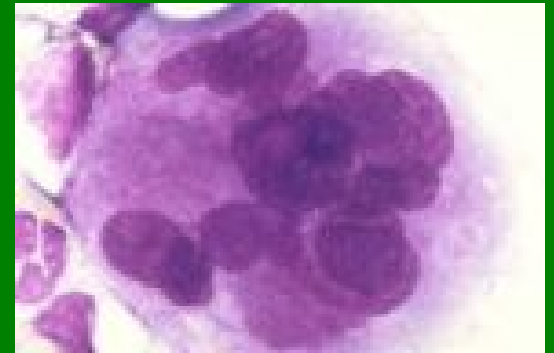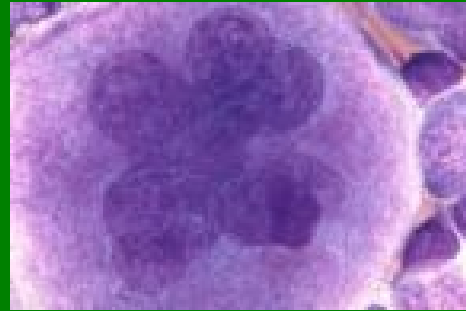
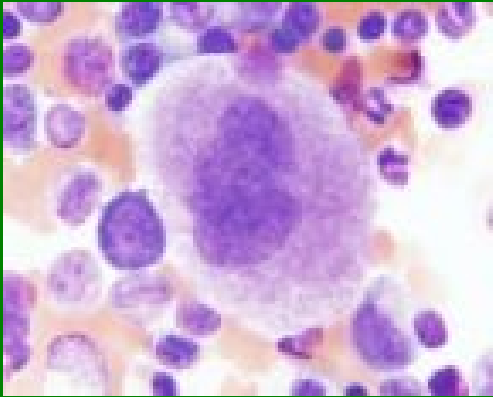
**Lymfocyty**



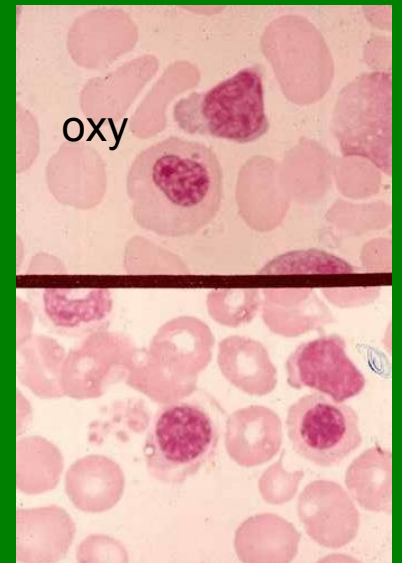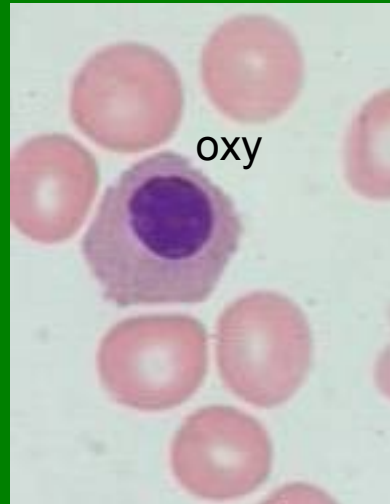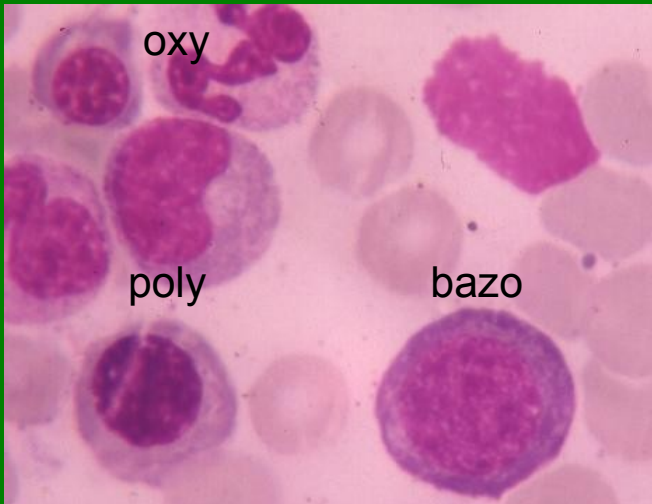
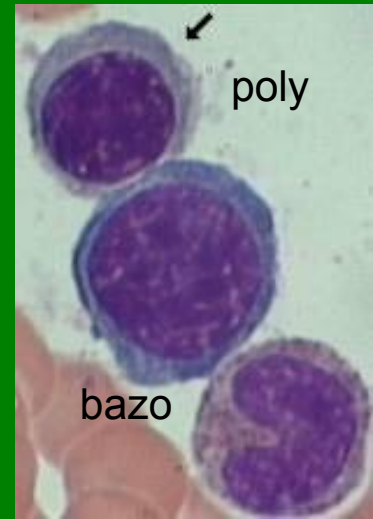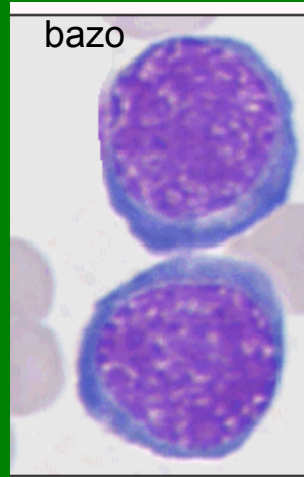
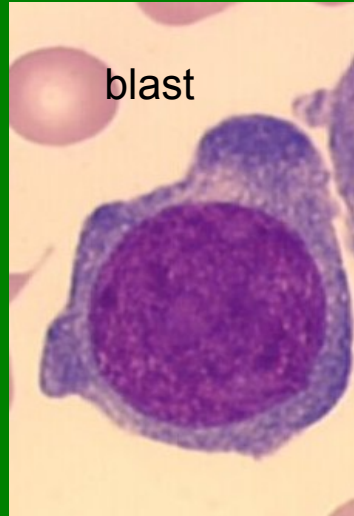
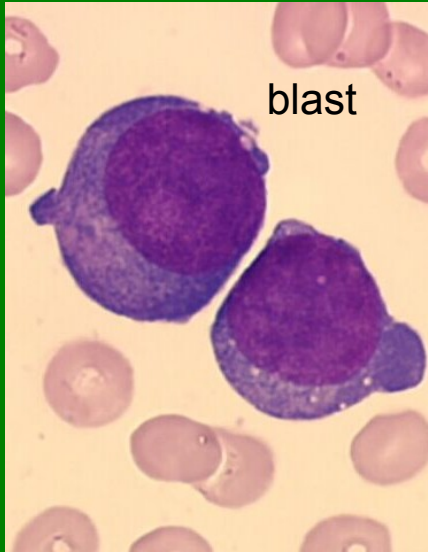**Plazmatická buňka**



# Megakaryocyty, PLT



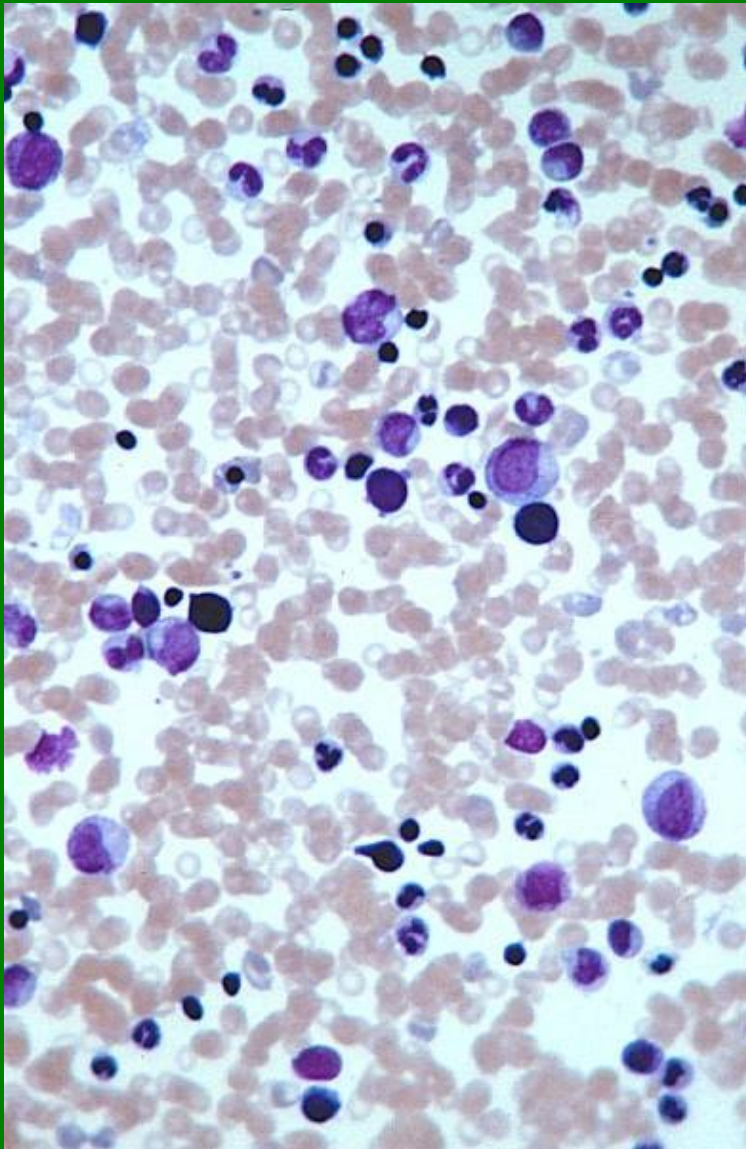
# NRBC





# Kostní dřeň - buněčnost

normální



vysoká

