

# USMLE Step 1 Session

## (Imuno)Pathology 3

26.11.2014, Klub A. Trýba

FB: USMLE @ Masaryk



Marek Čiorny  
(324602 at mail.muni.cz)

## Q1

An 8-year-old boy presents with periorbital edema and throbbing headaches. His parents report that the boy had a “strep throat” 2 weeks ago. Urinalysis shows 3+ hematuria. A renal biopsy shows hypercellular glomeruli, and electron microscopic examination of glomeruli discloses subepithelial “humps.” Which of the following best explains the pathogenesis of glomerulonephritis in this patient?

- (A) Antineutrophil cytoplasmic autoantibodies
- (B) Deposition of circulating immune complexes
- (C) Directly cytotoxic IgG and IgM antibodies
- (D) IgE-mediated mast cell degranulation
- (E) T cell–mediated delayed hypersensitivity reaction

## Q1

An 8-year-old boy presents with **periorbital edema** and throbbing **headaches**. His parents report that the boy had a “**strep throat**” 2 weeks ago. Urinalysis shows **3+ hematuria**. A renal biopsy shows **hypercellular glomeruli**, and electron microscopic examination of glomeruli discloses **subepithelial “humps”**. Which of the following best explains the pathogenesis of glomerulonephritis in this patient?

- (A) Antineutrophil cytoplasmic autoantibodies
- (B) Deposition of circulating immune complexes
- (C) Directly cytotoxic IgG and IgM antibodies
- (D) IgE-mediated mast cell degranulation
- (E) T cell–mediated delayed hypersensitivity reaction

# A1

B: Deposition of circulating immune complexes. Type III hypersensitivity reactions are characterized by immune complex deposition, complement fixation, and localized inflammation. Antibody directed against either a circulating antigen or an antigen that is deposited in a tissue can give rise to a type III response. Diseases that seem to be most clearly attributable to the deposition of immune complexes are **systemic lupus erythematosus**, **rheumatoid arthritis**, and varieties of **glomerulonephritis**.

Streptococcal infection in this case led to the deposition of antigens and antibodies in glomerular basement membranes, resulting in clinical features of nephritic syndrome (e.g., hematuria, oliguria, and hypertension).

Poststreptococcal illnesses do not include any of the other choices.

Diagnosis: Postinfectious glomerulonephritis

**A1: what is the diagnosis?**

# A1: what is the diagnosis?

## **Nephritic syndrome**

Nephritic syndrome = an inflammatory process. When it involves glomeruli, it leads to hematuria and RBC casts in urine. Associated with azotemia, oliguria, hypertension (due to salt retention), and proteinuria (< 3.5 g/day).

## **Acute poststreptococcal glomerulonephritis**

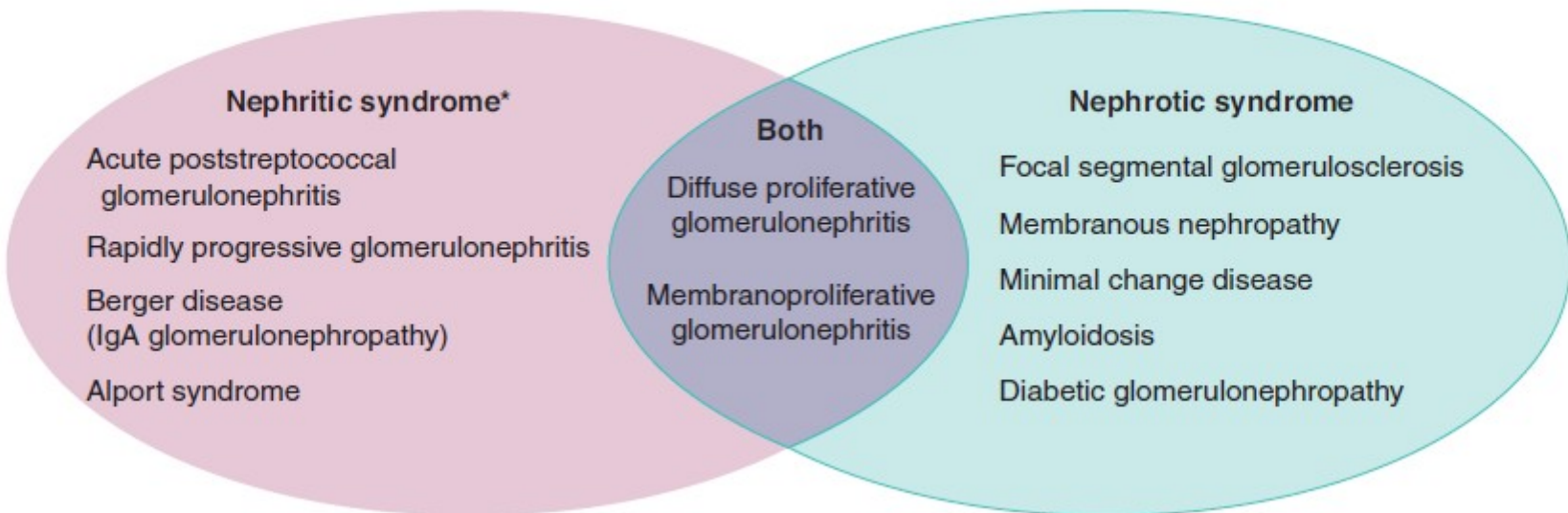
LM—glomeruli enlarged and hypercellular.  
IF—(“starry sky”) granular appearance (“lumpy-bumpy”) due to IgG, IgM, and C3 deposition along GBM and mesangium.  
EM—subepithelial immune complex (IC) humps.

Most frequently seen in children. Occurs ~2 weeks after group A streptococcal infection of the pharynx or skin. Resolves spontaneously. Type III hypersensitivity reaction. Presents with peripheral and periorbital edema, dark urine (cola-colored), and hypertension. ↑ anti-DNase B titers and ↓ complement levels.



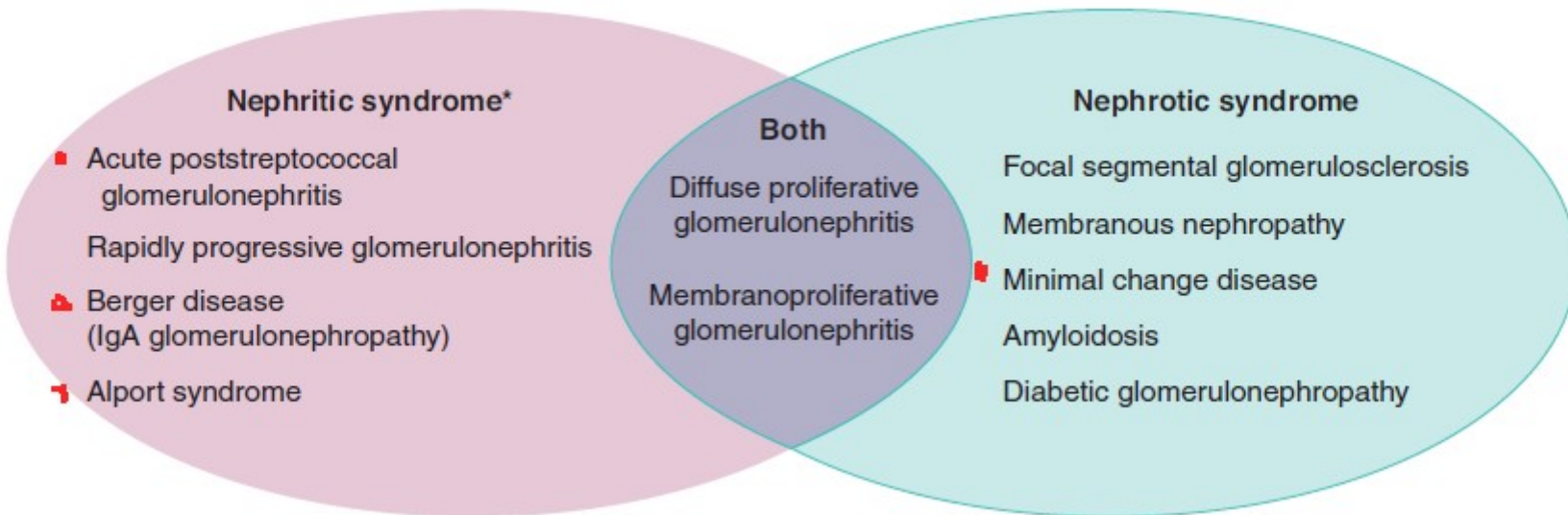
# A1: what other glomerular diseases are prevalent in children?

## Glomerular diseases



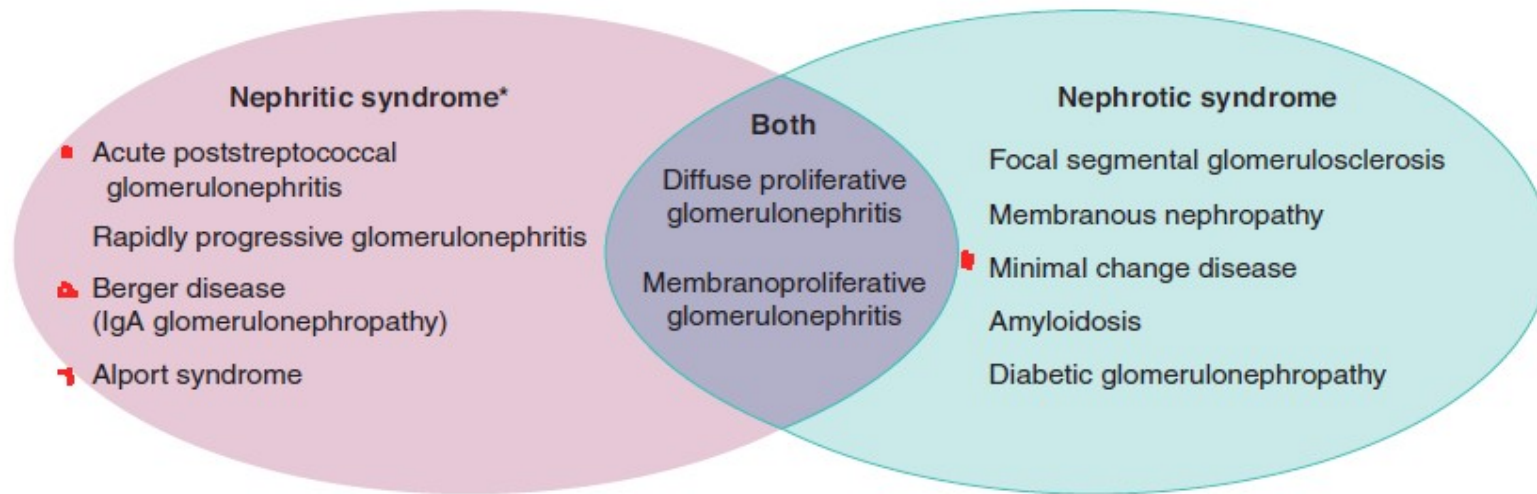
# A1: what other glomerular diseases are prevalent in children?

## Glomerular diseases





## Glomerular diseases



### IgA nephropathy (Berger disease)

LM—mesangial proliferation.  
EM—mesangial IC deposits.  
IF—IgA-based IC deposits in mesangium.  
Seen with Henoch-Schönlein purpura.

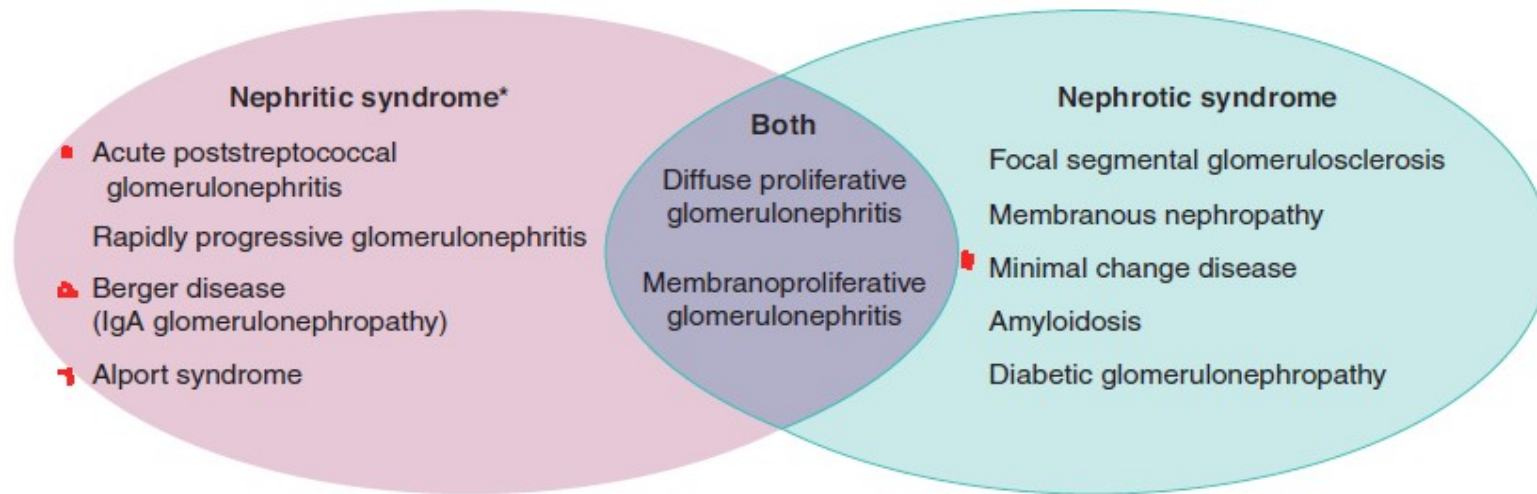
Often presents/flare with a URI or acute gastroenteritis. Episodic hematuria with RBC casts.

### Alport syndrome

Mutation in type IV collagen → thinning and splitting of the glomerular basement membrane. Most commonly X-linked.

Glomerulonephritis, deafness, and, less commonly, eye problems.

## Glomerular diseases



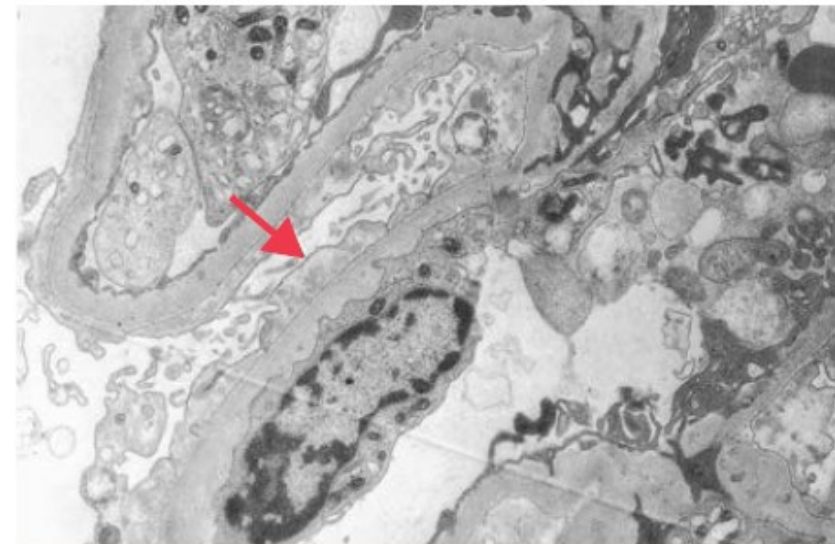
### Minimal change disease (lipoid nephrosis)

LM—normal glomeruli (lipid may be seen in PCT cells).

IF ⊖.

EM—effacement of foot processes **C**.

Most common in children. May be triggered by recent infection, immunization, or immune stimulus. May be associated with Hodgkin lymphoma (e.g., cytokine-mediated damage). Excellent response to corticosteroids.



**C** Minimal change disease (lipoid nephrosis). Note effacement of foot processes on EM (arrow).

A1: what other diseases can be triggered by Strep A infection?

# A1: what other diseases can be triggered by Strep A infection?

- **Rheumatoid fever**
  - M protein ~ endocardium.
    - M protein degrades C3b and thus prevents phagocytosis
  - Sx:
    - Migratory polyarthritits
    - Carditis (endocarditis, carditis, pericarditis)
    - MV stenosis, MV regurgitation
    - Subcutaneous nodules
    - Erythema marginatum
    - Sydenham chorea
- **Toxic shock-like syndrome**
  - erythrogenic toxin is a superantigen

## Q2

A 21-year-old woman presents with a 3-month history of malaise, joint pain, weight loss, and sporadic fever. The patient appears agitated. Her temperature is 38°C (101°F). Other physical findings include malar rash, erythematous pink plaques with telangiectatic vessels, oral ulcers, and nonblanching purpuric papules on her legs. Laboratory studies show elevated levels of blood urea nitrogen and creatinine. Antibodies directed to which of the following antigens would be expected in the serum of this patient?

- (A) C-ANCA (anti-proteinase-3)
- (B) Double-stranded DNA
- (C) P-ANCA (anti-myeloperoxidase)
- (D) Rheumatoid factor
- (E) Scl-70 (anti-topoisomerase I)



## Q2

A 21-year-old woman presents with a 3-month history of malaise, joint pain, weight loss, and sporadic fever. The patient appears agitated. Her temperature is 38°C (101°F). Other physical findings include malar rash, erythematous pink plaques with telangiectatic vessels, oral ulcers, and nonblanching purpuric papules on her legs. Laboratory studies show elevated levels of blood urea nitrogen and creatinine. Antibodies directed to which of the following antigens would be expected in the serum of this patient?

- (A) C-ANCA (anti-proteinase-3)
- (B) Double-stranded DNA
- (C) P-ANCA (anti-myeloperoxidase)
- (D) Rheumatoid factor
- (E) Scl-70 (anti-topoisomerase I)

## A2

**B: Double-stranded DNA.** **Systemic lupus erythematosus** (SLE) is an autoimmune, inflammatory disease that may involve almost any organ but characteristically affects the kidneys, joints, serous membranes, and skin. Autoantibodies are formed against a variety of self-antigens. The most important **diagnostic autoantibodies** are those against **nuclear antigens**—in particular, antibody to **double-stranded DNA** and to a **soluble nuclear antigen complex** that is part of the **spliceosome** and is termed **Sm (Smith) antigen**. High titers of these two autoantibodies (termed **antinuclear antibodies**) are nearly pathognomonic for SLE.

Antibodies to rheumatoid factor (choice D) are seen in patients with rheumatoid arthritis.

Antineutrophil cytoplasmic antibodies (choices A and C) are seen in patients with small vessel vasculitis (e.g., Wegener granulomatosis).

Anti-Scl-70 (anti-topoisomerase I) are present in systemic scleroderma > CREST sy.

**Diagnosis: Systemic lupus erythematosus**

## Q3

Serum levels of complement proteins may be reduced during the active phase of disease in the patient described in Question 2 due to which of the following mechanisms of disease?

- (A) Binding of complement to immune complexes
- (B) Decreased complement protein biosynthesis
- (C) Defective activation of the complement cascade
- (D) Increased urinary excretion of immunoglobulins
- (E) Stimulation of the acute phase response

## Q3

**Serum levels of complement proteins** may be reduced during the **active phase of disease** in the patient described in Question 2 due to which of the following **mechanisms of disease**?

- (A) Binding of complement to immune complexes
- (B) Decreased complement protein biosynthesis
- (C) Defective activation of the complement cascade
- (D) Increased urinary excretion of immunoglobulins
- (E) Stimulation of the acute phase response

# A3

## **A: Binding of complement to immune complexes.**

Acquired deficiencies of early complement components occur in patients with autoimmune diseases, especially those associated with circulating immune complexes (e.g., systemic lupus erythematosus [SLE]). Antigen-antibody complexes formed in the circulation during the active stage of these diseases lead to a **marked reduction in circulating levels of complement** proteins (hypocomplementemia).

None of the other choices

mediates hypocomplementemia in patients with SLE.

Diagnosis: Systemic lupus erythematosus



## Q4

A 45-year-old woman complains of severe headaches and difficulty swallowing. Over the past 6 months, she has noticed small, red lesions around her mouth as well as thickening of her skin. The patient has “stone facies” on physical examination. A skin biopsy in this patient would most likely show a perivascular accumulation of which of the following extracellular matrix proteins?

- (A) Collagen
- (B) Elastin
- (C) Entactin
- (D) Fibronectin
- (E) Laminin

## Q4

A 45-year-old woman complains of severe headaches and difficulty swallowing. Over the past 6 months, she has noticed small, red lesions around her mouth as well as thickening of her skin. The patient has “stone facies” on physical examination. A skin biopsy in this patient would most likely show a perivascular accumulation of which of the following extracellular matrix proteins?

- (A) Collagen
- (B) Elastin
- (C) Entactin
- (D) Fibronectin
- (E) Laminin

# A4

**A: Collagen.** Scleroderma is an autoimmune disease of connective tissue. Scleroderma is characterized by vasculopathy and excessive collagen deposition in the skin and internal organs, such as the lung, gastrointestinal tract, heart, and kidney. The disease occurs four times as often in women as in men and mostly in persons aged 25 to 50 years.

Progressive systemic sclerosis is characterized by **widespread excessive collagen deposition**. There is emerging evidence for the expansion of fibrogenic clones of fibroblasts. These clones display augmented procollagen synthesis, including **increased circulating levels of type III collagen aminopropeptide**. Tissue levels of the other proteins are not significantly altered in patients with scleroderma.

Diagnosis: Scleroderma

## Q5

During the physical examination of a 22-year-old man, a purified protein derivative isolated from *Mycobacterium tuberculosis* is injected into the skin. Three days later, the injection site appears raised and indurated. Which of the following glycoproteins was directly involved in antigen presentation during the initiation phase of delayed hypersensitivity in this patient?

- (A) CD4
- (B) CD8
- (C) Class I HLA molecules
- (D) Class II HLA molecules
- (E) GlyCAM-1

## Q5

During the physical examination of a 22-year-old man, a **purified protein derivative** isolated from ***Mycobacterium tuberculosis*** is injected into the **skin**. Three days later, the injection site appears raised and indurated. Which of the following **glycoproteins** was **directly involved in antigen presentation** during the initiation phase of delayed hypersensitivity in this patient?

- (A) CD4
- (B) CD8
- (C) Class I HLA molecules
- (D) Class II HLA molecules
- (E) GlyCAM-1



# A5

**D: Class II HLA molecules.** Delayed-type hypersensitivity is defined as a **tissue reaction involving lymphocytes and mononuclear phagocytes**, which occurs in response to a soluble protein antigen and reaches greatest intensity 24 to 48 hours after initiation. In the initial phase, foreign **protein antigens or chemical ligands interact with accessory cells bearing class II HLA molecules**. Protein antigens are actively processed into short peptides within phagolysosomes and are presented on the cell surface in conjunction with the class II HLA molecules.

The latter are recognized by CD4+ T cells (choice A), which become activated to synthesize an array of cytokines. The cytokines recruit and activate lymphocytes, monocytes, fibroblasts, and other inflammatory cells.

Suppressor T cells are CD8+ (choice B). Class I HLA molecules (choice C) provide targets for cell-mediated cytotoxicity. GlyCAM-1 (choice E) is a cell adhesion molecule involved in lymphocyte trafficking.

**Diagnosis: Delayed-type hypersensitivity**

## Q6

A 40-year-old man complains of having yellow skin and sclerae, abdominal tenderness, and dark urine. Physical examination reveals jaundice and mild hepatomegaly. Laboratory studies demonstrate elevated serum bilirubin (3.1 mg/dL), decreased serum albumin (2.5 g/dL), and prolonged prothrombin time (17 seconds). Serologic tests reveal antibodies to hepatitis B core antigen (IgG anti-HBcAg). The serum is also positive for HBsAg and HBeAg. Which of the following glycoproteins serves as the principal cell surface receptor for viral antigens on B lymphocytes in this patient?

- (A) CD4
- (B) CD8
- (C) HLA class I molecules
- (D) HLA class II molecules
- (E) Membrane immunoglobulin

## Q6

A 40-year-old man complains of having **yellow skin and sclerae, abdominal tenderness, and dark urine**. Physical examination reveals **jaundice** and mild **hepatomegaly**. Laboratory studies demonstrate elevated serum **bilirubin** (3.1 mg/dL), decreased serum **albumin** (2.5 g/dL), and prolonged **prothrombin time** (17 seconds). Serologic tests reveal **antibodies to hepatitis B core antigen** (IgG anti-HBcAg). The serum is also **positive for HBsAg and HBeAg**. Which of the following glycoproteins serves as the principal **cell surface receptor for viral antigens on B lymphocytes** in this patient?

- (A) CD4
- (B) CD8
- (C) HLA class I molecules
- (D) HLA class II molecules
- (E) Membrane immunoglobulin

## A6

**E: Membrane immunoglobulin (mIg).** The clinicopathologic findings presented here indicate that this patient is a **chronic HBV carrier with active hepatitis**. Humoral immune responses to specific viral antigens in this patient involve the activation and differentiation of B lymphocytes into antibody-secreting plasma cells. **Analogous to T cells, B cells express an antigen-binding receptor, namely mIg.** This immunoglobulin bears the same antigen specificity as the soluble immunoglobulin that is ultimately secreted.

Class I HLA molecules (choice C) provide targets for CD8+ T cells in cell-mediated cytotoxicity. Class II HLA molecules (choice D) are recognized by CD4+ T cells, which become activated to synthesize an array of cytokines.

**Diagnosis: Humoral immunity, chronic hepatitis**

## Q6b

A 40-year-old man complains of having yellow skin and sclerae, abdominal tenderness, and dark urine. Physical examination reveals jaundice and mild hepatomegaly. Laboratory studies demonstrate elevated serum bilirubin (3.1 mg/dL), decreased serum albumin (2.5 g/dL), and prolonged prothrombin time (17 seconds). Serologic tests reveal antibodies to hepatitis B core antigen (IgG anti-HBcAg). The serum is also positive for HBsAg and HBeAg.

What glycoprotein on virally infected hepatocytes provides a target for cell-mediated cytotoxicity in this patient?

- (A) CD4
- (B) CD8
- (C) Class I HLA molecules
- (D) Class II HLA molecules
- (E) GlyCAM-1



## Q6b

A 40-year-old man complains of having yellow skin and sclerae, abdominal tenderness, and dark urine. Physical examination reveals jaundice and mild hepatomegaly. Laboratory studies demonstrate elevated serum bilirubin (3.1 mg/dL), decreased serum albumin (2.5 g/dL), and prolonged prothrombin time (17 seconds). Serologic tests reveal antibodies to hepatitis B core antigen (IgG anti-HBcAg). The serum is also positive for HBsAg and HBeAg.

What **glycoprotein on virally infected hepatocytes** provides a **target for cell-mediated cytotoxicity** in this patient?

- (A) CD4
- (B) CD8
- (C) Class I HLA molecules
- (D) Class II HLA molecules
- (E) GlyCAM-1

## A6b

A 40-year-old man complains of having yellow skin and sclerae, abdominal tenderness, and dark urine. Physical examination reveals jaundice and mild hepatomegaly. Laboratory studies demonstrate elevated serum bilirubin (3.1 mg/dL), decreased serum albumin (2.5 g/dL), and prolonged prothrombin time (17 seconds). Serologic tests reveal antibodies to hepatitis B core antigen (IgG anti-HBcAg). The serum is also positive for HBsAg and HBeAg.

What **glycoprotein on virally infected hepatocytes** provides a **target for cell-mediated cytotoxicity** in this patient?

- (A) CD4
- (B) CD8
- (C) Class I HLA molecules**
- (D) Class II HLA molecules
- (E) GlyCAM-1

## Q7

A 45-year-old woman presents with a 1-year history of dry mouth and eyes. A biopsy of a minor salivary gland reveals infiltrates of lymphocytes forming focal germinal centers. Which of the following cellular organelles is a target for autoantibodies in this patient?

- (A) Centromere
- (B) Lysosome
- (C) Nucleus
- (D) Peroxisome
- (E) Plasma membrane

## Q7

A 45-year-old woman presents with a 1-year history of **dry mouth and eyes**. A biopsy of a minor salivary gland reveals **infiltrates of lymphocytes forming focal germinal centers**. Which of the following **cellular organelles** is a **target for autoantibodies** in this patient?

- (A) Centromere
- (B) Lysosome
- (C) Nucleus
- (D) Peroxisome
- (E) Plasma membrane

# A7

**C: Nucleus.** In Sjögren syndrome (SS), autoantibodies to soluble nuclear nonhistone proteins, especially the antigens SS-A and SS-B, are found in half of patients with primary SS and are associated with more severe glandular and extraglandular manifestations.

Autoantibodies to DNA or histones are rare. Organ-specific autoantibodies, such as those directed against salivary gland antigens, are distinctly uncommon.

Autoantibodies to centromere proteins (choice A) are seen in the CREST variant of progressive systemic sclerosis.

## Sjögren syndrome

Autoimmune disorder characterized by destruction of exocrine glands (especially lacrimal and salivary). Predominantly affects females 40–60 years old.

Findings:

- Xerophthalmia (↓ tear production and subsequent corneal damage)
- Xerostomia (↓ saliva production)
- Presence of antinuclear antibodies: SS-A (anti-Ro) and/or SS-B (anti-La)
- Bilateral parotid enlargement

Can be a 1° disorder or a 2° syndrome associated with other autoimmune disorders (e.g., rheumatoid arthritis).

Complications—dental caries; mucosa-associated lymphoid tissue (MALT) lymphoma (may present as unilateral parotid enlargement).



## Q8

A 30-year-old woman complains of impaired speech and frequent aspiration of food. Physical examination reveals diplopia and drooping eyelids. A mediastinal mass is removed and diagnosed as thymoma. The symptoms of muscle weakness in this patient are caused by antibodies directed against which of the following cellular components?

- (A) Acetylcholine receptor
- (B) Calcium channel
- (C) Desmoglein-3
- (D) Rheumatoid factor
- (E) Thyroid-stimulating hormone (TSH) receptor

## Q8

A 30-year-old woman complains of **impaired speech** and frequent **aspiration of food**. Physical examination reveals **diplopia** and **drooping eyelids**. A mediastinal mass is removed and diagnosed as **thymoma**. The symptoms of **muscle weakness** in this patient are caused by **antibodies** directed against which of the following cellular components?

- (A) Acetylcholine receptor
- (B) Calcium channel
- (C) Desmoglein-3
- (D) Rheumatoid factor
- (E) Thyroid-stimulating hormone (TSH) receptor

# A8

## Neuromuscular junction diseases

	Myasthenia gravis	Lambert-Eaton myasthenic syndrome
FREQUENCY	Most common NMJ disorder	Uncommon
PATHOPHYSIOLOGY	Autoantibodies to postsynaptic ACh receptor	Autoantibodies to presynaptic Ca <sup>2+</sup> channel → ↓ ACh release
CLINICAL	Ptosis, diplopia, weakness Worsens with muscle use	Proximal muscle weakness, autonomic symptoms (dry mouth, impotence) Improves with muscle use
ASSOCIATED WITH	Thymoma, thymic hyperplasia	Small cell lung cancer
AChE INHIBITOR ADMINISTRATION	Reversal of symptoms	Minimal effect



## Q9

A 31-year-old man with AIDS complains of difficulty swallowing. Examination of his oral cavity demonstrates whitish membranes covering much of his tongue and palate. Endoscopy also reveals several whitish, ulcerated lesions in the esophagus. These pathologic findings are fundamentally caused by loss of which of the following immune cells in this patient?

- (A) B lymphocytes
- (B) Helper T lymphocytes
- (C) Killer T lymphocytes
- (D) Monocytes/macrophages
- (E) Natural killer (NK) cells

## Q9

A 31-year-old man with **AIDS** complains of difficulty swallowing. Examination of his oral cavity demonstrates **whitish membranes covering much of his tongue and palate**. Endoscopy also reveals several whitish, ulcerated lesions in the esophagus. These pathologic findings are fundamentally **caused by loss of which of the following immune cells** in this patient?

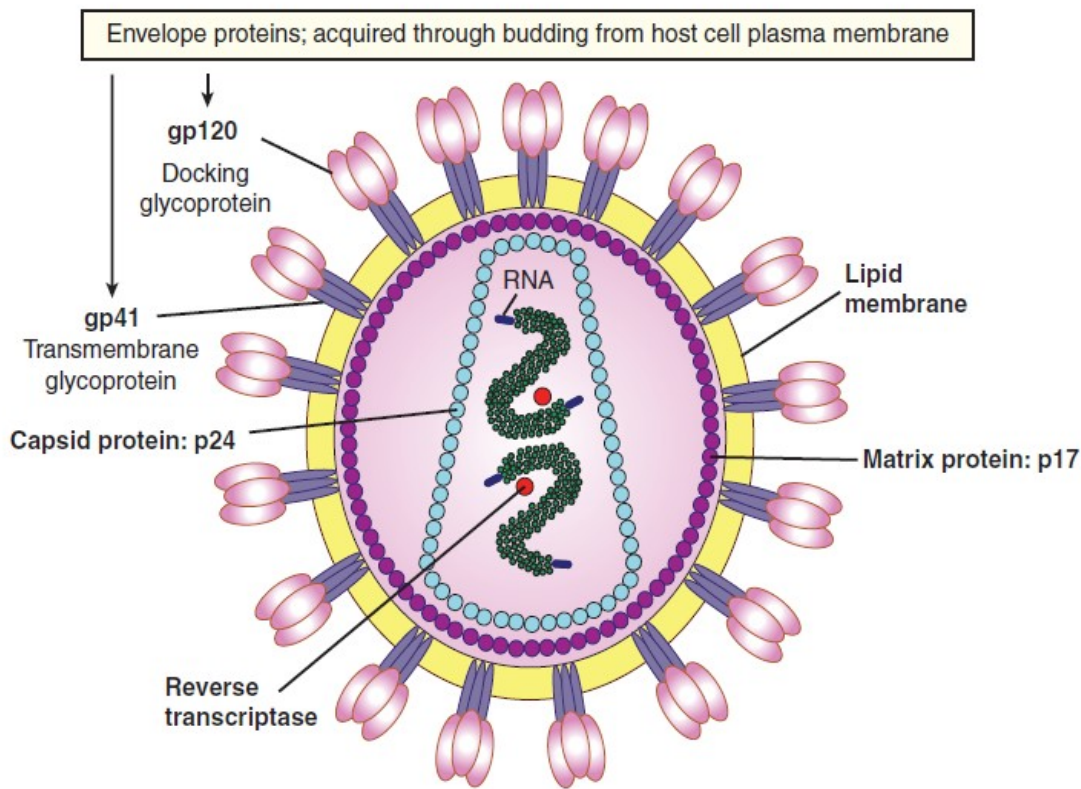
- (A) B lymphocytes
- (B) Helper T lymphocytes
- (C) Killer T lymphocytes
- (D) Monocytes/macrophages
- (E) Natural killer (NK) cells



# A9

**B: Helper T lymphocytes.** The fundamental lesion is **infection of CD4+ (helper) T lymphocytes**, which leads to the depletion of this cell population and impaired immune function.

## HIV



Diploid genome (2 molecules of RNA).

The 3 structural genes (protein coded for):

- *env* (gp120 and gp41):
  - Formed from cleavage of gp160 to form envelope glycoproteins.
  - gp120—attachment to host CD4+ T cell.
  - gp41—fusion and entry.
- *gag* (p24)—capsid protein.
- *pol*—reverse transcriptase, aspartate protease, integrase.

Reverse transcriptase synthesizes dsDNA from RNA; dsDNA integrates into host genome. Virus binds CCR5 (early) or CXCR4 (late) co-receptor and CD4 on T cells; binds CCR5 and CD4 on macrophages.

Homozygous CCR5 mutation = immunity.

Heterozygous CCR5 mutation = slower course.

## Q9b

A 31-year-old man with AIDS complains of difficulty swallowing. Examination of his oral cavity demonstrates whitish membranes covering much of his tongue and palate. Endoscopy also reveals several whitish, ulcerated lesions in the esophagus.

Which of the following enzymes converts the HIV genome into double-stranded DNA in host cells in this patient?

- (A) DNA polymerase (Pol-1)
- (B) DNA polymerase (Pol-2)
- (C) Integrase
- (D) Reverse transcriptase
- (E) Topoisomerase

## Q9b

A 31-year-old man with AIDS complains of difficulty swallowing. Examination of his oral cavity demonstrates whitish membranes covering much of his tongue and palate. Endoscopy also reveals several whitish, ulcerated lesions in the esophagus.

Which of the following enzymes **converts the HIV genome into double-stranded DNA in host cells** in this patient?

- (A) DNA polymerase (Pol-1)
- (B) DNA polymerase (Pol-2)
- (C) Integrase
- (D) Reverse transcriptase
- (E) Topoisomerase

## A9b

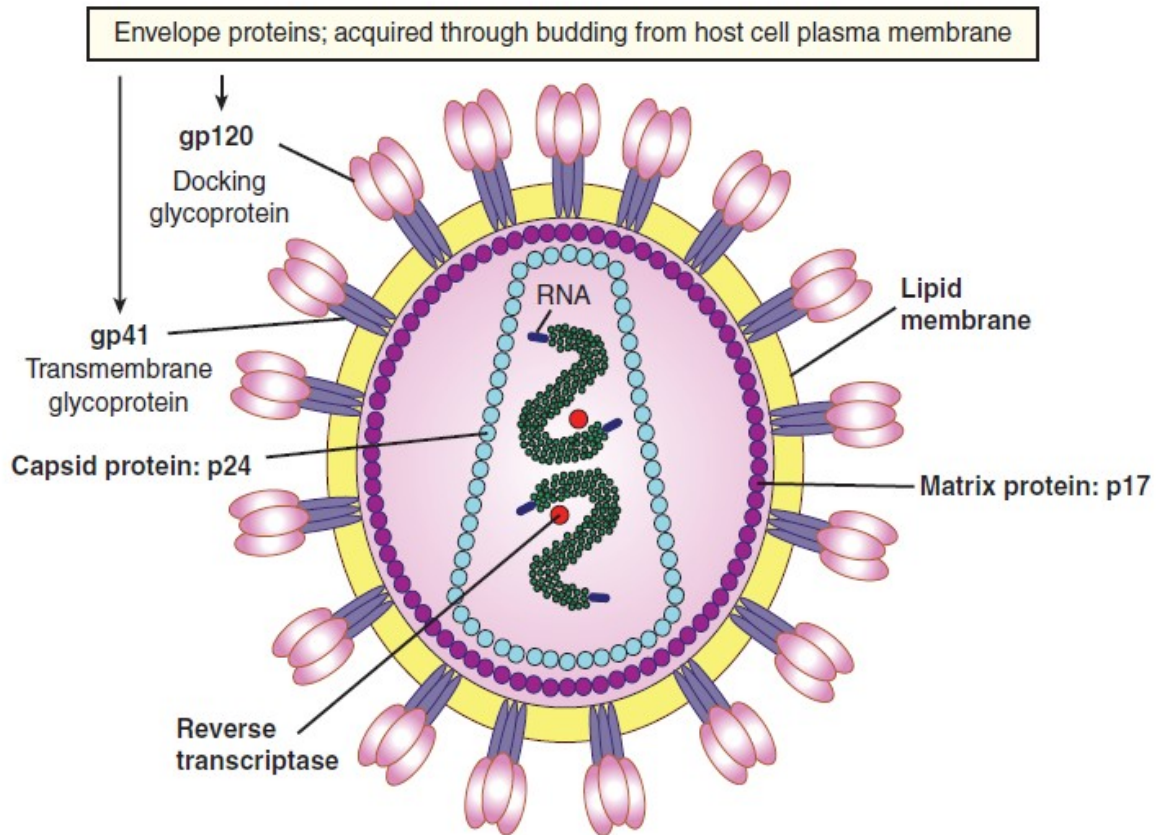
D: Reverse transcriptase. The primary etiologic agent of AIDS is HIV-1, an enveloped **RNA retrovirus** that contains a **reverse transcriptase (RNA-dependent DNA polymerase)**. After it enters into the cytoplasm of a T lymphocyte, the virus is uncoated, and its RNA is copied into double-stranded DNA by retroviral reverse transcriptase. The DNA derived from the virus is integrated into the host genome by the viral integrase protein (choice C), thereby producing the latent proviral form of HIV-1. Viral genes are replicated along with host chromosomes and, therefore, persist for the life of the cell.

Diagnosis: AIDS



# A9b

## HIV



Diploid genome (2 molecules of RNA).

The 3 structural genes (protein coded for):

- *env* (gp120 and gp41):
  - Formed from cleavage of gp160 to form envelope glycoproteins.
  - gp120—attachment to host CD4+ T cell.
  - gp41—fusion and entry.
- *gag* (p24)—capsid protein.
- *pol*—reverse transcriptase, aspartate protease, integrase.

Reverse transcriptase synthesizes dsDNA from RNA; dsDNA integrates into host genome.

Virus binds CCR5 (early) or CXCR4 (late) co-receptor and CD4 on T cells; binds CCR5 and CD4 on macrophages.

Homozygous CCR5 mutation = immunity.

Heterozygous CCR5 mutation = slower course.



## Q10

A 12-month-old infant with a history of recurrent infections, eczema, generalized edema, and easy bruising is diagnosed with an X-linked, recessive, congenital immunodeficiency. The CBC shows thrombocytopenia. What is the most likely diagnosis?

- (A) DiGeorge syndrome
- (B) Isolated IgA deficiency
- (C) Severe combined immunodeficiency
- (D) Wiskott-Aldrich syndrome
- (E) X-linked agammaglobulinemia of Bruton

## Q10

A 12-month-old infant with a history of recurrent infections, eczema, generalized edema, and easy bruising is diagnosed with an X-linked, recessive, congenital immunodeficiency. The CBC shows thrombocytopenia. What is the most likely diagnosis?

- (A) DiGeorge syndrome
- (B) Isolated IgA deficiency
- (C) Severe combined immunodeficiency
- (D) Wiskott-Aldrich syndrome
- (E) X-linked agammaglobulinemia of Bruton

# A10

D: **Wiskott-Aldrich syndrome**. This rare syndrome is characterized by

- (1) recurrent infections,
- (2) hemorrhages secondary to thrombocytopenia, and
- (3) eczema.

It typically manifests in boys within the **first few months of life** as **petechiae** and **recurrent infections (e.g., diarrhea)**. It is caused by numerous distinct mutations in a gene on the X chromosome that encodes a protein called WASP (Wiskott-Aldrich syndrome protein), which is expressed at high levels in lymphocytes and megakaryocytes. WASP binds members of the Rho family of GTPases. WASP itself controls the assembly of **actin filaments** that are required to form **microvesicles**.

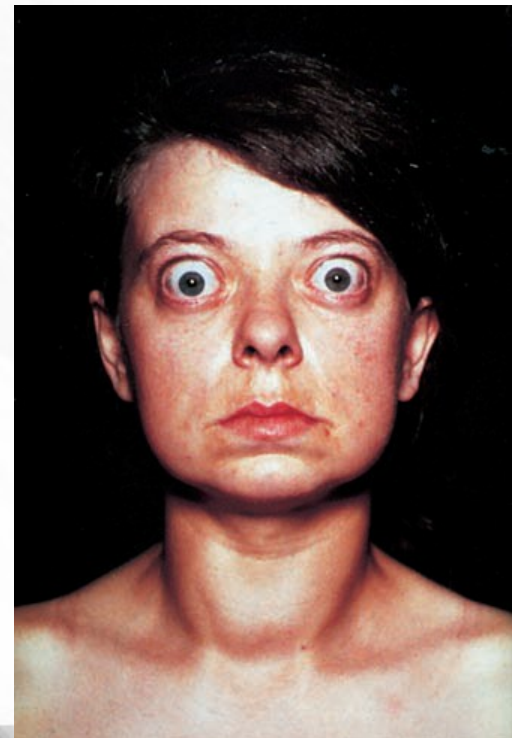X-linked agammaglobulinemia of Bruton (choice E) is not associated with thrombocytopenia and eczema. Choices A, B, and C are not X-linked genetic diseases.

Diagnosis: Wiskott-Aldrich syndrome

## Q11

A 53-year-old woman complains of progressive weight loss, nervousness, and sweating. Physical examination reveals tachycardia and exophthalmos. Her thyroid is diffusely enlarged and warm on palpation. Serum levels of thyroid-stimulating hormone (TSH) are low, and levels of thyroid hormones (T<sub>3</sub> and T<sub>4</sub>) are markedly elevated. Which of the following mechanisms of disease best explains the pathogenesis of this patient's thyroid condition?

- (A) Antibody-dependent cellular cytotoxicity
- (B) Cytopathic autoantibodies
- (C) Delayed-type hypersensitivity
- (D) Immediate hypersensitivity
- (E) Immune complex disease

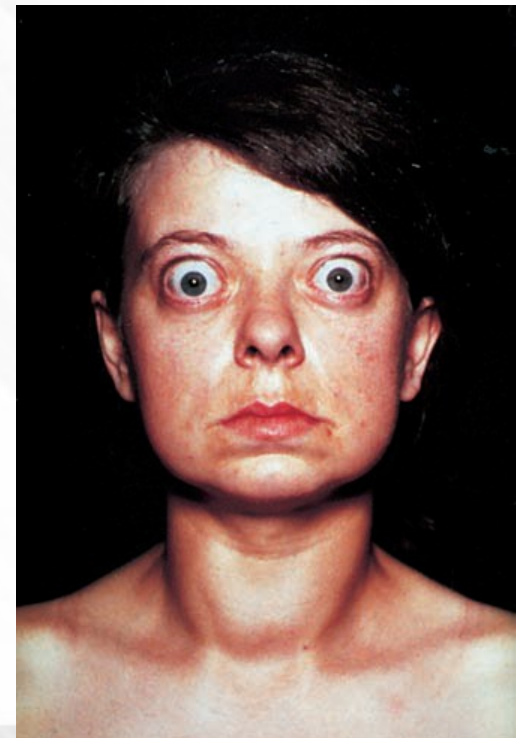




## Q11

A 53-year-old woman complains of progressive **weight loss, nervousness, and sweating**. Physical examination reveals **tachycardia and exophthalmos**. Her thyroid is diffusely **enlarged** and **warm** on palpation. Serum levels of thyroid-stimulating hormone (TSH) are **low**, and levels of thyroid hormones (T<sub>3</sub> and T<sub>4</sub>) are **markedly elevated**. Which of the following mechanisms of disease best explains the **pathogenesis of this patient's thyroid condition**?

- (A) Antibody-dependent cellular cytotoxicity
- (B) Cytopathic autoantibodies
- (C) Delayed-type hypersensitivity
- (D) Immediate hypersensitivity
- (E) Immune complex disease





## A11

The answer is B: **Cytopathic autoantibodies**. Graves disease is a type II hypersensitivity disorder caused by antibodies to the TSH receptor on follicular cells of the thyroid. **Antibody binding to the TSH receptor stimulates a release of tetraiodothyronine (T<sub>4</sub>) and triiodothyronine (T<sub>3</sub>) from the thyroid into the circulation.** Circulating T<sub>4</sub> and T<sub>3</sub> suppress TSH production in the pituitary. Sweating, weight loss, and tachycardia are evidence of the hypermetabolism typical of hyperthyroidism. Graves disease also causes exophthalmos.

Delayed-type hypersensitivity (choice C) is seen in patients with poison ivy and graft rejection.

Immune complex disease (choice E) is caused by deposition of immune complexes and complement activation.

Diagnosis: Graves disease

# Děkuji za účast a diskusi

FB: USMLE @ Masaryk



Marek Čierny  
(324602 at mail.muni.cz)