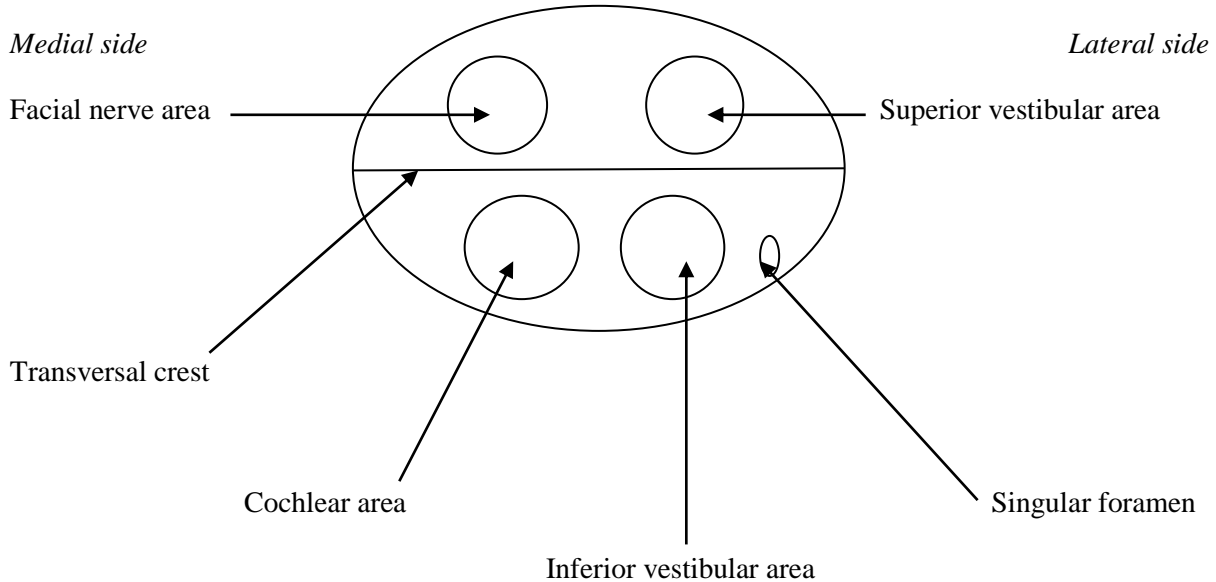


## Temporal canals

1. **Canalis nervi facialis** – begins at the bottom of internal acoustic meatus and ends in stylomastoid foramen; (facial nerve)

The bottom of internal acoustic meatus:



- The canal has three parts:
  1. After the canal began at bottom of internal acoustic meatus it goes upright to the longitudinal axis of pyramis (there goes out the branch called greater petrosal nerve).
  2. Near the greater petrosal nerve hiatus it turns to the lateral side and goes at the medial wall of middle ear cavity. Then the canal is located at the dorsal wall of middle ear cavity. (parallel with the longitudinal axis)
  3. The last part of facial canal turns downwards and ends in stylomastoid foramen.

**Canaliculus chordae tympani** – chorda tympani is branch of facial nerve and begins in the 3<sup>rd</sup> part of facial canal and ends in petrotympanic fissure; (chorda tympani)

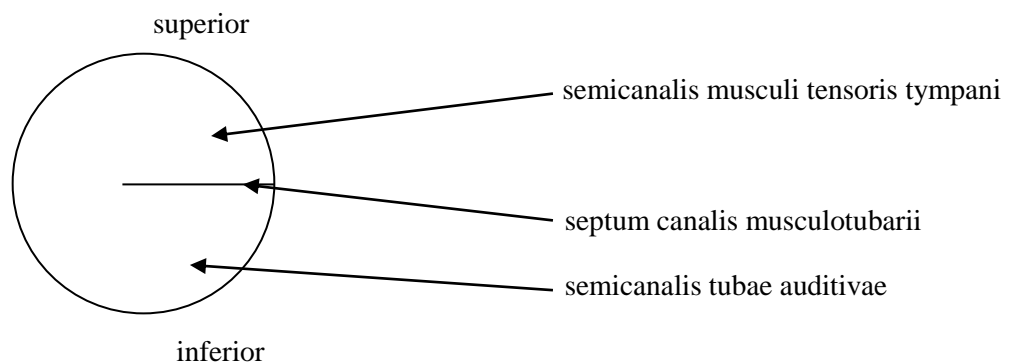
**Carotid canal (canalis caroticus)** – it starts at inferior surface of pyramis in external aperture of carotid canal;- it has sigmoid shape (because the blood pressure is too high for nerve tissue, it could cause damage of brain. So that the function of this canal is to reduce blood pressure before the blood enters to the brain);-ends at the top of pyramis (internal aperture of carotid canal); (internal carotid artery)

**Caroticotympanic canaliculi (canaliculi caroticotympanici)** – they start within the carotid canal (first curvature) and end in the middle ear cavity ; (caroticotympanic nerves)

**Mastoid canaliculus (canaliculus mastoideus)** - starts at the bottom of jugular fossa and ends in tympanomastoid fissure; (auricular branch of vagus nerve)

**Tympanic canaliculus (canaliculus tympanicus)** - starts at the bottom of fossula petrosa (between the jugular fossa and external aperture of carotid canal), it goes through the middle ear cavity and ends in lesser petrosal hiatus; (tympanic nerve → lesser petrosal nerve)

**Musculotubarius canal (canalis musculotubarius)** – begins at the top of pyramis more ventrally than the internal aperture of carotid canal; is divided by the septum canalis musculotubarii into two levels: upper (semicanalis muscoli tensoris tympani) and lower (semicanalis tubae auditivae); ends in middle ear cavity; (tensor tympani muscle and Eustachian tube)



**Vestibular canaliculus (canaliculus vestibuli)** – this canaliculus is for endolymfa drainage; it starts in the inner ear and ends at the posterior surface of pyramis in external aperture of aqueductus vestibuli

**Cochlear canaliculus (canaliculus cochleae)** - this canaliculus is for perilymfa drainage; it starts in the inner ear and ends in external aperture of cochlear canaliculus