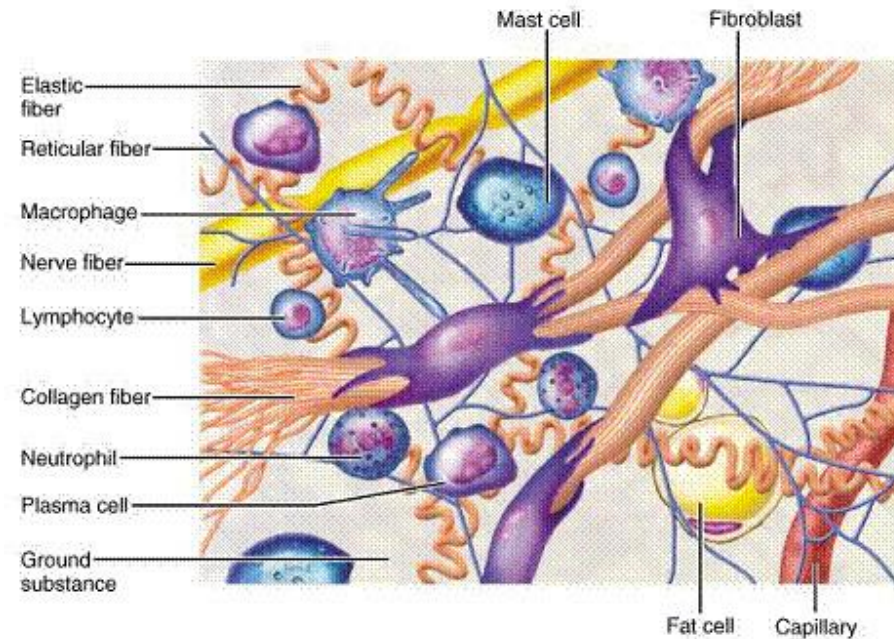
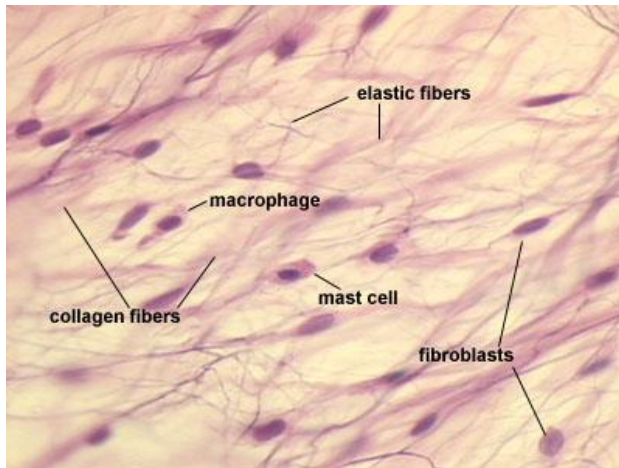
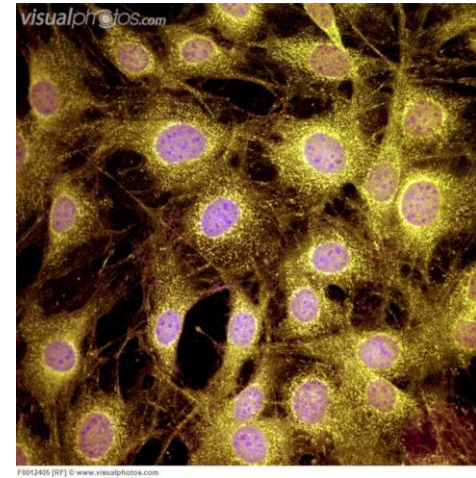


Vazivo

- Mezenchym
- Stavba:
 - Buňky
 - Mezibuněčná hmota
 - Fibrilární složka
 - Interfibrilární (amorfní)



Buňky vaziva

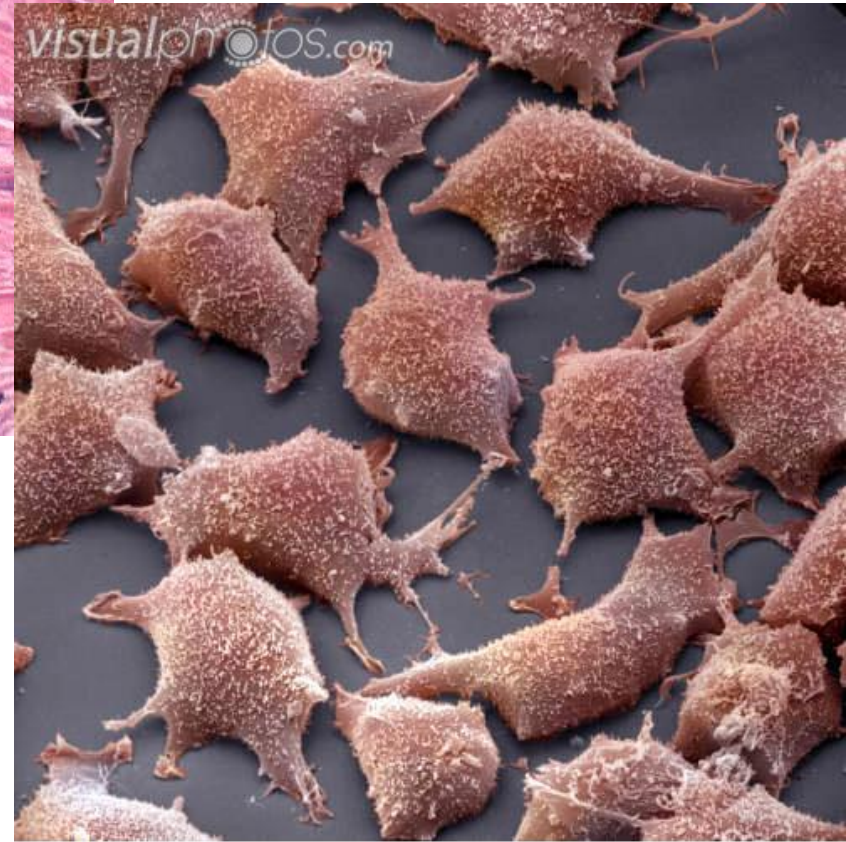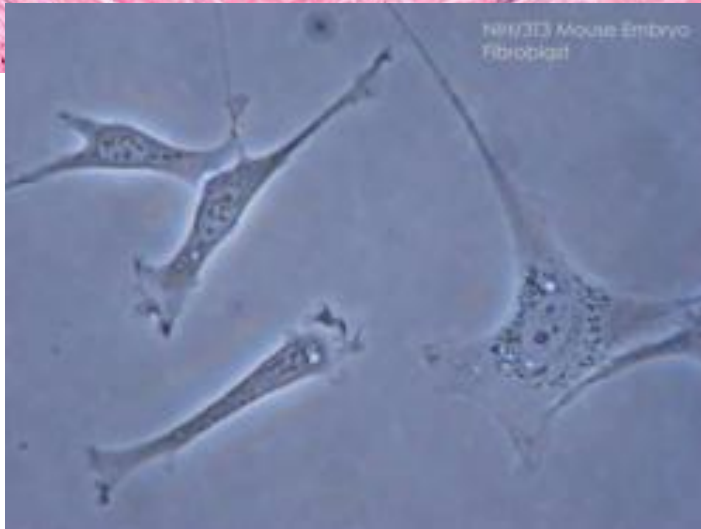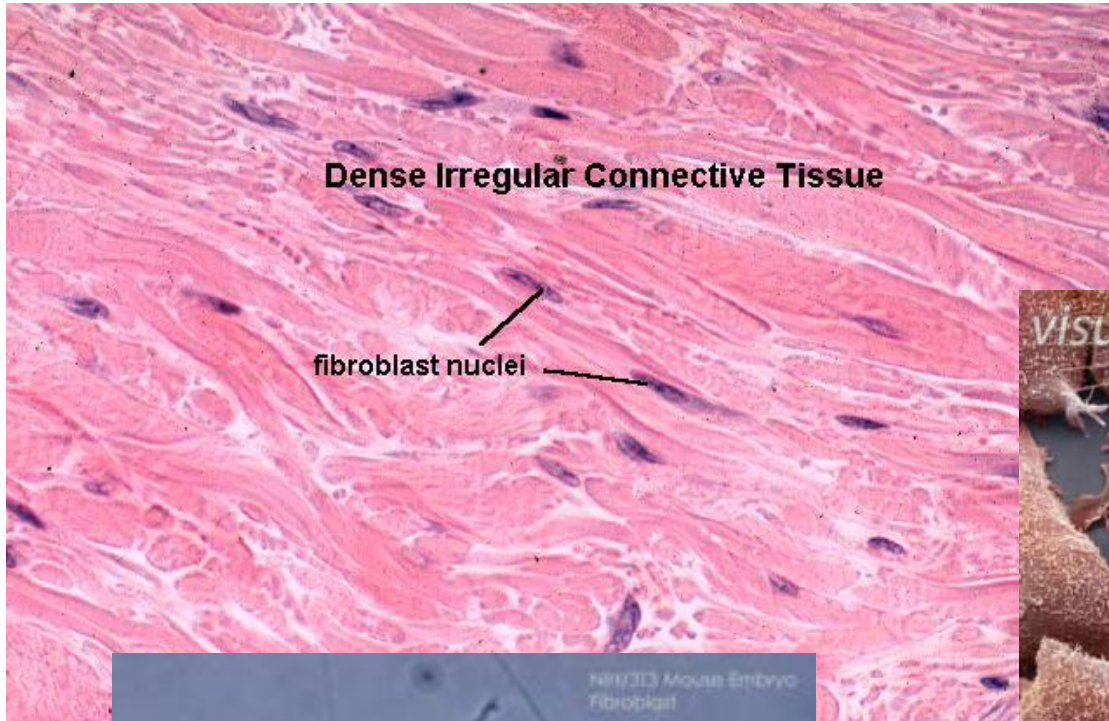
- Fibroblasty a fibrocyty
- Retikulární buňky
- Pigmentové buňky
- Nediferencované buňky

vaziva = tkáňové kmenové buňky

- Tukové buňky
 - Univakuolární adipocyt
 - Multivakuolární adipocyt

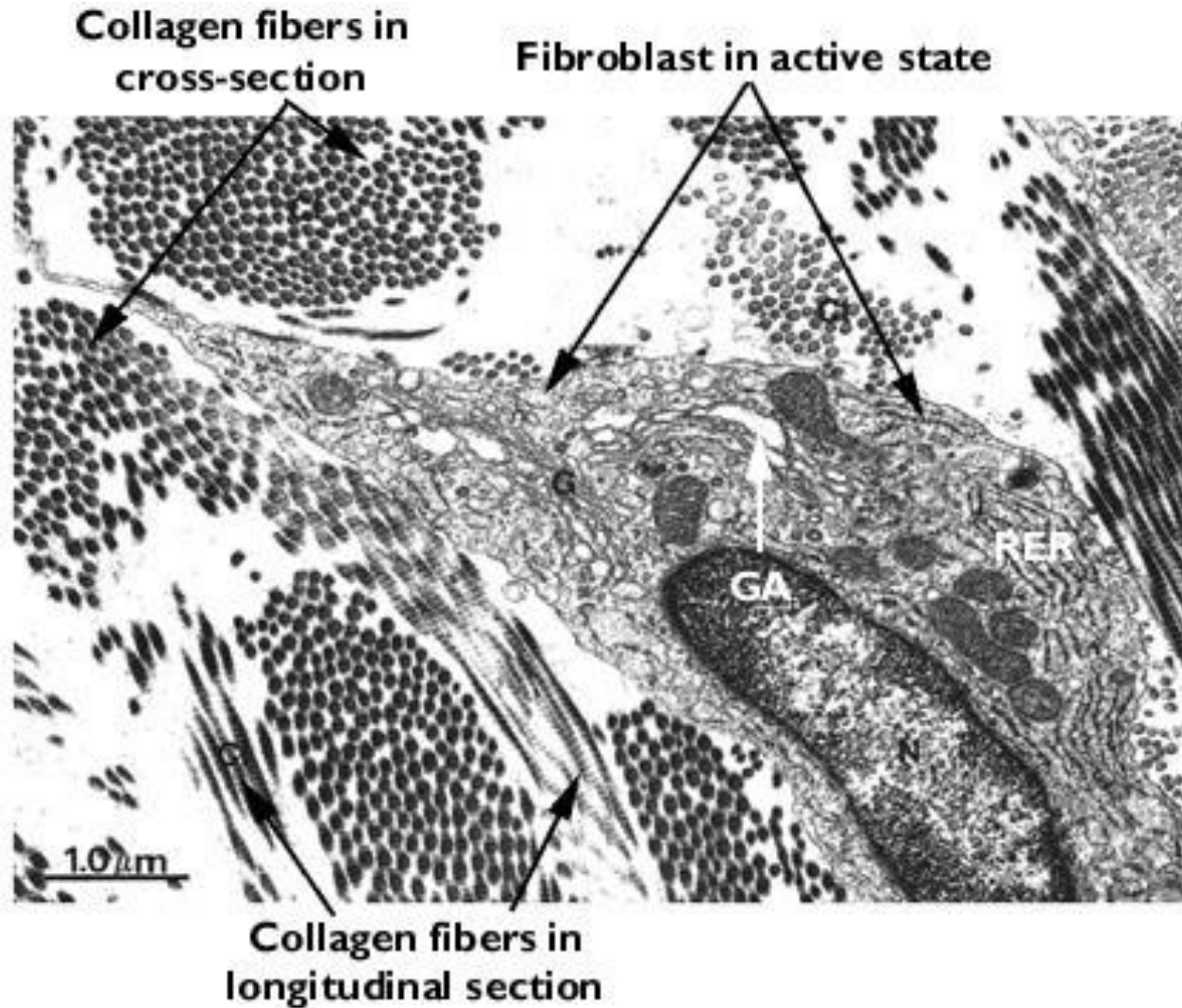
- Leukocyty
 - Histiocyty (makrofágy)
 - Heparinocyty (žírné buňky)
 - Plazmatické buňky
 - Lymfocyty
 - Eosinofily
 - Neutrofily

Fibroblasty, fibrocyty

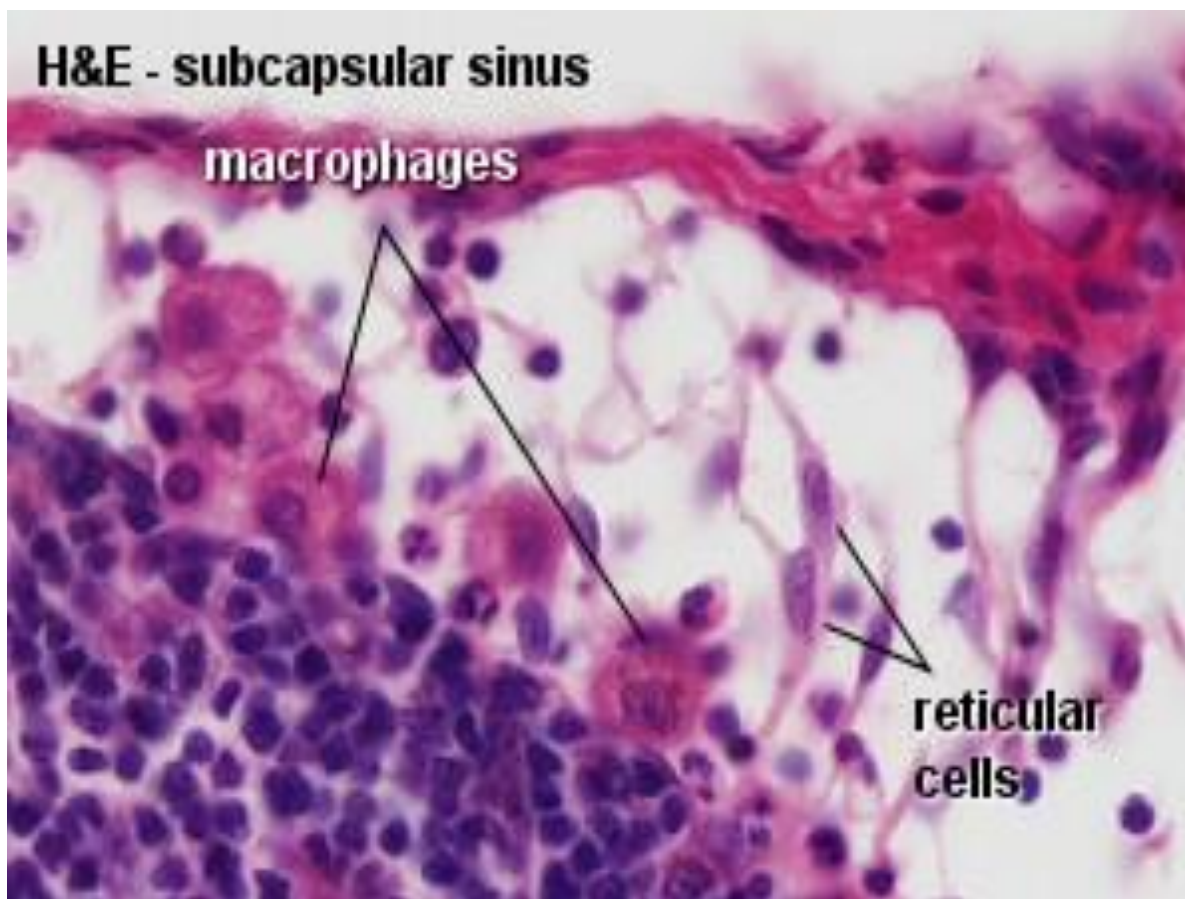


BJ4415 [RM] © www.visualphotos.com

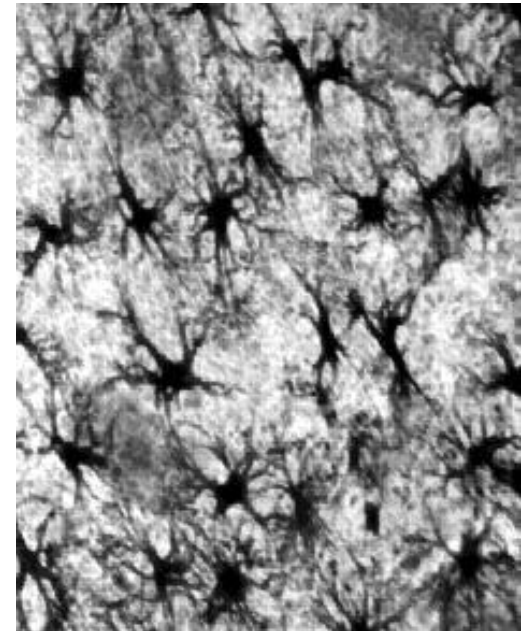
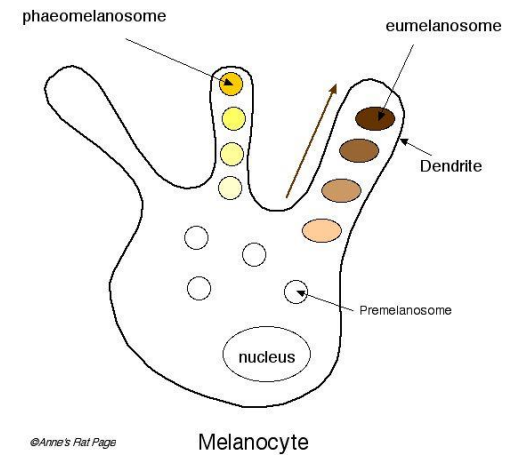
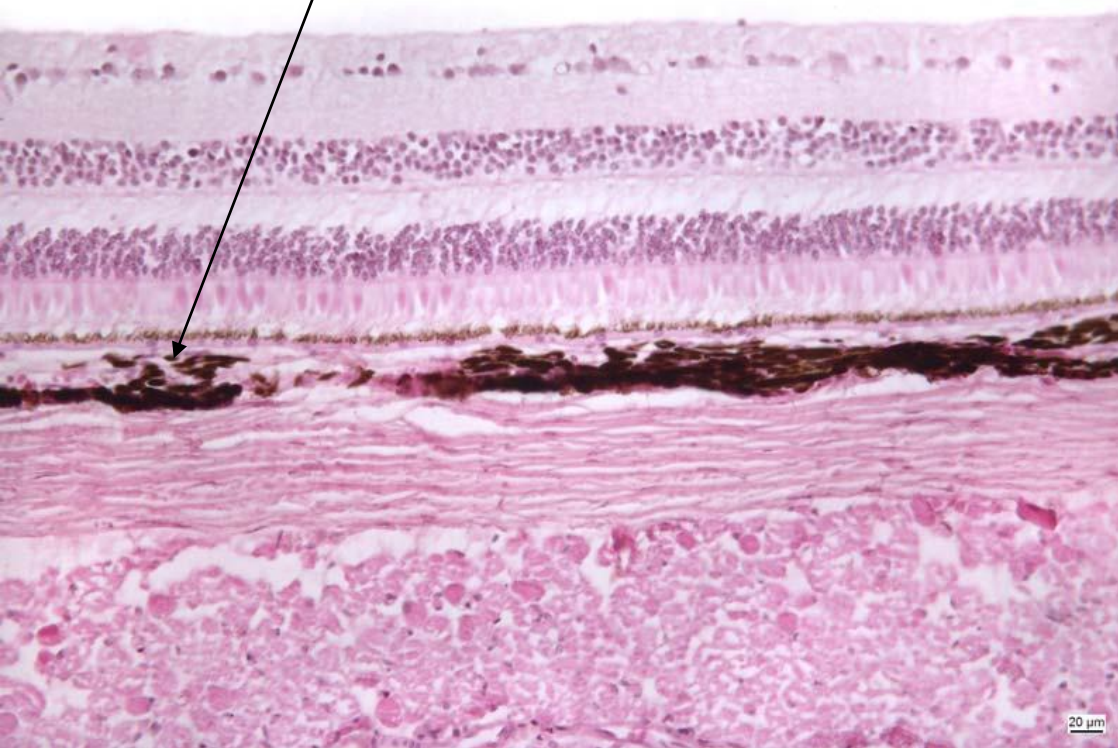
Fibroblasty a kolagenní vlákna



Retikulární buňky

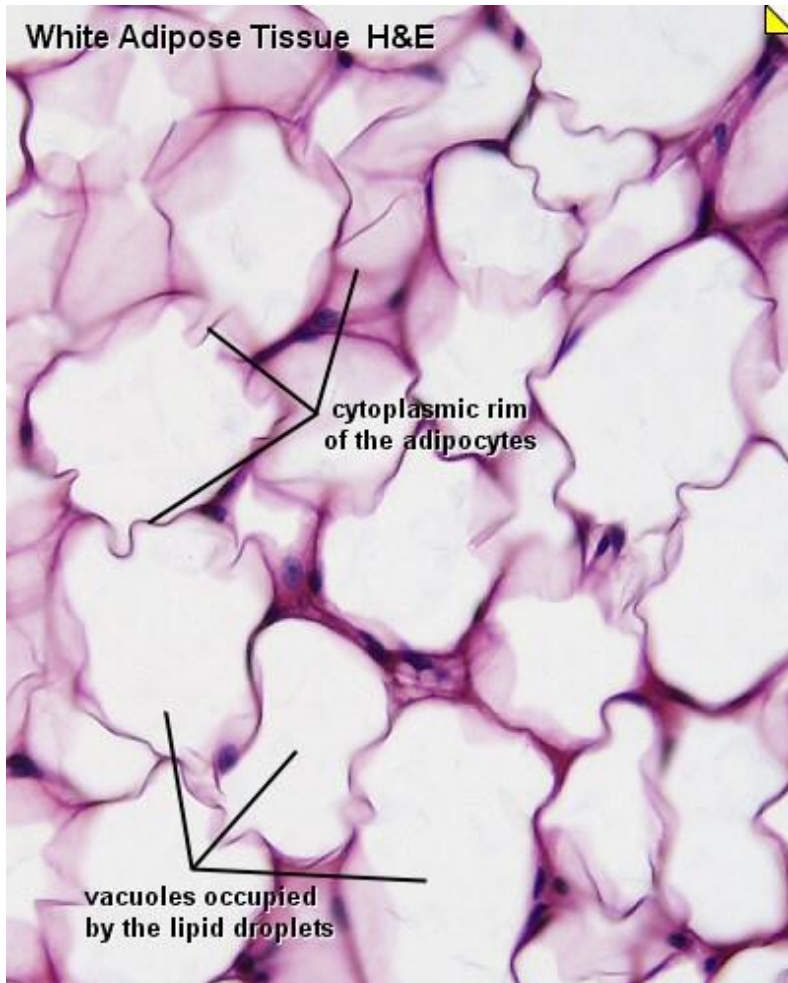


Pigmentové buňky

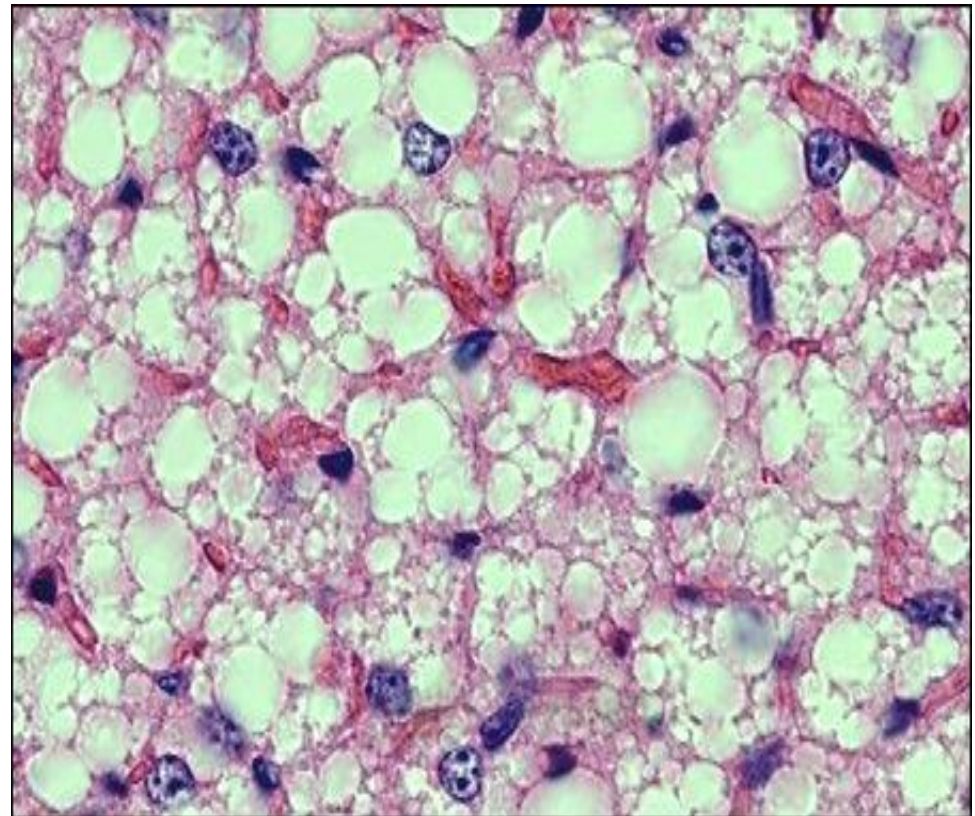


Tukové buňky

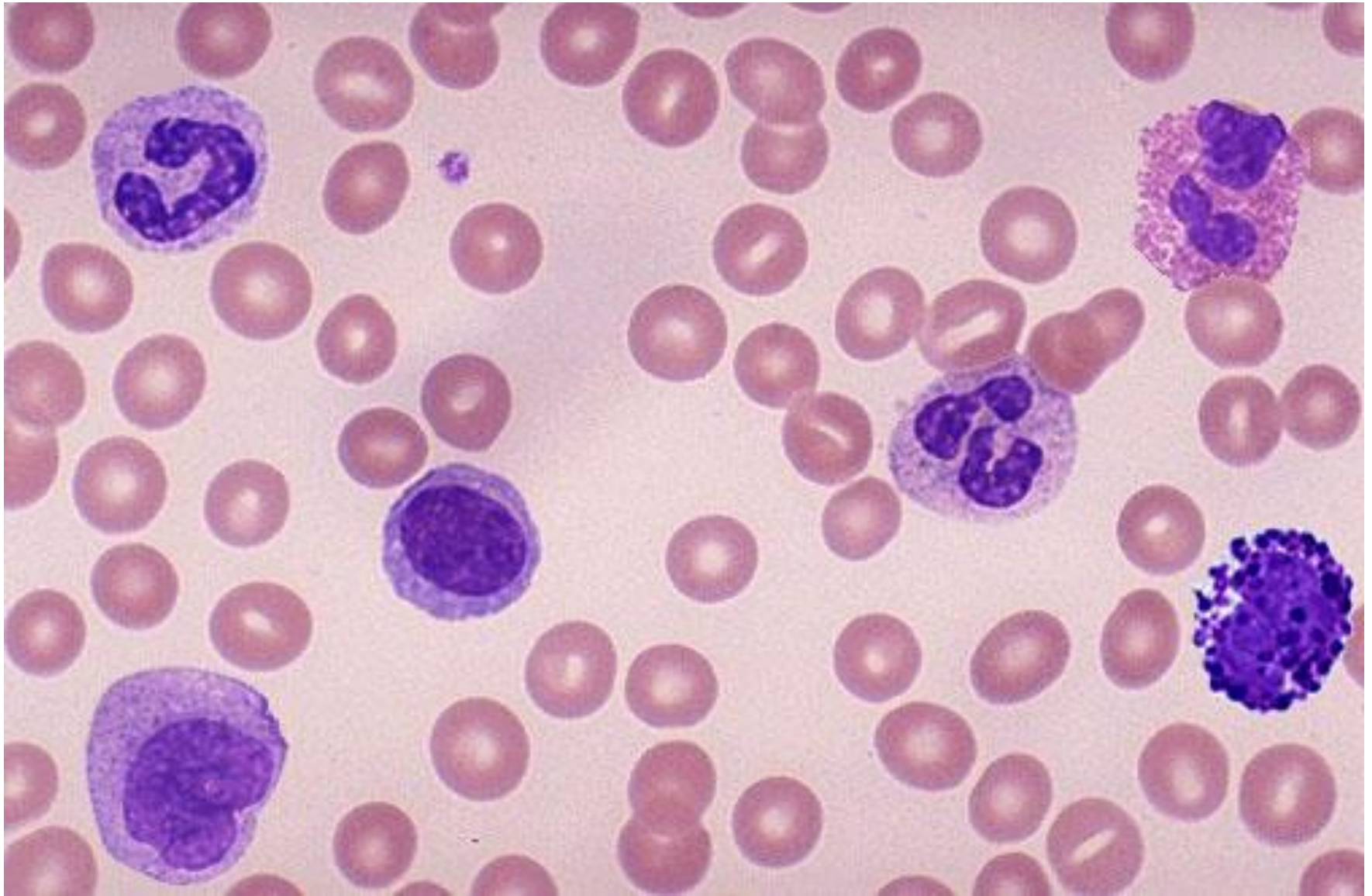univakuolární



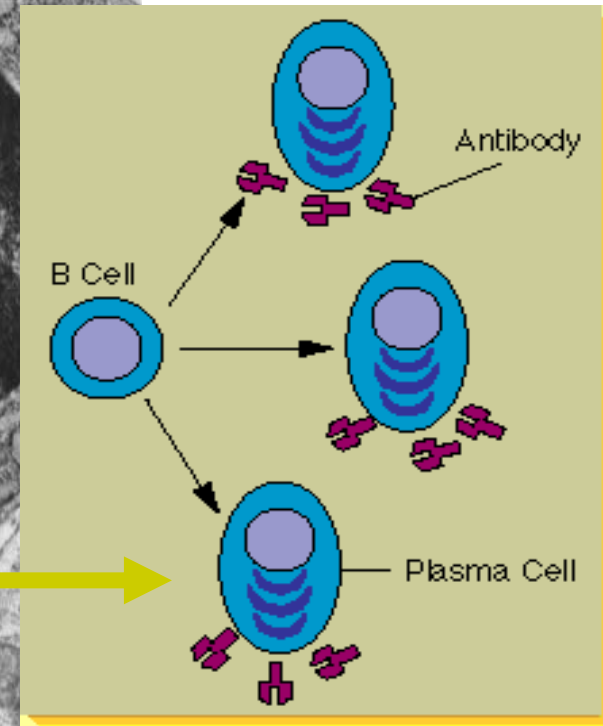
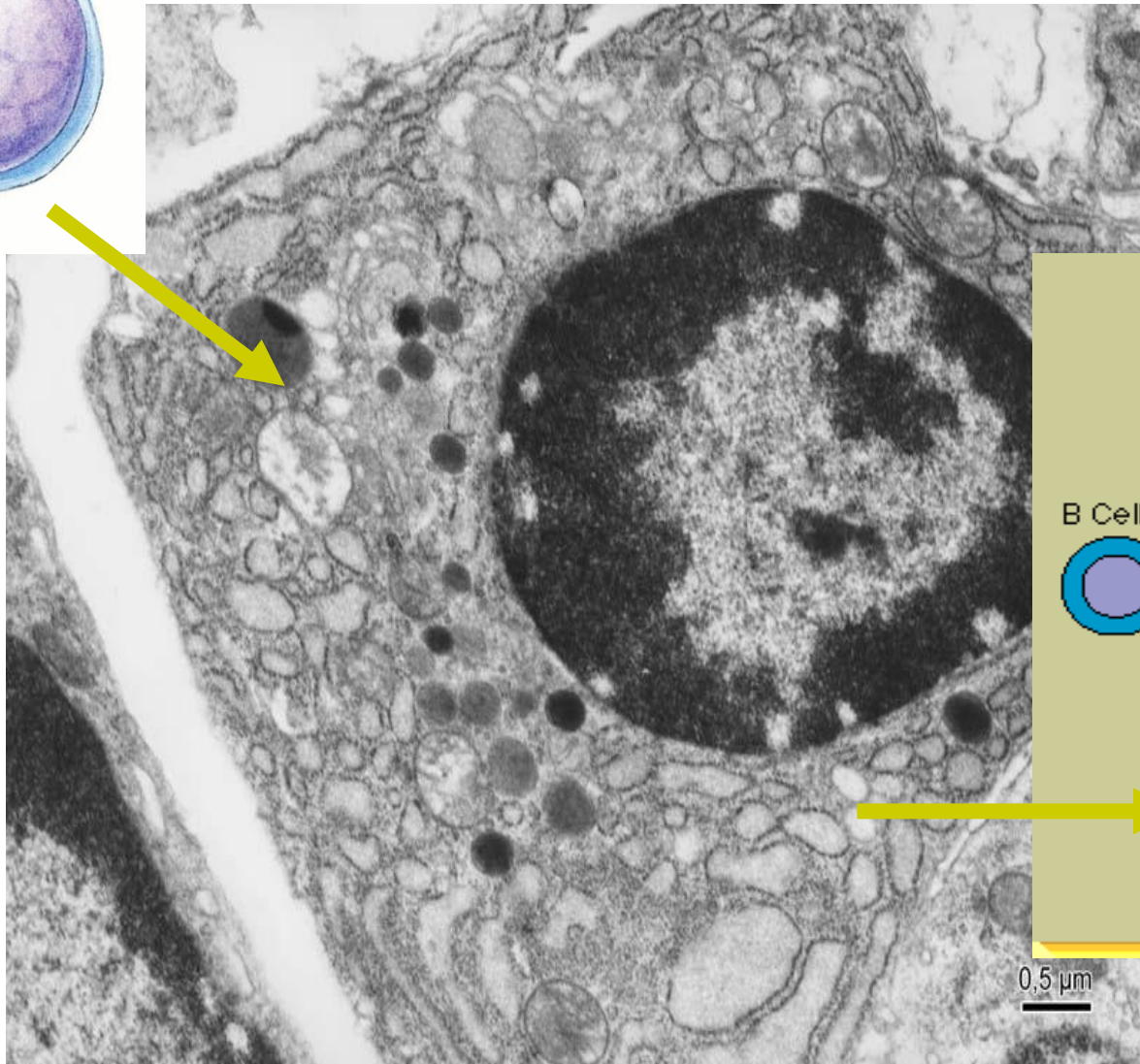
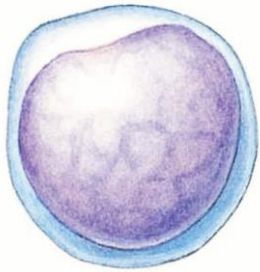
multivakuolární



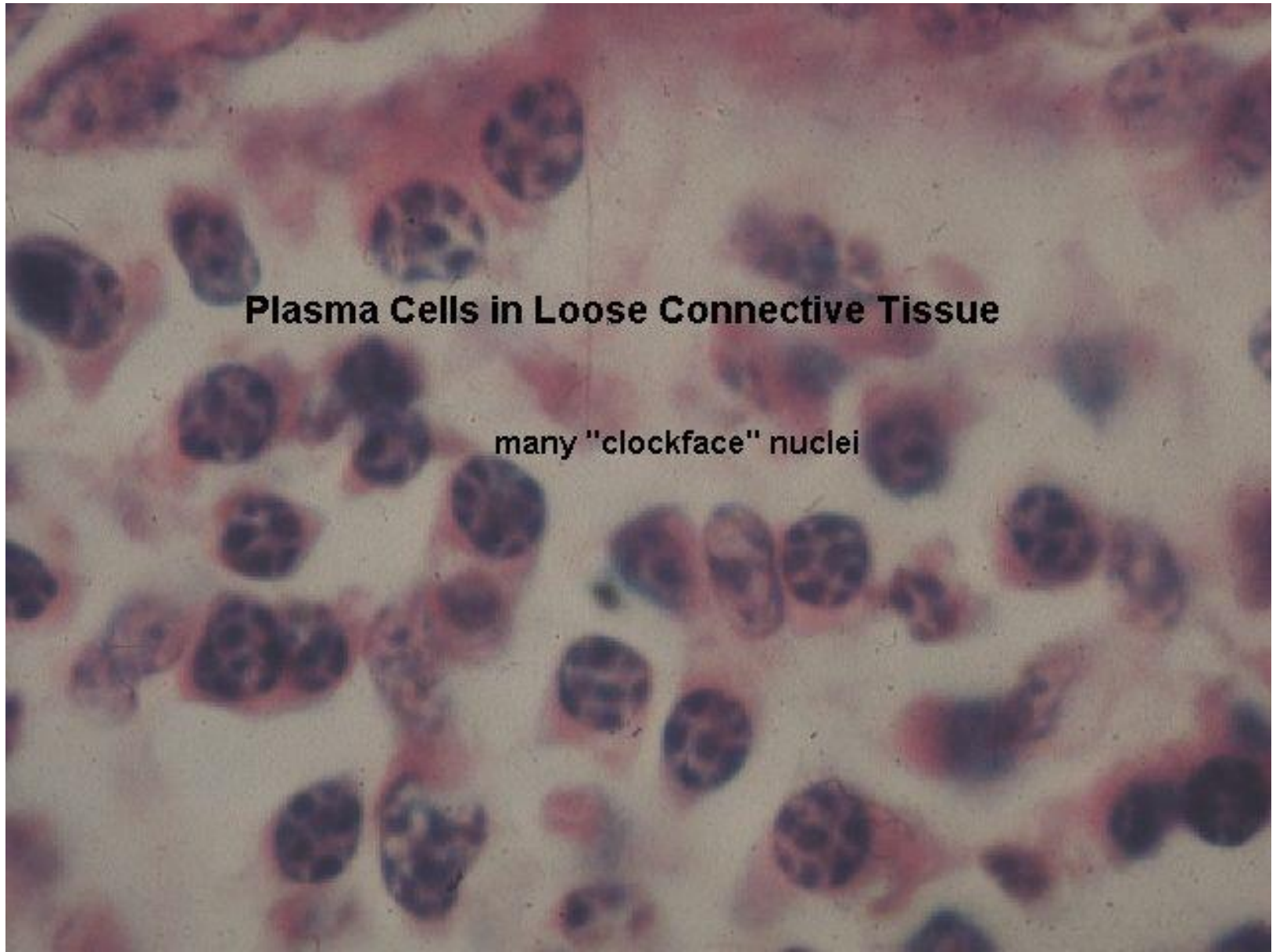
Pohyblivé (migrující) buňky vaziva



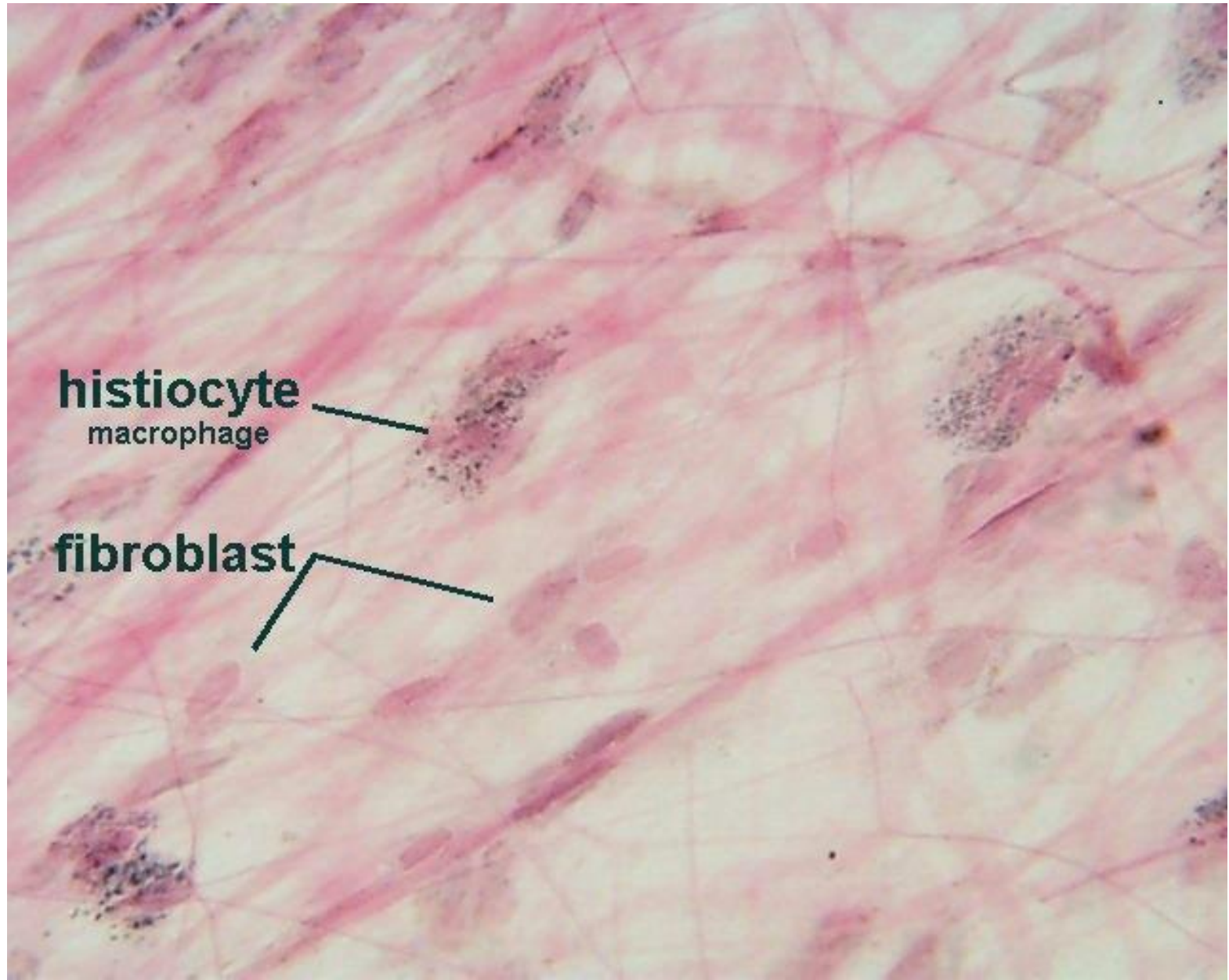
Plazmatické buňky



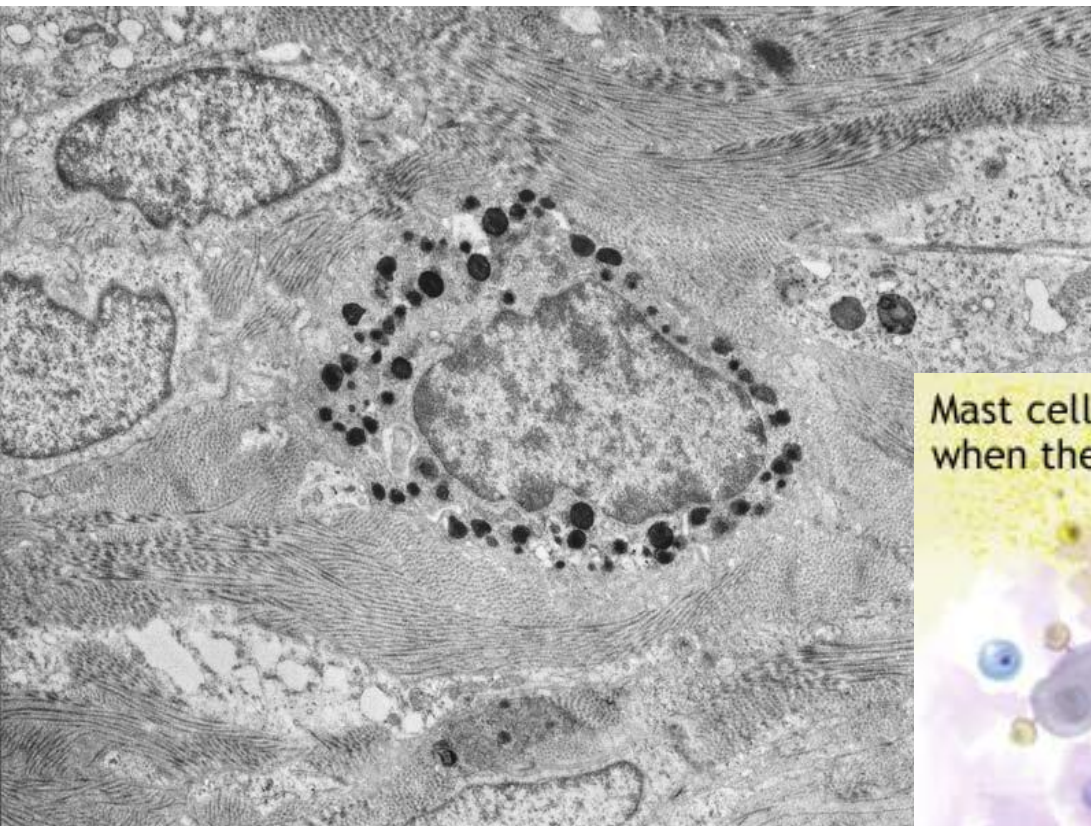
Plazmatické buňky



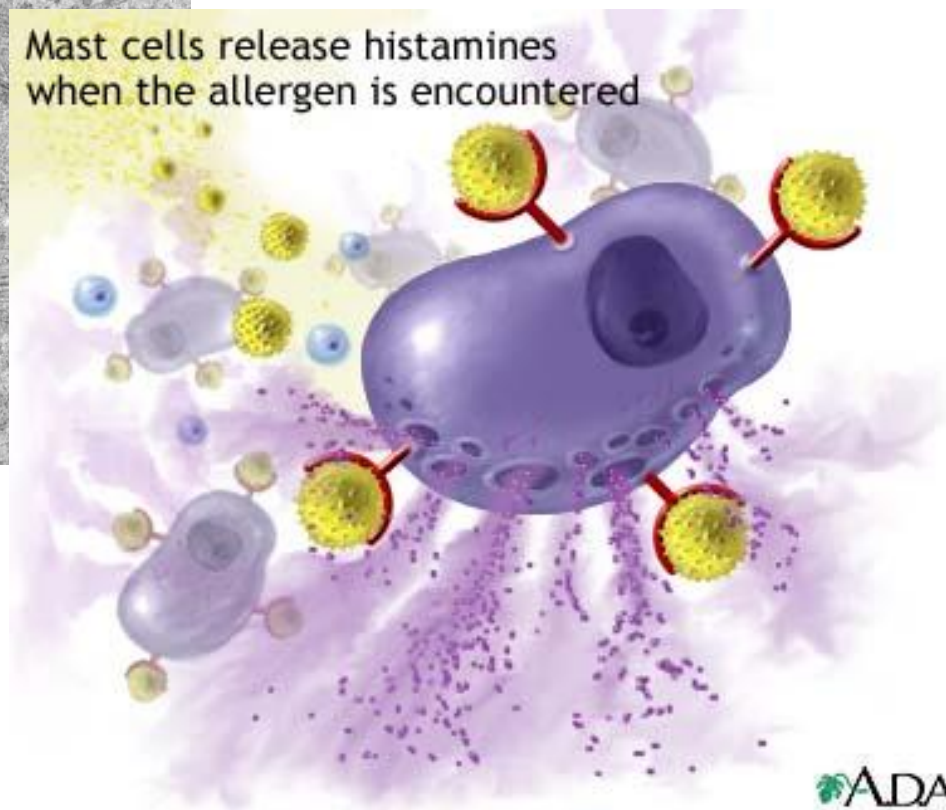Makrofág



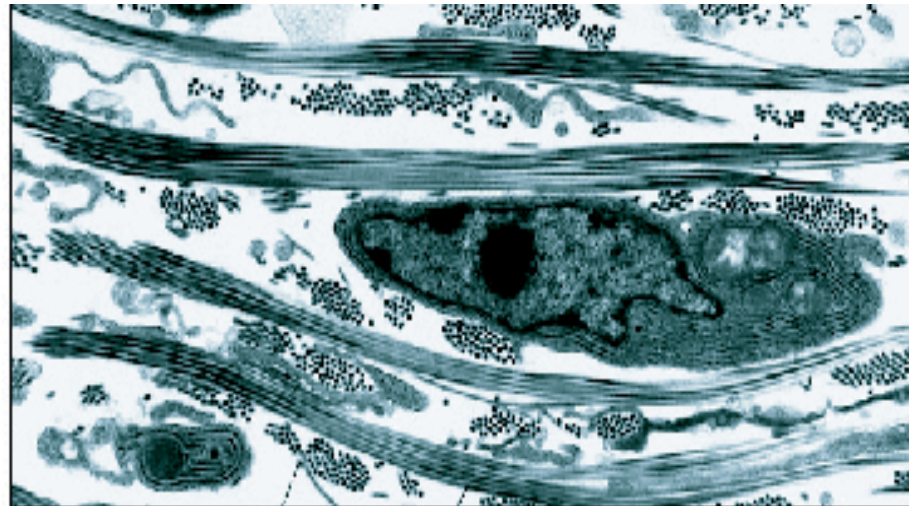
Žírné buňky



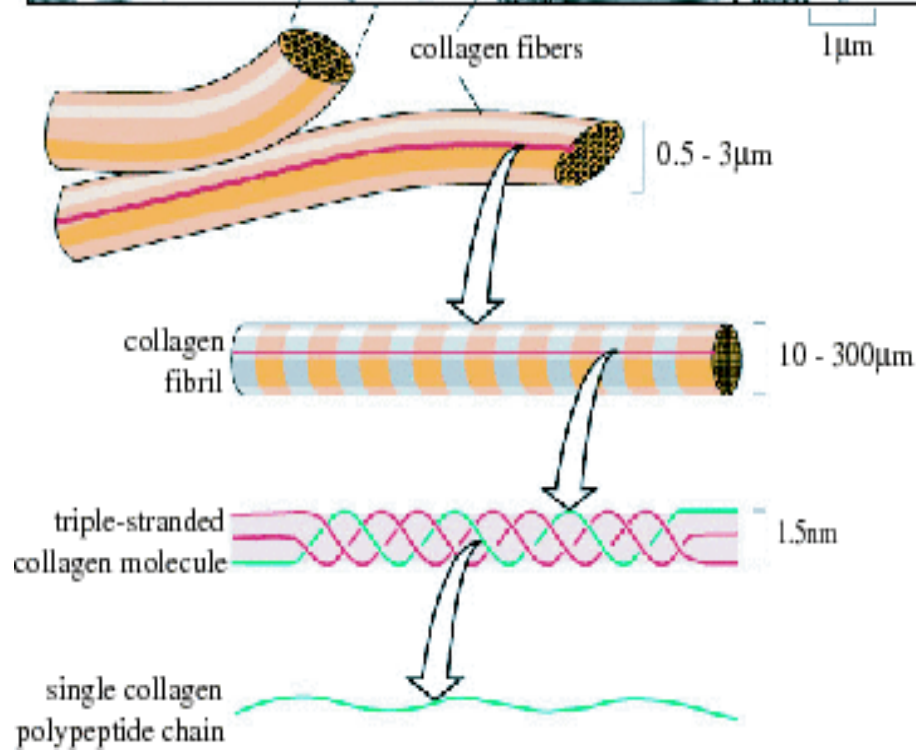
Mast cells release histamines when the allergen is encountered



Mezibuněčná hmota



- Fibrilární složka
 - Kolagenní vlákna
 - Elastická
 - Retikulární

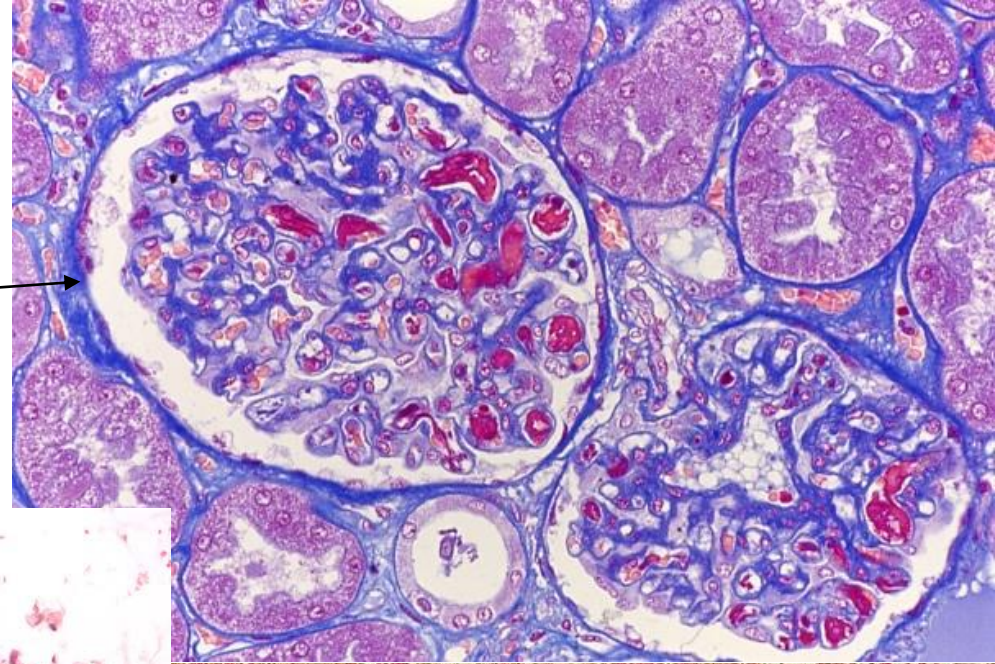


- Interfibrilární složka – základní hmota amorfnní
 - Glykosaminoglykany
 - Proteoglykany
 - Glykoproteiny

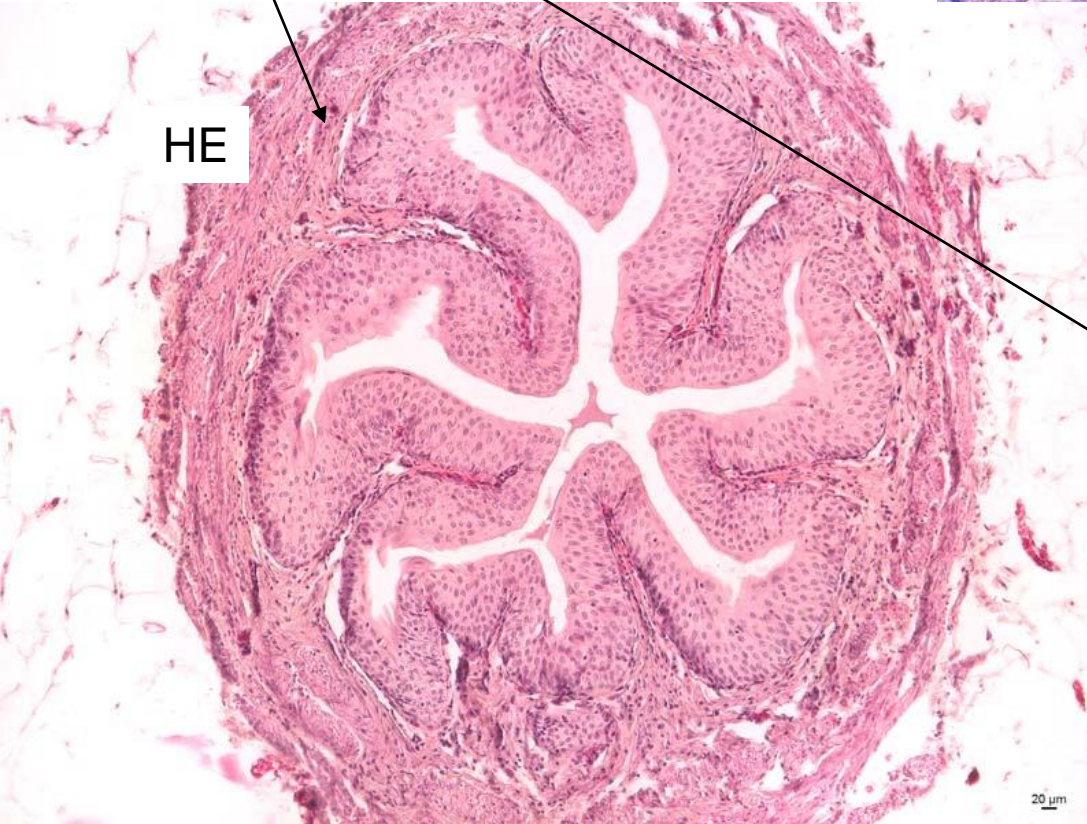
kolagenní vlákna

ve světelném
mikroskopu

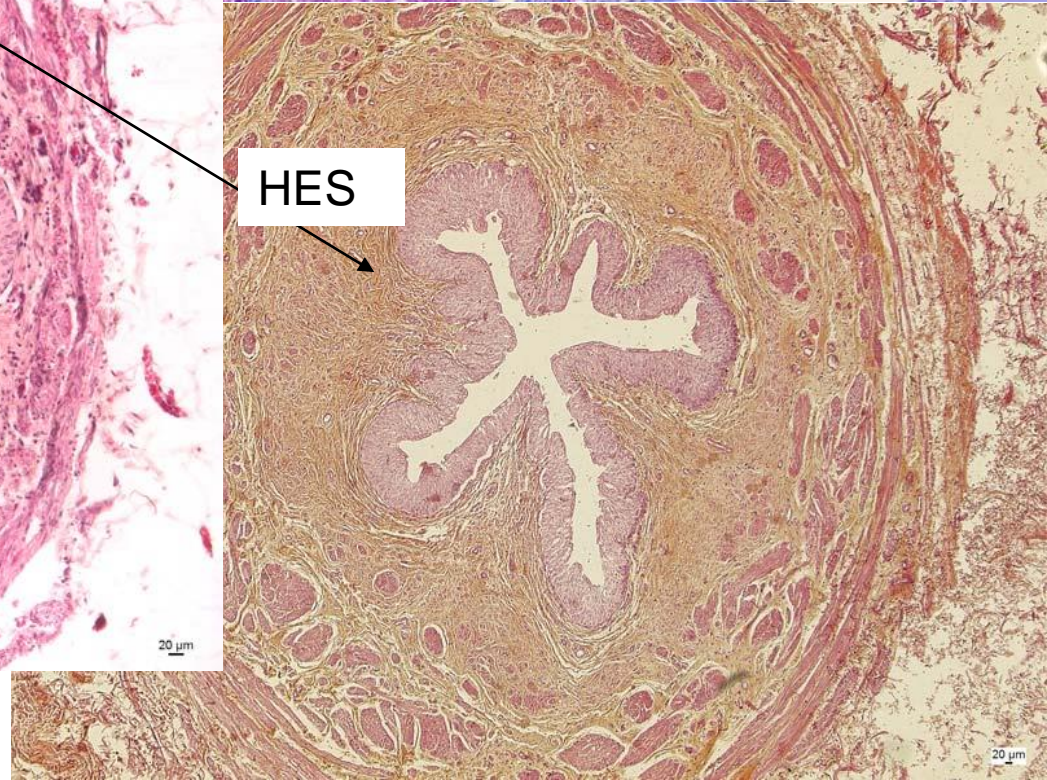
AZAN



HE



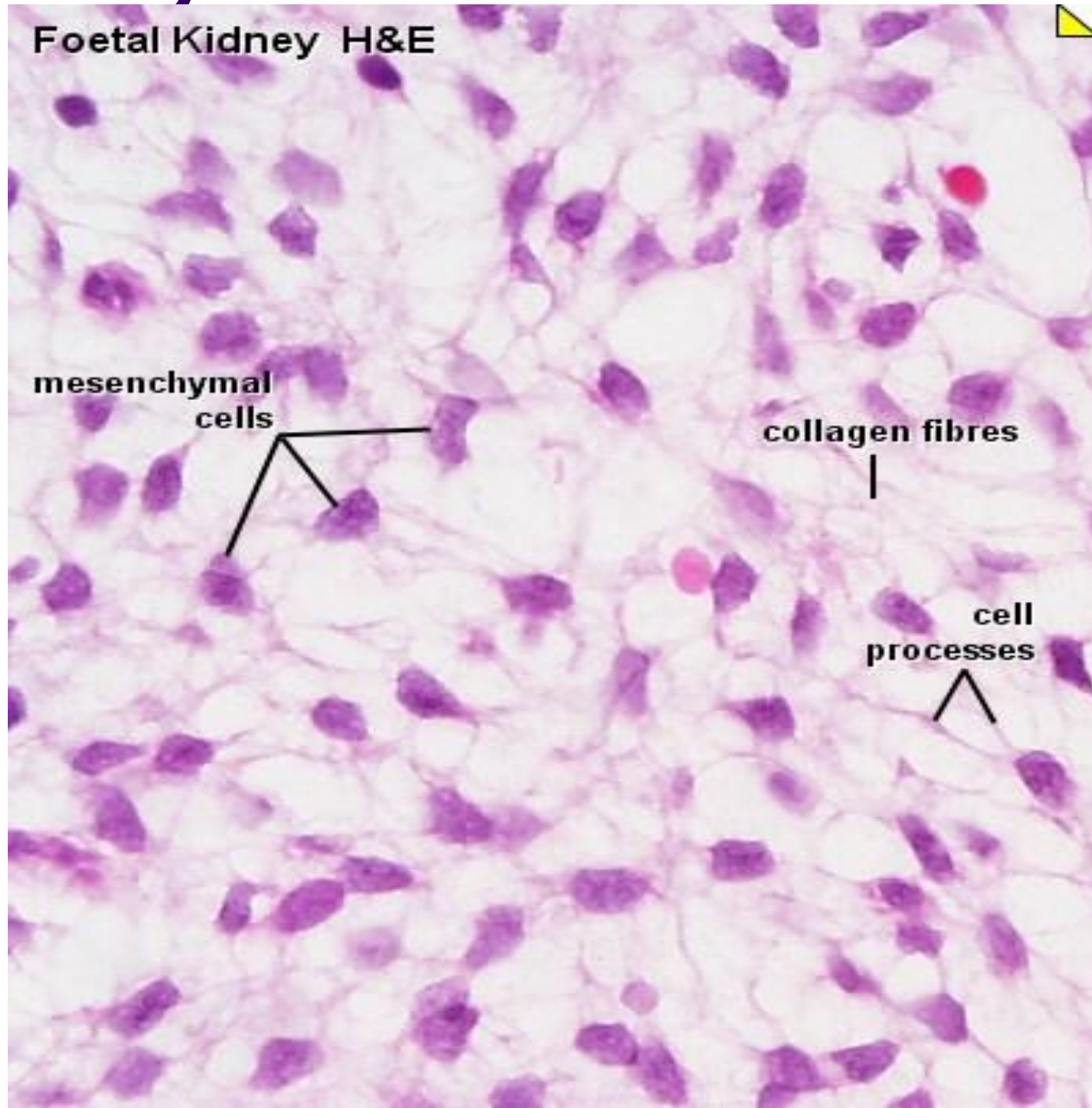
HES



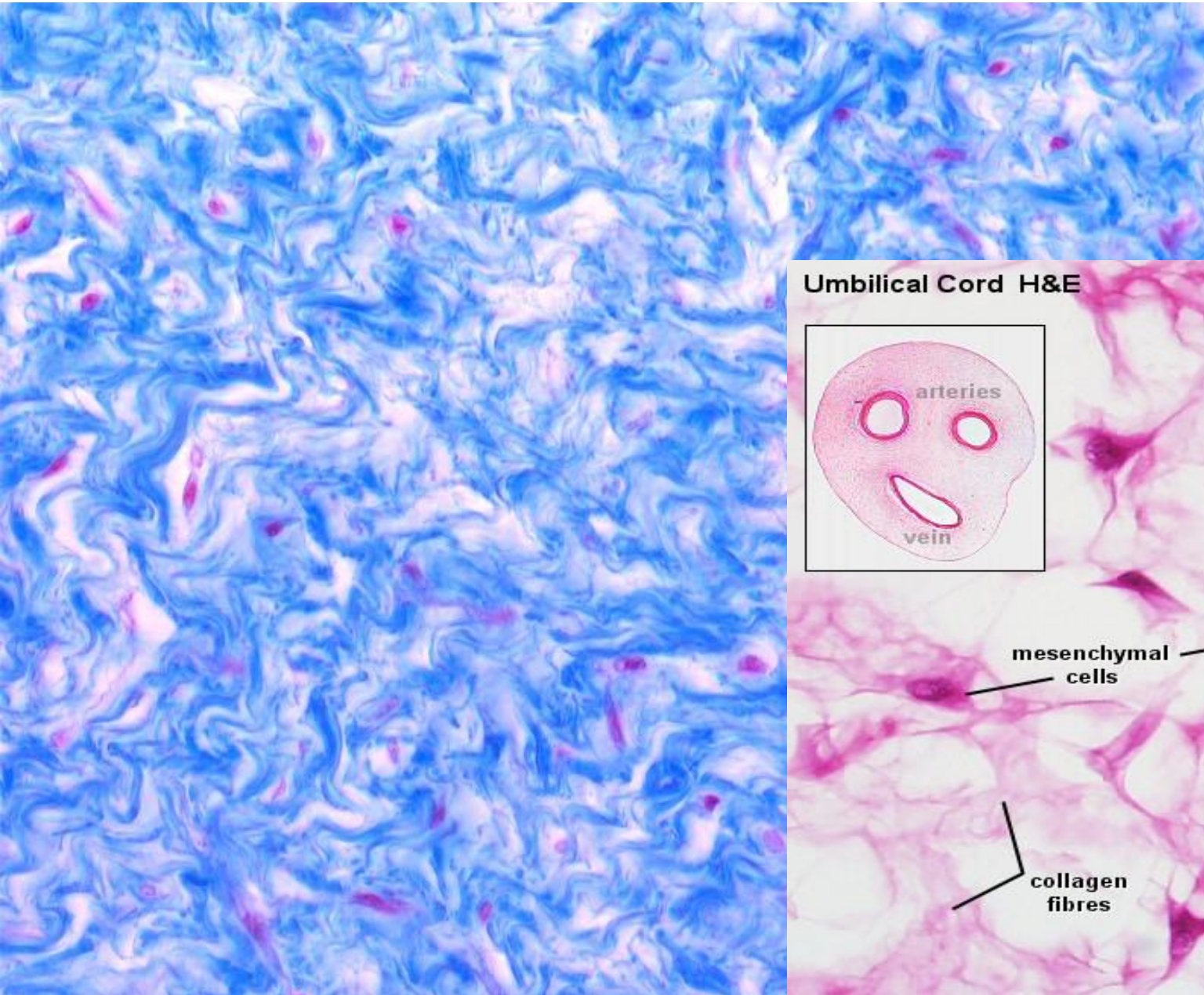
Typy vaziva

- Mesenchym
- Rosolovité
- Kolagenní vazivo – řídké
- Kolagenní vazivo – husté
 - neuspořádané
 - uspořádané
- Elastické
- Retikulární
- Tuková tkáň

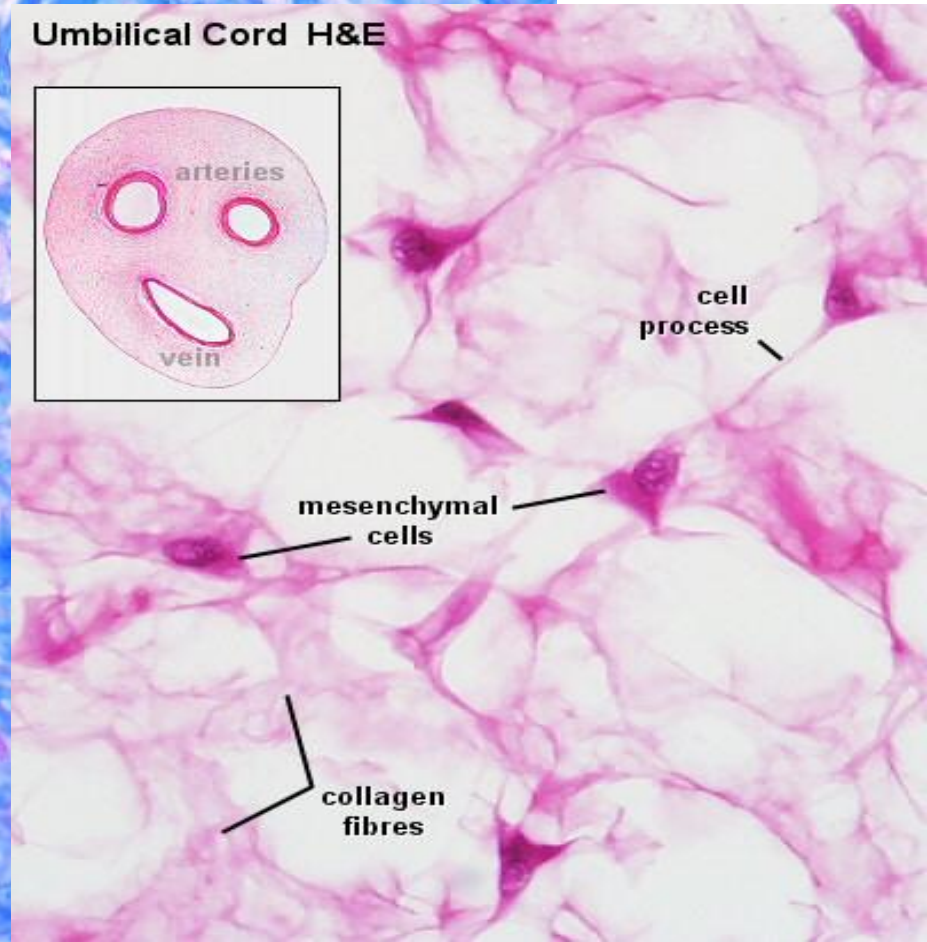
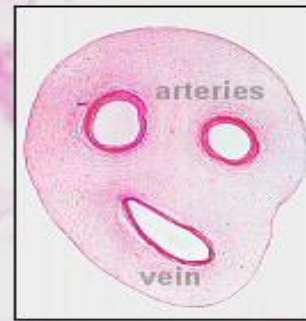
Mesenchym



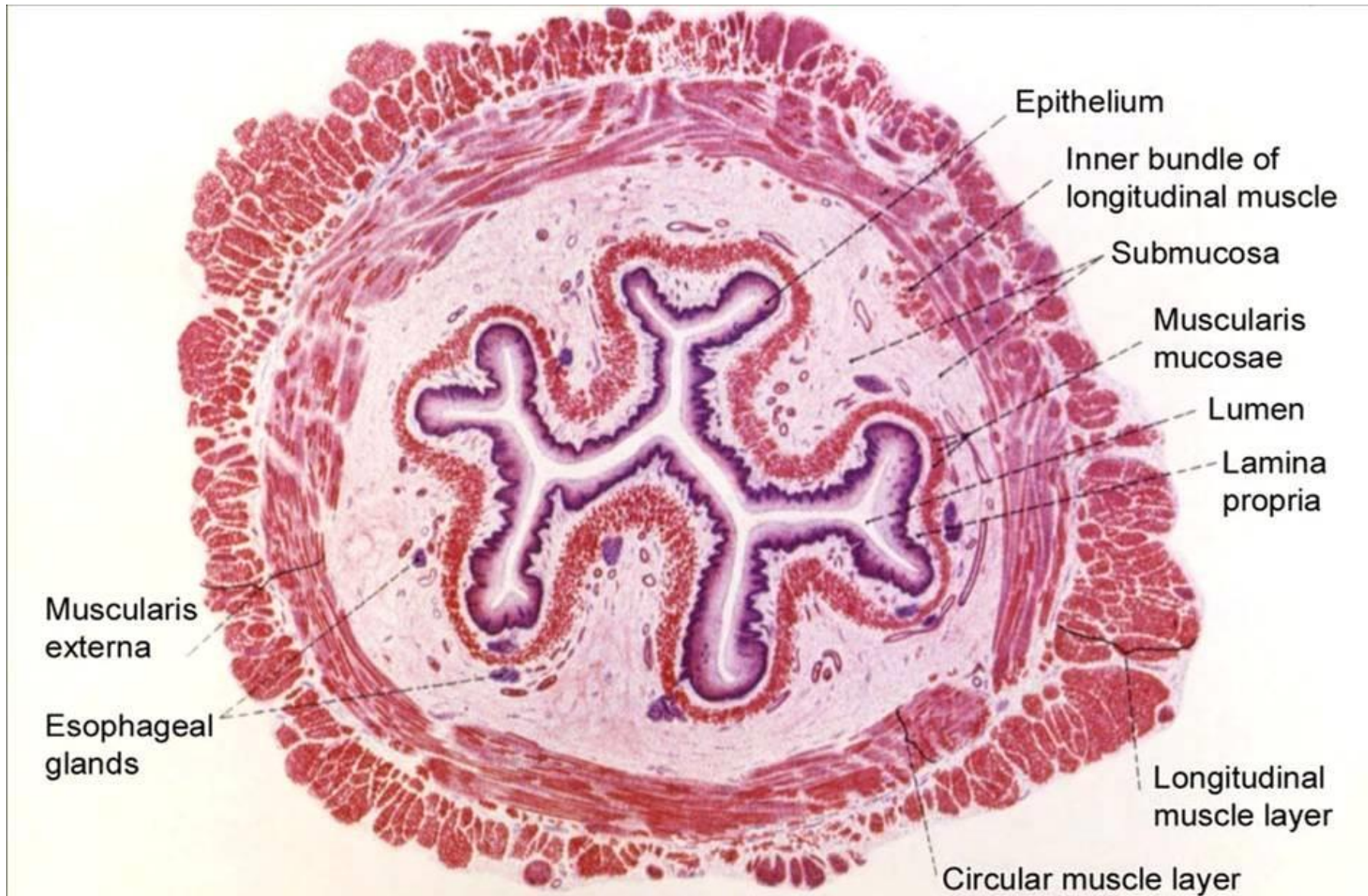
Rosolovité vazivo



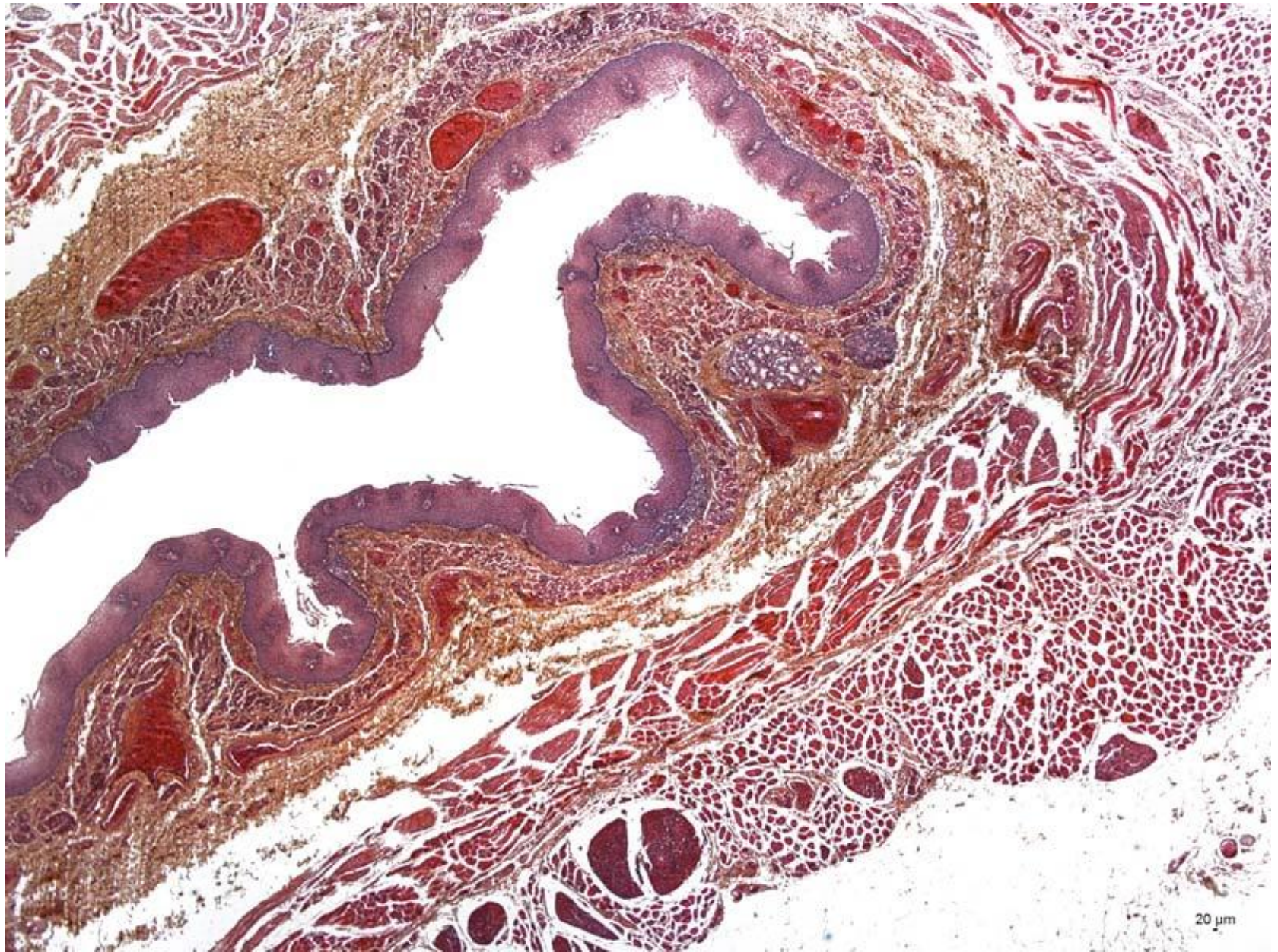
Umbilical Cord H&E



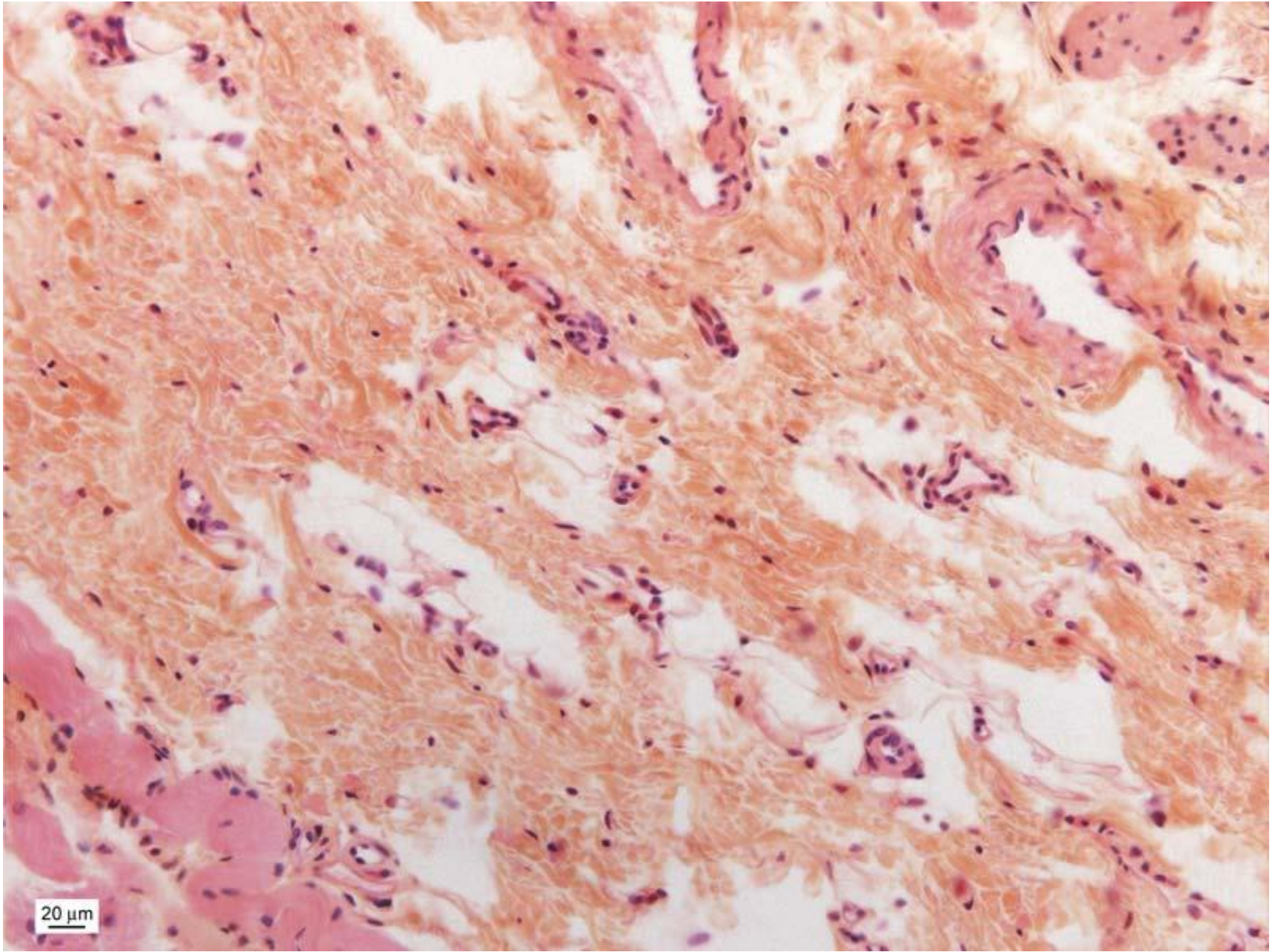
Kolagenní vazivo – řídké (jícen)



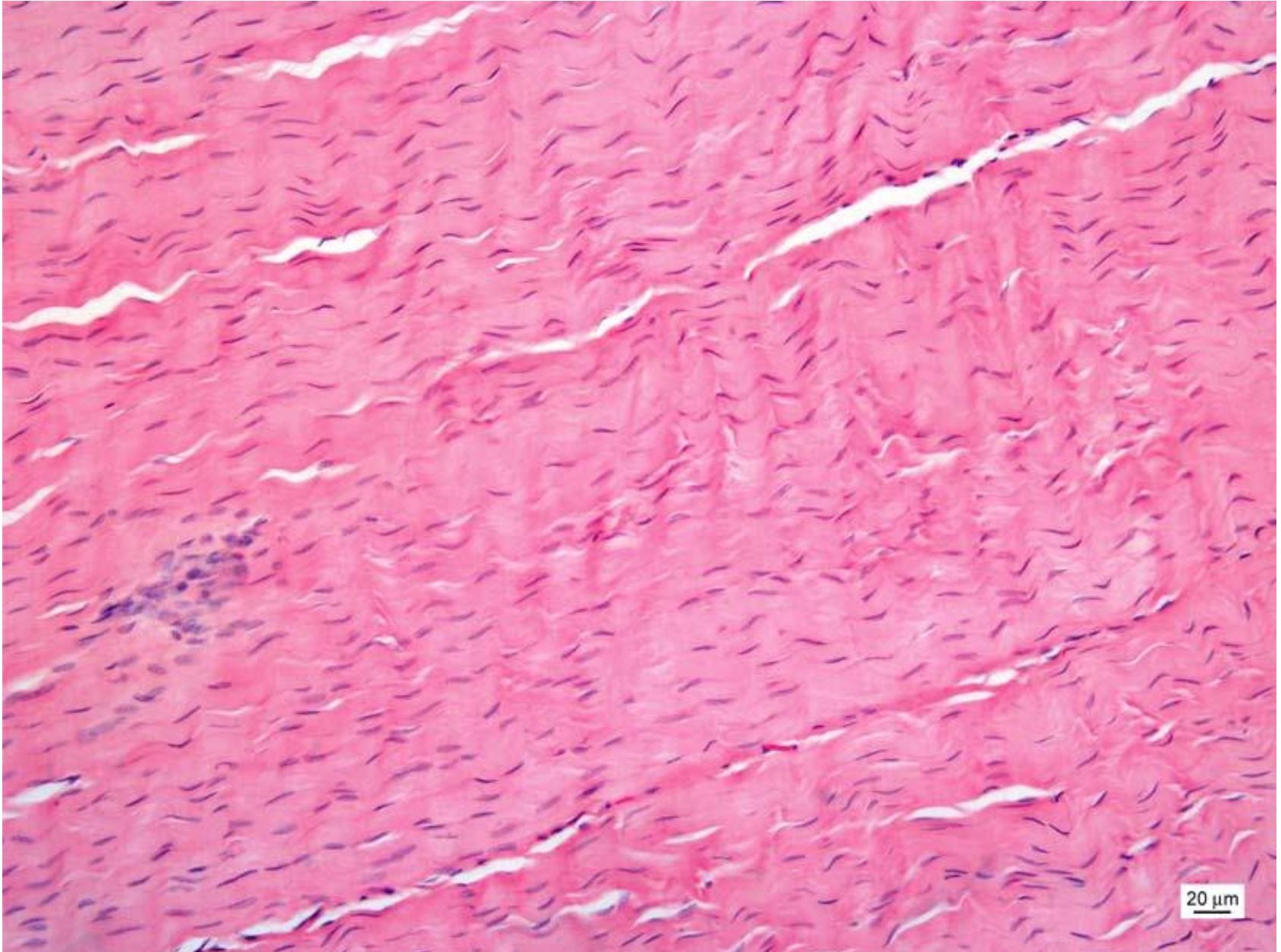
Kolagenní vazivo - řídké



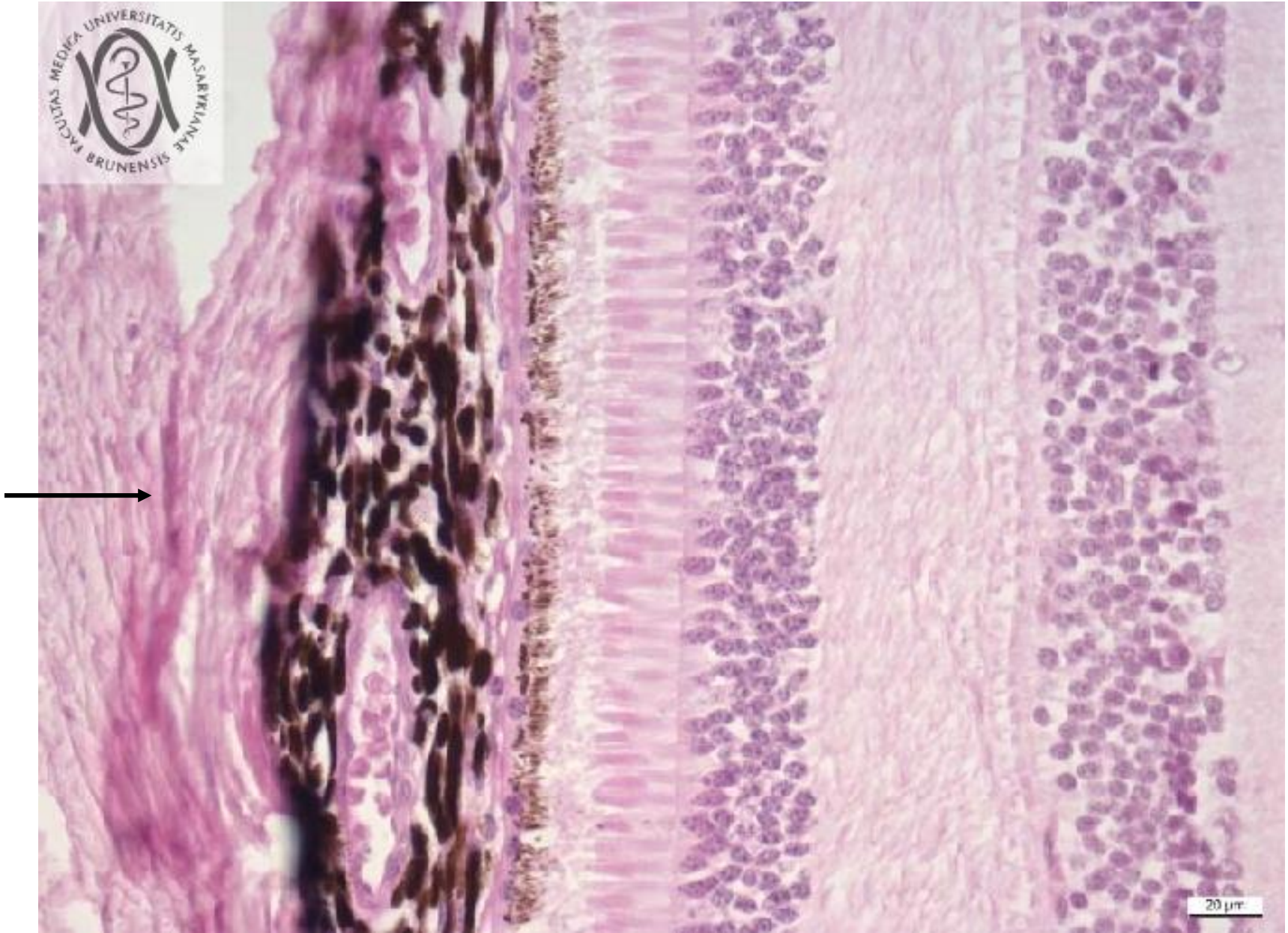
Kolagenní vazivo - řídké



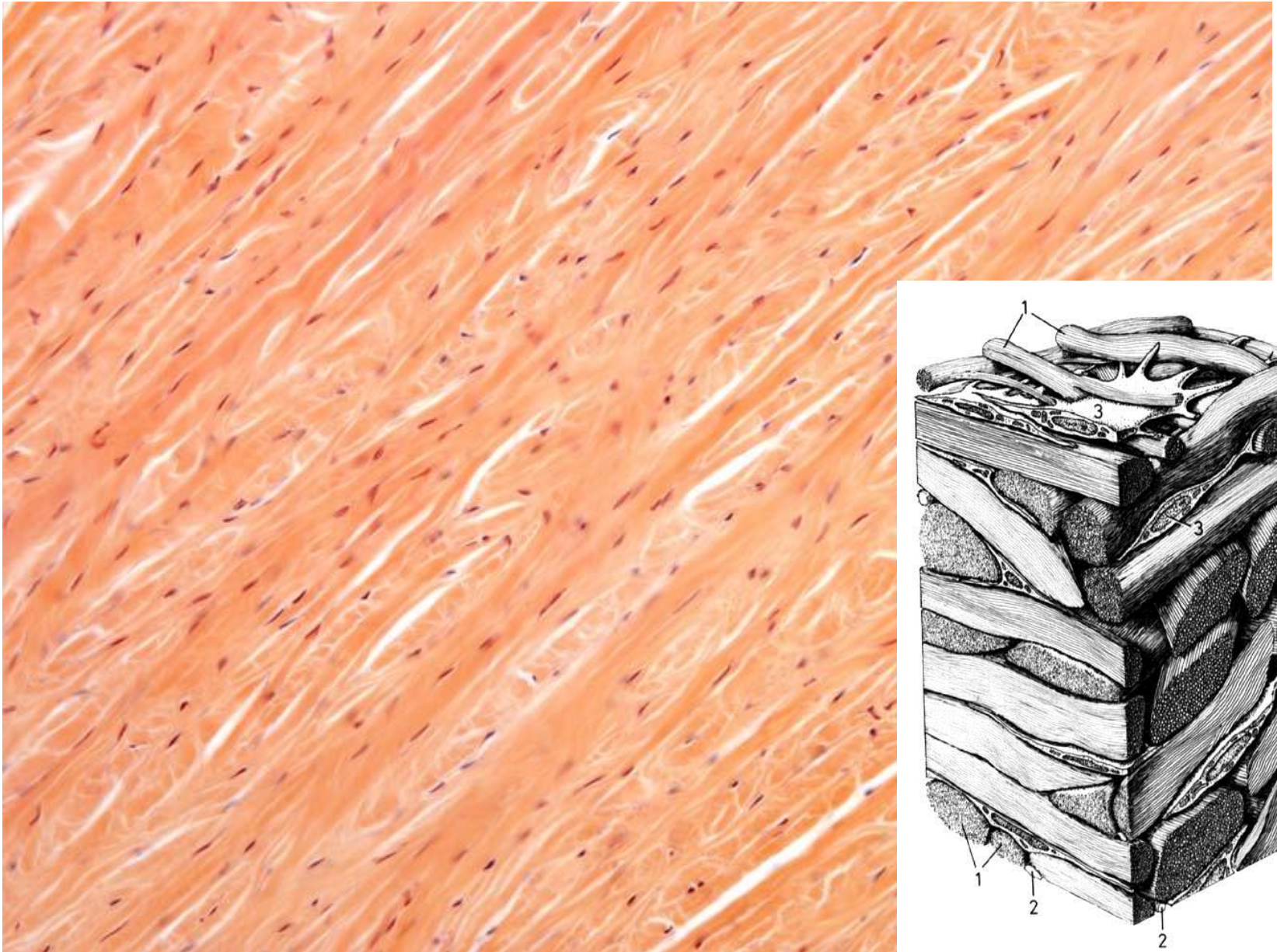
Husté kolagenní vazivo - uspořádané



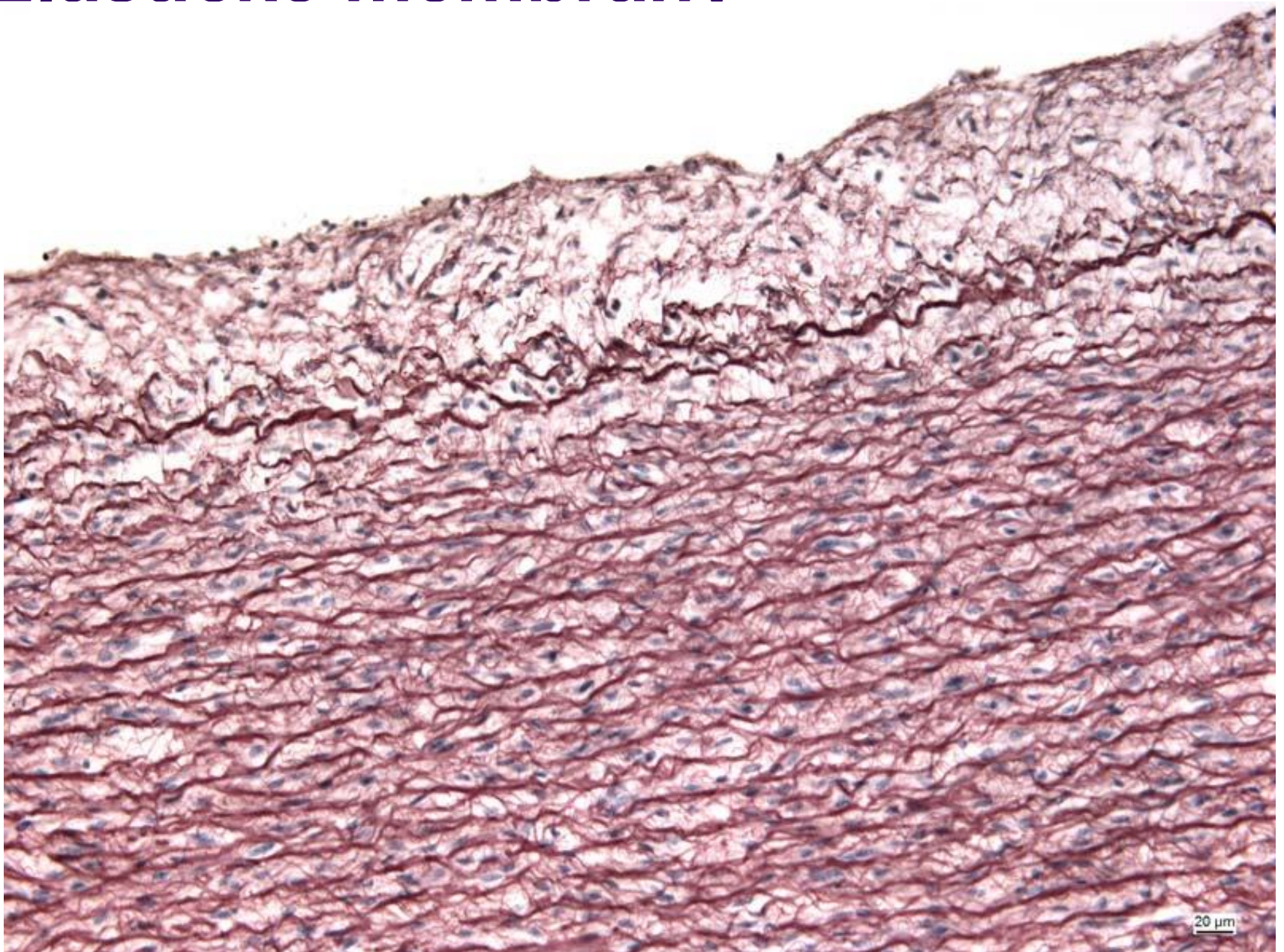
Husté kolagenní vazivo - neuspořádané



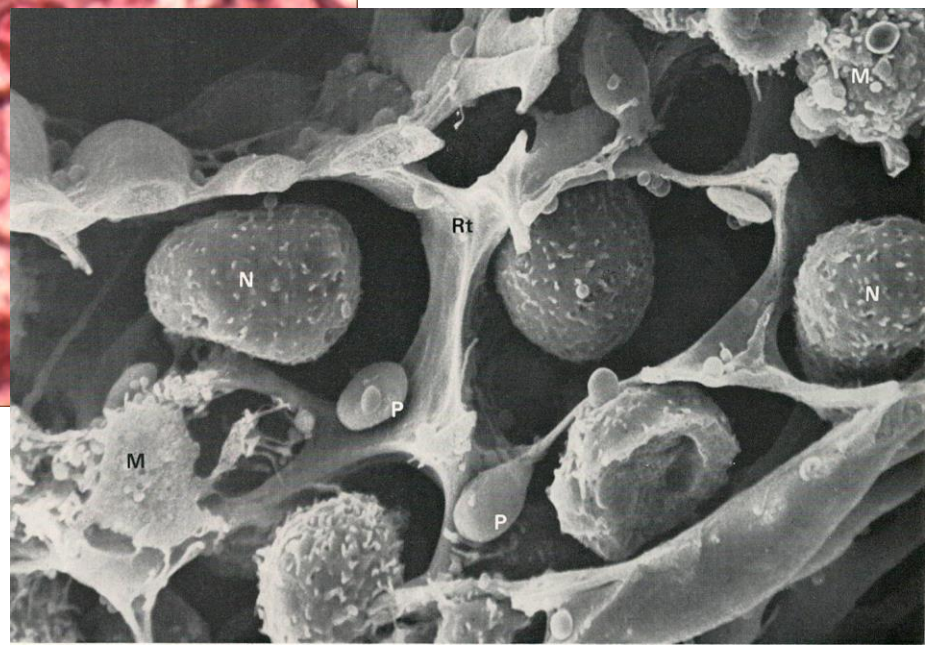
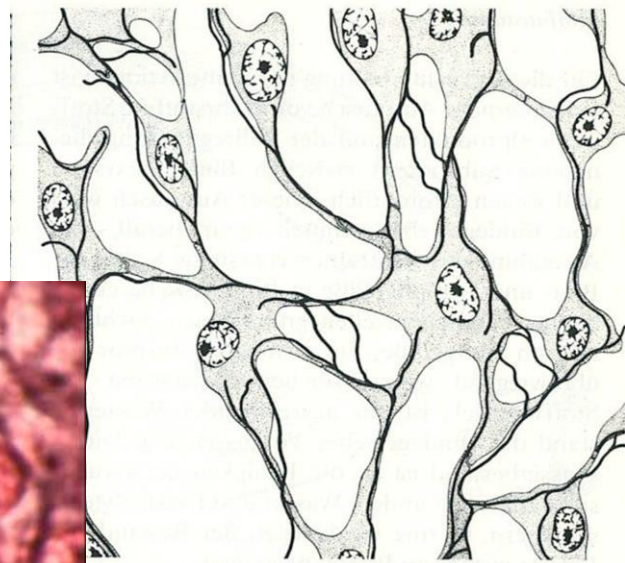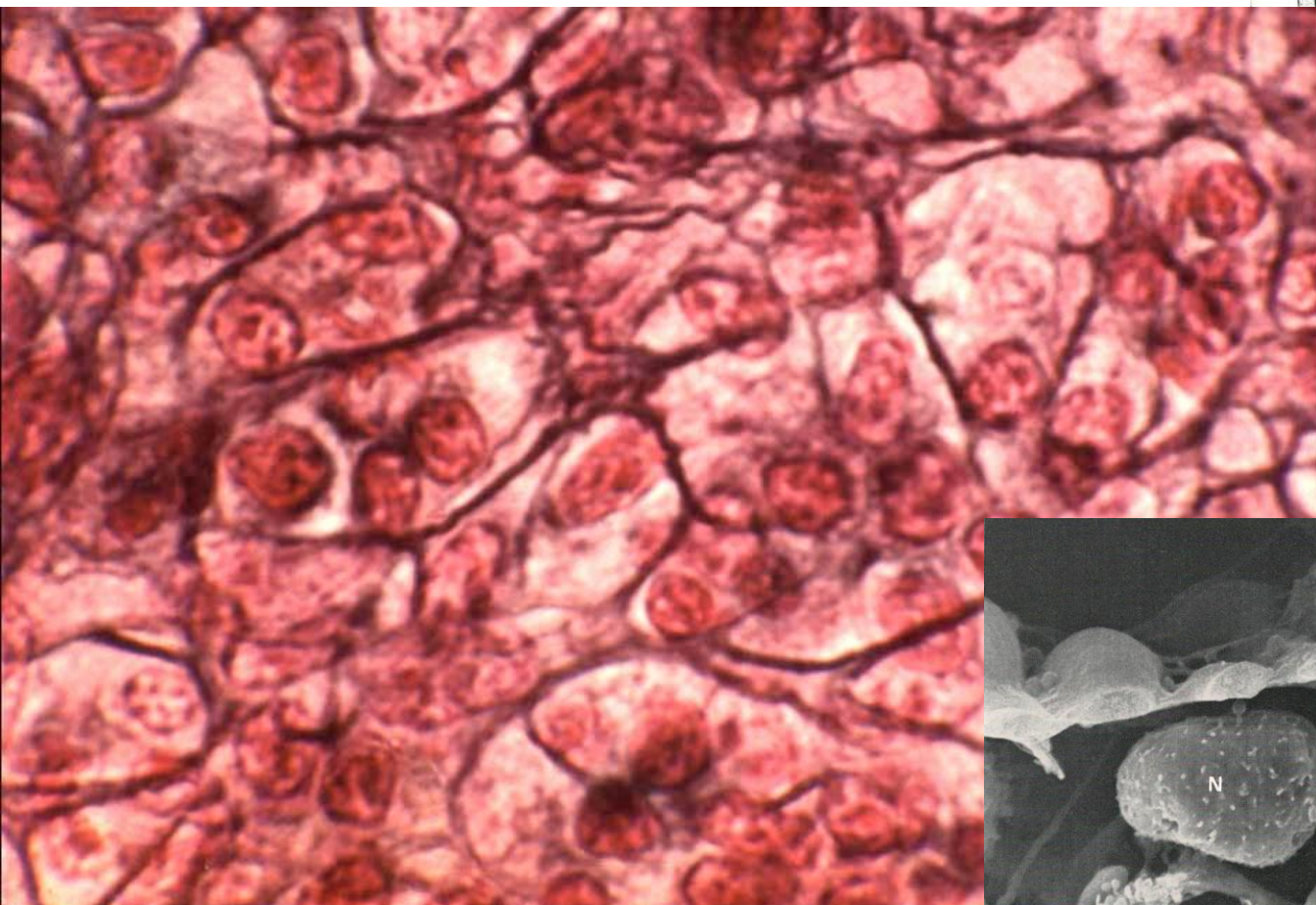
Husté kolagenní vazivo - neuspořádané



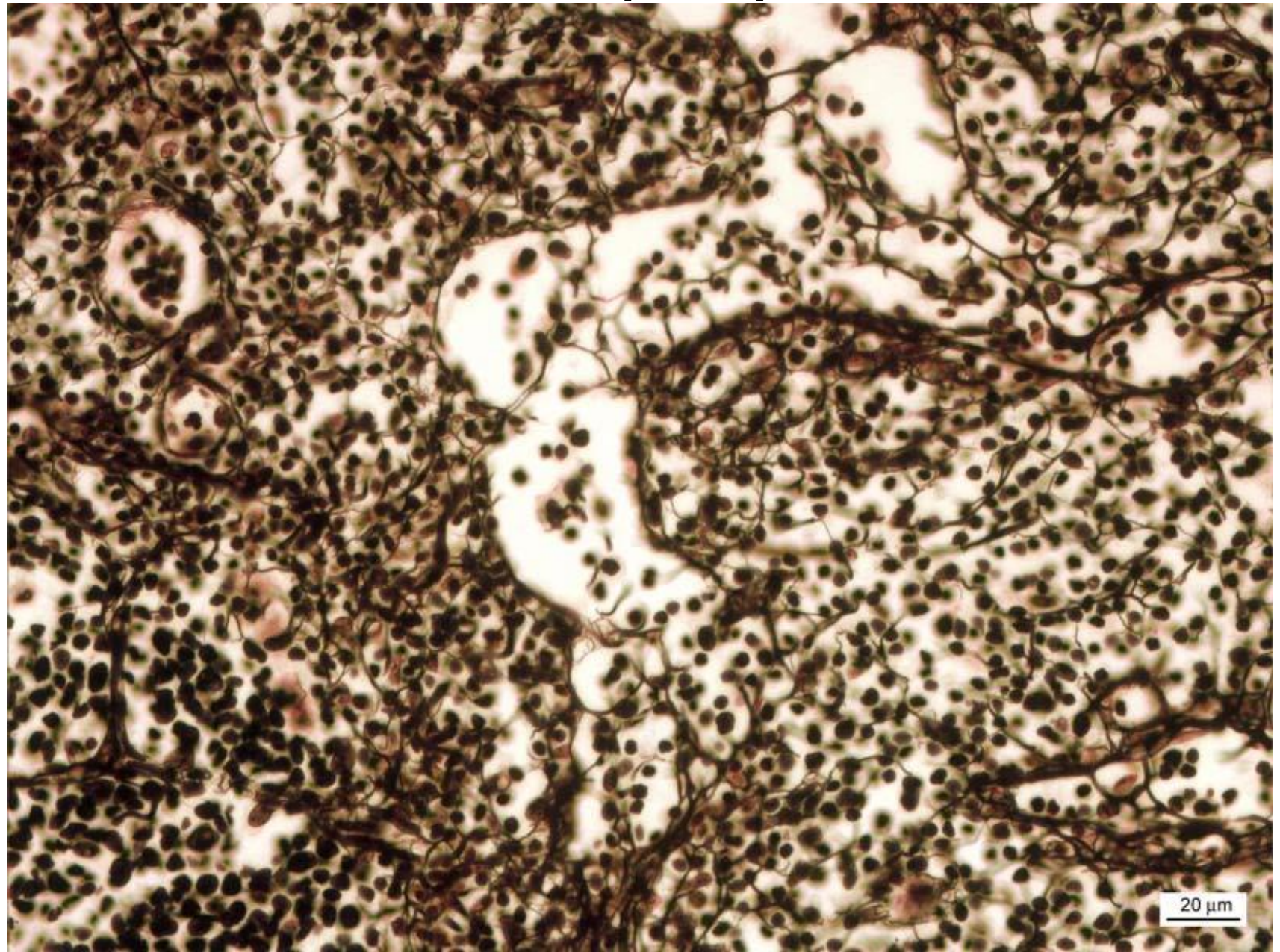
Elastické membrány



Retikulární vazivo



Retikulární vazivo (lien)



Tukové vazivo

