

**Institute for Microbiology, Medical Faculty of Masaryk University  
and St. Anna Faculty Hospital in Brno**

# **Agents of wound infections**

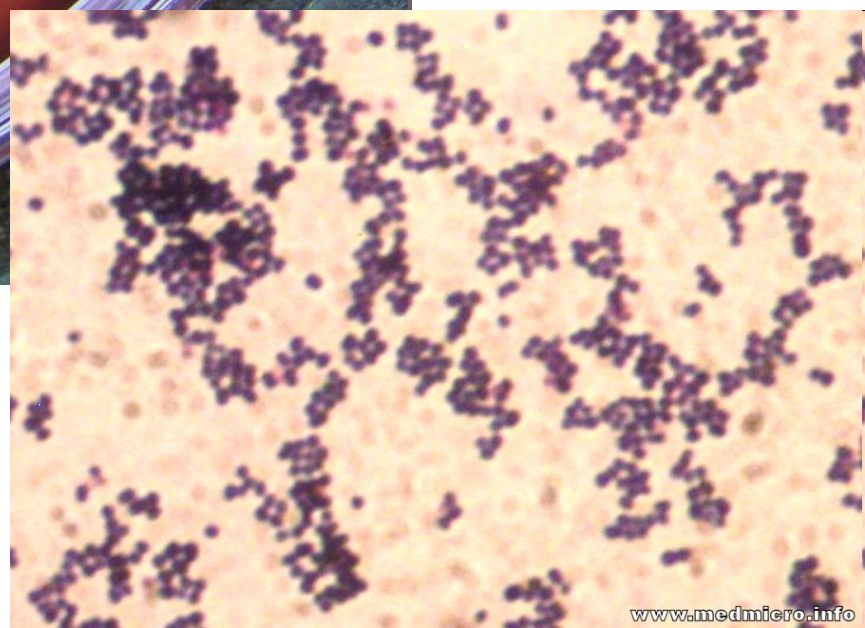
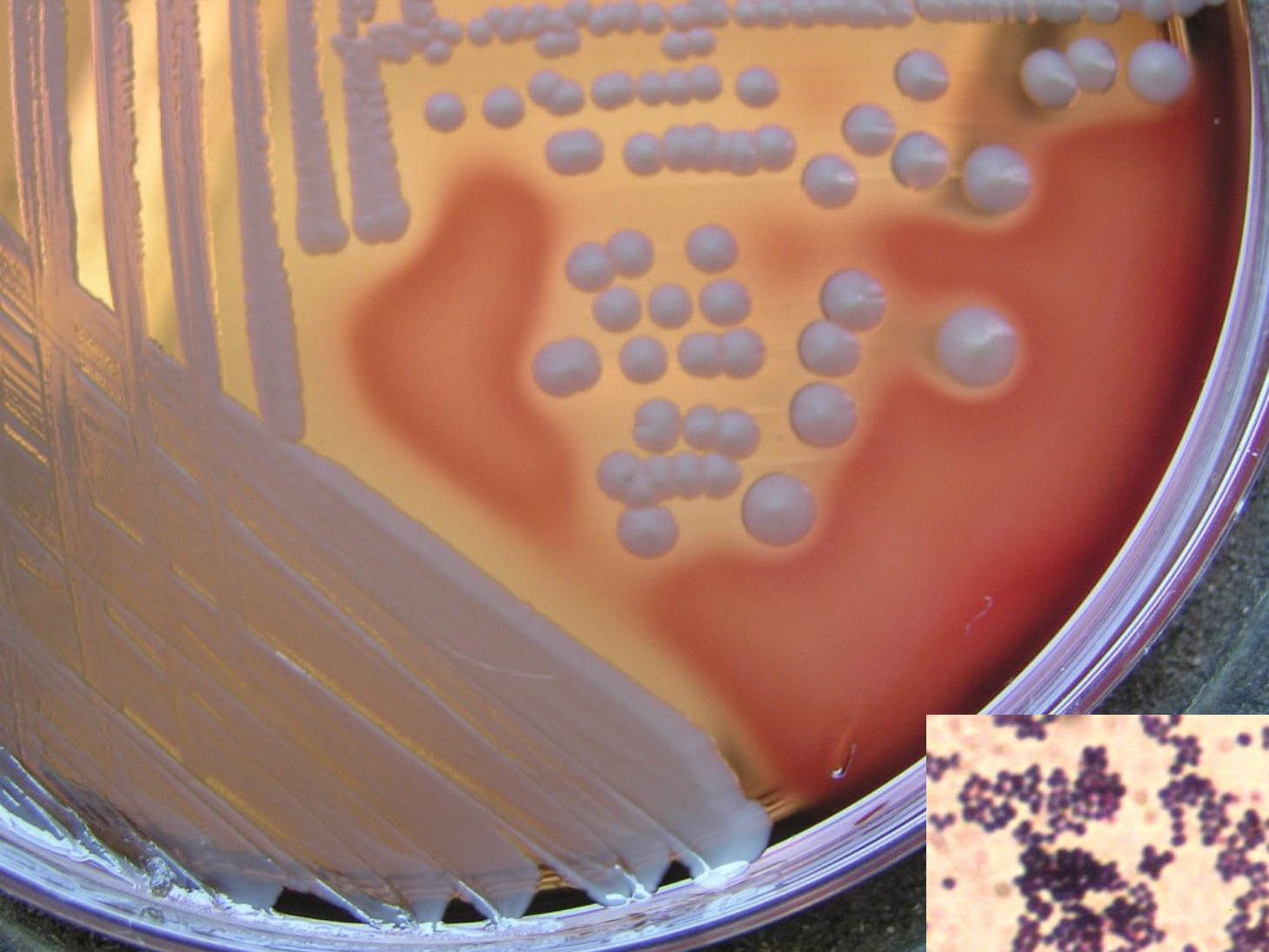
# Types of wound

- common **superficial** injuries
- severe **contused** wounds
- sustained **in water**
- sustained in the **tropics**
- **surgical** wounds
- **burns**
- **bites** inflicted by **man/animal**

# Common superficial injuries

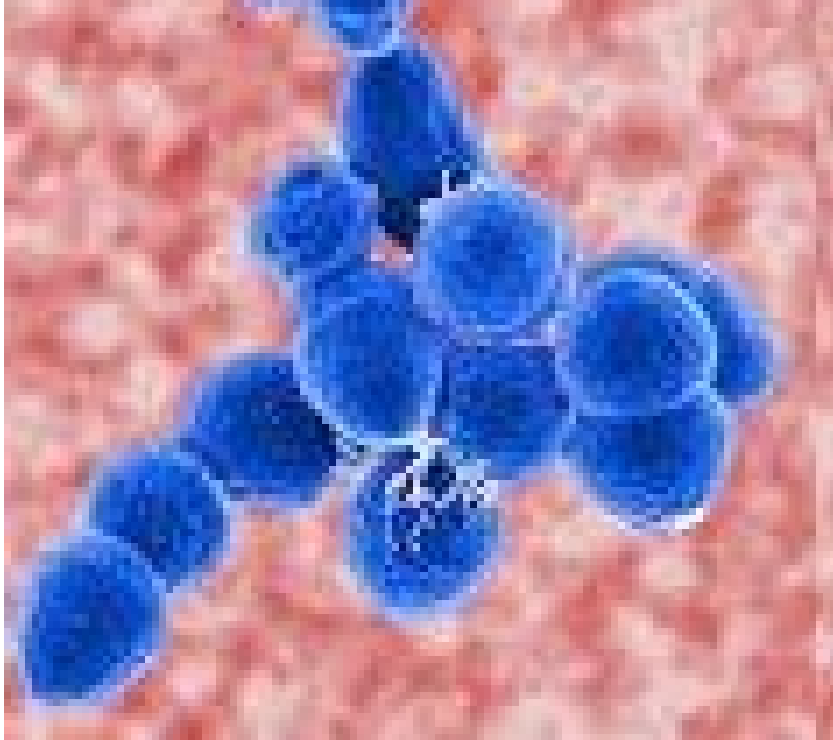
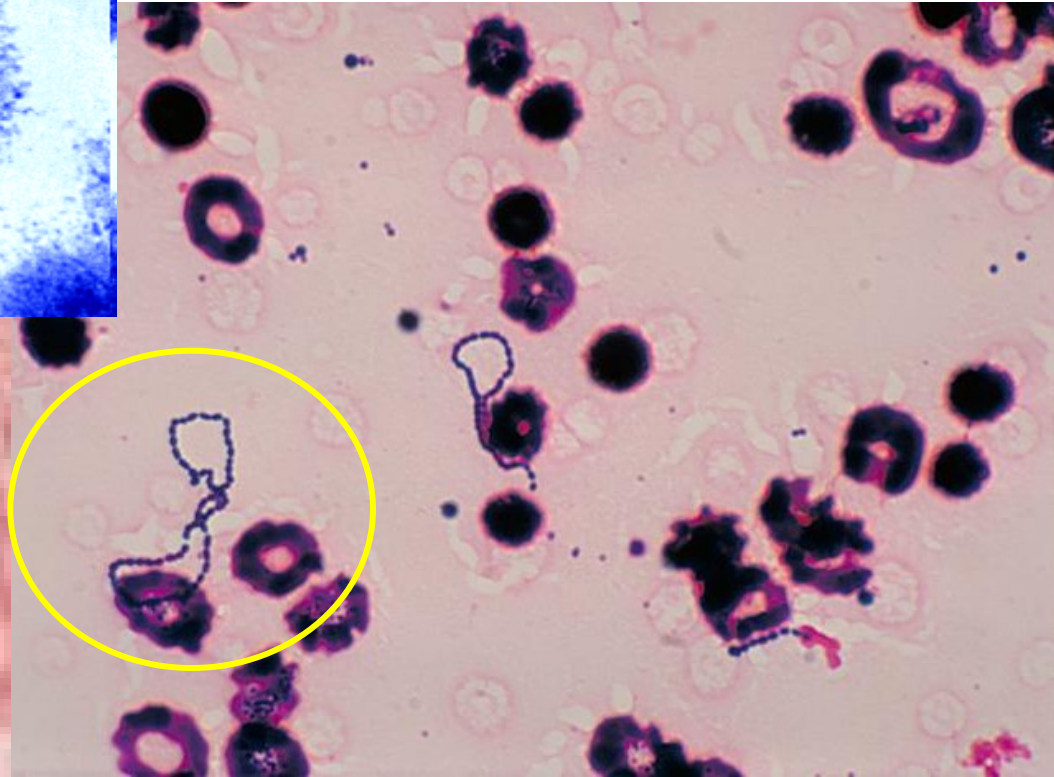
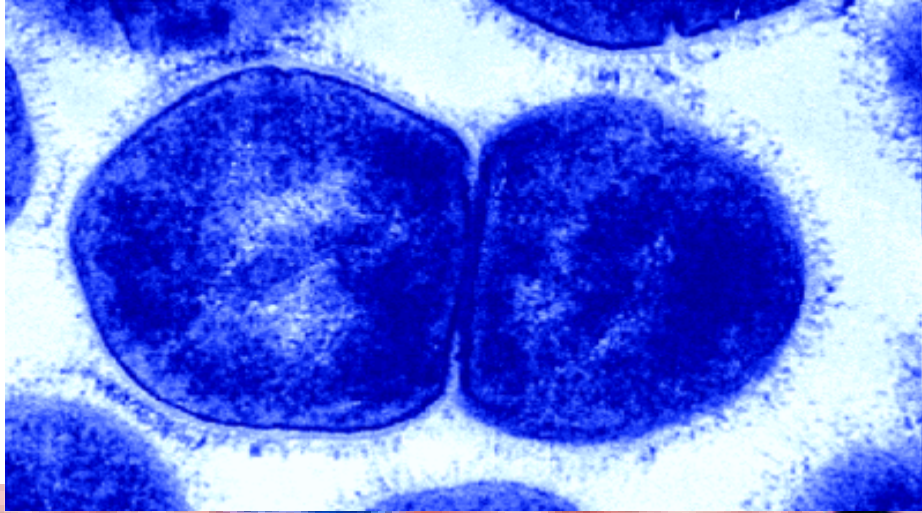
- *Staphylococcus aureus*
- *Streptococcus pyogenes*
- beta-hemolytic streptococci of other groups (above all G, F, C)

**! Attention in the case of the foreign body in the wound (splinter, thorn) and in deeper stab wounds (fork soiled by horse manure): *Clostridium tetani***



**STAPHYLOCOCCI**

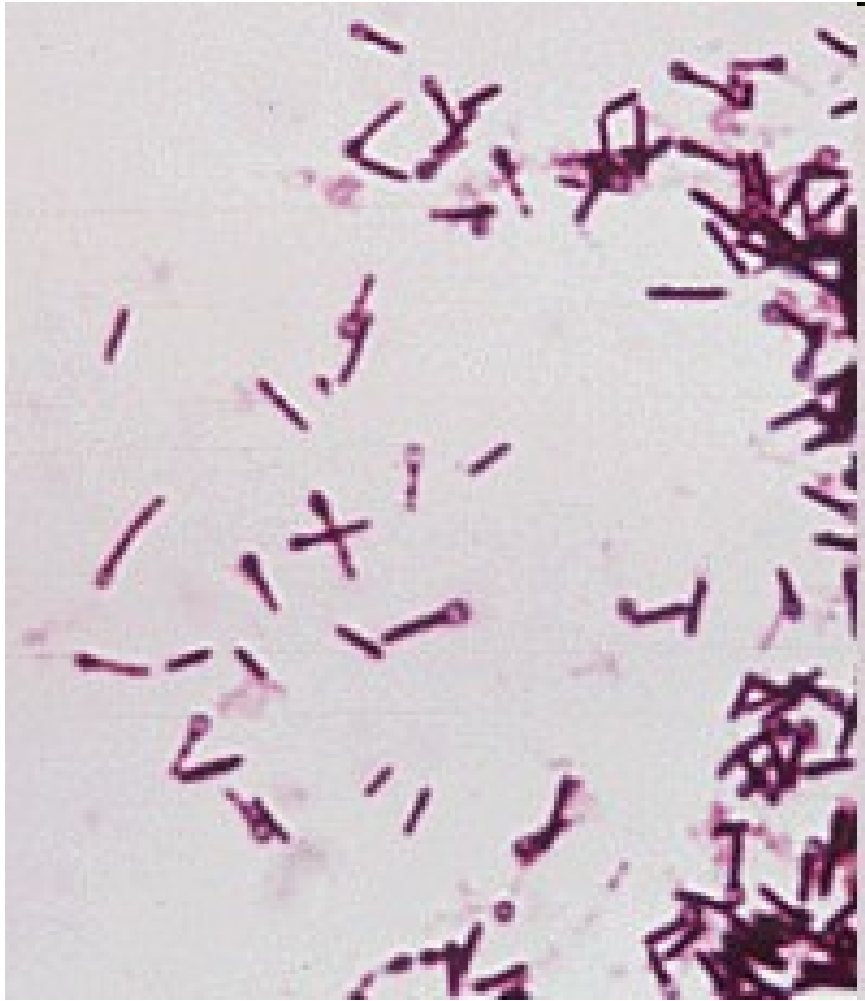# STREPTOCOCCI



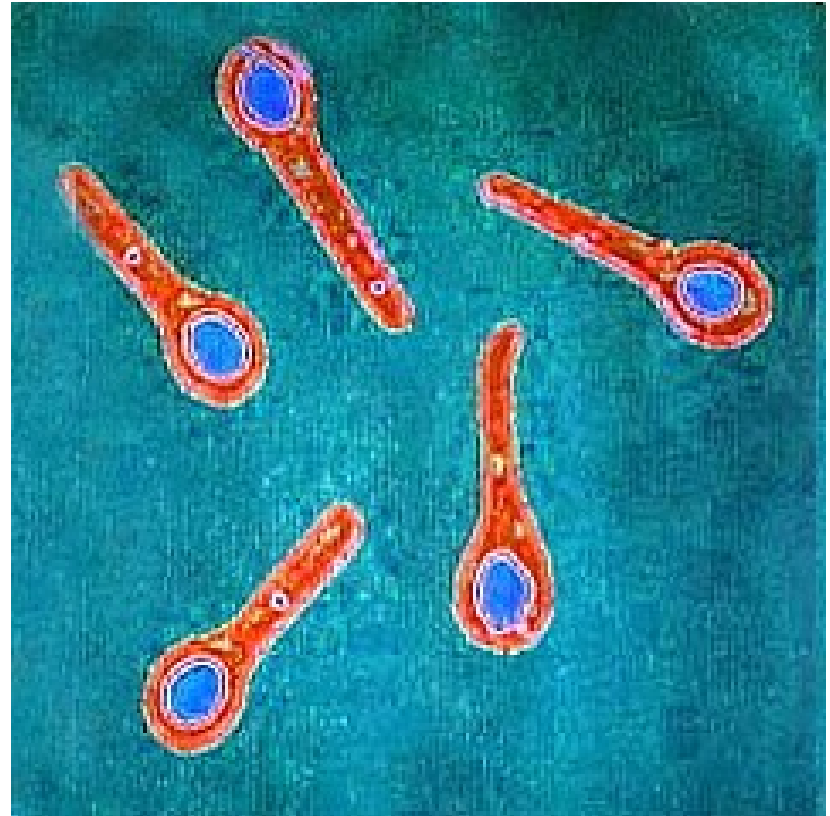
Left: [microbewiki.kenyon.edu](http://microbewiki.kenyon.edu).

Below: <http://upload.wikimedia.org>





## CLOSTRIDIUM TETANI



[microbiologybytes.wordpress.com/](http://microbiologybytes.wordpress.com/)

***Sir Charles Bell's portrait of a soldier dying of tetanus.***

The characteristic **rigidity of the body** is referred to as **opisthotonus** and **risus sardonicus**.

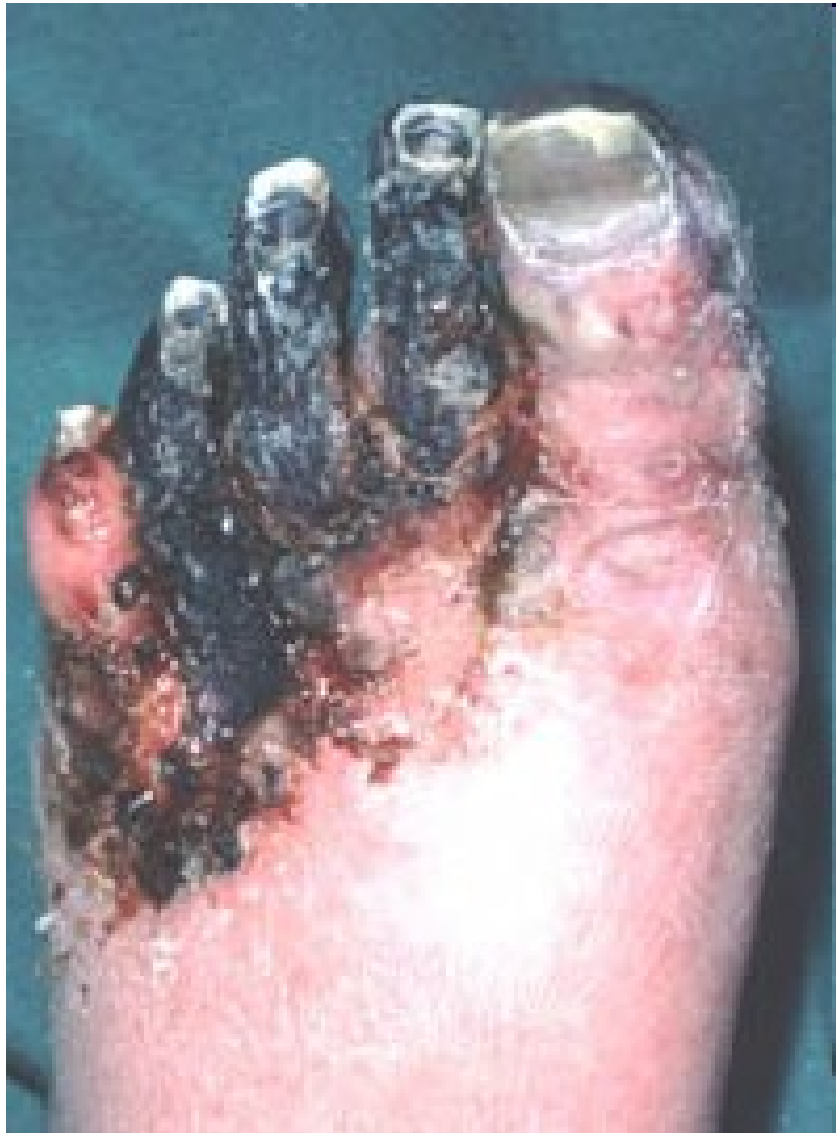(Original in the Royal College of Surgeons of Edinburgh, Scotland)



# Severe contused wounds

- **Agents of clostridial myonecrosis**  
(*Clostridium perfringens*, *C. septicum*,  
*C. novyi*, *C. histolyticum*)  
clostridial myonecrosis = anaerobic  
traumatosis = **gas gangrene** ~ malignant  
edema
- ***Clostridium tetani***





<http://www.thewoundcarecenter.com>

# Wounds sustained in water

- In fresh water:

*Pseudomonas aeruginosa*

*Aeromonas hydrophila*

other pseudomonads and aeromonads

- In salt water:

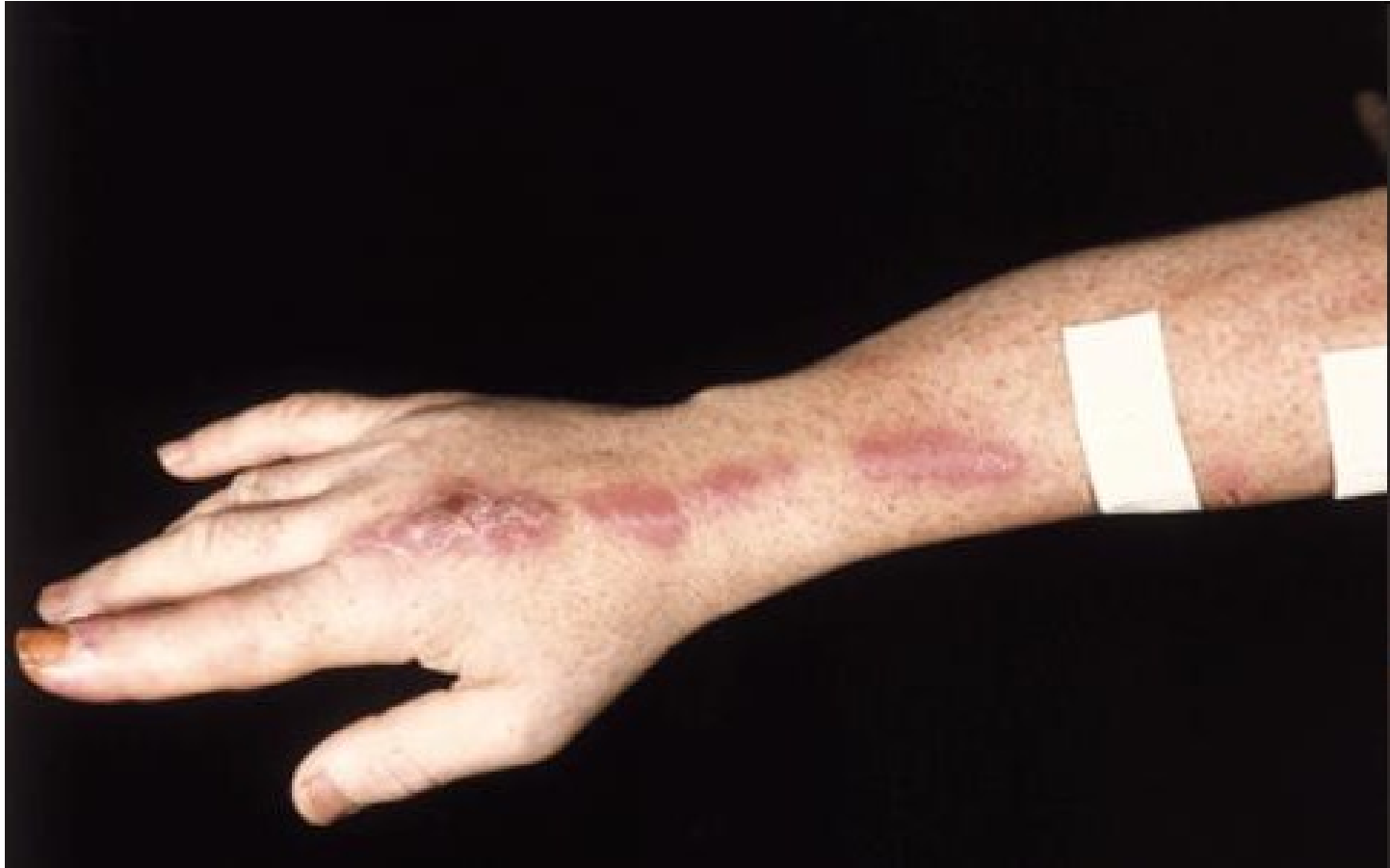*Vibrio parahaemolyticus, V. vulnificus*

*Mycobacterium marinum* (also in fresh-water swimming pools, fish tanks etc.)

# Injuries sustained in the tropics

## Mainly on feet

- **soil nocardiae**  
(*Dermatophilus congolensis*, *Rhodococcus equi*)
- **atypical mycobacteria**  
(*Mycobacterium ulcerans*, *Mycobacterium haemophilum*)
- **micromycetes**  
(*Sporothrix schenckii*, *Paracoccidioides brasiliensis*)



*Sporothrix schenckii* (a dimorphic fungus that is a yeast in the body) - usually acquired by implantation of spores at the site of minor trauma in an extremity.

Note the erythematous papule on the index finger just proximal to the nail (site of inoculation) and the linear pattern of erythematous nodules (dermal and subcutaneous) extending proximally along lymphatic vessels.

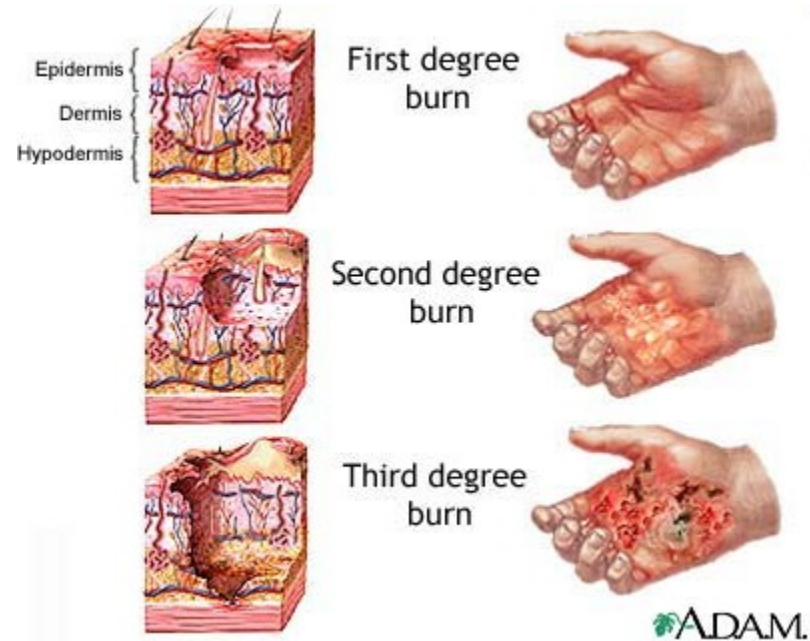
# Surgical wounds

- ***Staphylococcus aureus***
- **coagulase-negative staphylococci**  
(mainly *Staph. epidermidis*)
- **Enterobacteriaceae** (*E. coli*, *P. mirabilis*)
- ***Streptococcus pyogenes***
- **anaerobes**  
(*Peptostreptococcus micros*, *Peptostreptococcus anaerobius*,  
*Bacteroides fragilis*)

# Burns

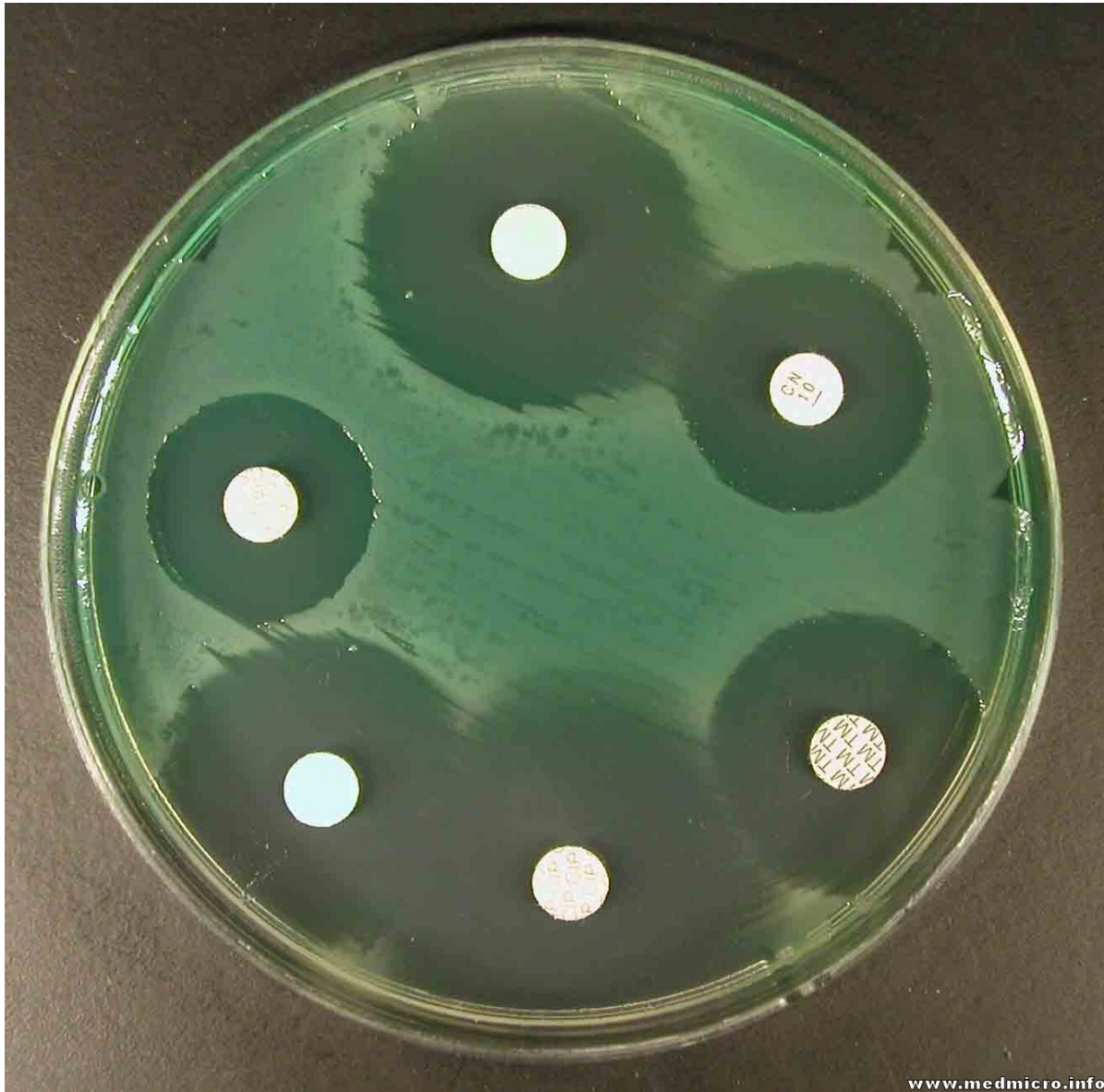**Mostly:**

- *Pseudomonas aeruginosa*
- *Staphylococcus aureus*
- *Streptococcus pyogenes*
- other streptococci
- enterococci
- candidae and aspergilli





# **P. AERUGINOSA**



# Bites inflicted by man

members of oral microflora:

- „oral streptococci“ (*Streptococcus sanguinis*, *S. oralis*, *S. anginosus*)
- anaerobes (*Fusobacterium nucleatum* ssp. *nucleatum*, *Porphyromonas gingivalis*)

*Staphylococcus aureus*

# Animal bites

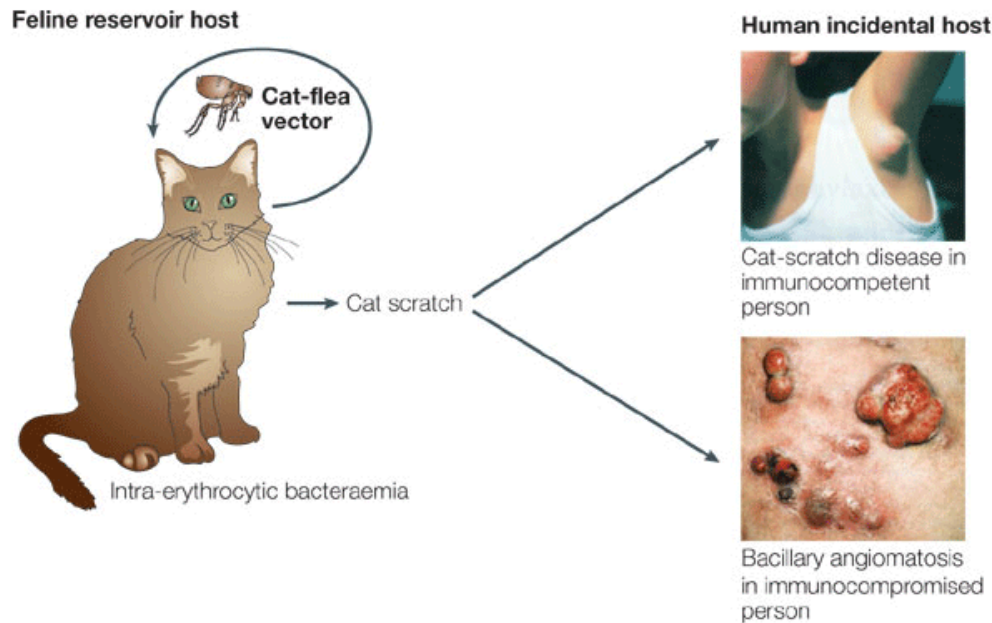
- *Pasteurella multocida* (cats, dogs)
- *Staphylococcus aureus* (any animal)
- *Capnocytophaga canimorsus* (dogs)
- *Streptobacillus moniliformis* (rats)
- *Spirillum minus*  
(mice, rats, cats, dogs)



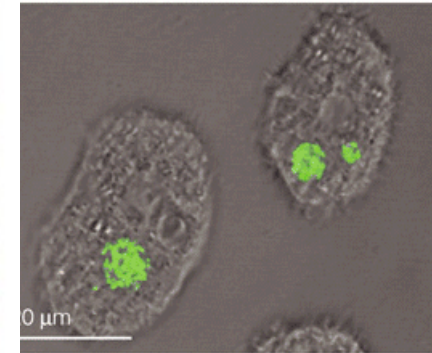
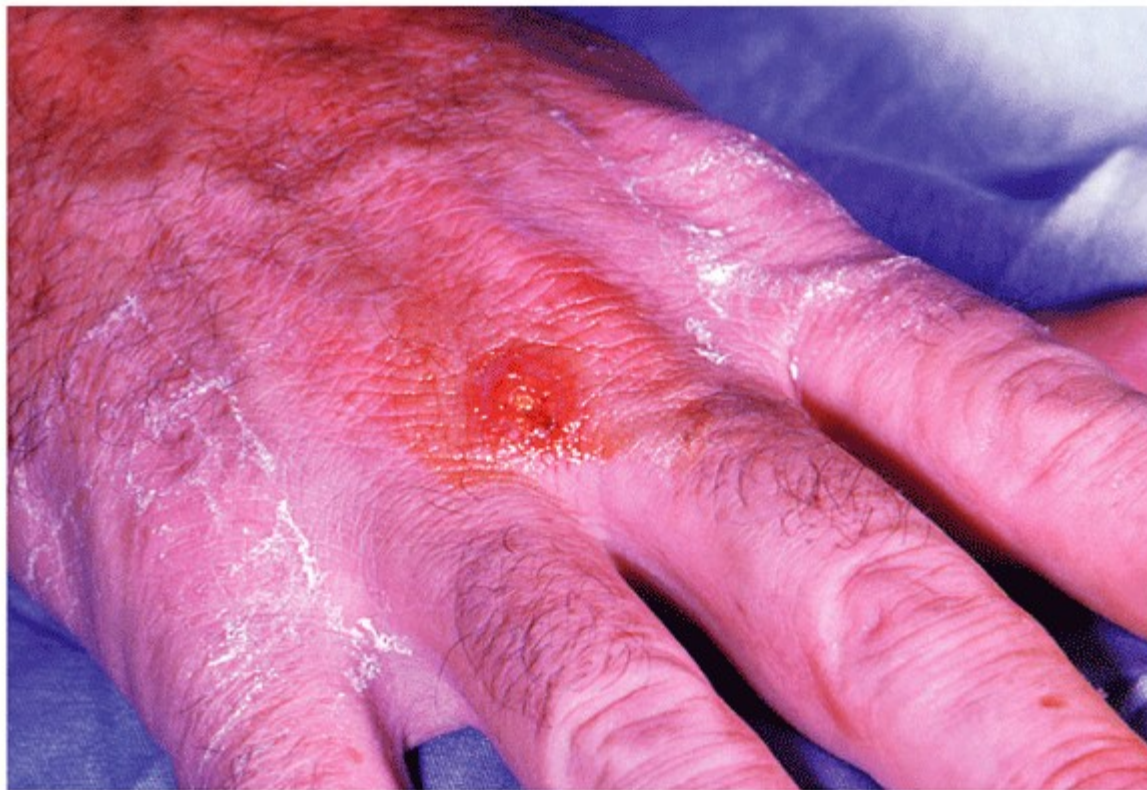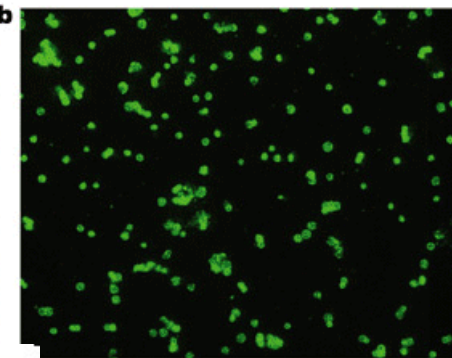
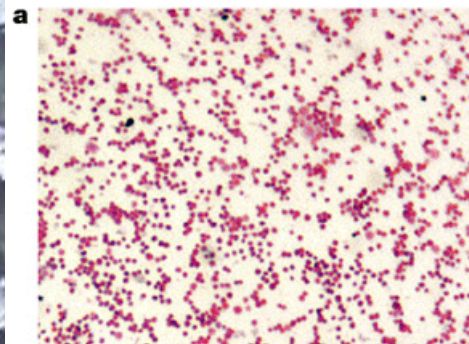
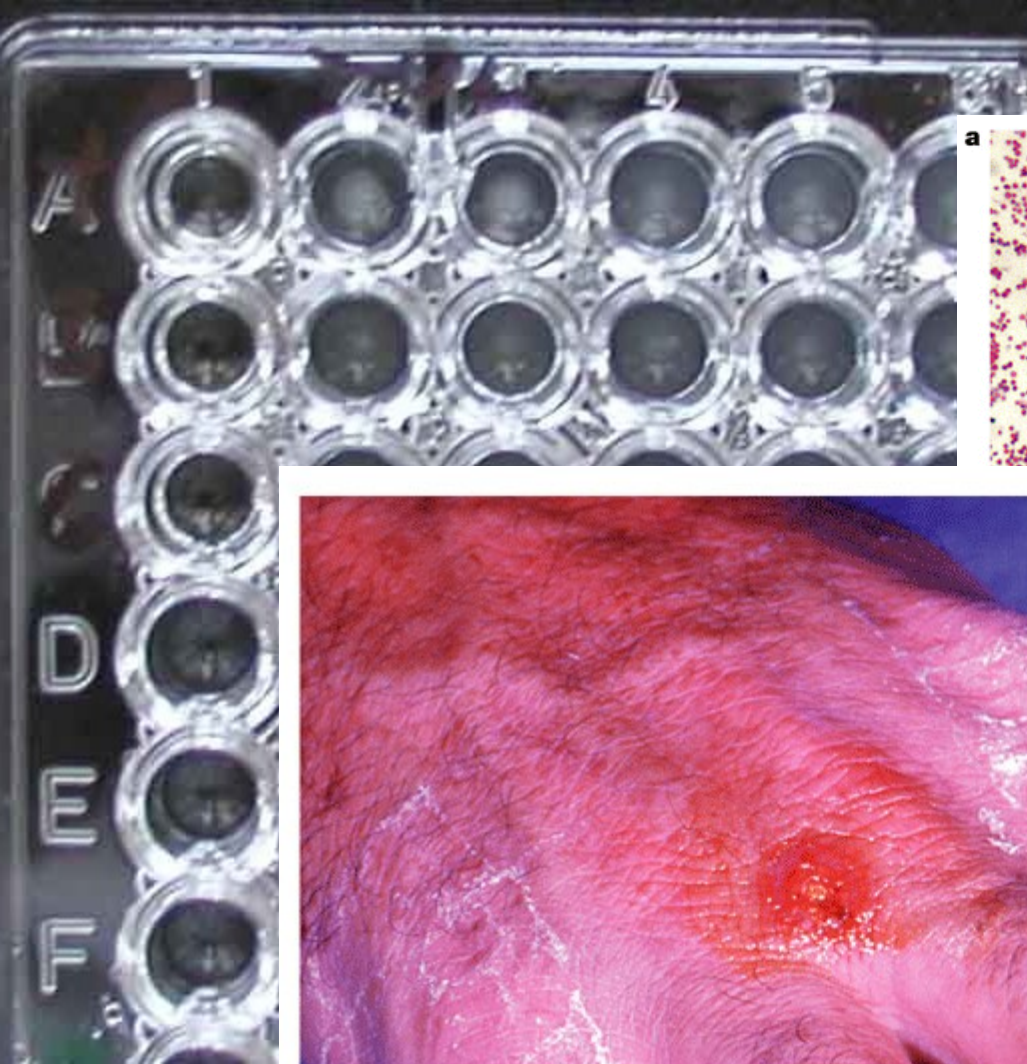
# Other injuries by animals

*Francisella tularensis* (rodents, hares – tularemia)

*Bartonella henselae* (cat scratch disease)







Nature Reviews | Microbiology

**FRANCISELLA TULARENSIS**

Nature Reviews | Microbiology

**Egon Schiele**  
**(1890-1918):**  
**Dead mother**  
**(1910)**

