

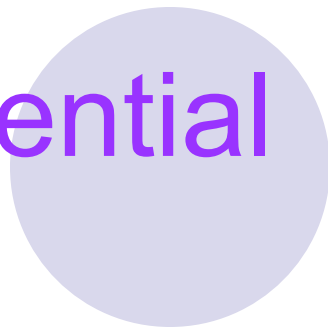
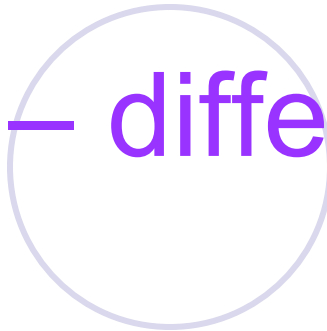







RED EYE – differential diagnosis



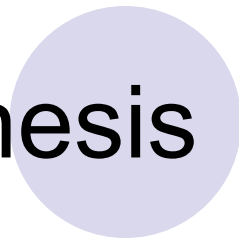




- „Red eye“ is sign of pathology of anterior or posterior ocular segment, of orbit or of ocular adnexa.



Anamnesis



- Systemic disease
- Eye disease
- Development of difficulties
- Character of difficulties



Eyelids - blepharitis

- Blepharitis - anterior and posterior
- Chronic anterior blepharitis
- Anterior blepharitis affects the area surrounding the bases of the eyelashes and may be staphylococcal or seborrhoeic



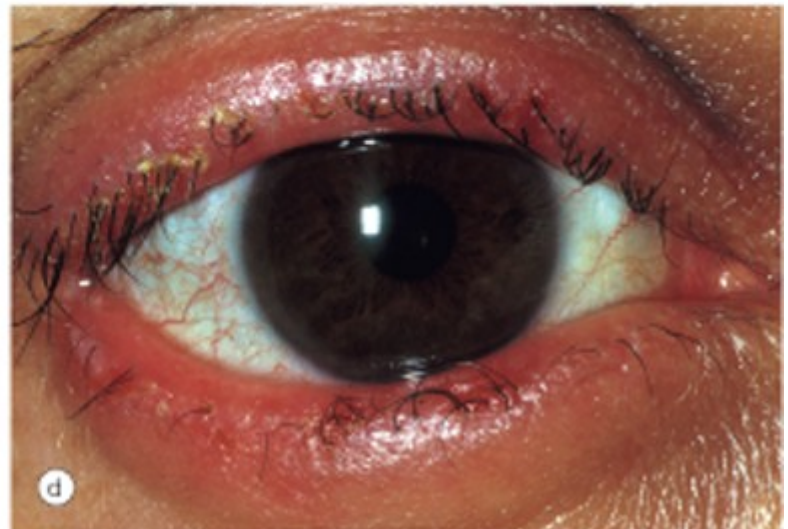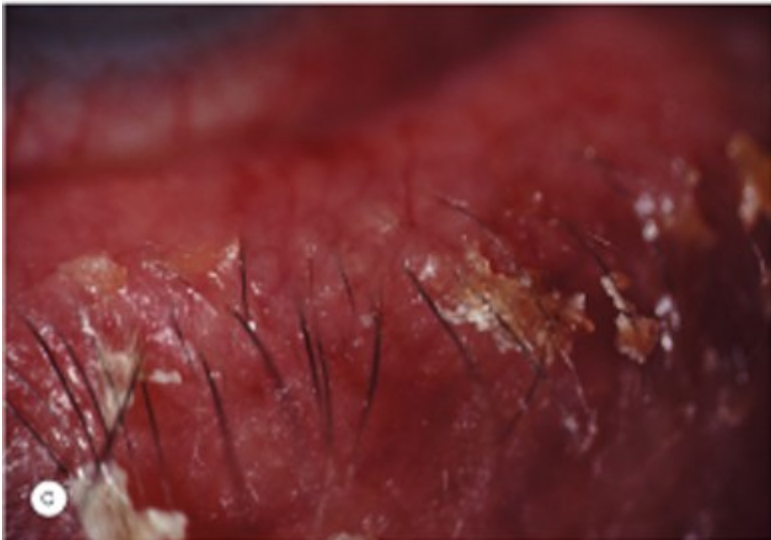
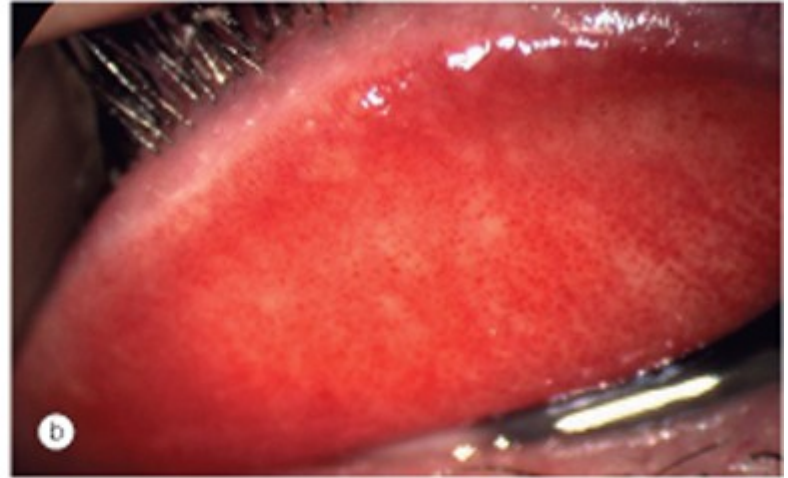

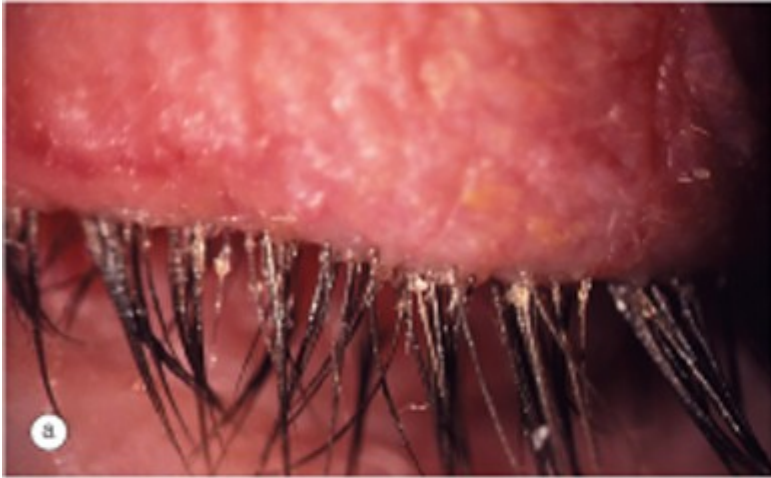
Eyelids - blepharitis

- Burning, grittiness and mild photophobia with remissions and exacerbations
- Symptoms are usually worse in the mornings

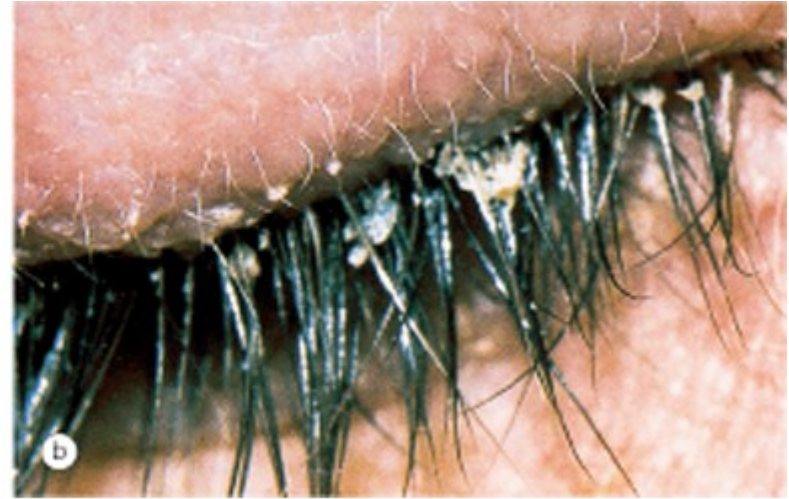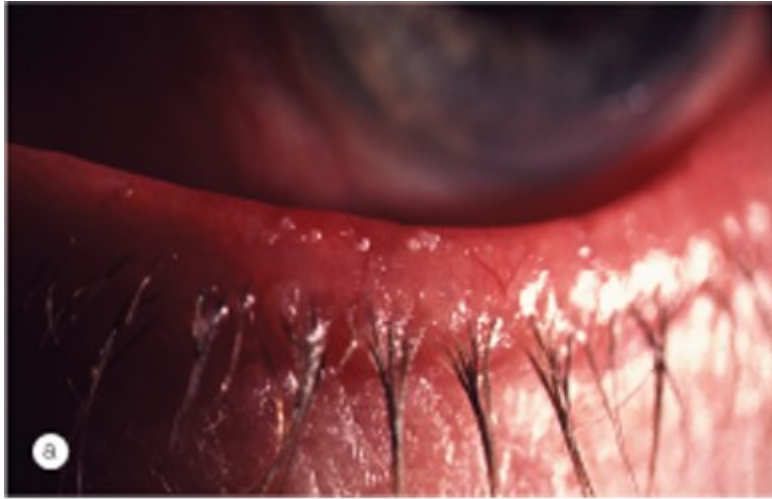
Eyelids - anterior blepharitis

- ***Staphylococcal blepharitis***
- Hard scales and crusting mainly located around the bases of the lashes (collarettes) .
- Madarosis, trichiasis and poliosis in severe long-standing cases.

- ***Seborrhoeic blepharitis***
- Hyperaemic and greasy anterior lid margins with sticking together of lashes
- The scales are soft and located anywhere on the lid margin and lashes



Chronic seborrhoeic blepharitis



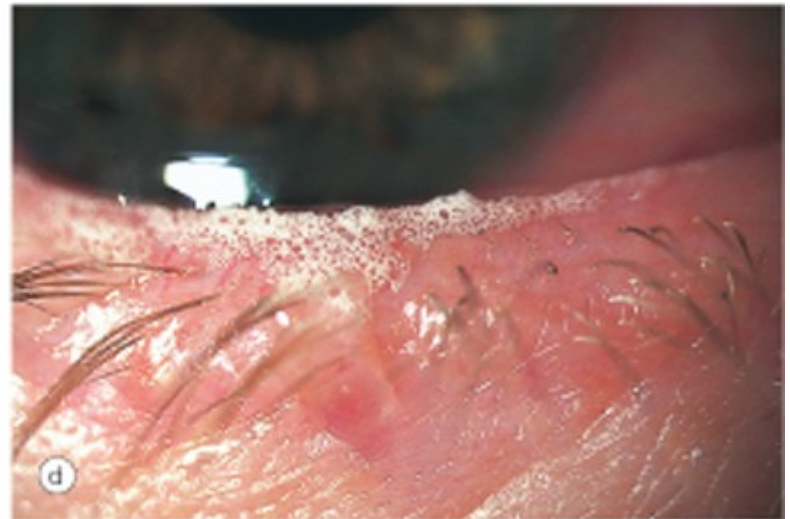
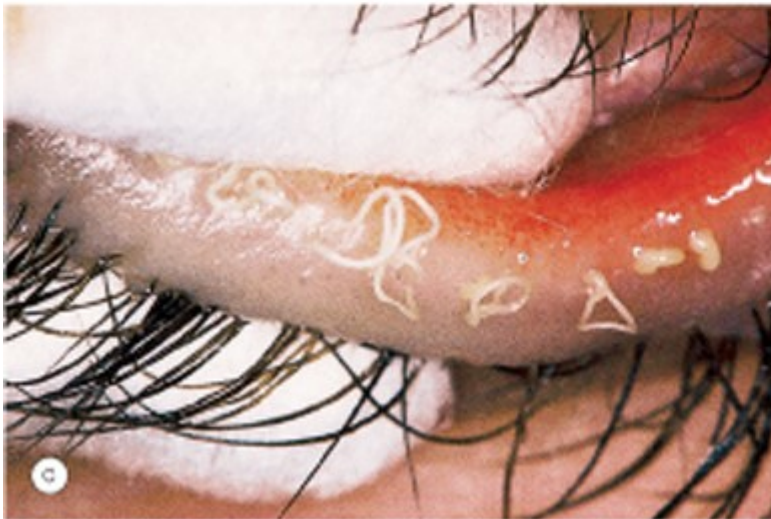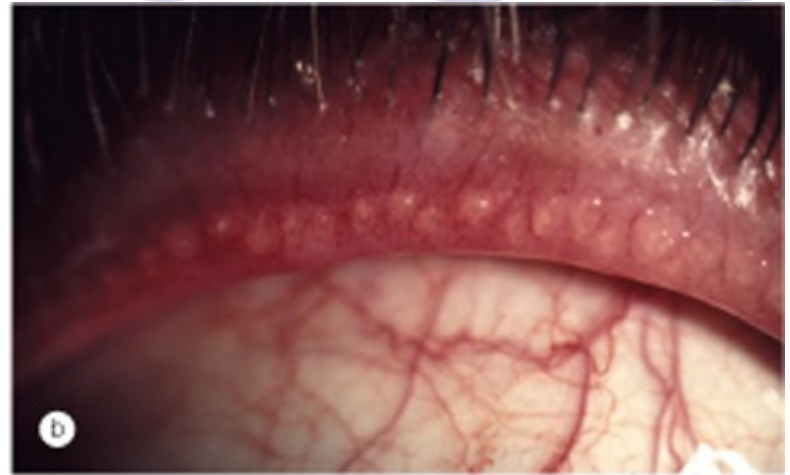
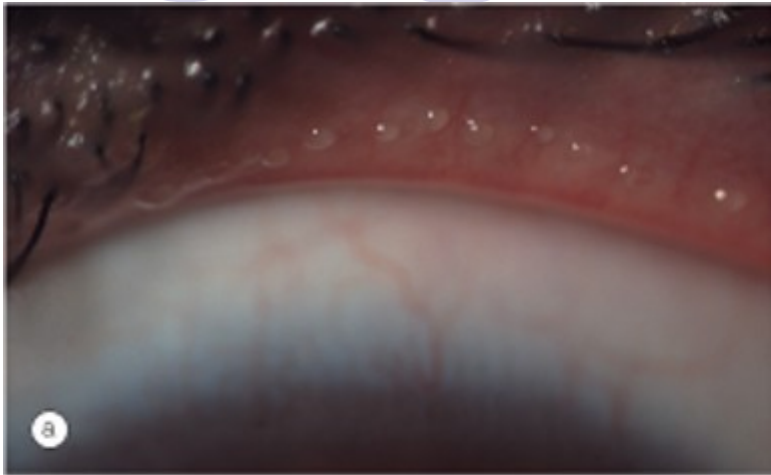


© 2007 Elsevier Ltd. Kanski: Clinical Ophthalmology 6e

Eyelids – posterior blepharitis

- Chronic posterior blepharitis
- Caused by meibomian gland dysfunction

Eyelids – posterior blepharitis

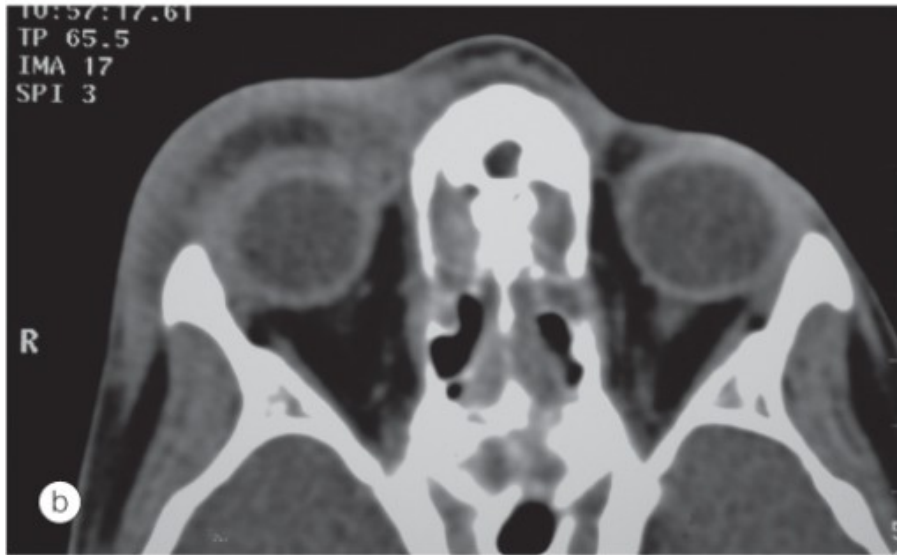
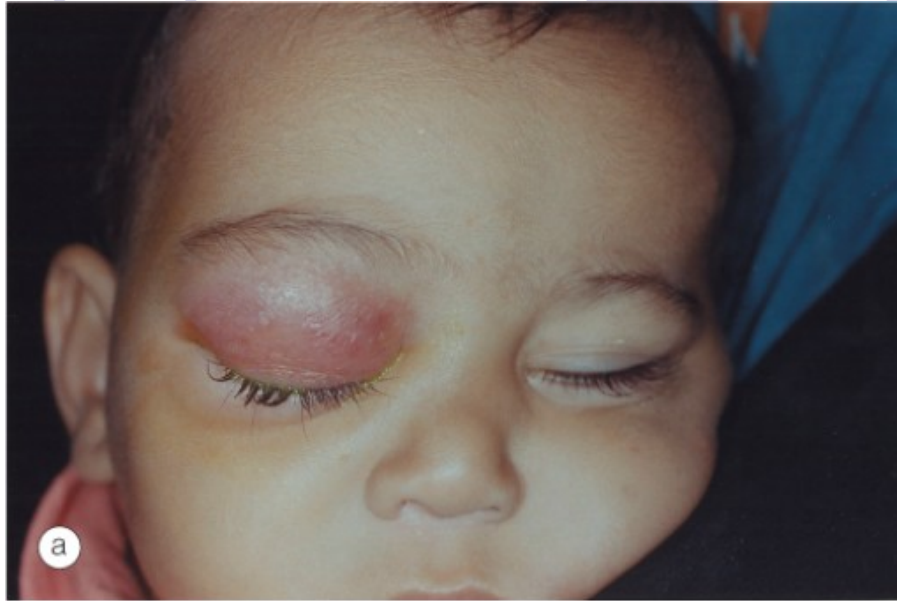- **Signs** of meibomian gland dysfunction :
- Capping of meibomian gland orifices with oil globules
- Pouting, recession, or plugging of the meibomian gland orifices
- Hyperaemia and telangiectasis of the posterior lid margin
- Pressure on the lid margin results in expression of meibomian fluid that may be turbid or appear like toothpaste
- The tear film is oily and foamy and froth may accumulate on the lid margins or inner canthi





Orbit – preseptal cellulitis

- Infection of the subcutaneous tissues anterior to the orbital septum.
- **Causes**
 - Skin trauma - laceratio, insect bites (*S. aureus* or *S. pyogenes*)
 - Spread of local infection - from an acute hordeolum or dacryocystitis.
 - From remote infection of the upper respiratory tract or middle ear by haematogenous spread
- **Signs** - Unilateral, tender and red periorbital oedema



Orbit - Bacterial orbital cellulitis

- **Life-threatening infection** of the soft tissues behind the orbital septum, mainly in children
- The most prevalent causative organisms are *S. pneumoniae*, *S. aureus*, *S. pyogenes* and *H. influenzae*.
- **Pathogenesis**
- Sinus-related - ethmoidal, typically affects children and young adults.
- Extension of preseptal cellulitis
- Local spread from adjacent dacryocystitis, and mid-facial or dental infection
- Haematogenous spread



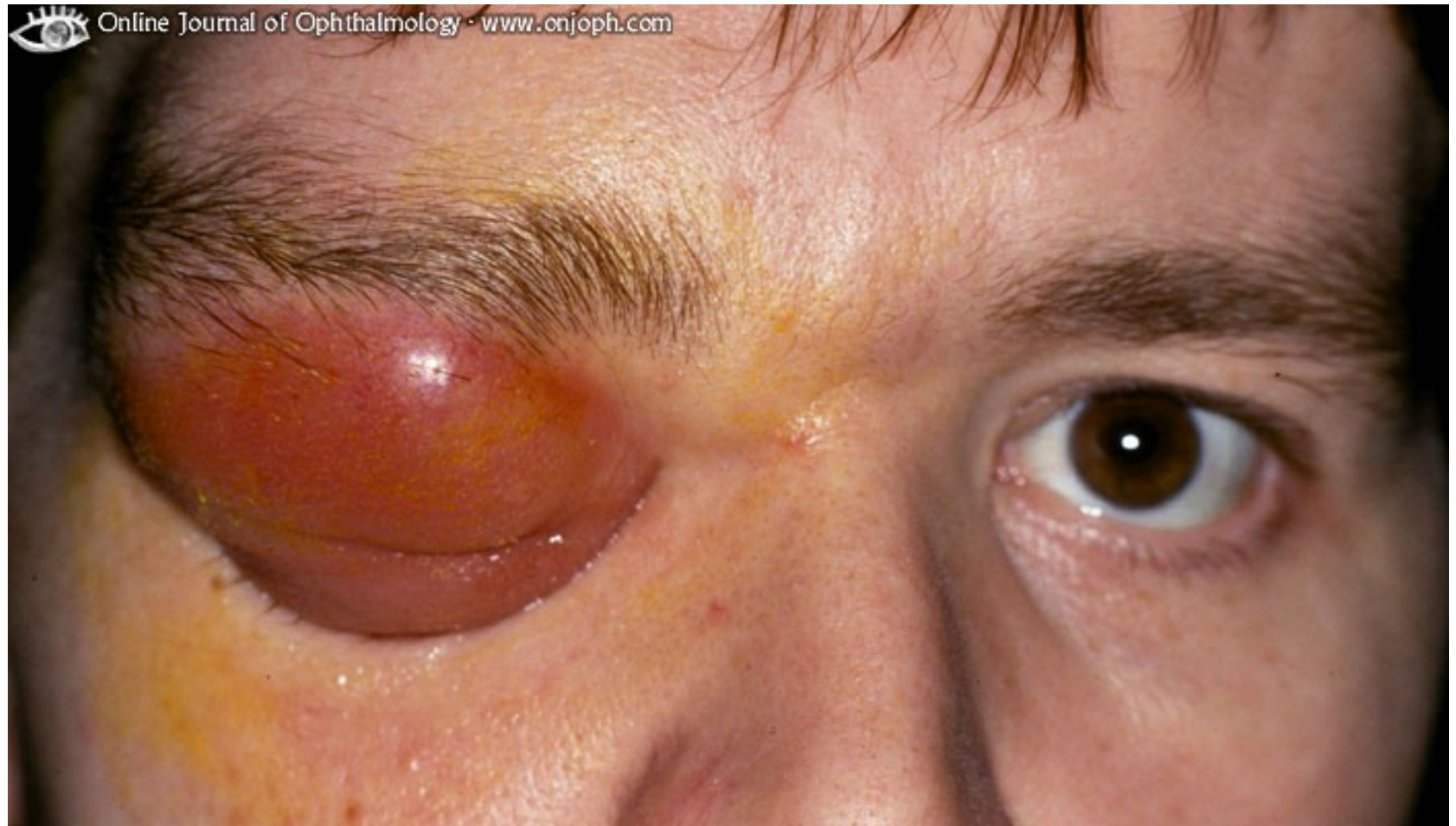




Orbit - Bacterial orbital cellulitis


- **Presentation** is with a rapid onset of severe malaise, fever, pain and visual impairment
- **Signs**
 - Unilateral, tender, warm and red periorbital oedema
 - Proptosis, lid swelling
 - Painful ophthalmoplegia
 - Optic nerve dysfunction

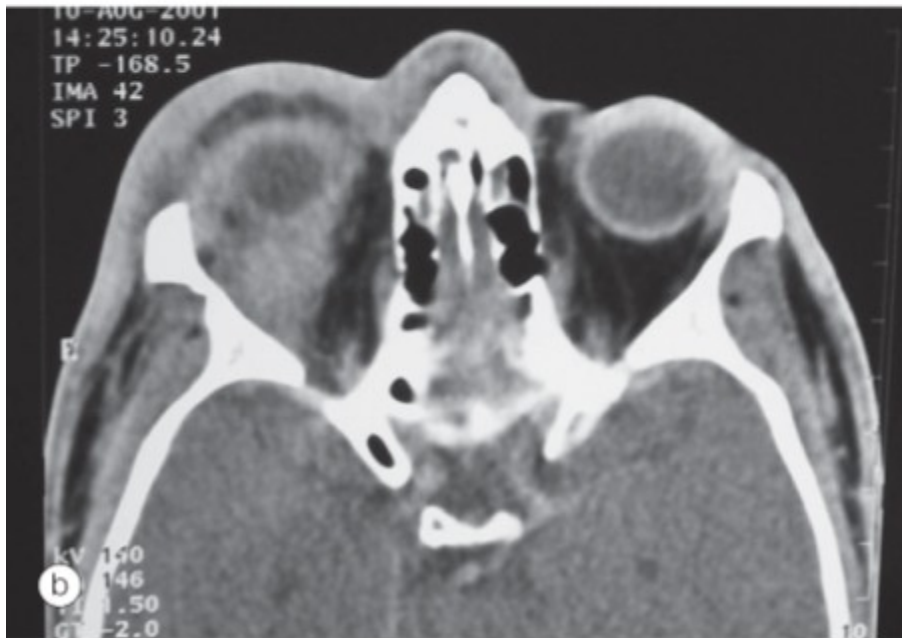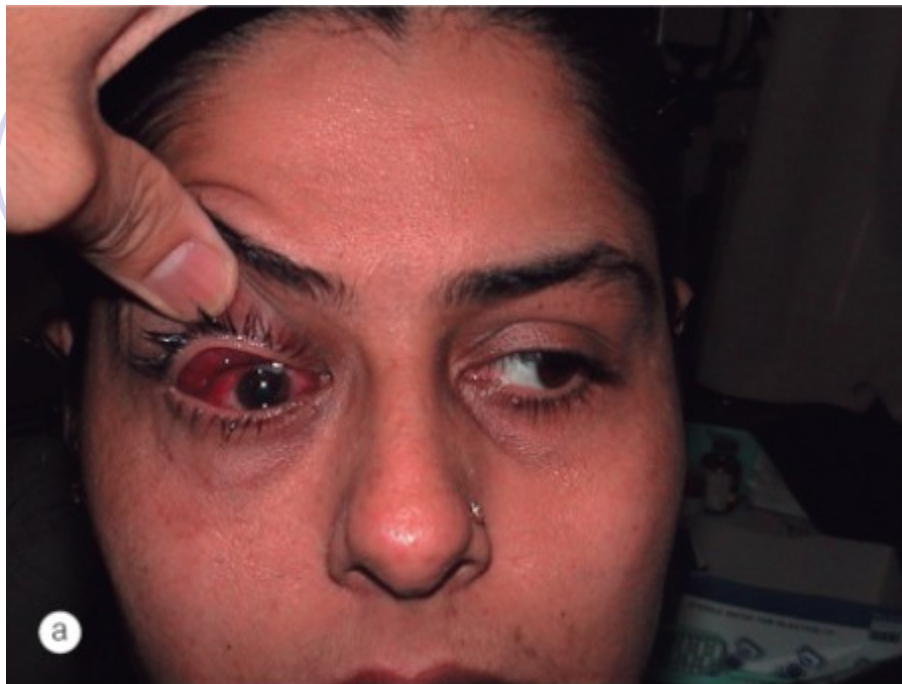Orbit - Bacterial orbital cellulitis

- **Complications**

- Ocular complications - exposure keratopathy, raised intraocular pressure, occlusion of the central retinal artery or vein, endophthalmitis and optic neuropathy
- Intracranial complications - meningitis, brain abscess and cavernous sinus thrombosis
- Subperiosteal abscess - along the medial orbital wall
- Orbital abscess in post-traumatic or postoperative cases.



 Online Journal of Ophthalmology · www.onjoph.com





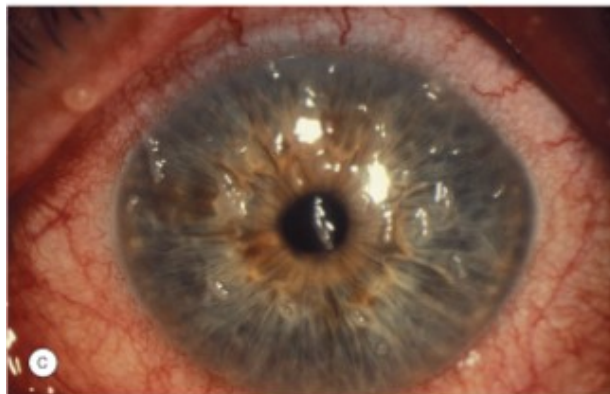
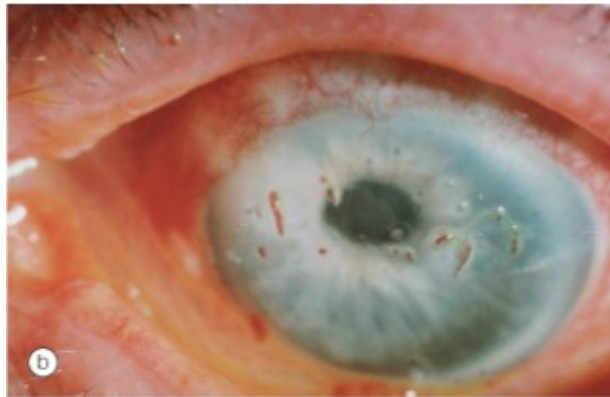
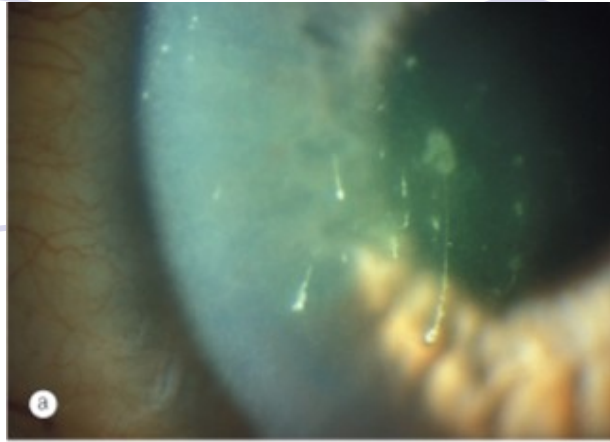

Dry Eye Disorders

- There is inadequate tear volume or function resulting in an unstable tear film and ocular surface disease.
- **Keratoconjunctivitis sicca** (KCS) refers to any eye with some degree of dryness.
- **Xerophthalmia** describes a dry eye associated with [vitamin A](#) deficiency.
- **Xerosis** refers to extreme ocular dryness and keratinization that occurs in eyes with severe conjunctival cicatrization.
- **Sjögren syndrome** is an autoimmune inflammatory disease which is usually associated with dry eyes.



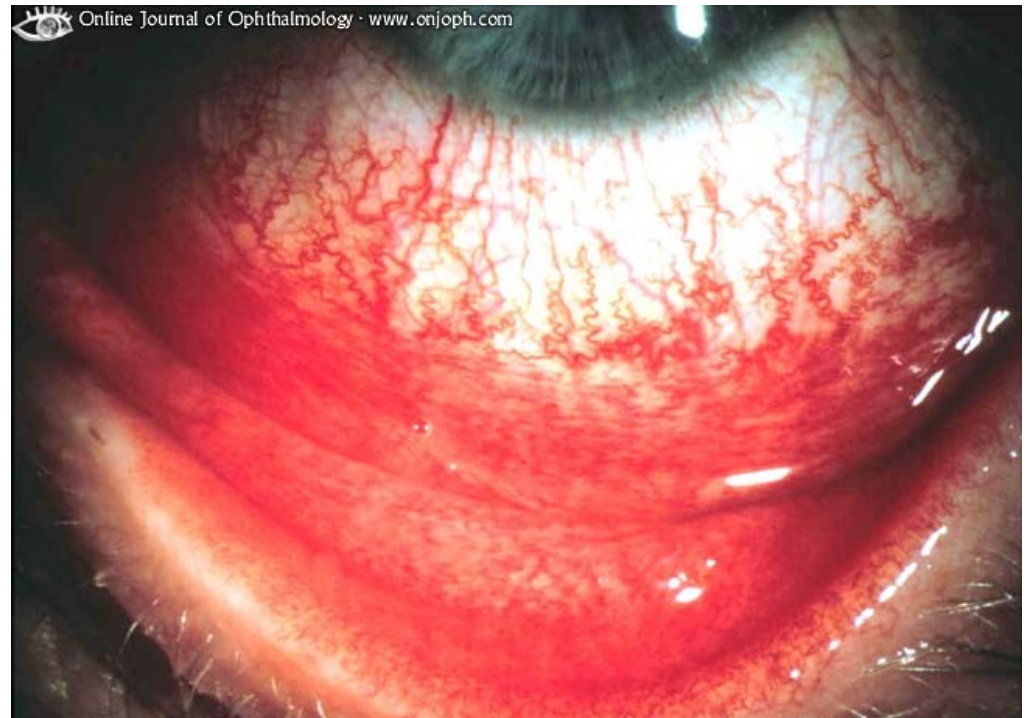
Dry Eye Disorders

- **Symptoms**
- feelings of dryness, grittiness and burning - worsen during the day, transient blurring of vision, redness and crusting of the lids



Conjunctiva

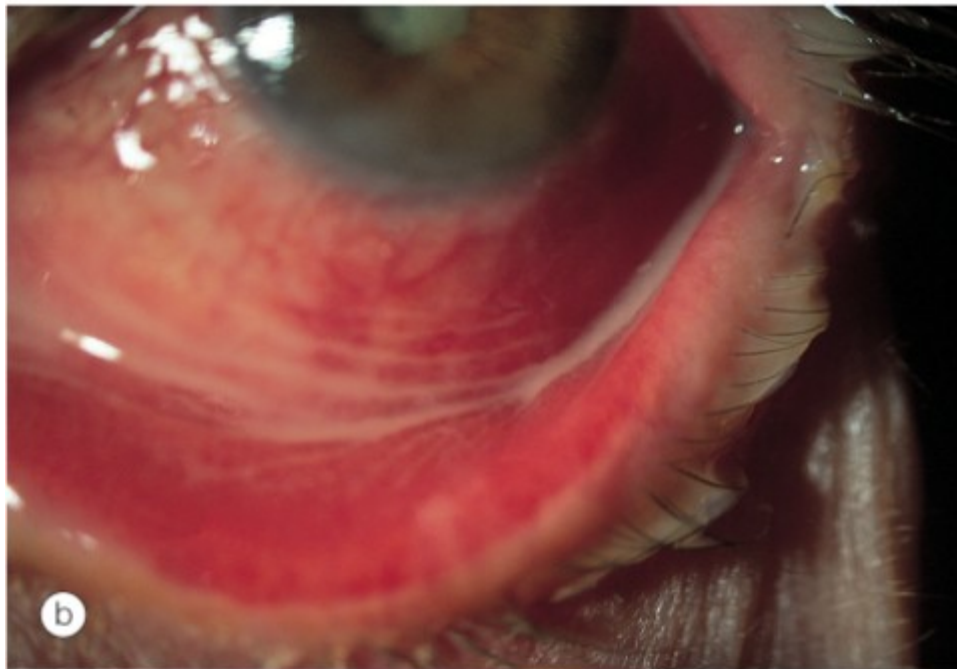
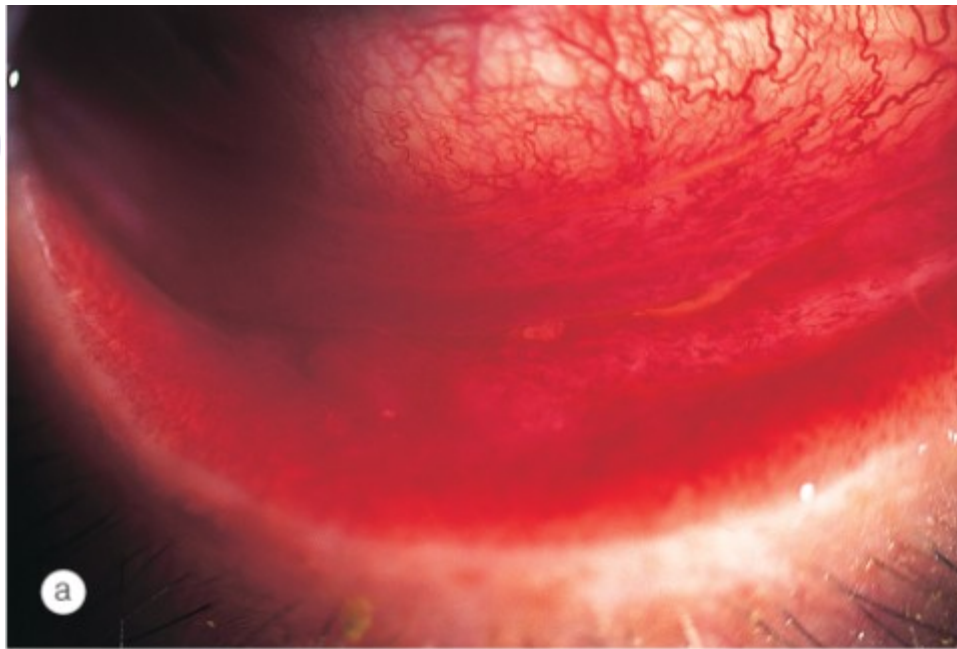
- **Conjunctival injection** is diffuse, beefy-red and more intense away from the limbus
- Instillation of 10% phenylephrine drops will constrict the conjunctival and superficial episcleral vasculature

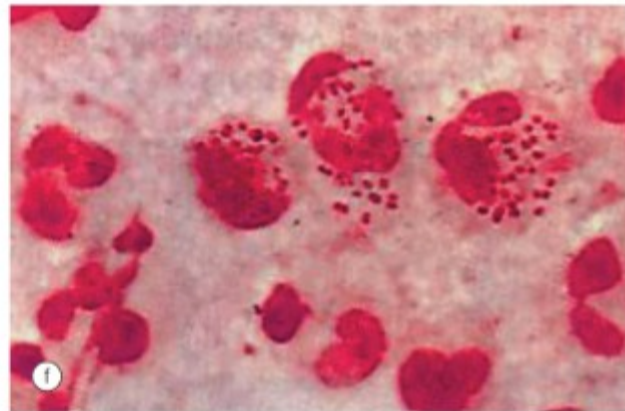
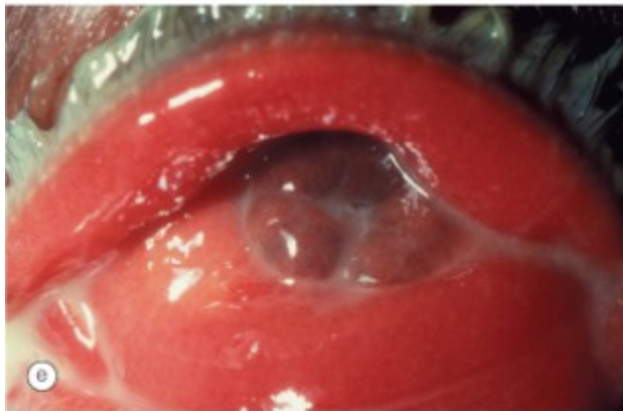
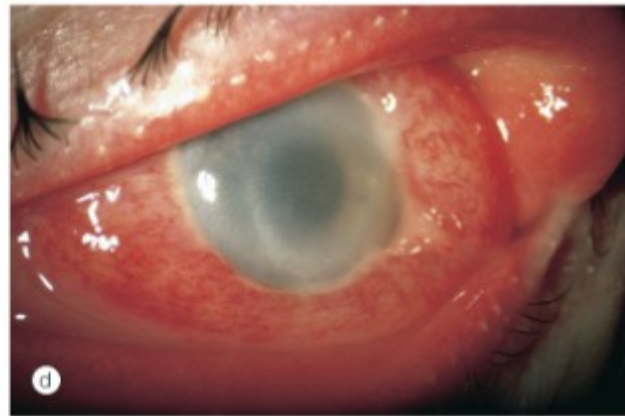
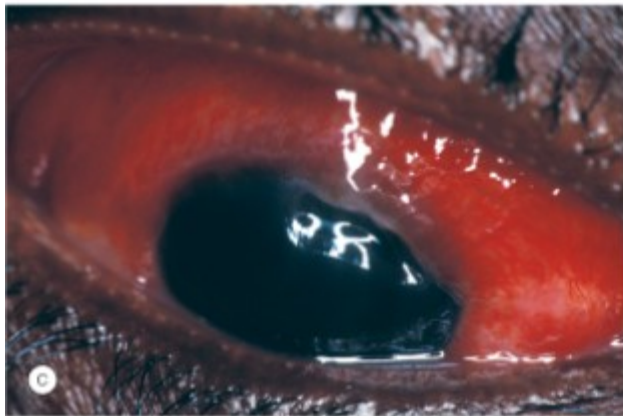
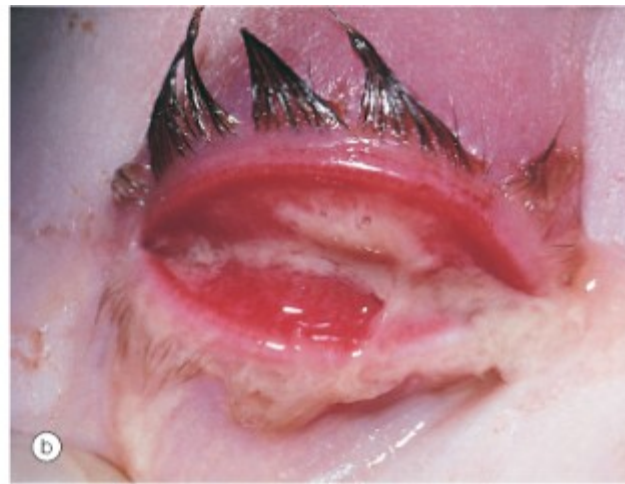
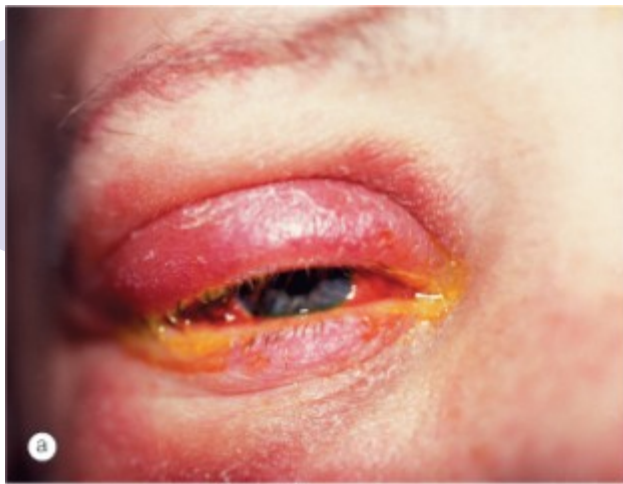


Conjunctivitis

- **Bacterial** - *H. influenzae*, *S. pneumoniae*, *S. aureus*
- Papillary reaction over the tarsal plates
- Mucopurulent discharge
- Gonococcal keratoconjunctivitis - pseudomembrane formation, Lymphadenopathy, Corneal ulceration








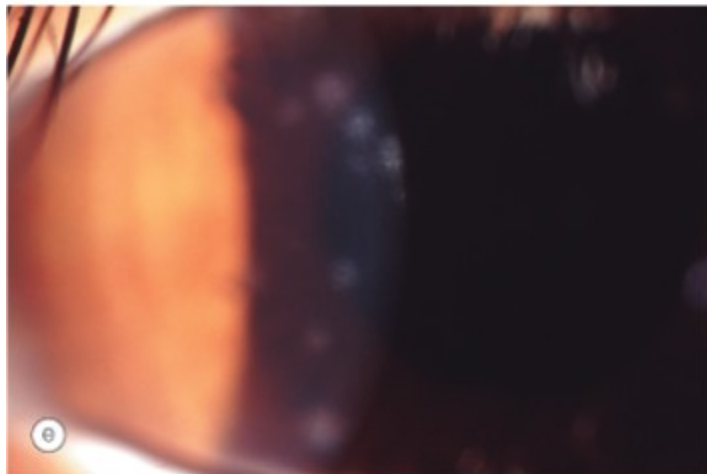

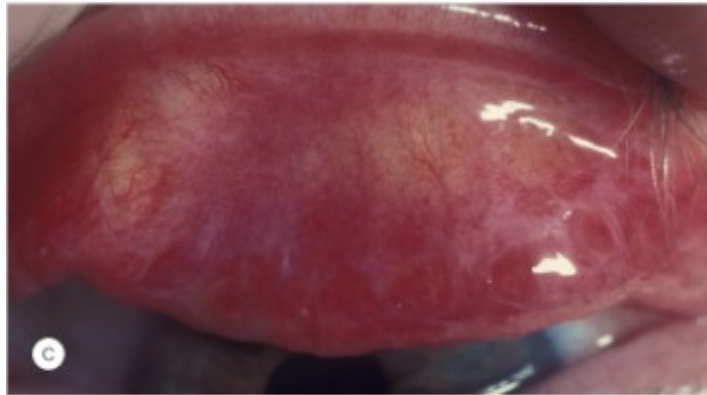
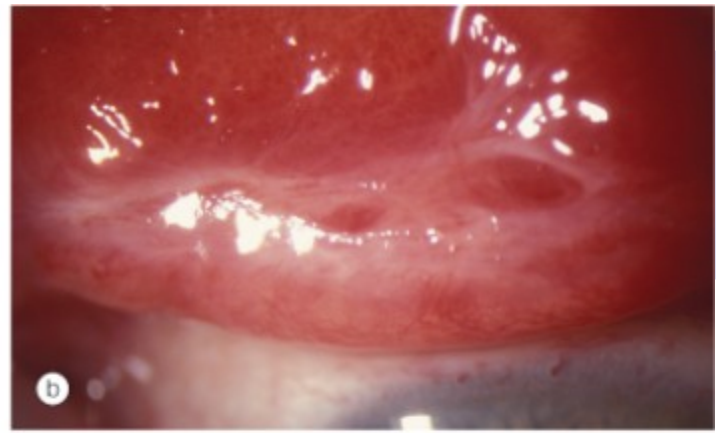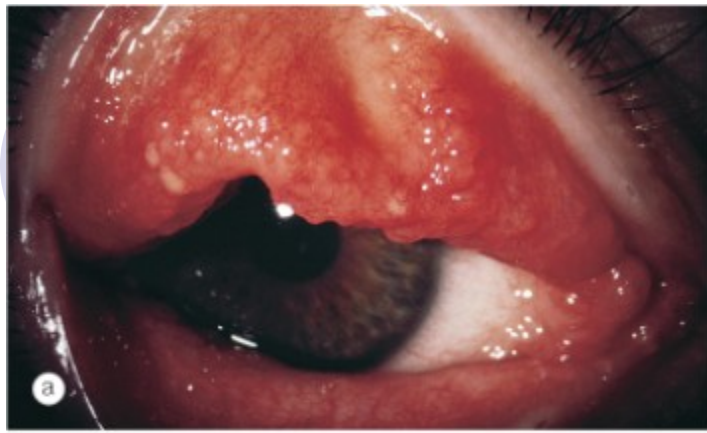
Conjunctivitis

- **Viral conjunctivitis**
- **Adenoviral keratoconjunctivitis** - the most common external ocular viral infection
- Sporadic or occur in epidemics in hospitals, schools and factories
- **Transmission** of this highly contagious virus -respiratory or ocular secretions
- Dissemination is by contaminated towels or equipment such as tonometer heads



Conjunctivitis

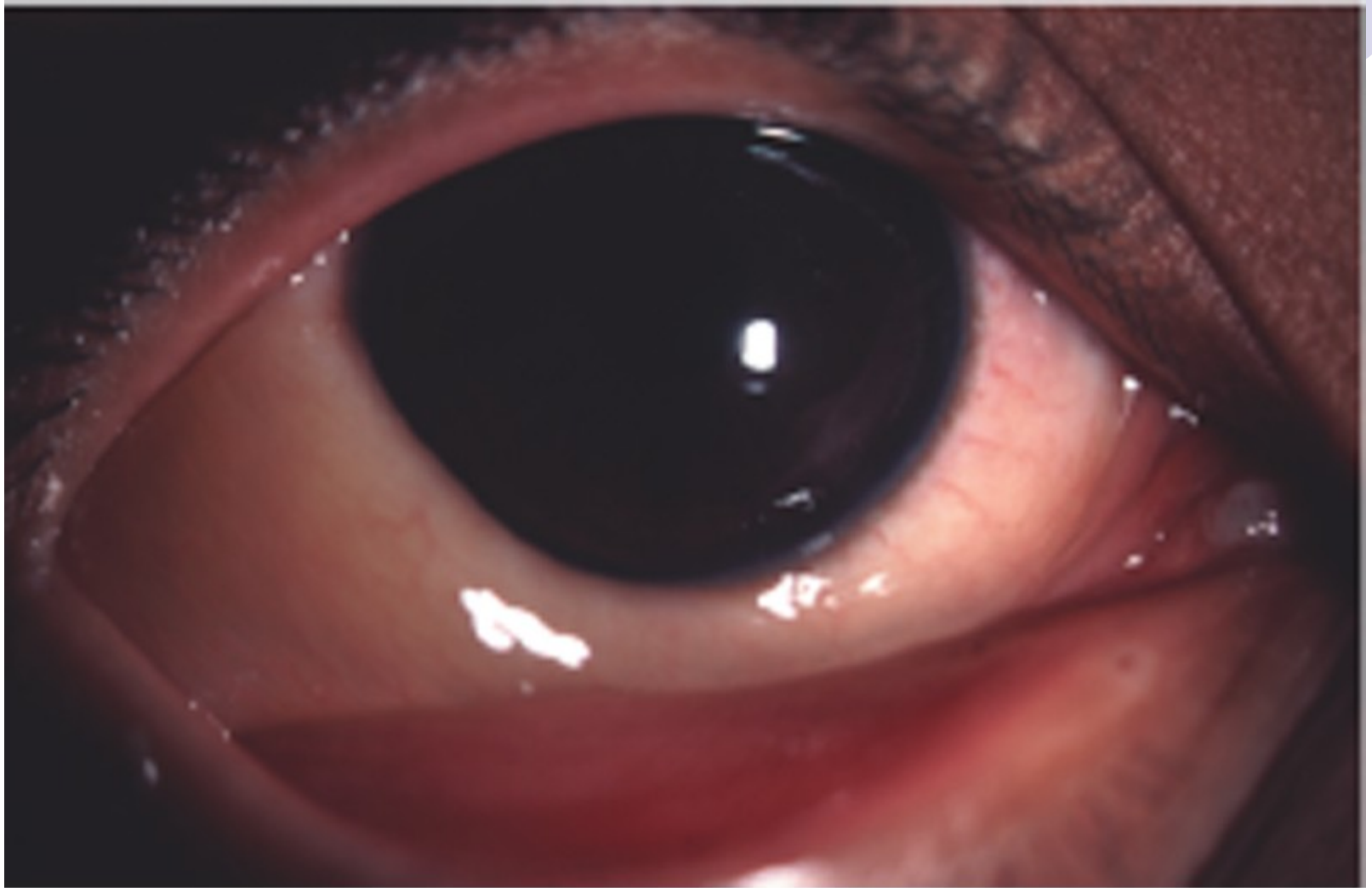
- **Presentation**
- Unilateral watering, redness, discomfort and photophobia
- The contralateral eye is typically affected 1-2 days later, but less severely
- Eyelid oedema and tender pre-auricular lymphadenopathy.
- Follicular conjunctivitis





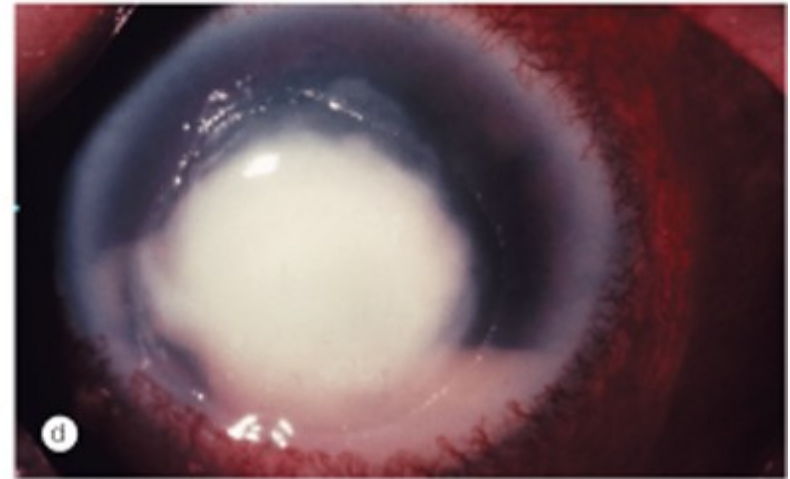
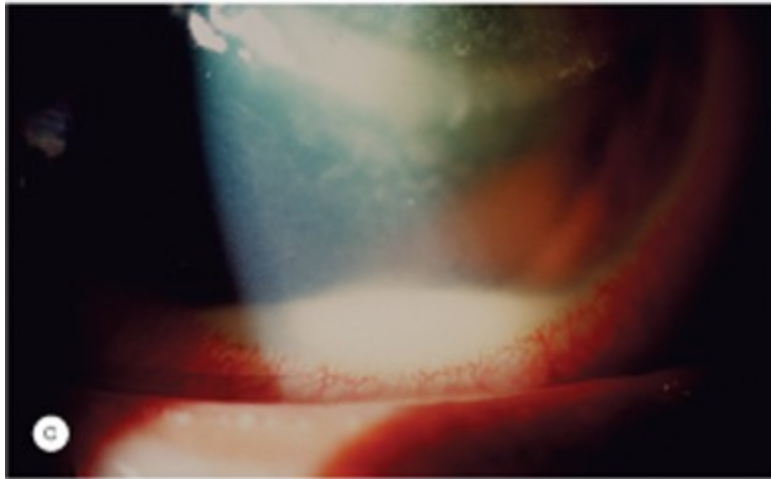
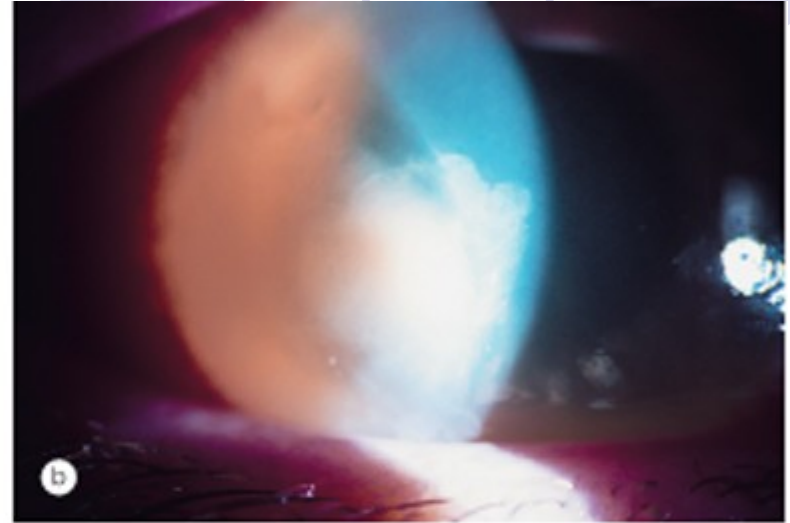
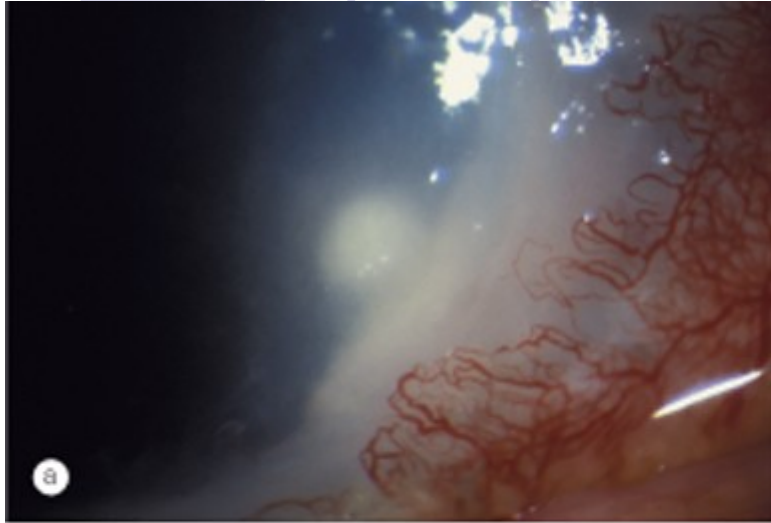
Conjunctivitis

- **Acute allergic rhinoconjunctivitis**
- **Seasonal allergic conjunctivitis** (hay fever) - onset during the spring and summer
- The most frequent allergens are tree and grass pollens
- **Perennial allergic conjunctivitis** causes symptoms throughout the year with exacerbation in the autumn when exposure to house dust mites, animal dander and fungal allergens is greatest
- **Presentation** - redness, watering and **itching**, associated with sneezing and nasal discharge



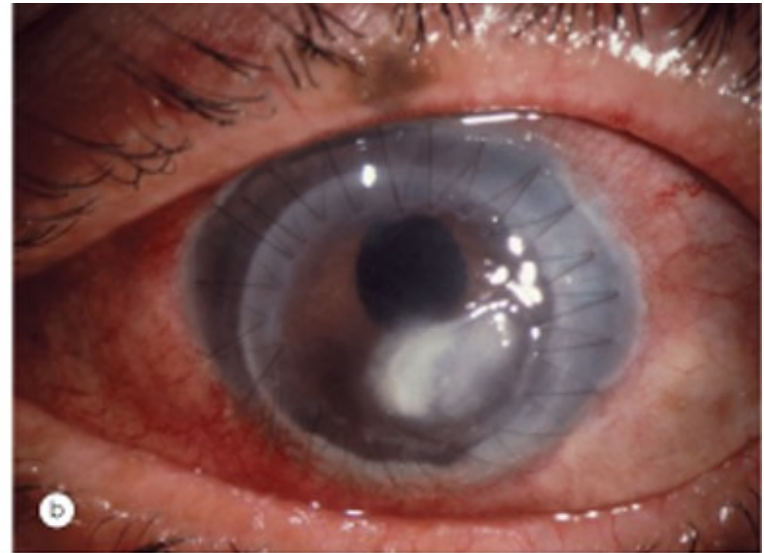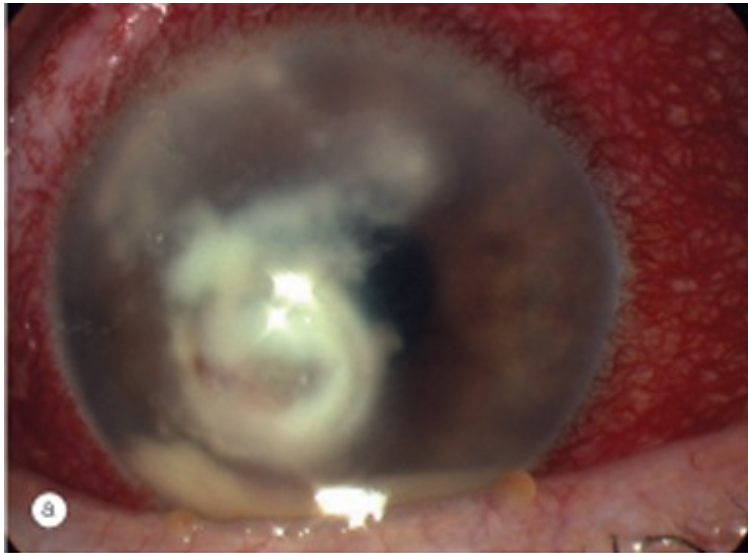Cornea – infectious keratitis

- **Keratitis – bacterial** (P. aeruginosa ,S. aureus, S. pyogenes)
- Risk factors - **Contact lens wear**, trauma
- **Presenting symptoms** - pain, photophobia, blurred vision and discharge
- **Signs**
- An epithelial defect, infiltrate around the margin, circumcorneal injection
- Stromal oedema and small hypopyon
- Progressive ulceration may lead to corneal perforation and endophthalmitis.



Cornea – infectious keratitis

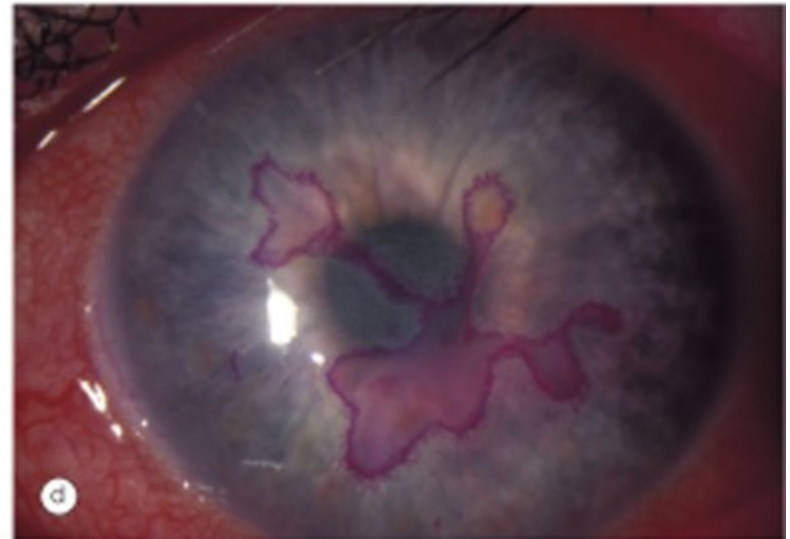
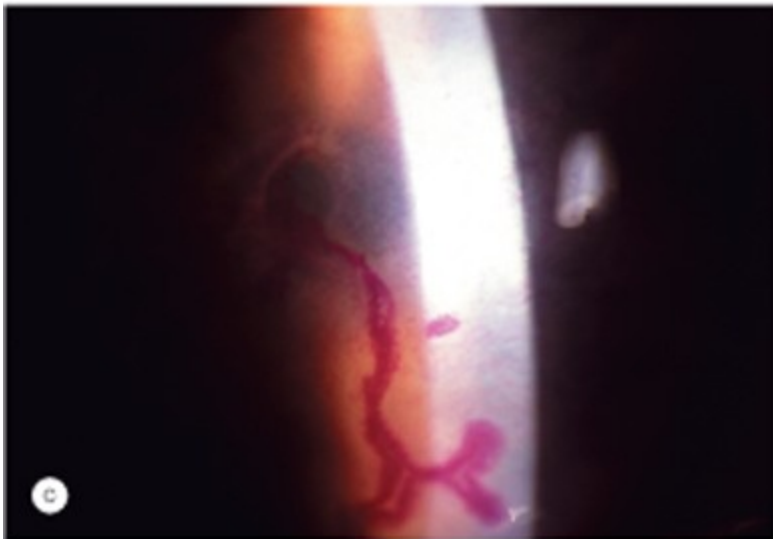
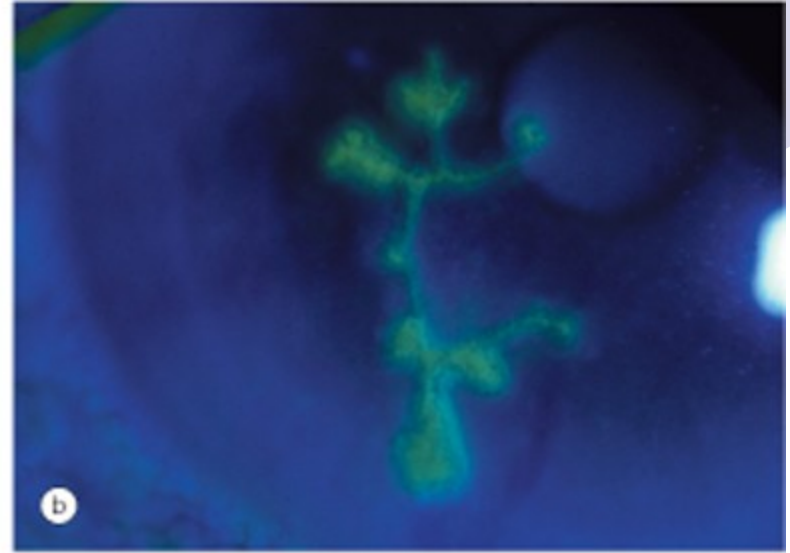
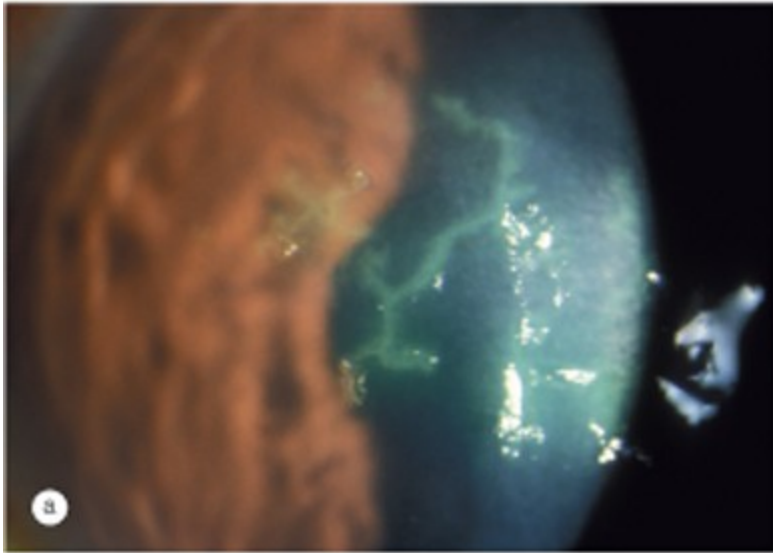
- **Keratitis – fungal** (stromal infiltrate with indistinct margins, surrounded by satellite lesions, hypopyon)





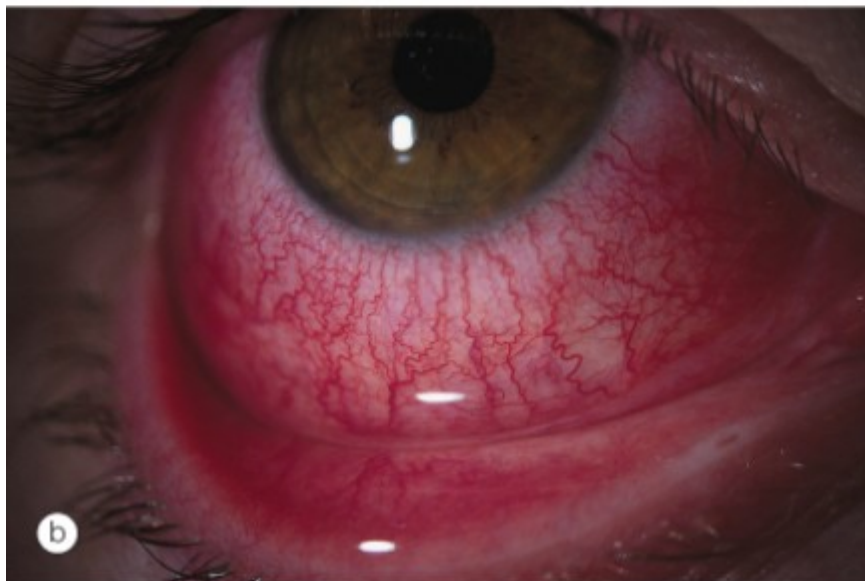
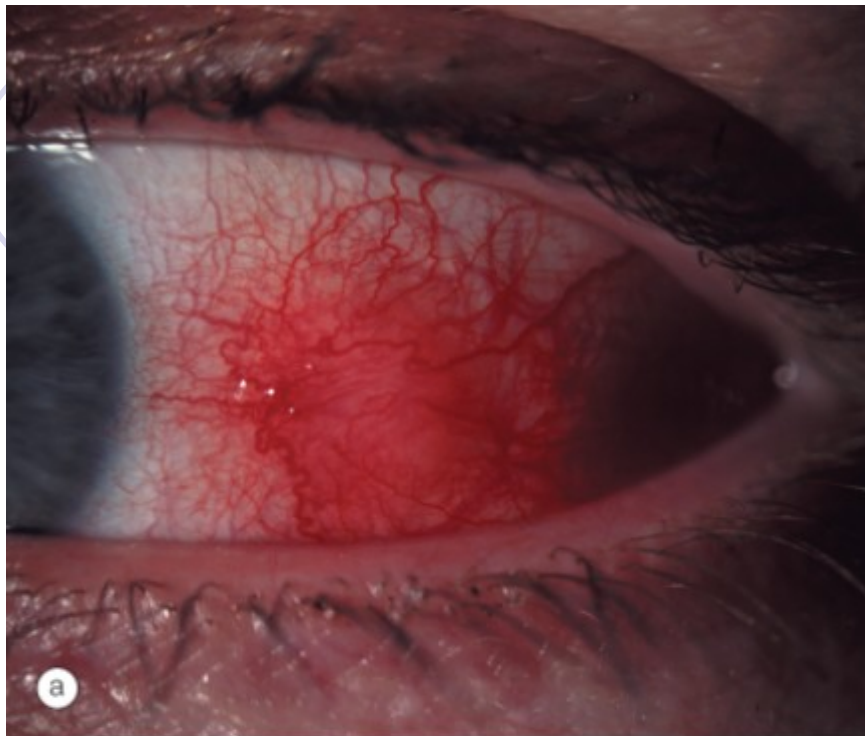
Cornea – infectious keratitis

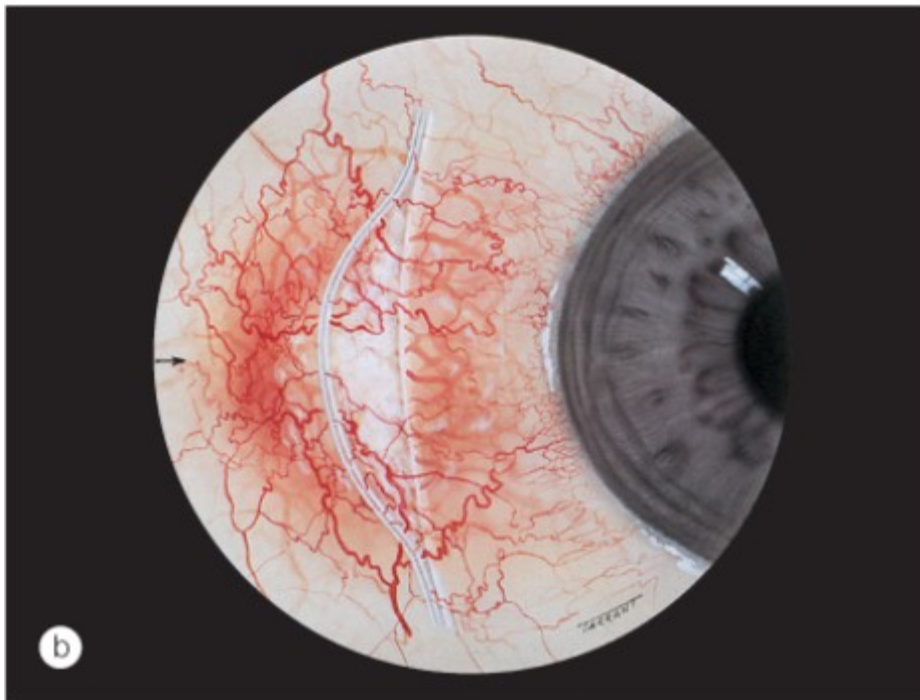
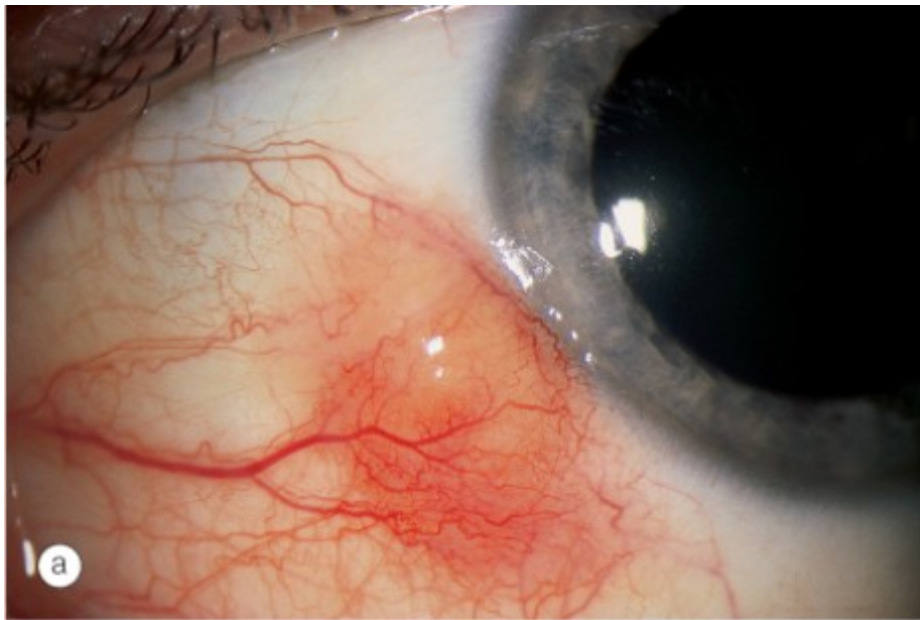
- **Keratitis viral** – herpes simplex virus
- linear-branching (dendritic) ulcer, corneal sensation is reduced









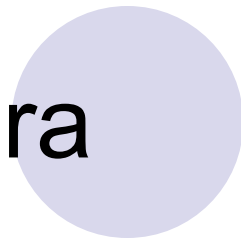
- Episcleritis – simple (sectoral or diffuse) , nodular – young, female
- **Presentation** - always sudden
- The eye becoming red and uncomfortable within an hour of the start of an attack - hotness, pricking or generalized discomfort
- Without systemic associations



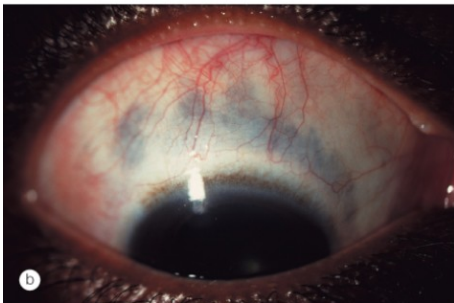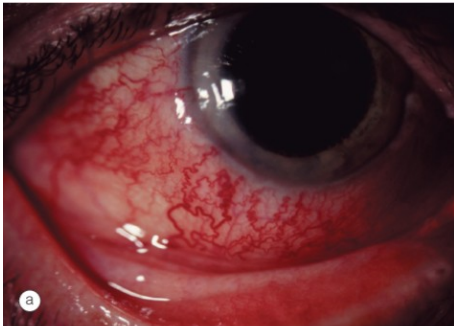


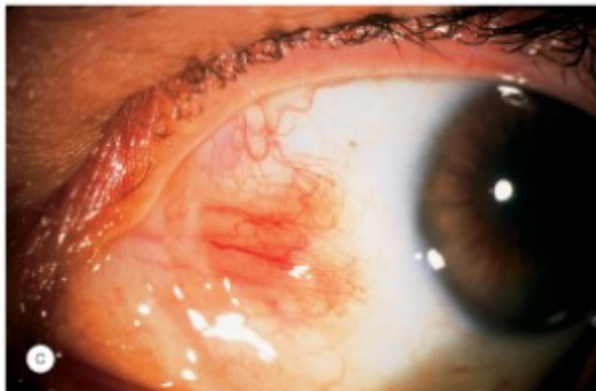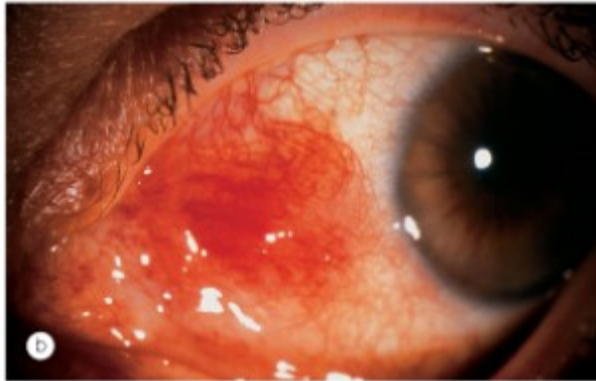


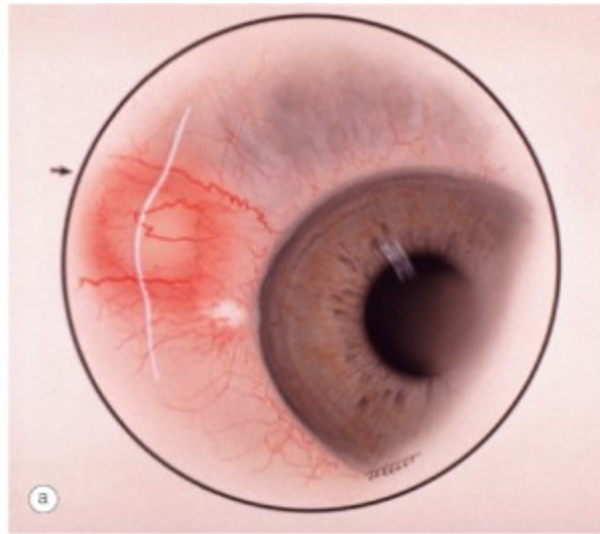



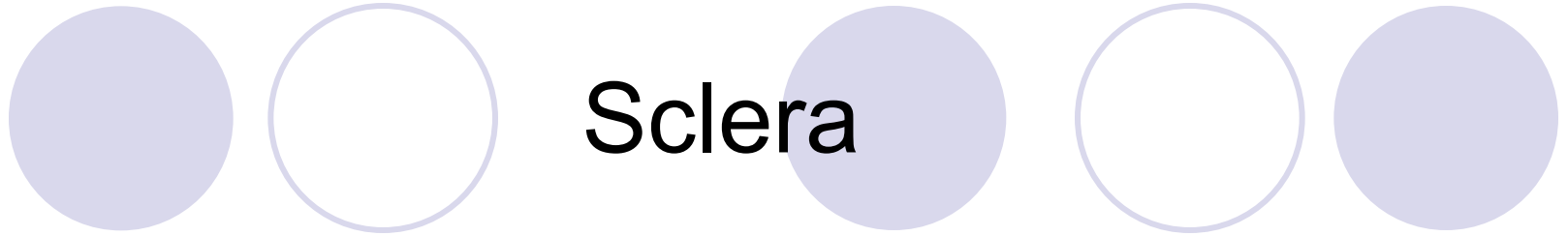
Sclera



- **Scleritis** - oedema and cellular infiltration of the entire thickness of the sclera
- *Anterior non-necrotizing scleritis* – diffuse or nodular
- Redness, pain which may spread to the face and temple

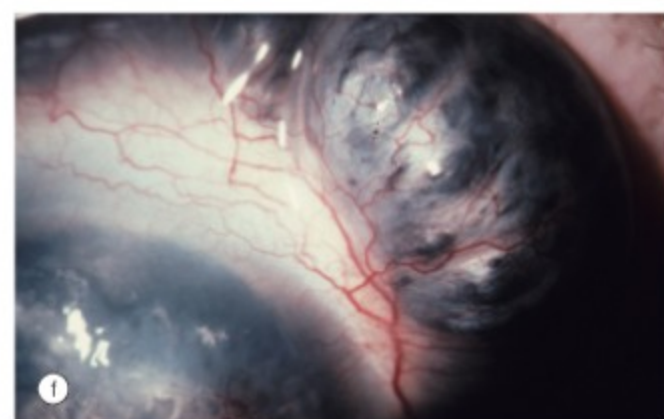
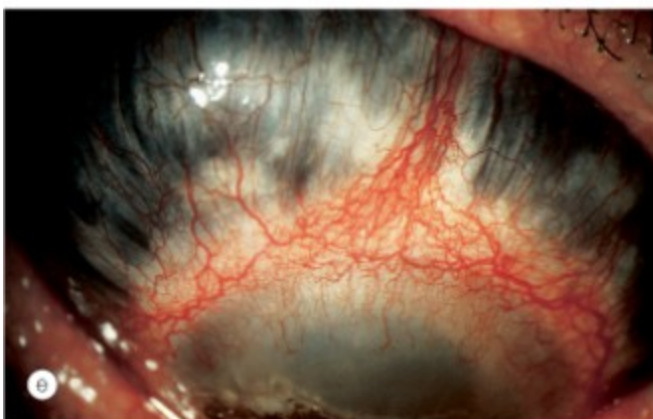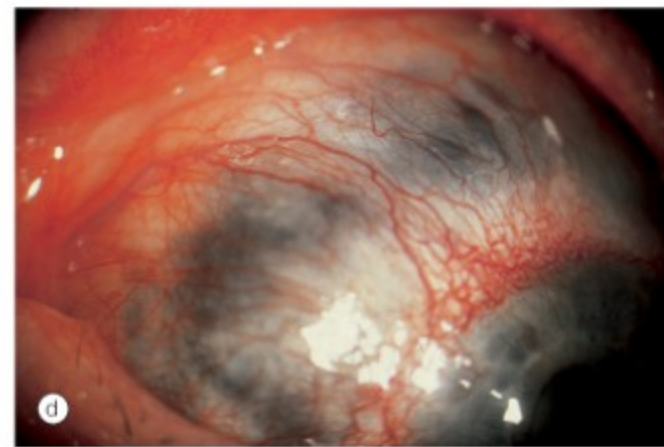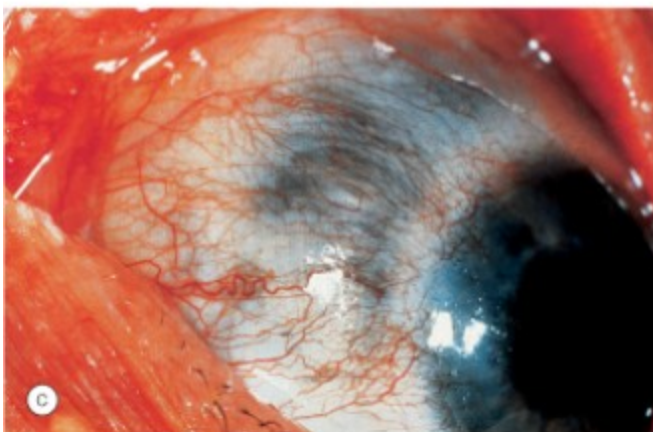
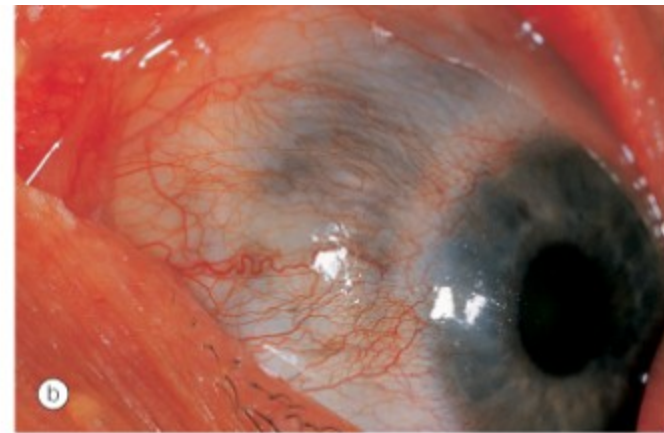
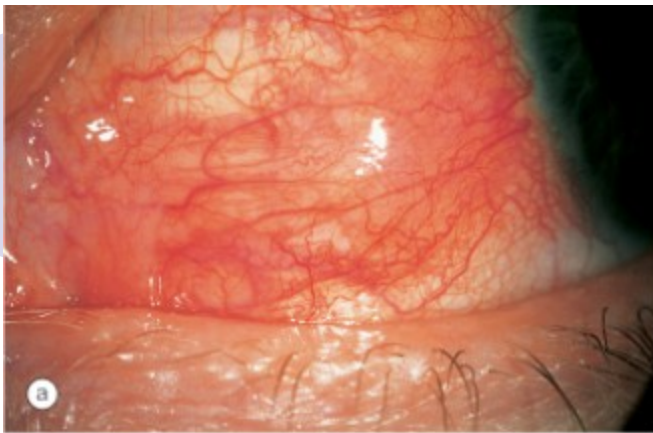


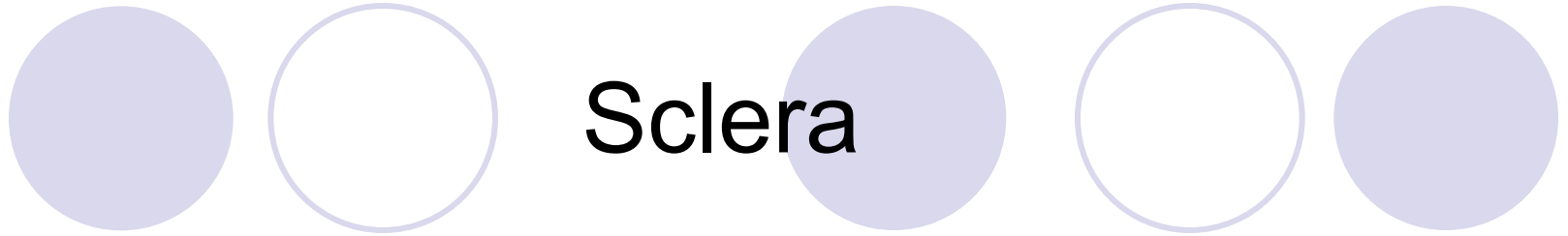




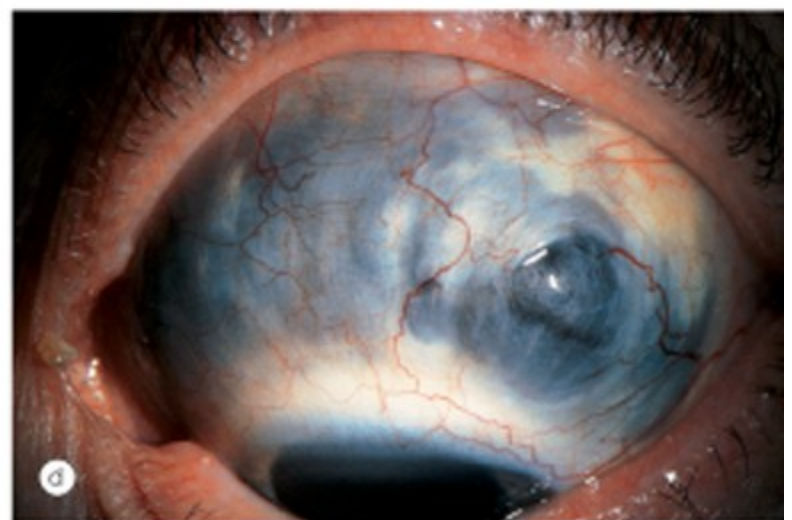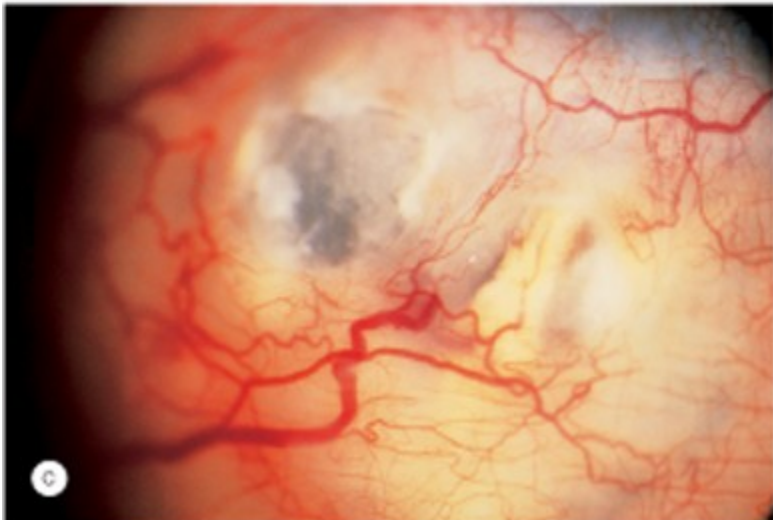



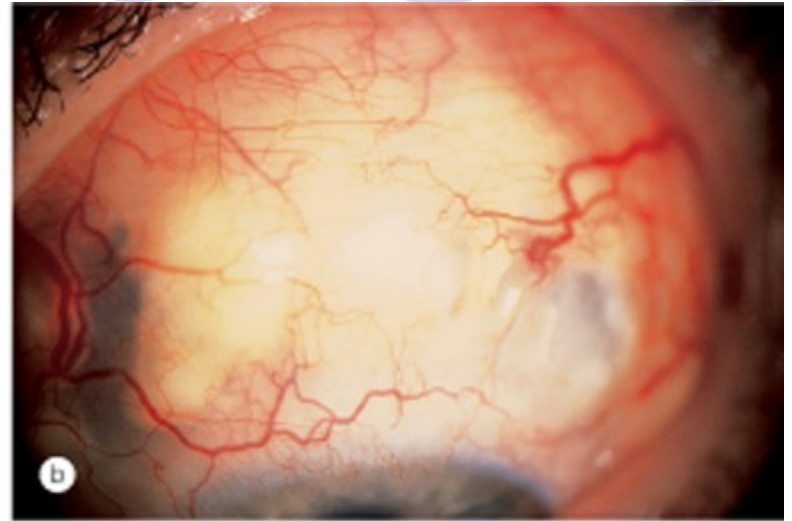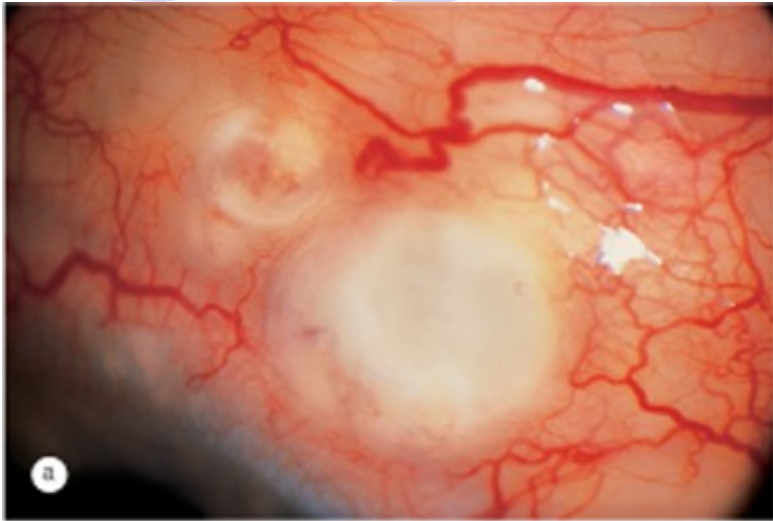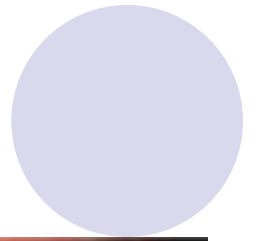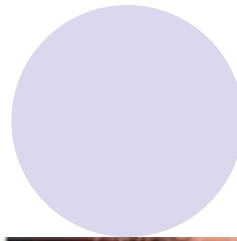Sclera

- *Necrotizing anterior scleritis with inflammation*
- pain - severe and persistent
- Scleral thinning due to necrosis allows the blue choroid to show through the translucent hydrated scar tissue that has replaced normal sclera

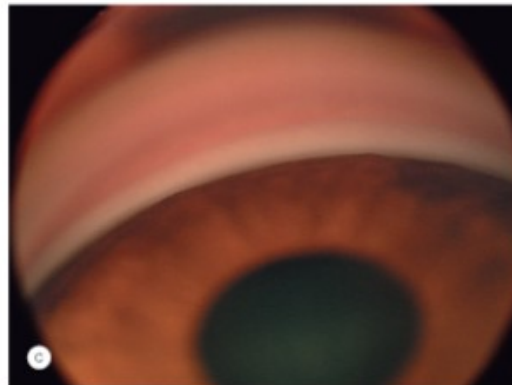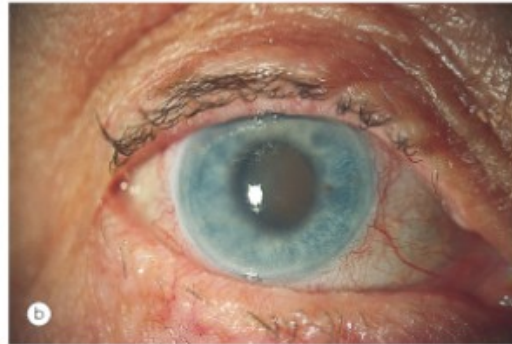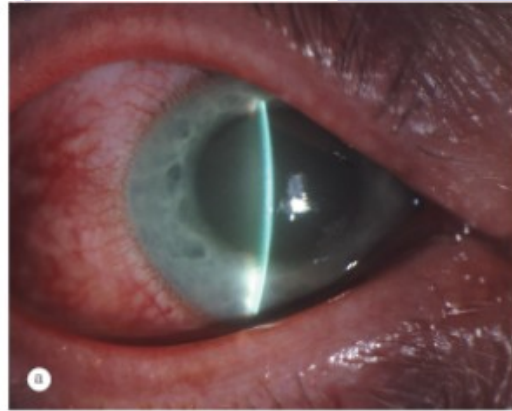






- *Scleromalacia perforans*
- Specific type of necrotizing scleritis without inflammation that typically affects elderly women with long-standing rheumatoid arthritis
- Yellow scleral necrotic plaques near the limbus without vascular congestion



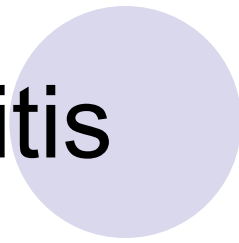


Glaucoma - Acute congestive angle closure





Uveitis

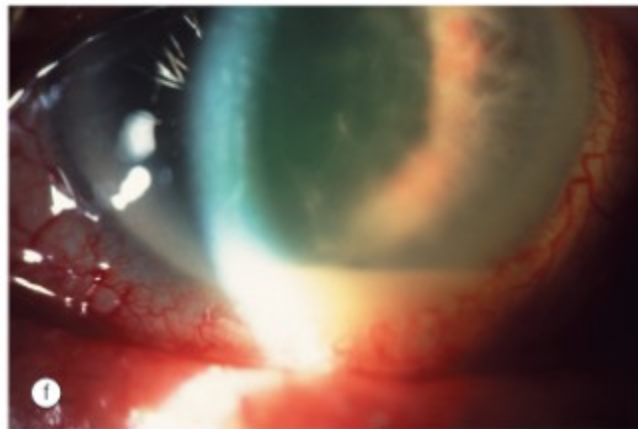
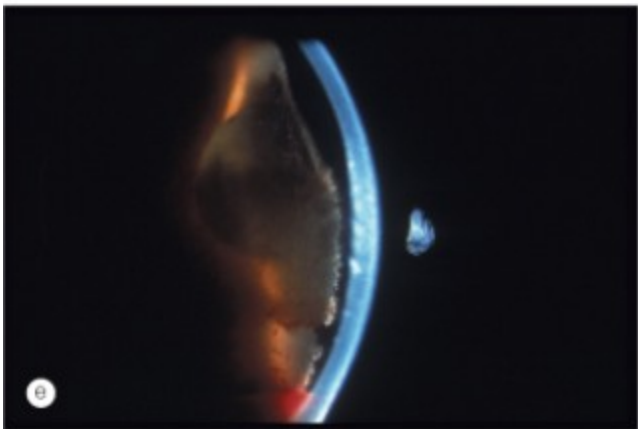
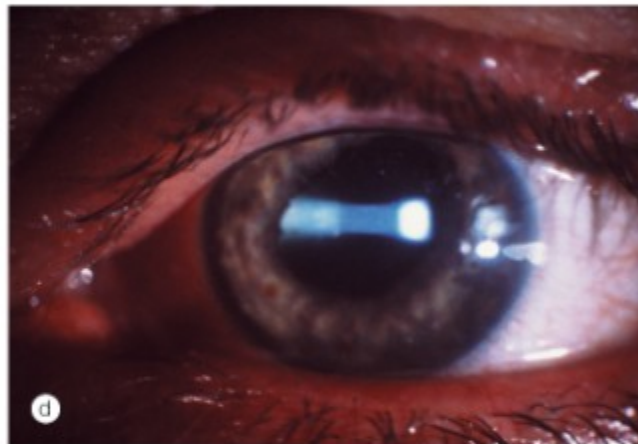
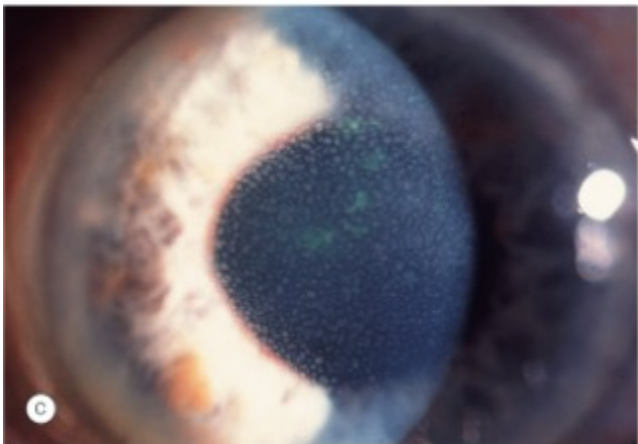
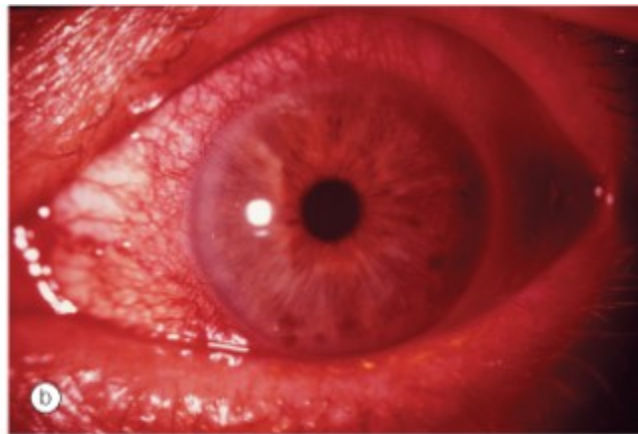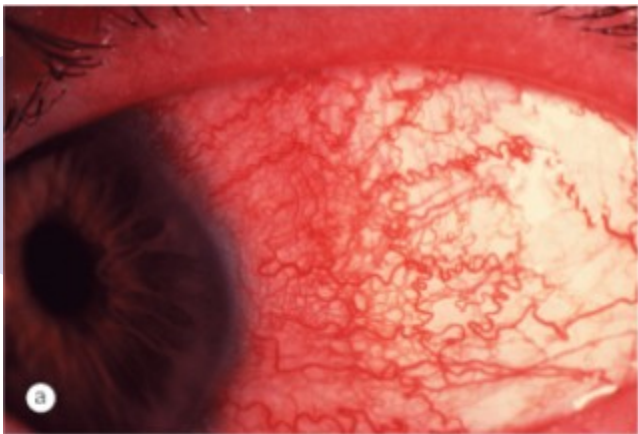


- **Anterior uveitis** may be subdivided into:
- Iritis in which the inflammation primarily involves the iris.
- Iridocyclitis in which both the iris and ciliary body are involved
- **Ciliary injection** - peripheral hyperemia of the anterior ciliary vessels which produces a deep red or rose color of the corneal stroma, and must be distinguished from hyperemia of the conjunctival vessels. May spread to the perilimbic corneal tissue. Called also ciliary flush.



Anterior uveitis

- **Ciliary (circumcorneal) injection**
- **Miosis** due to sphincter spasm **Endothelial dusting** by myriad of cells is present early and gives rise to a 'dirty' appearance
- **Aqueous cells**
- **Aqueous flare** reflects the presence of protein due to a breakdown of the blood-aqueous barrier
- **Aqueous fibrinous exudate**
- **Hypopyon**
- **Posterior synechiae** may develop quite quickly and must be broken down before they become permanent

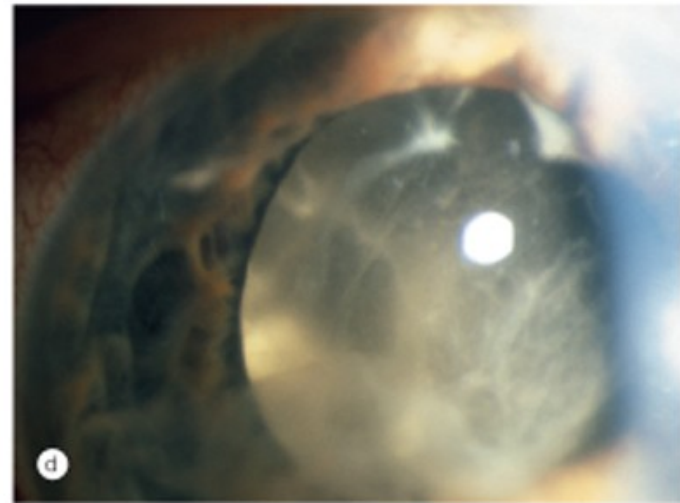
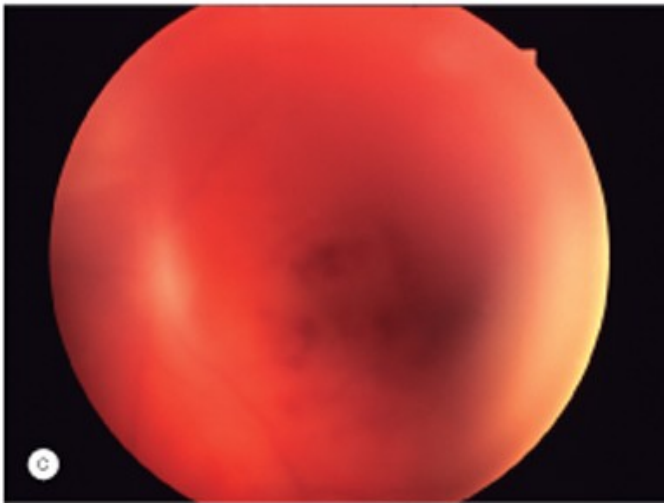
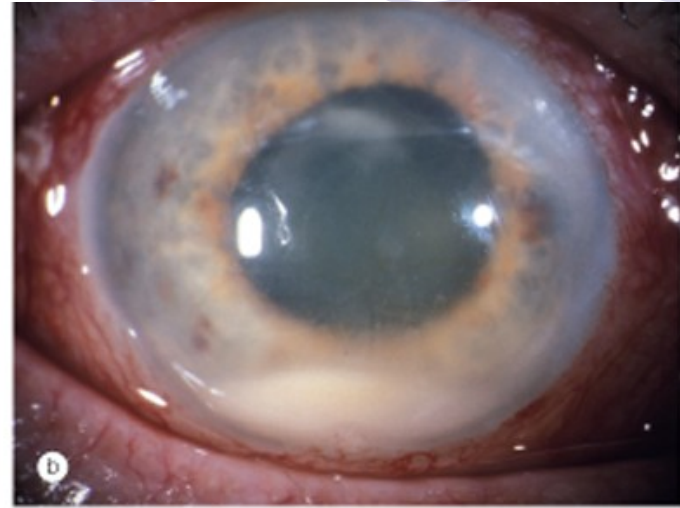
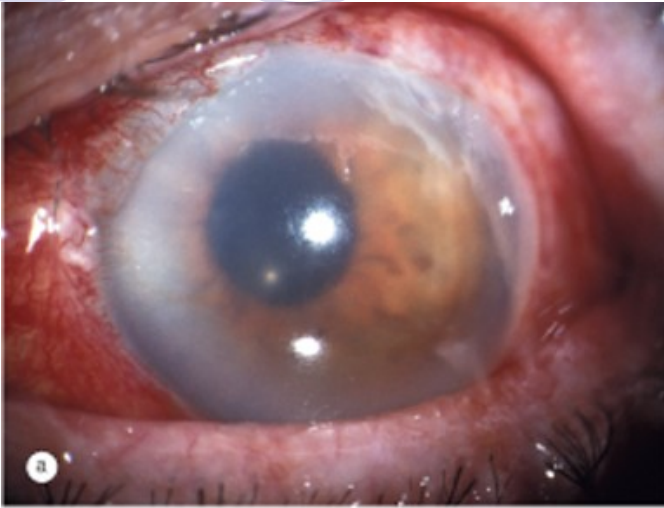


Acute endophthalmitis

- Acute inflammation of all ocular structure
- Endogenous or exogenous (surgery, trauma)
- Signs - chemosis, corneal injection, relative afferent pupil defect, corneal haze, fibrinous exudate and hypopyon, vitritis with impaired view of the fundus

Acute endophthalmitis



End !!!!

