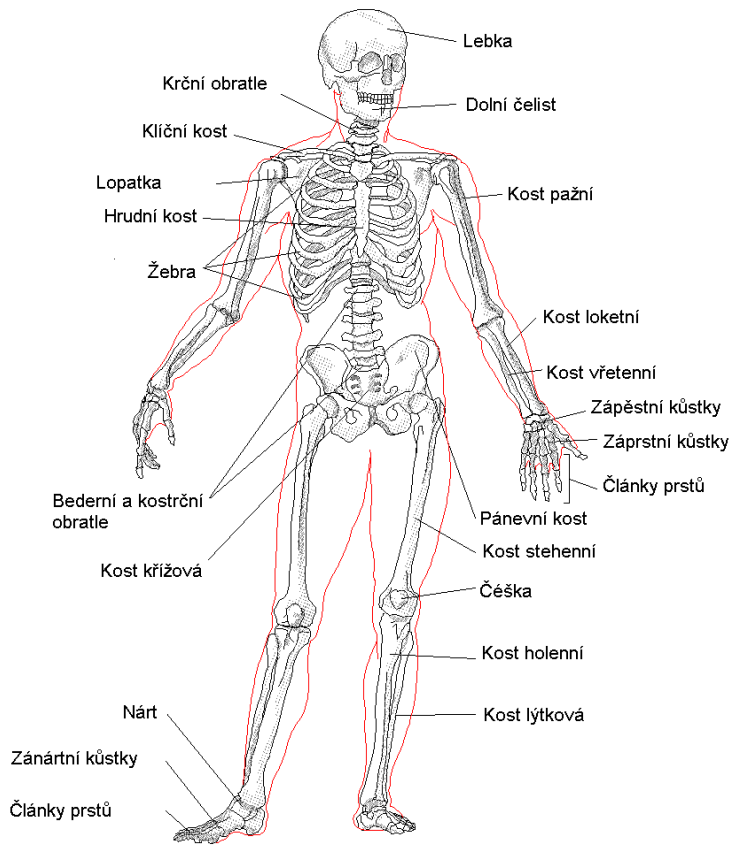
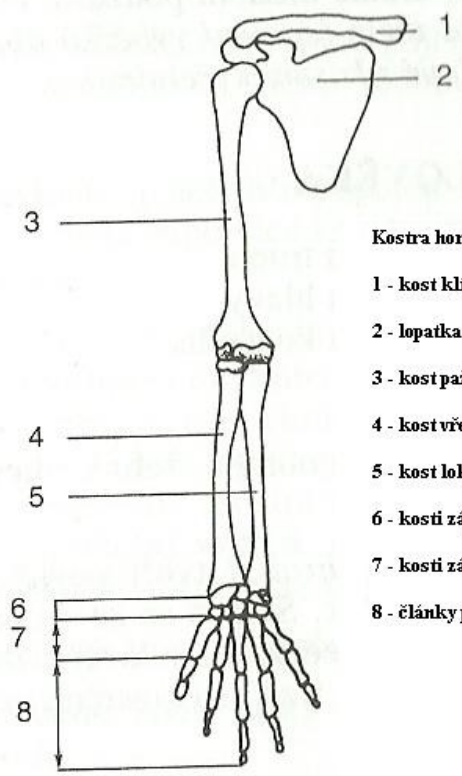


CZECH FOR FOREIGNERS III

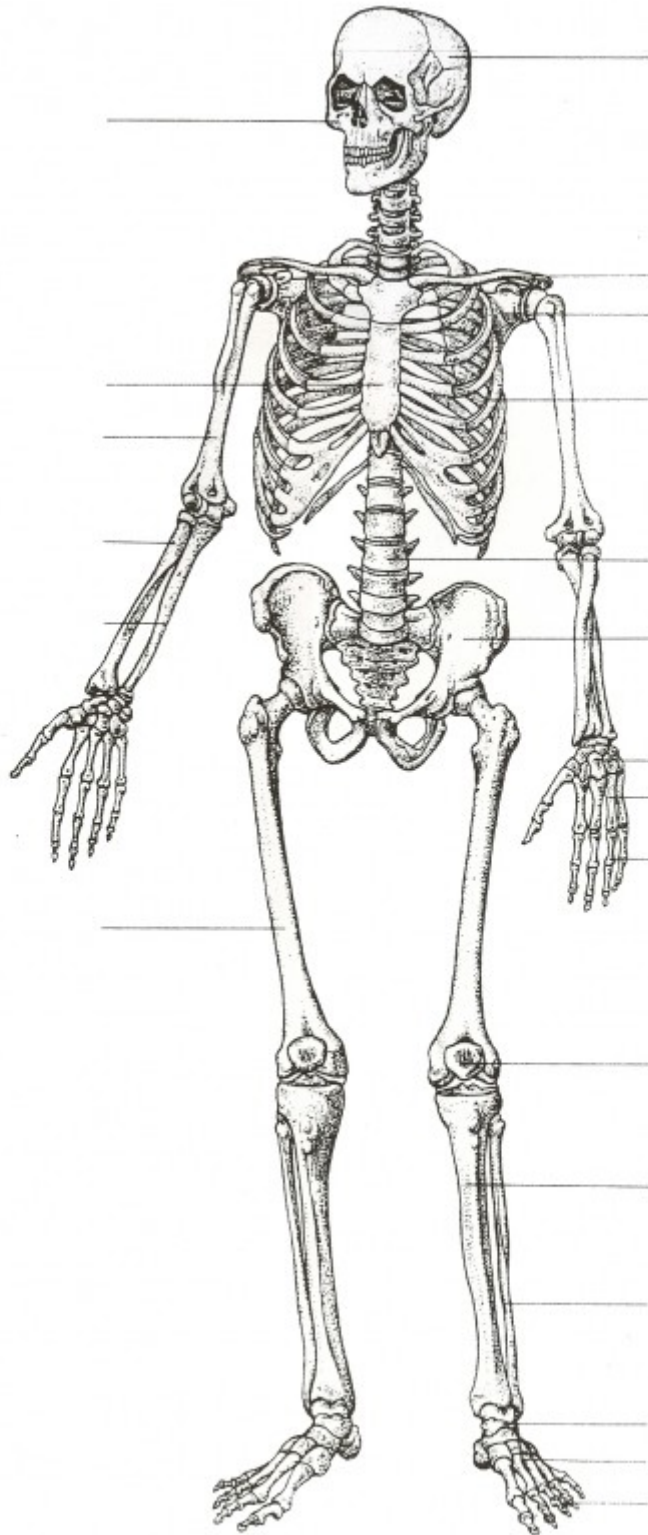
TALKING MEDICINE /LEKCE 1: LIDSKÉ TĚLO I





Kostra horní končetiny

- 1 - kost klíční (clavicula)
- 2 - lopatka (scapula)
- 3 - kost pažní (humerus)
- 4 - kost vřetenní (radius)
- 5 - kost loketní (ulna)
- 6 - kosti zápěstní (ossa carpi)
- 7 - kosti záprstní (ossa metacarpalia)
- 8 - články prstů (phalanges)



Translate into Czech.

skeleton		right elbow	
bone		pelvis	
join		hip joint	
tendon		collar bone/clavicula	

muscle		humerus	
cranium		cuboid bone/ulna	
vertebra		thigh bone/femur	
vertebral column		calf bone/fibula	
spinal cord		shin bone/tibia	

Translate into Czech.

blood		sense of sight	
vein		sense of hearing	
artery		sense of smell	
vessel		sense of touch	
valve		sense of taste	