

1st and 2nd Latin and Greek declension

Translate

- Musculi
- Musculus antebrachii
- Musculi antebrachii
- Musculi dorsi
- Musculi magni dorsi
- Musculus colli
- Musculi colli
- Musculi longi colli
- Musculus linguae
- Musculi linguae
- Musculi profundi linguae
- Musculi (bulbi) oculi
- Musculi recti et obliqui (bulbi) oculi
- Musculi coccygei et thoracici
- Musculi digitorum
- Musculi longi digitorum
- Ligamentum
- Ligamenta

Translate

- Ligamentum radiatum costae
- Ligamentum transversum carpi
- Ligamentum proprium ovarii
- Ligamentum latum uteri
- Ligamentum transversum scapulae
- Ligamentum venae cavae


Translate

- Collum anatomicum humeri
- Fractura colli anatomici humeri
- Cancer coli /intestini crassi
- Therapia chirurgica cancri coli/intestini crassi
- Fundus vesicae urinariae
- Anomalia congenita organi interni
- Anomaliae congenitae organorum internorum
- Organa accessoria bulbi oculi
- Nervus accessorius et vagus
- Nervi symphatici
- Digitus tertius/medius
- Tuberculum costae
- Tuberculum thyreoideum

Translate

- Morbus contagiosus
- Morbi contagiosi
- Periculum rupturae
- Signum morbi
- Signa morborum
- Signa morbi epidemici
- Morbus neonati
- Morbi neonatorum
- Morbi adulti
- Morbi adulatorum
- Morbi bronchorum
- Morbi oesophagi, ventriculi et jejuni
- Morbi novi et methodi novae therapiae

Can you recognize the anatomical object named after the object on the picture?



Form phrases from words in boxes

Ligamentum latum uteri

Fissura transversa cerebri

Membrana interossea
antebrachii

Anomalia congenita bulbi
oculi

Form phrases from words in boxes

Tunica mucosa vesicae
felleae

Lobus sinister
glandulae thyreoideae

Truncus nervi
accessorii

Plicae transversae recti

Form phrases from words in boxes

Collum vesicae felleae

Musculi transversi
dorsi

Apertura mediana
ventriculi quarti

Fissura congenita
palati duri

Fill in missing endings:

fossa vestibuli

ligamentum transversum scapulae

fractura palati clausa

nervus transversus colli

nodi lymphatici iliacii interni

fractura septi nasi

A) Fill in missing endings

B) Change into the plural

apertura extern a

ruptura ven ae cav ae

tunica mucos a

costa spuri a

costa liber a

nucleus rub er

bronchus sinist er

nasus extern us

aperturae externae

rupturae venarum cavarum

tunicae mucosae

costae spuriae

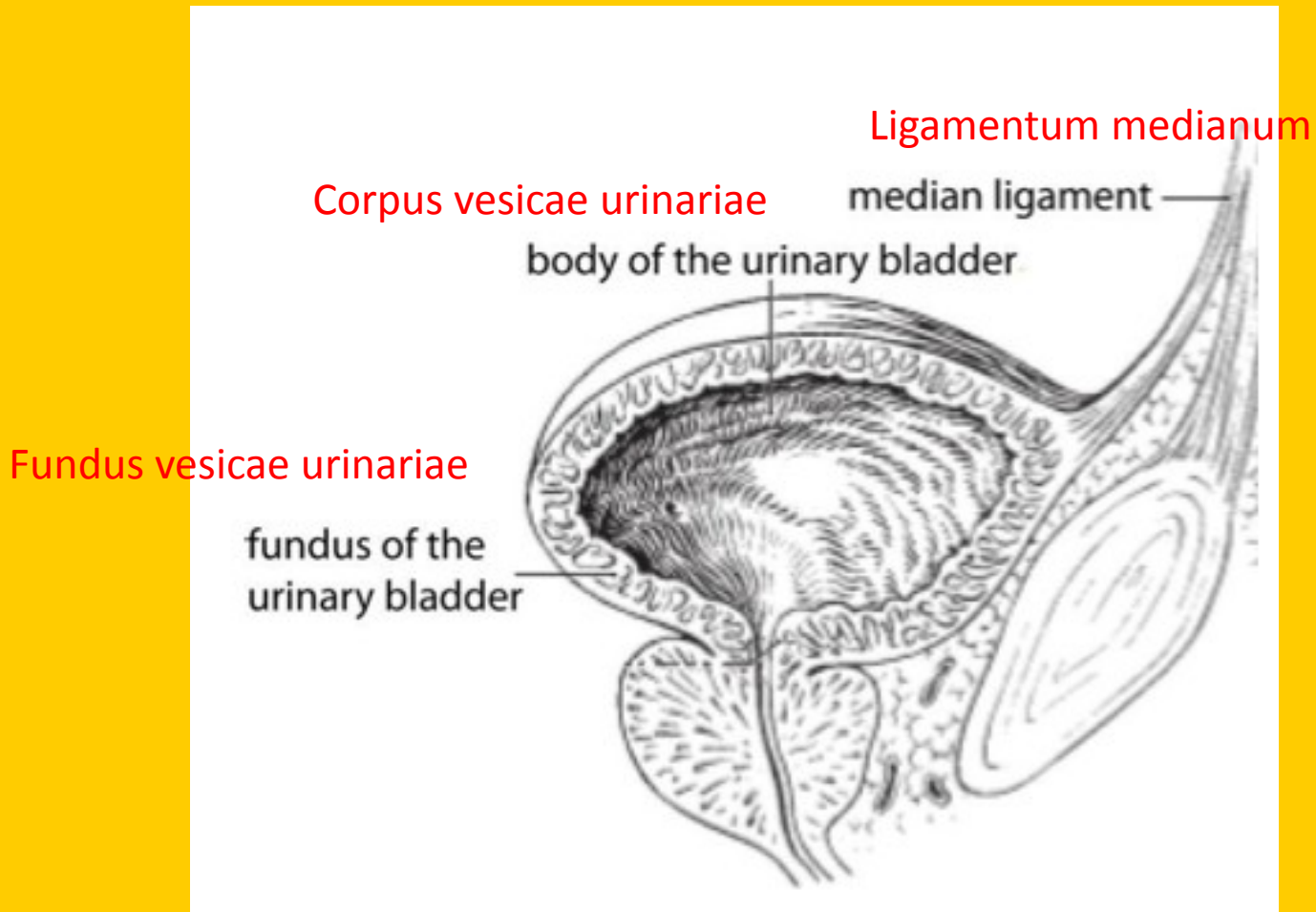
costae liberae

nuclei rubri

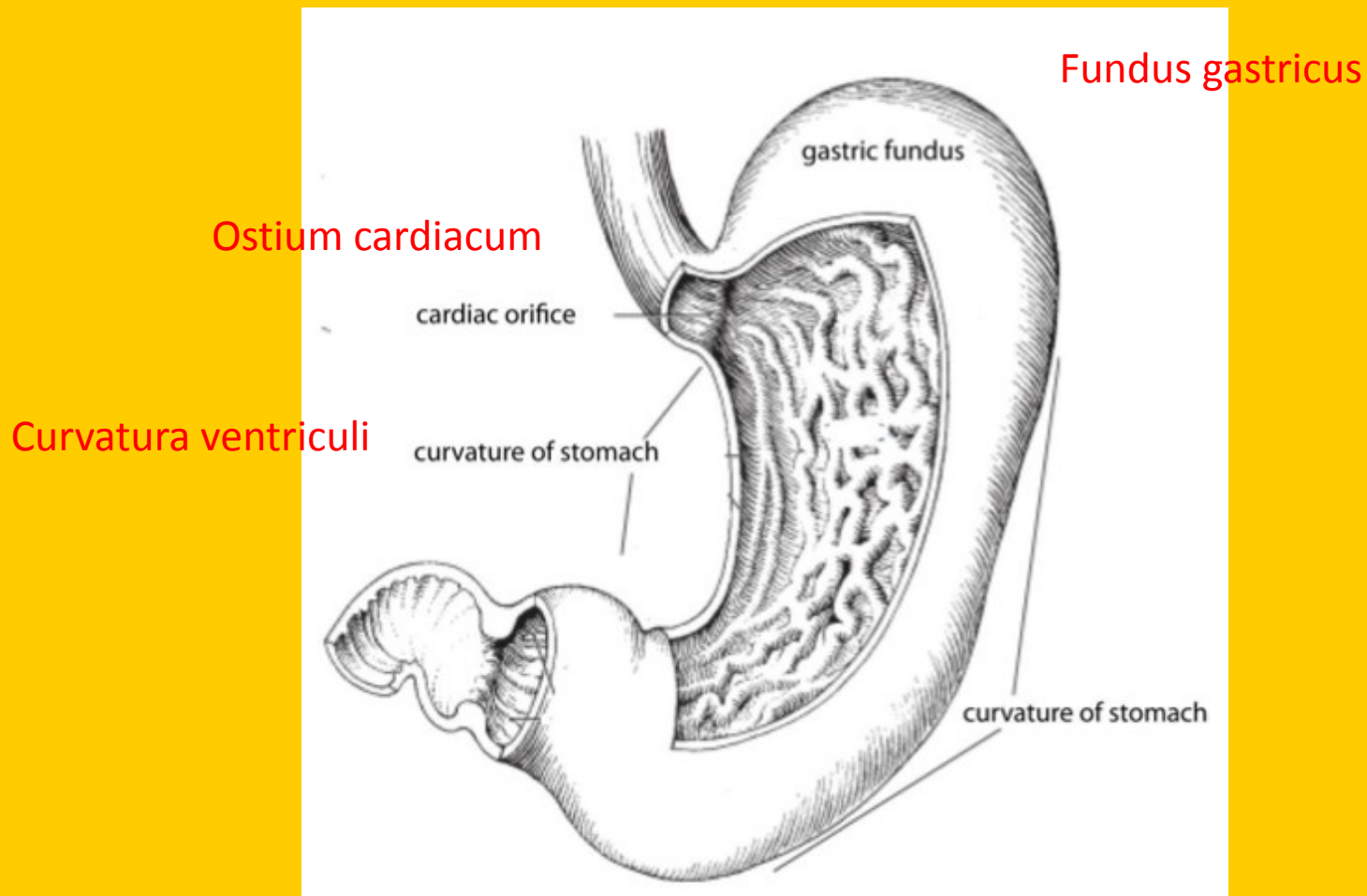
- / bronchi sinistri

- / nasi externi

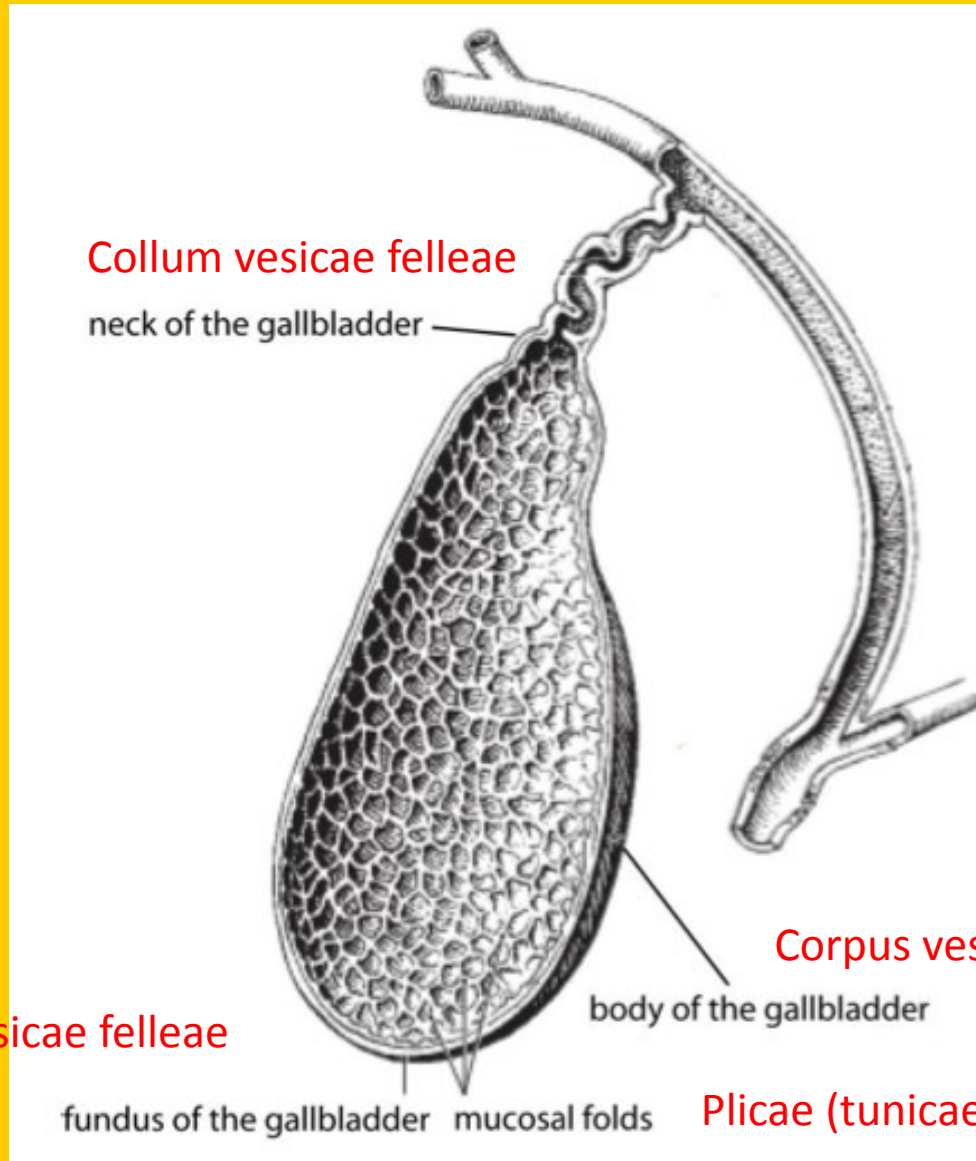
Translate the legend to the image:



Translate the legend to the image:



Translate the legend to the image:



Collum vesicae felleae

neck of the gallbladder

Corpus vesicae felleae

body of the gallbladder

Fundus vesicae felleae

fundus of the gallbladder

mucosal folds

Plicae (tunicae) mucosae