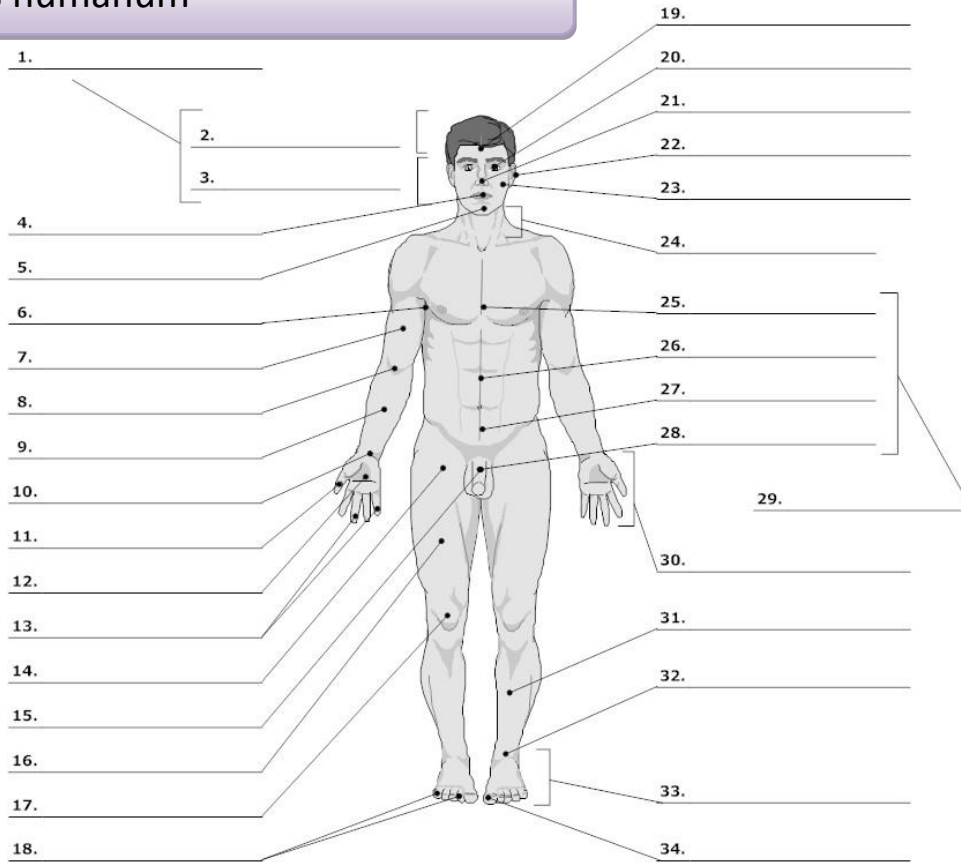


PART I : EXERCISES/VOCABULARY

Corpus humanum

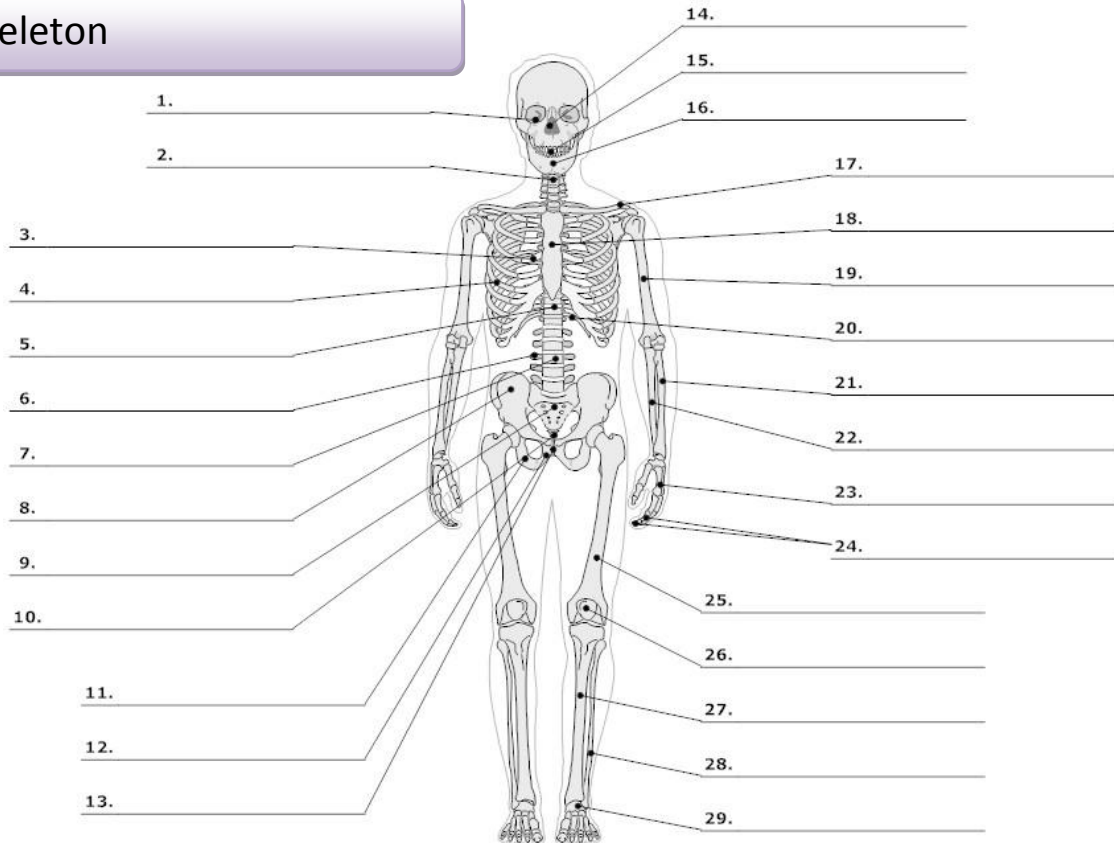


LIFEART Collection Images Copyright © 1999-2001. By Lippincott Williams & Wilkins, Baltimore, MD

- | | | | |
|--|---------------------|---|--|
| 0. corpus, oris, n.
cutis, is, f. | body
skin | 16. femur, oris, n. | thigh, femur |
| 1. caput, itis, n. | head | 17. genu, us, n. | knee |
| 2. capilli, orum, m. | hair | 19. frons, frontis, f. | forehead |
| 3. facies, ei, f. | face | 20. oculus, i, m. | eye |
| 4. os, oris, n.
lingua, ae, f. | mouth
tongue | 21. nasus, i, m. | nose |
| 5. mentum, i, n. | chin | 22. auris, is, f. | ear |
| 6. axilla, ae, f. | armpit, axilla | 23. bucca, ae, f. | cheek |
| 7. brachium, ii, n. | upper arm, brachium | 24. collum, i, n.
cervix, icis, f. | neck (mainly on bones)
neck, cervix (mainly on soft parts/organs) |
| 8. cubitus, i, m. | elbow | 25. pectus, oris, n. | chest |
| 9. antebrachium, ii, n. | forearm | 26. abdomen, inis, n. | belly, abdomen |
| 10. carpus, i, m. | wrist | 27. hypogastrium, ii, n. | hypogastrium |
| 11. pollex, icis, m. | thumb | 29. truncus, i, m. | trunk |
| 12. palma, ae, f. | palm (of the hand) | 30. manus, us, f. | hand |
| 13.,18. digitus, i, m. | finger | 31. crus, cruris, n. | lower leg, shank |
| 14. sulcus, i, m. ¹ | fold, groove | 32. tarsus, i, m.
talus, i, m. | tarsus
anklebone, talus |
| 15.,28. penis, is m. | penis | 33. pes, pedis, m. | foot |
| | | 34. hallux, ucis, m. | big toe |

¹ sulcus glutealis

Skeleton



LifeART Collection Images Copyright © 1989-2001 by Lippincott Williams & Wilkins, Baltimore, MD

- | | | | |
|--|--|--------------------------------------|-----------------------------------|
| 0. skeleton, i, n. | skeleton | scapula, ae, f. | shoulder blade, scapula |
| os, ossis, n. | bone | 18. sternum, i, n. | breastbone, sternum |
| cranium, ii, n. | skull | 19. humerus, i, m. | arm bone, humerus |
| 1. orbita, ae, f. | orbit | 20. arcus, us, m.² | arch |
| 2. collum, i, n. | neck (mainly on bones) | 21. radius, ii, m. | radial bone, radius |
| cervix, icis, f. | neck, cervix (mainly on soft parts/organs) | 22. ulna, ae, f. | elbow bone |
| 3. thorax, acis, m. | thorax (chest with ribs) | 23. metacarpus, i, m. | metacarpus |
| 4. costa, ae, f. | rib | carpus, i, m. | wrist |
| 5. discus, i, m. | disc | 24. phalanx, gis, f. | one of the finger bones, phalange |
| 6. processus, us, m. | process (an outgrowth of tissue) | 25. femur, oris, n. | thighbone, femur |
| 7. vertebra, ae, f. | vertebra | 26. patella, ae, f. | kneecap, patella |
| 8. pelvis, is, f. | pelvis | 27. tibia, ae, f. | shinbone, tibia |
| coxa, ae, f. | hip, hip joint | 28. fibula, ae, f. | calf bone, fibula |
| os ilii (ilia, ilium, n.) | ilium | 29. metatarsus, i, m. | metatarsus |
| 9. os sacrum (sacer, a, um) | sacral bone | | |
| 10. coccyx, gis, f. | tailbone, coccyx | | |
| 11. os ischii (ischium, ii, n.) | ischium | | |
| 12. os pubis (pubes, is, f.) | pubis | | |
| 13. symphysis, is, f. | symphysis | | |
| 14. nasus, i, m. | nose | | |
| 15. dens, dentis, m. | tooth | | |
| 16. mandibula, ae, f. | jawbone | | |
| 17. clavicula, ae, f. | collarbone, clavicle | | |

² arcus costalis

