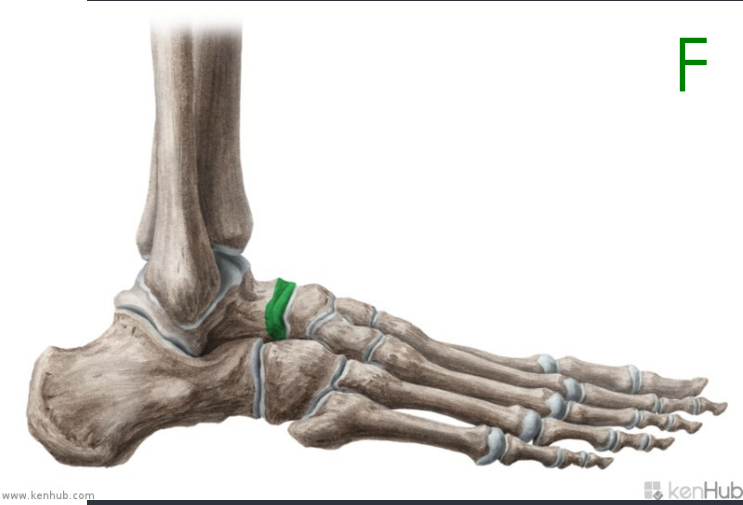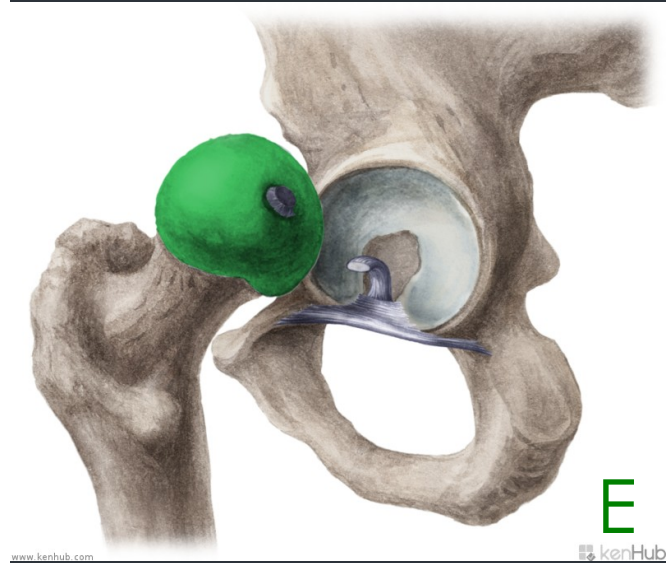
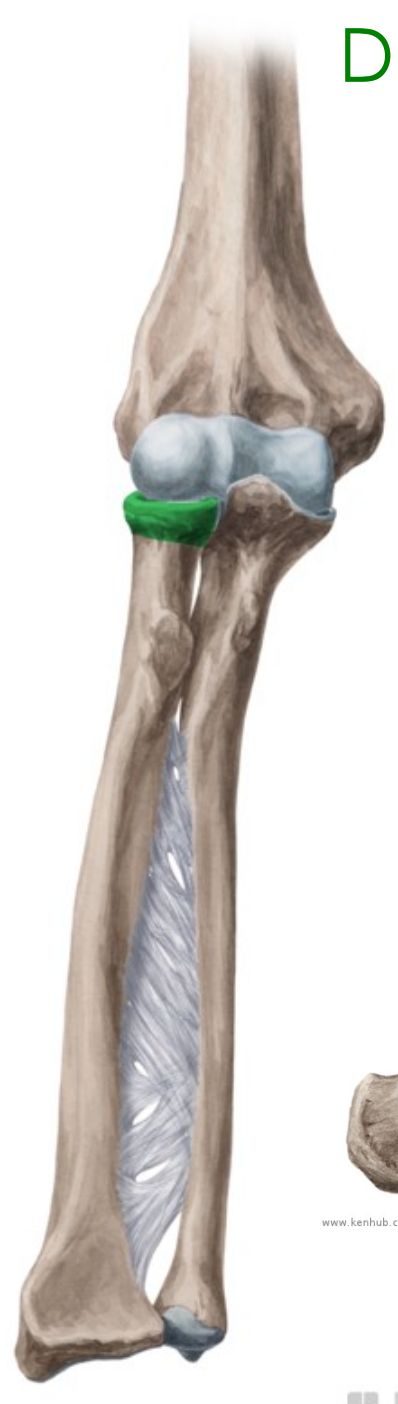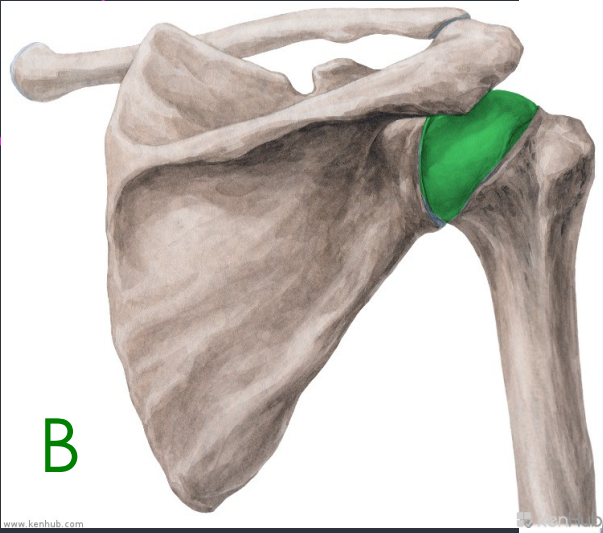
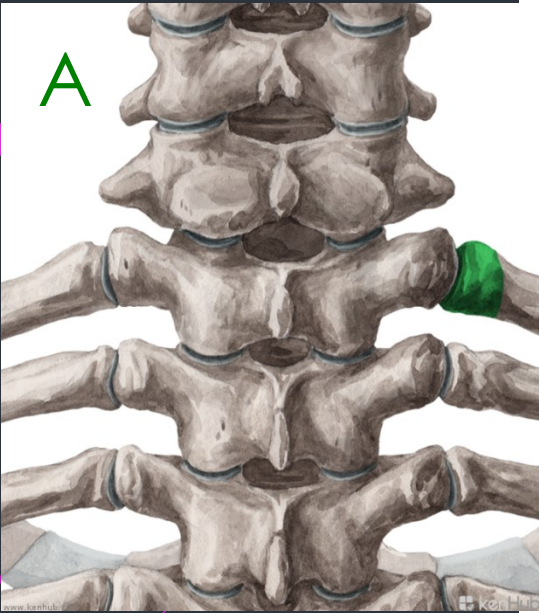
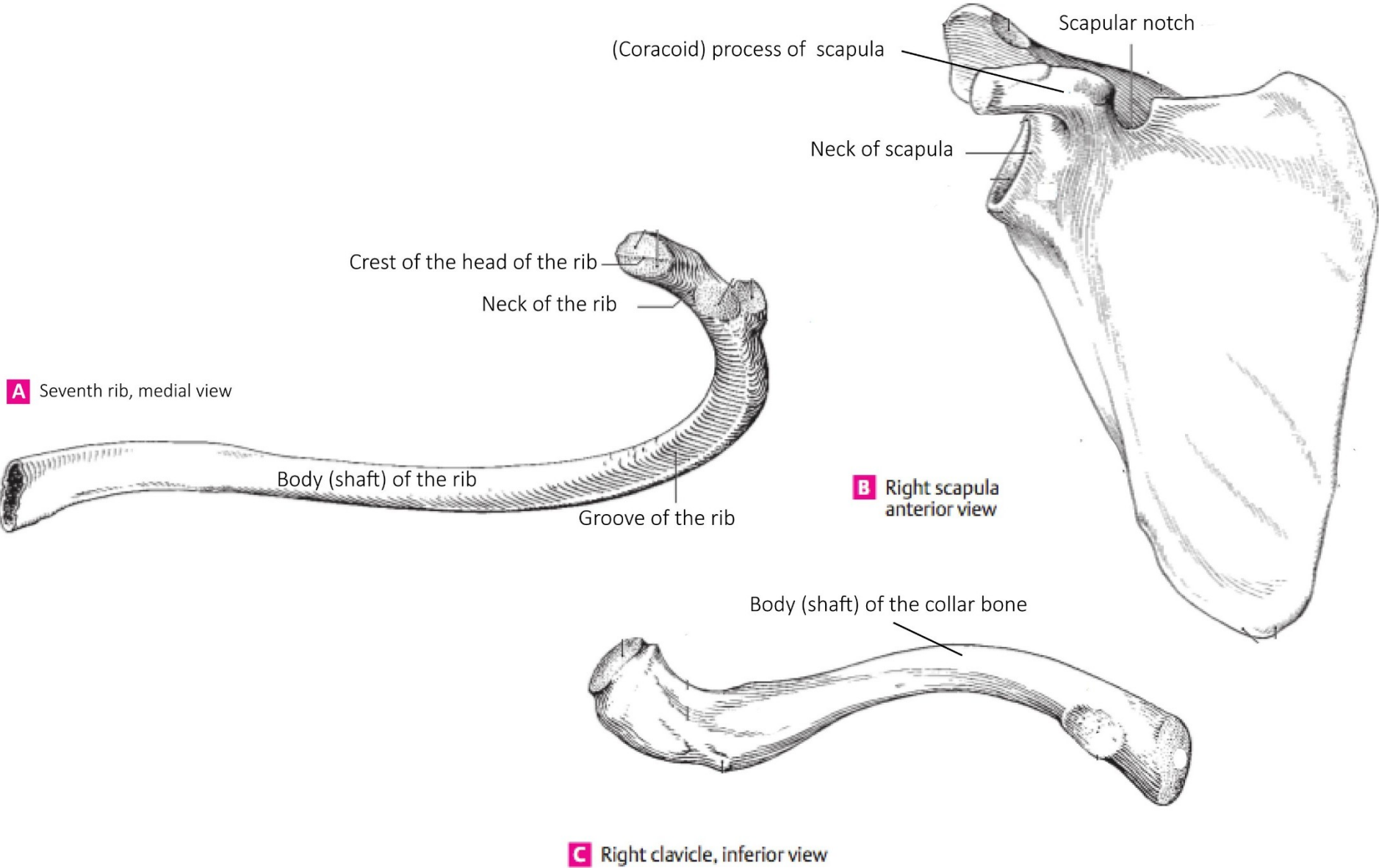




Questions

- ▶ **What case expresses the state of dependency?**
- ▶ **How is it usually translated into English?**
- ▶ **What cases are used with prepositions in medical terminology?**
- ▶ **Are there any prepositions connected with two cases?**
- ▶ **Which prepositions are connected with the ablative case?**





Adjectives of the 1st and 2nd declension, dictionary entry

Magnus, a, um

Magnus magna magnum

m.

f.

n.

coxa

oculus

crus

bucca

fibula

cervix

sulcus

arcus

metatarsus

hallux

Dexter, a, um

Dexter dextra dextrum

m.

f.

n.

(* liber, libera, liberum)

coxa

oculus

crus

bucca

fibula

cervix

sulcus

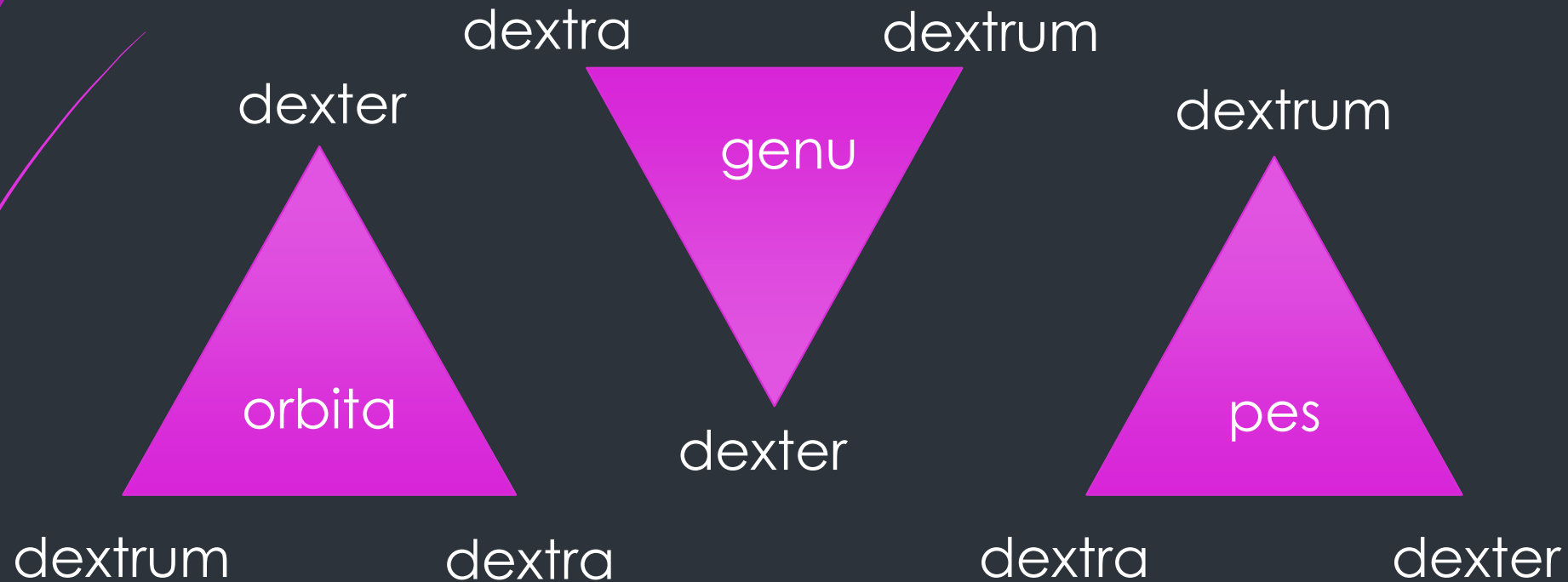
arcus

metatarsus

hallux

Agreed-attribute

What is the correct adjective for the noun in the triangle?



Za správnosť

M. Jozef

Lekárska správa - nález

Označenie zdrav. zariadenia, odd., pracovisko

pre

Priezvisko a meno

Kurdišovič Igor

rok nar.

Klin. dg

vykonané v

Dnes asi o 19.30 pri služobnom zákopu
kosti vpravo, na okolnosti spomína, v bezv
I.č. v ÚVTOS.

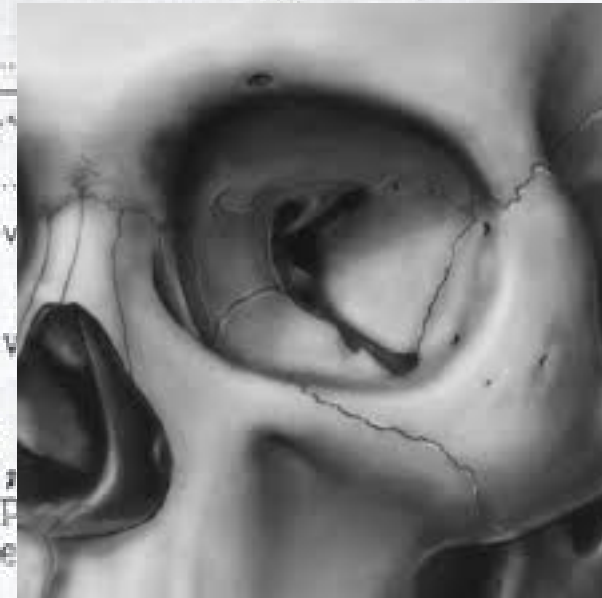
Vyš: RFG, OPG, PND, Clementschitch - bez
e.o. hematóm v obl. jarmovej kosti vpravo,
opuch v obl. jarmovej kosti vpravo táto nep
bilat. bez scjodika, vizus orient. v norme
zachovalá

i.o. otváranie úst bez obmedz., sliz. EPN, skelet pevný, záryz v nor

Dg: Contusio faciei l.dx. reg. ossis zygomat.
Haematoma faciei l.dx. reg. ossis et arc. zygo at.
Ih: ine, len vyšetrenie.

Udp: Chladiť, analgetiká p.p. Vhodné v ÚVTOS predpisať Augmentin 625mg
p.o. á 8- hod.

KO: V prípade ťažkostí ihneď



Contusio faciei l.dx. reg. ossis zygomat.

Contusio faciei lateris dextri regionis ossis zygomatici

Haematoma faciei l. dx. reg. ossis et arc. zygomat.

Haematoma faciei lateris dextri regionis ossis et arcus

zygomatici