

**Mikrobiologický ústav LF MU Brno**

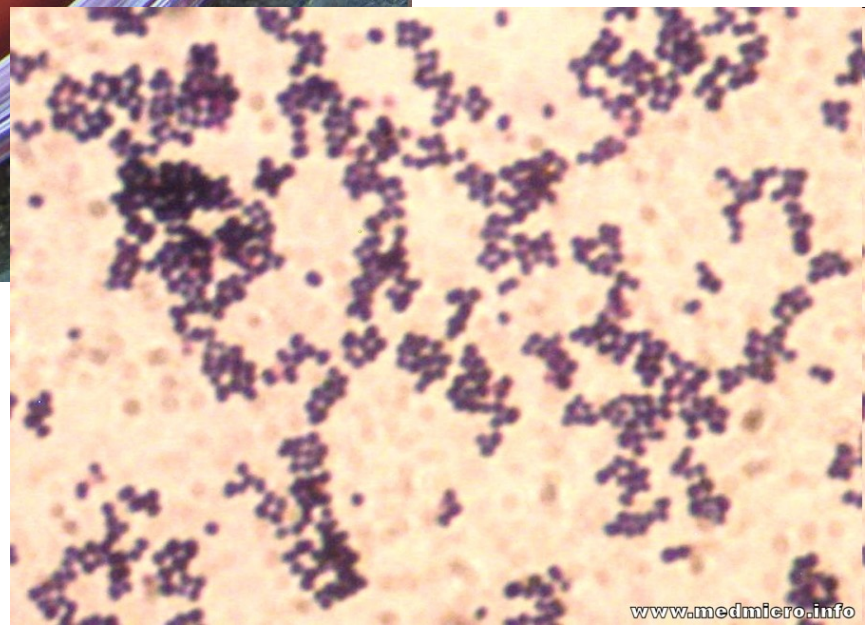
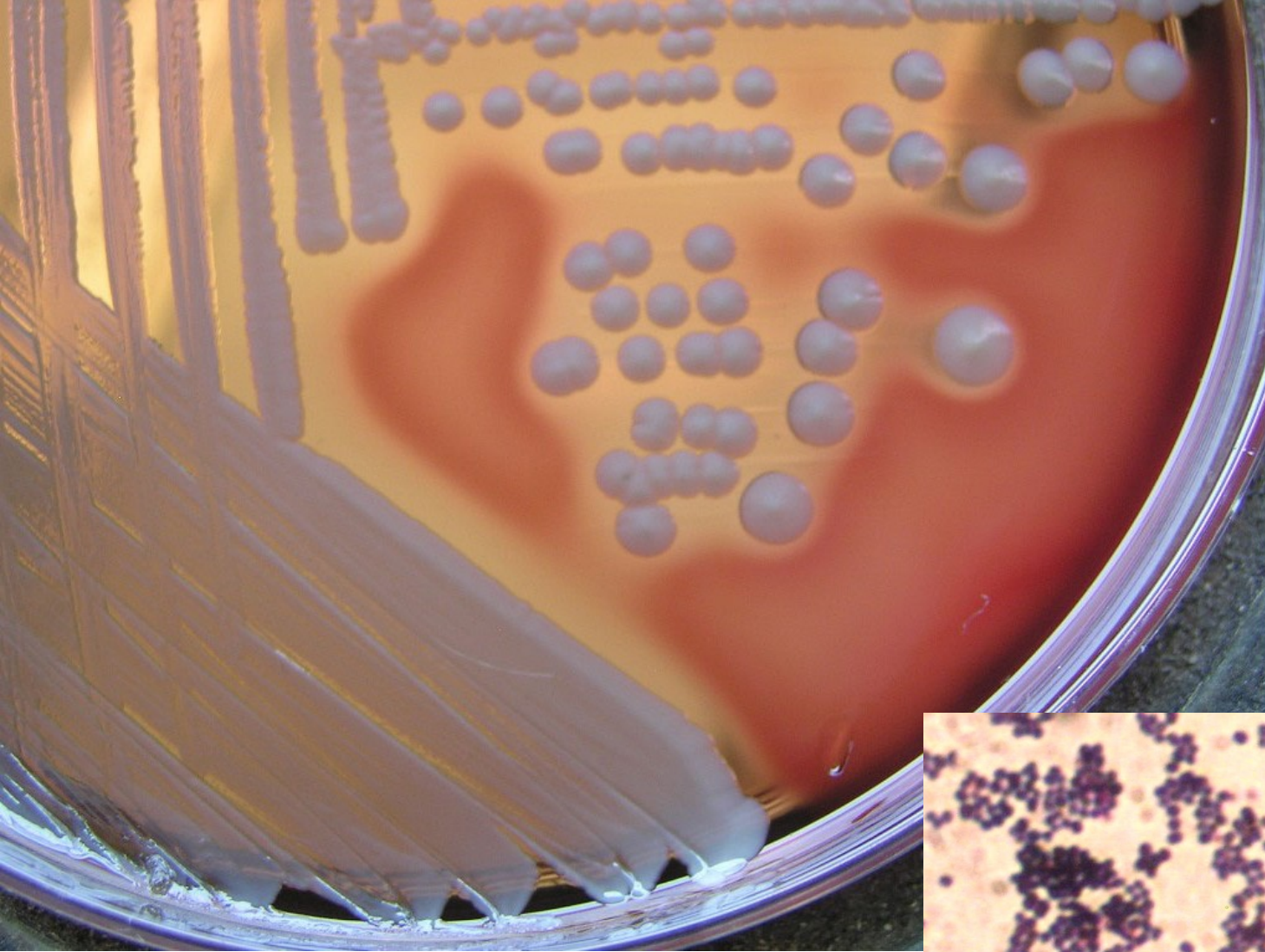
# **Infekce ran**

# Typy ran

- **povrchové**
- **zhmožděné**
- **vzniklé ve vodě**
- **vzniklé v tropech**
- **chirurgické**
- **popáleniny**
- **pokousání**

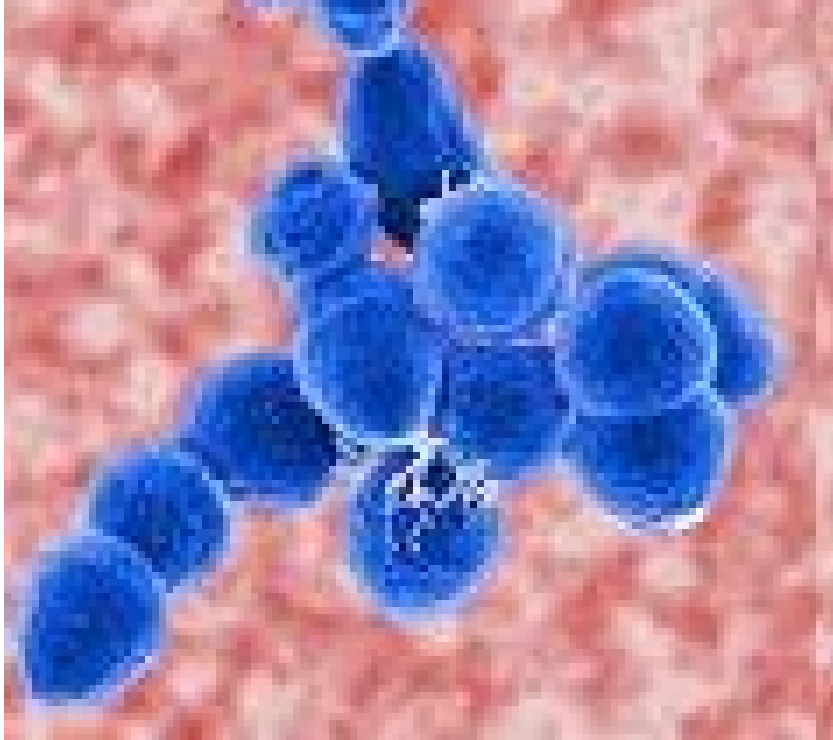
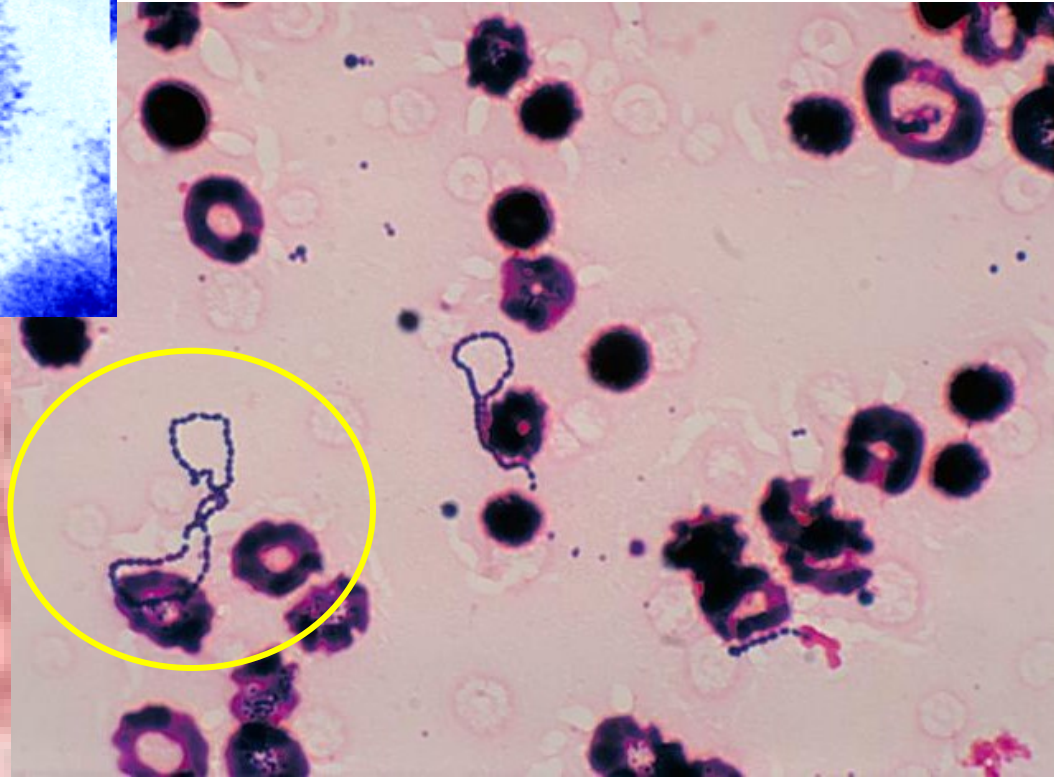
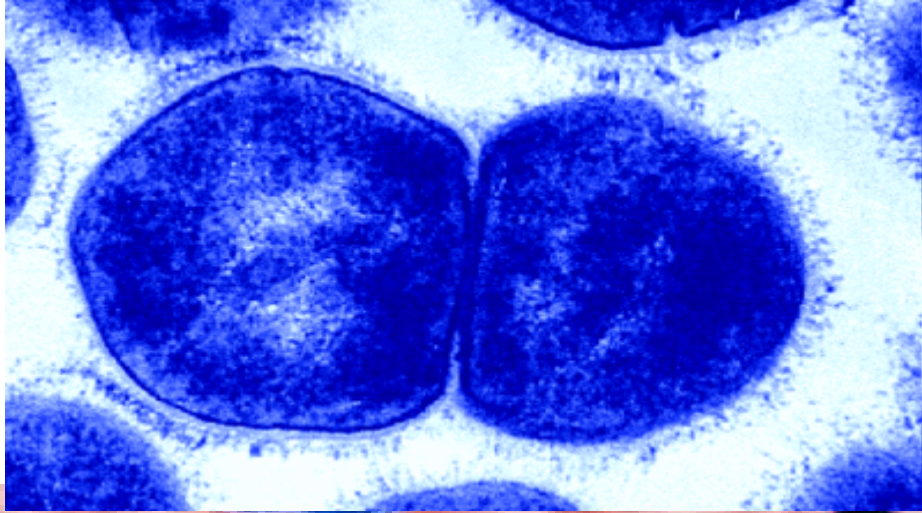
# Povrchová poranění

- *Staphylococcus aureus*
  - *Streptococcus pyogenes*
  - beta-hemolytické streptokoky (G, F, C)
- ! cizí těleso (tříska), hluboká rána (vidle znečištěné hnojem): *Clostridium tetani***



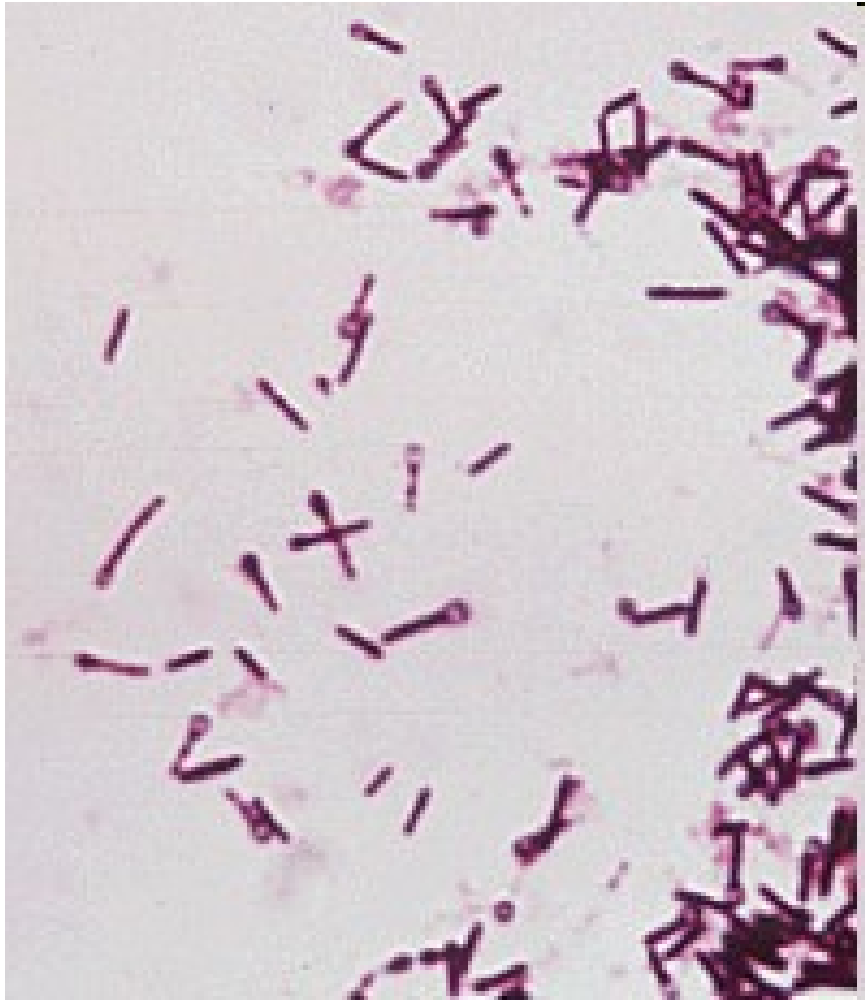**STAFYLOKOKY**

# STREPTOKOKY

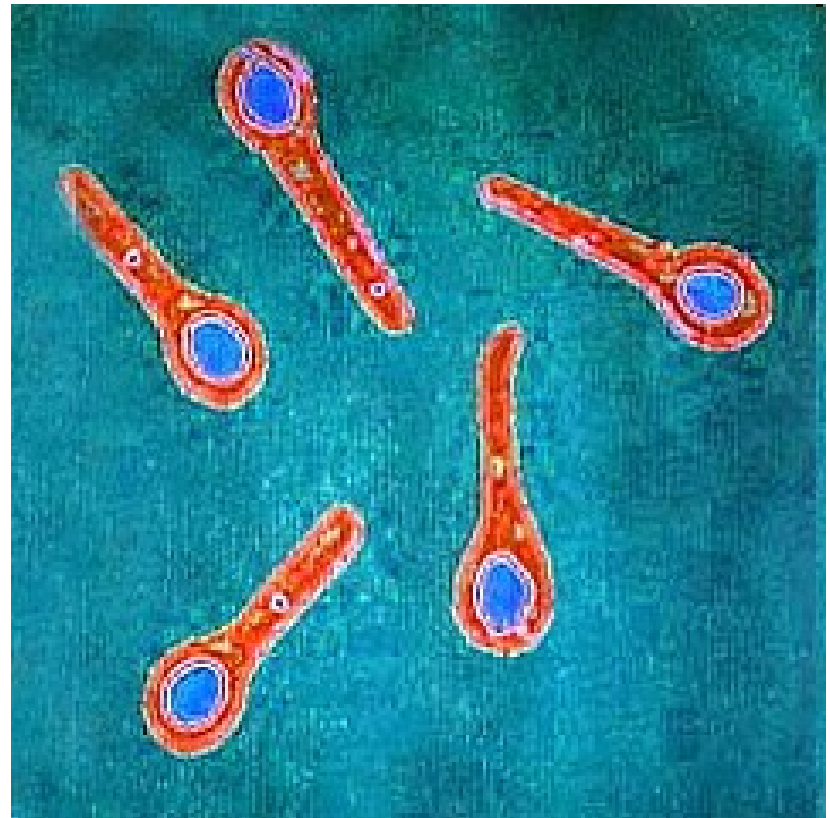


Left: [microbewiki.kenyon.edu](http://microbewiki.kenyon.edu).

Below: <http://upload.wikimedia.org>



## CLOSTRIDIUM TETANI



[microbiologybytes.wordpress.com/](http://microbiologybytes.wordpress.com/)

***Sir Charles Bell's portrait of a soldier dying of tetanus.***

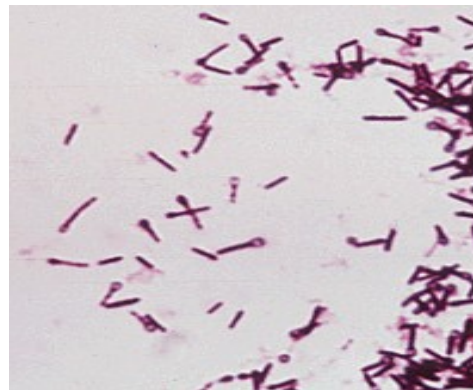
The characteristic **rigidity of the body** is referred to as **opisthotonus** and **risus sardonicus**.

(Original in the Royal College of Surgeons of Edinburgh, Scotland)

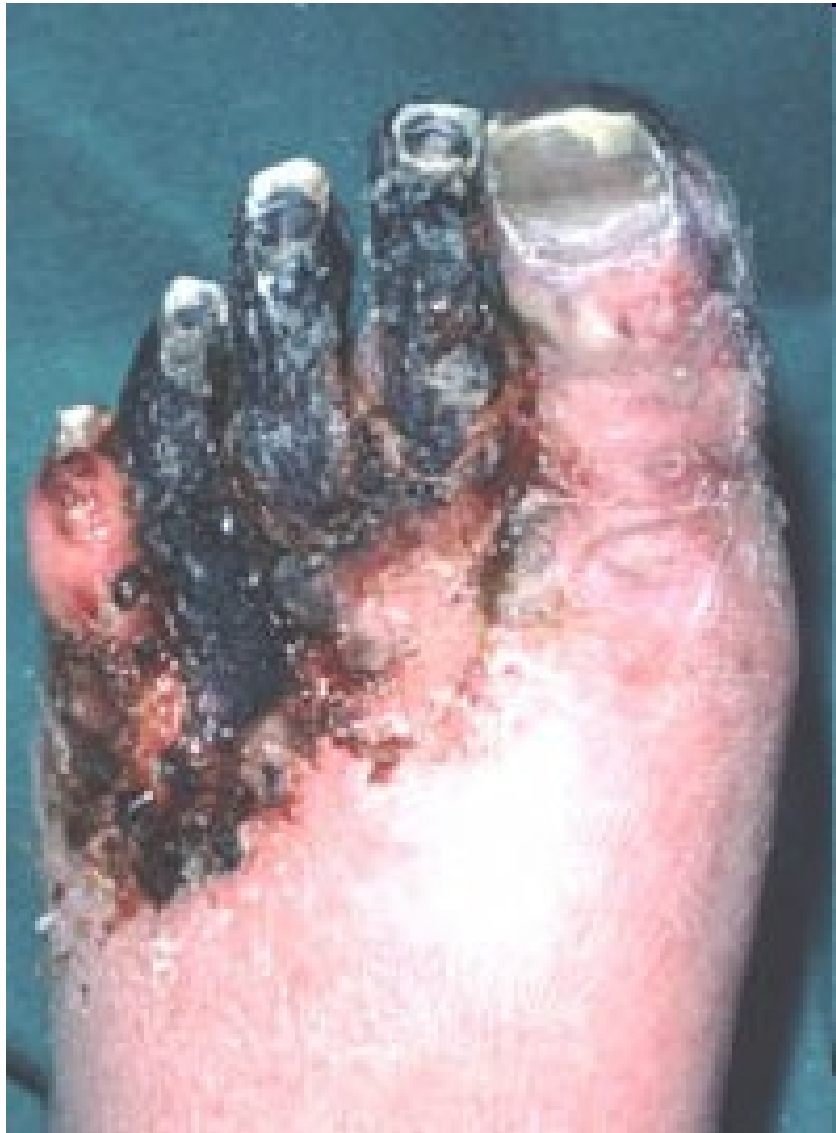

# Zhmožděné rány

- **Původci klostridiové myonekrózy**  
(*Clostridium perfringens*, *C. septicum*,  
*C. novyi*, *C. histolyticum*)  
= anaerobní traumatóza = plynatá sněť
- ***Clostridium tetani***







<http://www.thewoundcarecenter.com>

# Rány vzniklé ve vodě

- Sladkovodní:

*Pseudomonas aeruginosa*

*Aeromonas hydrophila*

- Slané:

*Vibrio parahaemolyticus, V. vulnificus*

*Mycobacterium marinum* (bazény, akvária)

# Rány v tropech

- **půdní nokardie**

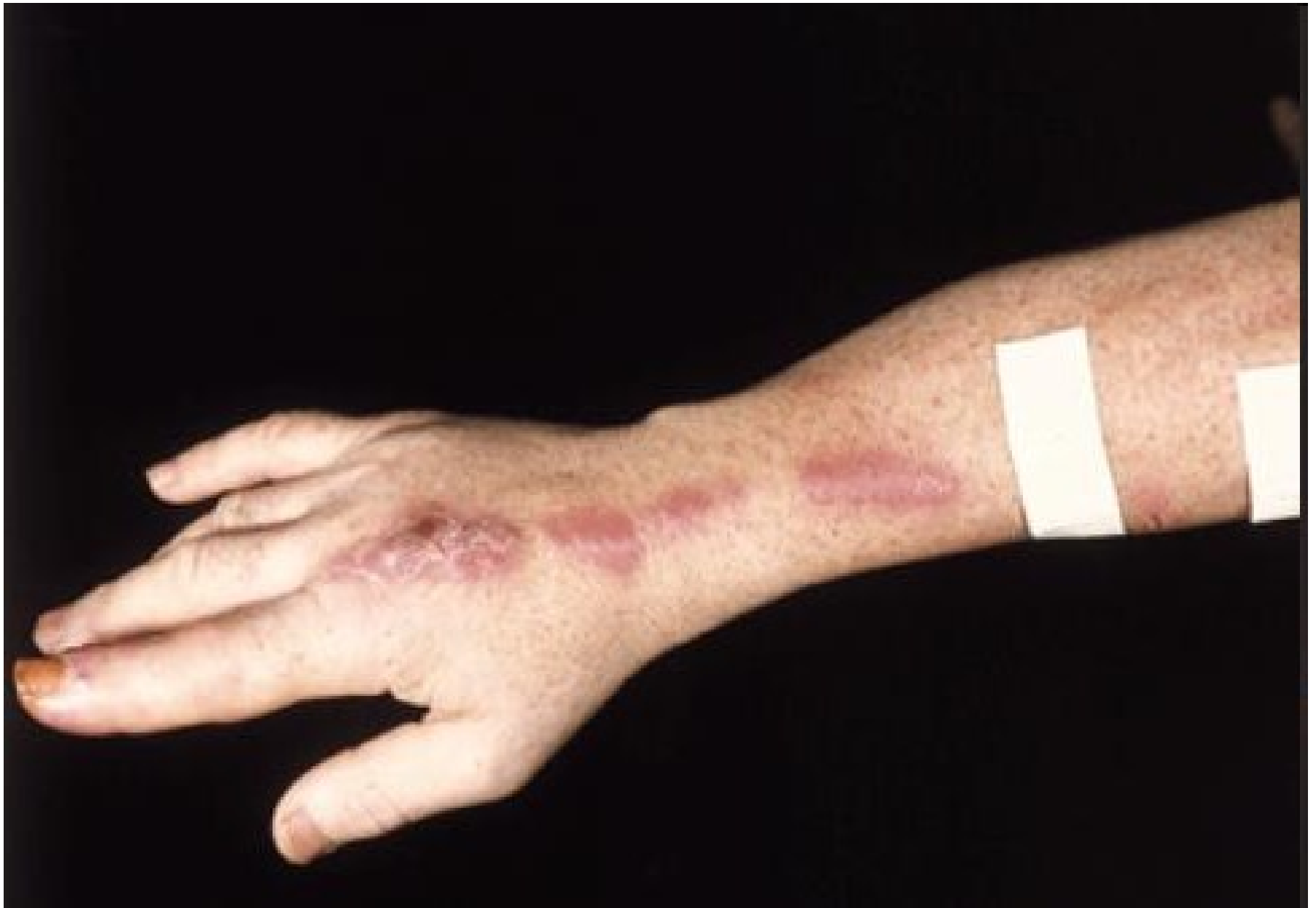*Dermatophilus congolensis, Rhodococcus equi*

- **atypická mykobakteria**

*Mycobacterium ulcerans, Mycobacterium haemophilum)*

- **micromycety**

*Sporothrix schenckii, Paracoccidioides brasiliensis*

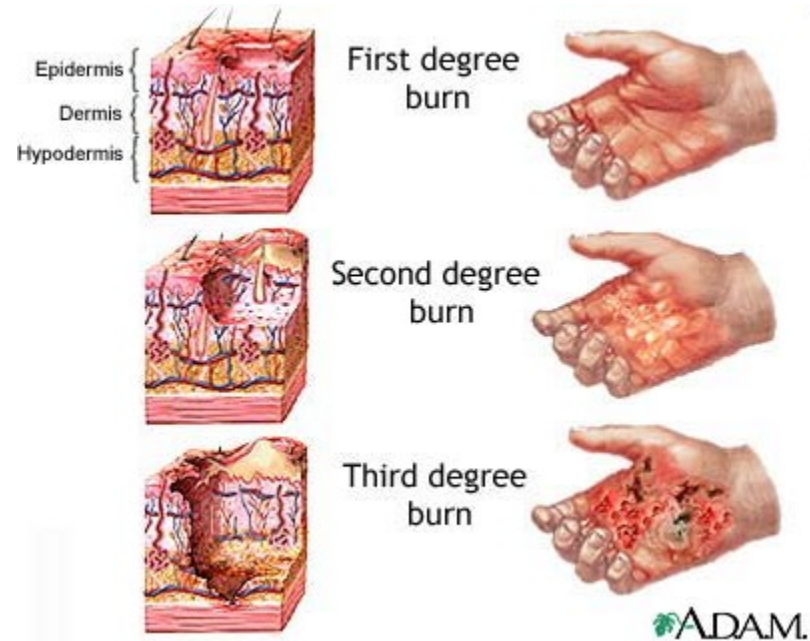


# Chirurgické rány

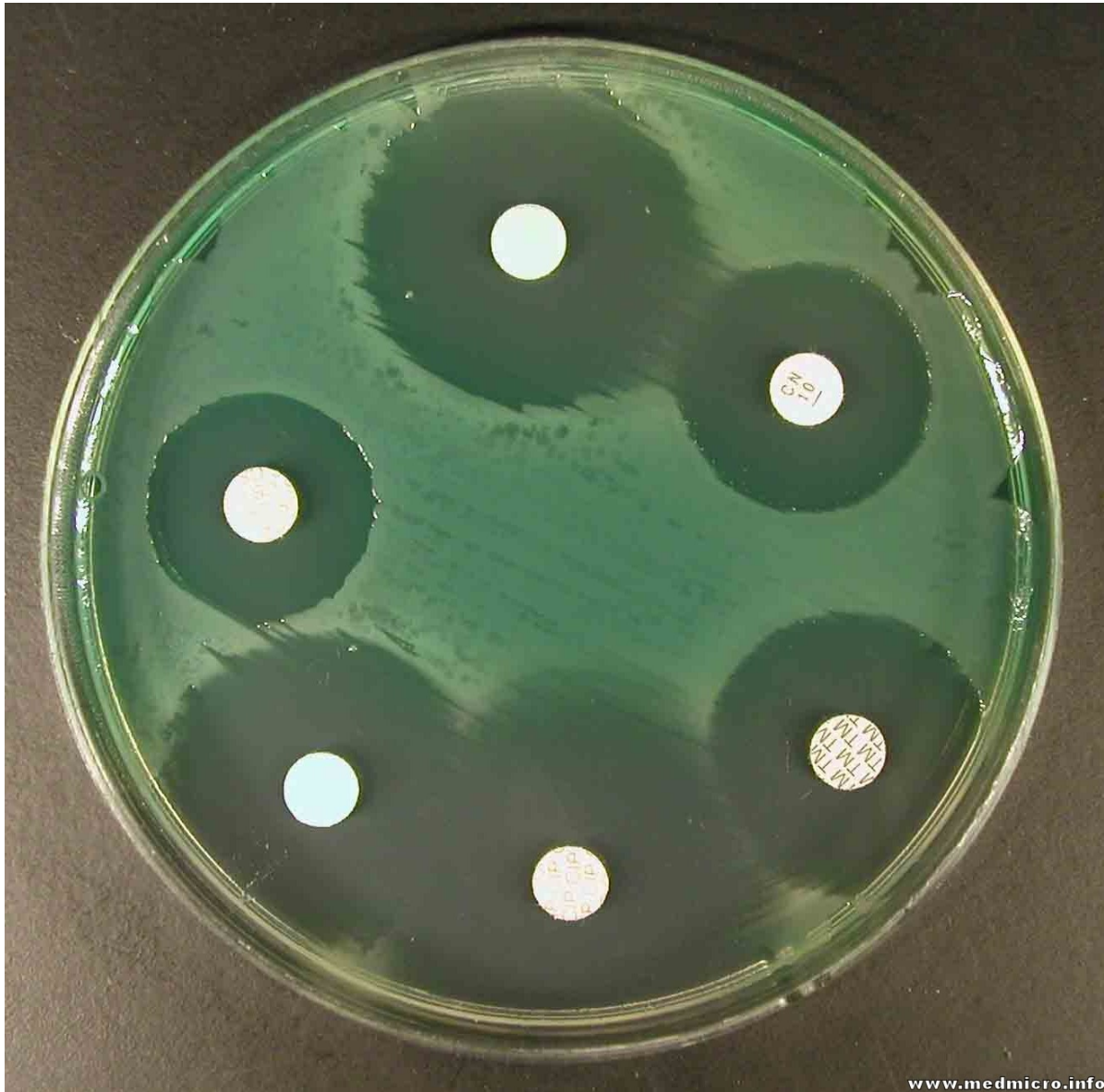
- *Staphylococcus aureus*
- *S. epidermidis*
- **Enterobacteriaceae** (*E. coli*, *P. mirabilis*)
- *Streptococcus pyogenes*
- anaeroby

# Popáleniny

- *Pseudomonas aeruginosa*
- *Staphylococcus aureus*
- *Streptococcus pyogenes*
- enterokoky
- kvasinky, aspergilus



# **P. AERUGINOSA**



# Rány kousnutím

## Orální flóra

- „ústní streptokoky“ (*Streptococcus sanguinis*, *S. oralis*, *S. anginosus*)
- anaeroby (*Fusobacterium nucleatum* ssp. *nucleatum*, *Porphyromonas gingivalis*)

***Staphylococcus aureus***



# Pokousání zvířetem

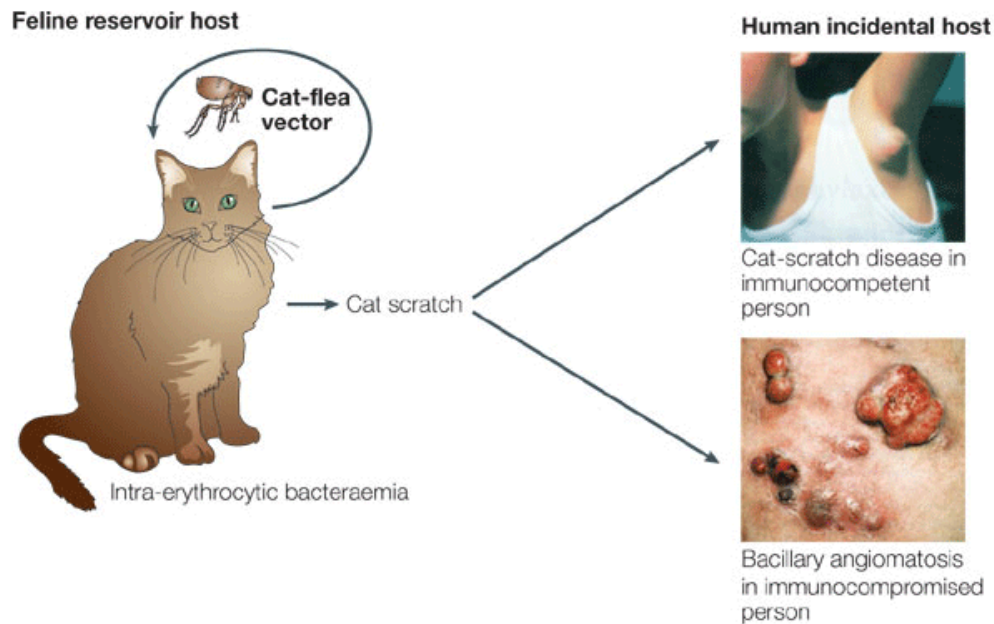
- *Pasteurella multocida* (psi, kočky)
- *Staphylococcus aureus*
- *Capnocytophaga canimorsus* (pes)
- *Streptobacillus moniliformis* (krysa)
- *Spirillum minus*  
(myš, krysa, pes, kočka)

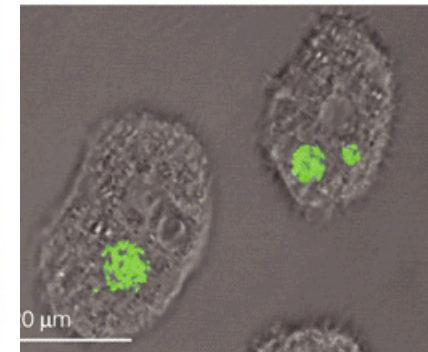
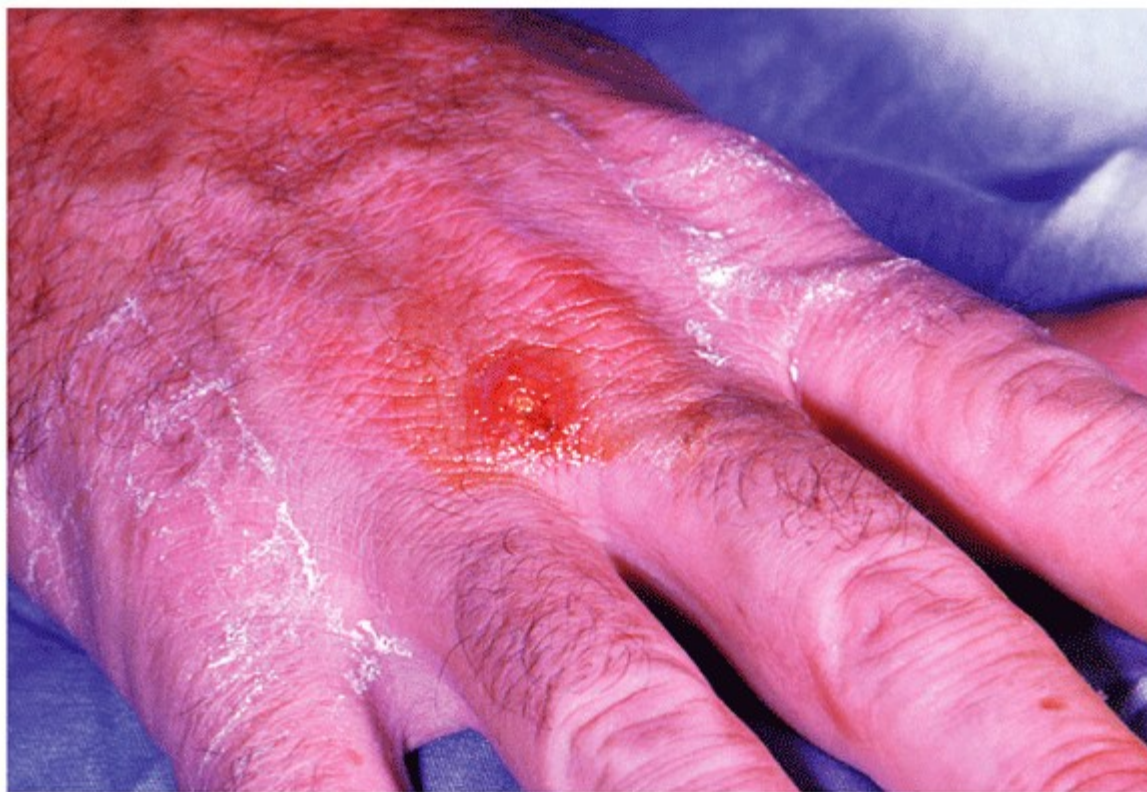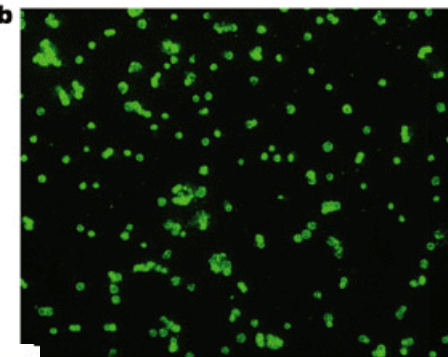
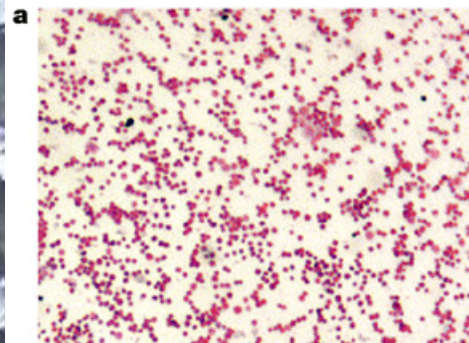
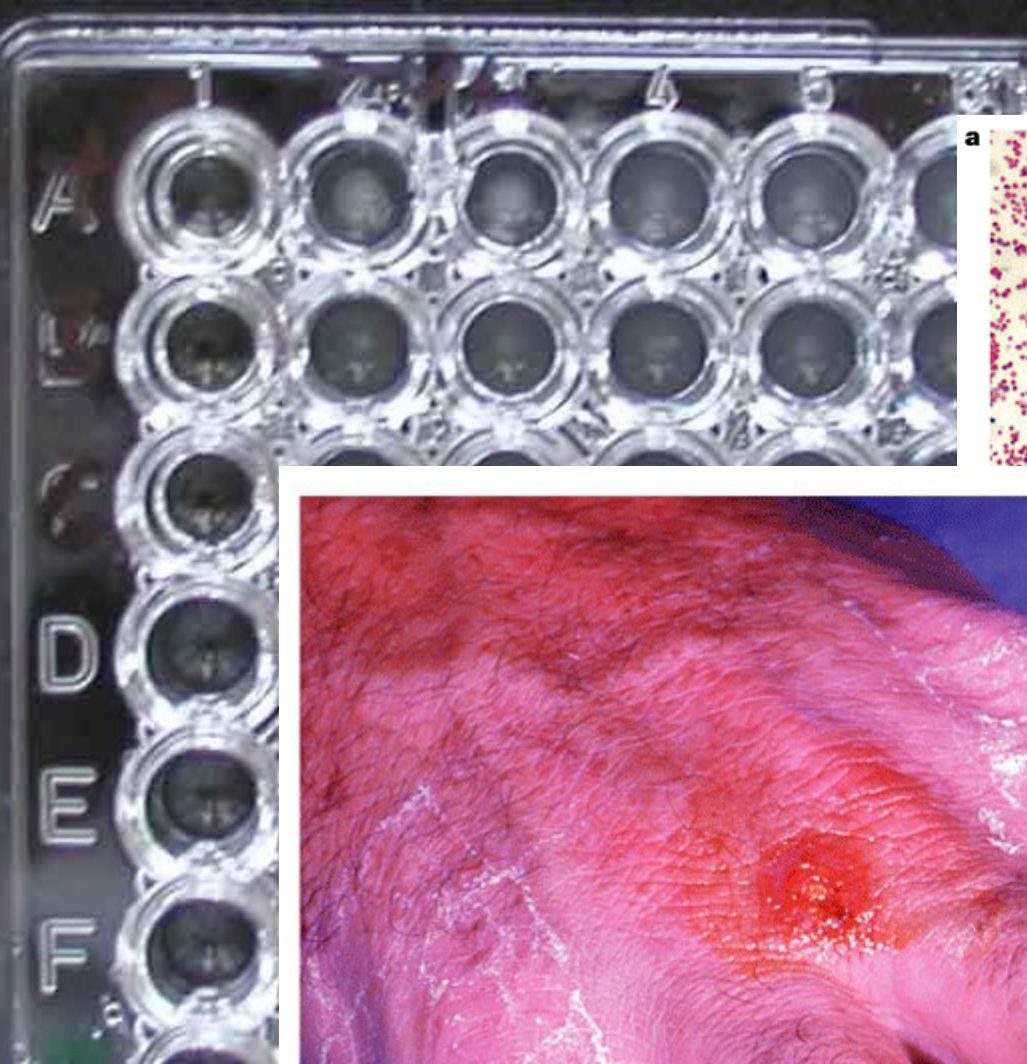


# Poranění zvířetem

*Francisella tularensis* (hlodavci, zajíci – tularemia)

*Bartonella henselae* (“cat scratch disease”)





Nature Reviews | Microbiology

**FRANCISELLA TULARENSIS**

Nature Reviews | Microbiology

**Egon Schiele  
(1890-1918):  
Dead mother  
(1910)**

