

Intraoral radiographic images can be acquired with digital receptors or radiographic film. Digital image receptors include rigid sensors and phosphor plate receptors. Intraoral digital receptors are available in sizes comparable to traditional dental film. Rigid digital receptors are typically available in sizes 0, 1, and 2 while the plate receptors are available in sizes 0, 1, 2, 3, and 4. The range of available sizes is dependent on the specific product manufacturer. Digital receptors cannot be sterilized. Therefore, it is important to utilize proper infection control techniques to prepare and cover digital receptors for placement inside the mouth. Refer to manufacturer recommendations for proper infection control procedures for digital receptors.



Rigid CCD Digital
Sensor
Sirona Dental
Systems, LLC

Digital Phosphor
Plate
Air Technique, Inc.

F-Speed Dental Film
Kodak Dental
Systems

Rigid digital receptors are categorized as direct digital receptors and are available in both wired and wireless formats. These rigid receptors are usually either a charge-coupled device (CCD) or complementary metal oxide semiconductor (CMOS) sensors. The same receptor can be used for each projection by repositioning the receptor for the next view after exposure. These direct digital receptors convert the x-ray beam into an electronic signal, which is then converted into a digital signal displayed as a grayscale image and stored in a computer. The digital image is displayed on the computer monitor almost immediately.

Indirect digital receptors known as storage phosphor plates (SPP) or photostimulable phosphor plates (PSP) are also available. These plates have a europium-activated barium fluorohalide emulsion which stores the latent image after exposure. Phosphor plates require careful handling to avoid abrasion of the emulsion and resultant image artifacts.¹ A separate plate is needed for each projection and the plates must be erased with white light before reuse. After the plate is exposed, the receptor is laser scanned and the image is digitized and displayed on the computer monitor. In newer scanner models, plate erasure occurs after the scanning step but before exit of the plate from the device.

Digital images can be adjusted to view the information in different ways. Software enhancement features include changes in density, contrast, colorization, zoom or magnification of particular areas of interest, measurement, image reversal and the application of filters for noise reduction or edge sharpening. Image enhancement tends to be subjective and is dependent on the visual preferences of the clinician interpreting the image.² Subtraction can also be performed using digital images. This is the process used to compare an area before and subsequent to treatment to assess progress or change. The computer subtracts the two images and the image that remains represents the difference or change between pre- and post-treatment. The challenge with digital subtraction is the need to register the images prior to subtraction. The images are seldom identical in their placement or projection geometry and must be matched structurally in order to determine the actual change that occurred between the two images taken at different points in time.³

After the image has been obtained, it can be stored in the computer, printed or sent electronically in instances of referral or insurance claims. Digital radiography facilitates storage and easy access for image viewing, duplication, printing or electronic transfer. Digital imaging is an integral part of a complete electronic record without the need for physical storage space and fear that the images will be damaged or destroyed. However, it is important to back-up patient records daily to avoid lost data. There are a variety of media that can be used for back-up storage such external hard drives, CDs, DVD or cloud technology.

Digital imaging like film radiography utilizes x-ray beam collimators to reduce the area of exposure at the skin surface with a preference for rectangular collimation and receptor holding devices to reduce retakes. Rectangular collimation more so than round reduces both primary and scatter radiation which not only benefits the patient but also improves image quality.⁴ Because digital receptors are more

sensitive to scatter radiation than film, rectangular collimation is recommended for use with digital imaging systems. There are a number of commercially available devices that the clinician can utilize to achieve rectangular collimation and reduce exposure.⁵ Current digital receptors offer equal or greater dose reduction than F-speed film and comparable diagnostic utility.²

The majority of technique and exposure errors can be produced with digital receptors as with conventional film with a few exceptions. The greatest advantage of digital imaging is elimination of processing errors which are the most common causes of retakes in film-based radiography. Digital imaging also eliminates the darkroom, processor and chemical maintenance which requires additional time and effort when done properly, and lengthy processing time. Regardless of the imaging system employed, the clinician should take all necessary steps to reduce the amount of radiation the patient receives in compliance with the ALARA Principle (As Low As Reasonably Achievable). Primary to dose reduction is the application of selection criteria in the determination of necessary radiographs.⁴

- [Previous](#)

Prior to presenting technique errors and the means to correct them, a clear understanding of technique must be established. Although the bisecting angle technique is still utilized and may be necessary in certain circumstances, the paralleling technique is the method of choice for intraoral radiography. However, the use of bisecting angle technique remains relevant due to the increasing use of rigid digital receptors for intraoral radiography. Rigid digital receptors are more difficult to place comfortably in the mouth particularly in children and the posterior regions of the mouth in adults.⁶⁻⁹ The use of rigid digital receptors produces more retakes due to technical errors than phosphor plate receptors or film.¹⁰ A good understanding of bisecting angle technique is necessary to correct dimensional errors associated with placement difficulties as well as instances when occlusal techniques are utilized for intraoral radiographic imaging particularly with rigid digital receptors.

Paralleling Technique

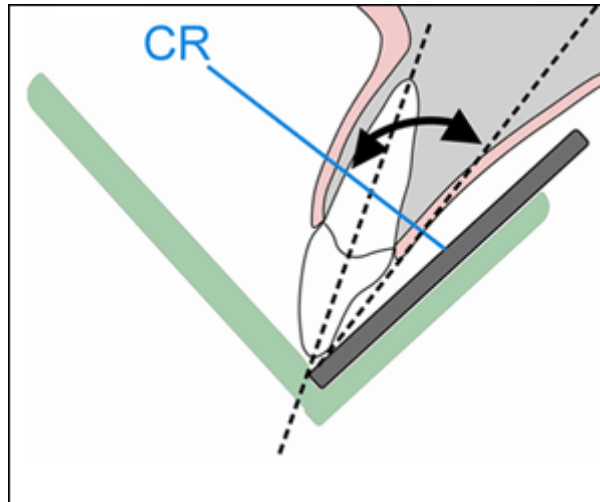
As previously discussed, the paralleling technique is the most accurate intraoral radiographic technique, meeting four of the five principles of accurate image projection. The paralleling technique does not allow for as short as possible object-to-receptor distance (Principle Three) as desired. In order to achieve parallelism, it is necessary to place the receptor more lingual to the structures. The use of receptor-holding devices helps to standardize and execute this technique.

The paralleling technique is accomplished by placing the receptor parallel to the long axis of the tooth. After this parallel relationship has been established, the central ray must be directed perpendicular to both the tooth and receptor. Because the receptor cannot always be placed as close as possible to the tooth due to the receptor-holding device or anatomical obstacles, image magnification may occur. However, this can be compensated for by using an increased source-object distance, which decreases magnification and unsharpness. The paralleling technique, when performed correctly, is superior to the bisecting angle technique by producing an image with both linear and dimensional accuracy.

Bisecting Angle Technique

The bisecting angle technique is accomplished by placing the receptor as close to the tooth as possible. The central ray of the x-ray beam should be directed perpendicular to an imaginary line that bisects or divides the angle formed by the long axis of the tooth and the plane of the receptor. Principle Three of accurate image projection is met by using this technique.

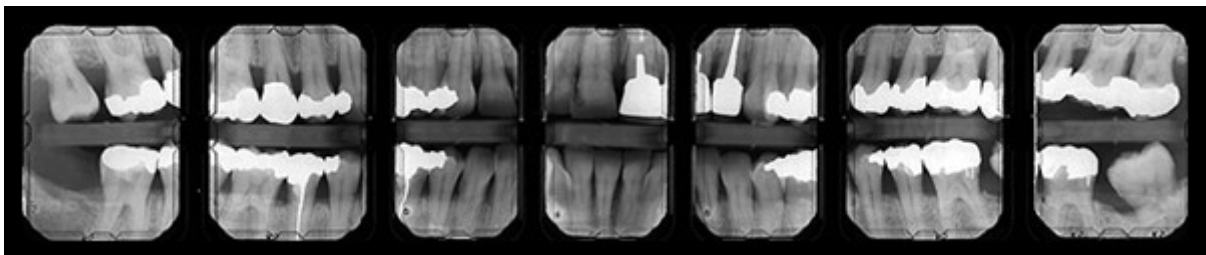
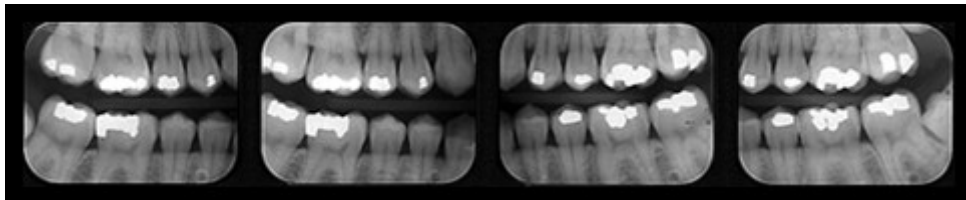
Images produced by the bisecting angle method are in true linear relationship. However, this technique does not follow several of the principles of accurate image projection and also requires accurate visualization of the bisected angle in order to accomplish it properly. Bisecting angle images are not anatomically accurate and are prone to shape distortion. However, the bisecting angle provides an alternative technique when parallel placement cannot be achieved or occlusal techniques are employed.



Bitewing Technique

The bitewing radiographic image is used to examine the interproximal surfaces of the teeth and is particularly useful for the detection of dental caries and alveolar bone levels. The receptor is placed into the mouth parallel to the crowns of the maxillary and mandibular posterior teeth. The patient stabilizes the receptor by biting on a tab or bitewing holder. The central ray of the x-ray beam is then directed through the contacts of the posterior teeth and at a +5° to +10° vertical angle.

Receptor-holding devices or bitewing tabs may be used to stabilize the receptor in the mouth. Receptors may be positioned in the horizontal or vertical dimension with this technique, depending upon the area to be examined. Bitewings may be taken in the anterior segments of the dentition as well. Some dentists, particularly periodontists, may prescribe a 7 image bitewing survey consisting of 4 vertical bitewings in the posterior with size 2 receptors and 3 vertical bitewings in the anterior using size 1 receptors. This permits evaluation for both alveolar bone loss and caries detection.




- [Previous](#)
- **Page 3 of 7**
- [Next](#)

×

×

×

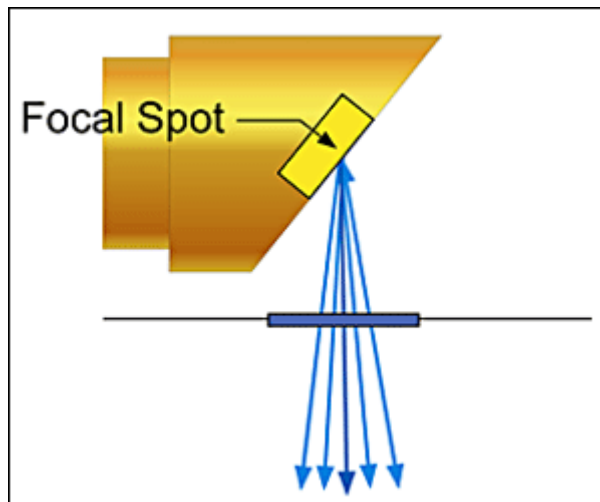
- Home
- |
- [About dentalcare.com](#)
- |
- [Contact Us](#)
- |
- [Terms & Conditions](#)
- |
- [Privacy Notice](#)
- |
- [Ad Choices](#) 
- |
- [Site Map](#)

©1996-2015 The Procter & Gamble Company, Cincinnati, Ohio, USA

image of the teeth and surrounding structures similar to a photograph. Whether using rigid or phosphor plate digital receptors or conventional film, the purpose of the receptor is to record the projected image or area of interest. In discussing the principles of accurate image projection, the source of x-ray photons is the focal spot on the anode target inside the x-ray tube within the x-ray head. The principles of accurate image projection can be summarized as follows:

Principle One: X-rays Should be Emitted from the Smallest Source of Radiation as Possible.

As electrons strike the focal spot, x-rays are emitted. The smaller the focal spot is inside the x-ray tubehead, the greater the detail or resolution of the resultant image. Manufacturers govern the size of the focal spot, and it cannot be changed by the operator. However, the focal spot can become enlarged over time due to continuous machine use. When focal spot enlargement does occur, the resultant radiographic image becomes less sharp. The focal spot should be monitored through a quality assurance program. Resolution test devices will determine any change in the focal spot size and can indicate when an x-ray head may need to be replaced. These tests may be part of state-mandated x-ray machine inspection.



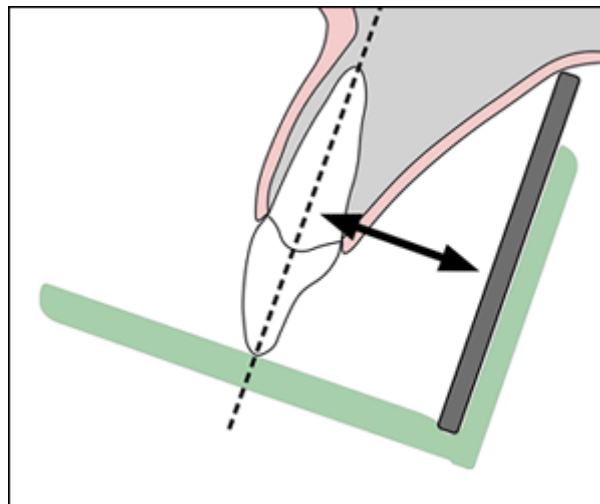
Principle Two: The X-ray Source-to-Object Distance Should be as Long as Possible.

The x-ray source-to-object distance refers to the distance between the focal spot and the object to be recorded. The use of a long open-ended position indicating device (PID or cone) will enable the x-ray photons to emerge in a straighter line therefore producing a more dimensionally accurate image. The straighter the x-ray photon line, the less divergent the x-ray beam. The resultant image will be a sharper, more accurate representation of the structures being radiographed and demonstrate less image magnification.



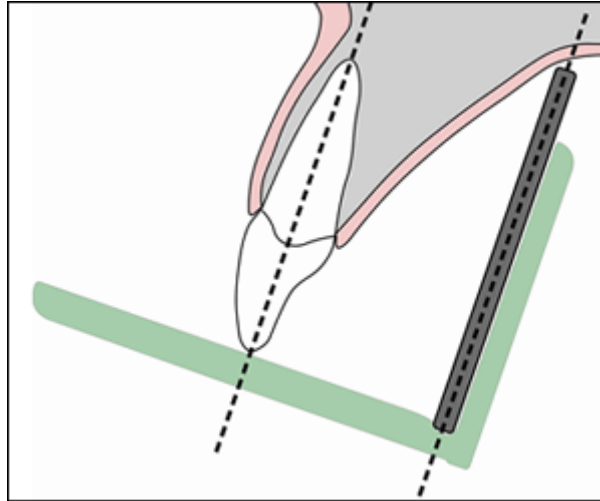
Principle Three: The Object-to-Receptor Distance Should be as Short as Possible.

The object in this principle refers to the tooth or structures being radiographed. Placing the object close to the receptor reduces magnification and increases image sharpness. The bisecting angle technique follows this single principle more so than the paralleling technique. However, the bisecting angle technique does not conform to the other principles of accurate image projection. As a result, it is more prone to shape distortion and is not recommended as a primary technique. Shape distortion is defined as deviation from the true shape of the object.



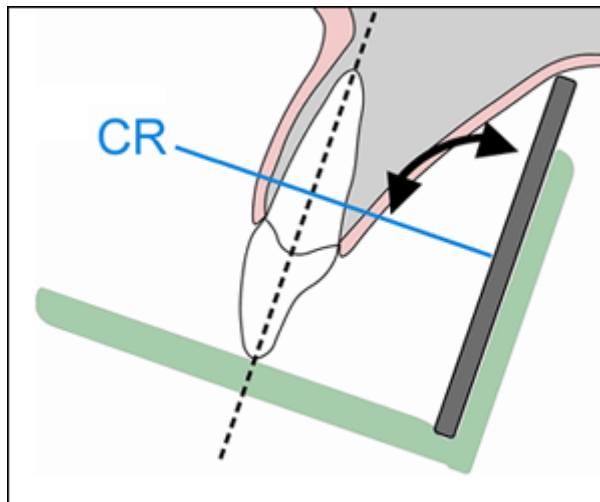
Principle Four: The Receptor and Long Axis of the Tooth Should be Parallel to Each Other.

When the receptor and the long axis of the tooth are parallel (as in the paralleling technique), the distortion of the radiographic image is decreased. Receptor to structure parallelism improves anatomic accuracy and reduces shape distortion.



Principle Five: The X-ray Beam Should be Directed Perpendicular to the Tooth and Receptor.

The x-ray beam must be directed perpendicular or at a right angle to the long axis of the tooth, which ideally is also perpendicular to the receptor. When this principle is not followed, an error in vertical angulation or length is seen, and the resultant image will appear either foreshortened (shorter than the actual object) or elongated (longer than the actual object). Right angle entry of the x-ray beam improves anatomic accuracy and reduces shape distortion.

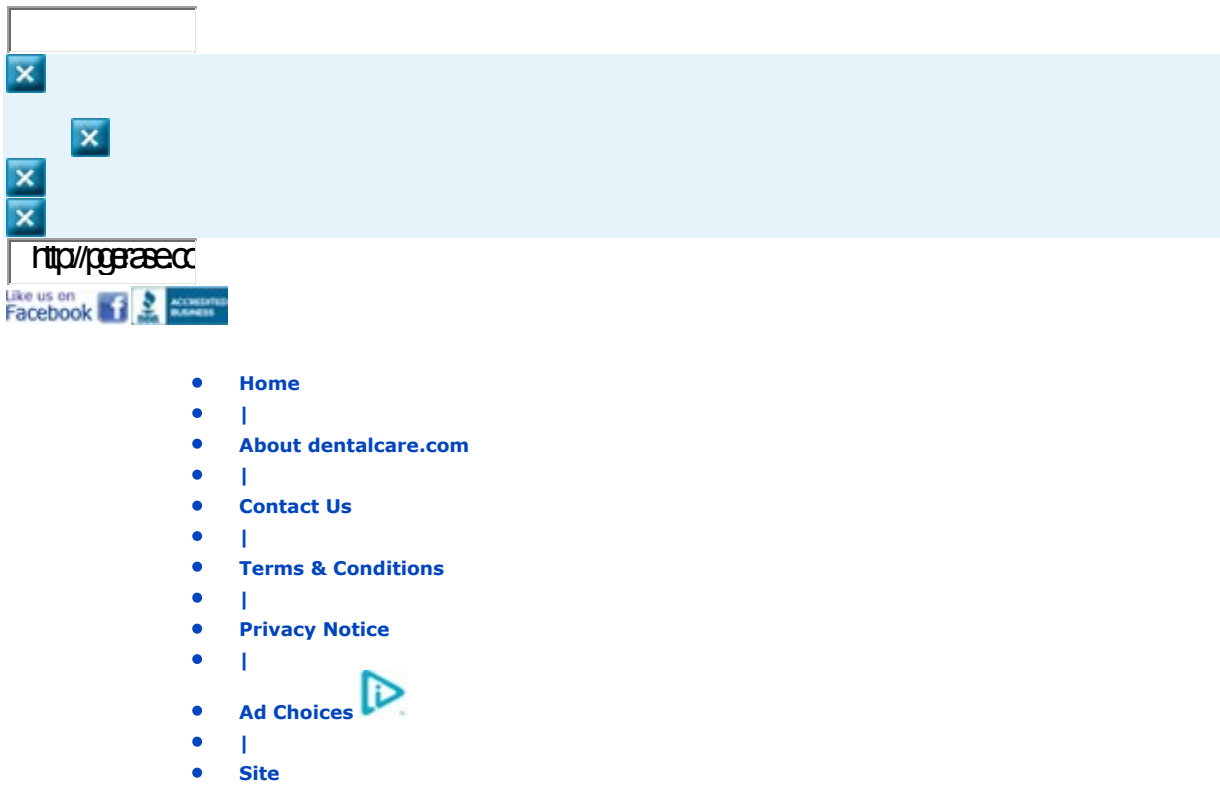


These same principles of accurate image projection can be demonstrated by using a flashlight and projecting the shadow of an object onto a wall in a dark room. Completing this simple exercise may help the novice radiographer to better understand how to apply these principles and their role in producing an accurate image. Also, it provides insight into how and why technical errors occur when the principles are violated.

The "perfect" radiographic technique incorporates all five principles of accurate image projection simultaneously. Unfortunately, an ideal technique which meets all the requirements for accurate image projection has not been found. However, the paralleling technique which typically utilizes receptor-holding devices is the preferred intraoral technique because it follows most of the principles of accurate image projection listed above.

- [Previous](#)
- **Page 2 of 7**
- [Next](#)





Intraoral radiographic images can be acquired with digital receptors or radiographic film. Digital image receptors include rigid sensors and phosphor plate receptors. Intraoral digital receptors are available in sizes comparable to traditional dental film. Rigid digital receptors are typically available in sizes 0, 1, and 2 while the plate receptors are available in sizes 0, 1, 2, 3, and 4. The range of available sizes is dependent on the specific product manufacturer. Digital receptors cannot be sterilized. Therefore, it is important to utilize proper infection control techniques to prepare and cover digital receptors for placement inside the mouth. Refer to manufacturer recommendations for proper infection control procedures for digital receptors.



Rigid CCD Digital Sensor
Sirona Dental Systems, LLC

Digital Phosphor Plate
Air Technique, Inc.

F-Speed Dental Film
Kodak Dental Systems

Rigid digital receptors are categorized as direct digital receptors and are available in both wired and wireless formats. These rigid receptors are usually either a charge-coupled device (CCD) or complementary metal oxide semiconductor (CMOS) sensors. The same receptor can be used for each projection by repositioning the receptor for the next view after exposure. These direct digital receptors convert the x-ray beam into an electronic signal, which is then converted into a digital signal displayed as a grayscale image and stored in a computer. The digital image is displayed on the computer monitor almost immediately.

Indirect digital receptors known as storage phosphor plates (SPP) or photostimulable phosphor plates (PSP) are also available. These plates have a europium-activated barium fluorohalide emulsion which stores the latent image after exposure. Phosphor plates require careful handling to avoid abrasion of the emulsion and resultant image artifacts.¹ A separate plate is needed for each projection and the plates

must be erased with white light before reuse. After the plate is exposed, the receptor is laser scanned and the image is digitized and displayed on the computer monitor. In newer scanner models, plate erasure occurs after the scanning step but before exit of the plate from the device.

Digital images can be adjusted to view the information in different ways. Software enhancement features include changes in density, contrast, colorization, zoom or magnification of particular areas of interest, measurement, image reversal and the application of filters for noise reduction or edge sharpening. Image enhancement tends to be subjective and is dependent on the visual preferences of the clinician interpreting the image.² Subtraction can also be performed using digital images. This is the process used to compare an area before and subsequent to treatment to assess progress or change. The computer subtracts the two images and the image that remains represents the difference or change between pre- and post-treatment. The challenge with digital subtraction is the need to register the images prior to subtraction. The images are seldom identical in their placement or projection geometry and must be matched structurally in order to determine the actual change that occurred between the two images taken at different points in time.³

After the image has been obtained, it can be stored in the computer, printed or sent electronically in instances of referral or insurance claims. Digital radiography facilitates storage and easy access for image viewing, duplication, printing or electronic transfer. Digital imaging is an integral part of a complete electronic record without the need for physical storage space and fear that the images will be damaged or destroyed. However, it is important to back-up patient records daily to avoid lost data. There are a variety of media that can be used for back-up storage such external hard drives, CDs, DVD or cloud technology.

Digital imaging like film radiography utilizes x-ray beam collimators to reduce the area of exposure at the skin surface with a preference for rectangular collimation and receptor holding devices to reduce retakes. Rectangular collimation more so than round reduces both primary and scatter radiation which not only benefits the patient but also improves image quality.⁴ Because digital receptors are more sensitive to scatter radiation than film, rectangular collimation is recommended for use with digital imaging systems. There are a number of commercially available devices that the clinician can utilize to achieve rectangular collimation and reduce exposure.⁵ Current digital receptors offer equal or greater dose reduction than F-speed film and comparable diagnostic utility.²

The majority of technique and exposure errors can be produced with digital receptors as with conventional film with a few exceptions. The greatest advantage of digital imaging is elimination of processing errors which are the most common causes of retakes in film-based radiography. Digital imaging also eliminates the darkroom, processor and chemical maintenance which requires additional time and effort when done properly, and lengthy processing time. Regardless of the imaging system employed, the clinician should take all necessary steps to reduce the amount of radiation the patient receives in compliance with the ALARA Principle (As Low As Reasonably Achievable). Primary to dose reduction is the application of selection criteria in the determination of necessary radiographs.⁴

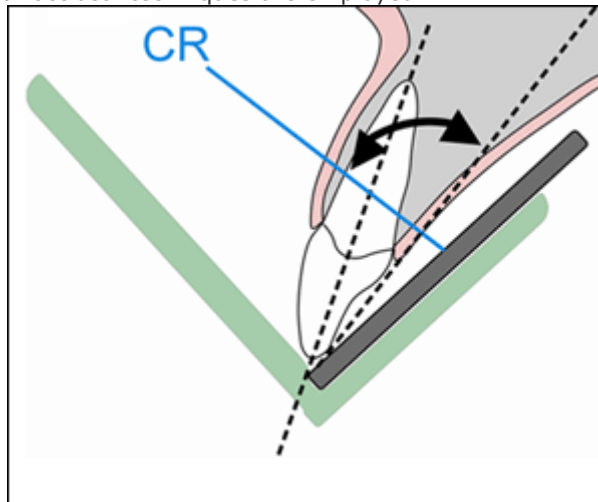
• [Previous](#)

- Prior to presenting technique errors and the means to correct them, a clear understanding of technique must be established. Although the bisecting angle technique is still utilized and may be necessary in certain circumstances, the paralleling technique is the method of choice for intraoral radiography. However, the use of bisecting angle technique remains relevant due to the increasing use of rigid digital receptors for intraoral radiography. Rigid digital receptors are more difficult to place comfortably in the mouth particularly in children and the posterior regions of the mouth in adults.⁶⁻⁹ The use of rigid digital receptors produces more retakes due to technical errors than phosphor plate receptors or film.¹⁰ A good understanding of bisecting angle technique is necessary to correct dimensional errors associated with placement difficulties as well as instances when occlusal techniques are utilized for intraoral radiographic imaging particularly with rigid digital receptors.
- **Paralleling Technique**
- As previously discussed, the paralleling technique is the most accurate intraoral radiographic technique, meeting four of the five principles of accurate image projection. The paralleling technique does not allow for as short as possible object-to-receptor distance (Principle Three) as desired. In order to achieve parallelism, it is necessary to place the receptor more lingual to the structures. The use of receptor-holding devices helps to standardize and execute this technique.
- The paralleling technique is accomplished by placing the receptor parallel to the long axis of the tooth. After this parallel relationship has been established, the central ray must be directed perpendicular to both the tooth and receptor. Because the receptor cannot always be placed as close as possible to the tooth due to the receptor-holding device or anatomical

obstacles, image magnification may occur. However, this can be compensated for by using an increased source-object distance, which decreases magnification and unsharpness. The paralleling technique, when performed correctly, is superior to the bisecting angle technique by producing an image with both linear and dimensional accuracy.

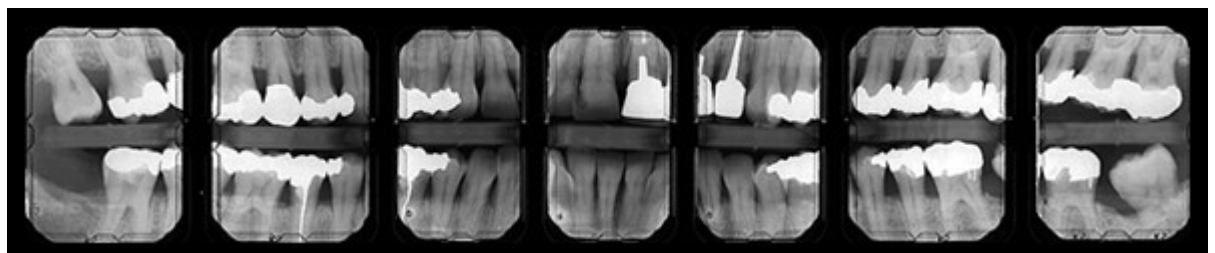
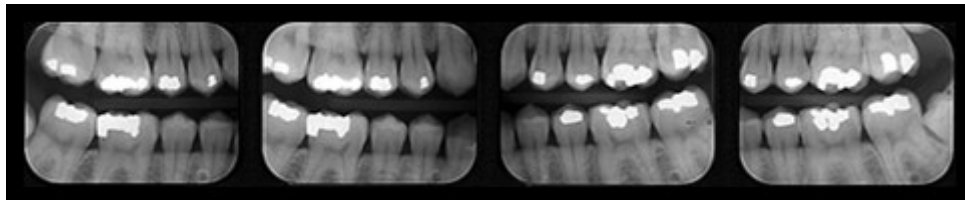
- **Bisecting Angle Technique**

- The bisecting angle technique is accomplished by placing the receptor as close to the tooth as possible. The central ray of the x-ray beam should be directed perpendicular to an imaginary line that bisects or divides the angle formed by the long axis of the tooth and the plane of the receptor. Principle Three of accurate image projection is met by using this technique.
- Images produced by the bisecting angle method are in true linear relationship. However, this technique does not follow several of the principles of accurate image projection and also requires accurate visualization of the bisected angle in order to accomplish it properly. Bisecting angle images are not anatomically accurate and are prone to shape distortion. However, the bisecting angle provides an alternative technique when parallel placement cannot be achieved or occlusal techniques are employed.



- **Bitewing Technique**

- The bitewing radiographic image is used to examine the interproximal surfaces of the teeth and is particularly useful for the detection of dental caries and alveolar bone levels. The receptor is placed into the mouth parallel to the crowns of the maxillary and mandibular posterior teeth. The patient stabilizes the receptor by biting on a tab or bitewing holder. The central ray of the x-ray beam is then directed through the contacts of the posterior teeth and at a $+5^\circ$ to $+10^\circ$ vertical angle.
- Receptor-holding devices or bitewing tabs may be used to stabilize the receptor in the mouth. Receptors may be positioned in the horizontal or vertical dimension with this technique, depending upon the area to be examined. Bitewings may be taken in the anterior segments of the dentition as well. Some dentists, particularly periodontists, may prescribe a 7 image bitewing survey consisting of 4 vertical bitewings in the posterior with size 2 receptors and 3 vertical bitewings in the anterior using size 1 receptors. This permits evaluation for both alveolar bone loss and caries detection.



Correctly exposing intraoral receptors includes four basic steps: receptor placement, vertical PID (cone) angulation alignment, horizontal PID (cone) angulation alignment, and central ray centering. Technique errors can occur if any of these procedures are completed improperly.


Patient Preparation Errors

Dental professionals should always explain the radiographic procedure to the patient and give clear instructions as to what the patient can do to help ensure a quality image, avoid retakes and reduce radiation exposure. The most common error in this category is movement. Factors causing a patient to move include:

- discomfort
- unsupported head position
- gagging and/or swallowing
- patient disability

Discomfort

Discomfort can be addressed by gentle, proper receptor placement, instructing the patient to close slowly, and the use of cushioned edges which can be attached to the receptor. Receptors placed more toward the midline of the palate and toward the tongue on the mandible will make placement more comfortable for the patient. Bending, folding or creasing film or a digital phosphor plate receptor will produce artifacts that may compromise the diagnostic quality of the radiographic image.



Edge Ease® and Slip Ease®, Strong Dental Products, Crosstex® International

Head Support

The headrest on the dental chair should be placed against the occipital lobe at the base of the back of the head. This will support the head during radiographic procedures and reduce the chance of movement. Proper headrest placement positions the occlusal plane parallel to the floor and the midsagittal plane perpendicular to the floor for maxillary periapicals and bitewings. It is helpful to readjust the head to raise the patient's chin up slightly for mandibular periapicals. This improves visibility into the floor of the mouth for receptor placement and keeps the floor of the mouth more relaxed.

Gagging / Swallowing

The gag reflex is a protective mechanism of the body that serves to clear the airway of obstruction. All patients have gag reflexes, some more sensitive than others. The gag reflex can be stimulated when the receptor contacts the soft palate, base of the tongue, or the posterior wall of the pharynx. When exposing a full mouth survey of radiographic images, it is recommended to begin in the anterior region of the mouth. An anterior placement is less likely to stimulate the gag reflex and will also help the patient become more accustomed and comfortable with the procedure.

To ensure a quick and smooth patient experience, prepare all equipment before the receptor is placed inside the mouth. The exposure settings should be set in advance, and the tubehead should be placed in the approximate area of exposure. It may help to encourage the patient to swallow once before the placement of the receptor. The patient can be instructed to release the biting pressure or remove the receptor as soon as the exposure is complete. Other recommended procedures to control gagging include deep breathing through the nose or mouth, anesthetizing the mouth with lozenges, mouthwash, topical anesthetic agents, or refocusing the patient's attention.¹¹ Distraction techniques such as instructing the patient to raise one leg, bend the toes toward the body, etc. will focus attention on the task rather than on gagging. When a patient begins to gag, remove the receptor, be confident and reassuring, and try again. A panoramic radiographic image may be a useful supplement to intraoral radiographs when the molar areas are extremely difficult for the patient to tolerate or for the clinician to obtain.

Patient Disability

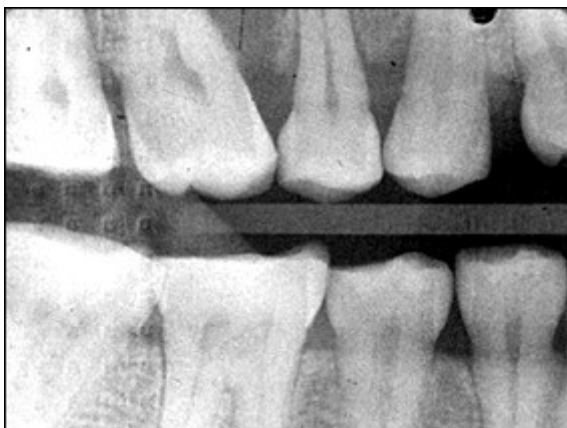Some patients may need assistance during the radiographic procedure due to physical or cognitive disability, injury or medical condition. In such circumstances, it may be necessary to ask a family member or guardian to assist in holding the patient in position. Shielding should be provided for both the patient and person providing the assistance. The clinician must consider what technique would work best in the situation. For instance, a patient with Parkinsons disease can better tolerate intraoral radiographs which have short exposure times rather than a panoramic image which requires a sustained still position and longer exposure cycle. Familiarity with the bisecting angle and occlusal techniques may be useful in situations that are less than ideal and require alternative approaches to imaging.

Receptor Placement Errors

Inadequate Coverage / Missing Apices

A common receptor placement error is inadequate coverage of the area to be examined radiographically. This typically occurs in molar projections when the patient has difficulty maintaining proper receptor placement. Each periapical and bitewing in a complete survey has established criteria which describes the structures of interest that should be recorded on each view. Consistent application of these criteria will minimize this error.

Missing apices can be caused by a receptor placement error. When using receptor holders, the biteblock should be placed on the teeth to be exposed and not on the opposing teeth. If the biteblock is placed on the opposing teeth and the patient is required to bite the receptor into place, a placement error is likely to result. Placing the receptor more lingual to the teeth where the palate and floor are deeper will make placement easier and more comfortable for the patient. Placement of the biteblock and receptor in the correct position first and then having the patient slowing bite to maintain the placement is the preferred and most effective approach.



Backward receptor image

Backward Placement

Placing the film backwards in the mouth causes the lead foil inside the packet to face the radiation source instead of the film. The x-ray beam is attenuated by the lead foil before striking the film. This causes the embossed pattern on the foil, a herringbone or diamond effect, to appear on the processed film. This

error also results in a lighter image and confusion about the correct anatomical area recorded when mounting the processed film. This error is also possible with phosphor plate receptors. In either instance, attention to the orientation of the receptor inside the mouth is critical for diagnostic results and avoidance of diagnostic errors.

Backwards placement is less likely with rigid digital receptors because of the wire attachment on the non-exposure side of the sensor. The exposure side of any receptor must be directed toward the x-ray source to produce an acceptable image.

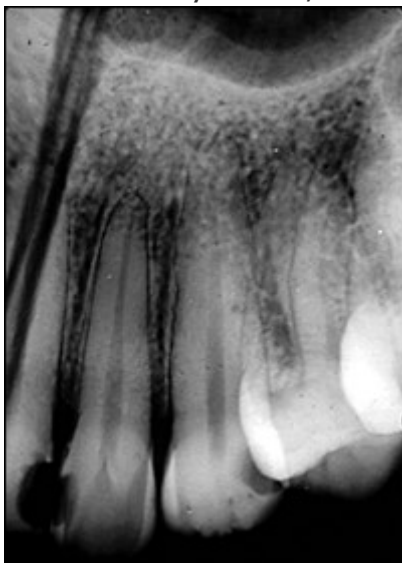Non-exposure side of receptors on the top row with exposure side on the bottom row.



Rigid CCD Digital Sensor
Sirona Dental Systems, LLC

F-Speed Dental Film
Kodak Dental Systems

Digital Phosphor Plate
Air Technique, Inc.

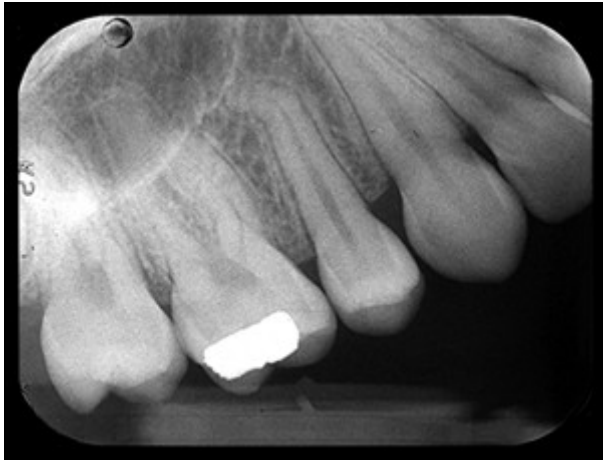

Receptor bending

Bending

Plate or film bending may occur due to contact with the curvature of the palate or lingual arch and/or mishandling of receptors. These receptors can be flexed but should never be bent. If the receptor is too large for the area, bending can also occur. Select a receptor size that will adequately cover the area without producing excessive discomfort to the patient. Crimping, creasing or folding a plate or film receptor damages the emulsion and compromises the quality of the image. Careful handling, use of a smaller receptor, and correct placement will address the problems of bending and image artifacts.

Rigid digital receptors cannot be bent but as previously indicated phosphor plate receptors can be creased, bent, scratched or folded. These alterations result in permanent damage of the plate and produce artifacts on the current and any subsequent image.¹ Damaged plates should be replaced when the artifacts interfere with the production of diagnostic images. Tissue cushions are better alternatives than bending or creasing a plate or film receptor.



Tilted Occlusal Plane

Tilted Occlusal Plane

When the receptor is not placed perpendicular to the occlusal plane, the occlusal plane will appear slanted or diagonal. When exposing bitewing radiographs, the top edge of the receptor may come in contact with the palatal gingiva or curvature of the palate. When this occurs, the occlusal plane will appear crooked. The receptor must be placed straight or perpendicular with the occlusal plane, or placed farther away from the teeth to avoid this error. Always place the biteblock in contact with the occlusal or incisal surfaces of the teeth you are imaging not on the opposing teeth. Placement on the opposing teeth will cause the receptor to displace when it contacts bony anatomy. Preferably, the receptor orientation dot should be placed toward the crowns of the teeth for periapical images and toward the mandible for bitewing images to reduce interference with viewing structures of interest on the recorded image.

Vertical Alignment Errors

When using the paralleling technique and receptor holders, the vertical angulation is dictated by the holding device to enable the x-ray beam to be perpendicular to both the receptor and teeth. Therefore, it is important that the clinician place the receptor parallel to the teeth to ensure proper vertical angulation. In contrast, when using the bisecting angle technique, the beam is perpendicular to the plane that bisects or divides the angle formed by the teeth and the receptor. Vertical alignment errors often occur with the bisecting angle technique and can result in elongation or foreshortening of the teeth. Other errors which can occur causing teeth to appear elongated or foreshortened include:

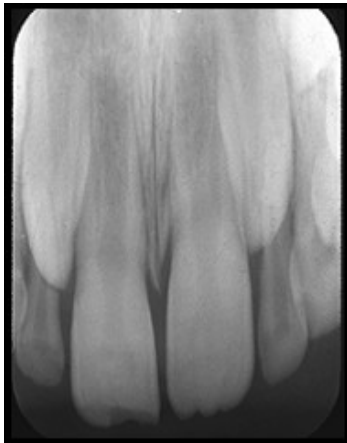- receptor position
- patient position

It is important to determine the cause of the error.

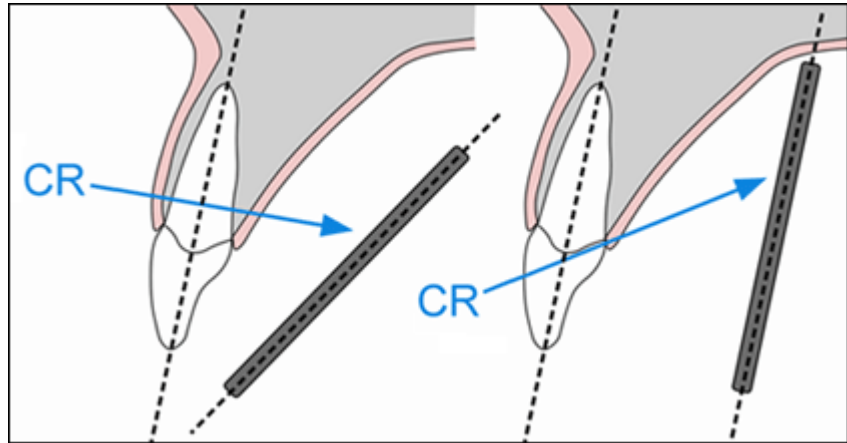
Elongation

Elongation or lengthening of the teeth and surrounding structures results from underangulation of the x-ray beam. When elongation occurs using the paralleling technique, the angulation of the x-ray beam is less than the long axis plane of the teeth. To correct this error the operator must increase the vertical angulation. In other words, for the maxillary arch, the positive angulation must be increased (PID pointing down); for the mandibular arch, the negative angulation must be increased (PID pointing up).

This error can also occur when using the bisecting angle technique. Often the error is caused by the x-ray beam being perpendicular to the long axis of the teeth, rather than bisecting the angle between the teeth and the receptor.

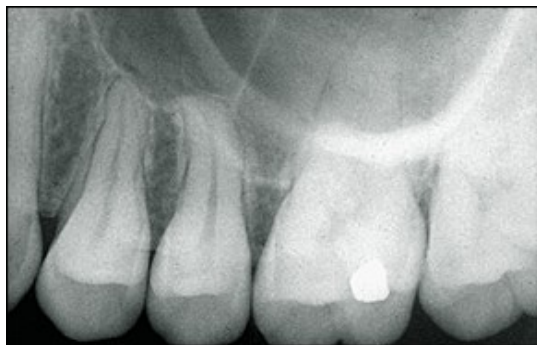

Elongation
Foreshortening

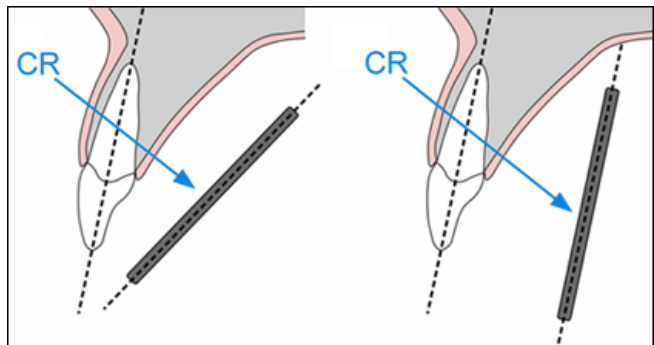


Receptor Angular Beam Under-Angulated

Foreshortening or shortening of the teeth and surrounding structures can also result from improper vertical angulation. Foreshortening is the result of overangulation of the x-ray beam. When foreshortening occurs when using the paralleling technique, the angulation of the x-ray beam is greater than the long axis plane of the teeth. To correct foreshortening when using the paralleling technique, the operator should decrease the positive vertical angulation for maxillary projections, and decrease the negative vertical for mandibular projections. This error can also occur if the receptor is not placed parallel to the long axis of the teeth.



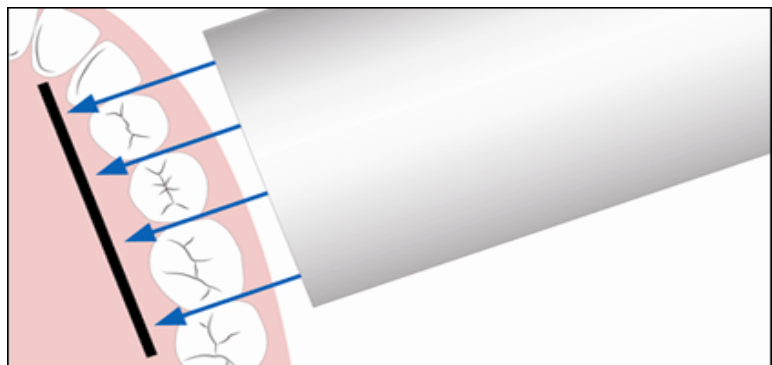
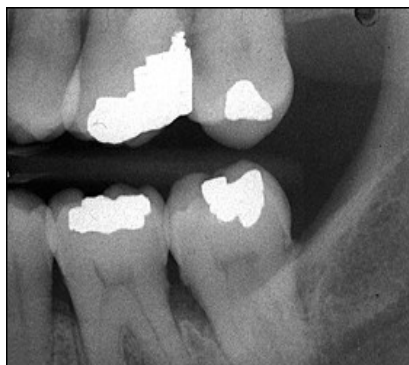Foreshortened



Receptor Angular Beam Over-Angulated

Horizontal Alignment Errors

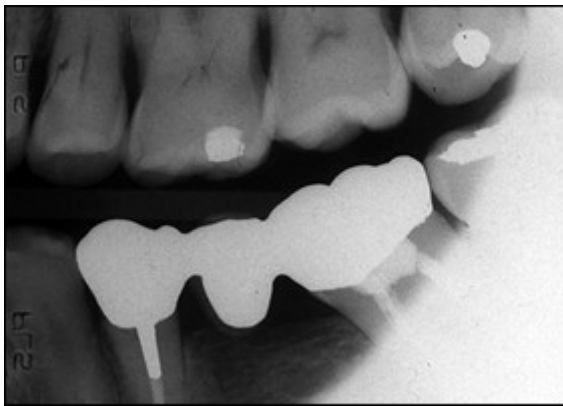
Proper horizontal alignment of the x-ray beam will open interproximal contacts and facilitate a thorough caries evaluation and assessment of bone levels, which are all components of a thorough clinical and radiographic examination. The x-ray beam should be aimed directly between the targeted teeth in order to open interproximal surfaces. Horizontal alignment errors cause the image to shift anteriorly or posteriorly, resulting in the overlapping of the interproximal surfaces.



Horizontal Overlapping

To determine if the horizontal angulation is positioned incorrectly, evaluate the extent of the overlap. The Buccal Object Rule can be used to determine the movement buccal and lingual cusps when trying to define the error. The Buccal Object Rule states: Buccal objects move in the opposite direction compared to the direction of the x-ray tubehead while lingual objects move in the same direction as the movement of the x-ray tubehead.¹² Application of the Buccal Object Rule to determine the cause of interproximal overlapping requires evaluation of the position of the x-ray tubehead and the direction of the overlapping on the bitewing image. For example, if the x-ray head is placed too posterior in position, the buccal cusps will overlap in an anterior direction as demonstrated in the molar bitewing image illustration. By way of comparison, if the x-ray head is placed too anterior in position, the buccal cusps with overlap in a posterior direction. To avoid this error, the central ray must pass through the teeth where the contacts need to be open.

When using receptor holding devices, horizontal errors can occur by improper horizontal alignment of the receptor. These errors can be avoided by placing the receptor relationship in alignment with the teeth so that the x-ray beam travels directly through the contact areas. This will place the receptor parallel to the buccal plane of the teeth of interest as well as the parallel to the instrument indicator ring.




Cone-Cutting

Beam Centering Errors

The central ray should be aligned over the center of the receptor with the x-ray beam directed perpendicular to the receptor. When this alignment is not observed, a cone-cut occurs. Cone-cuts appear as a clear zone on traditional radiographs after processing, due to the lack of x-ray exposure in the area of the cut. When using digital imaging, the cone-cut appears as an opaque or white area. The shape of the cone-cut depends on the type of collimator used when exposing the receptor. For example, if a round collimator is used, a curved cone-cut will appear. Square cone-cuts occur when using a rectangular collimator. To correct a cone-cut error, the beam should be re-centered toward the area of non-exposure. Improper assembly of receptor holding devices can also cause cone-cuts. When assembling these devices, make certain that the entire receptor can be seen while looking through the indicator ring.

- [Previous](#)
- **Page 5 of 7**
- [Next](#)



- [Home](#)
- |
- [About dentalcare.com](#)
- |
- [Contact Us](#)
- |
- [Terms & Conditions](#)
- |
- [Privacy Notice](#)
- |
- [Ad Choices](#) 
- |
- [Site Map](#)

©1996-2015 The Procter & Gamble Company, Cincinnati, Ohio, USA All rights reserved

Exposure Errors

Time Setting

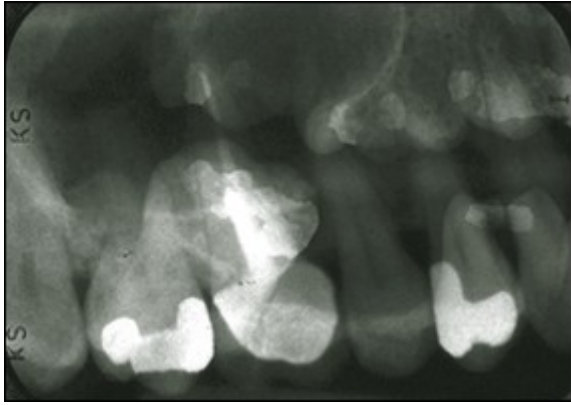
Incorrect exposure can be caused by many factors; the most common being improper exposure factor settings. Improper time selection is the most likely error, because most intraoral x-ray units have fixed or unchangeable milliamperage (mA) and kilovoltage (kVp) settings. Time and milliamperage control density or the overall darkness of an image while kilovoltage controls contrast or the differences in darkness. The exposure time settings should be based on the receptor speed, the area being exposed, and patient size and stature. Every treatment room should have an exposure factor chart to guide the operator in selecting the appropriate kVp, mA and time settings for each periapical and bitewing. Refer to the recommended manufacturer settings for specific intraoral views or projections. Generally speaking, the recommended time setting for each area is based on the size of an average adult patient.

Improper exposure time settings can also result from an inaccurate evaluation of patient size and stature. The operator should use longer times for larger-than-average patients and shorter times for smaller-than-average patients. Usually one step up for large patients and one step down for small patients will be adequate adjustment for each periapical and/or bitewing. Failing to adjust exposure time will result in images that are either too light or too dark. Generally speaking child exposure time settings are lower than adult exposure time settings because of the child's smaller size.

Under/Over Exposure

Underexposed receptors result in images that are too light or low in density. Light images can also be caused by an increase in the source-object distance, or not placing the tubehead close enough to the patient's face during exposure. Exposure times are prescribed on the assumption that the tubehead is no more than 2 centimeters away from the face of the patient. Receptors can be underexposed if the exposure switch is not activated for the indicated or correct length of time. In other words, the clinician let go of the exposure button too soon. Overexposure results in a high-density or dark image. The causes include improper exposure factor settings or improper assessment of patient size and stature.

When using digital image receptors, the density can be adjusted by specific enhancement features of the computer software program. However, images that are too light or low in density make it difficult to visualize the differences in structures and typically cannot be improved by software adjustments.³ Digital images that are dark or high in density can usually be salvaged by software adjustments in density unless the image appears totally black.³ This adjustment in density should be accomplished prior to printing or archiving the image. Extreme under or overexposure by necessity will result in retakes, thus exposing the patient to unnecessary radiation.



Double exposure

Double Exposure

Double exposure results when the receptor is exposed twice and two images appear superimposed onto each other. This error results in two errors; one receptor that was double-exposed and another that was not exposed. It is extremely important to avoid this error because it exposes the patient to radiation twice. To avoid this error, maintain an organized work space in which exposed receptors are placed in one area or turned over to separate from unexposed receptors.

Double exposure of rigid digital receptors is not possible but phosphor plate receptors can be double-exposed just like film.

Poor Image Definition

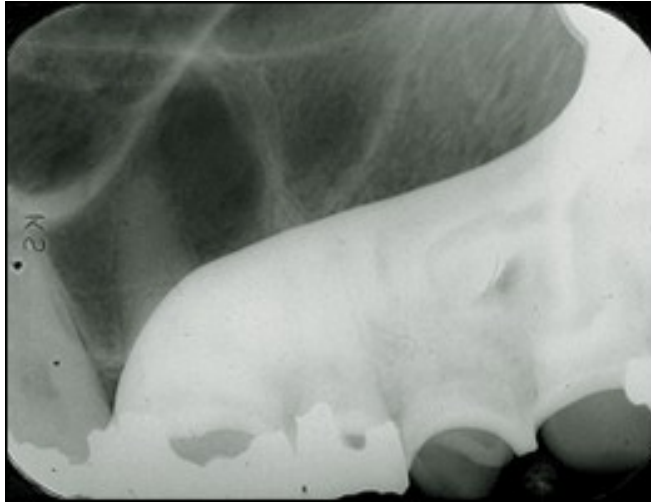Poor image definition or resolution can be the result of patient movement, receptor movement, and/or vibration of the x-ray tubehead. Movement has been discussed previously. Receptor movement may occur when the receptor is not properly stabilized in the mouth or when the patient moves the receptor because it feels uncomfortable.

To help prevent tubehead vibration or drifting, place the arm against the wall with the tubehead pointing down after each use. When the arm is fully extended for long periods of time, the joints can become weakened and fatigued, resulting in drifting and vibration. Tubeheads and arms should be professionally serviced if drifting and movement persist.

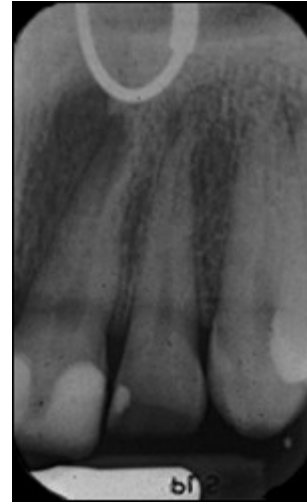Miscellaneous Objects

When a removable prosthesis is left in the mouth during exposure, a superimposed image of the appliance will appear over the teeth. Prior to radiographic procedures, ask patients to take out all removable items from the mouth, such as retainers, partial dentures, complete dentures, etc.

Eyeglass frames or stems may appear in maxillary periapical radiographs of patients with large eyeglasses and/or when extreme vertical angulation is utilized. Glasses should be removed prior to radiographic procedures. Facial jewelry in the path of the x-ray beam should be removed as well to avoid unwanted artifacts and unnecessary retakes.

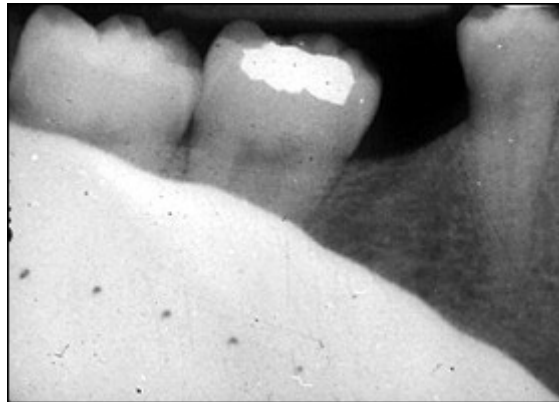

Partial



Nose Ring


Thyroid collars or lead aprons can also be recorded on radiographic images. This is normally caused by the collar being placed on too loosely or too high on the neck or when the vertical angulation is so steep that the collar is in the path of the x-ray beam.



Thyroid collar


Another technical error that occurs occasionally is when the receptor yields no image. This error can be caused by mechanical problems such as electrical failure, faulty generator, timer inaccuracy or faulty exposure switch. Failure to turn on the machine, placement of the receptor between the cheek and teeth, failure to line-up the x-ray beam and backward placement of digital receptors can also produce a blank or white image representative of this error.

- [Previous](#)
- **Page 6 of 7**
- [Next](#)



<http://pgrasecc>

Like us on Facebook    

- [Home](#)
- |
- [About dentalcare.com](#)
- |
- [Contact Us](#)
- |
- [Terms & Conditions](#)
- |
- [Privacy Notice](#)
- |
- [Ad Choices](#) 
- |
- [Site Map](#)

©1996-2015 The Procter & Gamble Company, Cincinnati, Ohio, USA All ri