
FEMALE GENITAL ORGANS (ORGANA GENITALIA FEMININA)

Organa genitalia interna:

Ovarium

Tuba uterina (Fallopian tube)

Uterus

Vagina

Organa genitalia externa:

Mons pubis

Labia majora pudendi

Labia minora pudendi

Clitoris

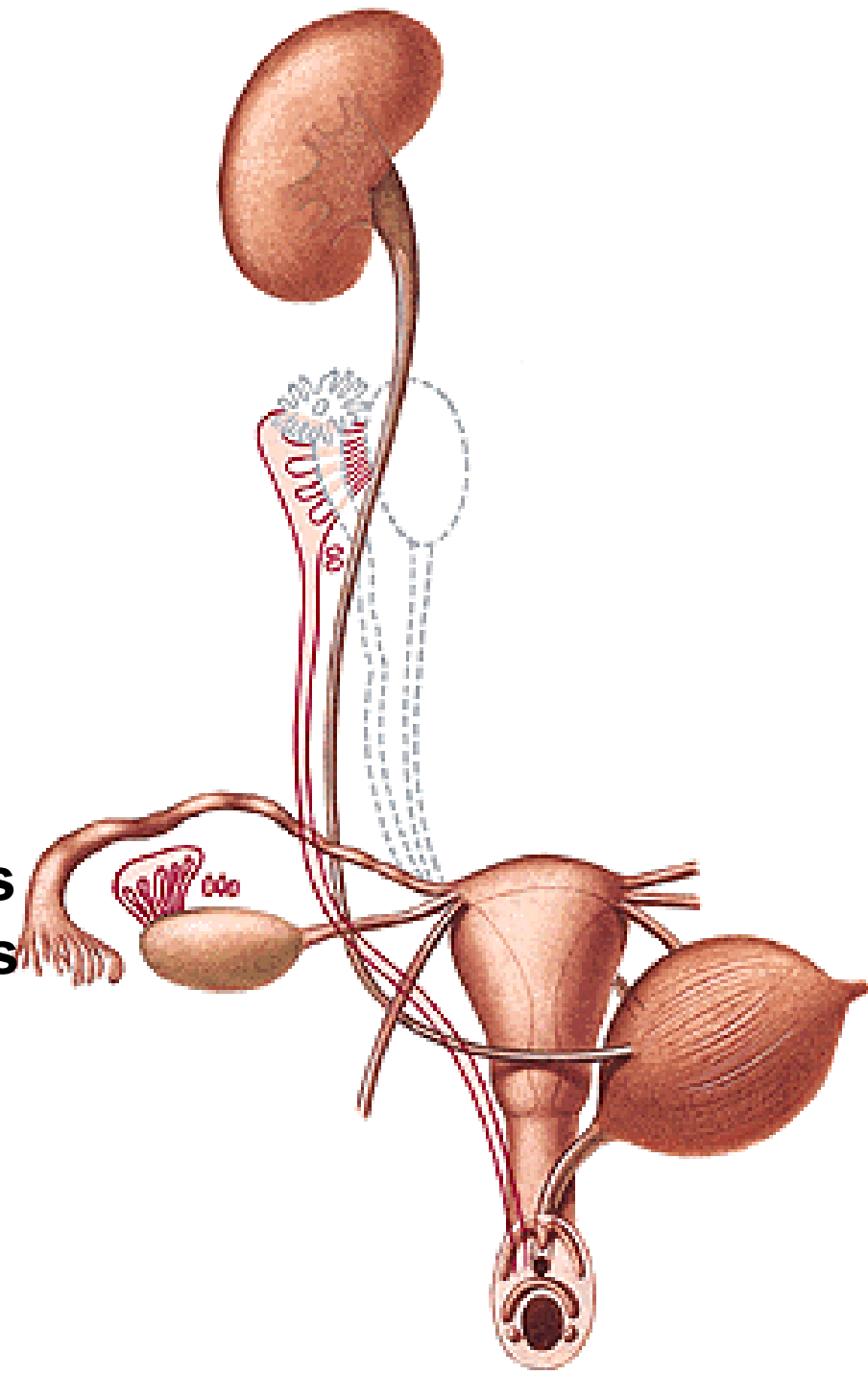
Glandulae vestibulares majores

Glandulae vestibulares minores

Bulbi vestibuli

Ductus Mülleri, plica genitalis

Torus genitalis



OVARIUM

Extremitas tubaria et uterina

Lig. suspensorium ovarii

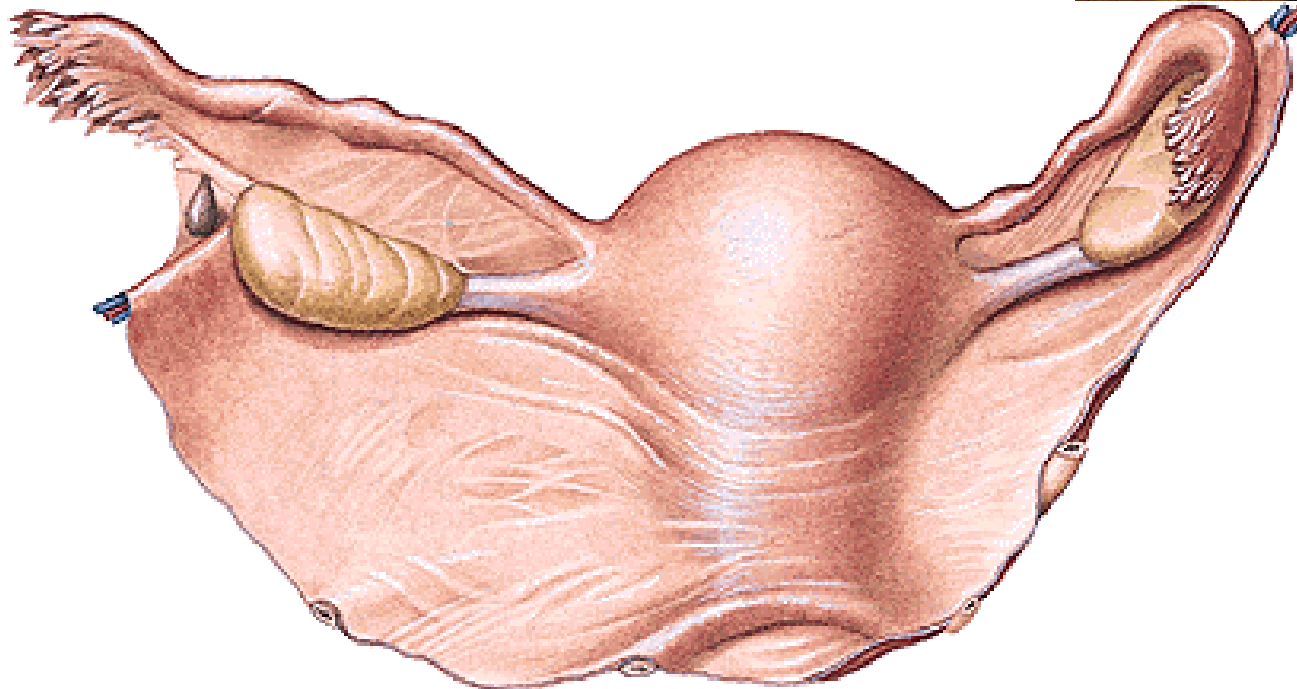
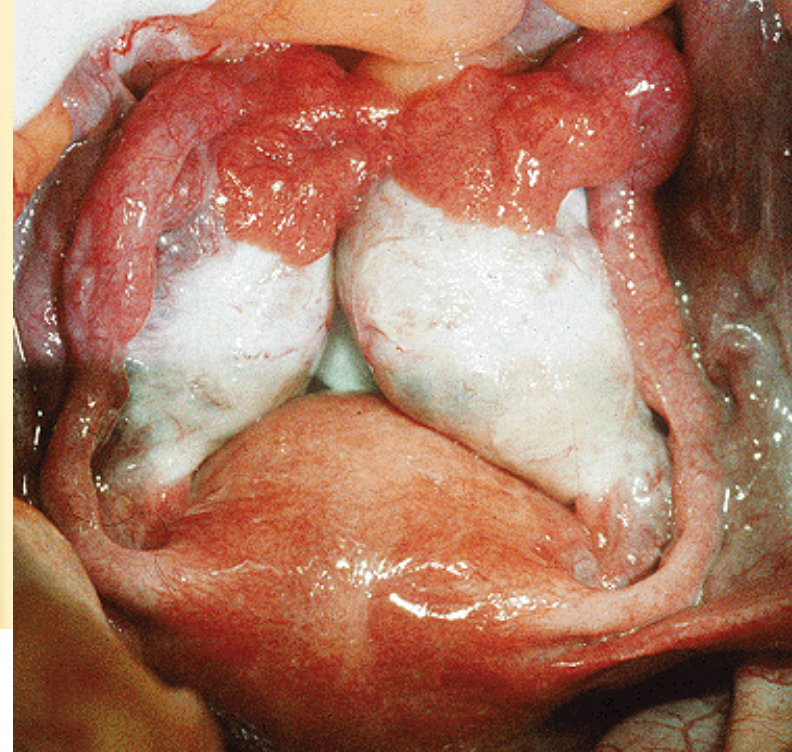
Lig. ovarii proprium

Facies medialis et lateralis

Margo liber et mesovaricus

Hilum ovarii

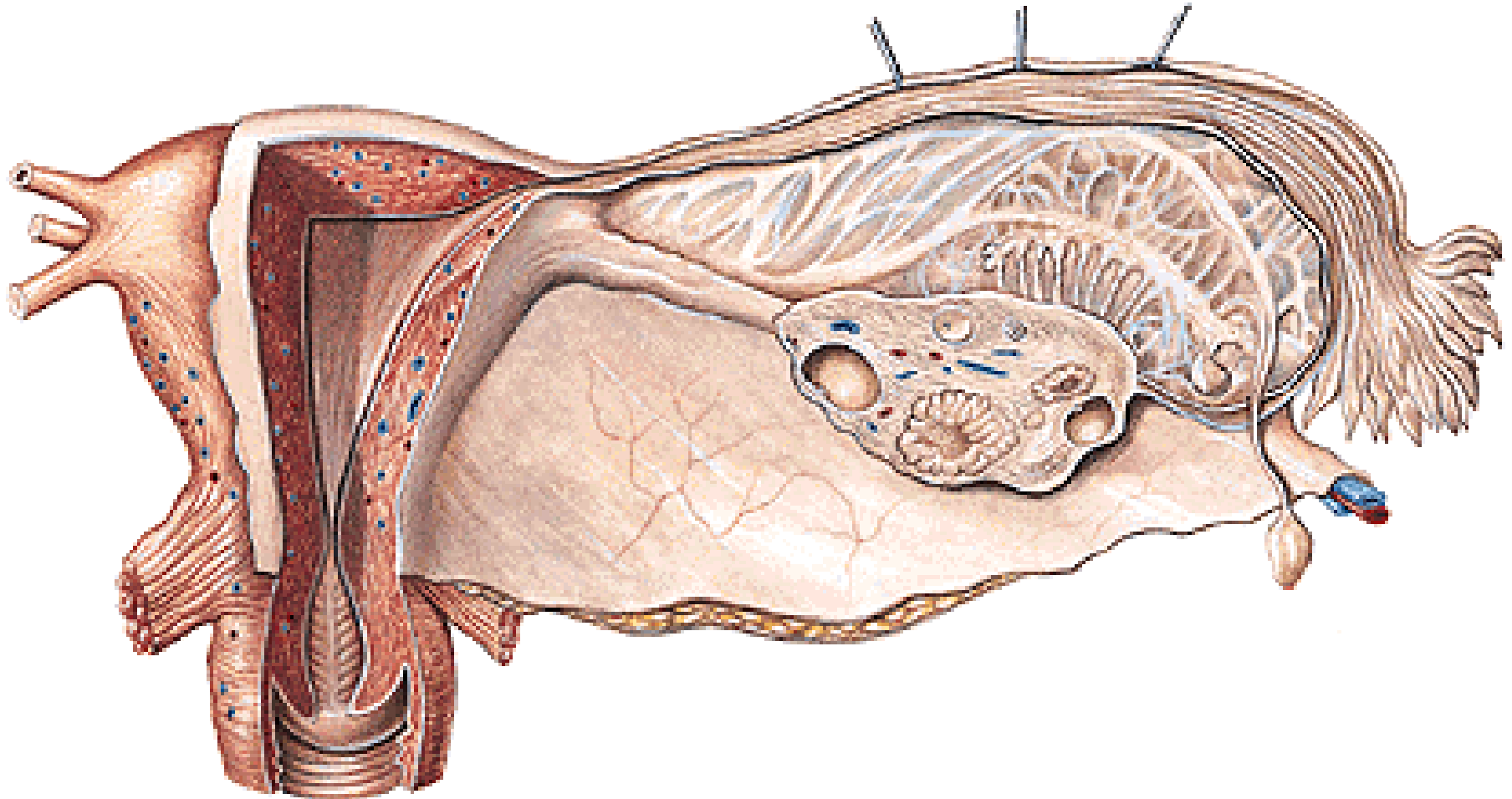
Mesovarium – lig. latum uteri



Tunica albuginea

Cortex ovarii - folliculi ovarii, corpora lutea

Medulla ovarii



Folliculi ovarici primarii

Folliculus ovaricus vesiculosus (Graaf) - ovum (120 μ m)

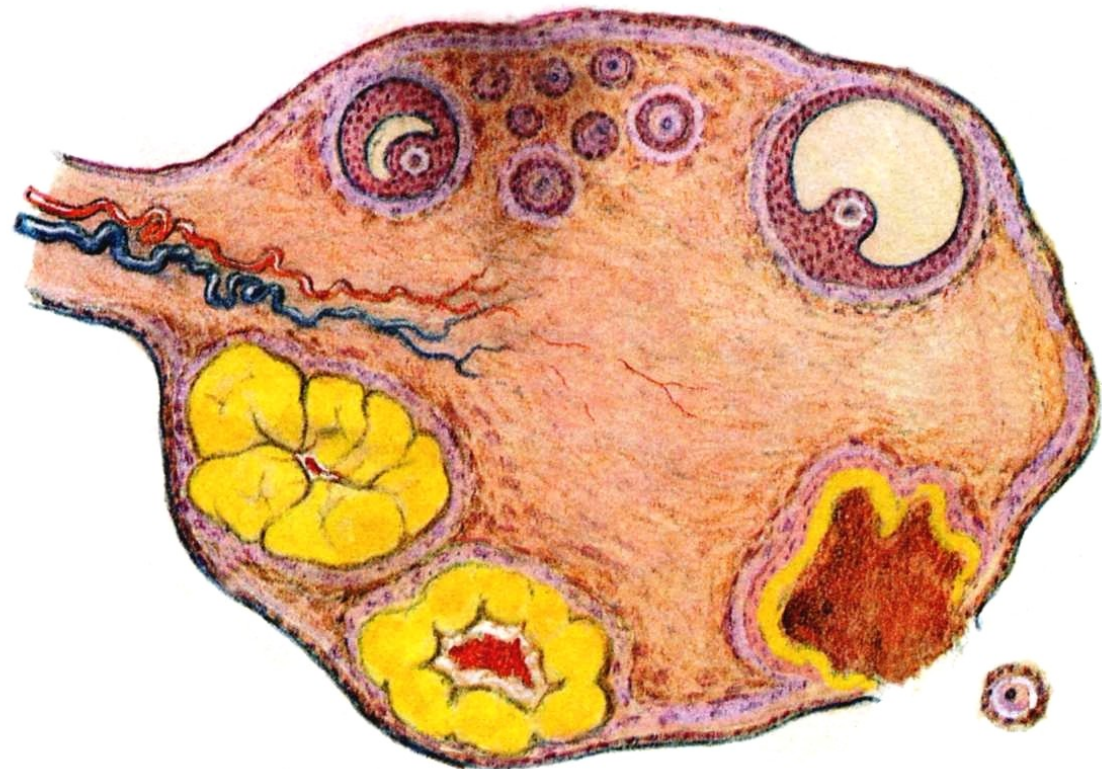
Ovulation

Corpus rubrum (hemorrhagicum)

Corpus luteum

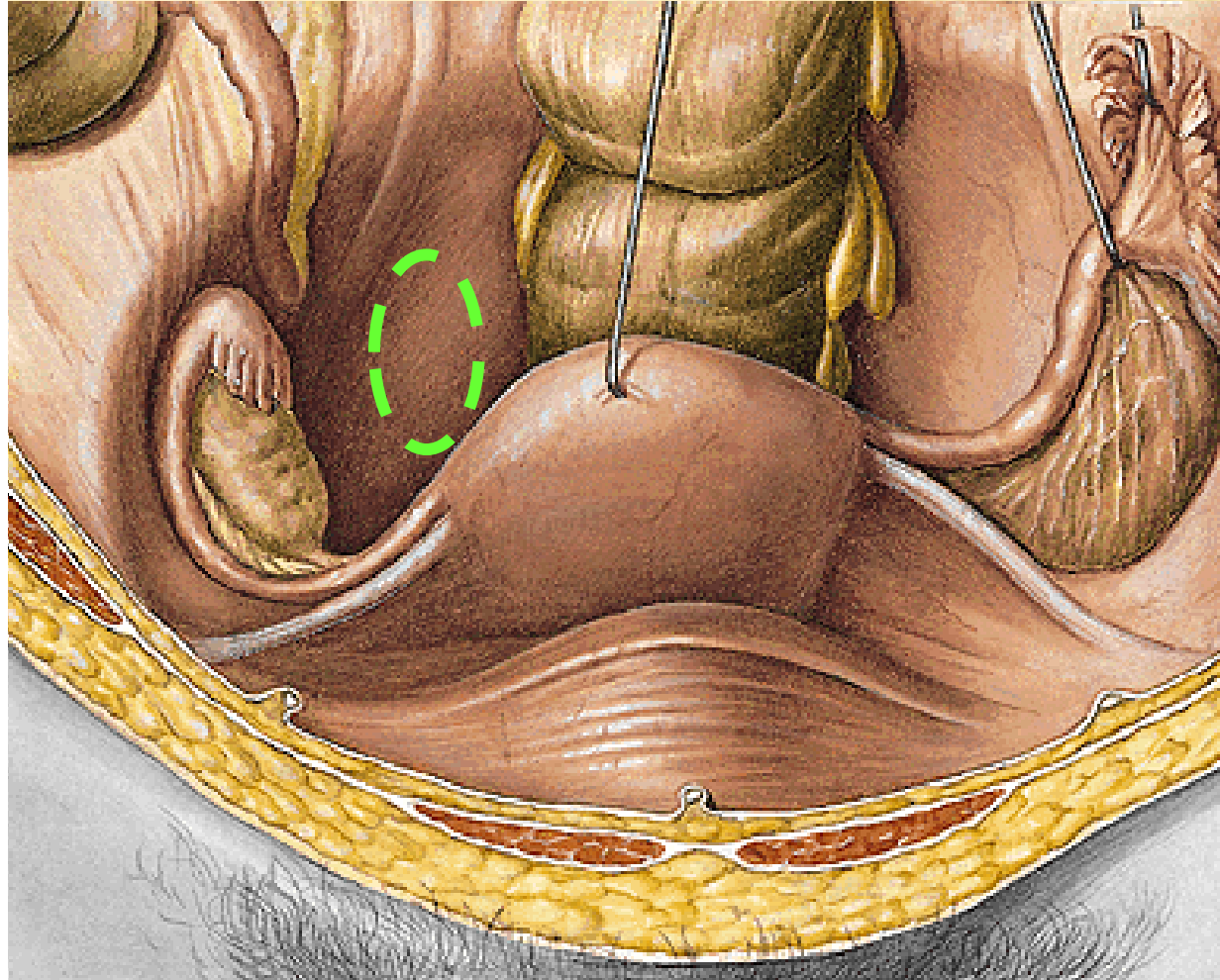
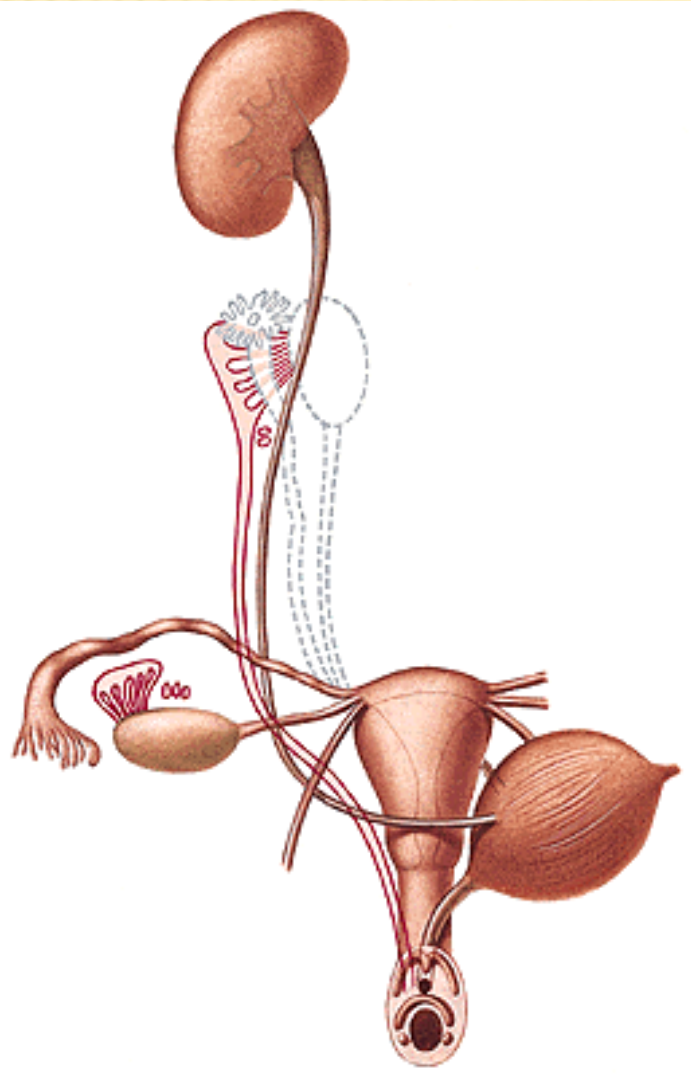
Corpus luteum graviditatis

Corpus albicans



Nullipara – fossa ovarica

Multipara – fossa of Claudius



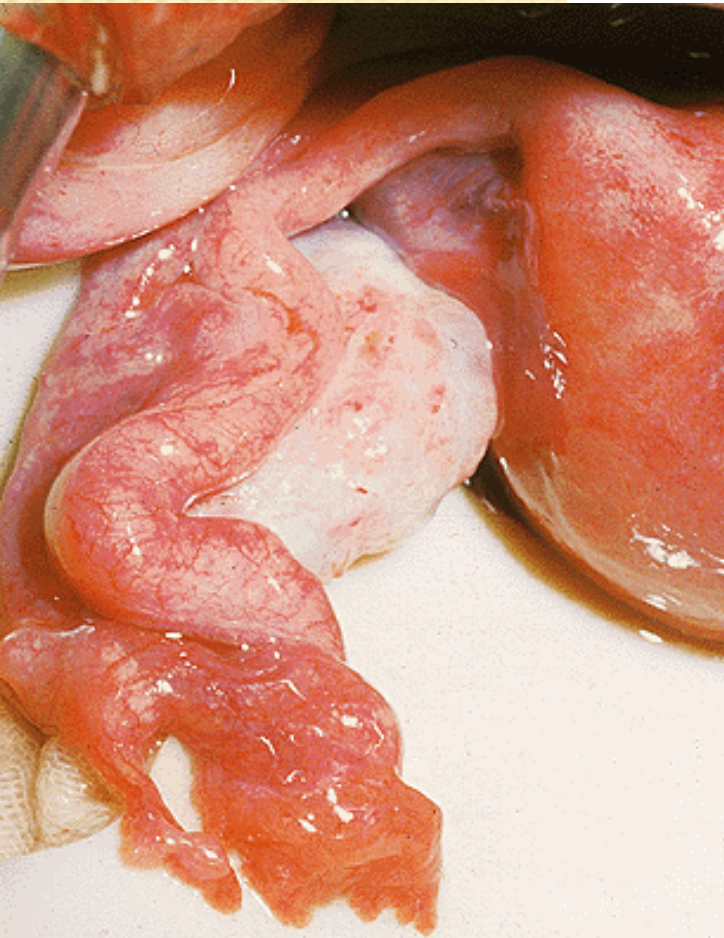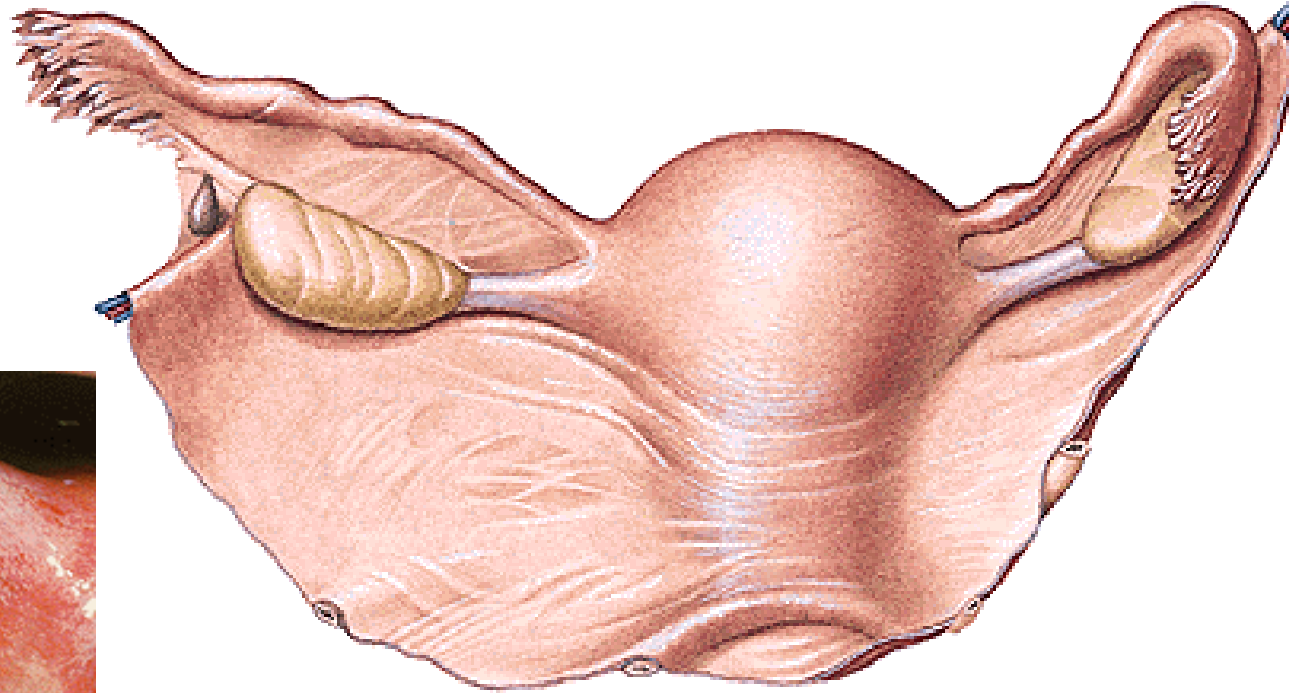
TUBA UTERINA (FALLOPIAN TUBE)

Infundibulum

Ostium abdominale

Fimbriae

Fimbria ovarica



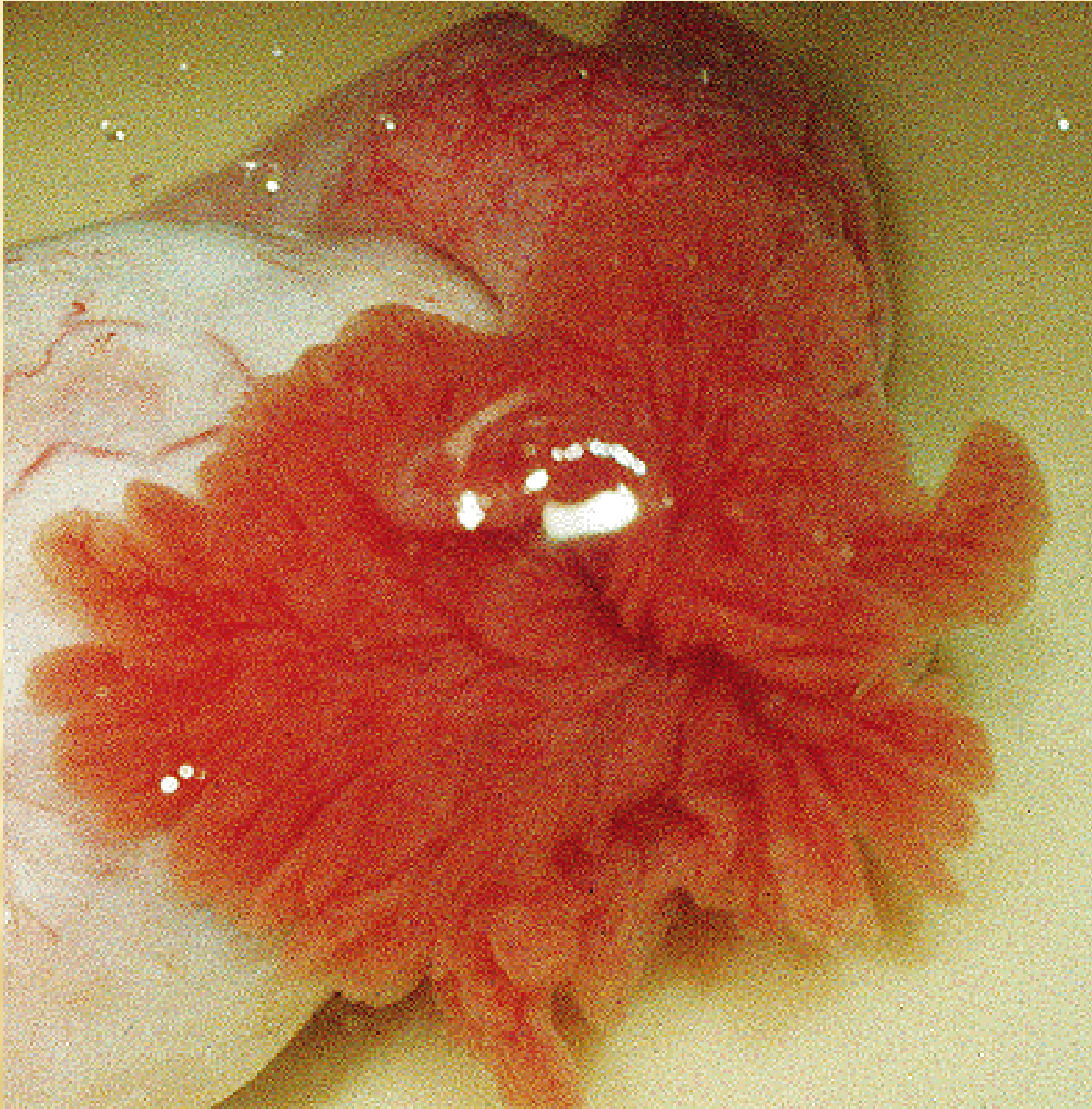Ampulla

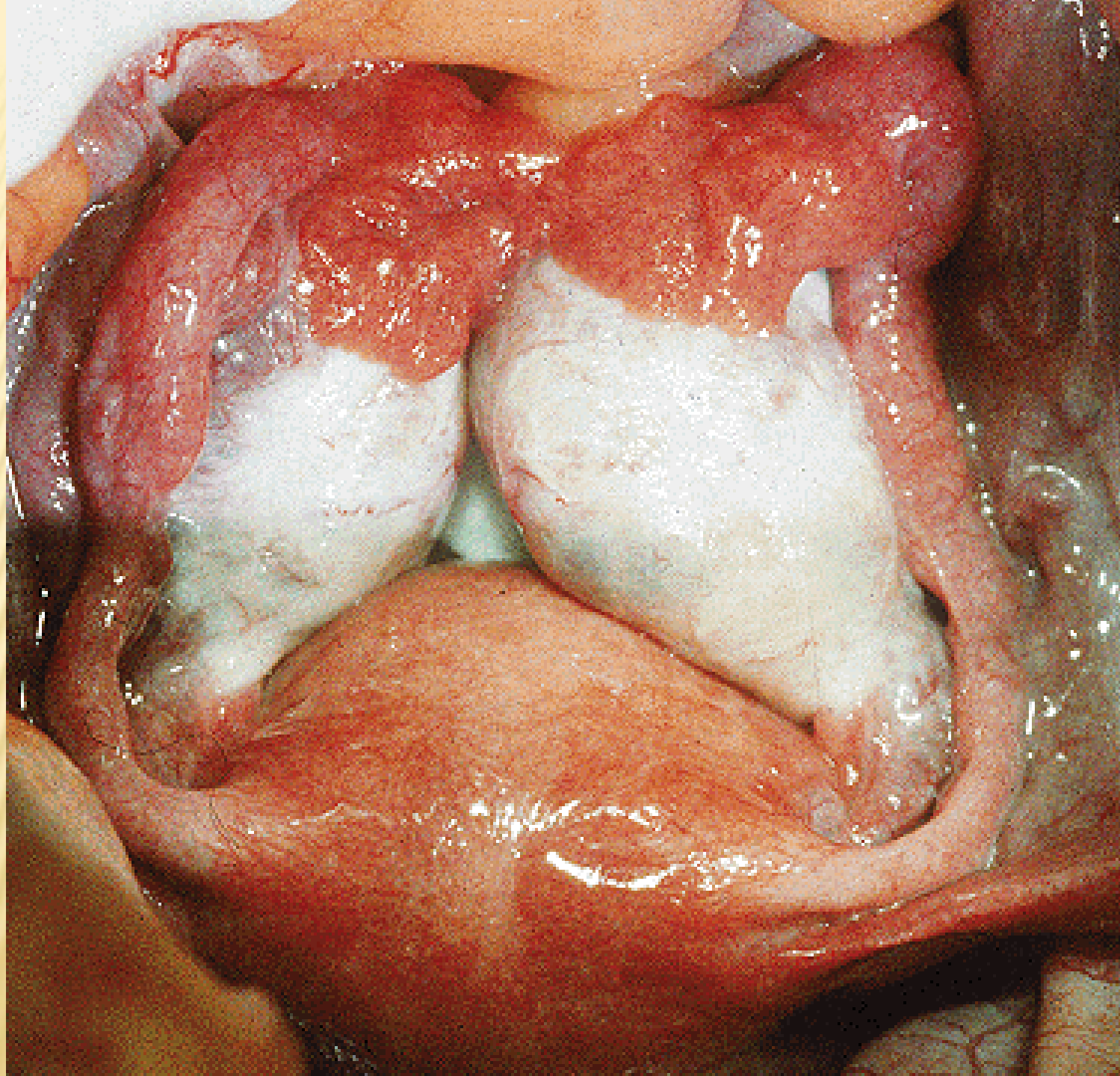
Isthmus

Pars uterina – ostium uterinum

Mesosalpinx

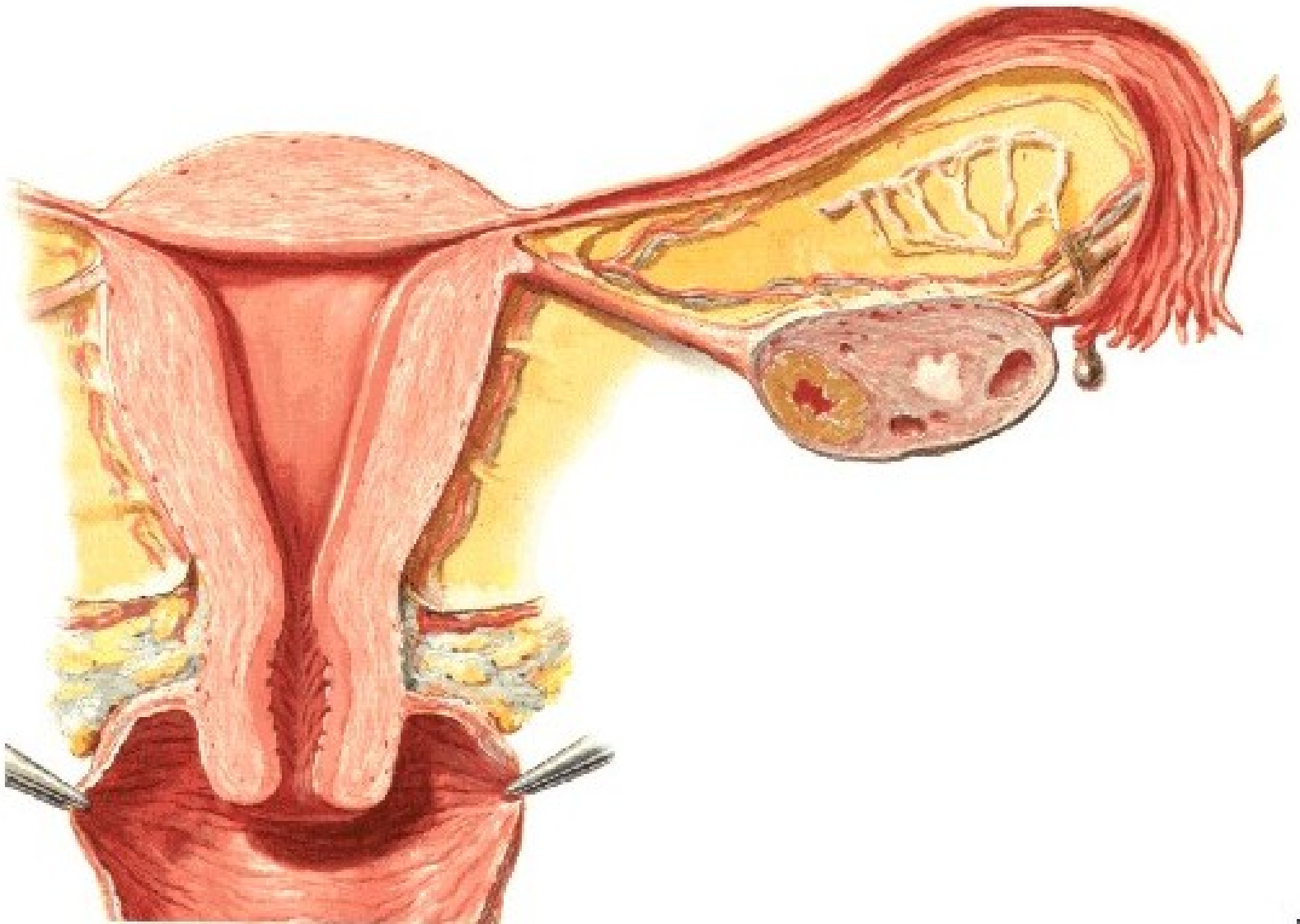
OSTIUM ABDOMINALE TUBAE UTERINAE



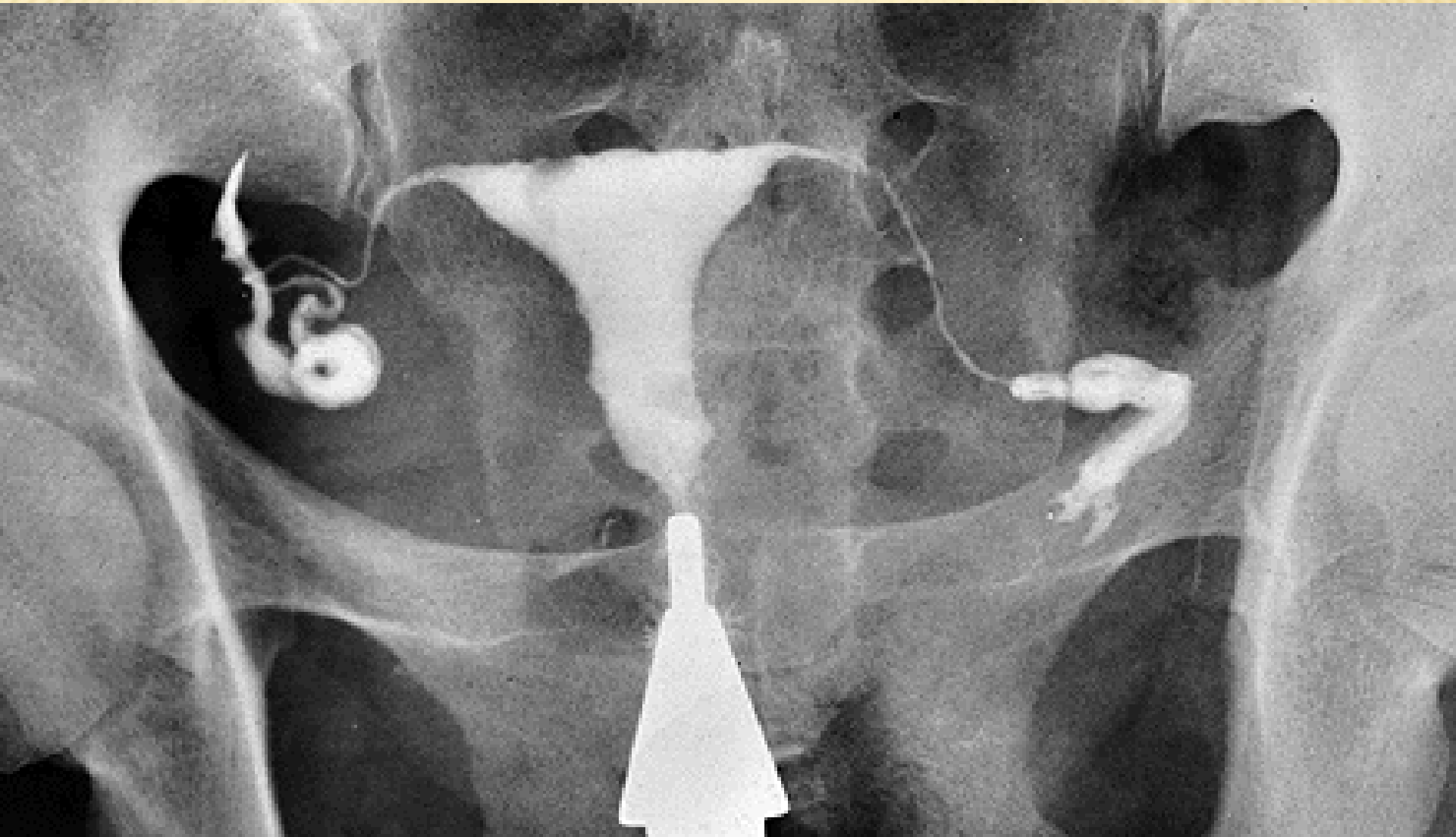


Plicae tubariae

Ectopic tubal pregnancy



HYSTEROSALPINGOGRAPHY



UTERUS (HYSTERA, METRA)

Corpus

Isthmus

Cervix - portio vaginalis

- portio supravaginalis

Fundus

Facies vesicalis

Facies intestinalis

Margo dexter et sinister

Cornu dextrum et sinistrum

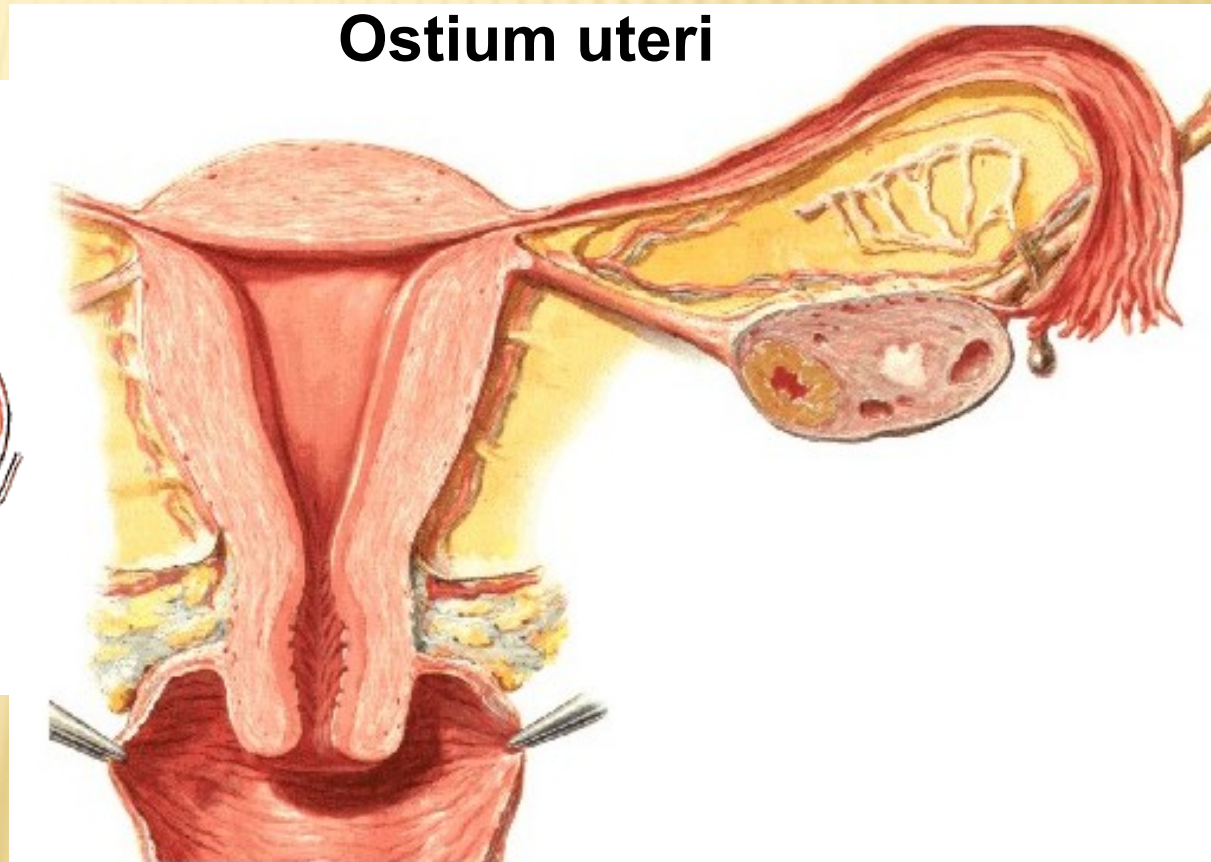
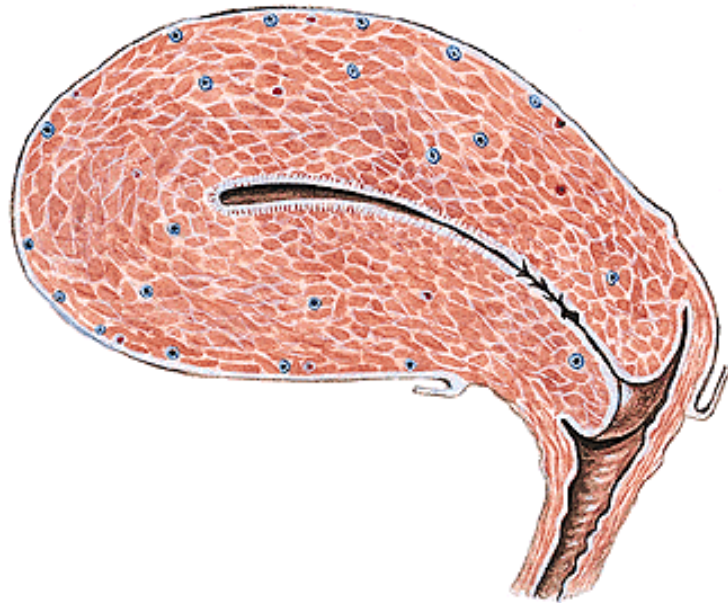Cavum uteri

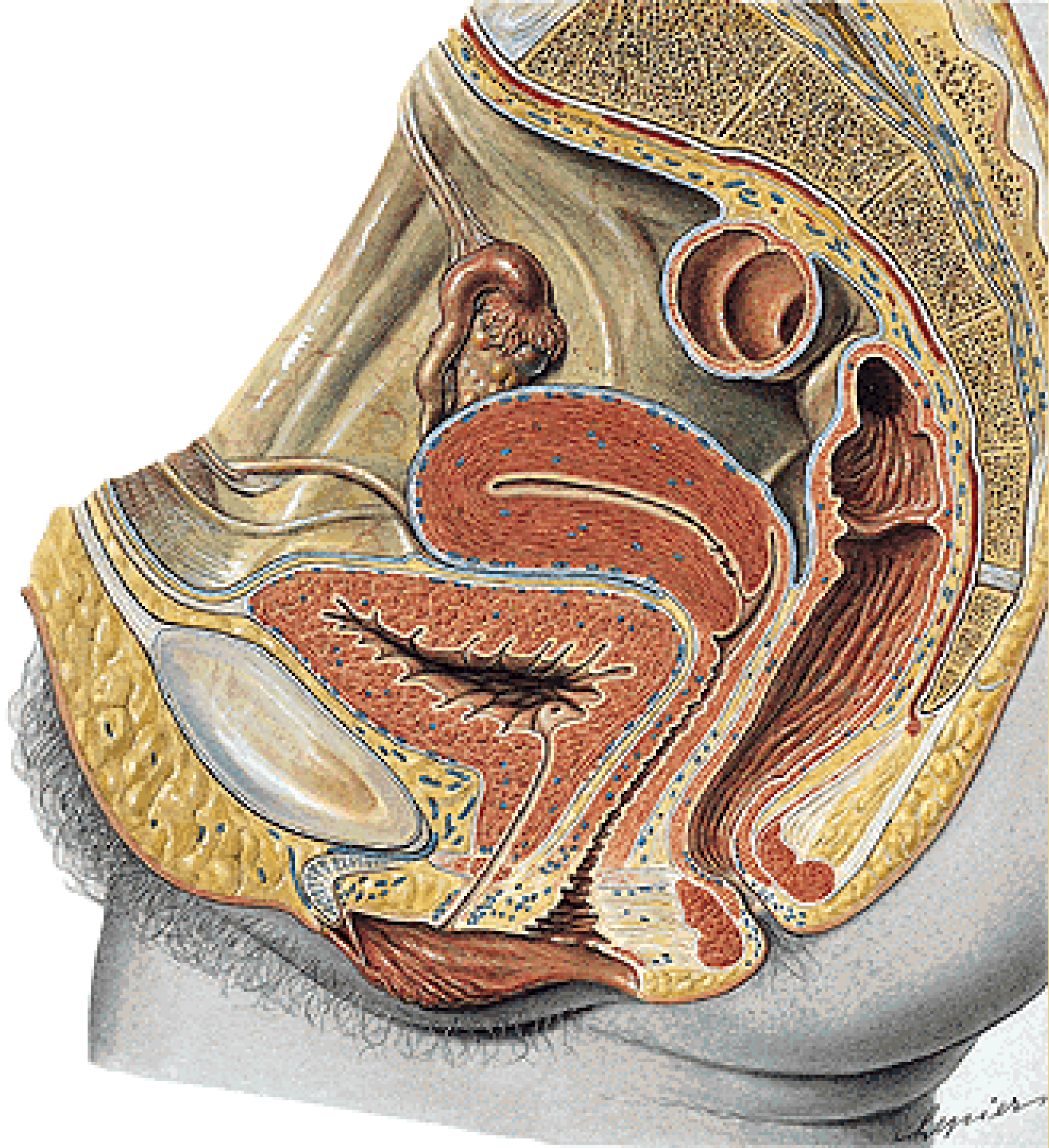
Canalis isthmi

Canalis cervicis

Plicae palmatae

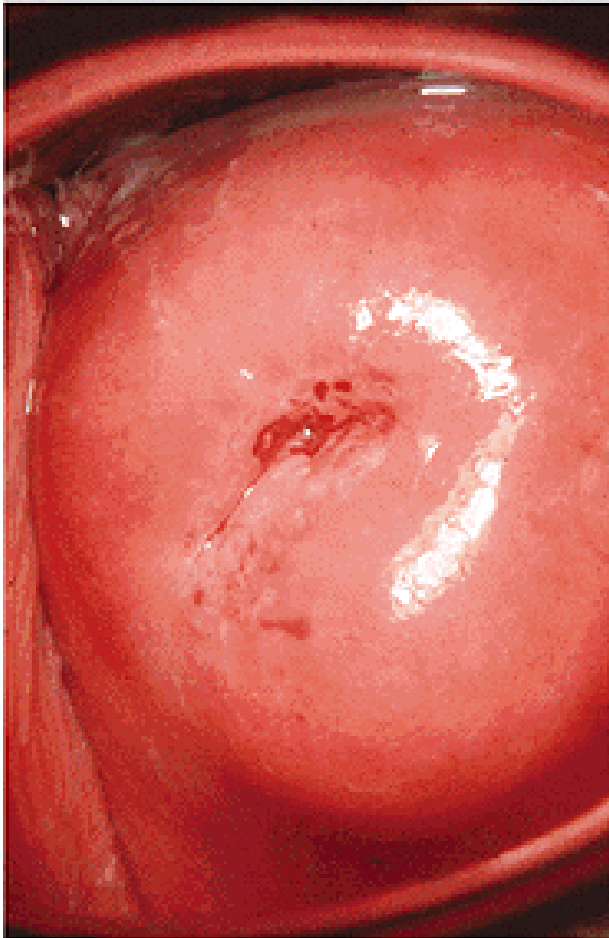
Ostium uteri



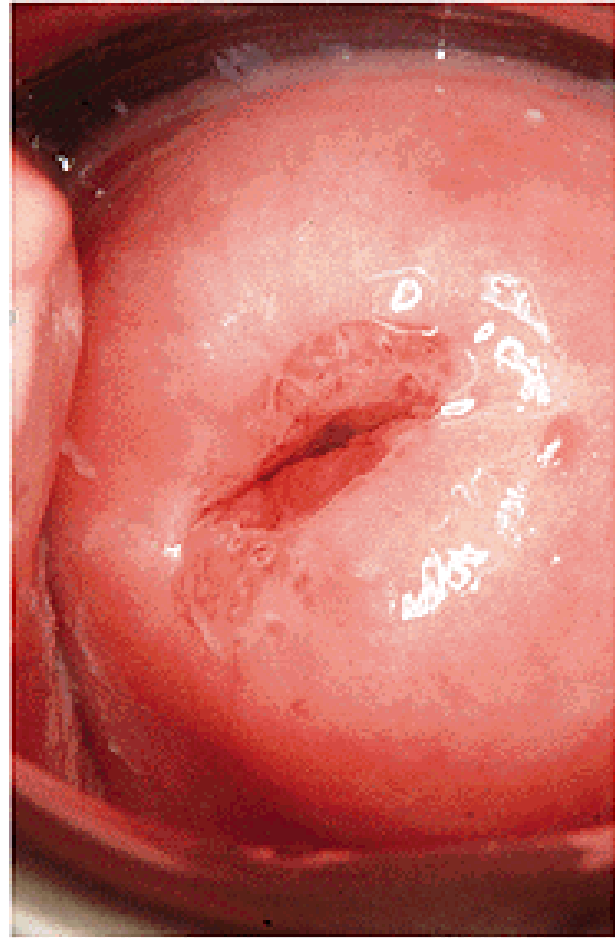

OSTIUM UTERI

NULLIPARA

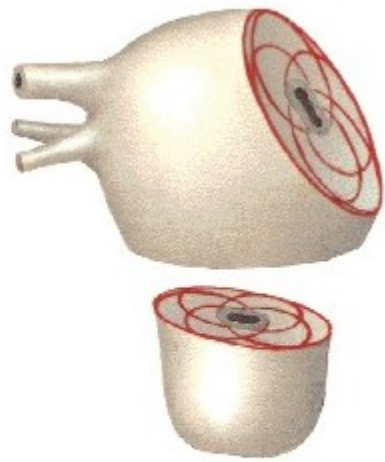
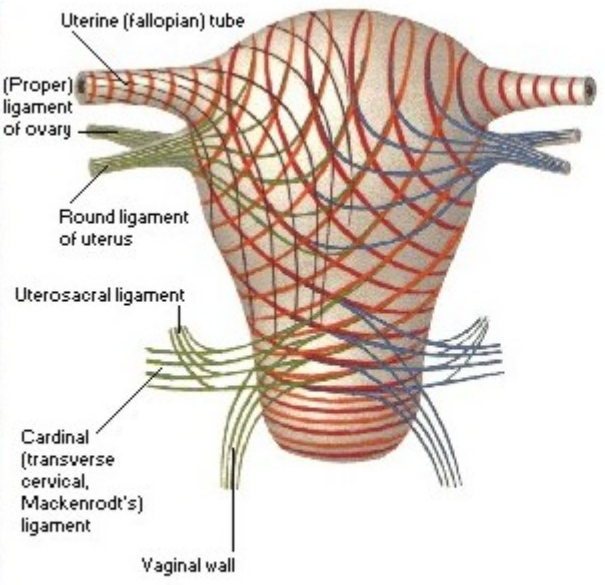
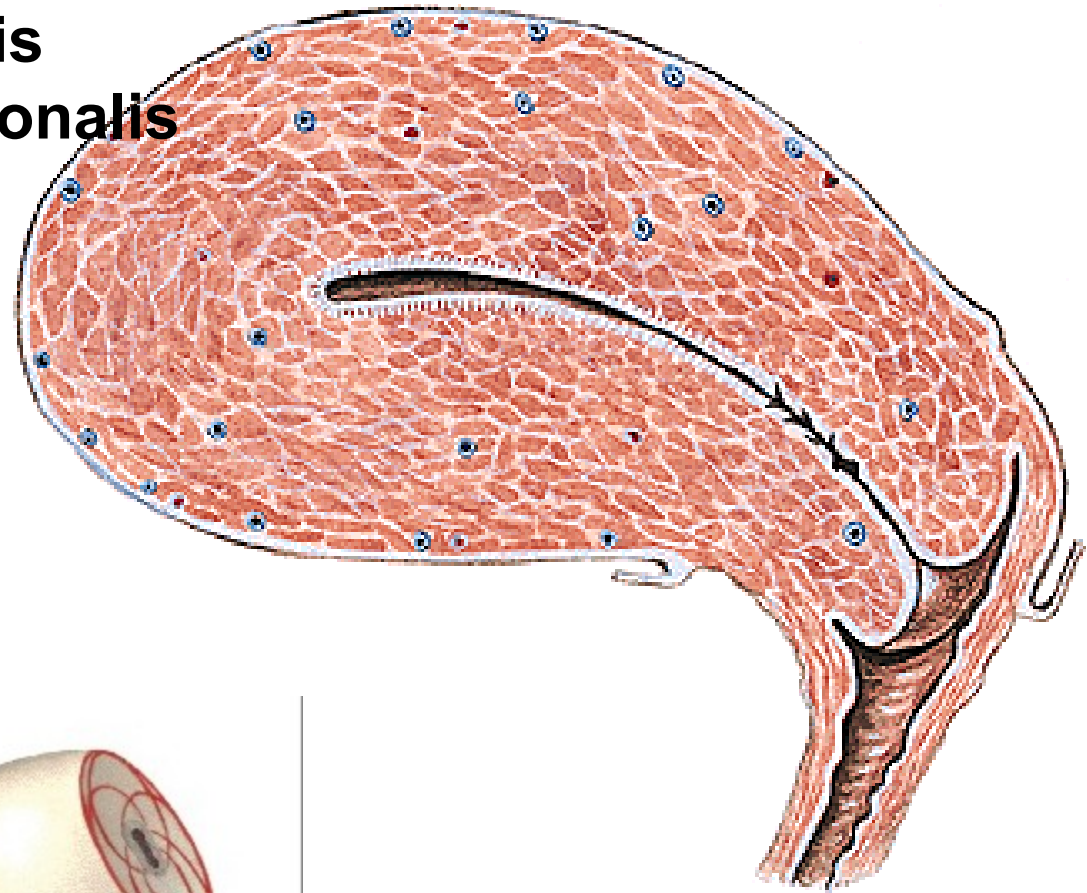


MULTIPARA



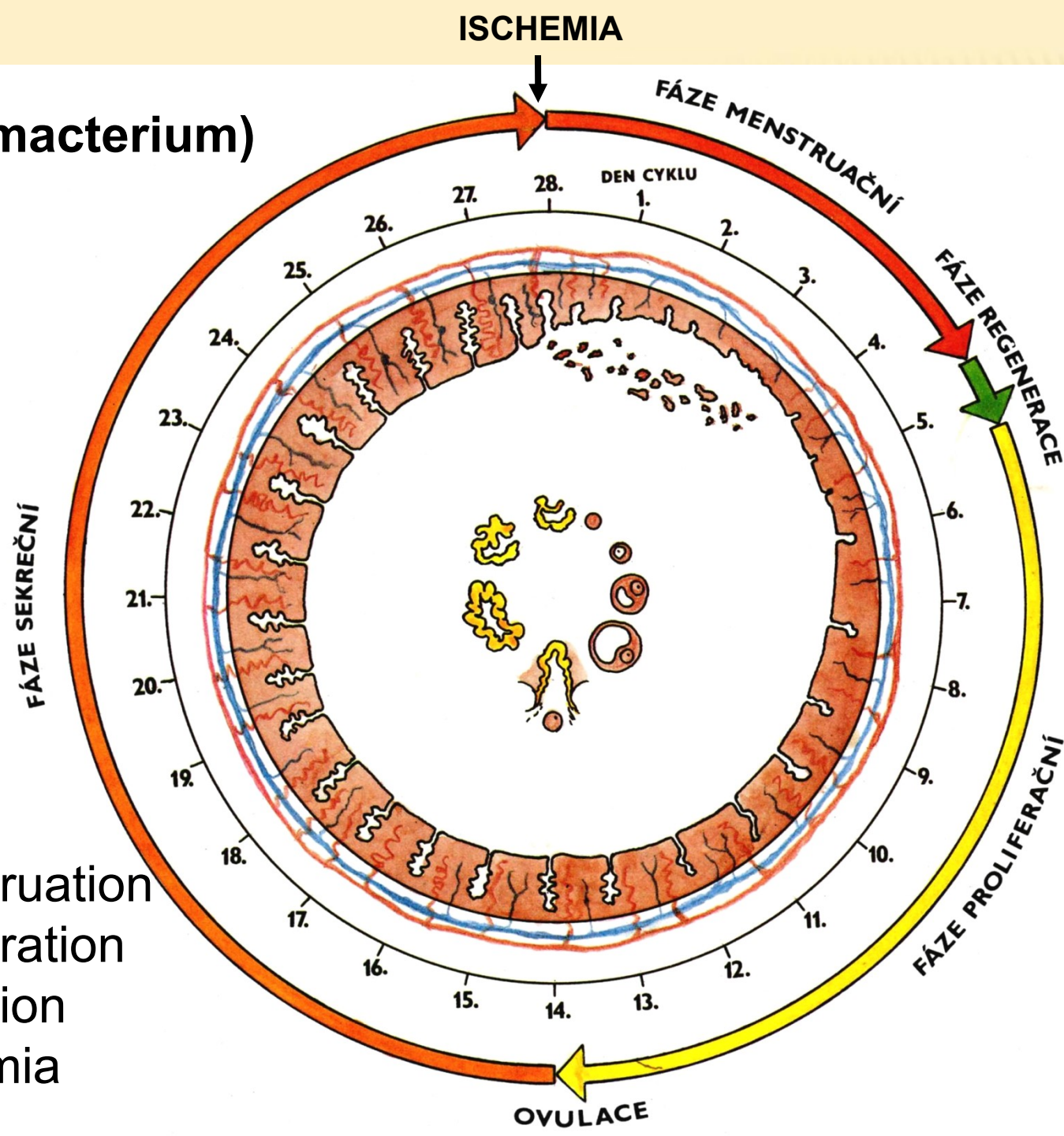
Endometrium - zona basalis - zona functionalis

- Glandulae uterinae
- Glandulae cervicales
- Myometrium



Spiral fibers pass deeply into wall and interlace (schema)

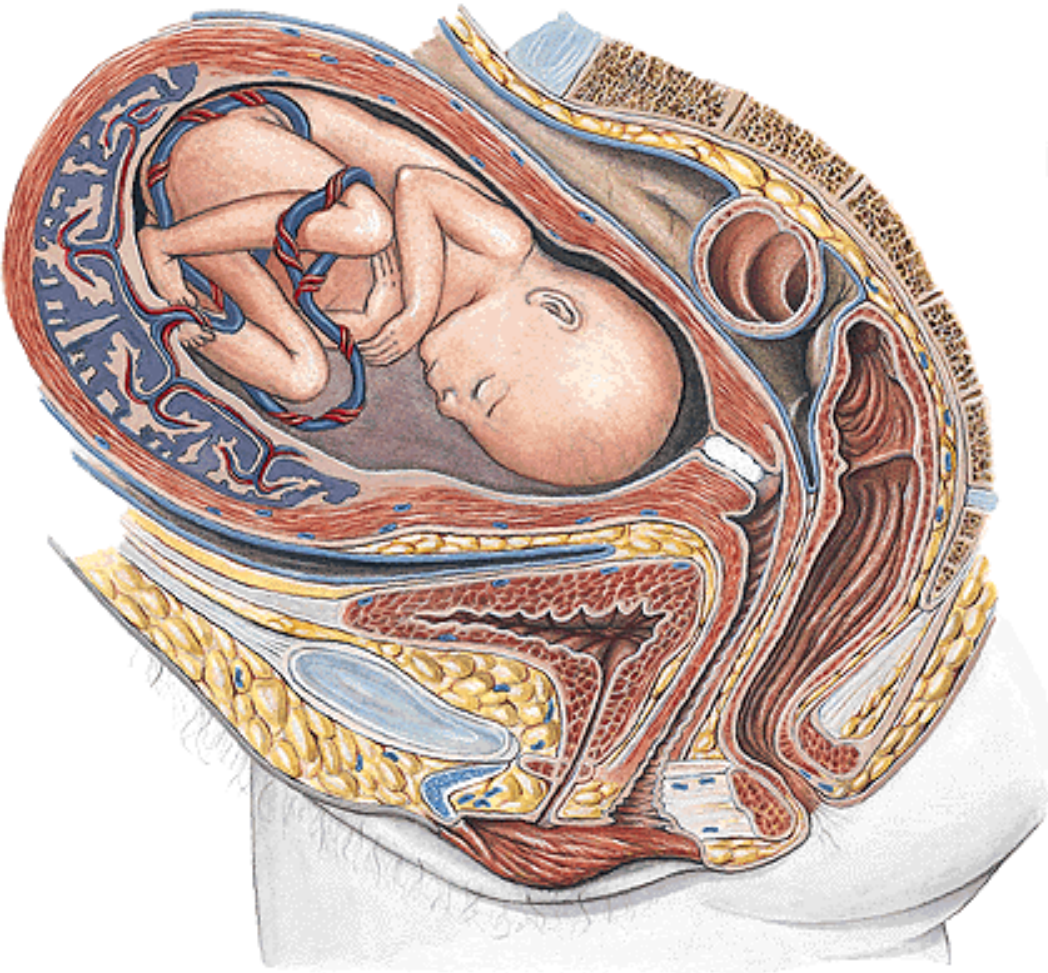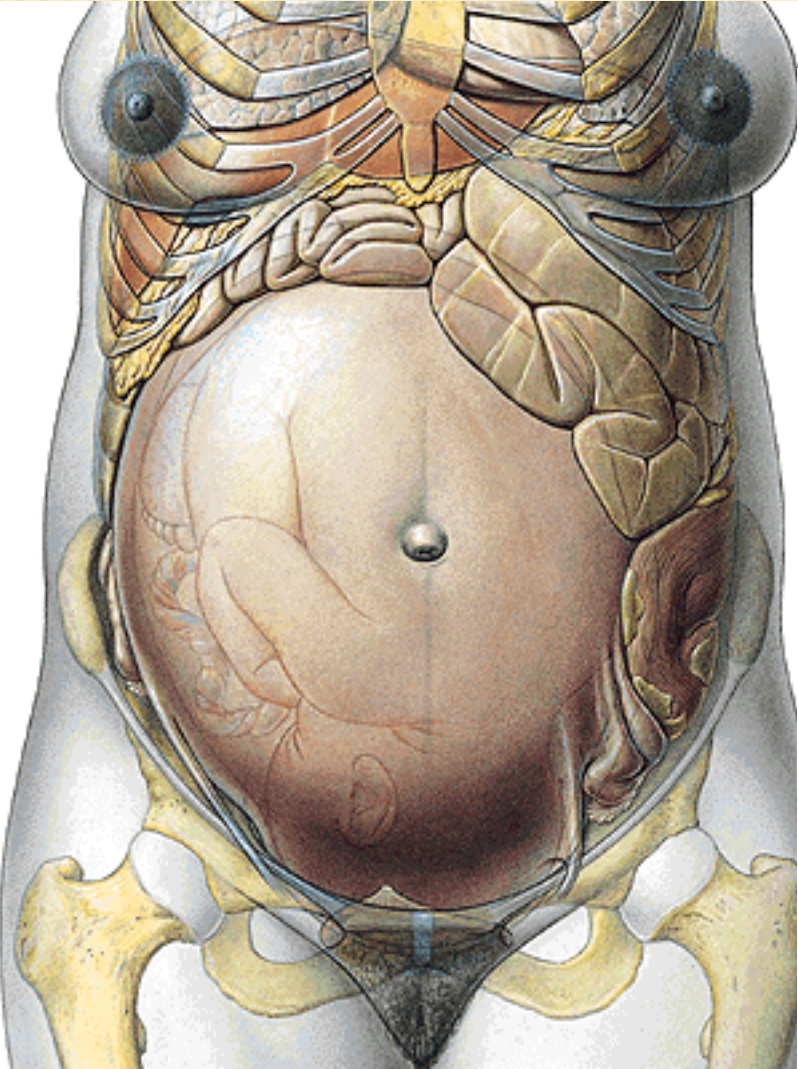
Menarche
Menopause (climacterium)

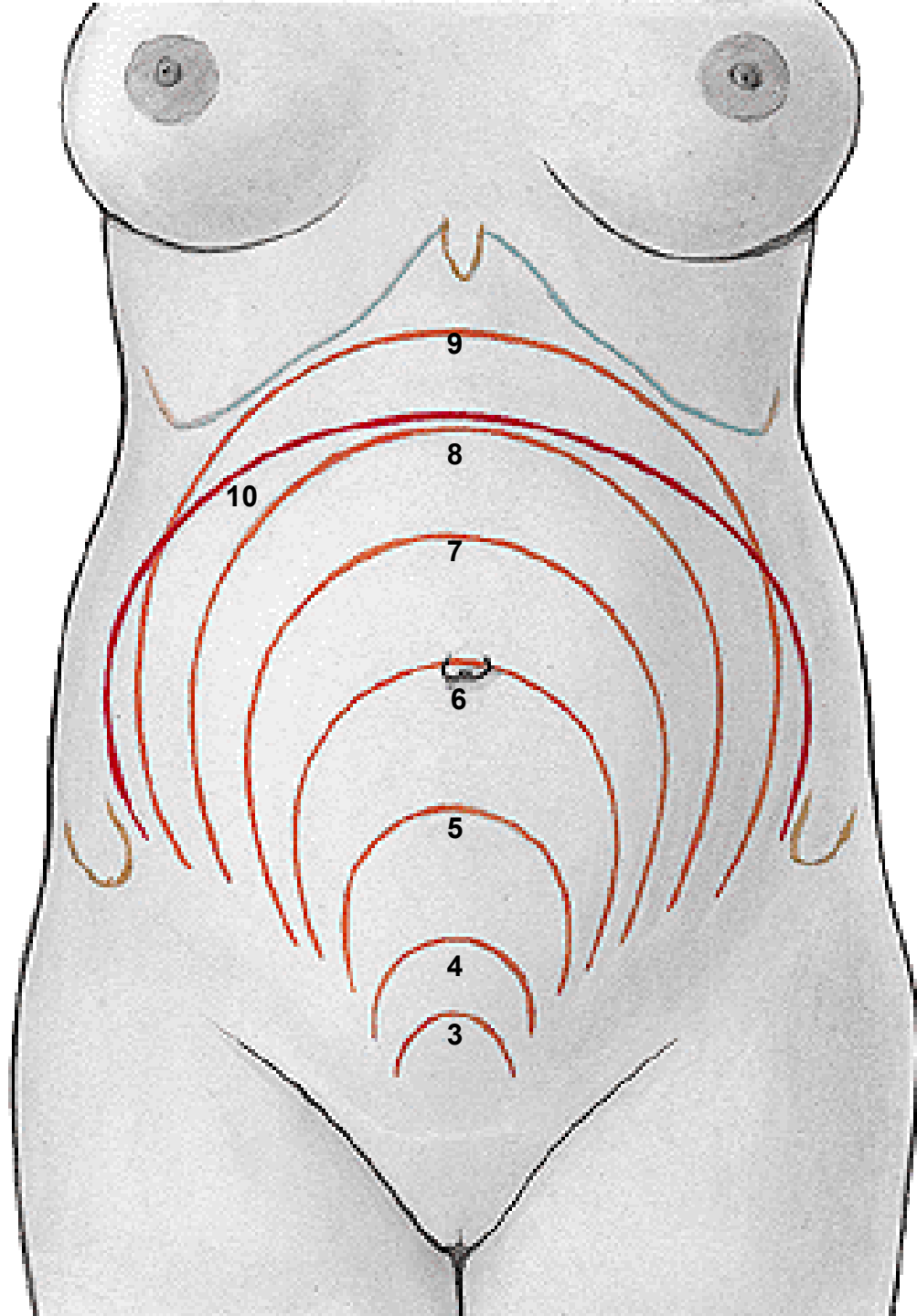


Menstrual cycle:

1. Phase of menstruation
2. Phase of proliferation
3. Phase of secretion
4. Phase of ischemia

GRAVIDITAS
Embryoblast
Trophoblast

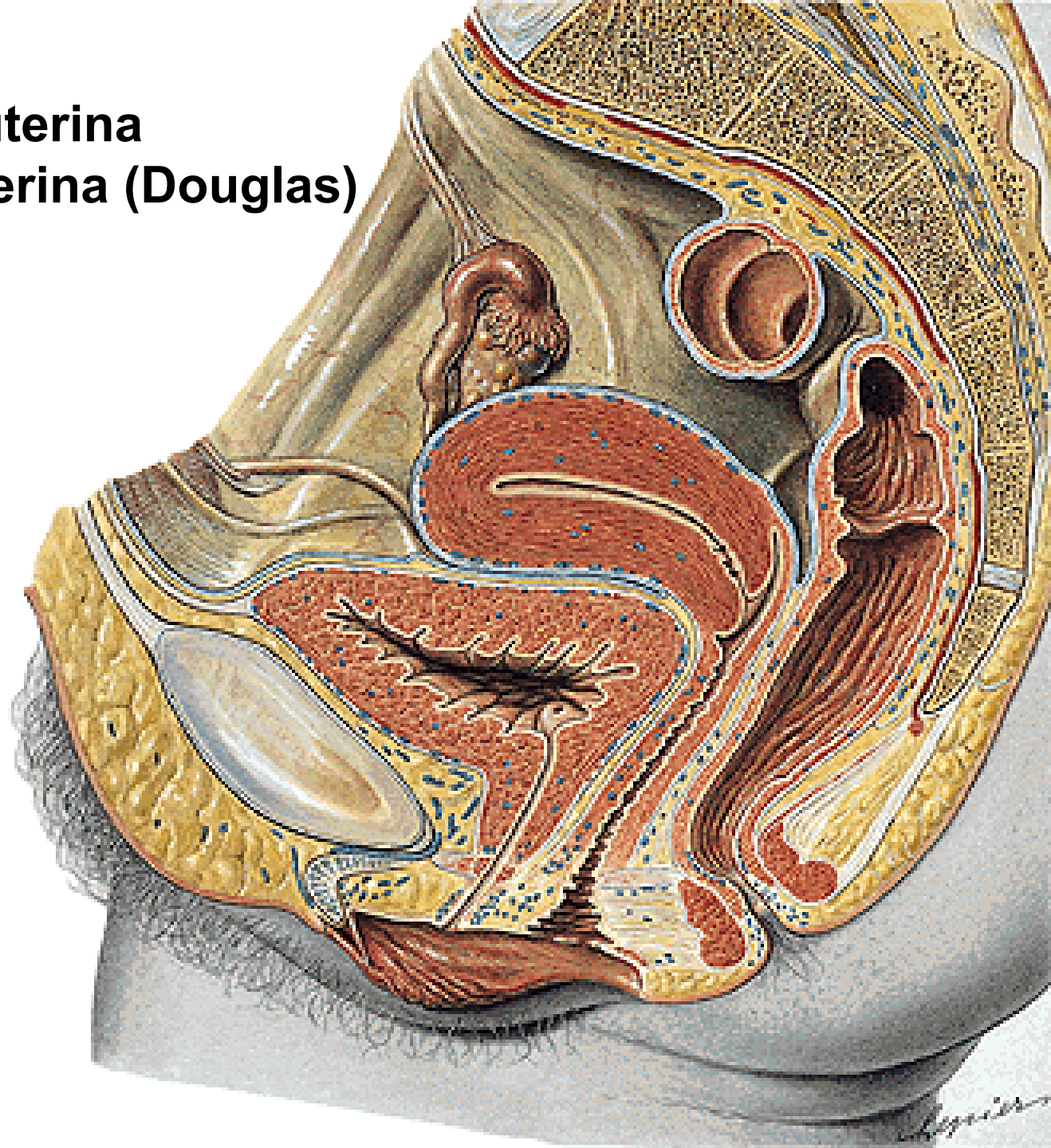




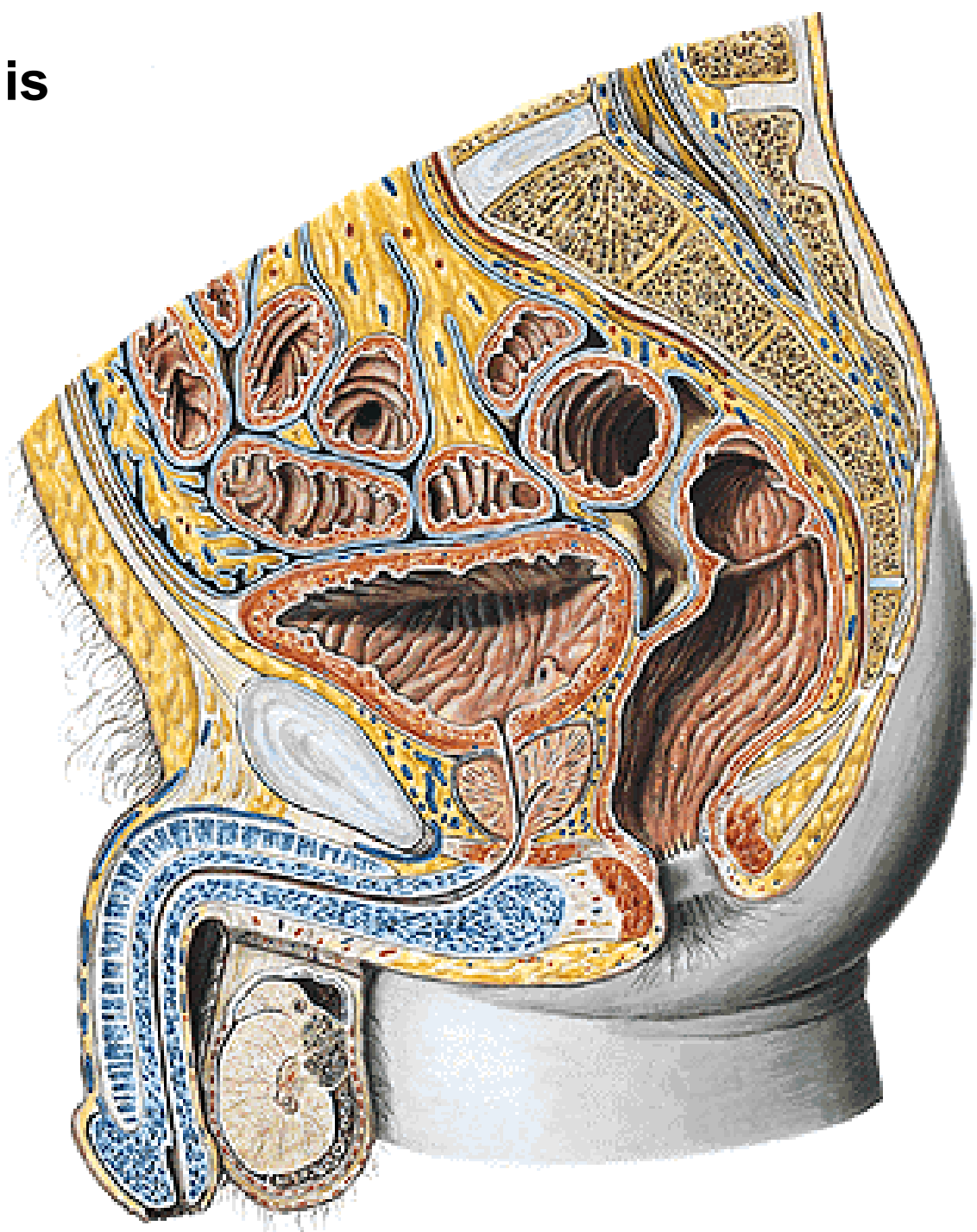
Perimetrium

Excavatio vesicouterina

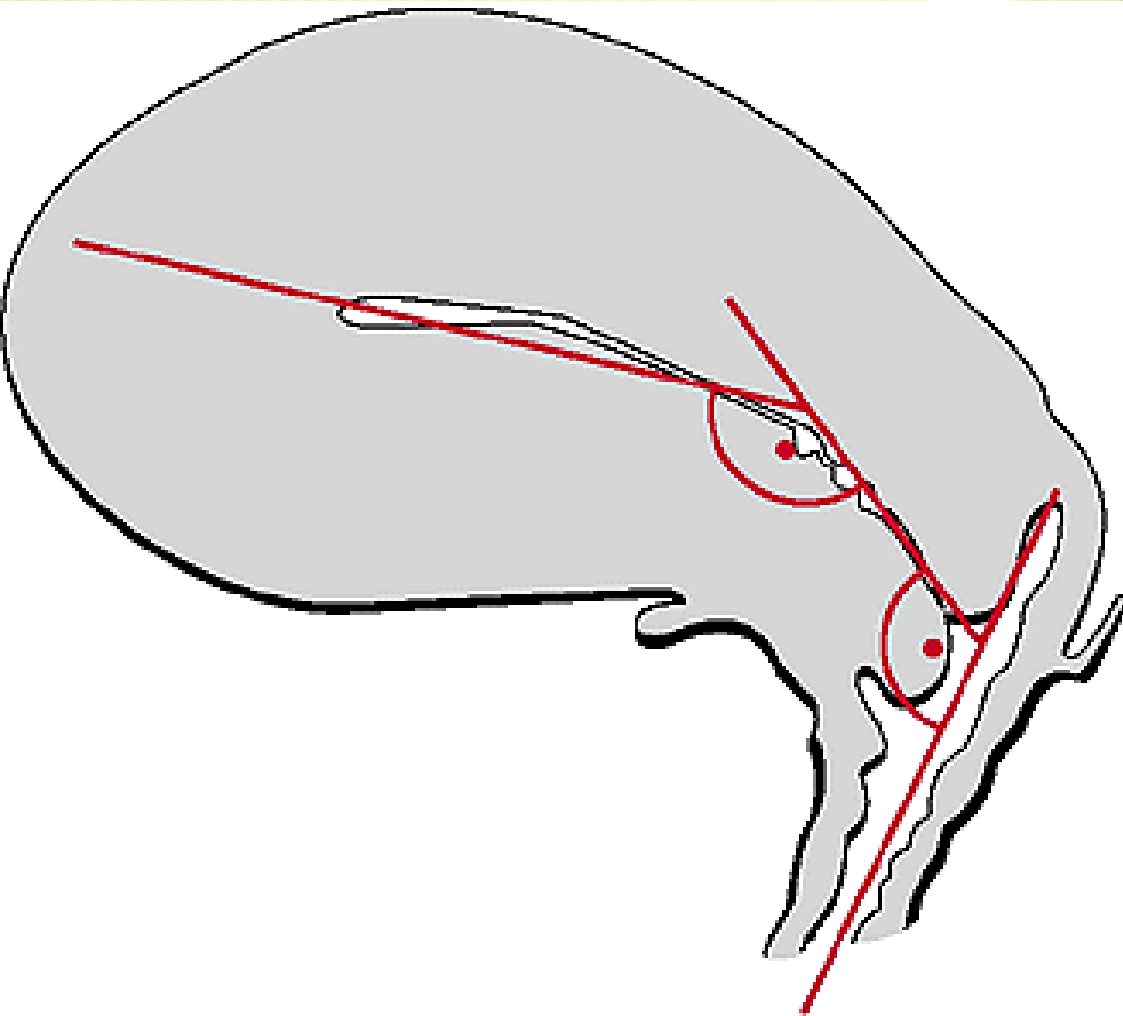
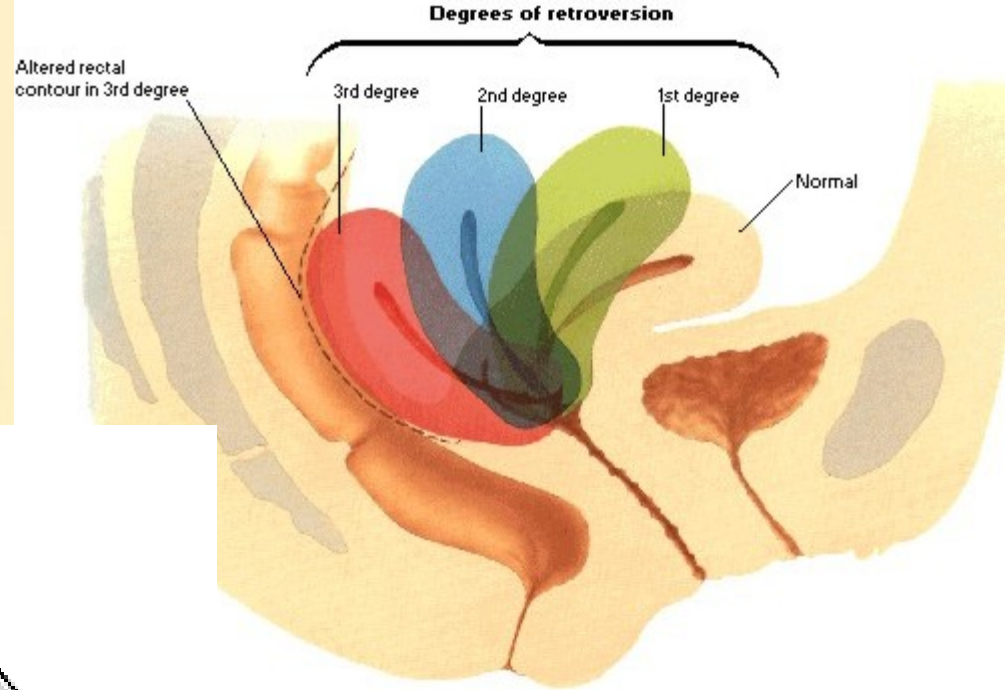
Excavatio rectouterina (Douglas)



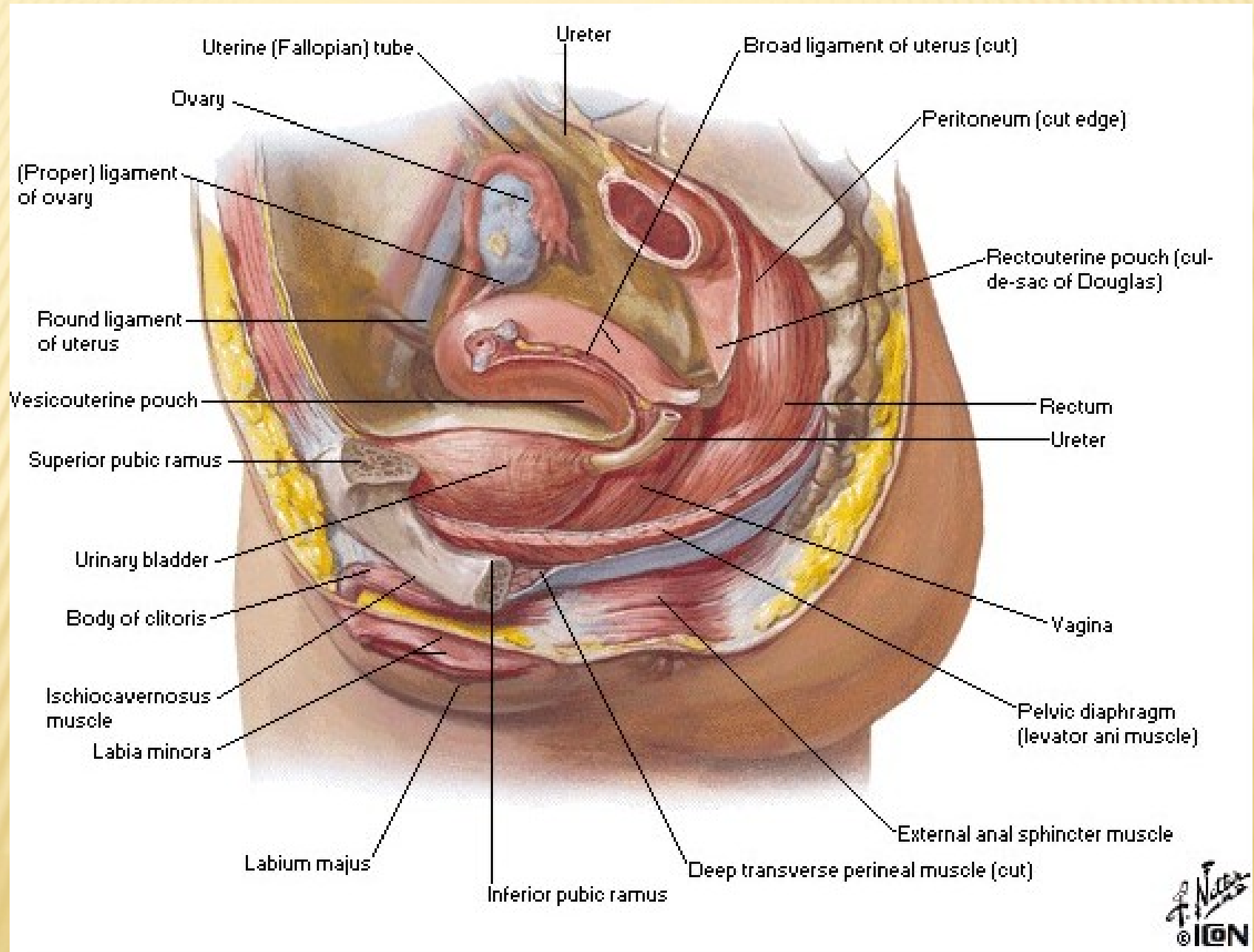
Excavatio rectovesicalis



Anteversio Anteflexio

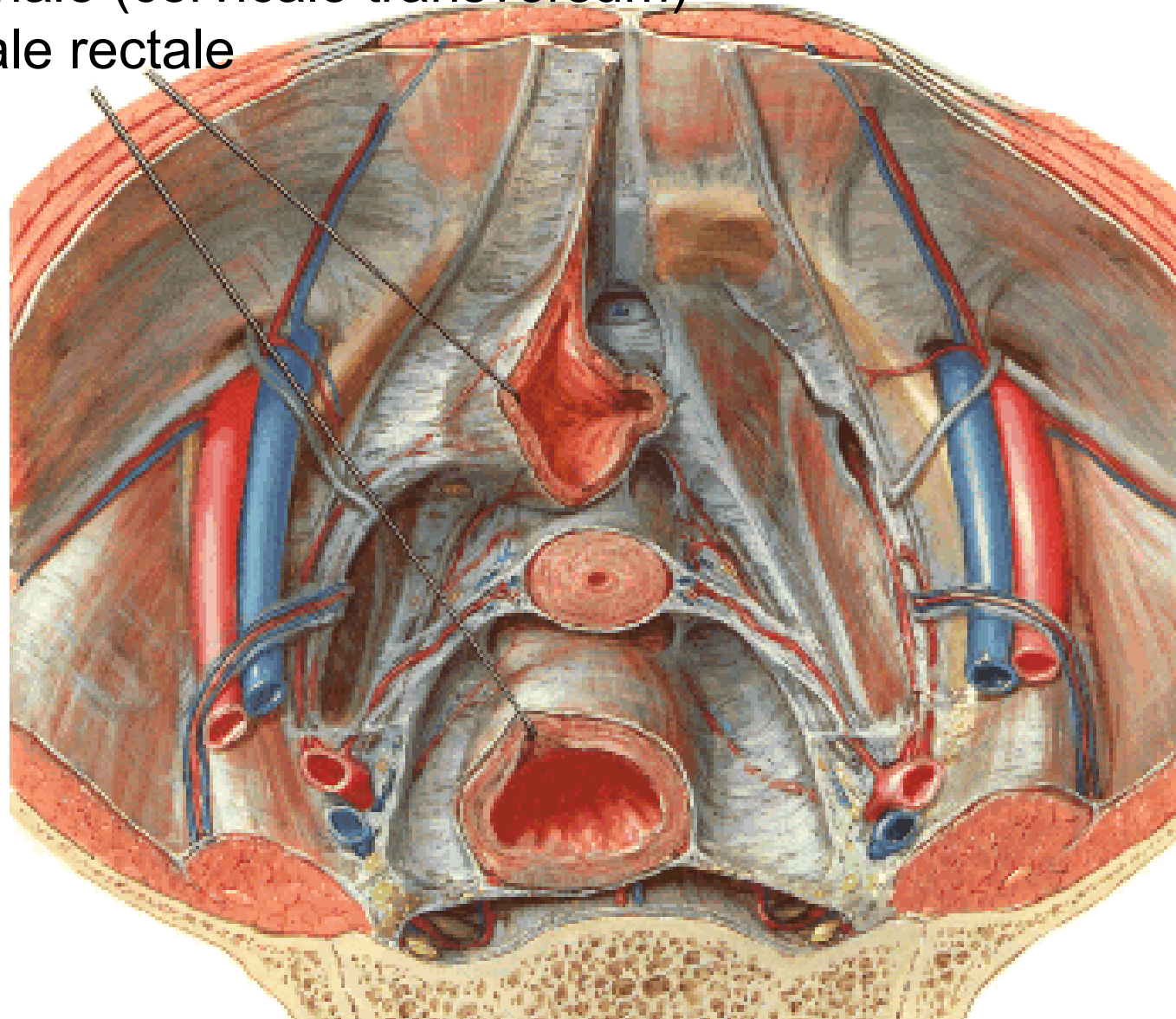


PARAMETRIUM



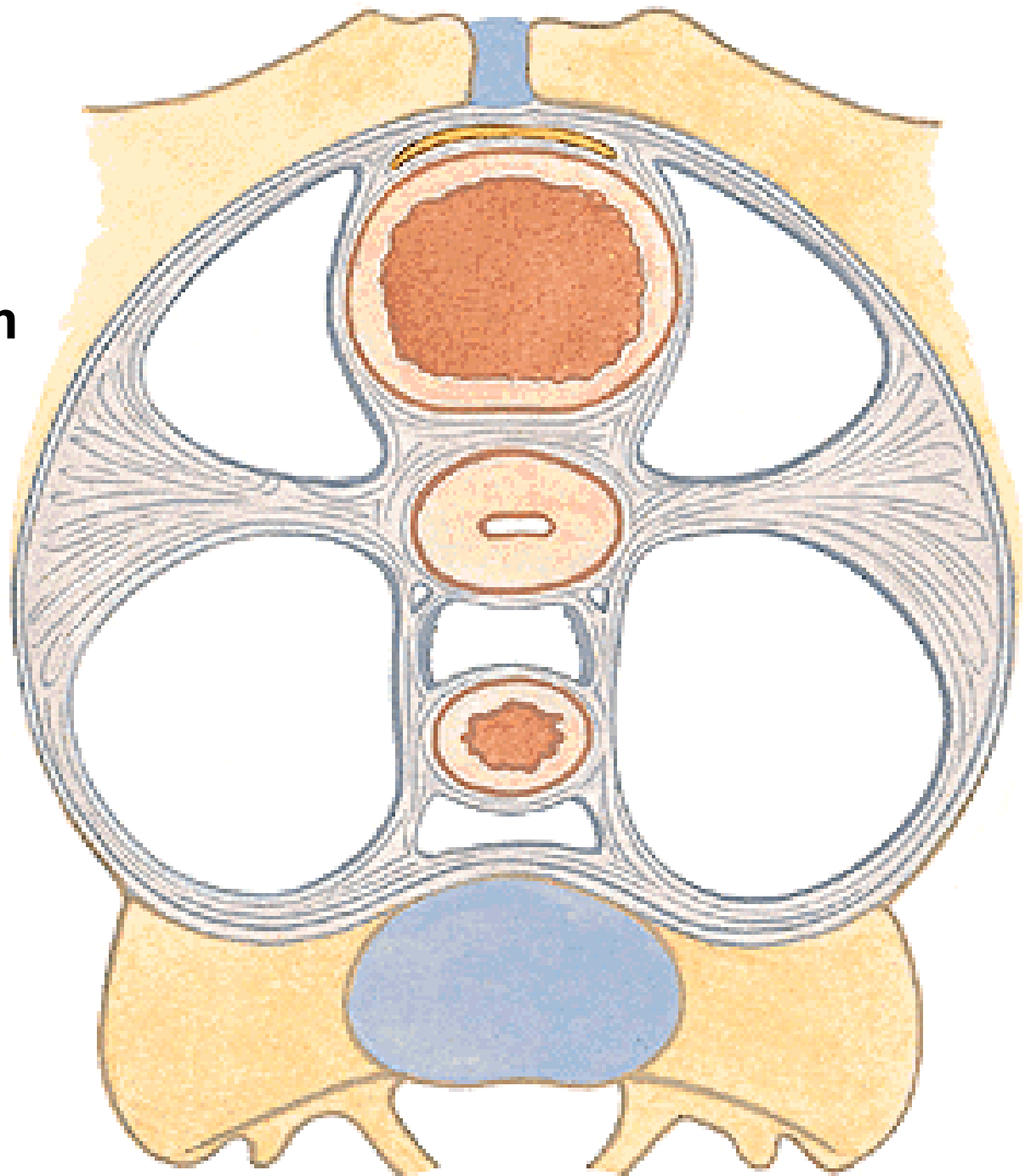
FASCIA PELVIS VISCERALIS

- ligamentum laterale vesicae urinariae
- ligamentum cardinale (cervicale transversum)
- ligamentum laterale rectale

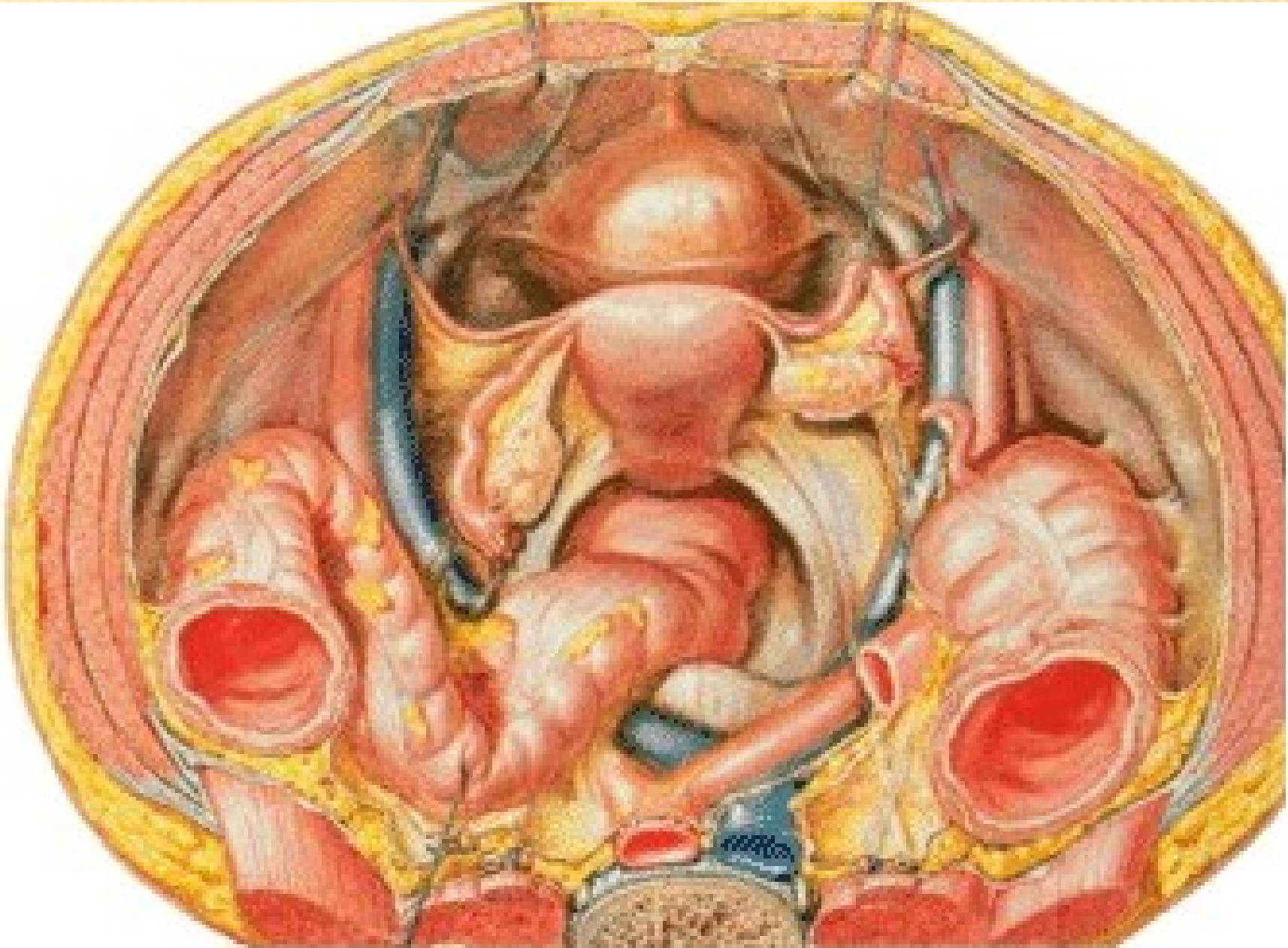


PARAMETRIUM

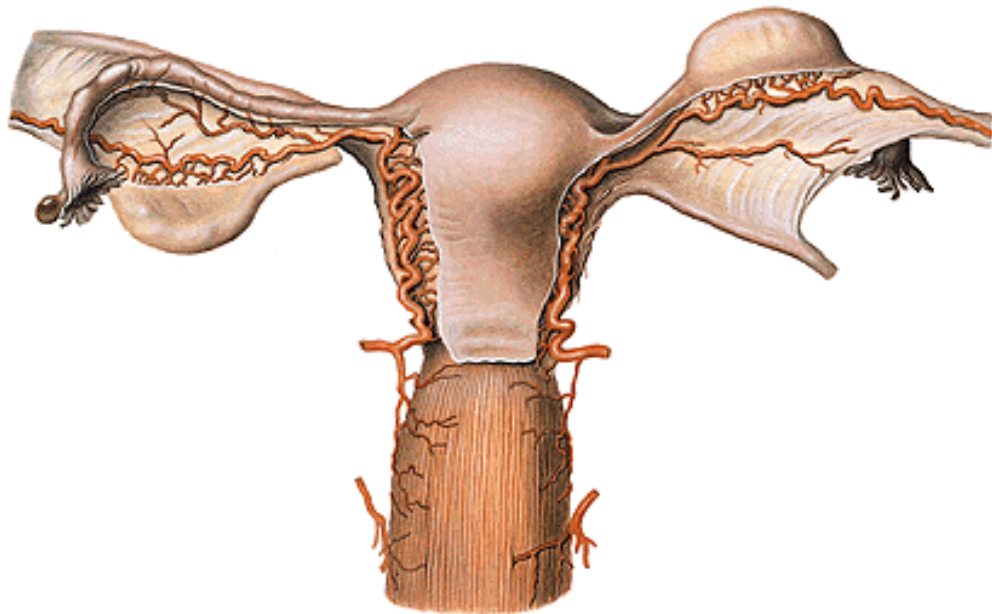
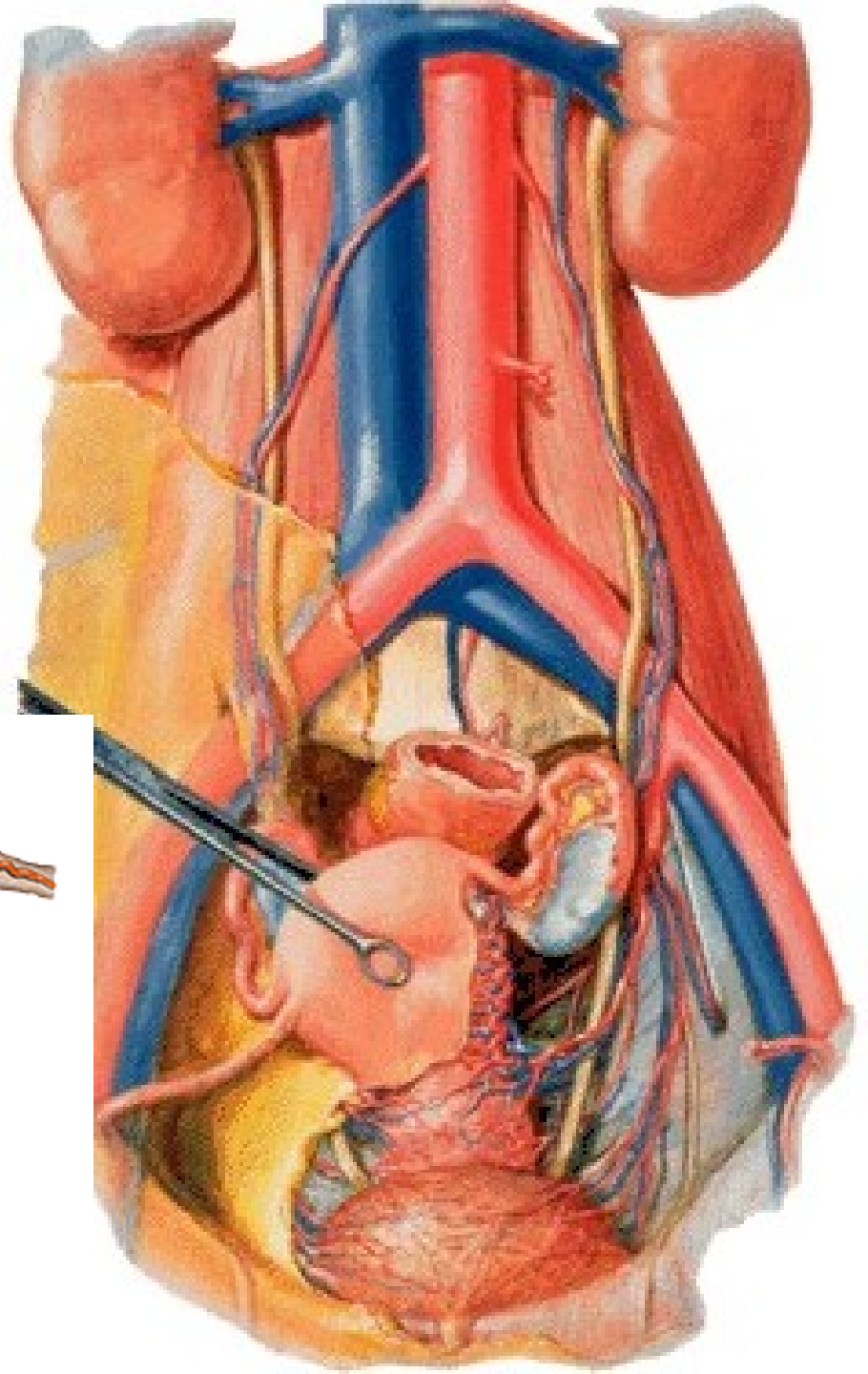
- Lig. pubocervicale
- lig. pubovesicale
- lig. vesicouterinum
- Lig. sacrouterinum
(m. rectouterinus)



Plica sacrouterina
Lig. teres uteri

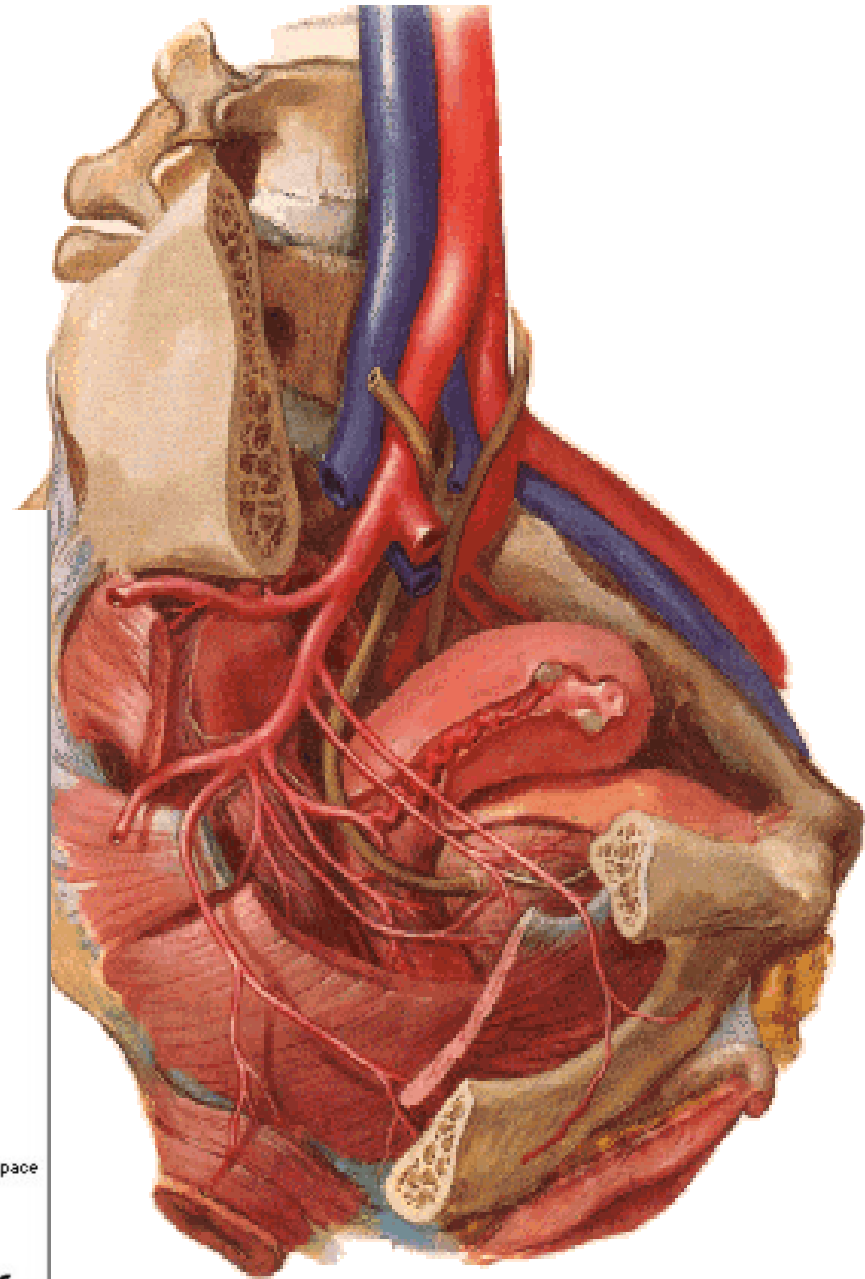
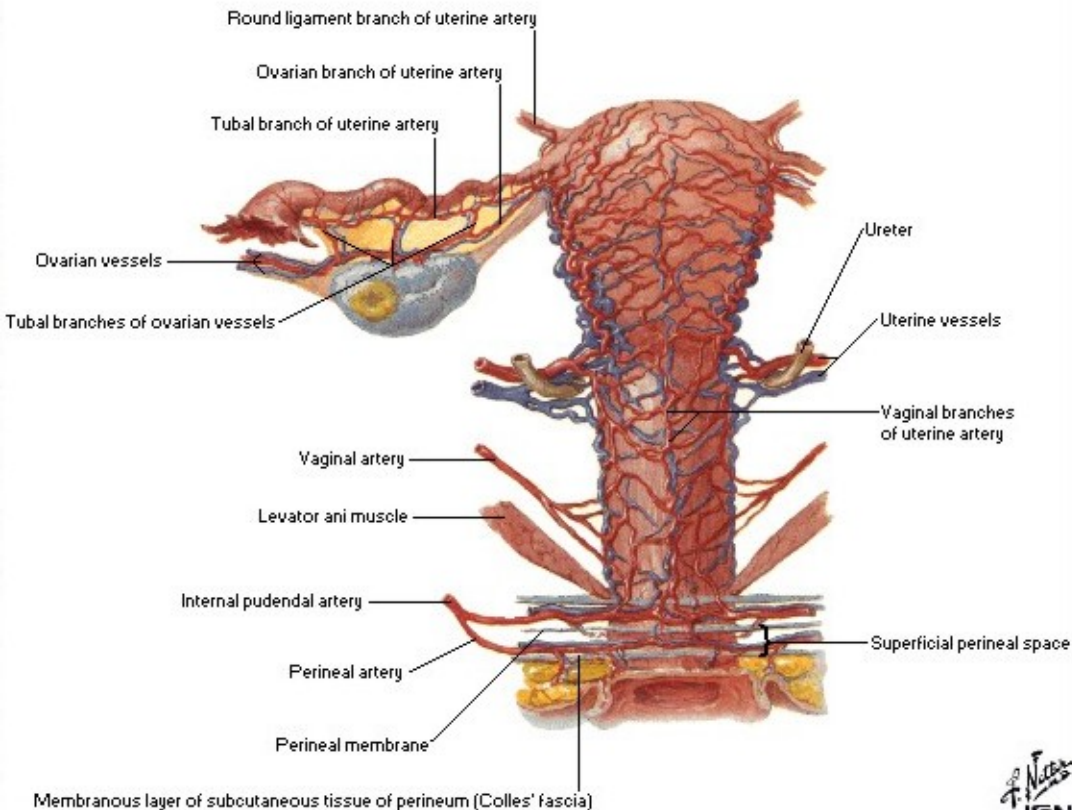


A. uterina x ureter



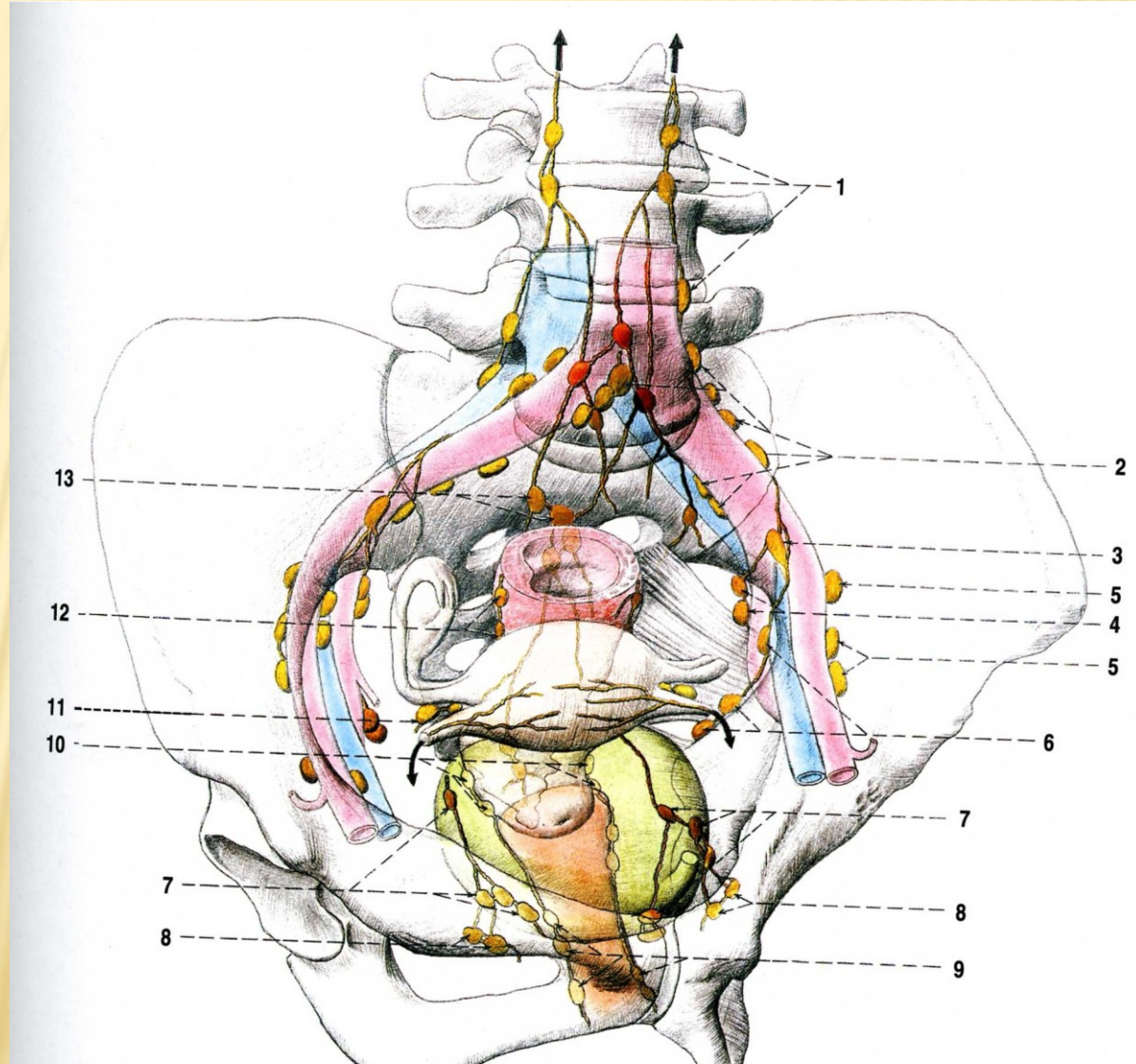
A. UTERINA

- r. uretericus
- rr. vaginales
- rr. heliциni
- r. tubarius
- r. ovaricus



Lymphatic drainage of the uterus

**NII. lumbales,
iliaci int., nodus lymph. uterinus (Bayer),
iliaci ext.,
inguinales spf.,
sacrales**



VAGINA (COLPOS)

Ostium vaginae

Vestibulum vaginae

Paries anterior

Paries posterior

Rugae vaginales

Columna rugarum ant.

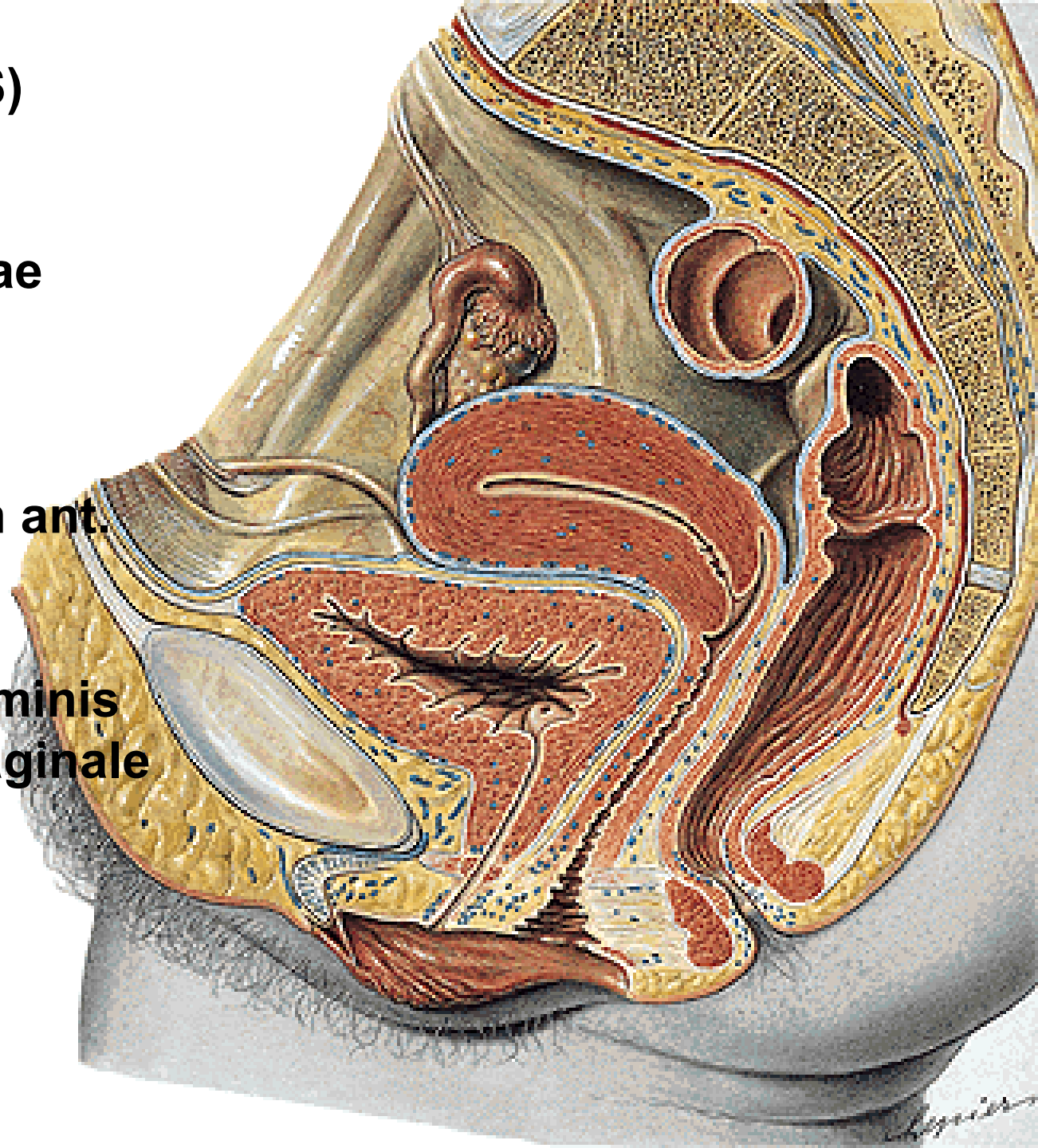
et posterior

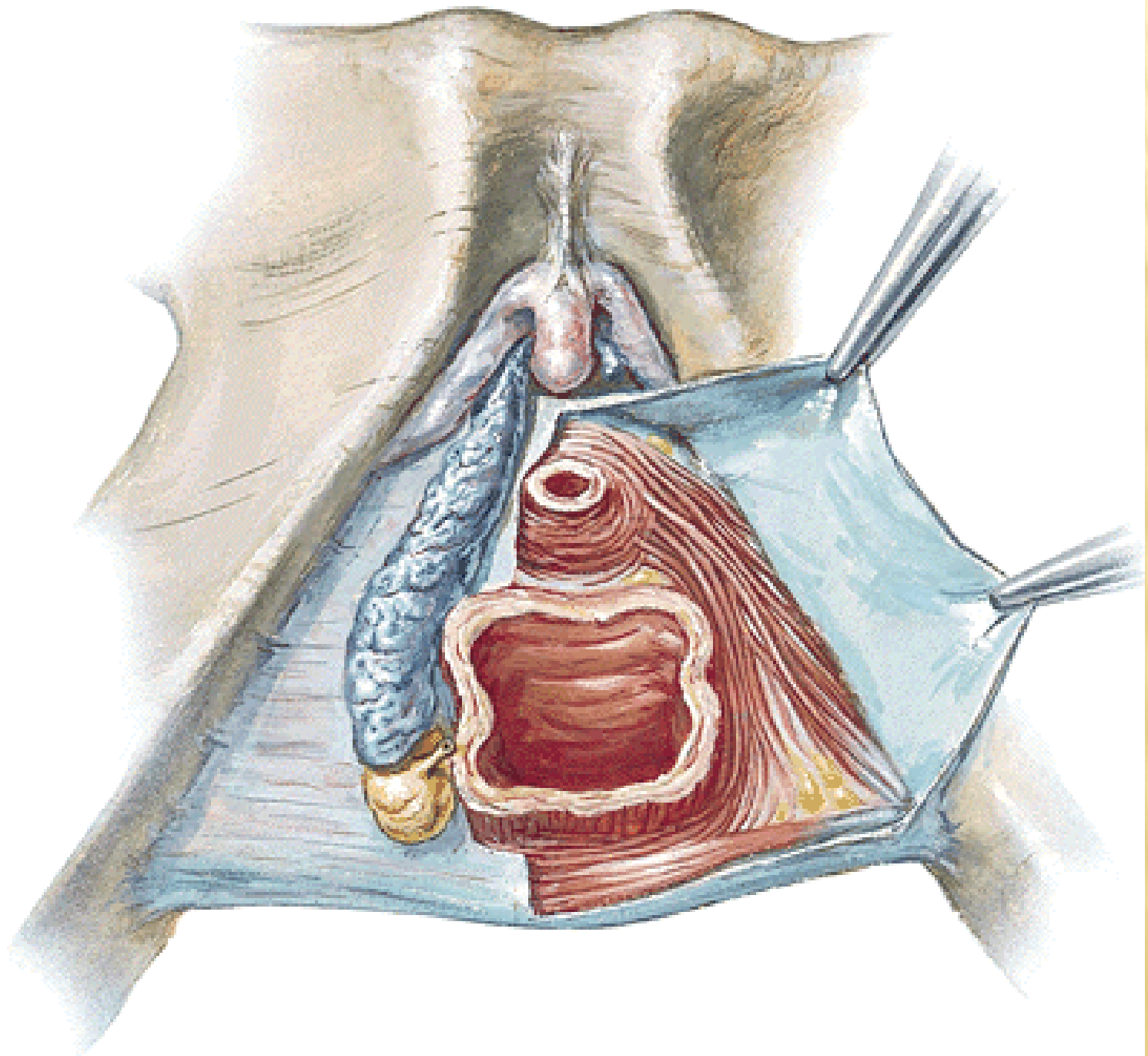
Fornix

Receptaculum seminis

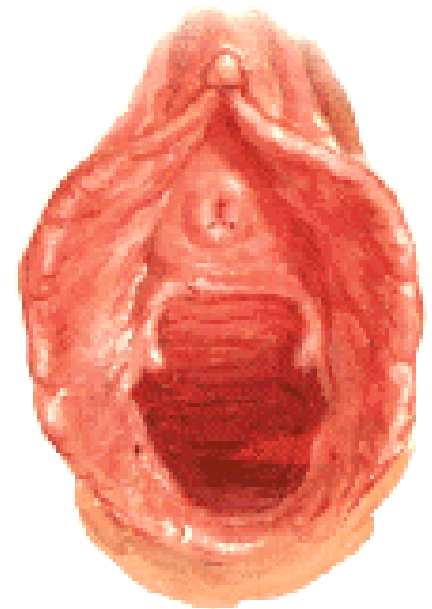
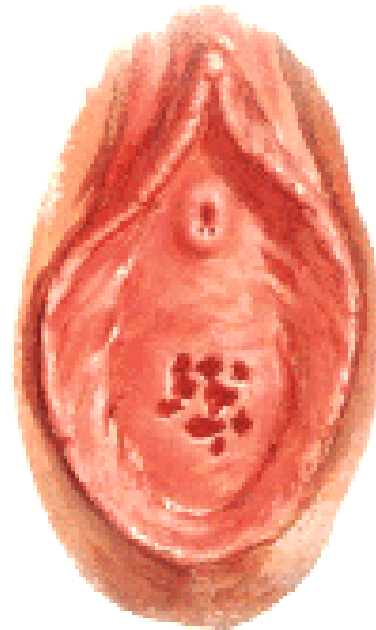
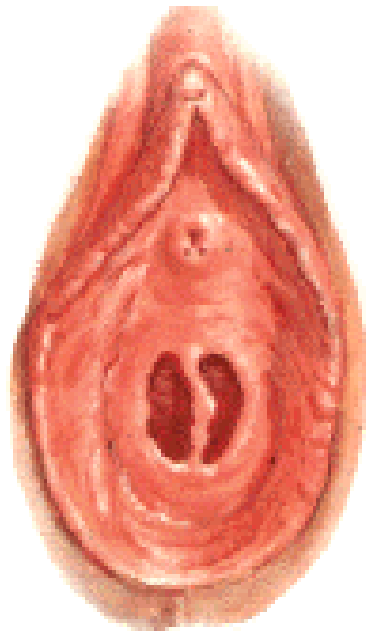
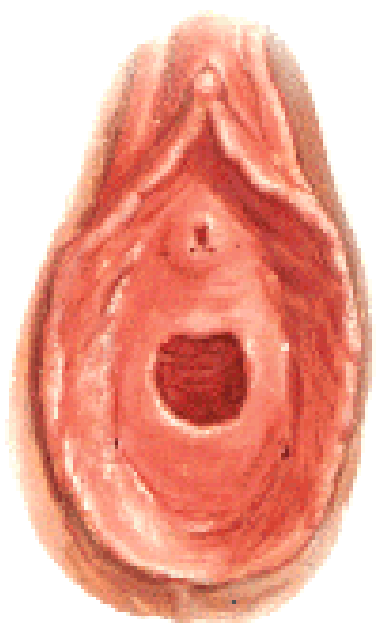
Septum urethrovaginale

Carina urethralis





Ostium vaginae:
Hymen
Defloratio
Carunculae hymenales



ORGANA GENITALIA EXTERNA (PUDENDUM/VULVA)

Mons pubis – pubes

Labium majus pudendi – commissura labiorum ant. et post.

Rima pudendi

Sulcus genitofemoralis

Sulcus interlabialis



Labium minus pudendi

- praeputium clitoridis

- frenulum clitoridis

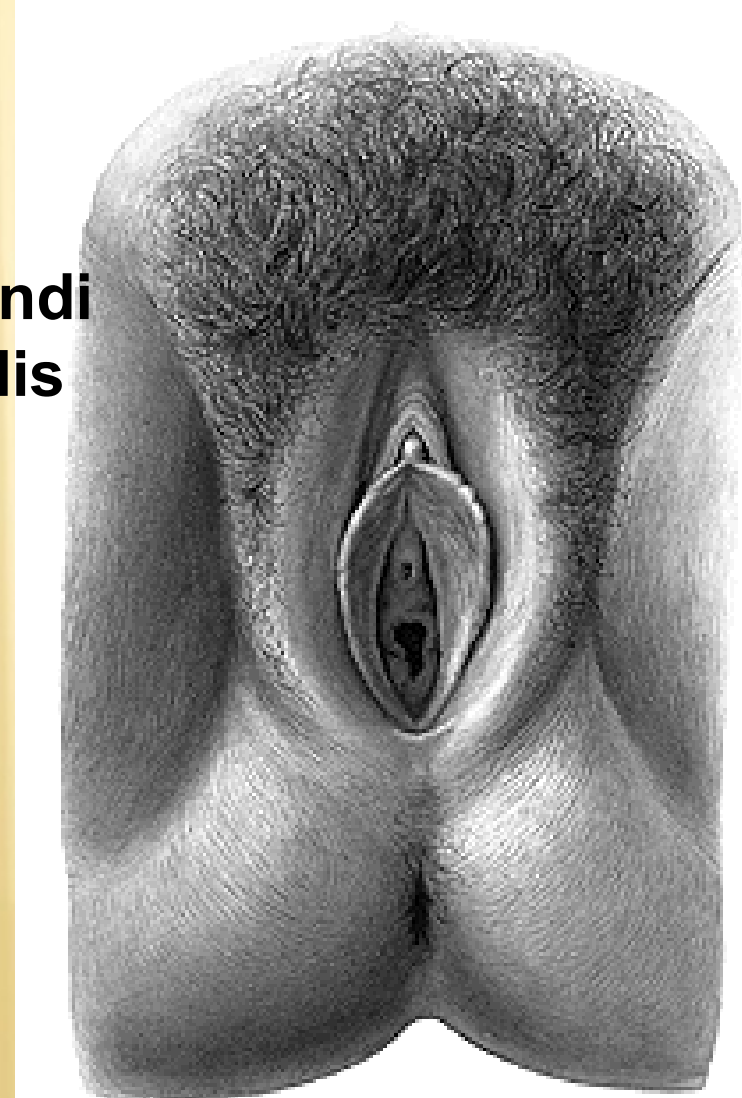
- frenulum labiorum

Vestibulum vaginae

Smegma

Perineum

Raphe perinei



CLITORIS

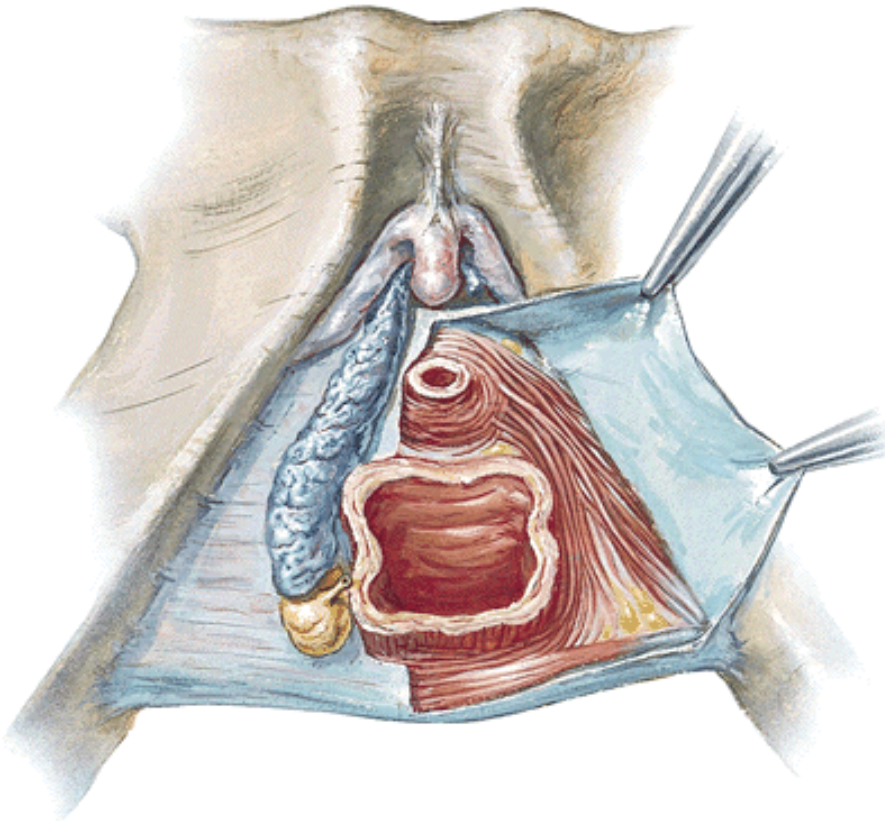
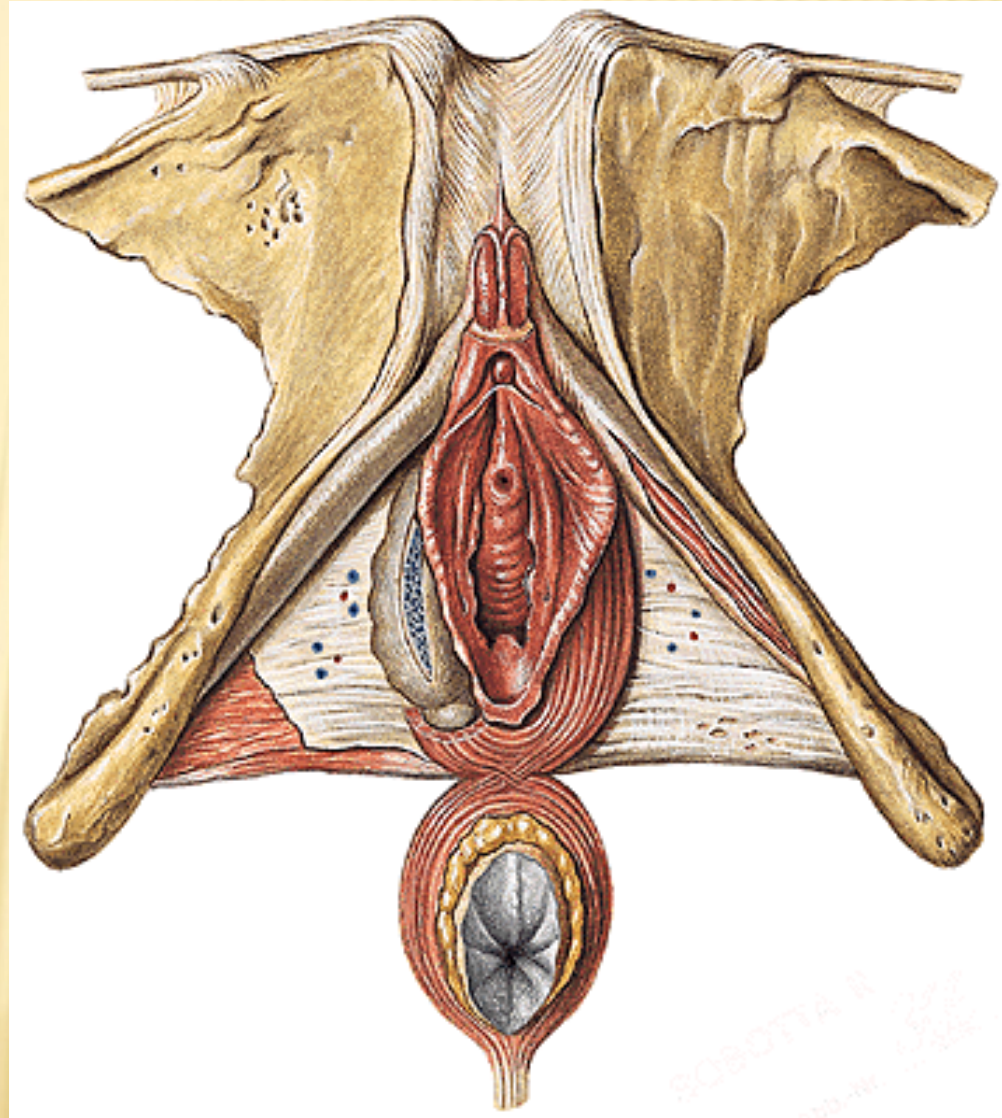
Crura clitoridis

Corpus clitoridis

Glans clitoridis

Lig. fundiforme

Lig. suspensorium



BULBI VESTIBULI

GLANDULAE VESTIBULARES MAJORES (BARTHOLIN)

GLANDULAE VESTIBULARES MINORES

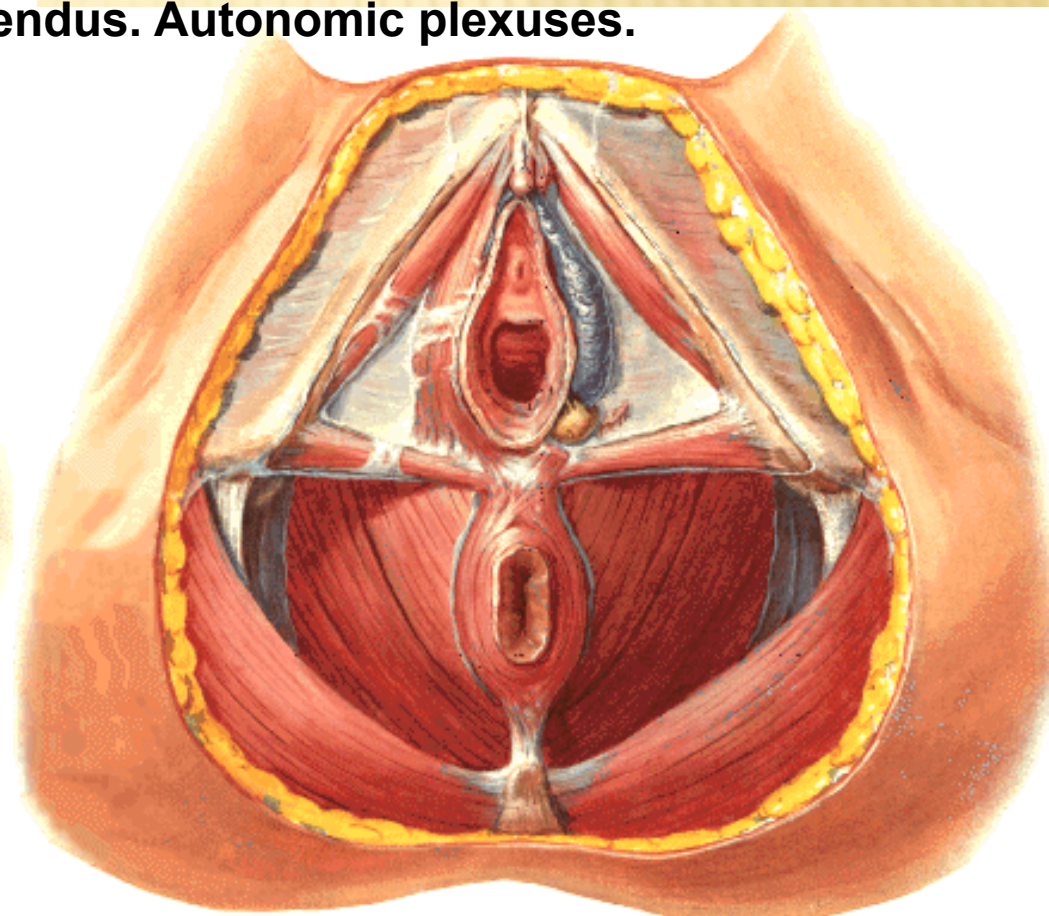
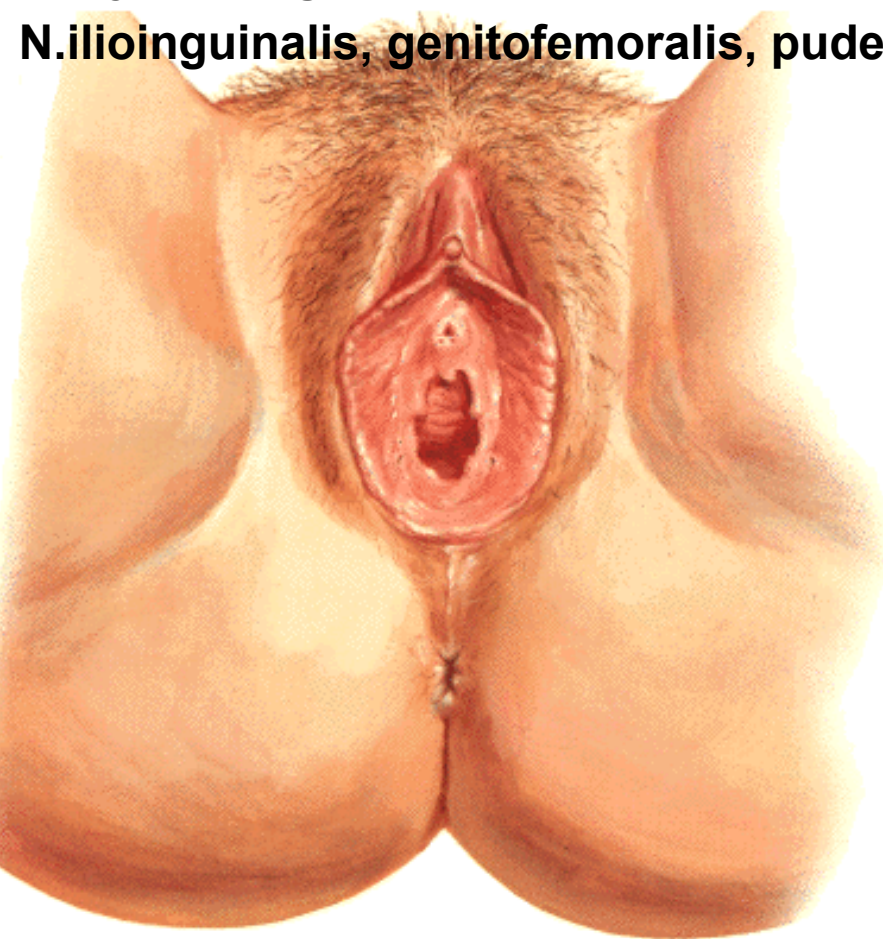A. pudenda int., aa. pudendae ext.

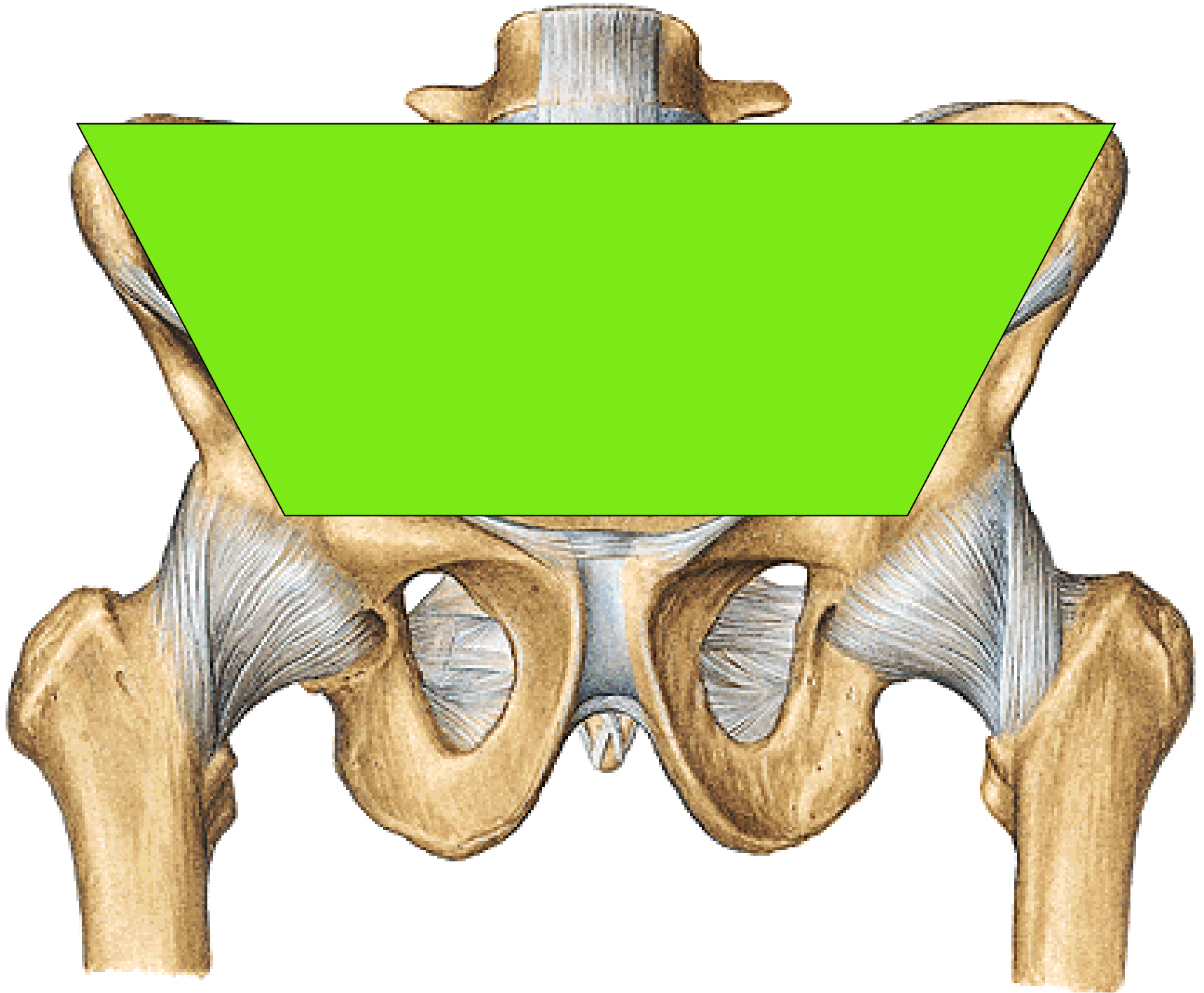
V. dorsalis clitoridis spf. and vv.labiales ant. – vv.pudendae ext.,

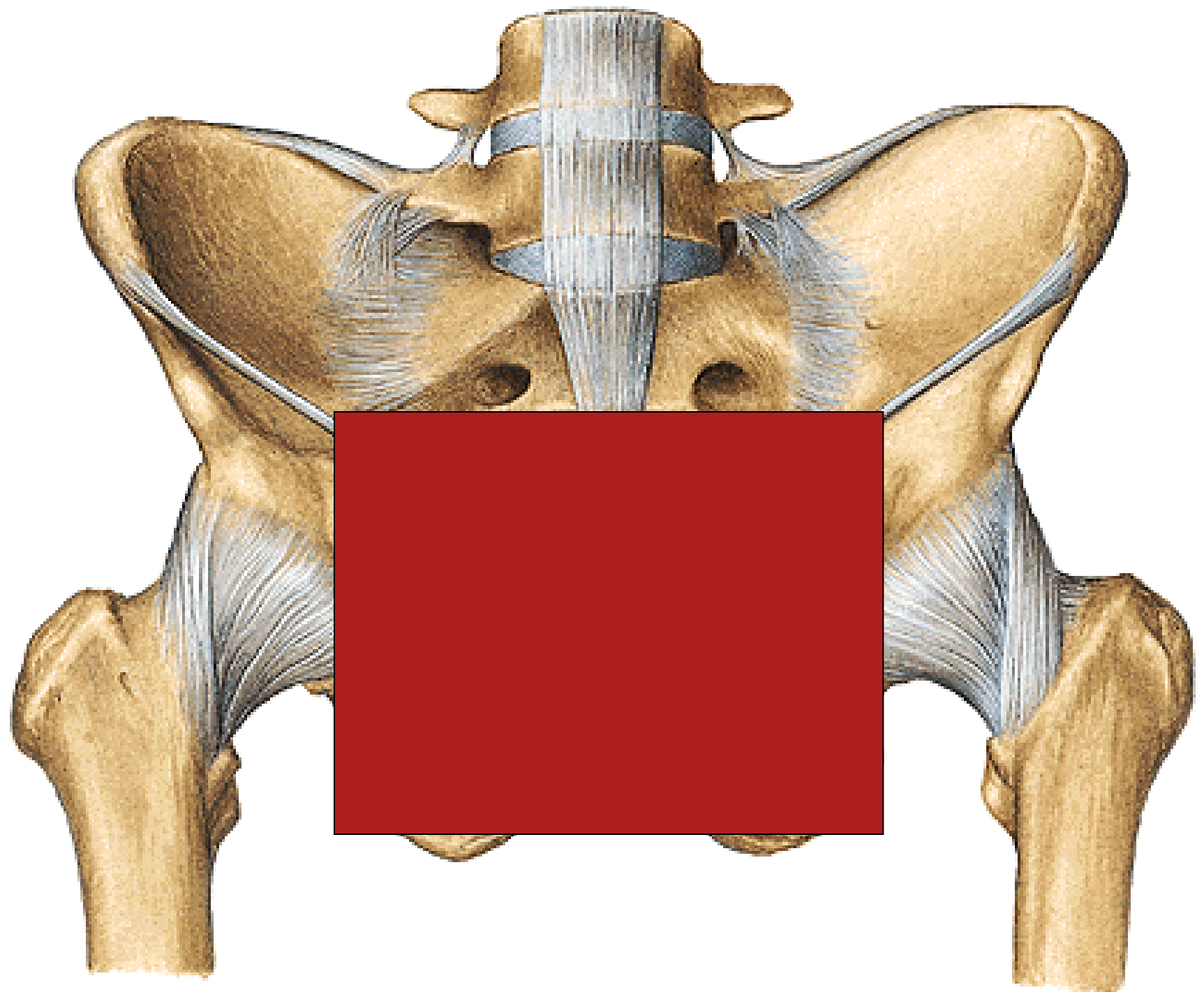
V.dorsalis clitoridis prof. and v.bulbi vestibuli – v.pudenda int.,

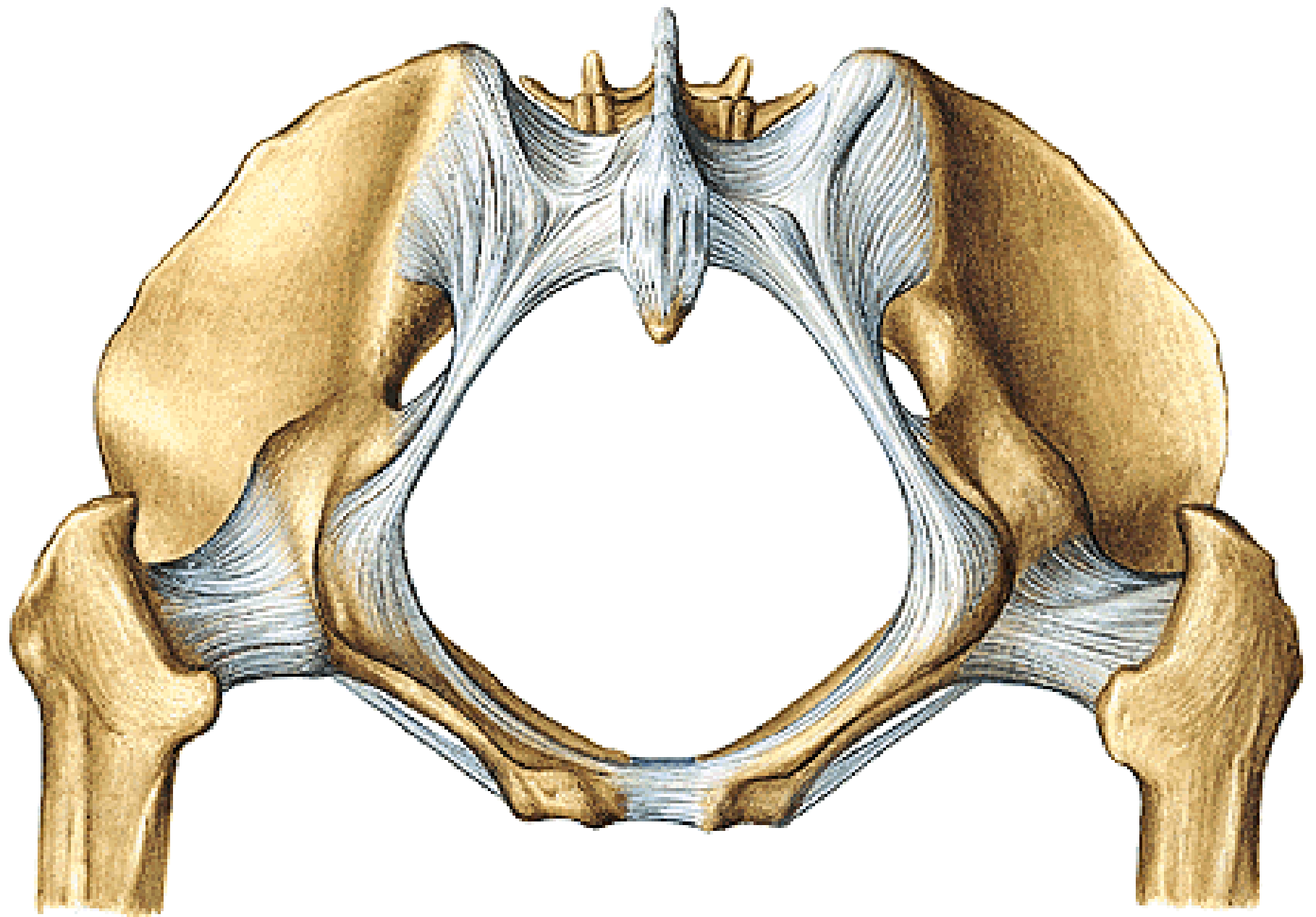
Nn.lymph.inguinales spf.

N.ilioinguinalis, genitofemoralis, pudendus. Autonomic plexuses.

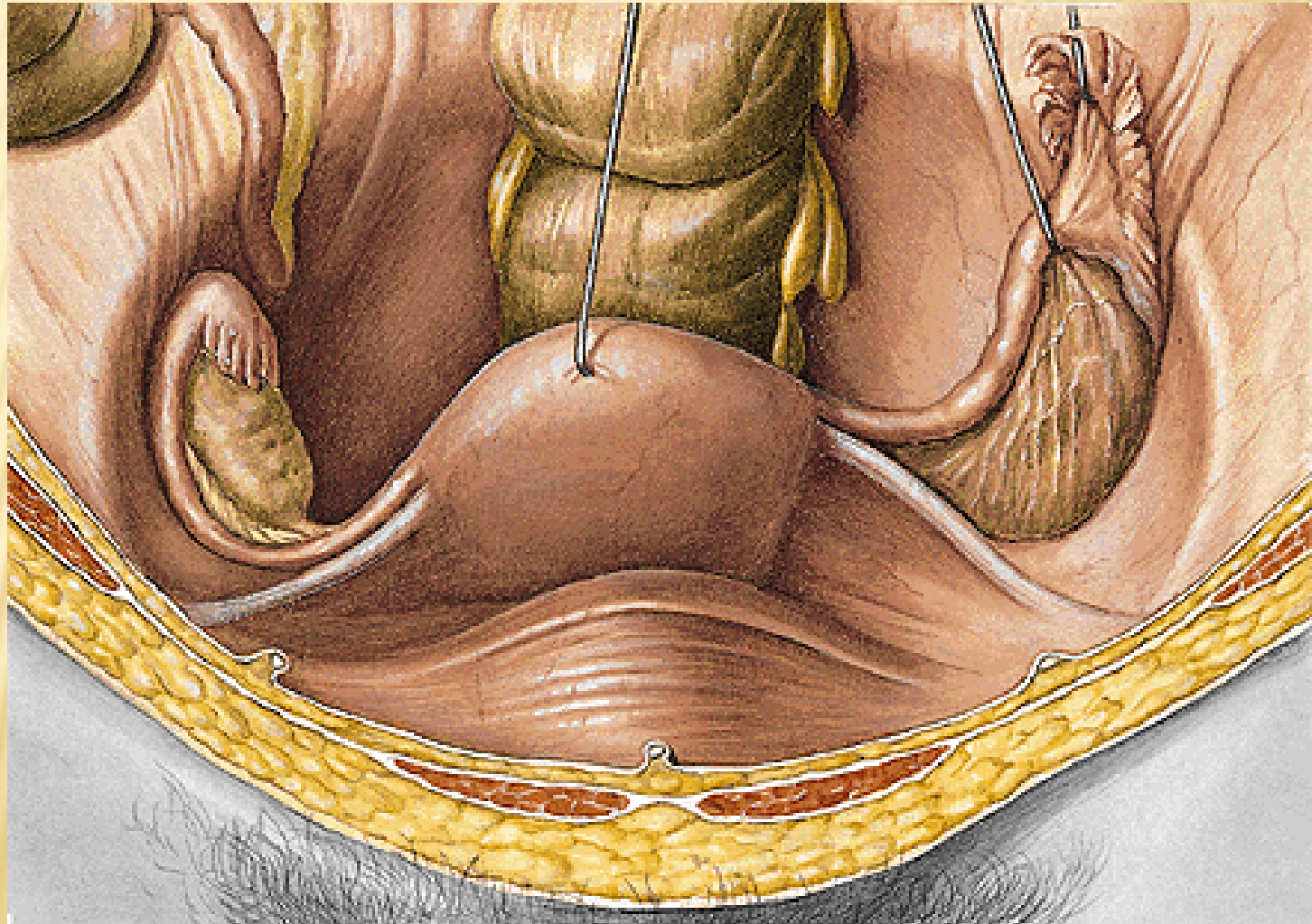






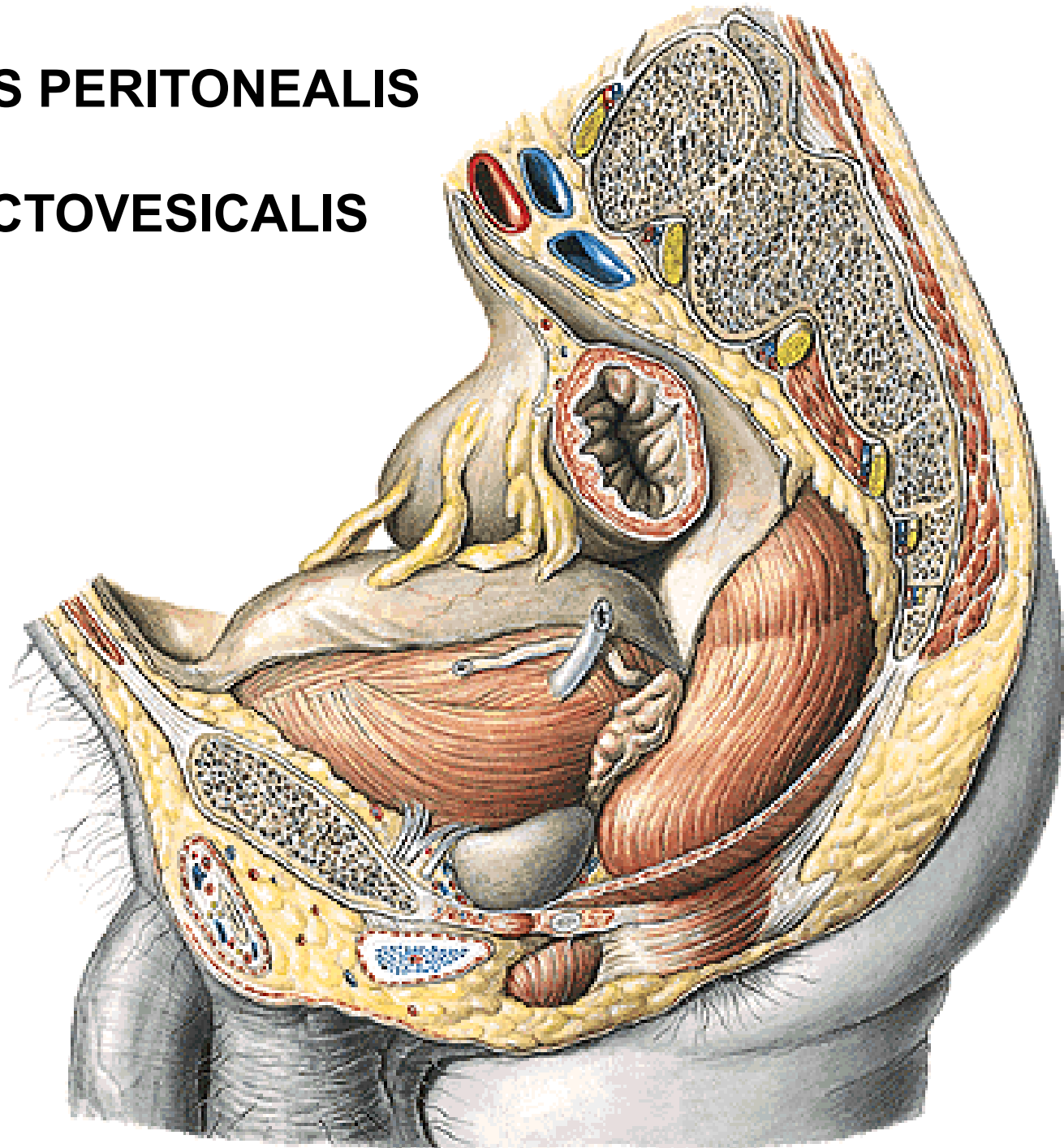


LIGAMENTUM LATUM UTERI
LIGAMENTUM OVARIUM PROPRIUM
LIGAMENTUM SUSPENSORIUM OVARIUM
LIGAMENTUM TERES UTERI



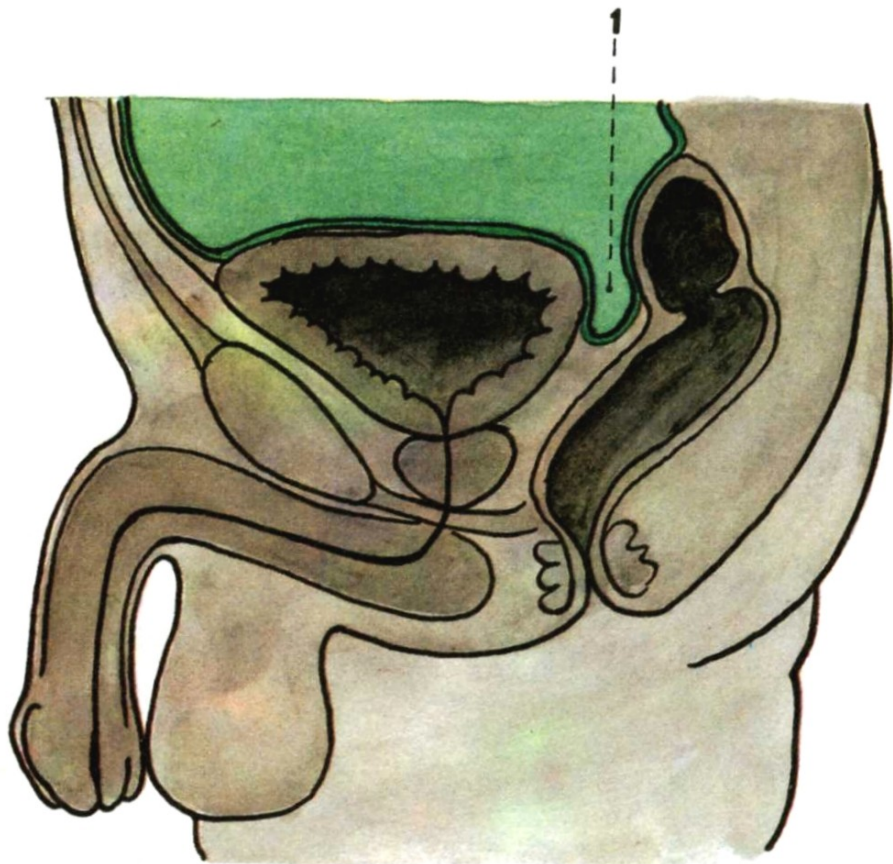
CAVITAS PELVIS PERITONEALIS

EXCAVATIO RECTOVESICALIS



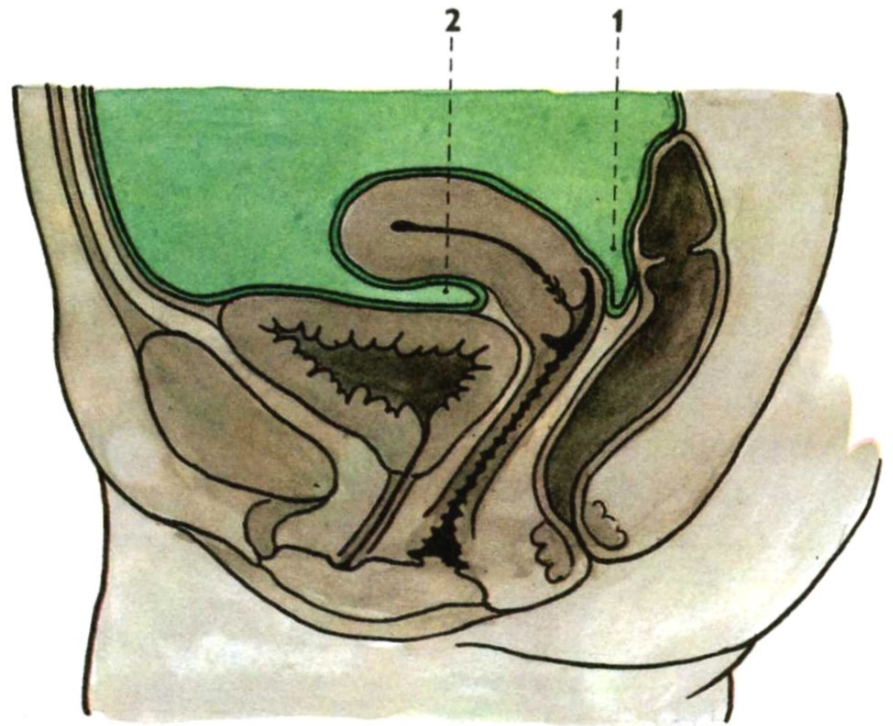
Median section through the male pelvis

1. excavatio rectovesicalis



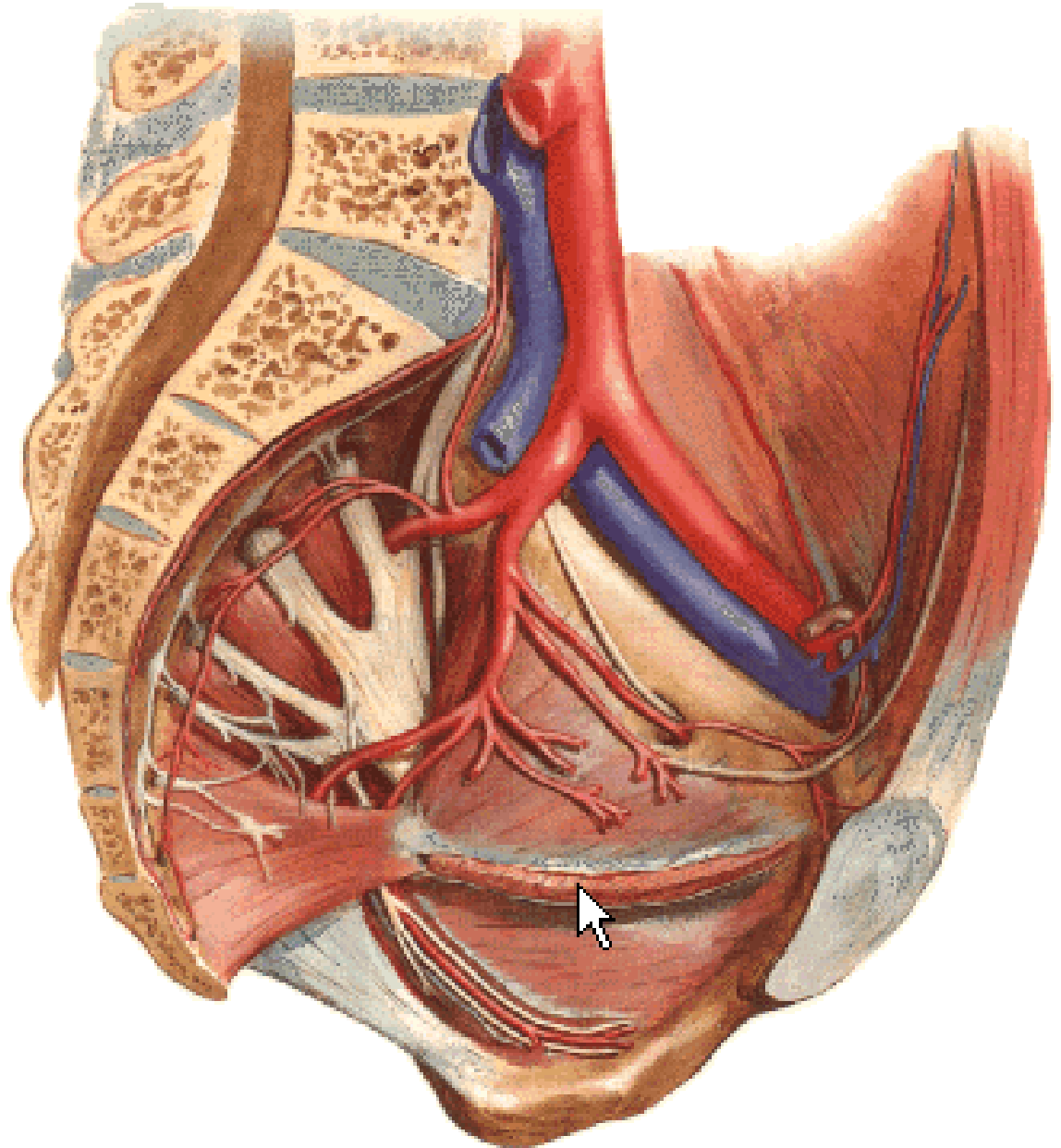
Median section through the female pelvis

1. excavatio rectouterina (Douglas)
2. excavatio vesicouterina



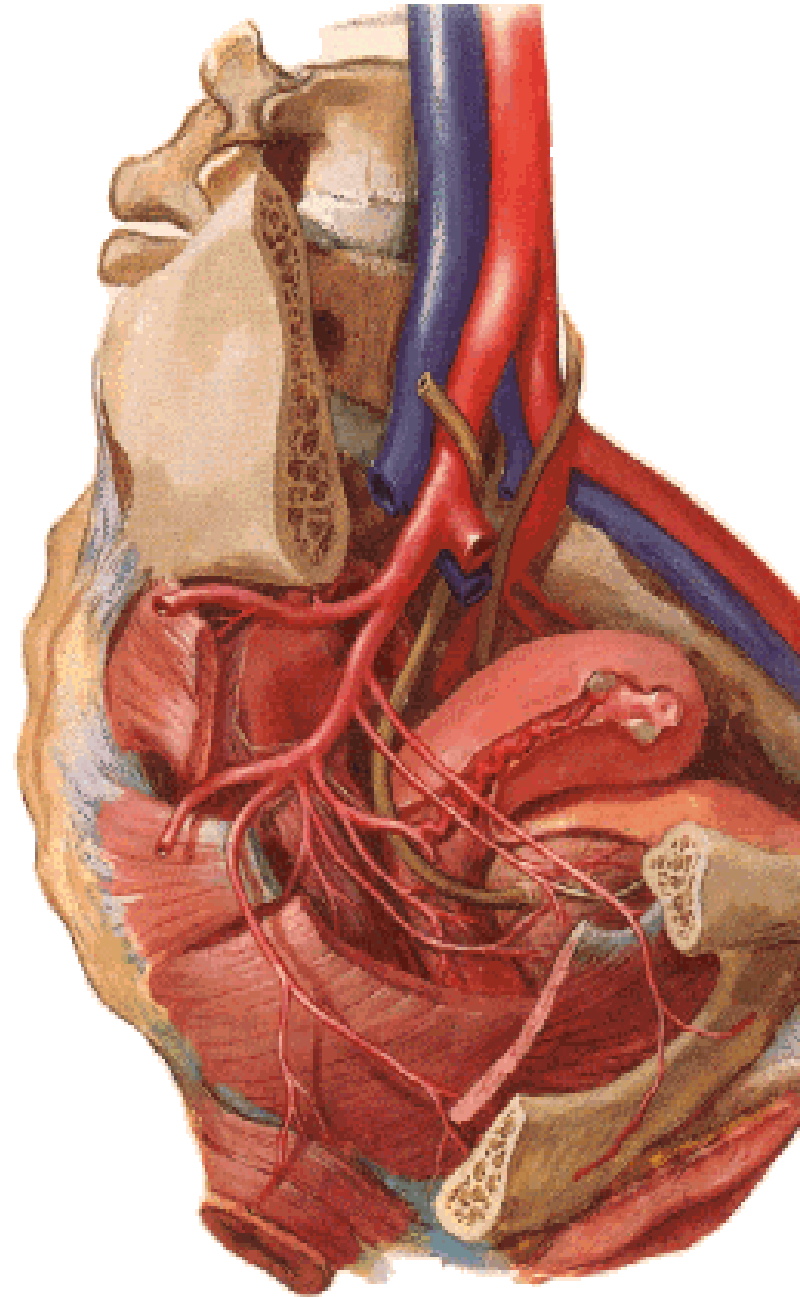
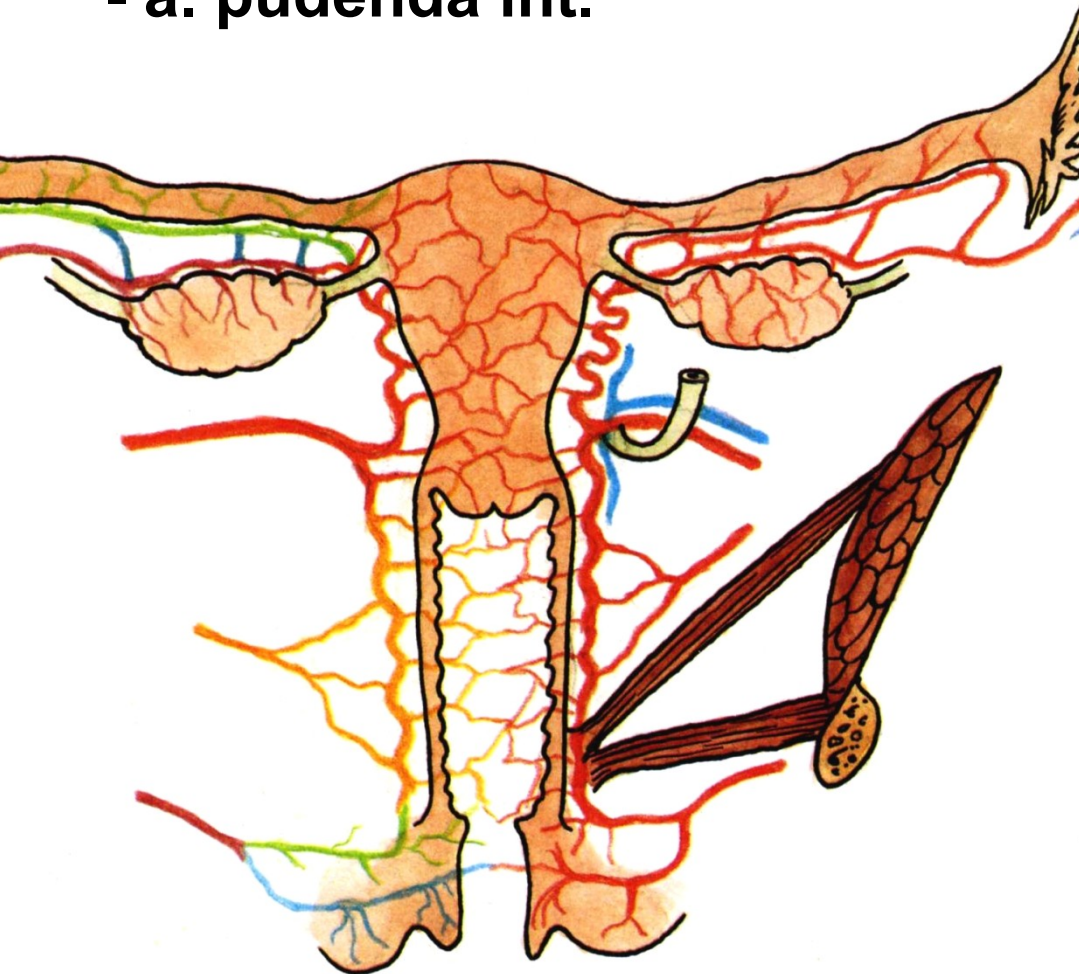
A. ILIACA INT.

- a. iliolumbalis
- aa. sacrales lat.
- a. obturatoria
- a. glutea sup.
- a. glutea inf.
- a. umbilicalis

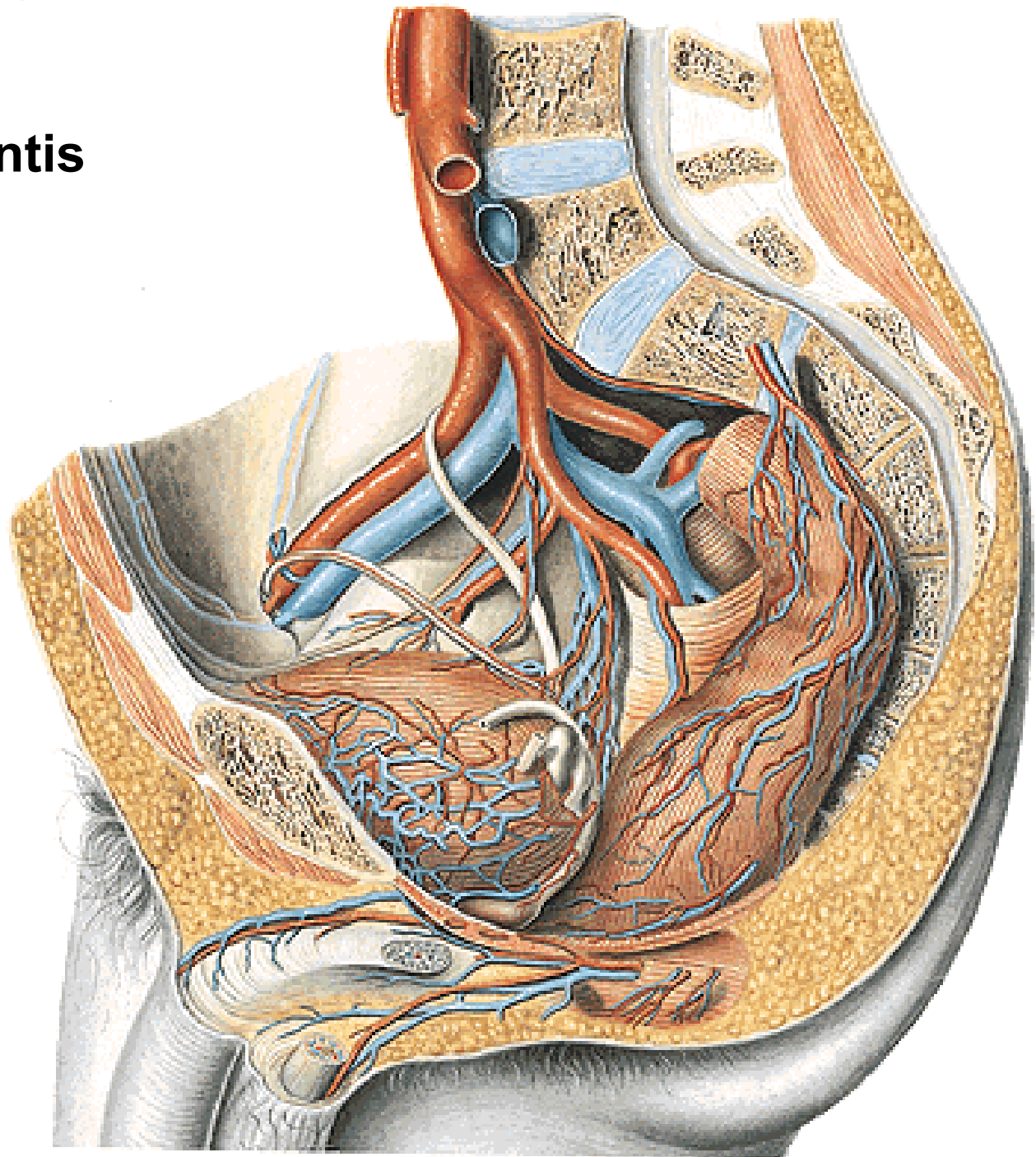


A. iliaca int.

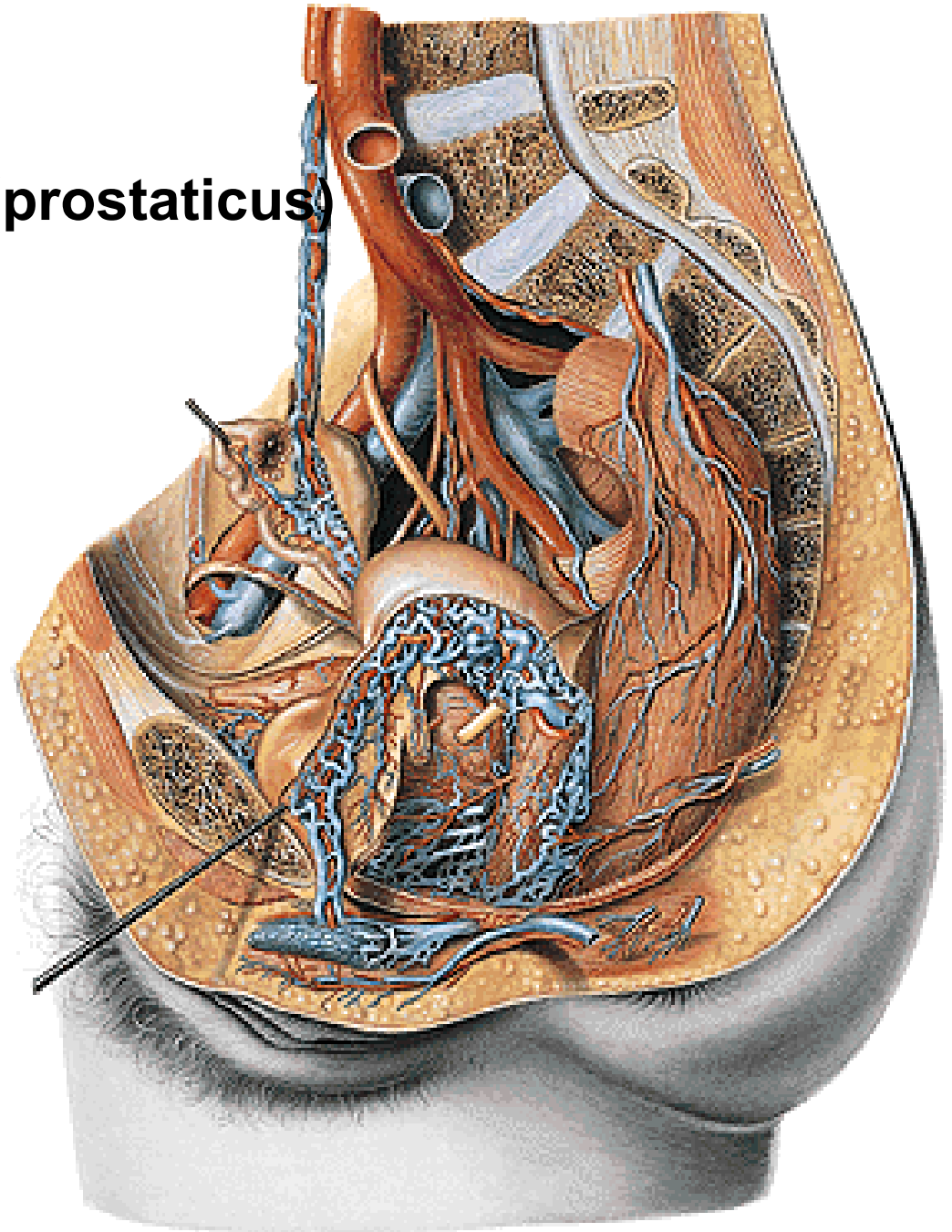
- a. uterina
- a. vaginalis
- a. vesicalis inf.
- a. rectalis media
- a. pudenda int.


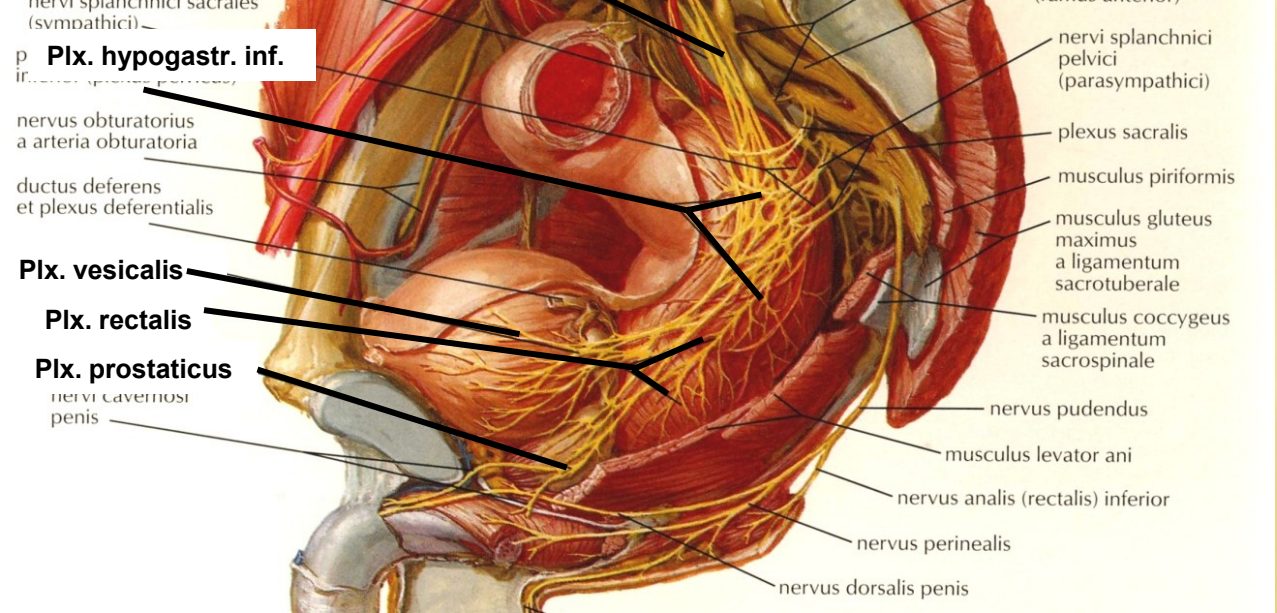
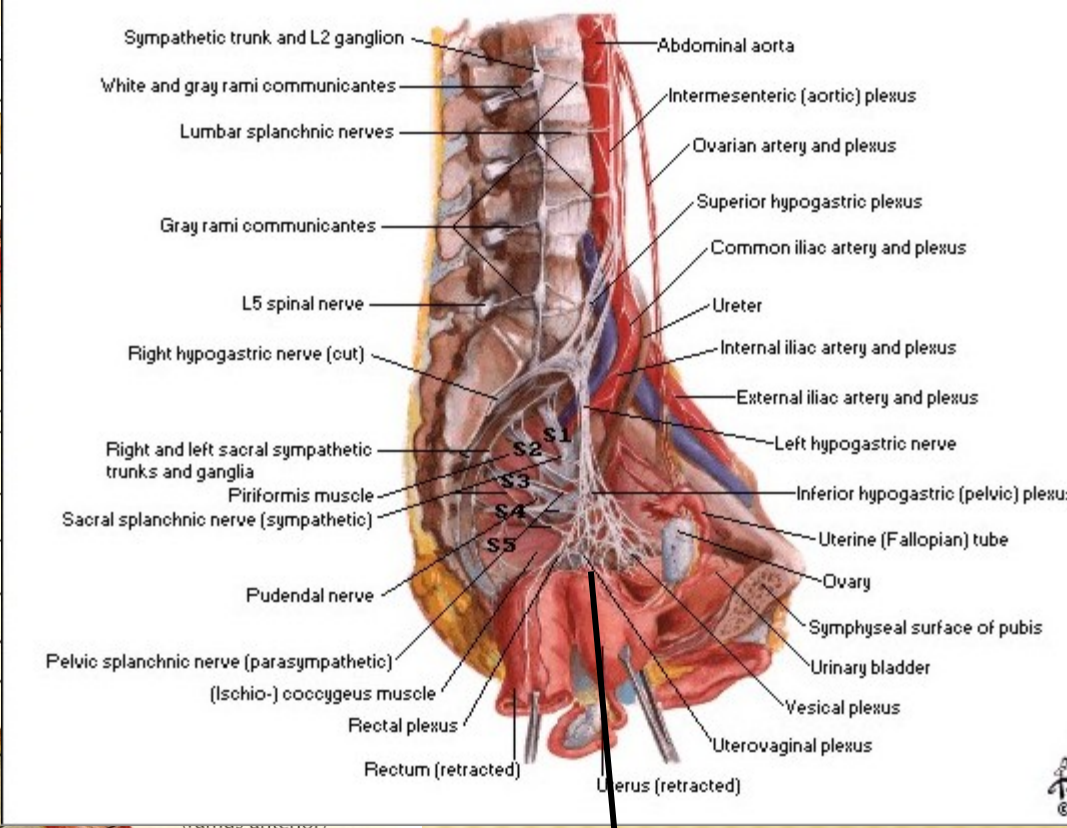
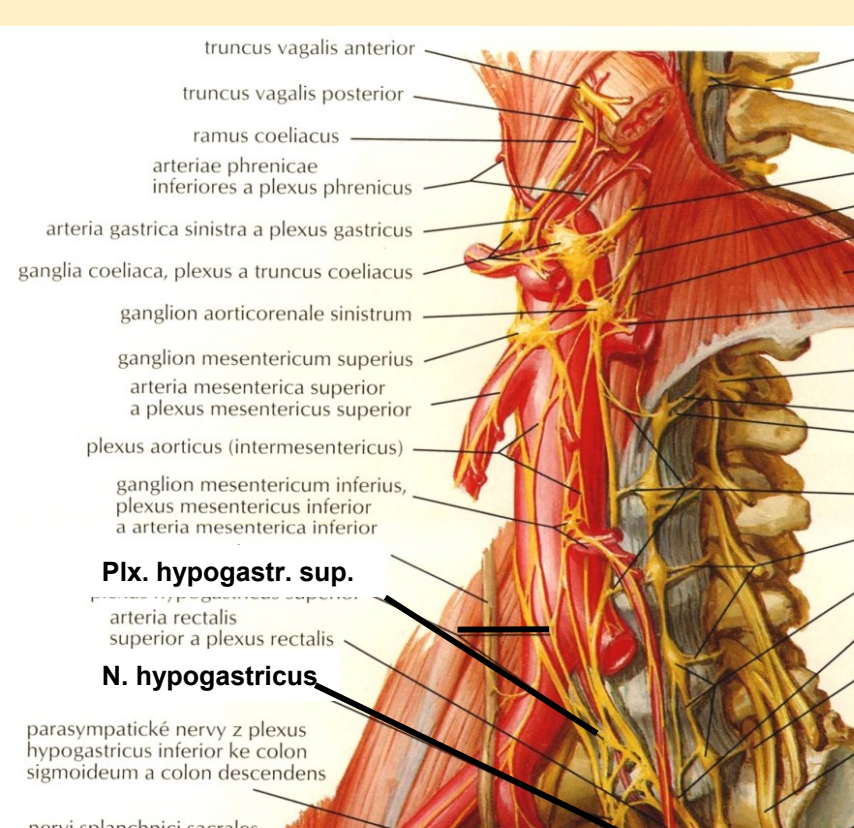


A. ductus deferentis
Rr. prostatici



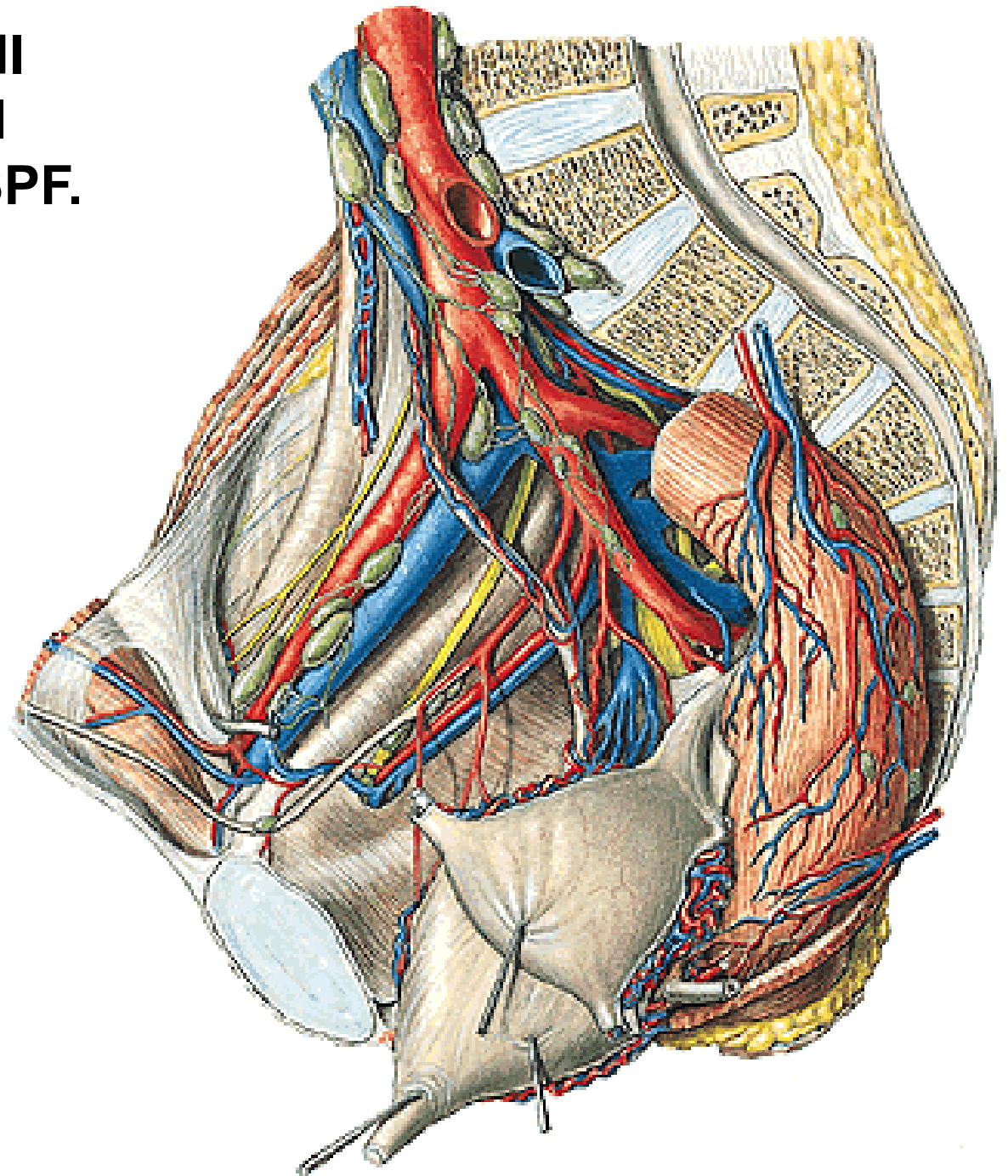
Plexus venosus vaginalis (prostaticus)
Plexus venosus uterinus
Plexus venosus vesicalis
Plexus venosus rectalis
Plexus venosus sacralis





Plx. uterovaginalis

NLL. ILIACI EXTERNI
NLL. ILIACI INTERNI
NLL. INGUINALES SPF.
NLL. SACRALES
NLL. LUMBALES

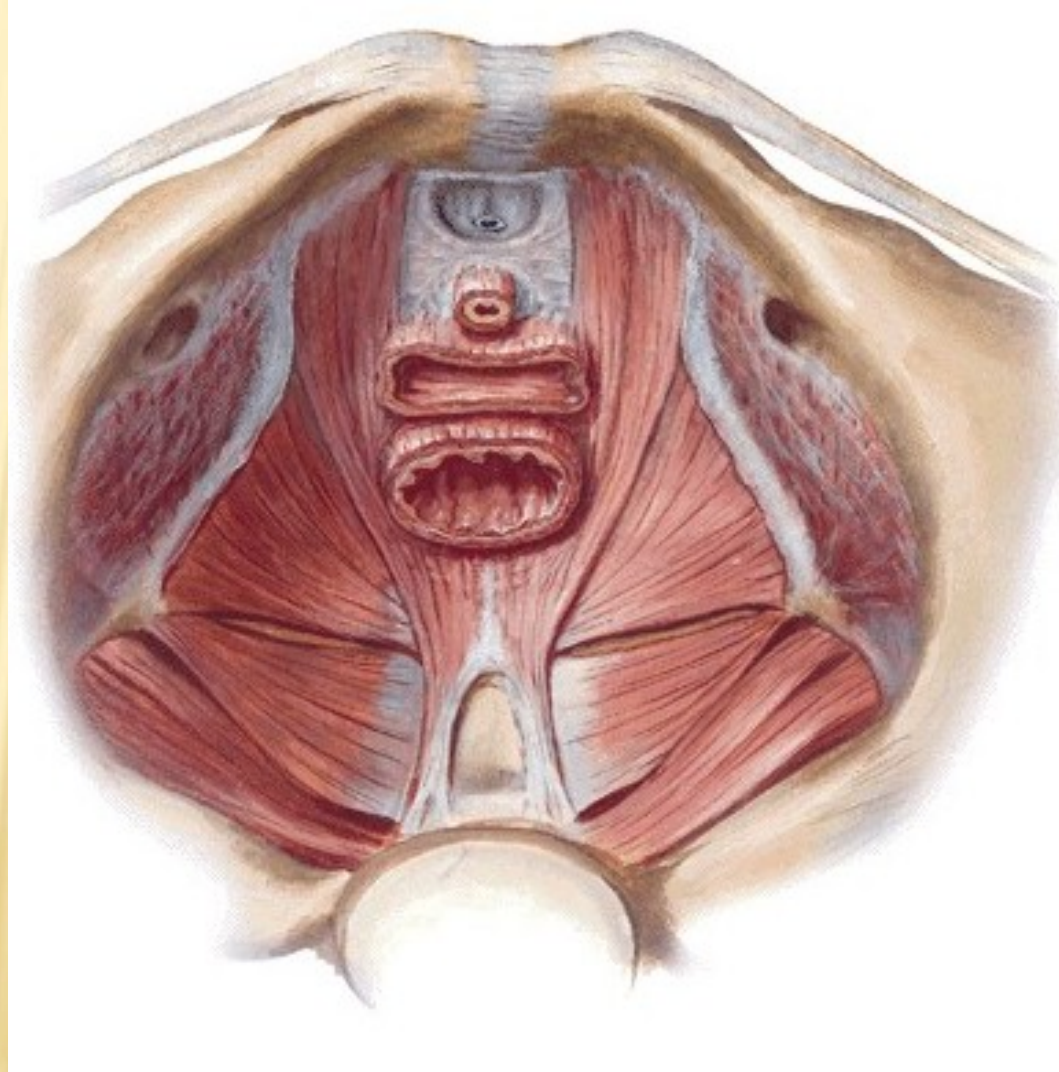


DIAPHRAGMA PELVIS

**M. levator ani – pars iliaca (m. iliococcygeus)
– pars pubica (m. pubococcygeus)
(m. pubovaginalis, m. puborectalis)**

M. (ischio)coccygeus

Hiatus urogenitalis



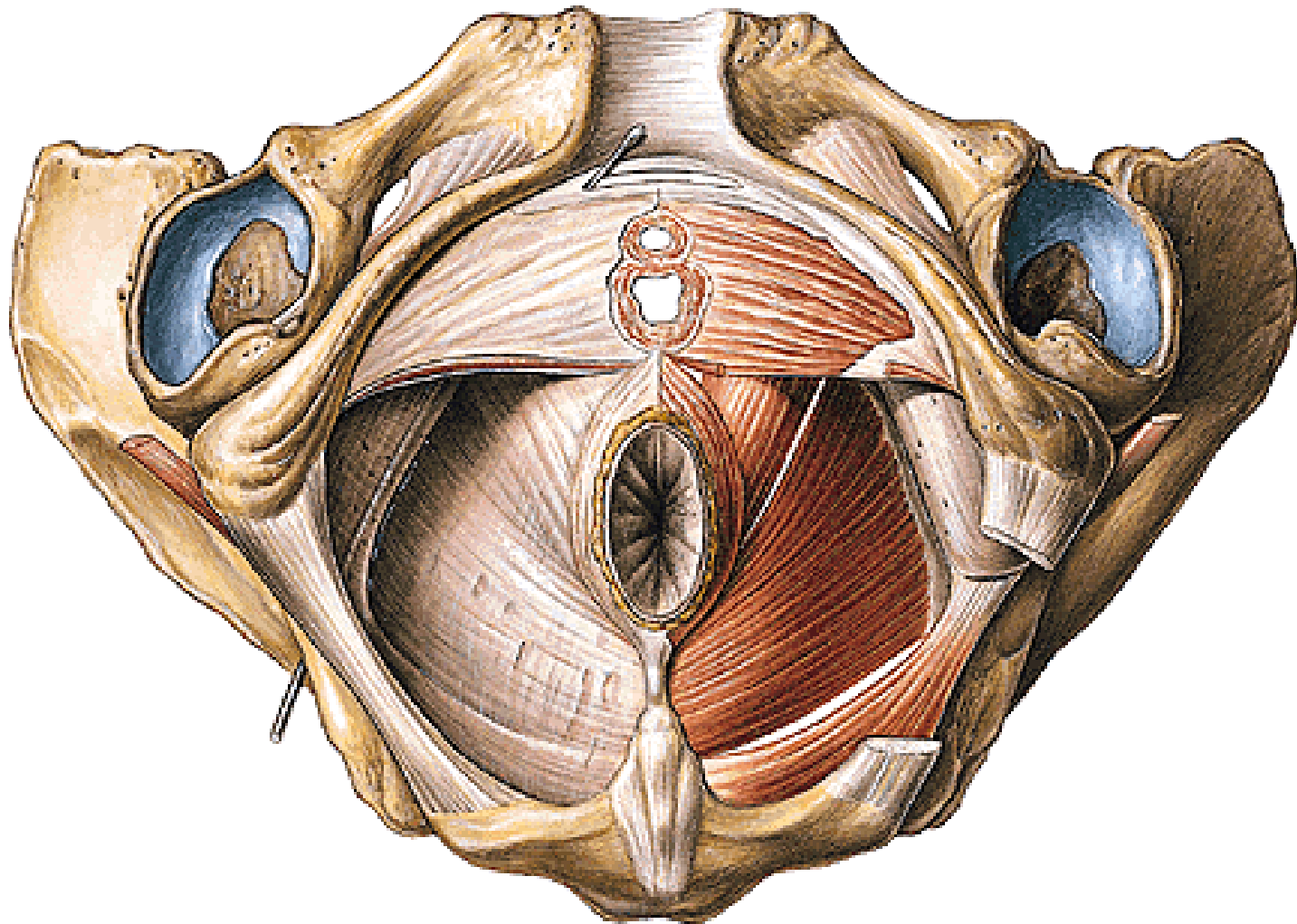
SACCUS PROFUNDUS PERINEI/DIAPHRAGMA UROGENITALE

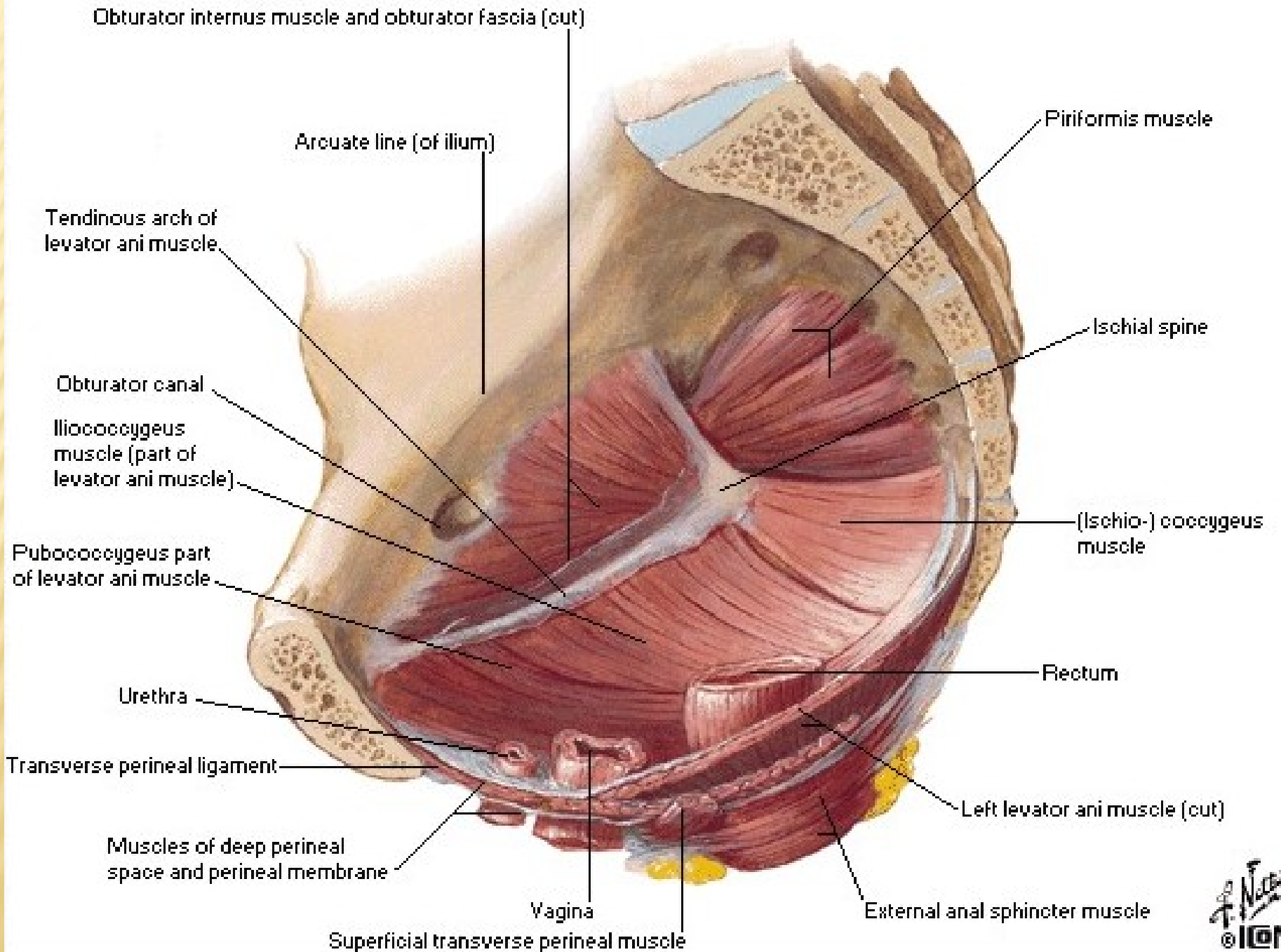
Lig. transversum perinei

M. sphincter urethrae externus (m. sphincter urethrovaginalis)

M. compressor urethrae

Centrum perineale





A.,v. et n. perinealis

A. penis (clitoridis) – a. dorsalis penis (clitoridis)

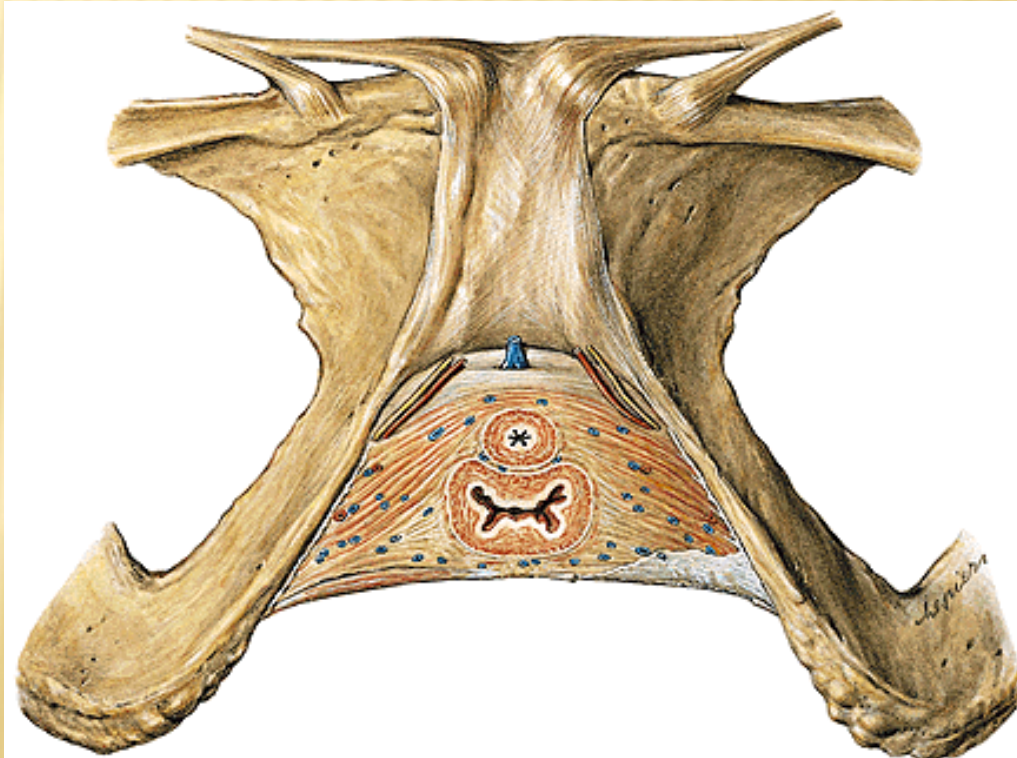
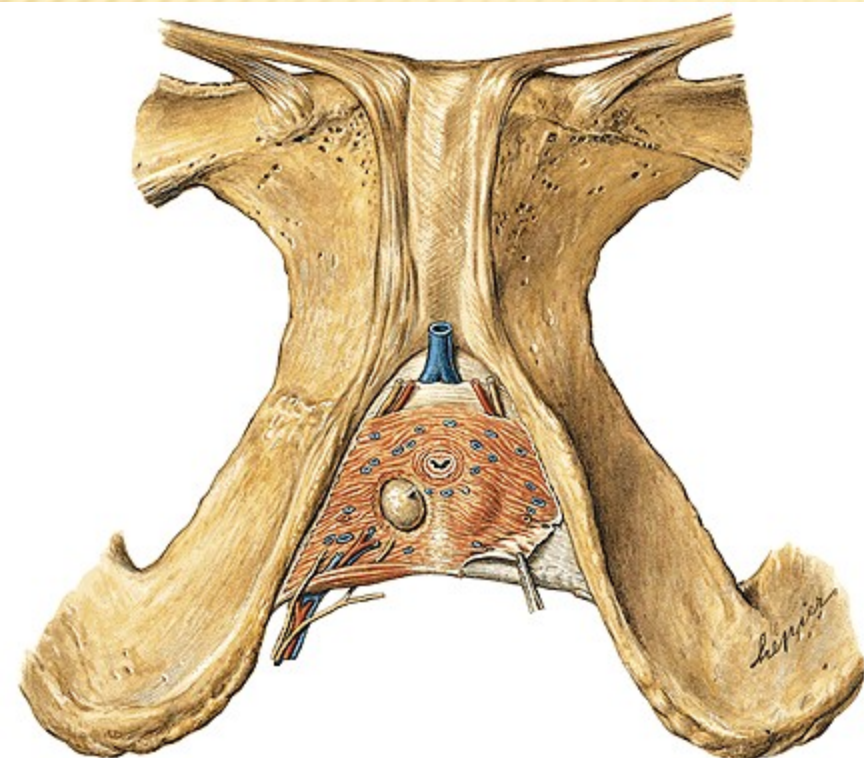
– a. profunda penis (clitoridis)

V. dorsalis penis (clitoridis) spf. – vv. pudendae ext.

V. dorsalis penis (clitoridis) profunda – vv. pudendae int.

N. dorsalis penis (clitoridis)

Gl. bulbourethralis



SPATIUM SUPERFICIALE PERINEI

M. ischiocavernosus

M. bulbospongiosus

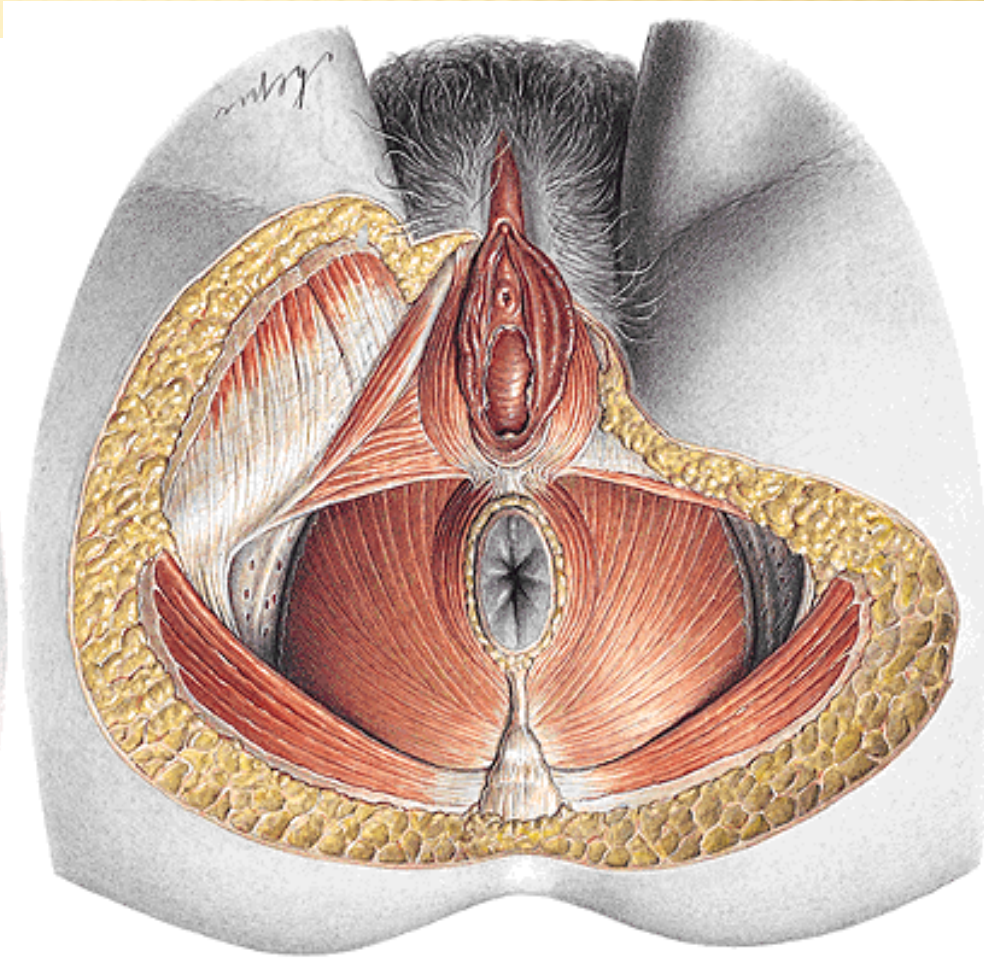
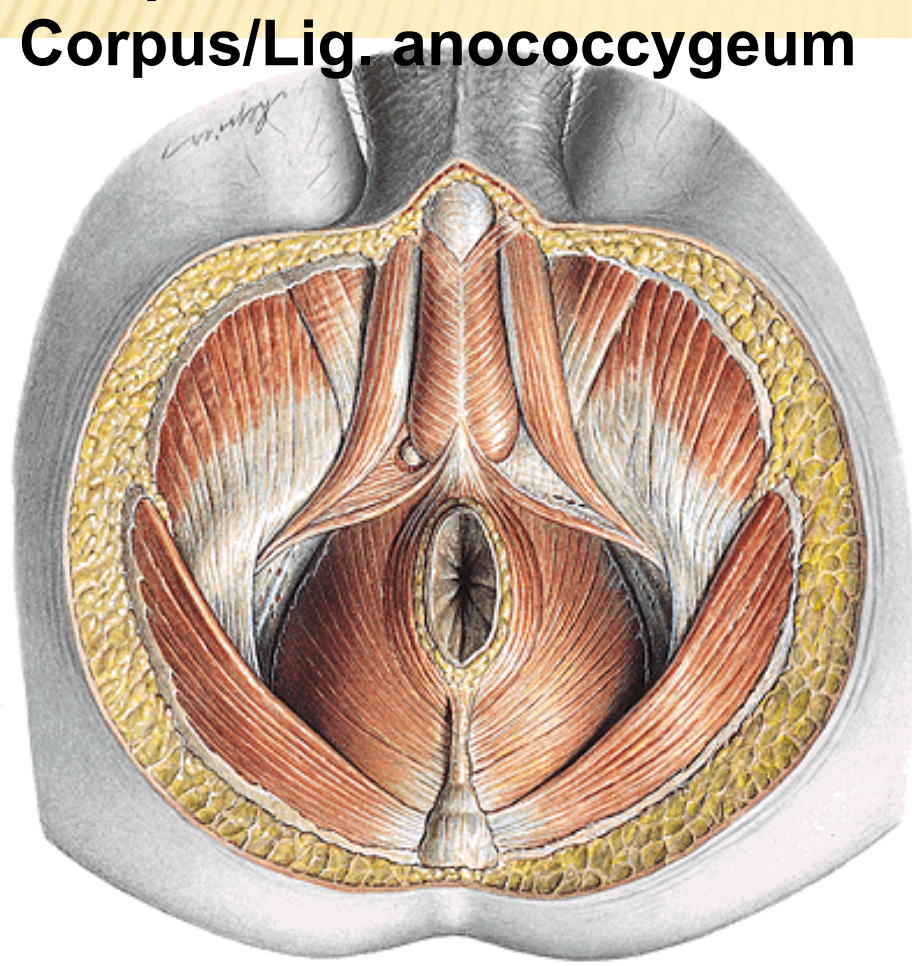
M. transversus perinei superficialis

Centrum perineale/tendineum perinei

M. sphincter ani externus

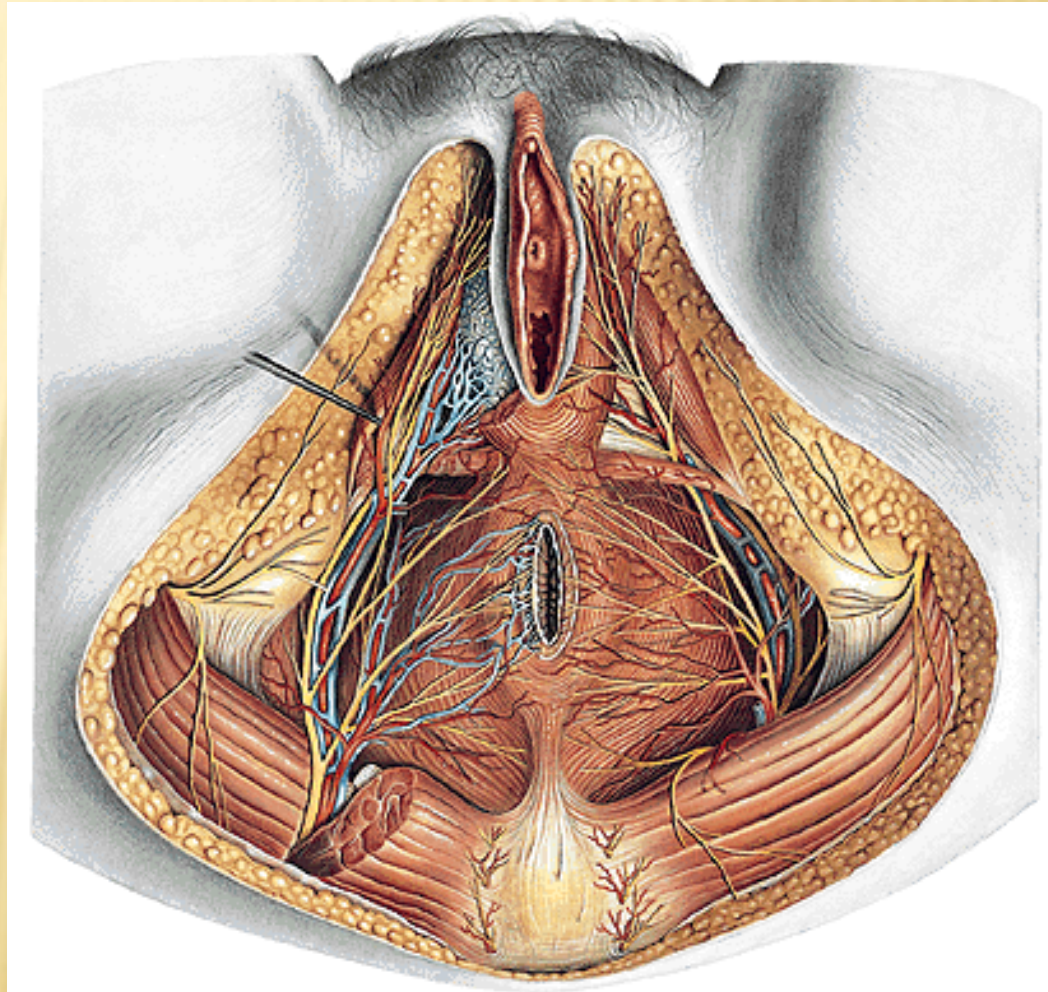
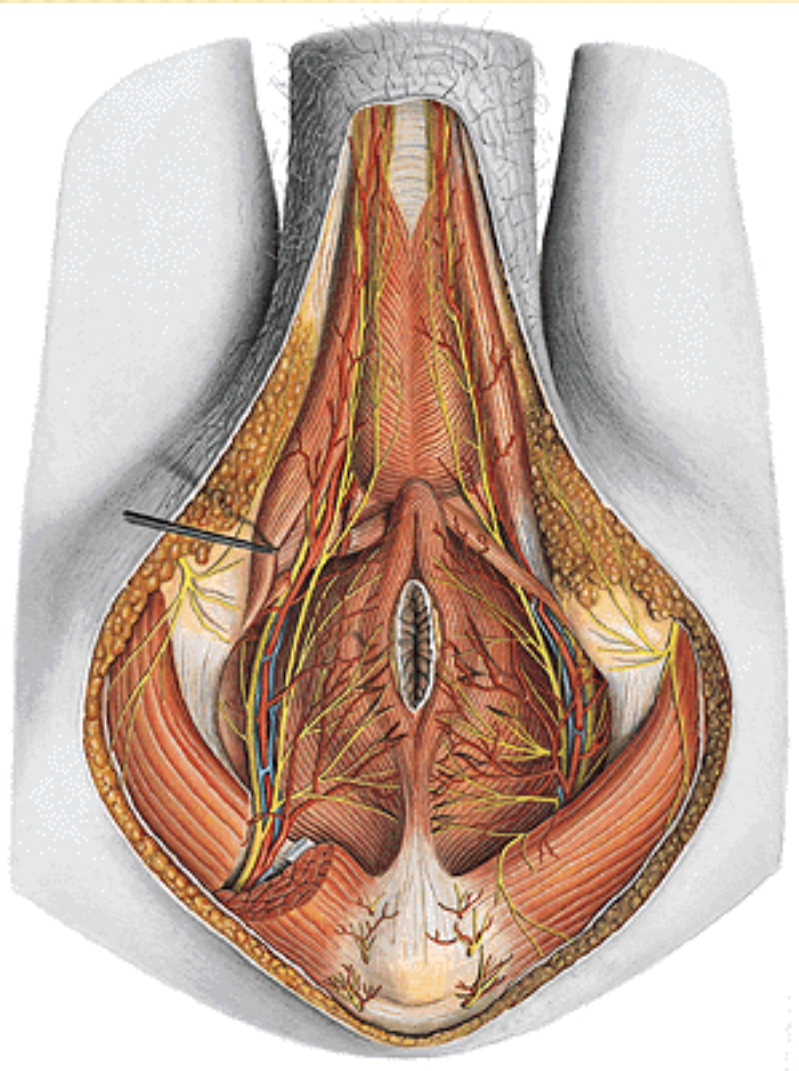
Corpus/Lig. anococcygeum

Rima pudendi

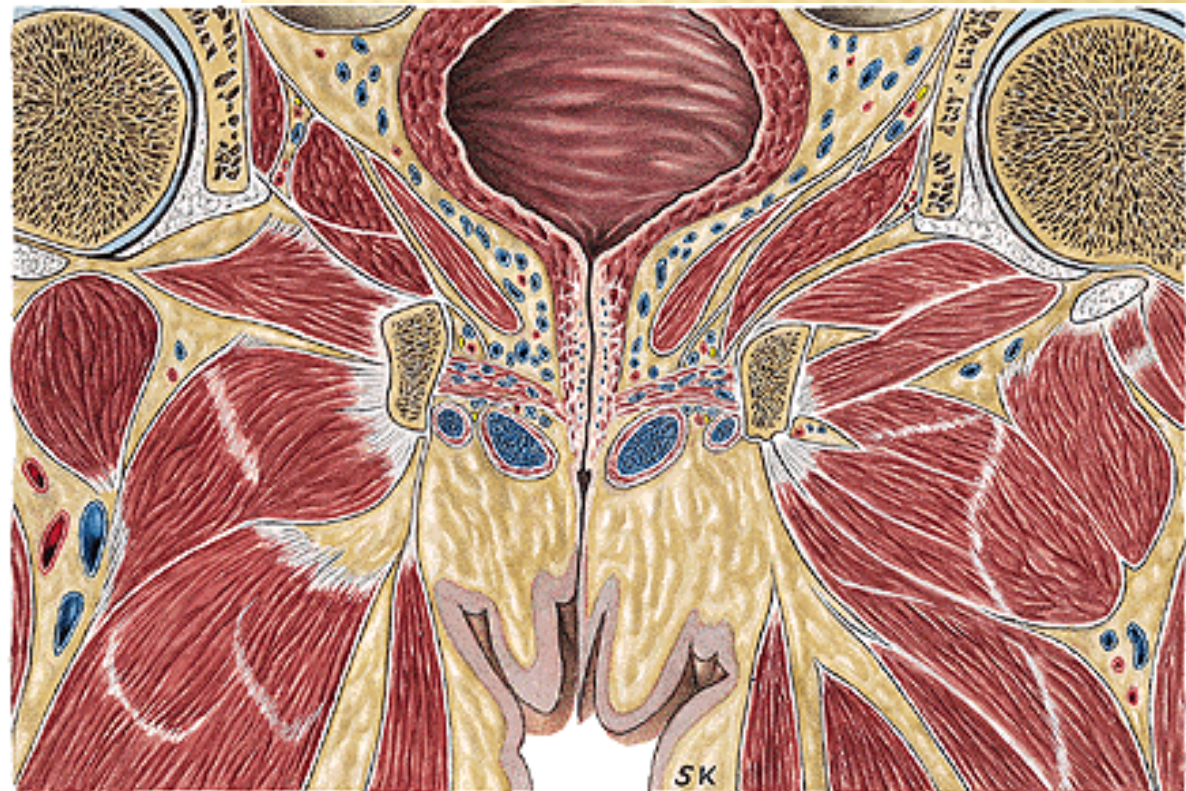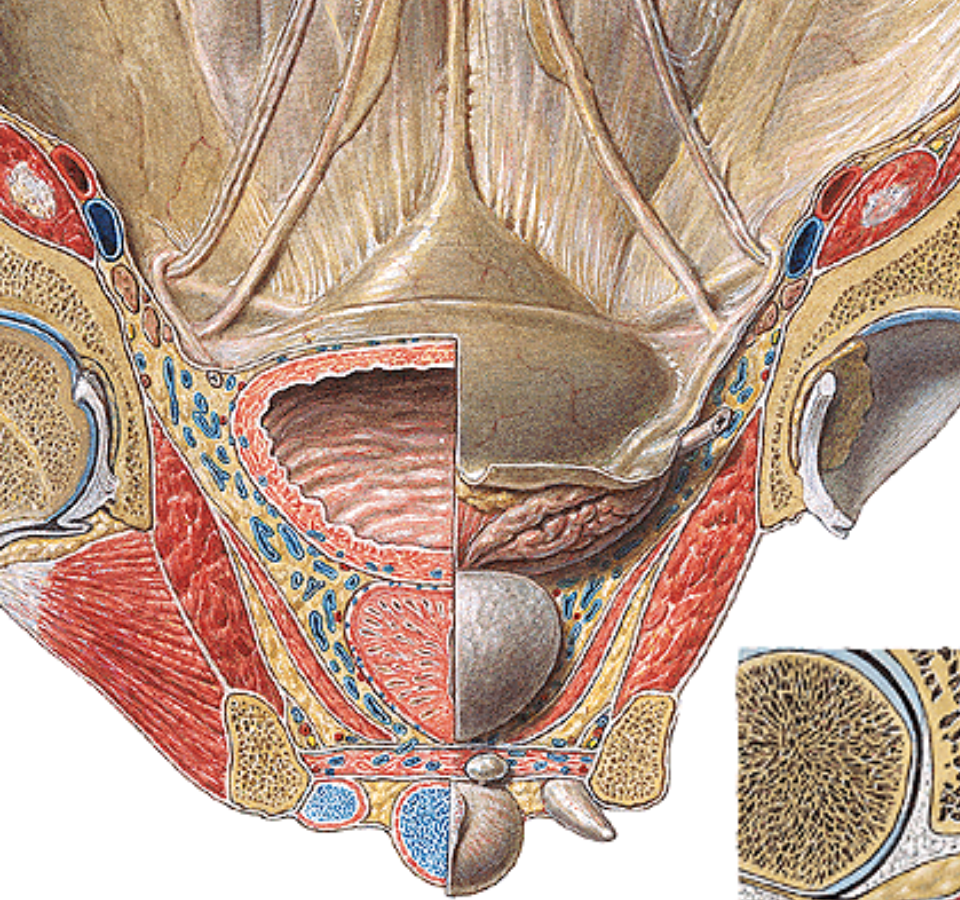


FOSSA ISCHIOANALIS/-RECTALIS

a. et v. pudenda interna, n. pudendus – canalis pudendalis
aa., vv. et nn. rectales inf.



Recessus pubicus fossae ischioanalis



PELVIC FASCIA (spatium sub-/infraperitoneale)

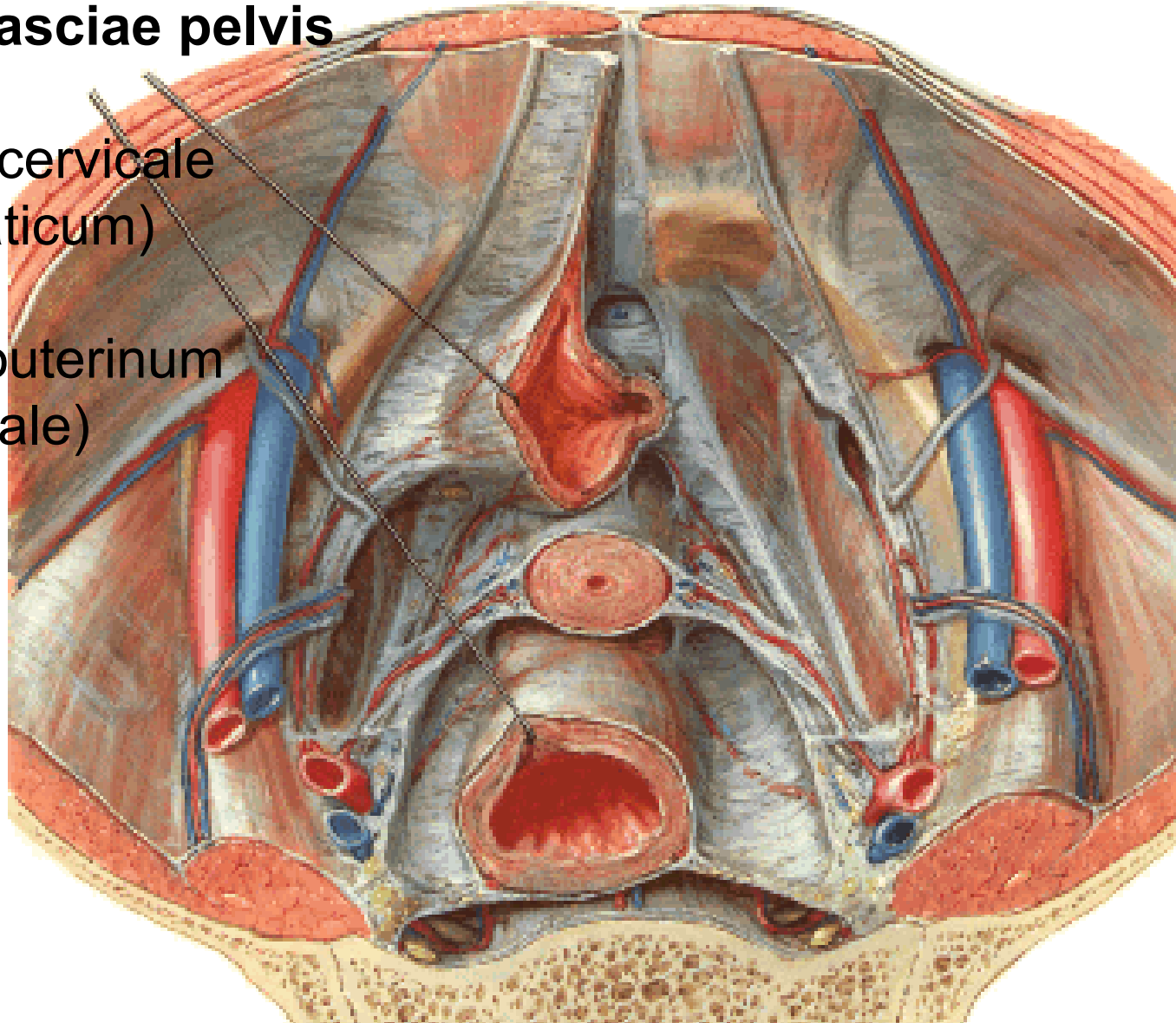
FASCIA PELVIS PARIETALIS

FASCIA PELVIS VISCERALIS

Arcus tendineus fasciae pelvis

– ligamentum pubocervicale
(puboprostaticum)

– ligamentum sacrouterinum
(sacrogenitale)



Diaphragma pelvis

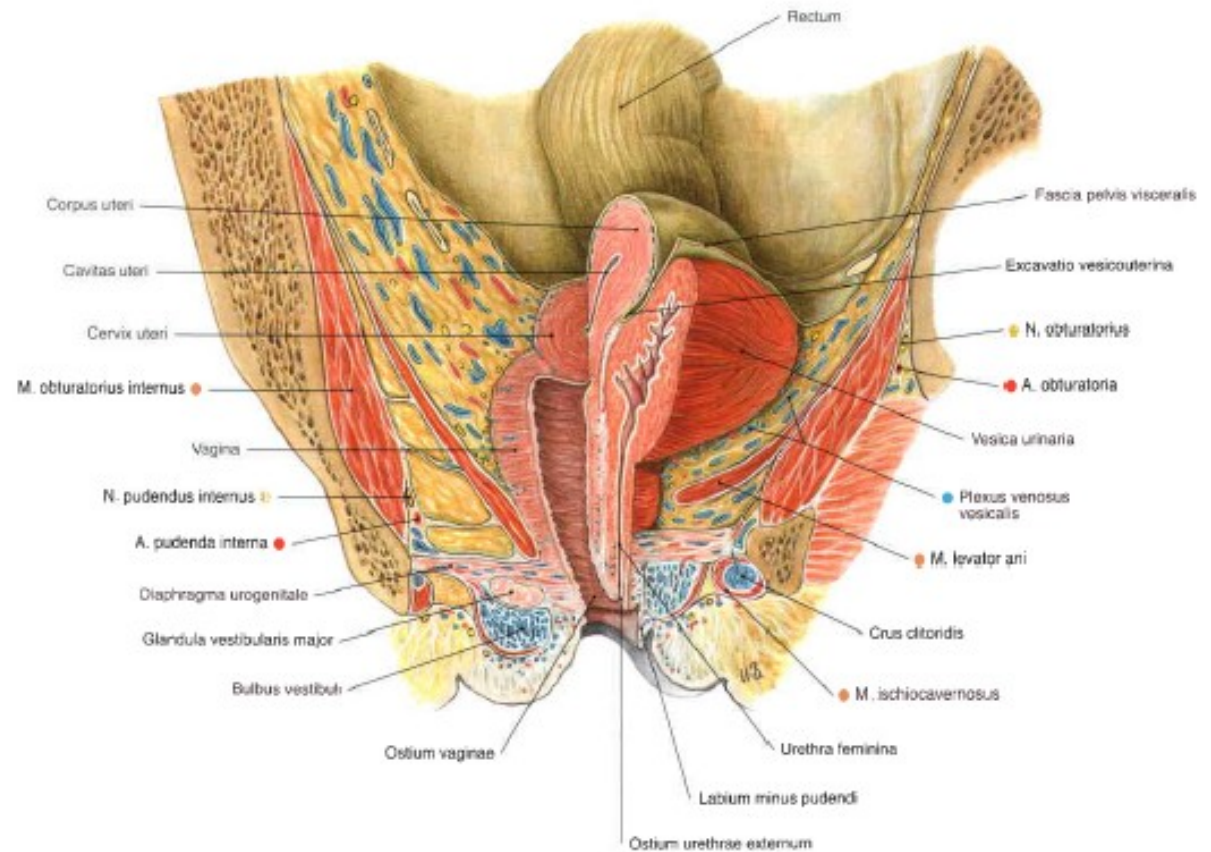
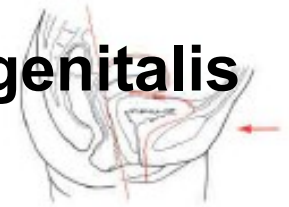Recessus pubicus fossae ischioanalis/-rectalis

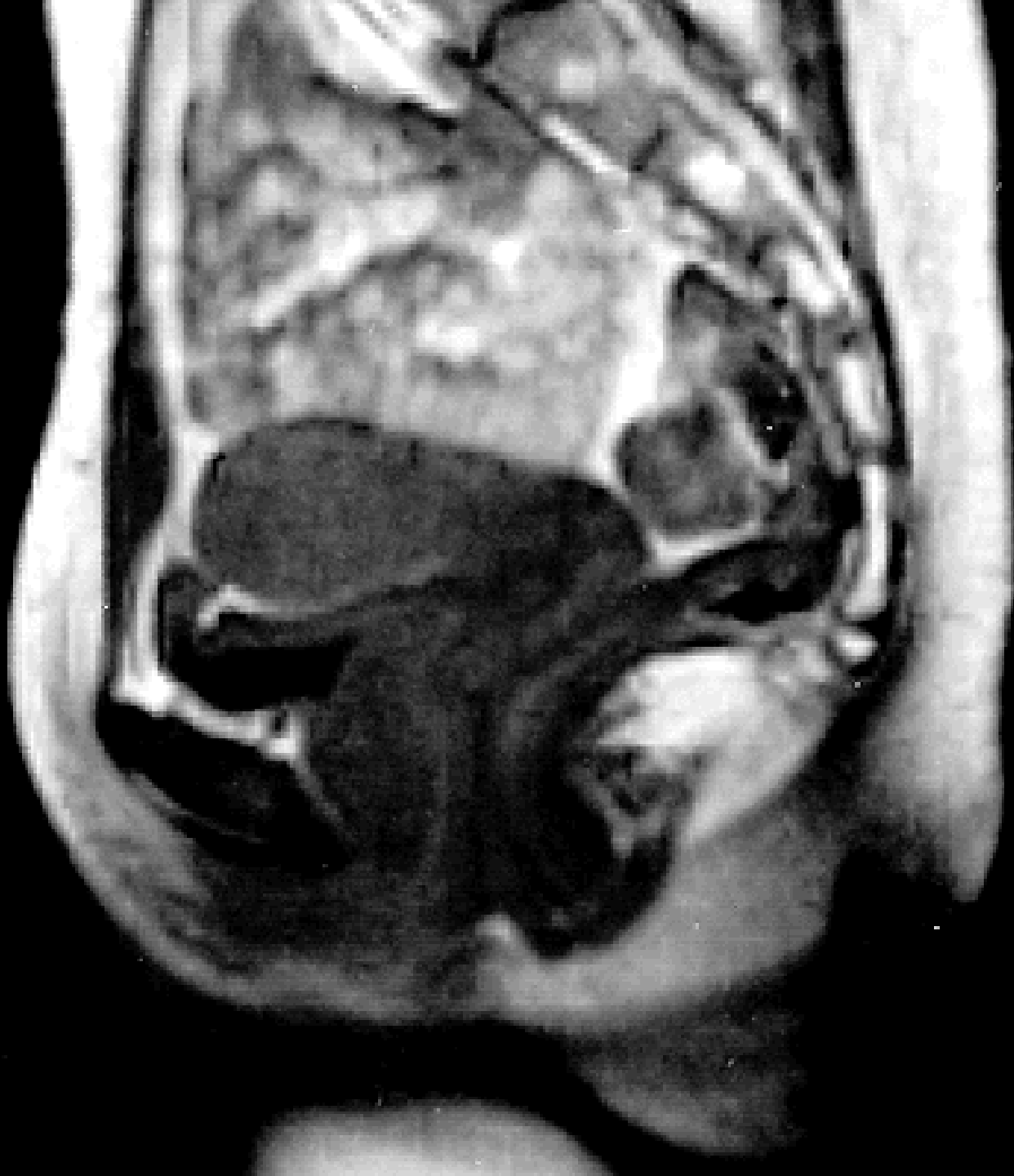Saccus perinei profundus

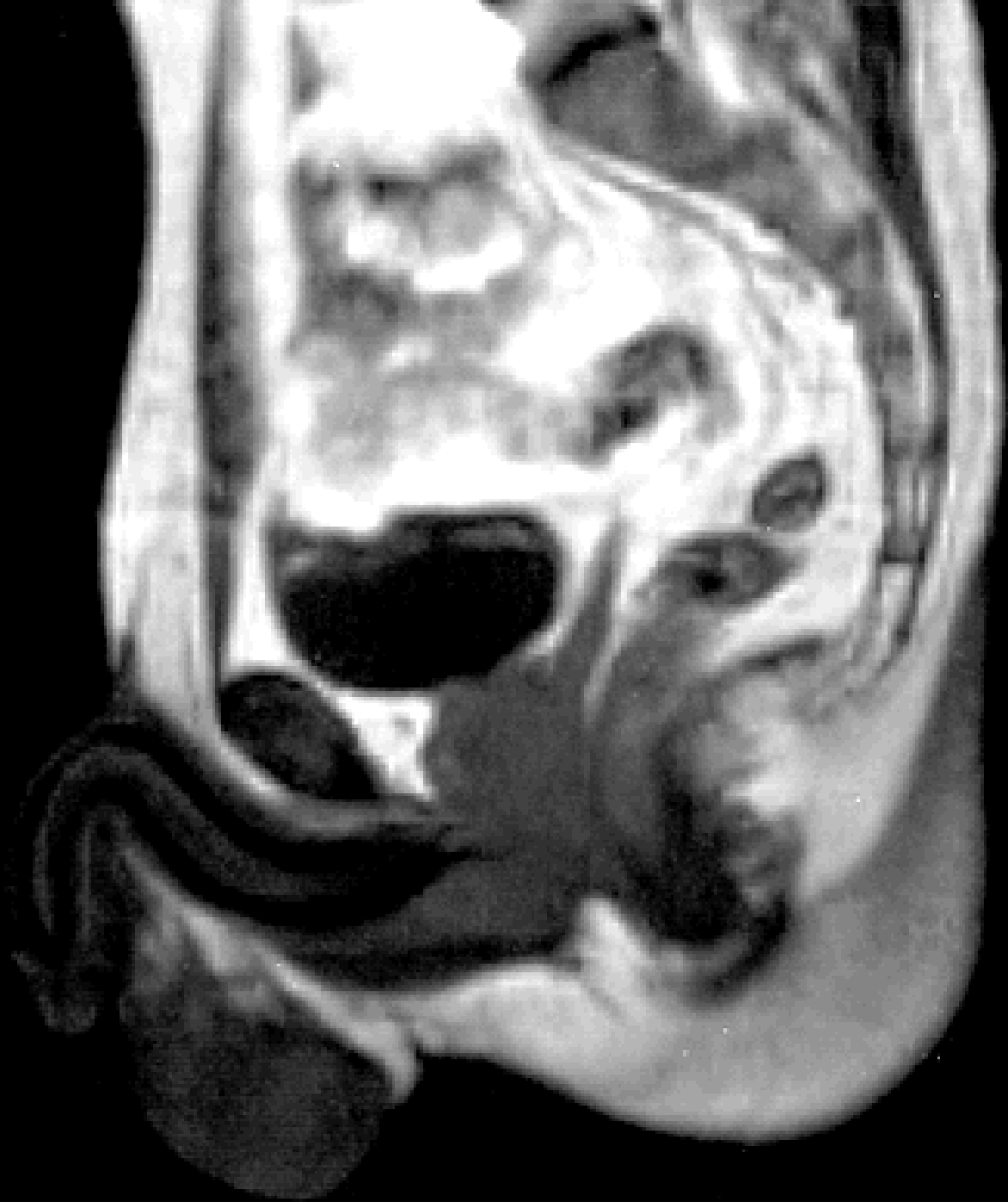
Membrana perinealis/Fascia inf.diaphragmatis urogenitalis

Spatium perinei spf.

Fascia perinei spf.







Illustrations and photographs were copied from:

Atlas der Anatomie des Menschen/Sobotta.

Putz,R., und Pabst,R. 20. Auflage. München:

Urban & Schwarzenberg, 1993

Netter: Interactive Atlas of Human Anatomy.

Windows Version 2.0

Čihák R: Anatomie 2 (Splanchnologia). Avicenum,

zdravotnické nakladatelství, Praha, 1988.