

DIGESTIVE SYSTEM

GASTROINTESTINAL TRACT – GIT (APPARATUS DIGESTORIUS)

Oral cavity (Cavitas oralis)

Pharynx

Oesophagus

Stomach (Gaster)

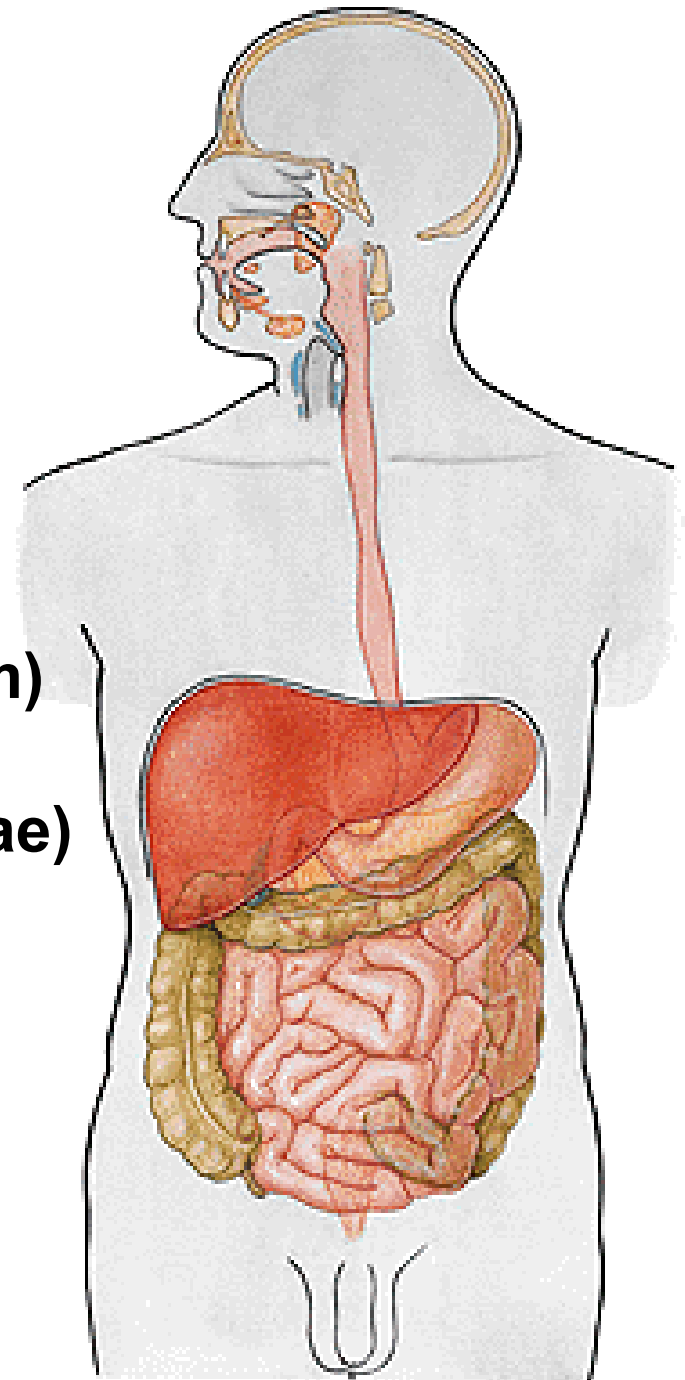
Small intestine (Intestinum tenue)

Large intestine (Intestinum crassum)

Salivary glands (Glandulae salivariae)

Liver (Hepar)

Pancreas

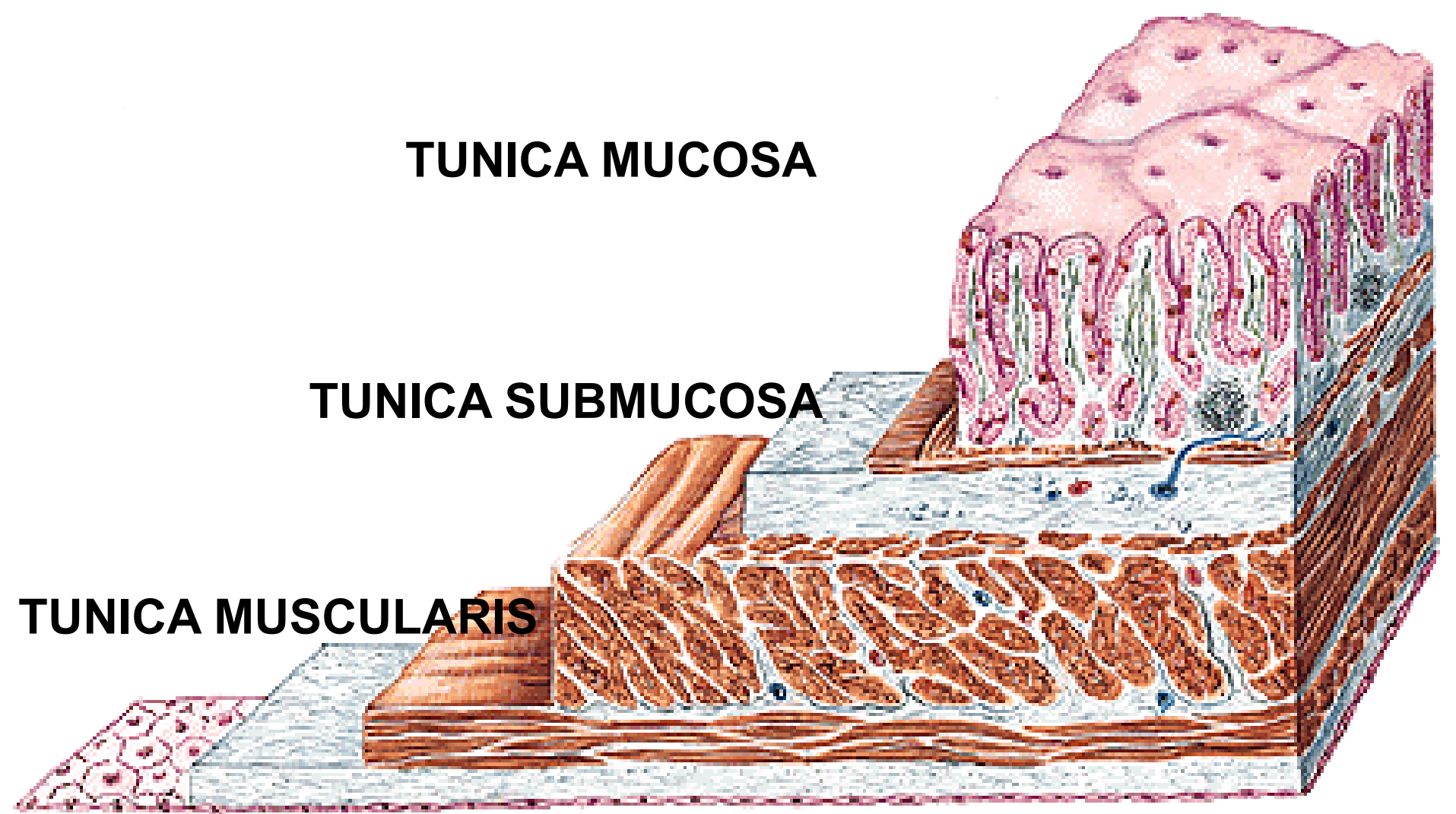


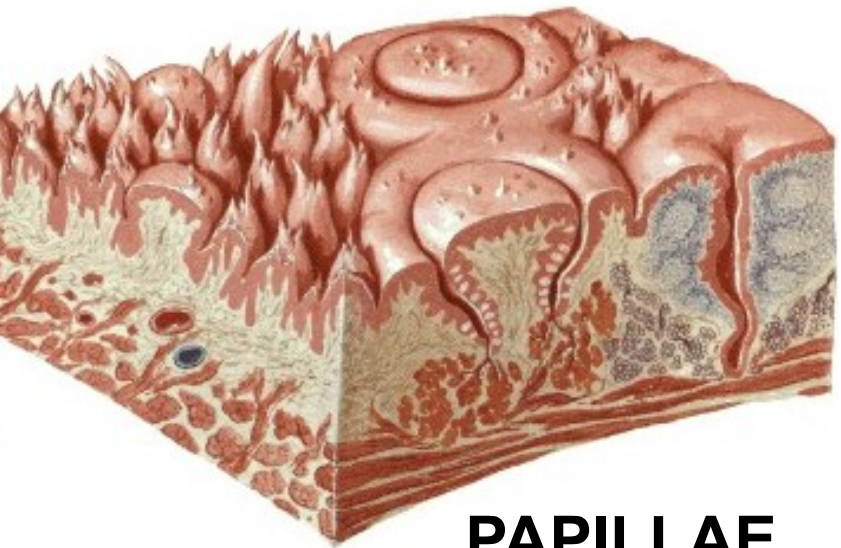
TUNICA MUCOSA

TUNICA SUBMUCOSA

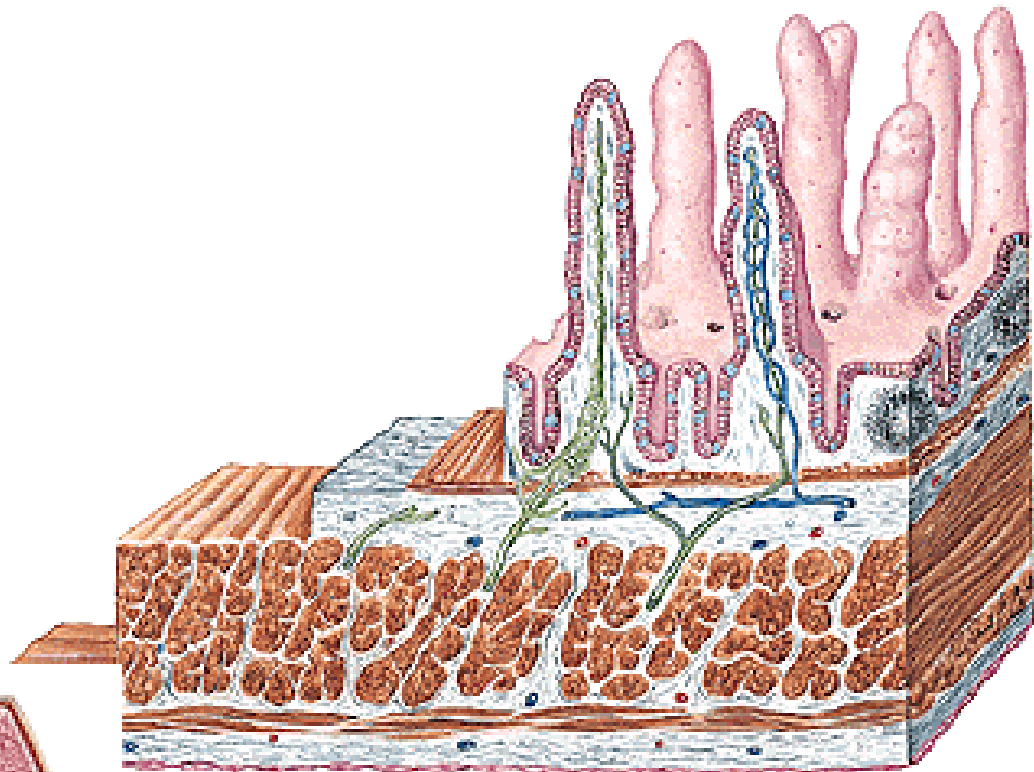
TUNICA MUSCULARIS

TUNICA ADVENTITIA (TUNICA SEROSA=visceral peritoneum)



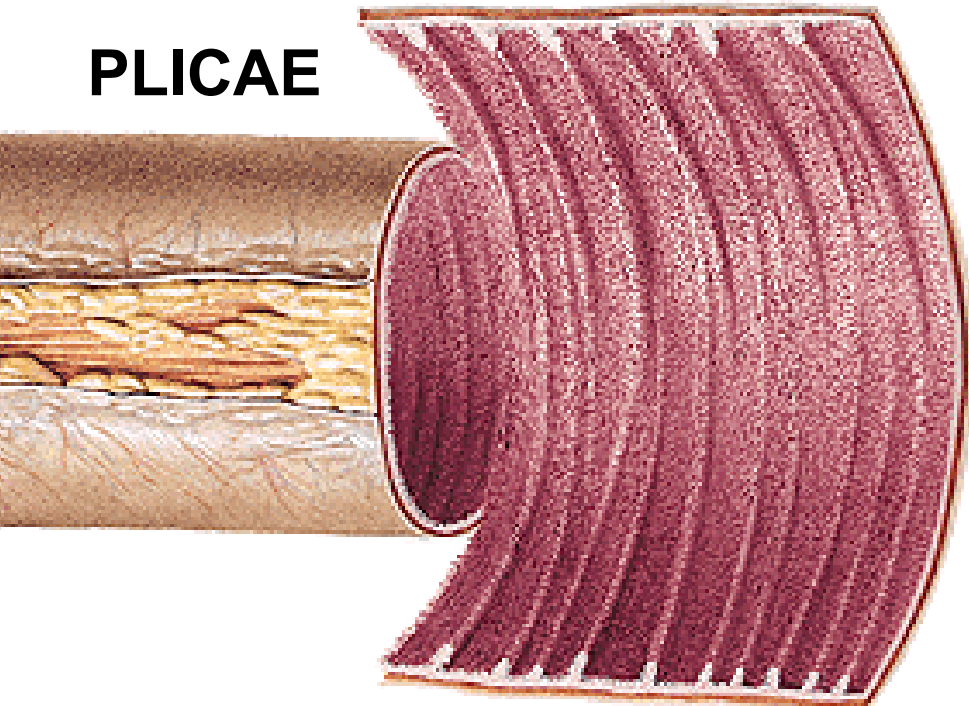


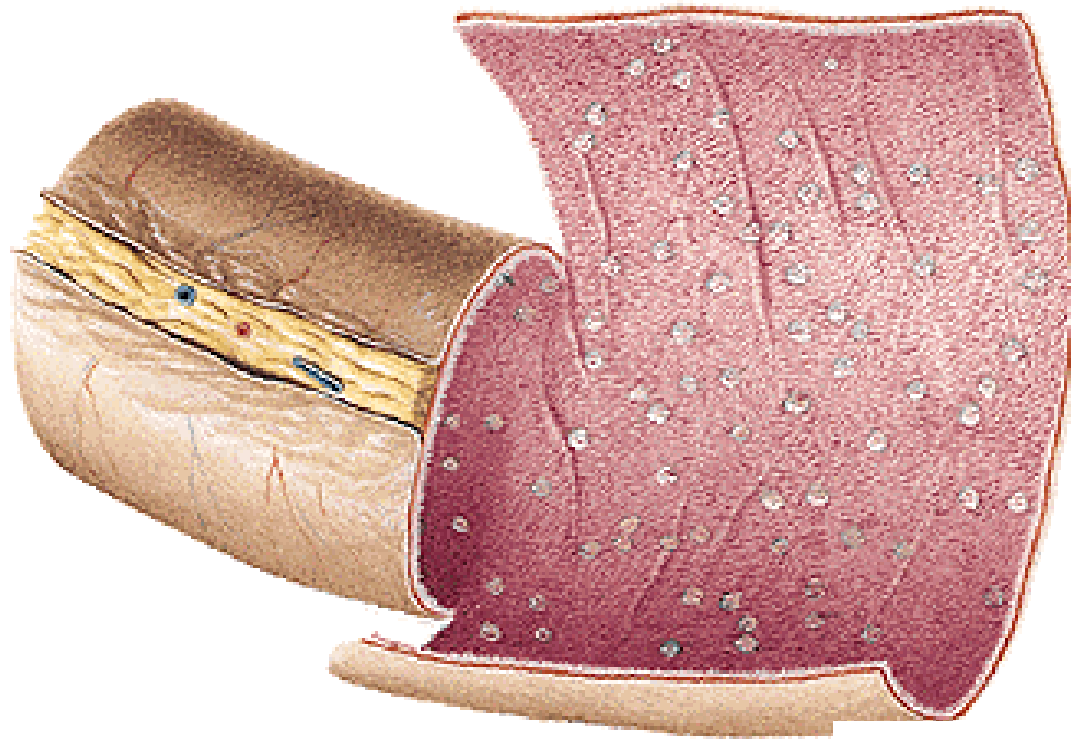PAPILLAE



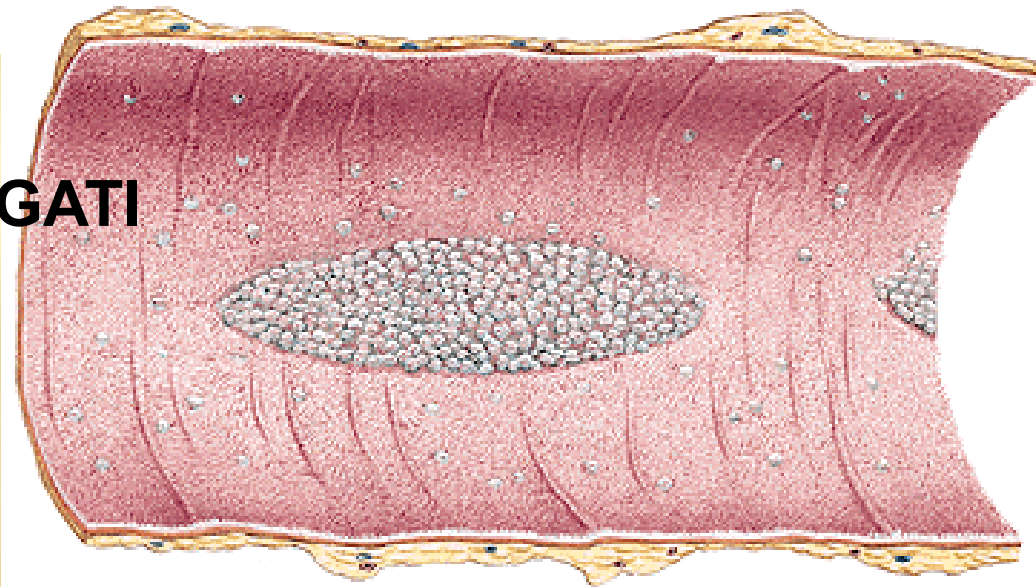
VILLI INTESTINALES

PLICAE





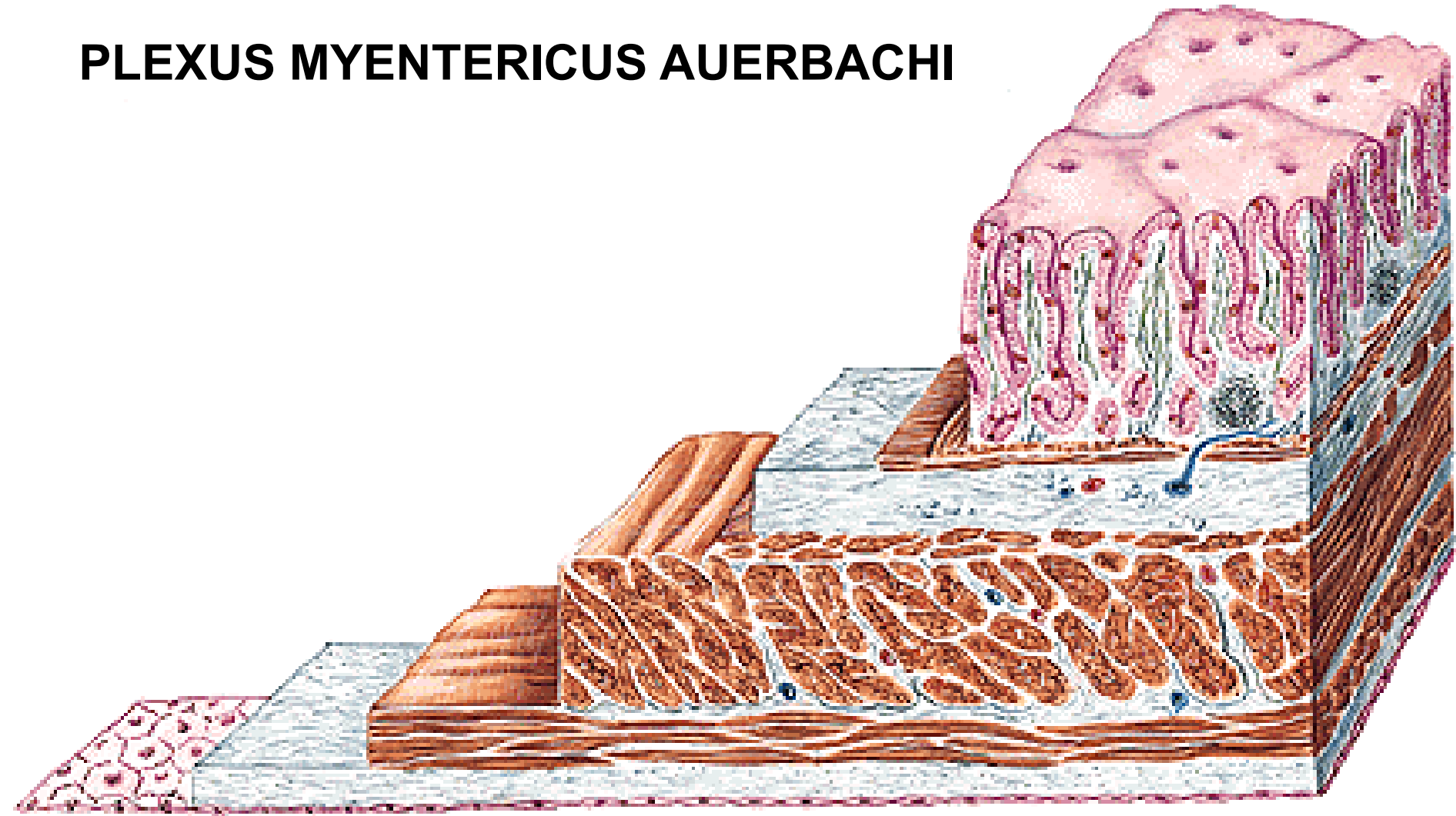
**FOLLICULI
LYMPHATICI SOLITARII**



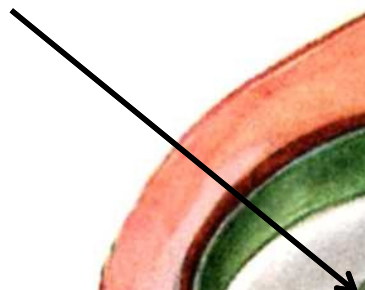
**FOLLICULI LYMPH. AGGREGATI
– PEYER'S PATCHES**

PLEXUS SUBMUCOSUS MEISSNERI

PLEXUS MYENTERICUS AUERBACHI



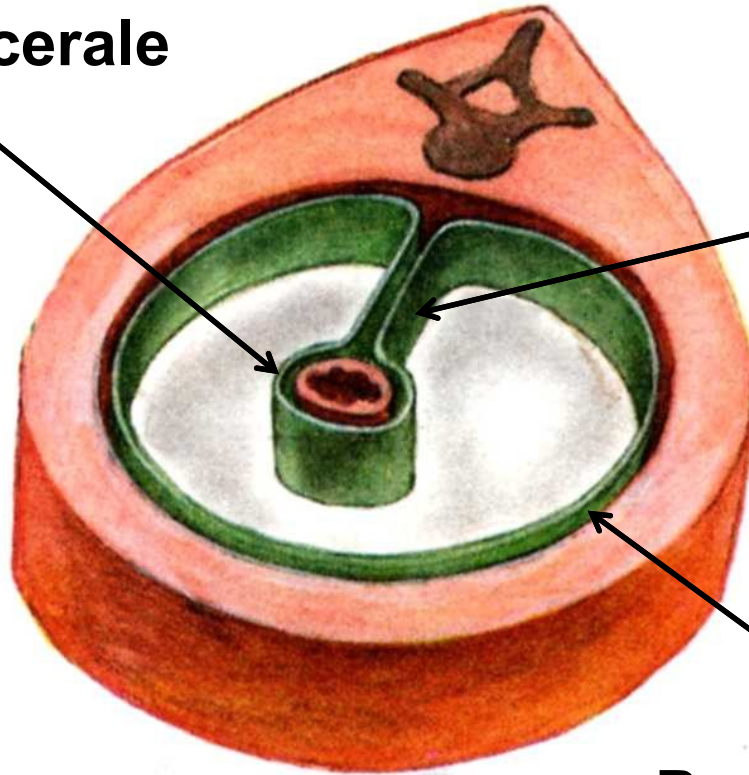

Peritoneum viscerale



Mesenterium



Peritoneum parietale



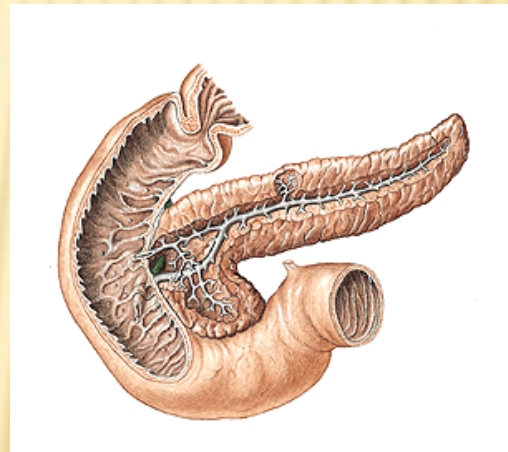
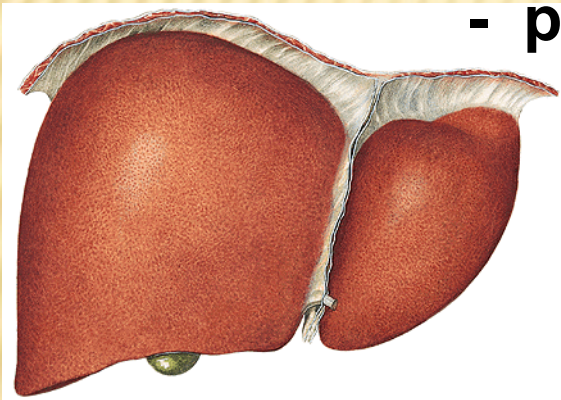
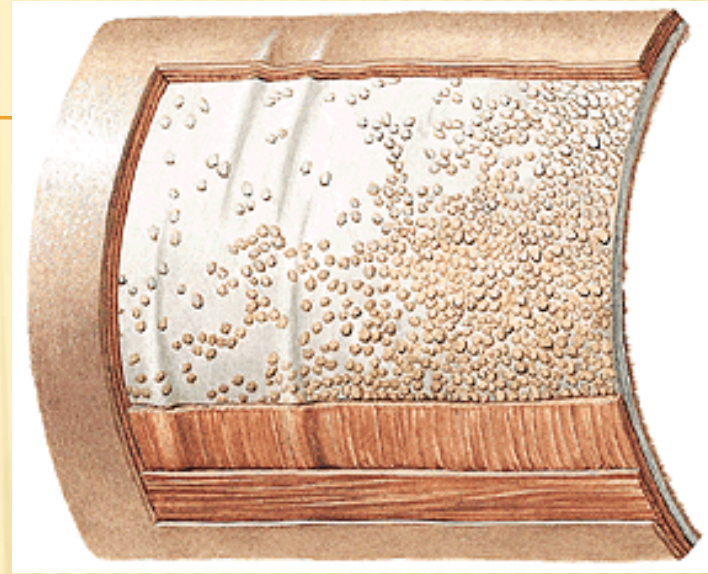
GLANDS OF GIT:

Intramural – goblet cells

- **small salivary glands**
- **glandulae duodenales**

Extramural – great salivary glands

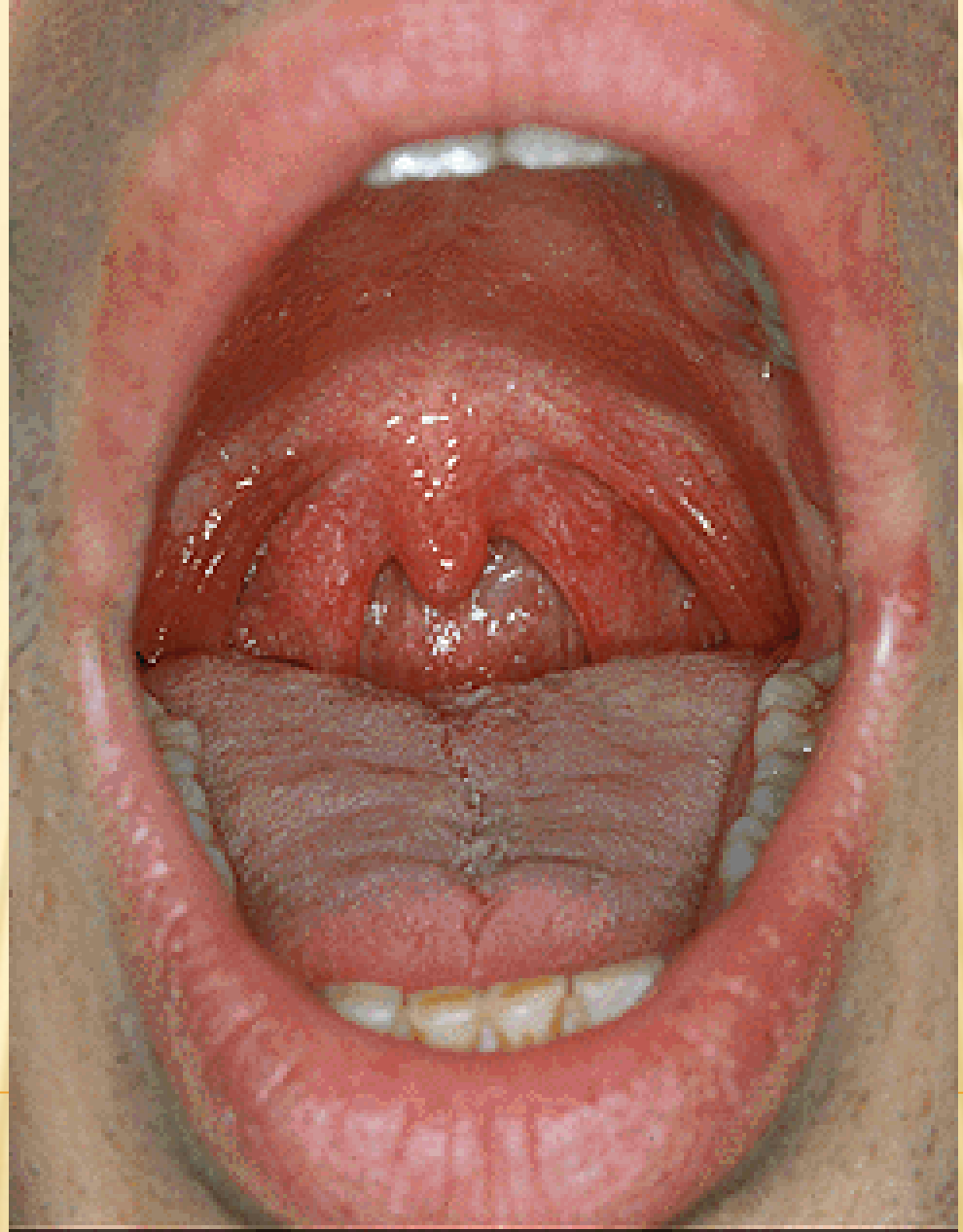- **liver**
- **pancreas**

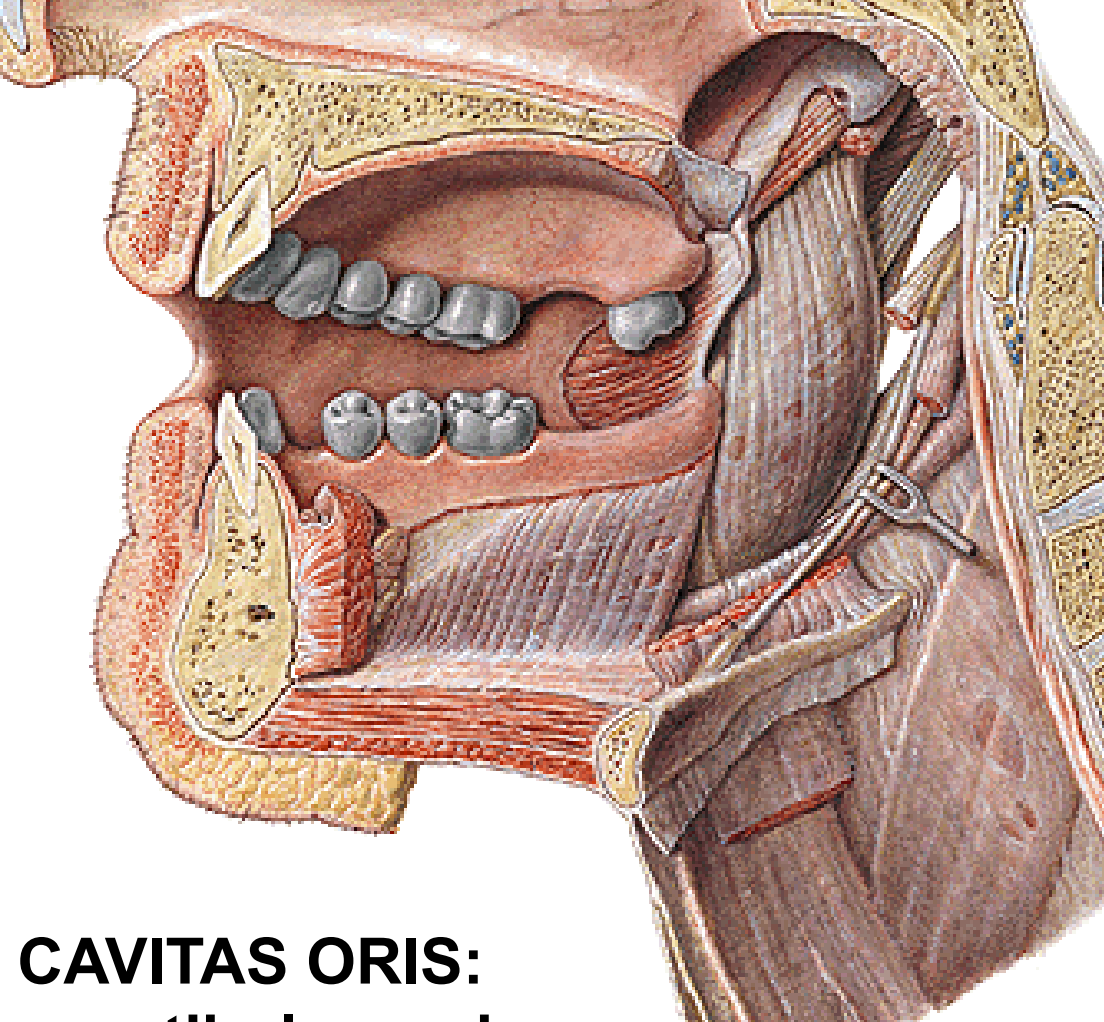


CAVITAS ORIS

Rima oris

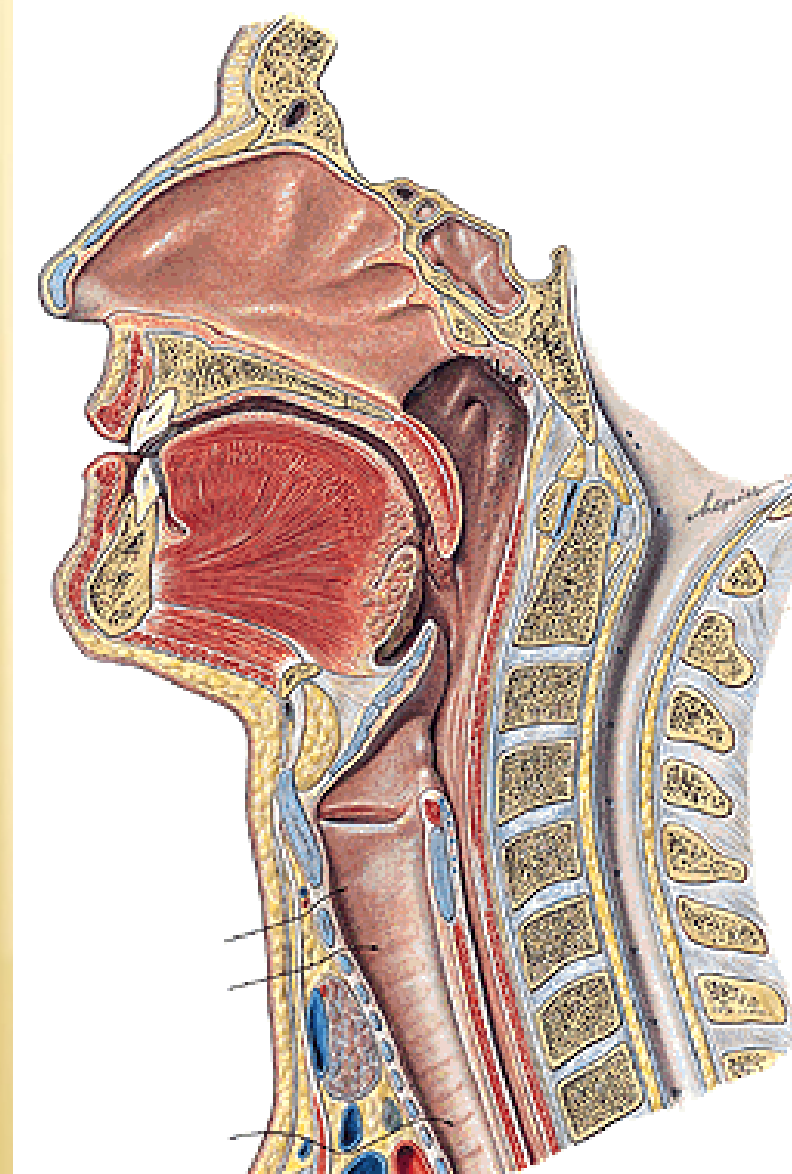
Isthmus faucium





CAVITAS ORIS:

- vestibulum oris**
- cavitas oris propria**



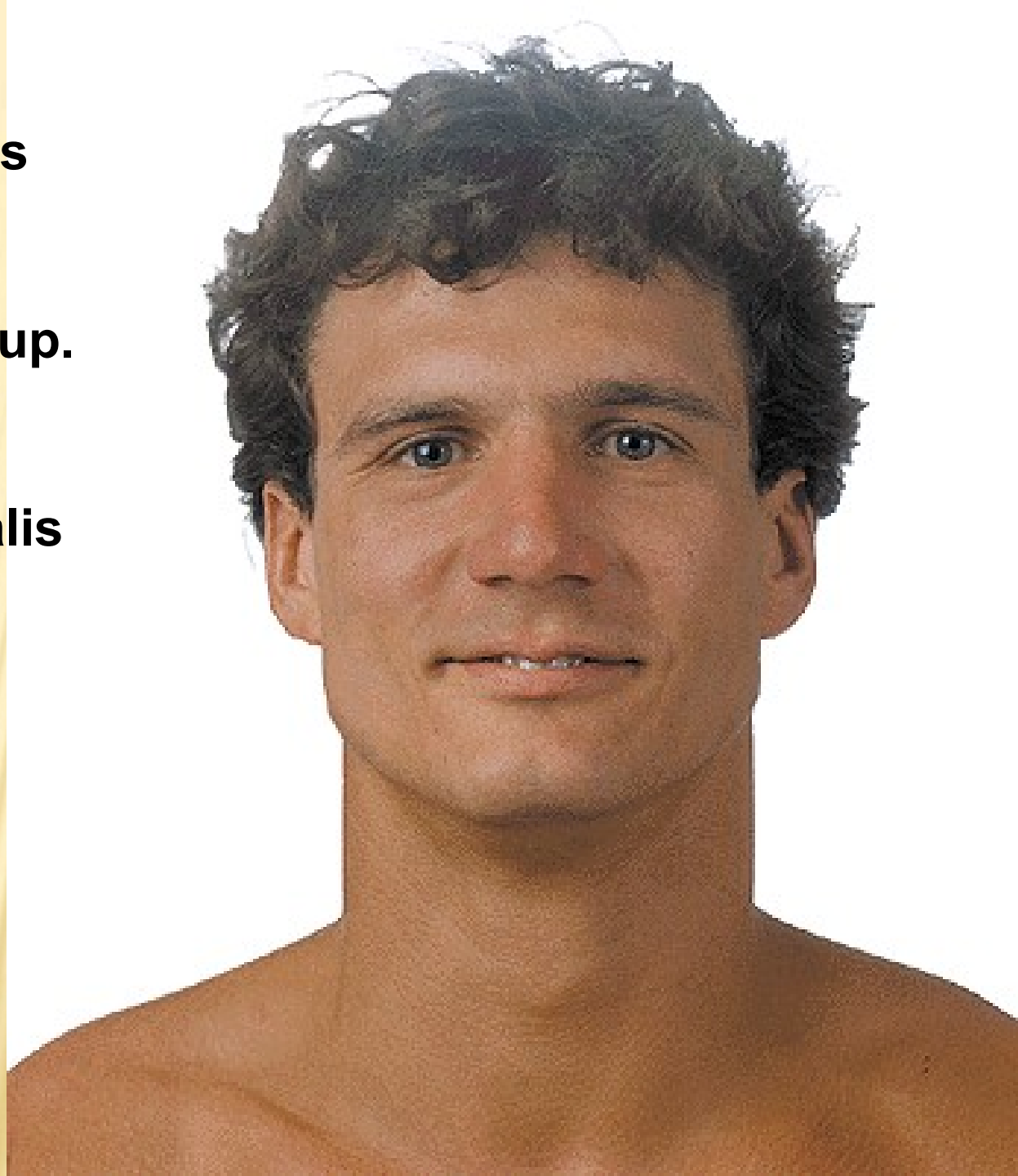
Labium superius:

- **sulcus nasolabialis**
- **pars intermedia**
- **philtrum**
- **tuberculum labii sup.**

Labium inferius:

- **sulcus mentolabialis**

Anguli oris



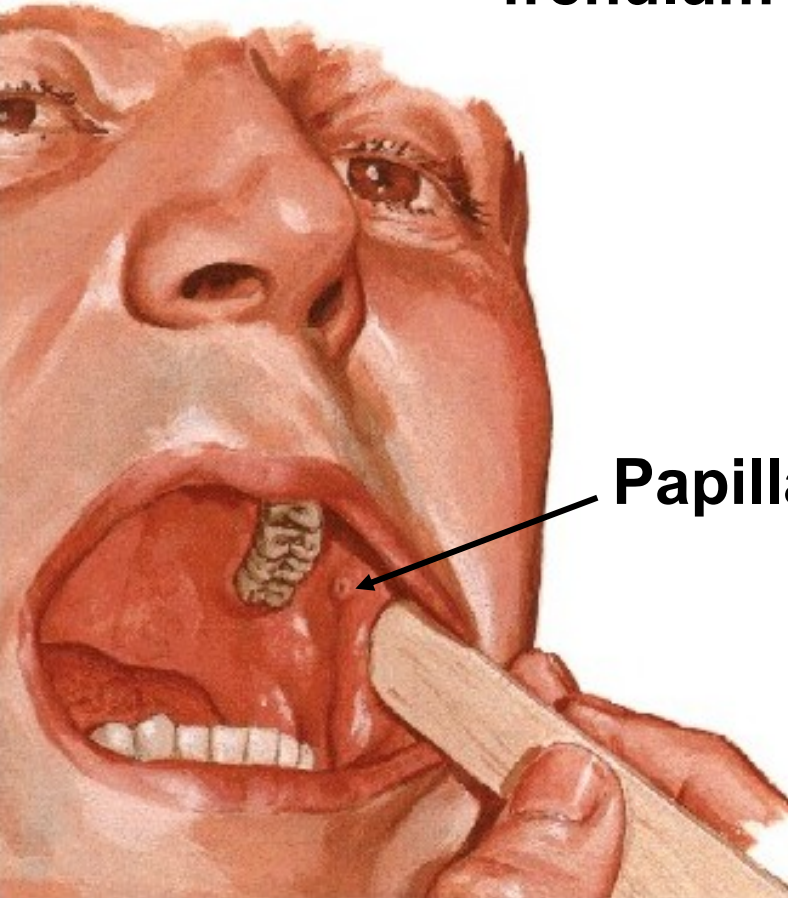
VESTIBULUM ORIS

Fornix vestibuli sup.

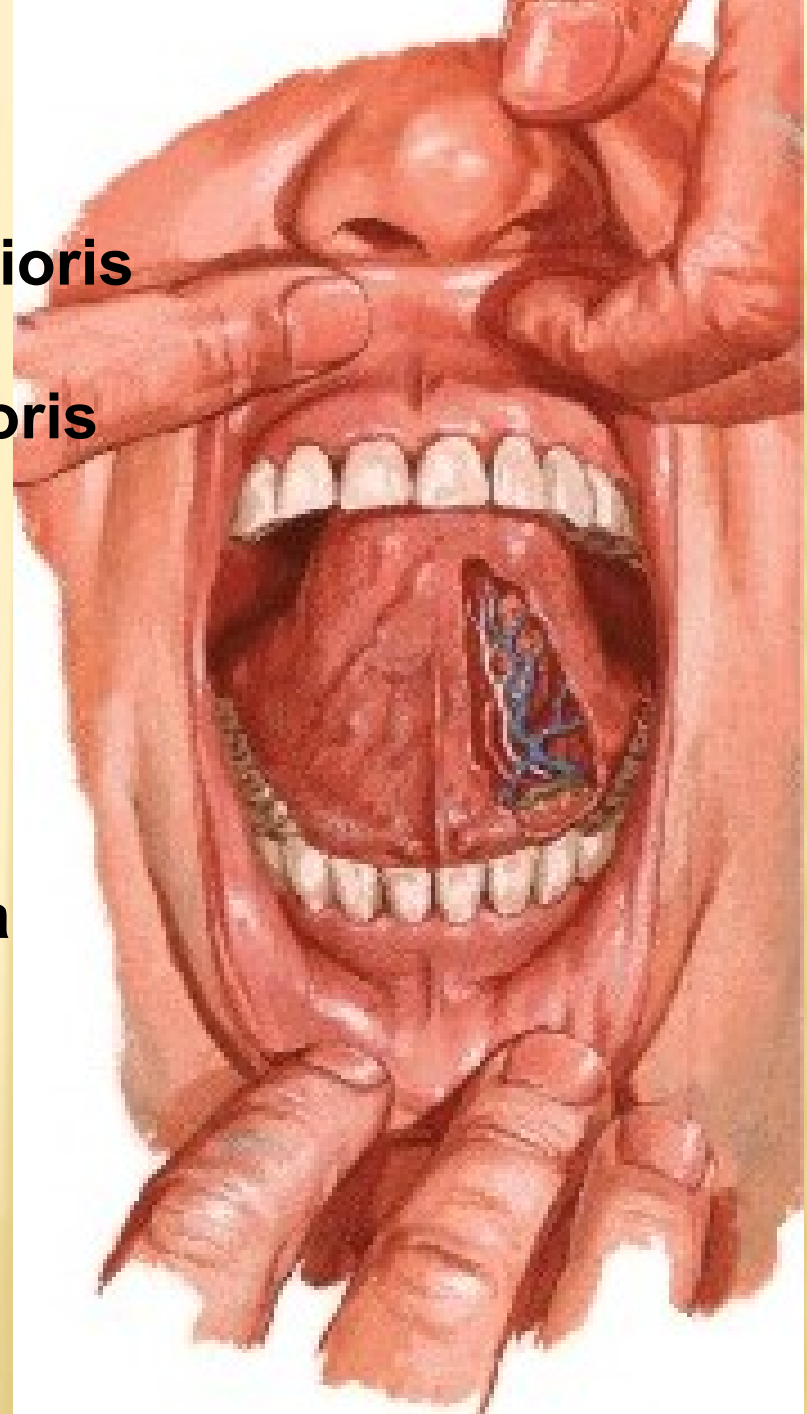
- frenulum labii superioris

Fornix vestibuli inf.

- frenulum labii inferioris



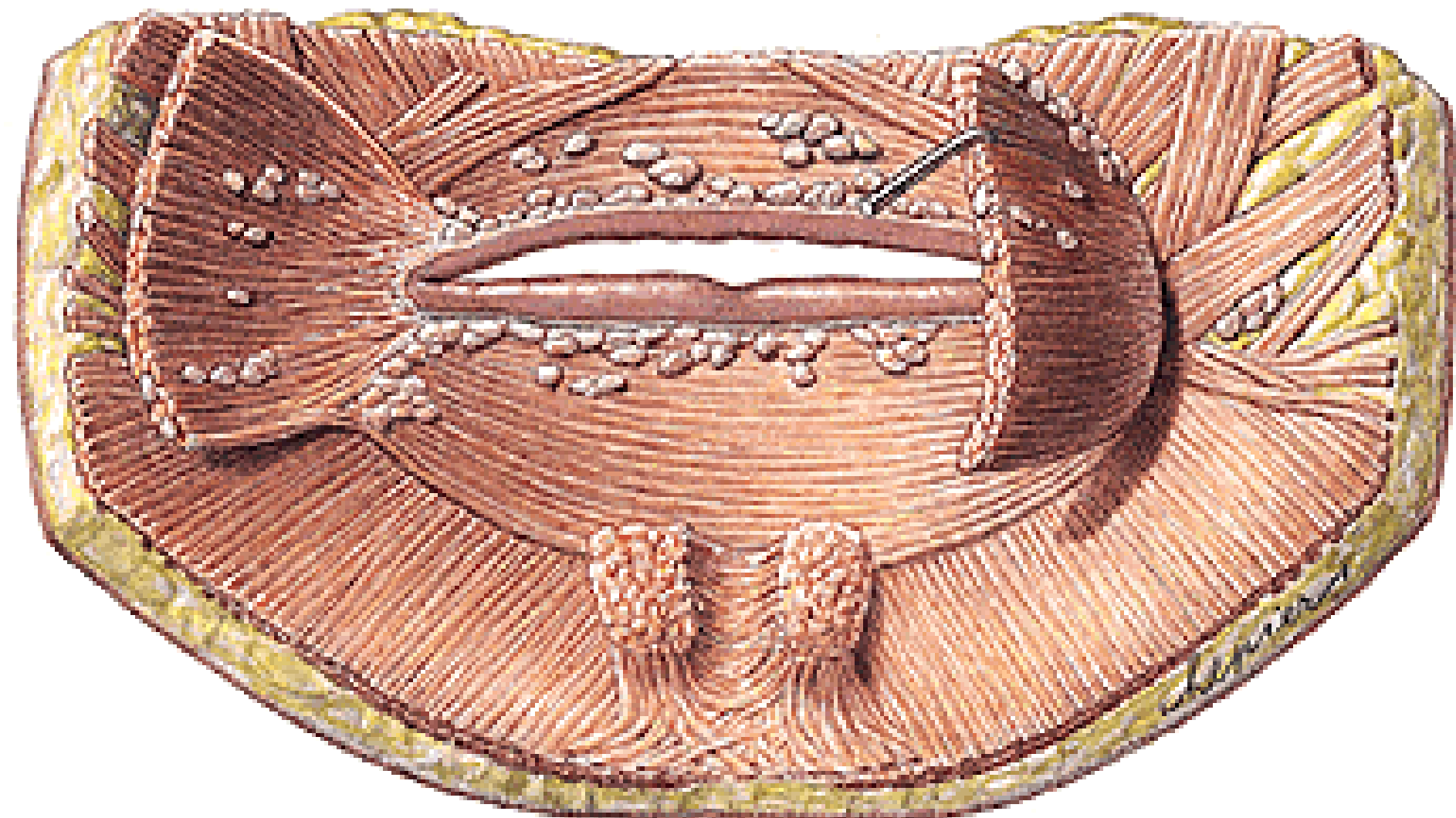
Papilla parotidea

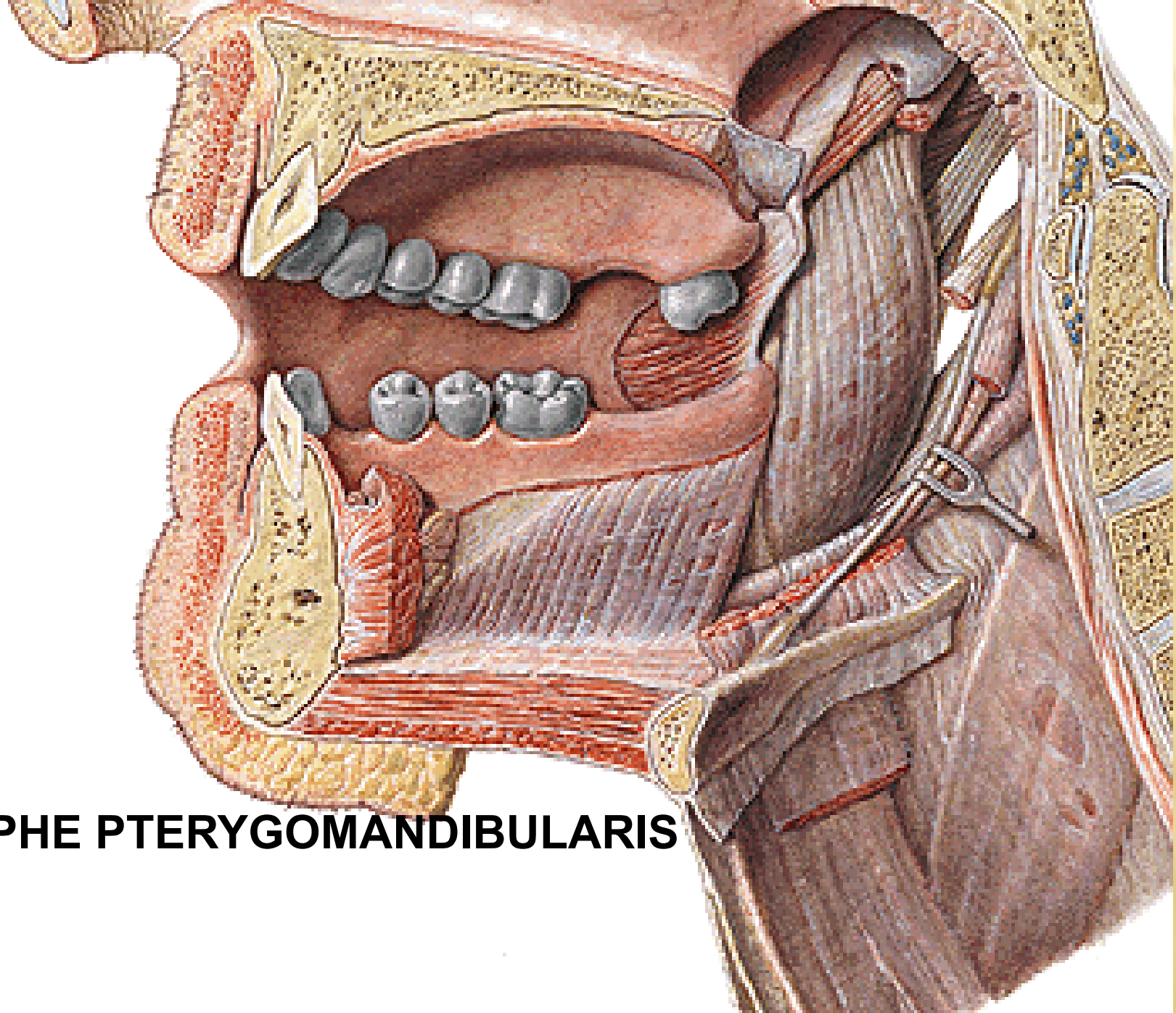


Glandulae labiales, buccales, molares

M. orbicularis oris

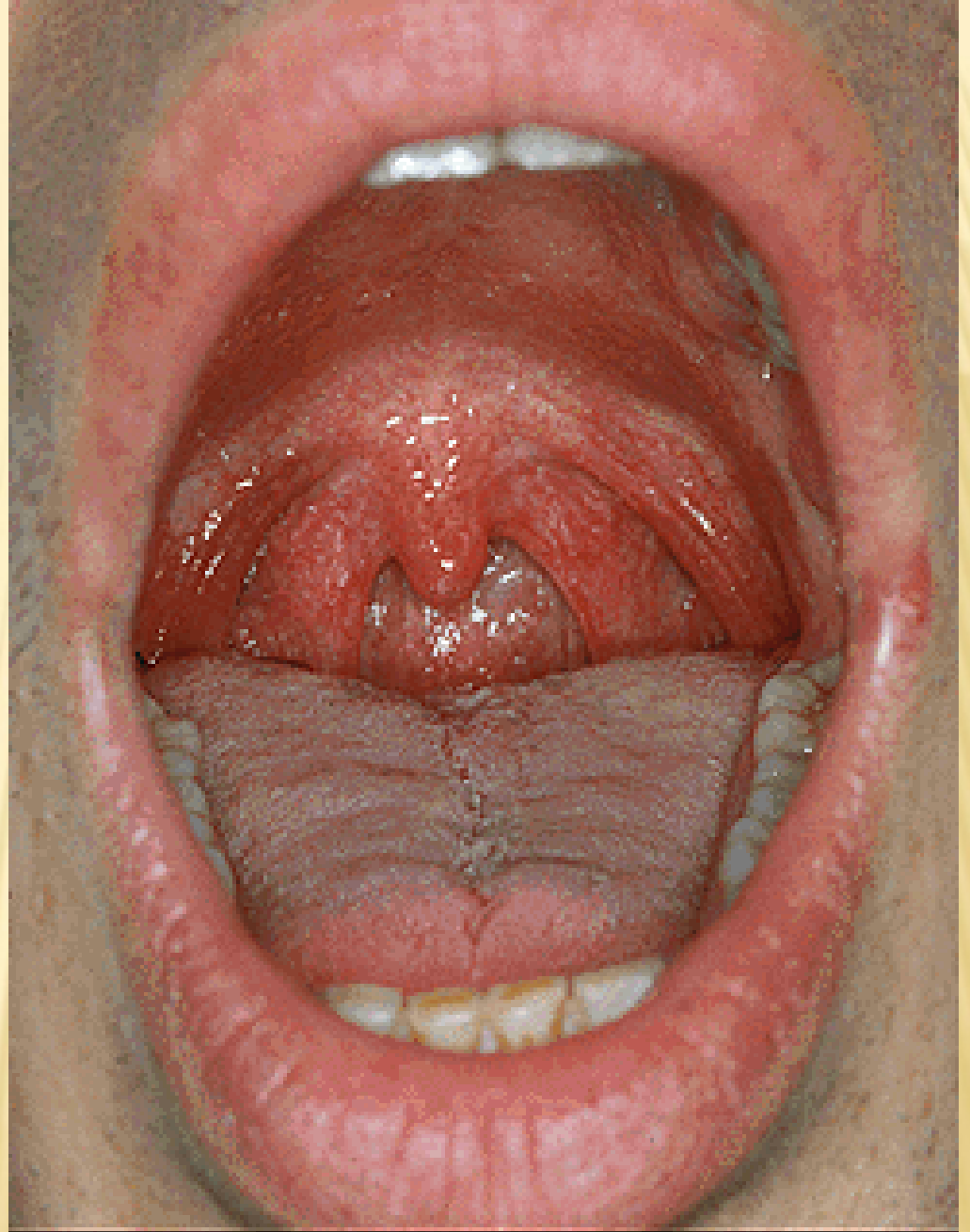M. buccinator





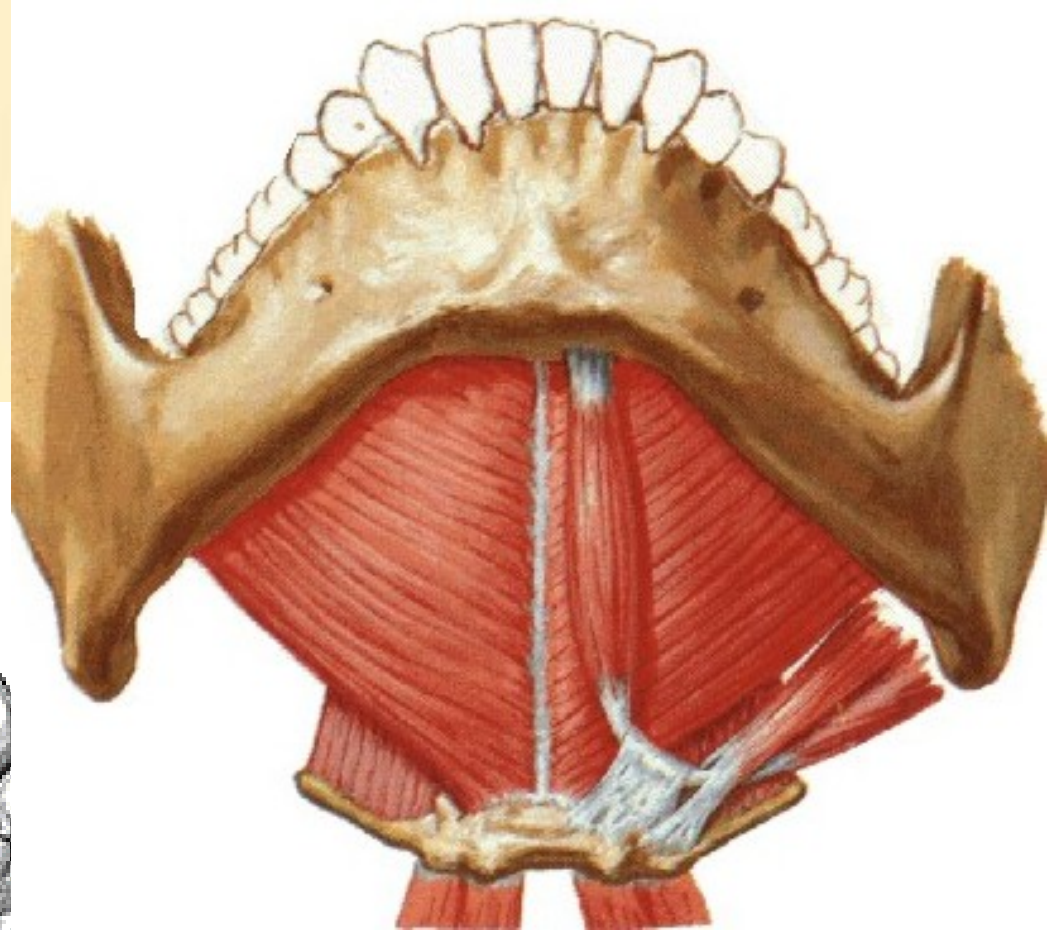
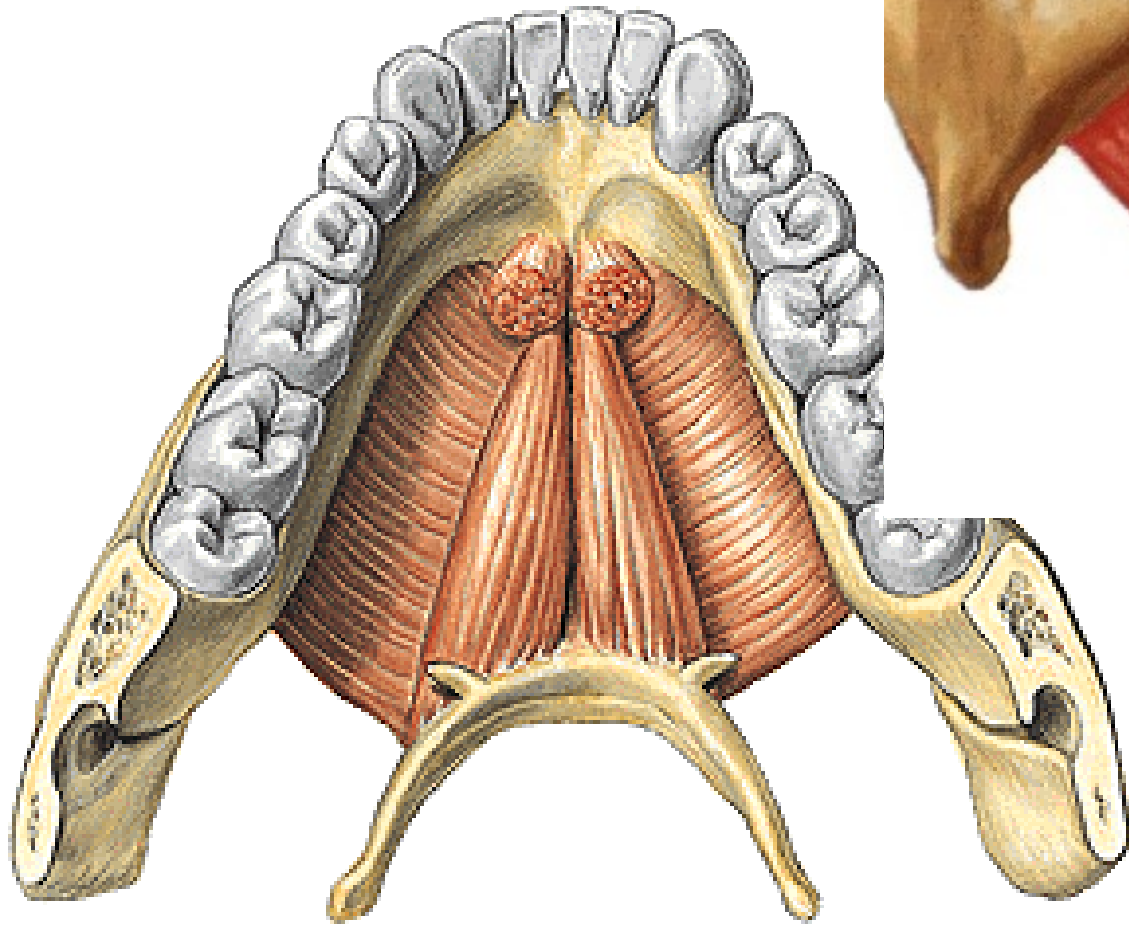
RAPHE PTERYGOMANDIBULARIS

CAVITAS ORIS PROPRIA



DIAPHRAGMA ORIS

- m. mylohyoideus
(raphe mylohyoidea)
- m. geniohyoideus
- m. digastricus

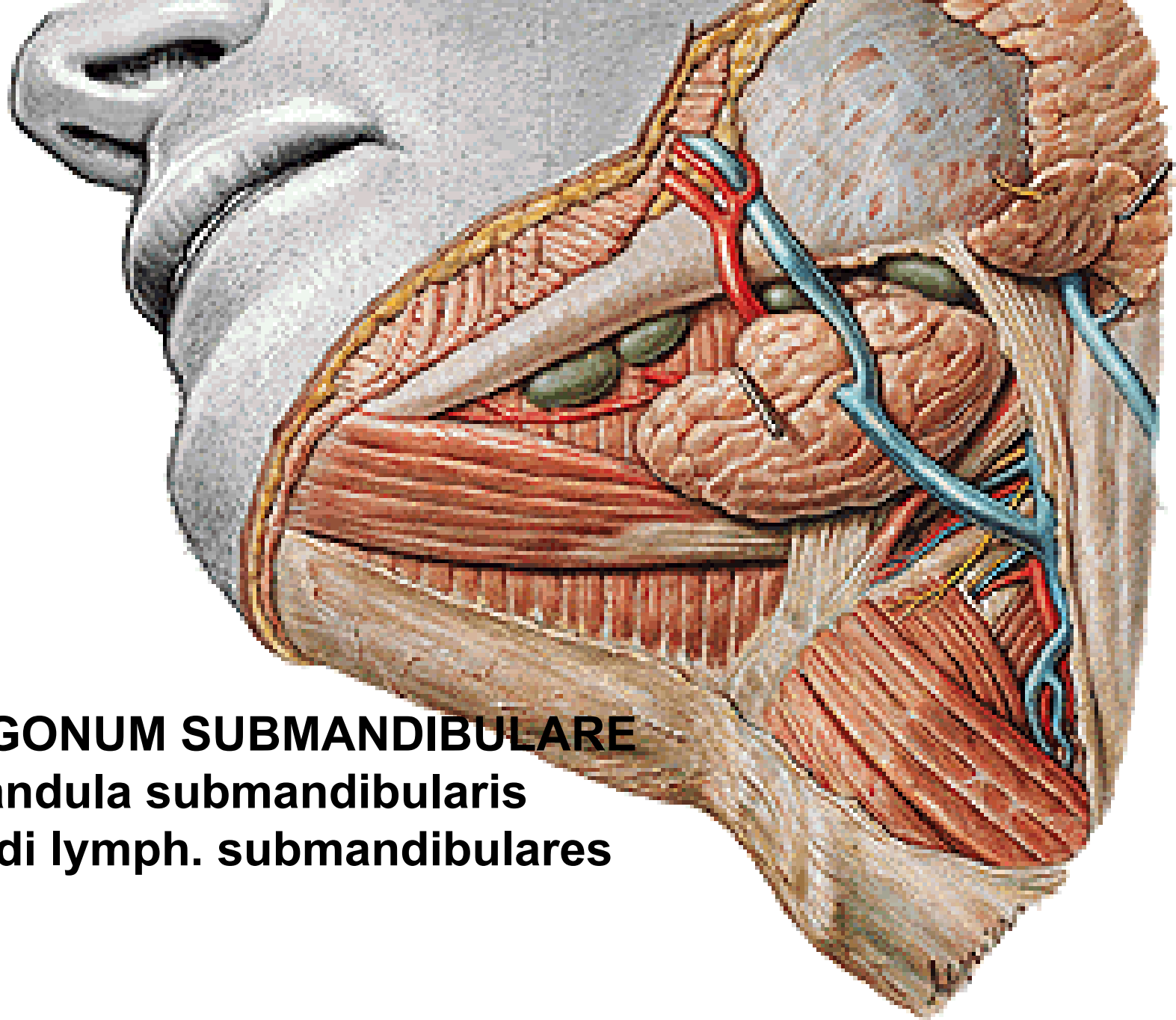


GLANDULAE SALIVARIAE MINORES

- labiales, buccales, molares, palatinae, linguales

GLANDULAE SALIVARIAE MAJORES

- submandibularis
- sublingualis
- parotis



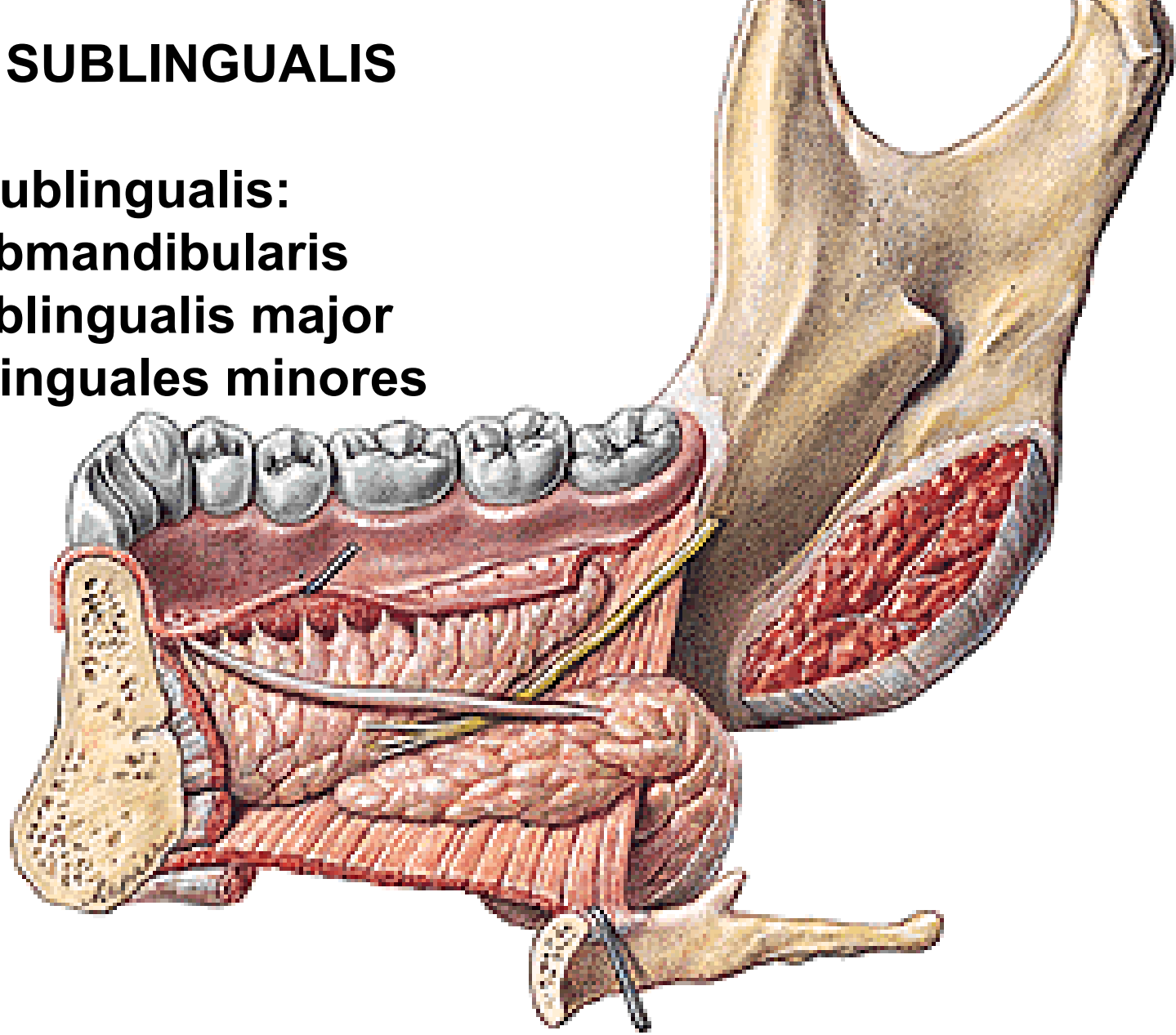
TRIGONUM SUBMANDIBULARE
- glandula submandibularis
- nodi lymph. submandibulares

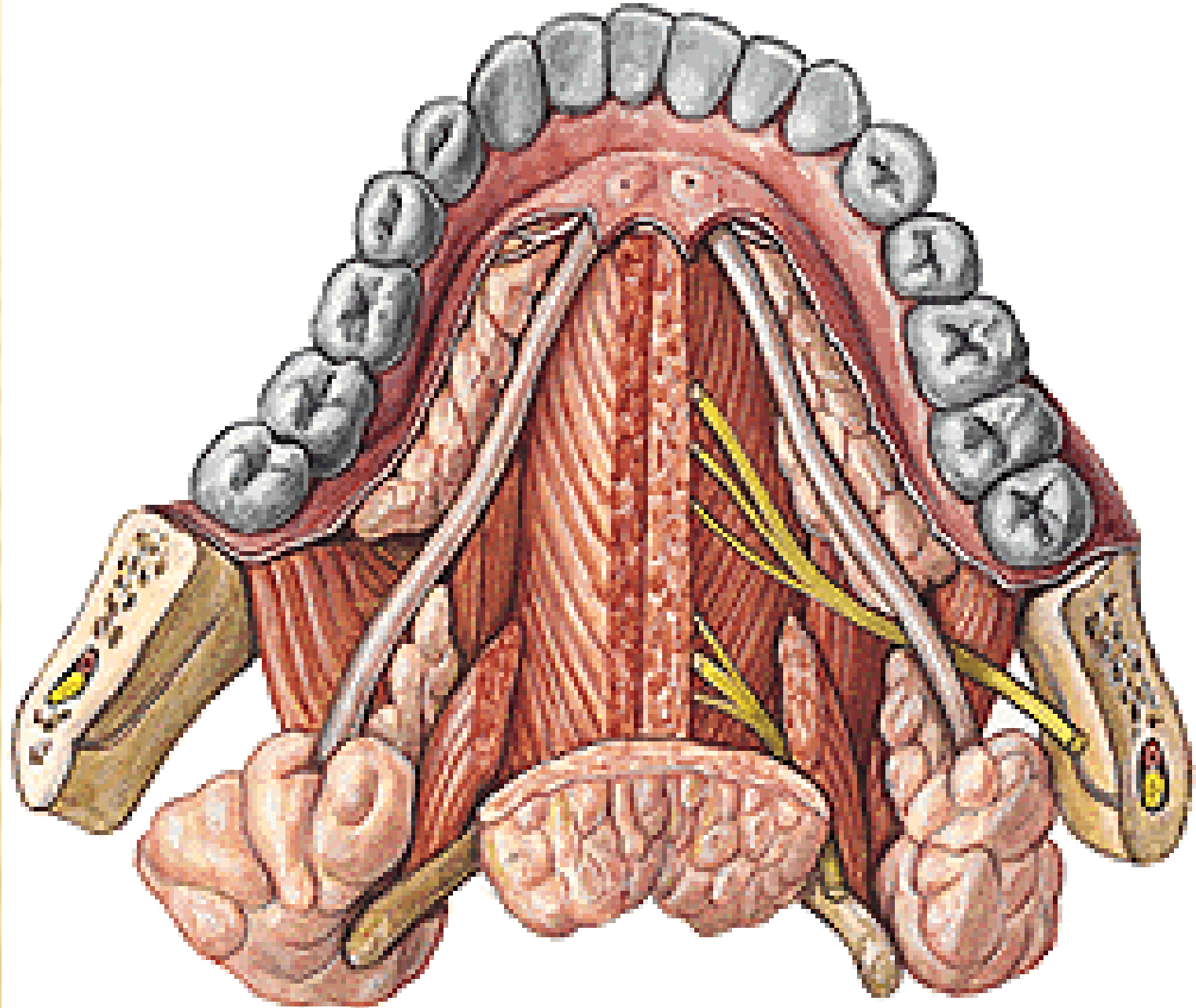
GLANDULA SUBLINGUALIS

Caruncula sublingualis:

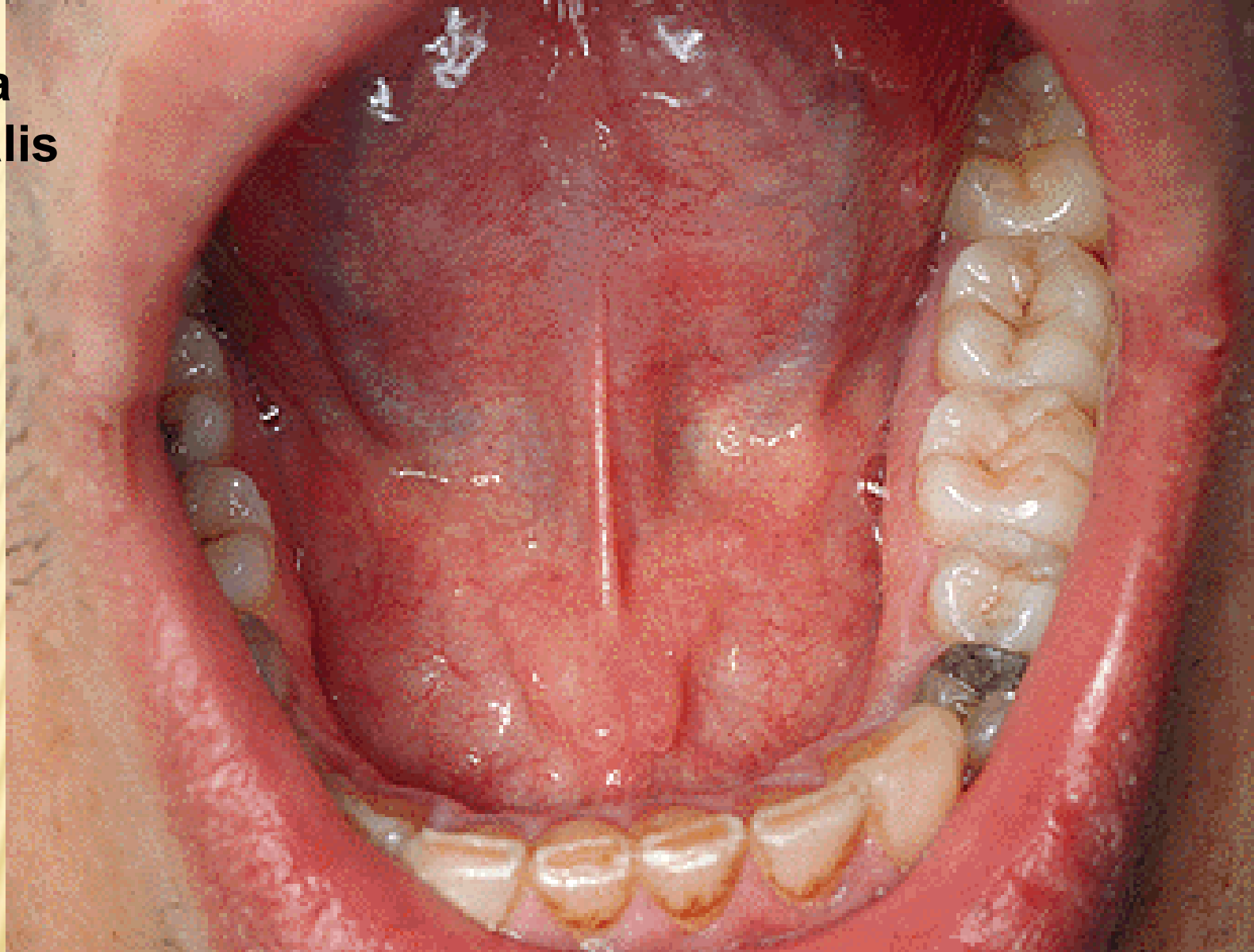- ductus submandibularis
- ductus sublingualis major

Ductus sublinguales minores





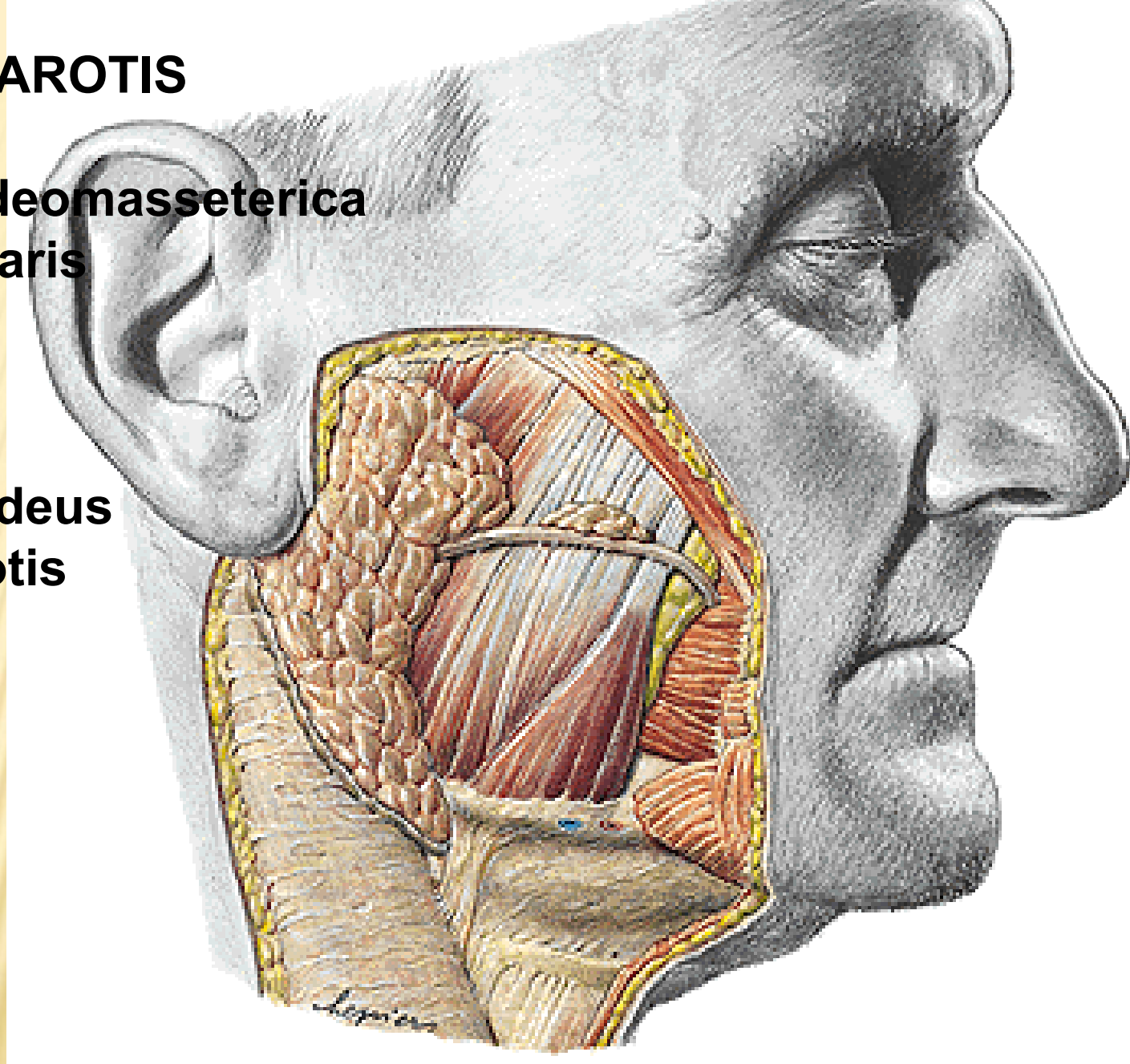
**Caruncula
sublingualis**



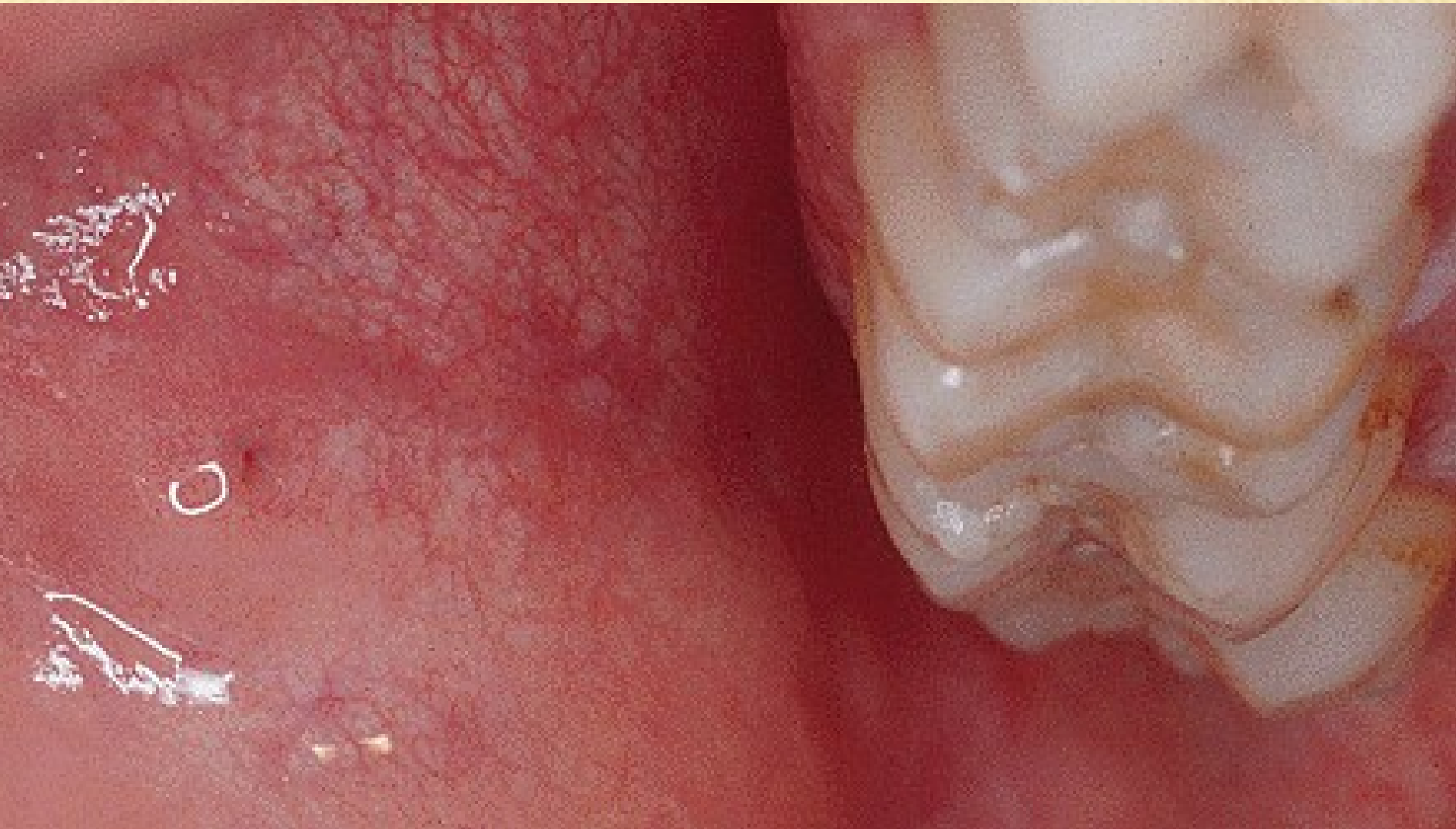GLANDULA PAROTIS

Fascia parotideomasseterica
Tractus angularis

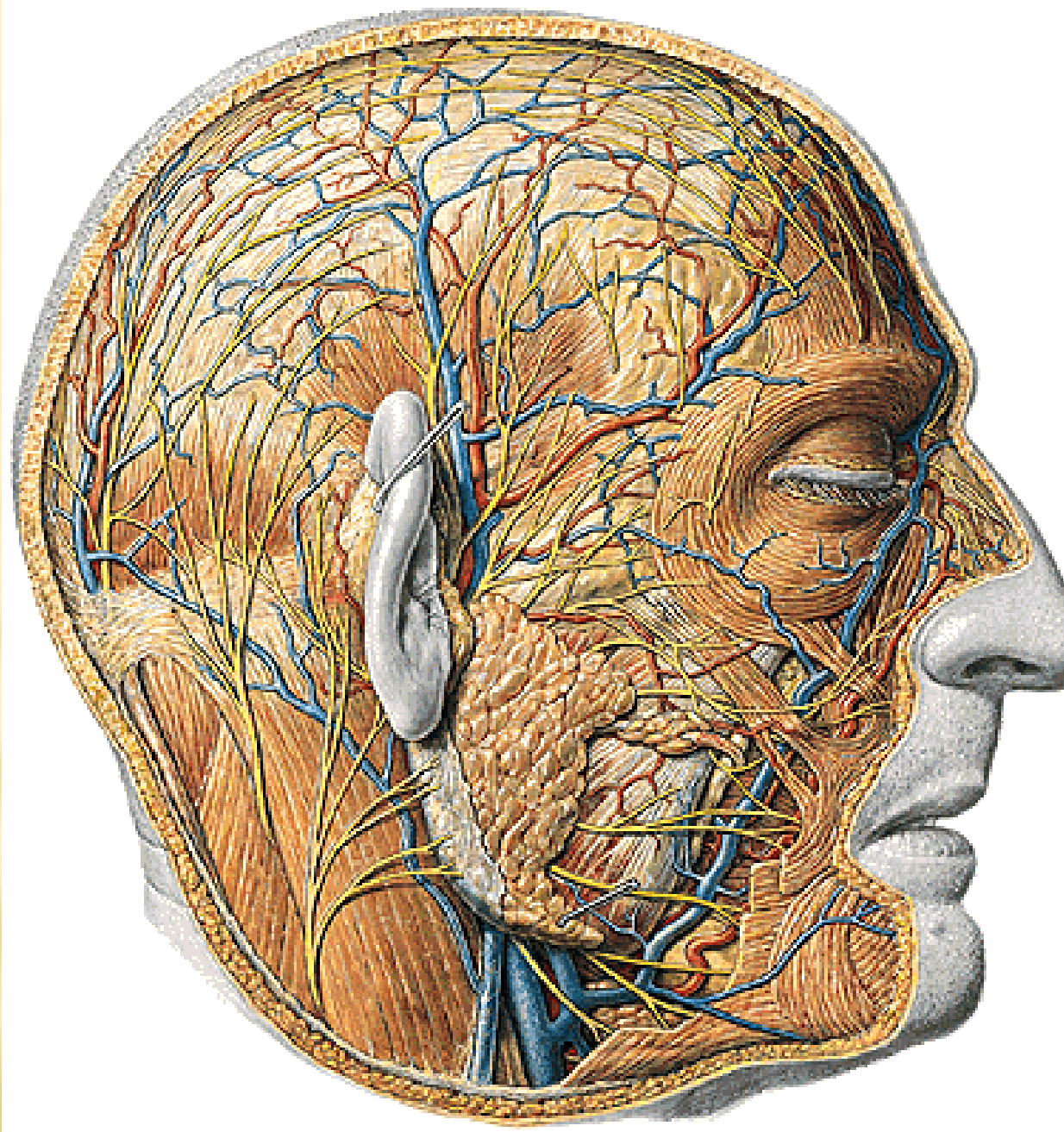
Ductus parotideus
Glandula parotis
accessoria



PAPILLA PAROTIDEA

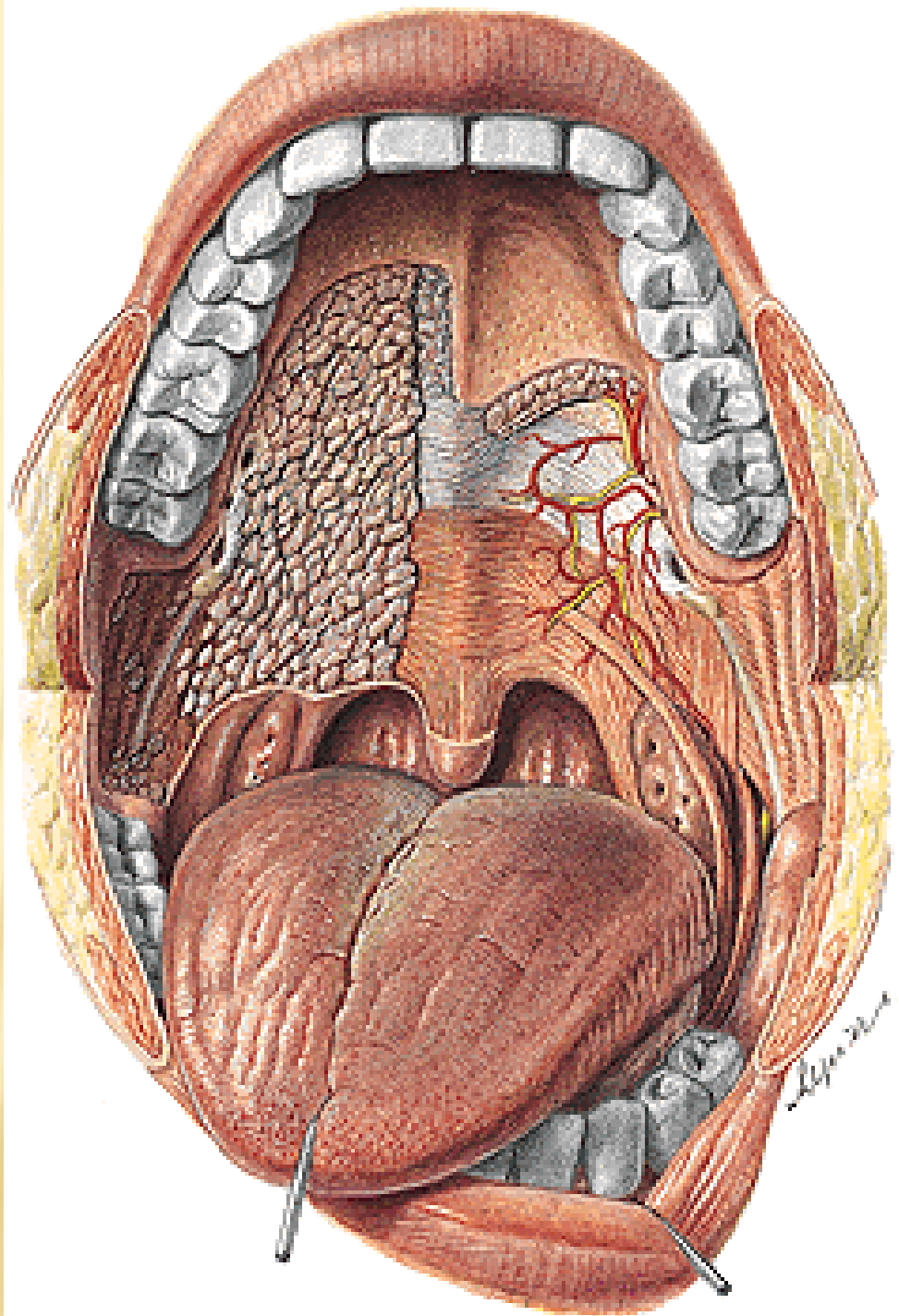


N. facialis (CN VII)
- plexus parotideus
V. retromandibularis
A. carotis ext.
N. auriculotemporalis

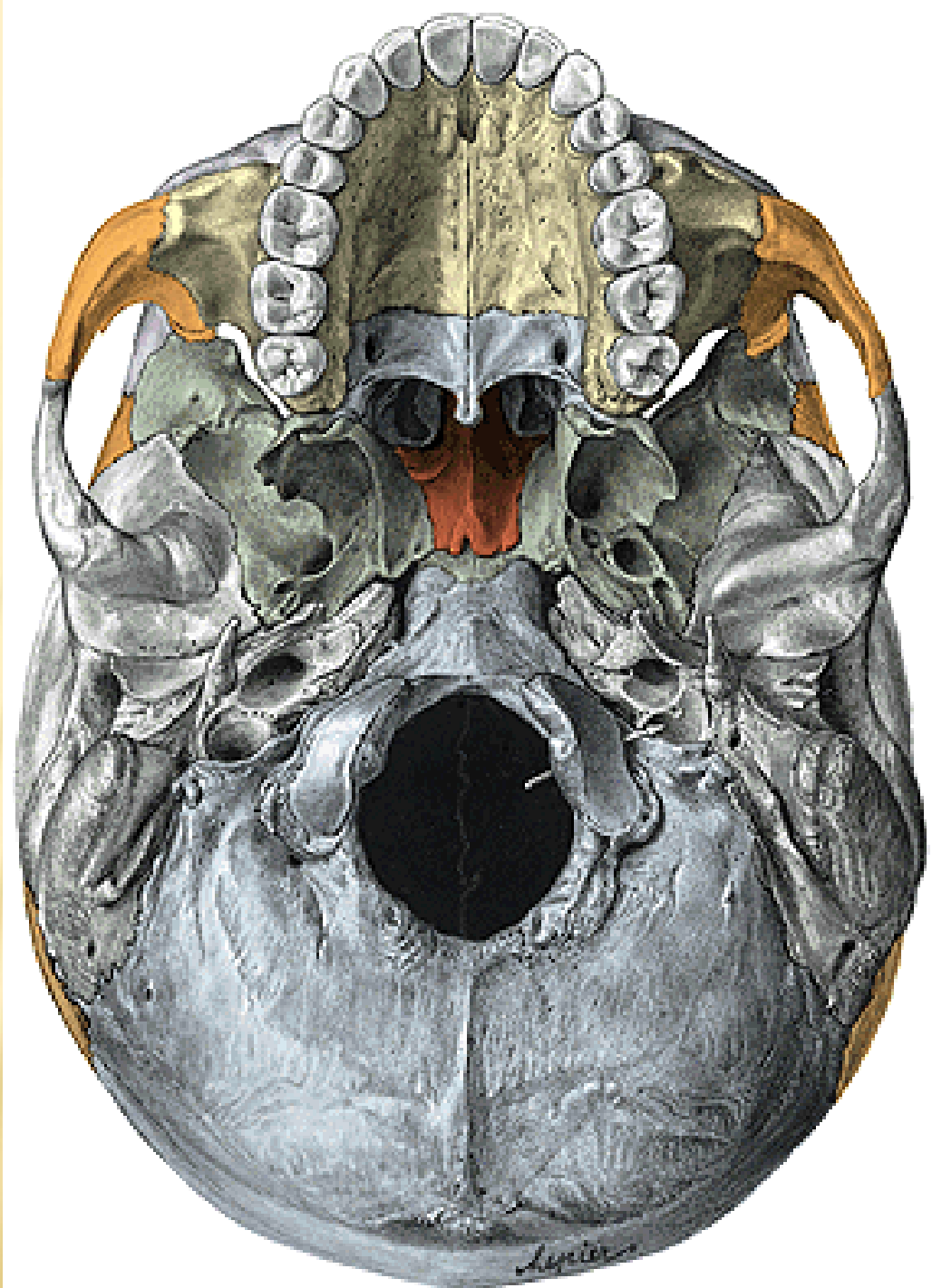

PALATUM

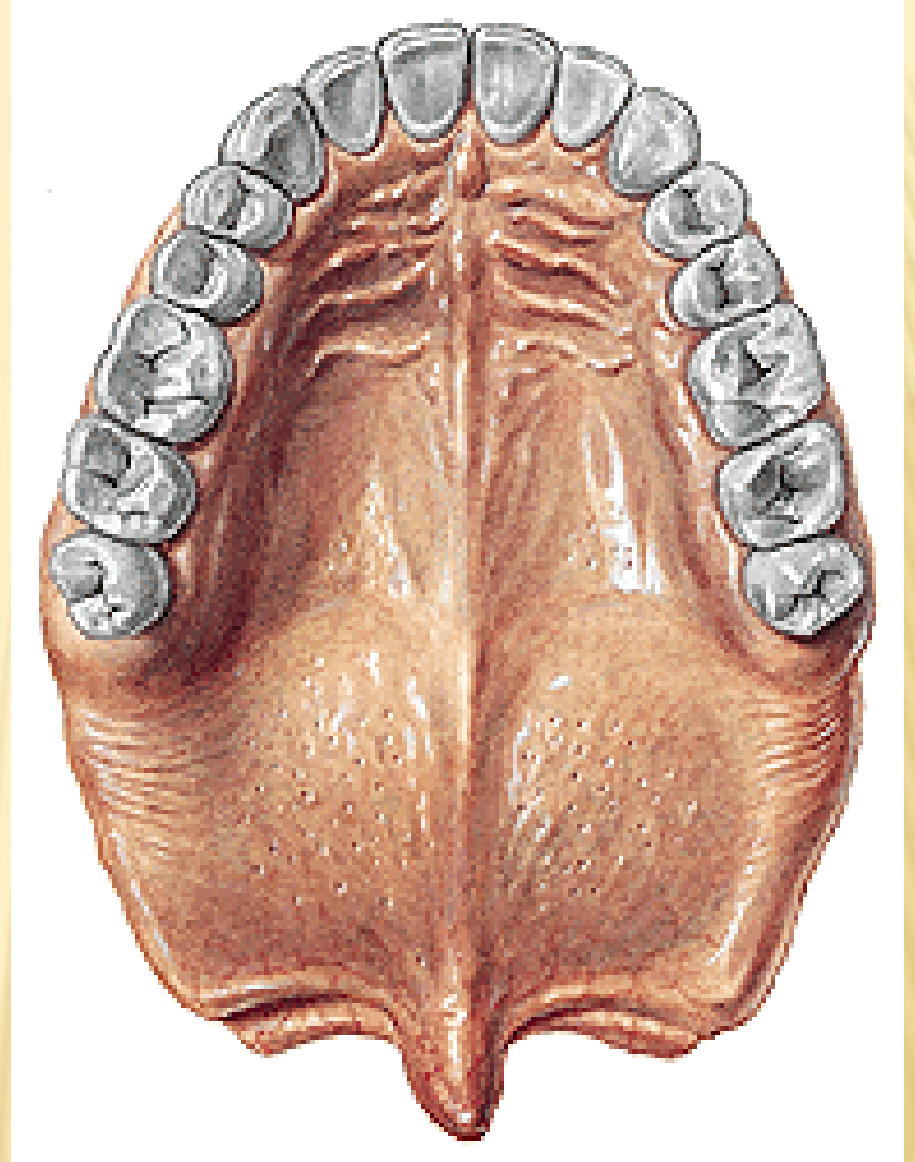
Glandulae palatinae
Vasa palatina majora
et minora
Nn. palatini minores
et majores



PALATUM DURUM

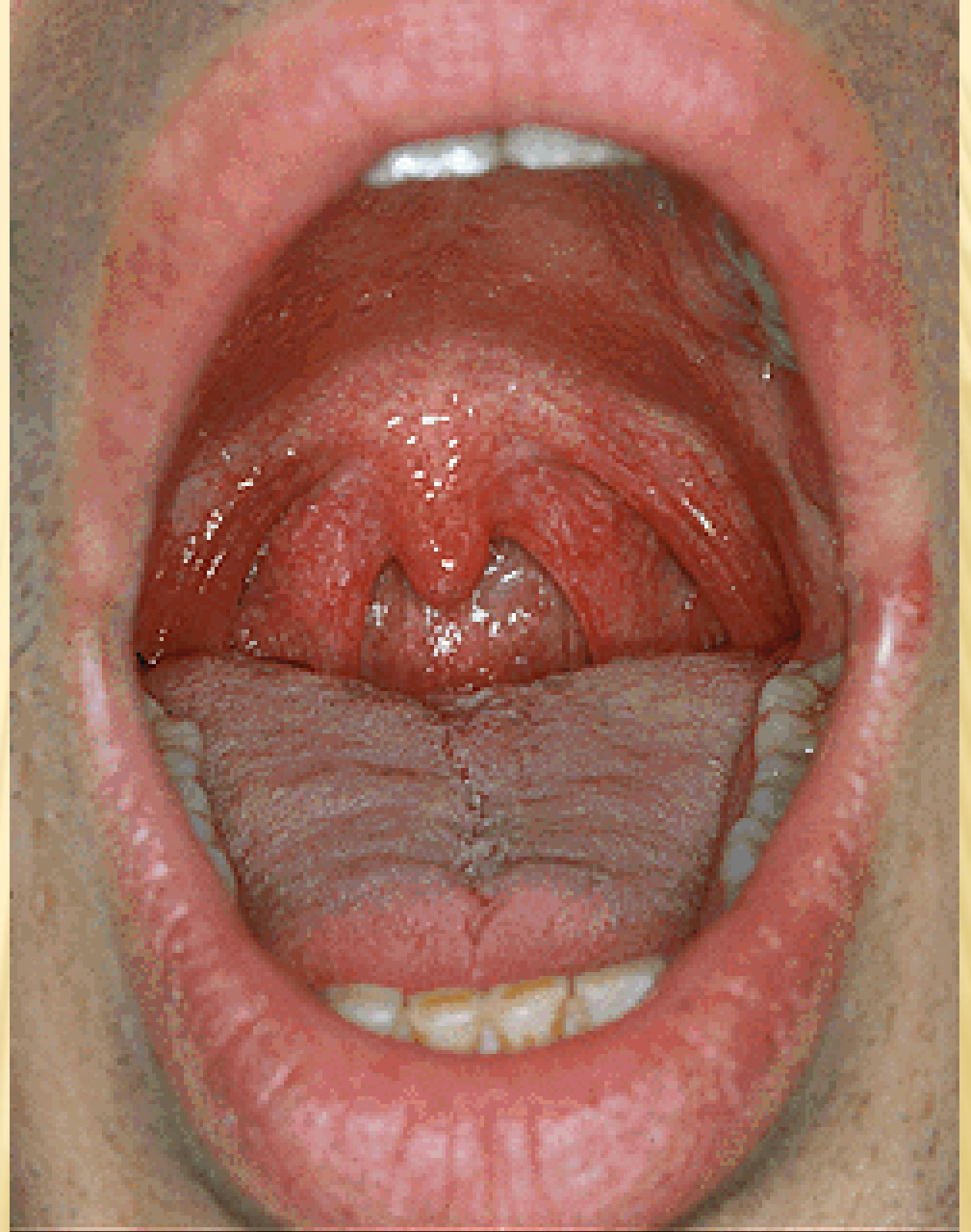

Raphe palati
Plicae palatinae transversae



PALATUM MOLLE (VELUM PALATINUM)

Uvula
Arcus palatoglossus
Arcus palatopharyngeus
Isthmus faucium



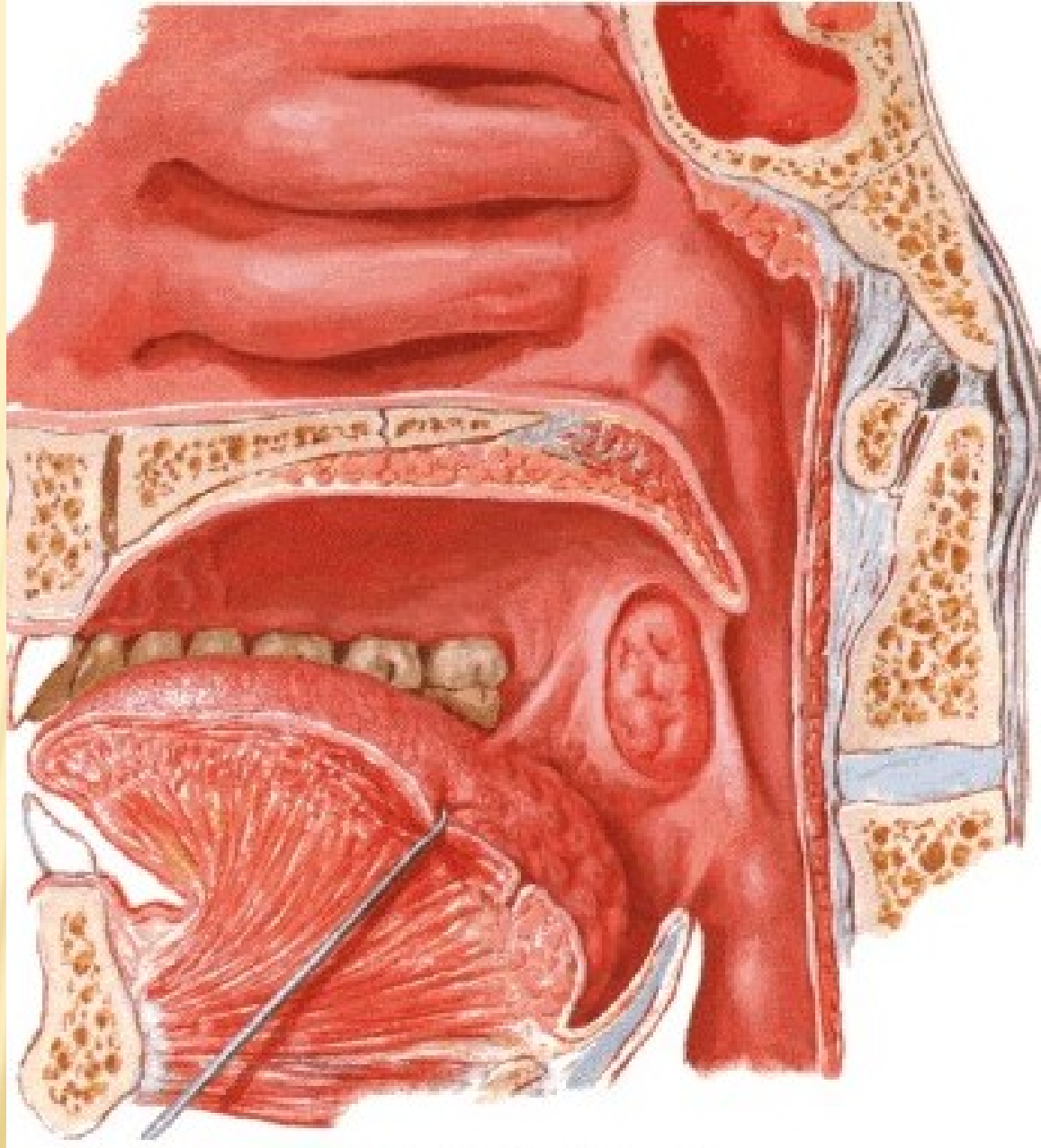
TONSILLA PALATINA

Sinus tonsillaris

Capsula tonsillaris

Fossulae tonsillares

Tonsillar pegs

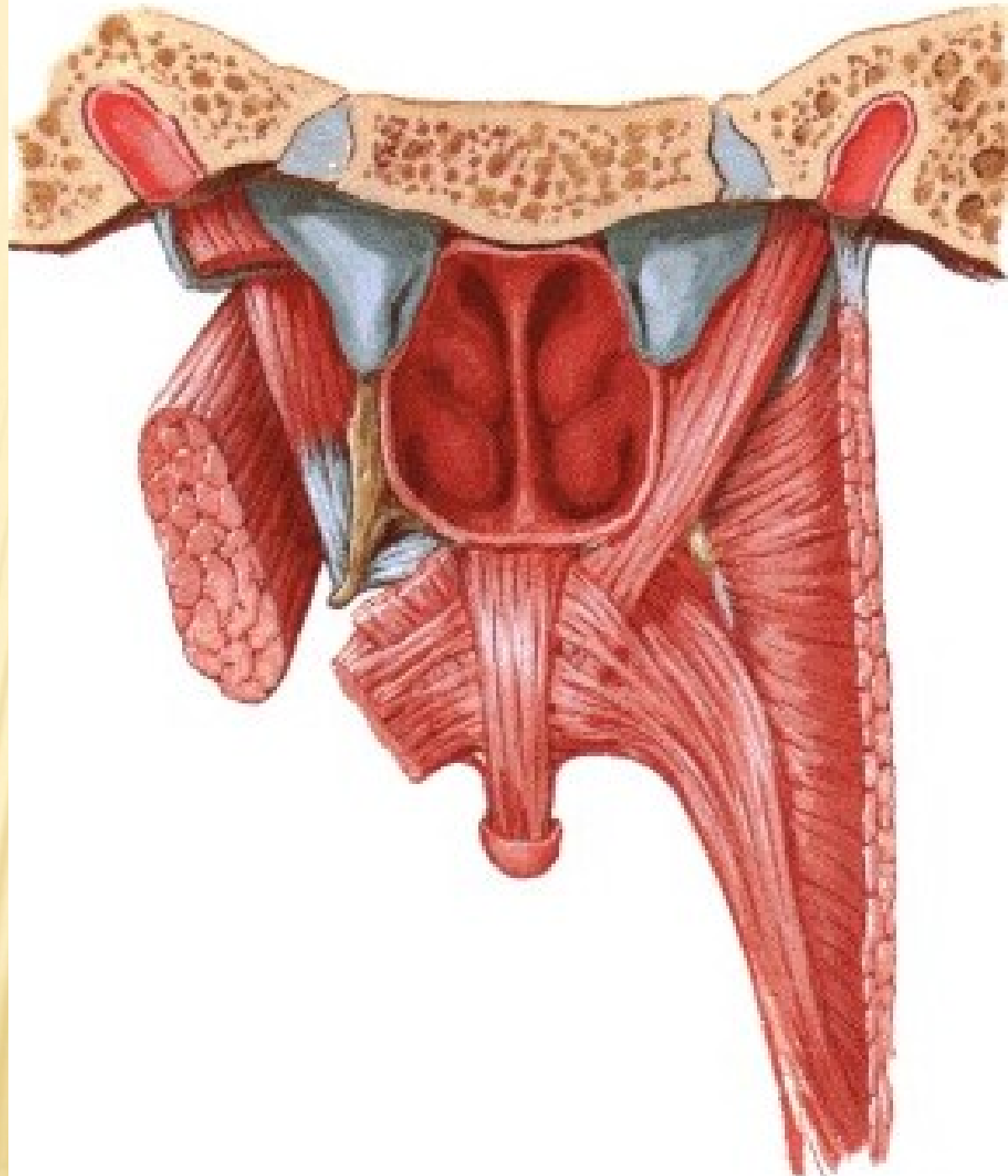


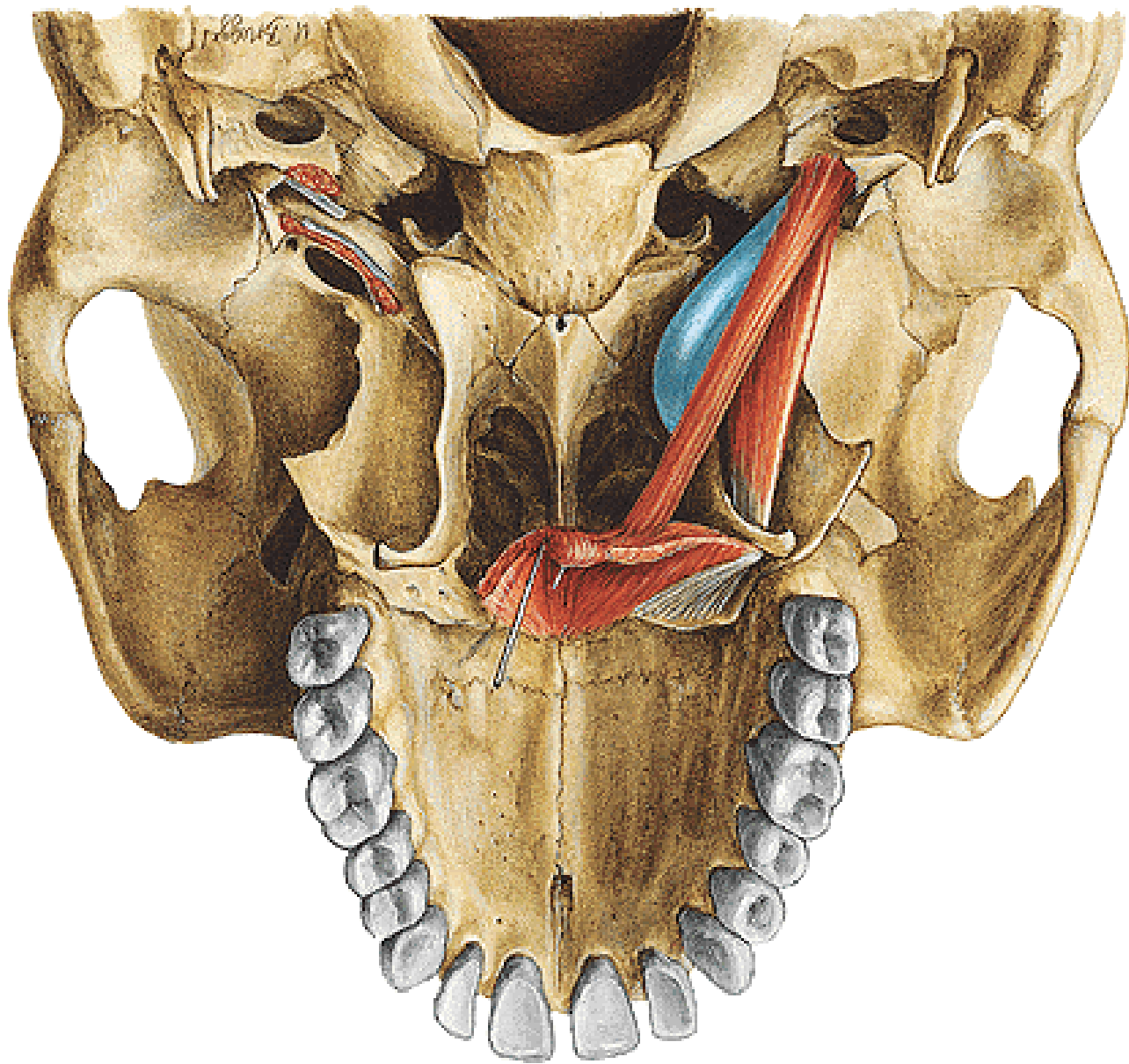
M. levator veli palatini
M. tensor veli palatini
M. uvulae
M. palatopharyngeus
M. palatoglossus

Aponeurosis palatina

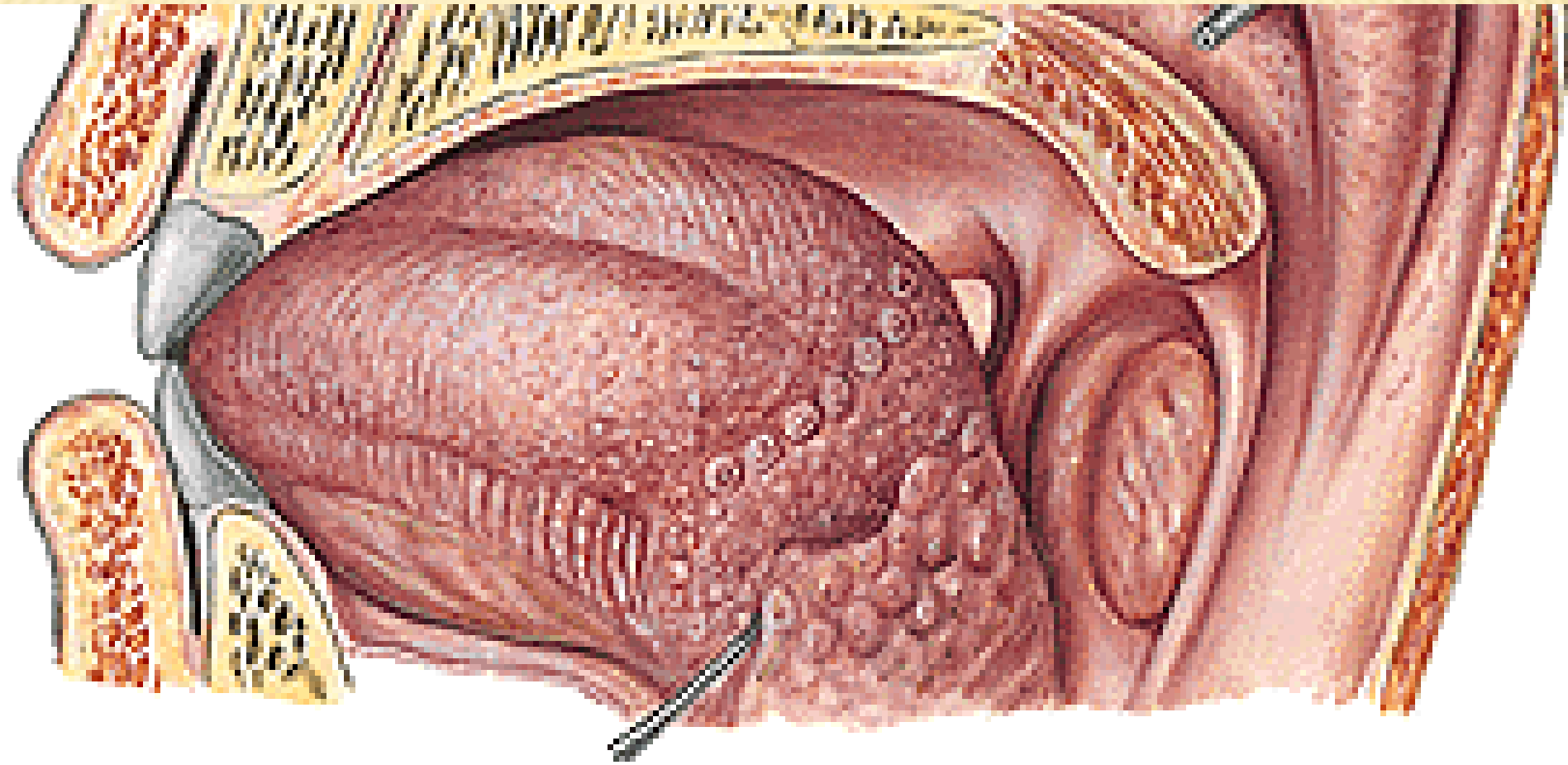
Plexus pharyngeus
– CN IX, X

Tensor – CN V





LINGUA – APEX, CORPUS, RADIX



DORSUM LINGUAE

Sulcus terminalis

Sulcus medianus

Foramen caecum

Margines linguae

Papillae filiformes

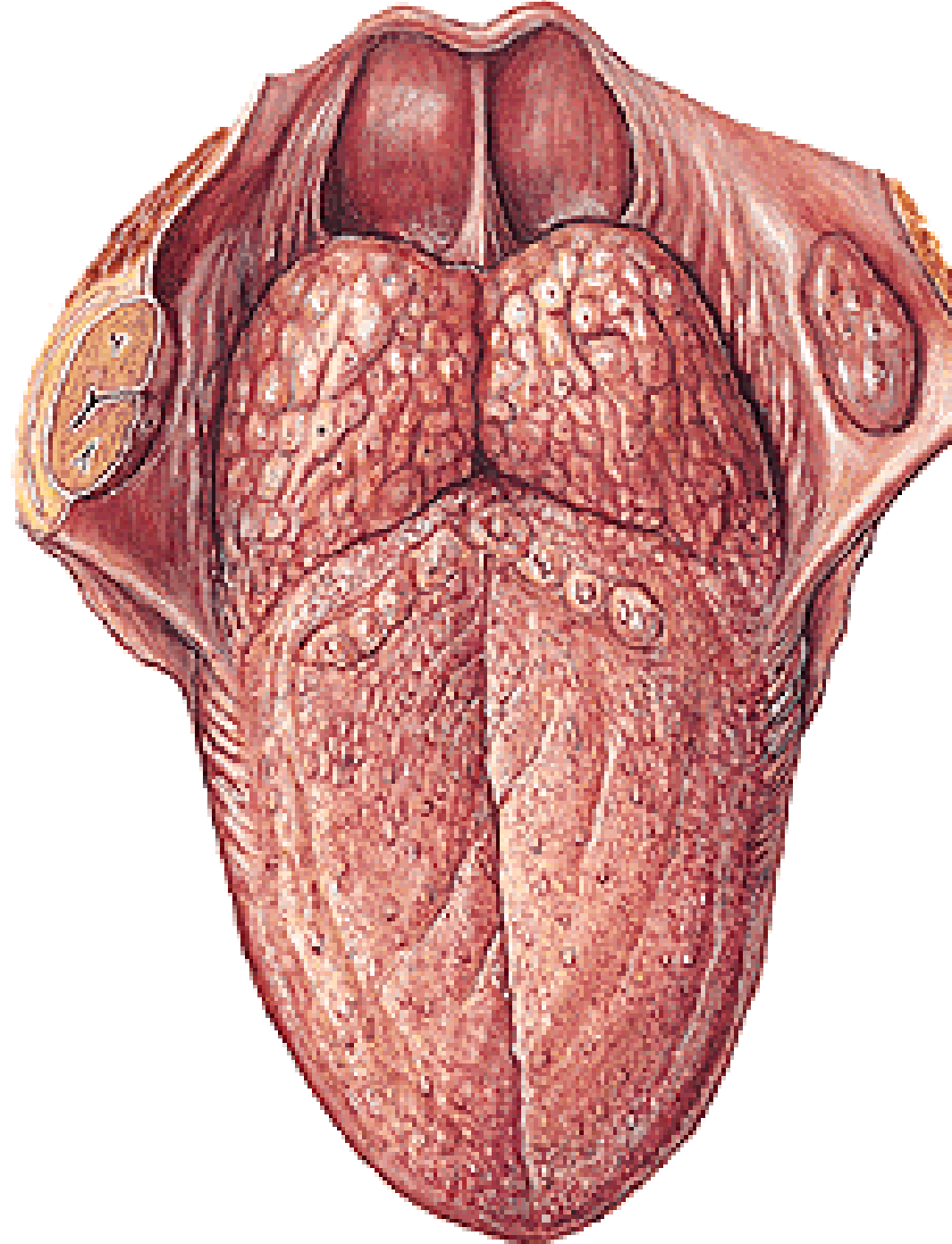
Papillae fungiformes

Papillae foliatae

Papillae vallatae

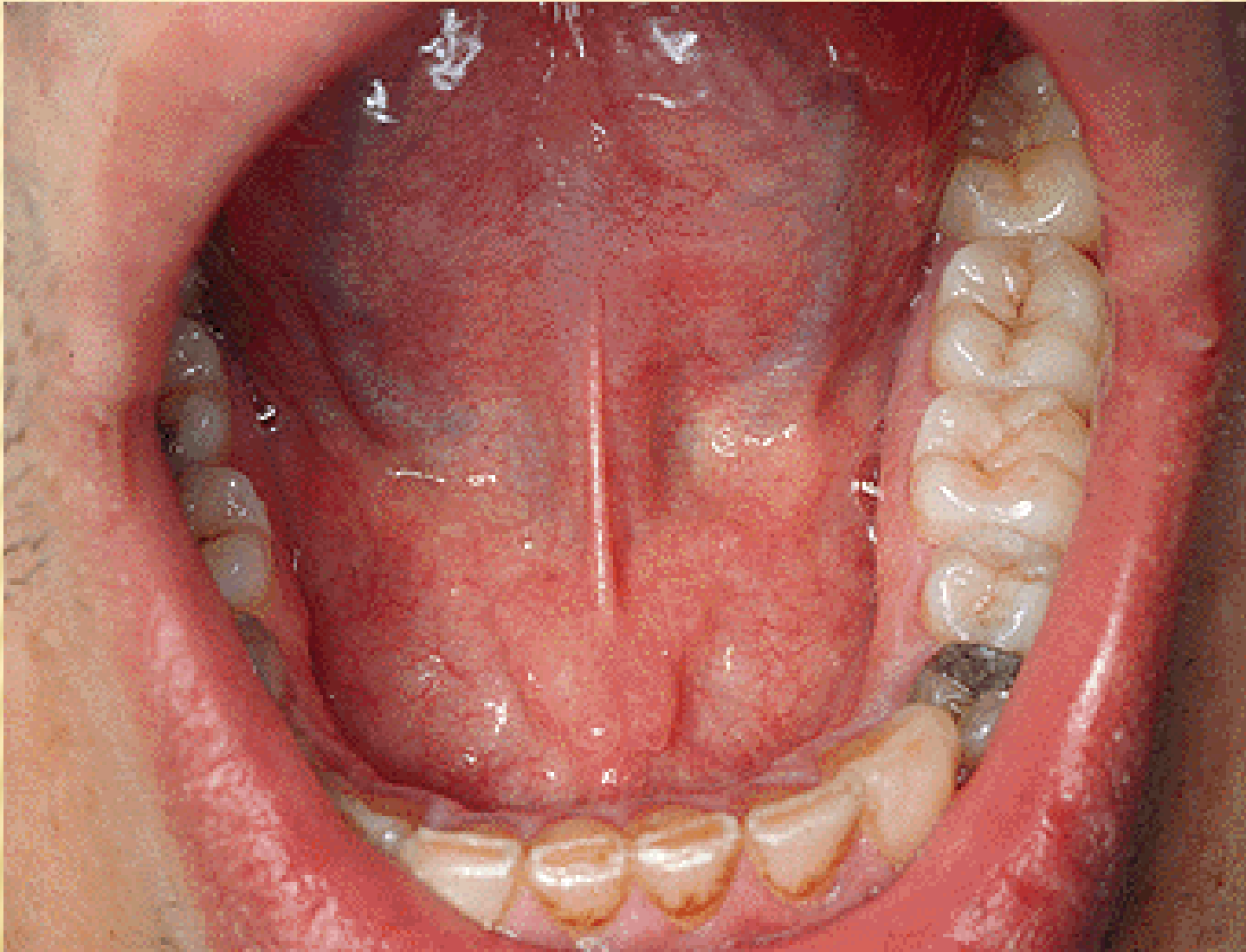Caliculi gustatorii

Tonsilla lingualis



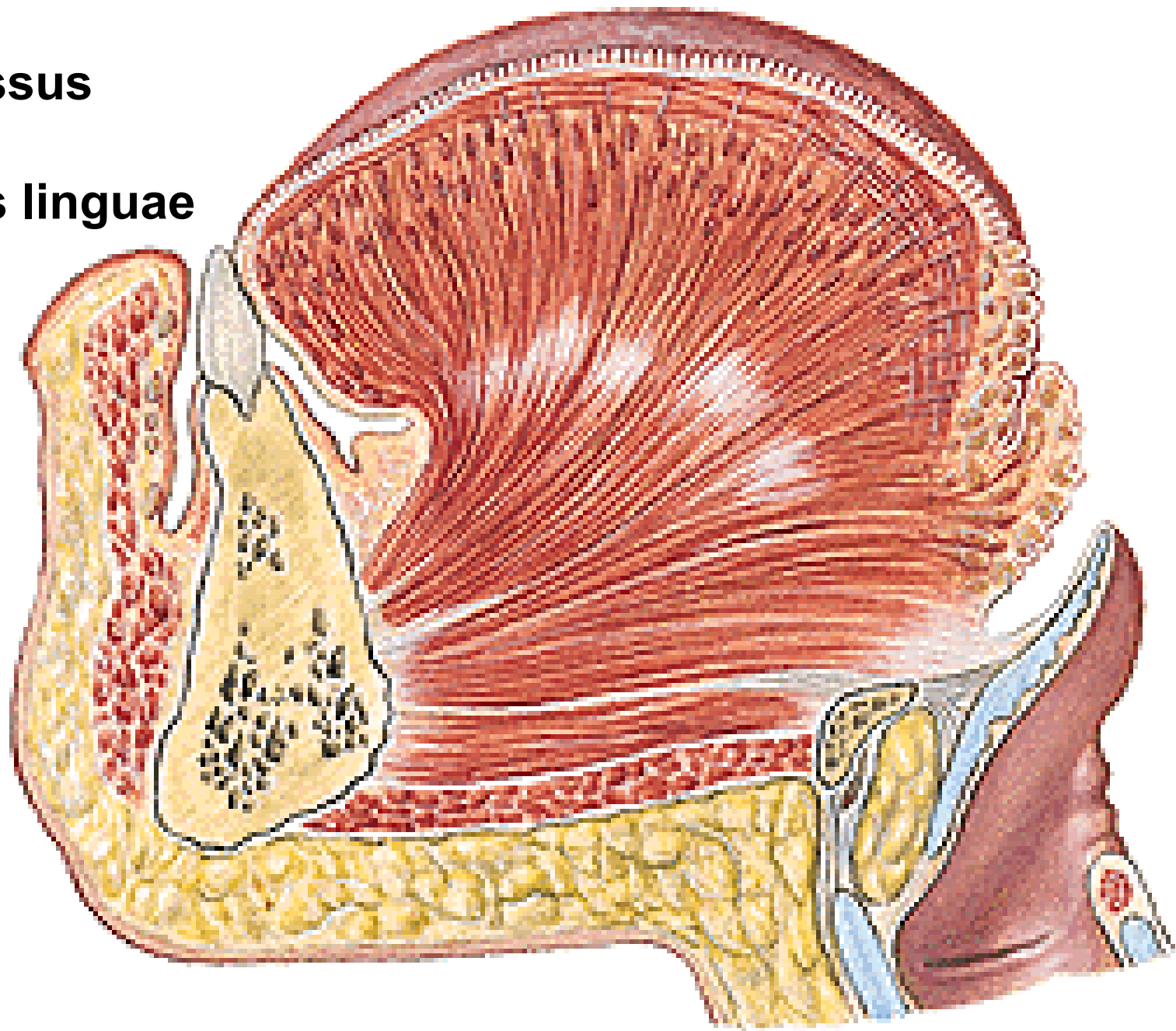
Facies inferior linguae

**Frenulum linguae
Plica sublingualis**

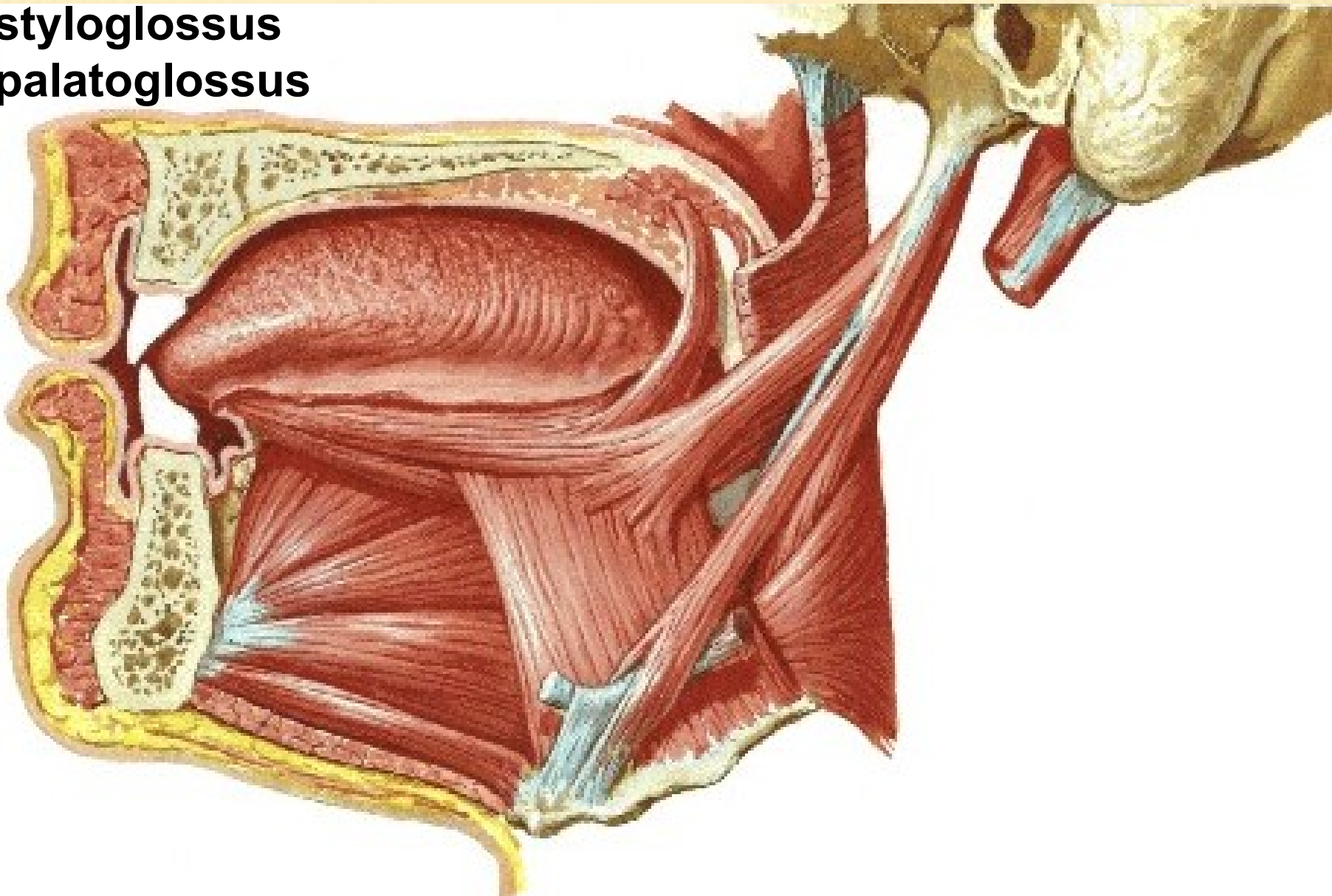


M. genioglossus

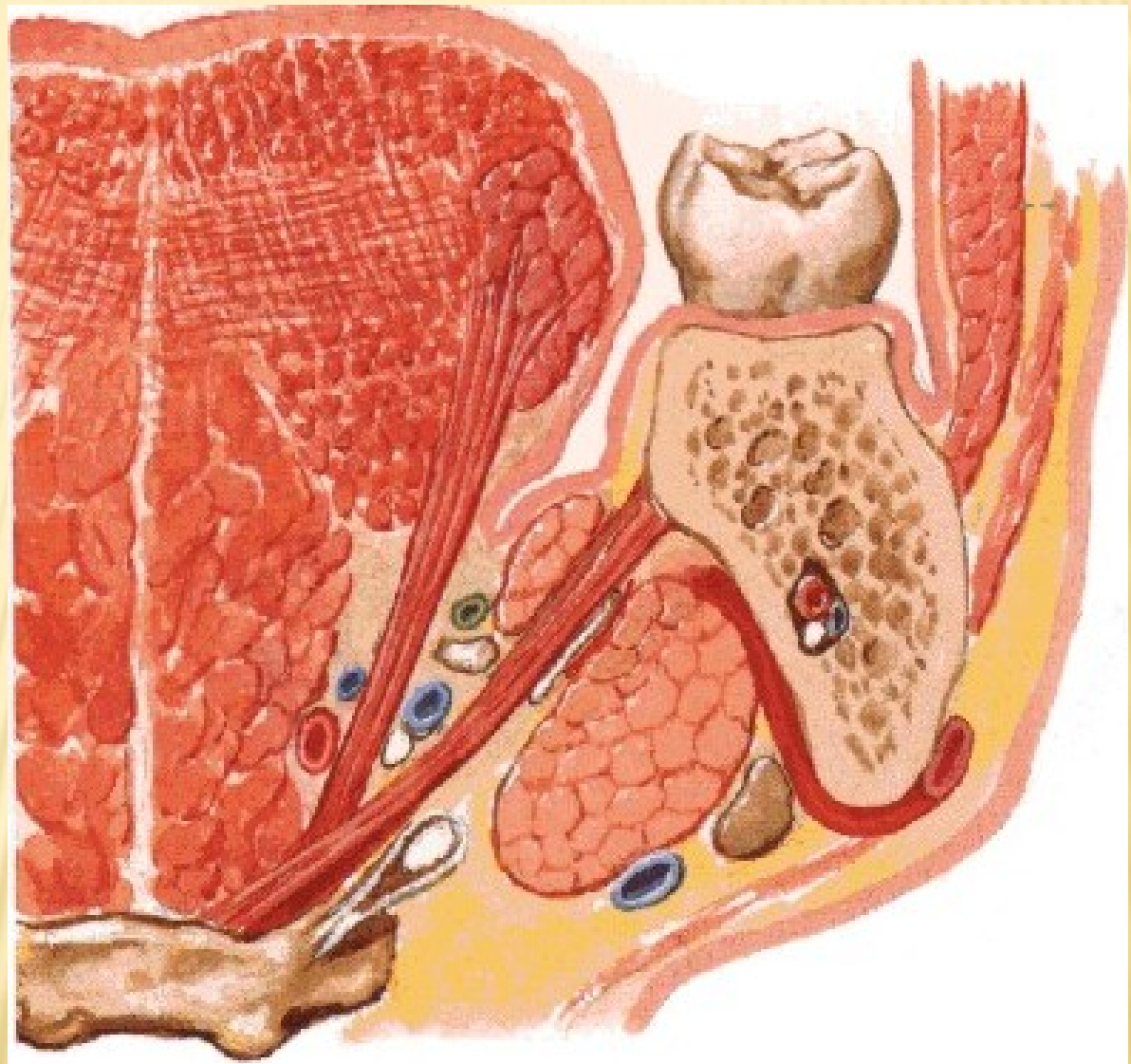
Aponeurosis linguae



M. hyoglossus
M. styloglossus
M. palatoglossus

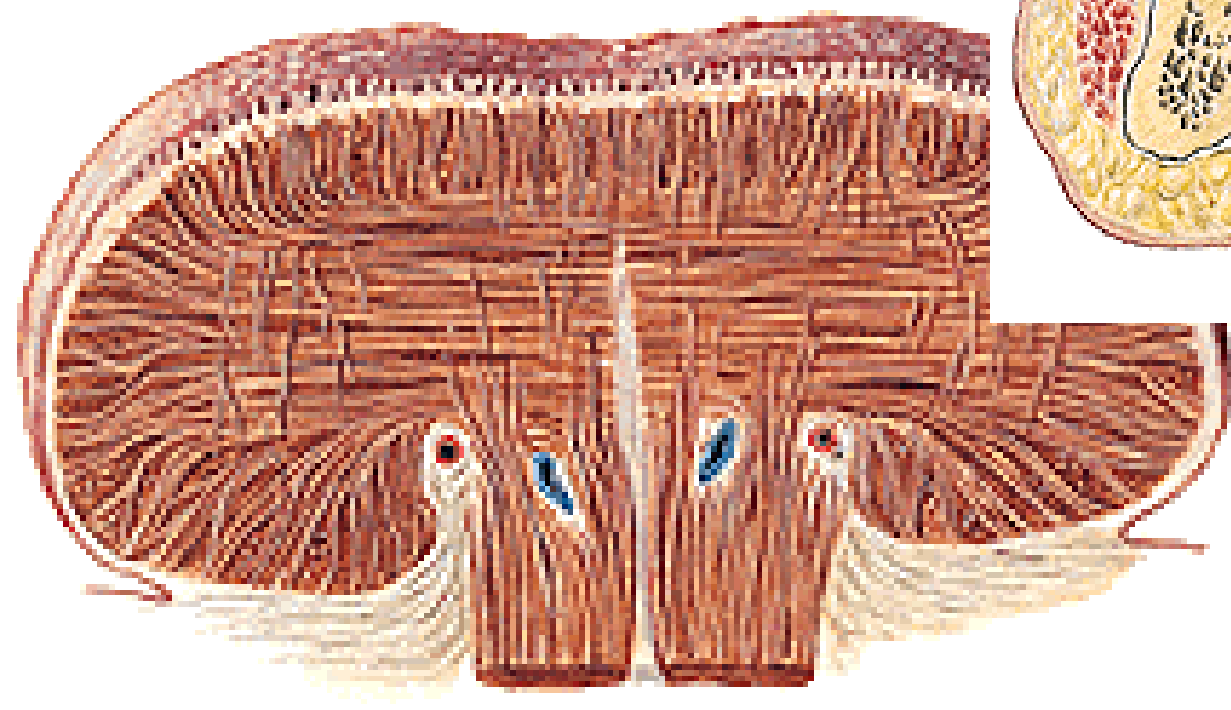
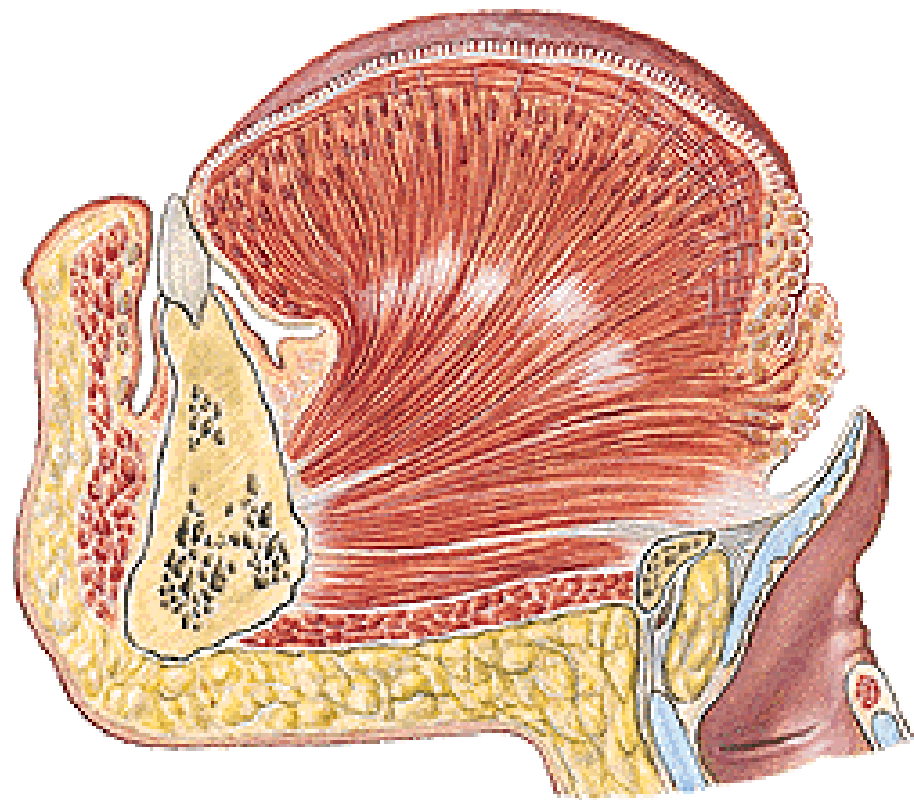


Canalis paralingualis – a. et v. lingualis



Septum linguae

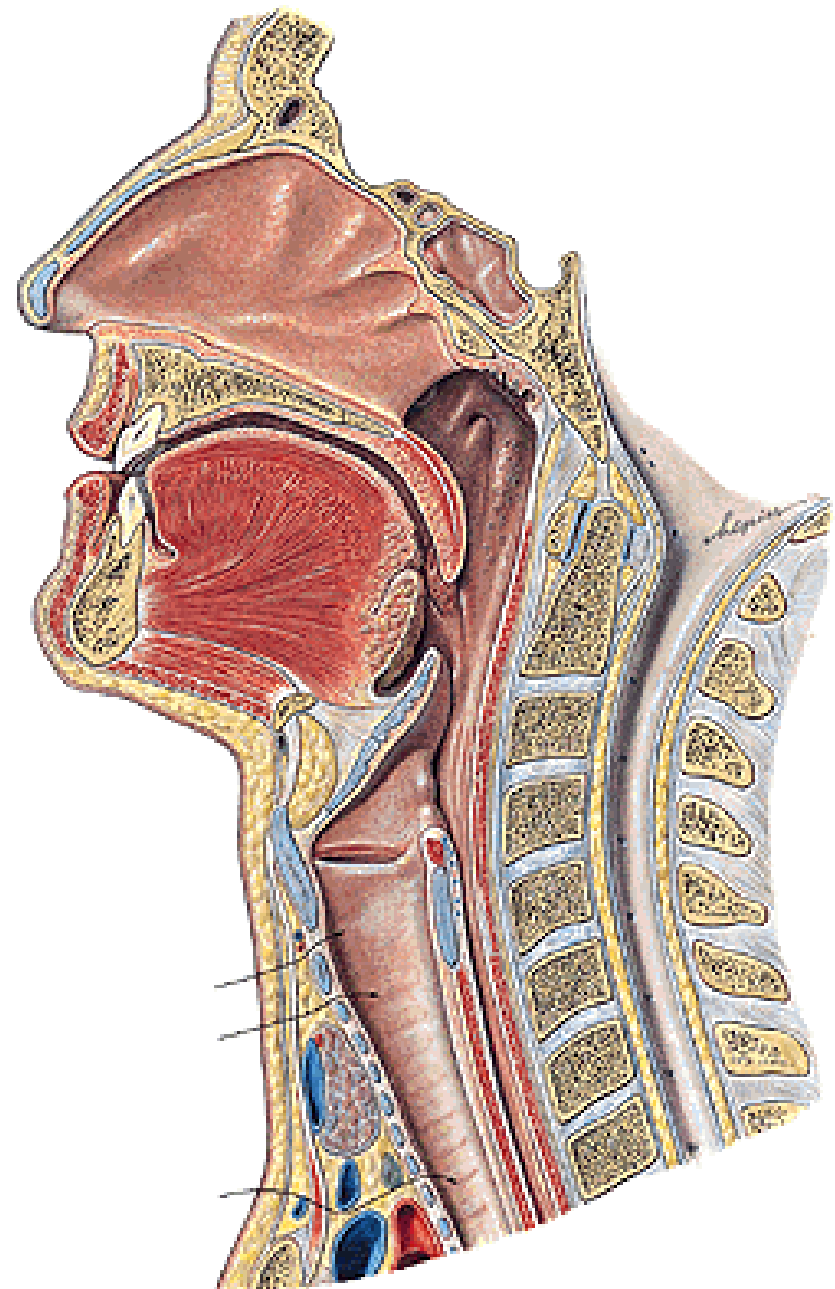
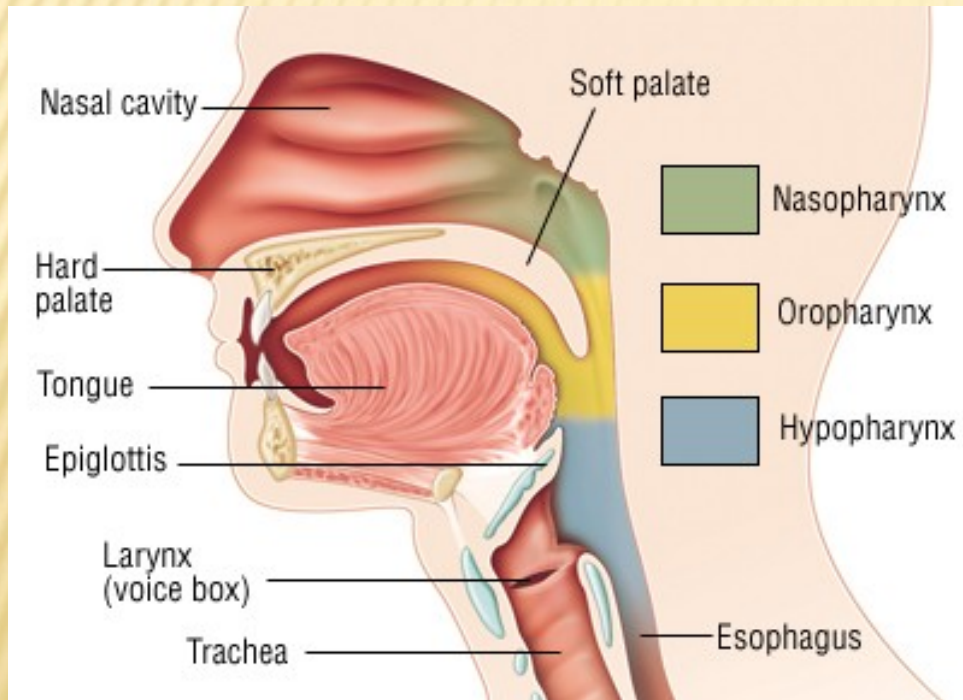
- M. longitudinalis sup.**
- M. longitudinalis inf.**
- M. transversus linguae**
- M. verticalis linguae**



CN XII

PHARYNX

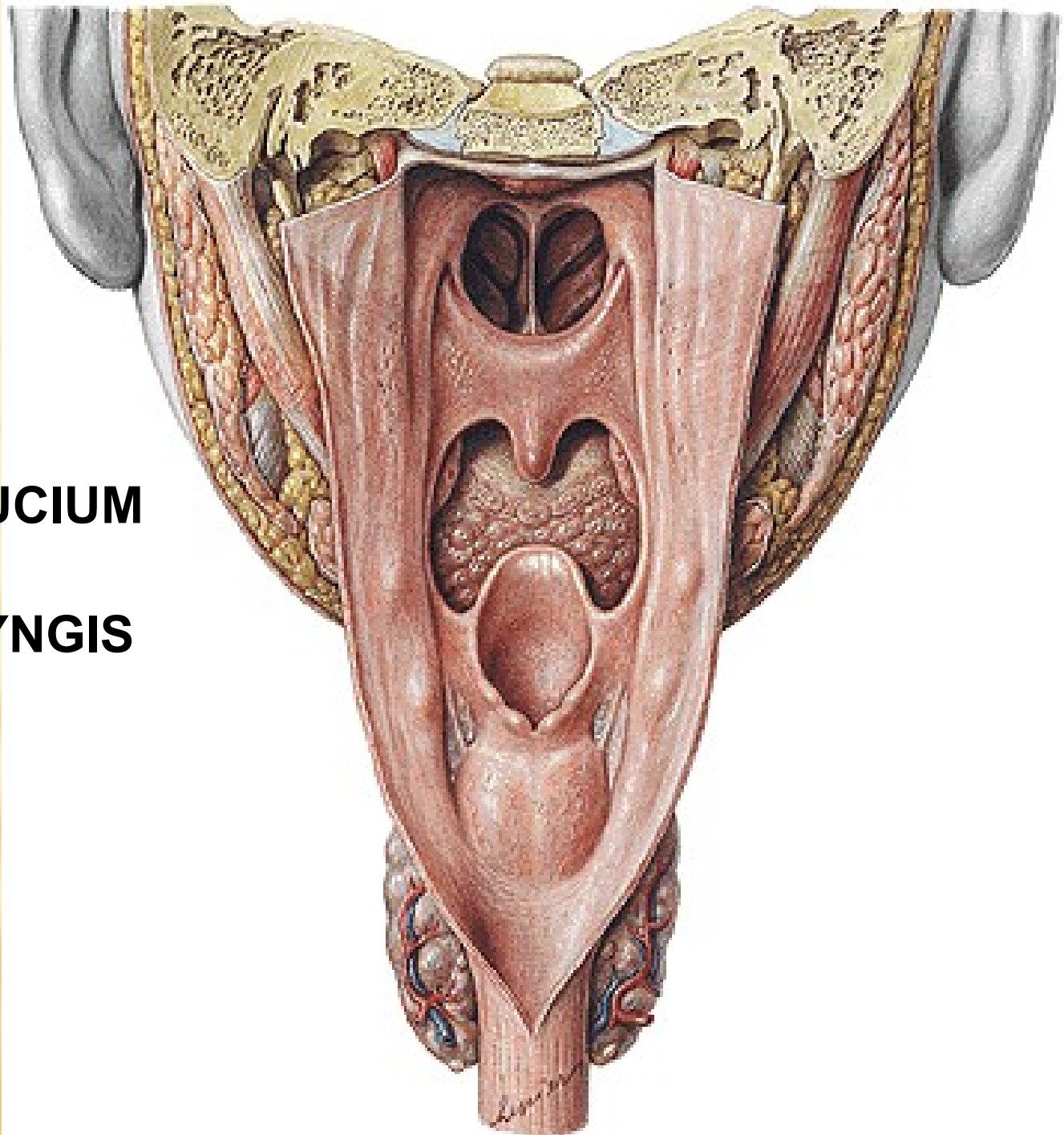
Fornix pharyngis
Cavitas pharyngis



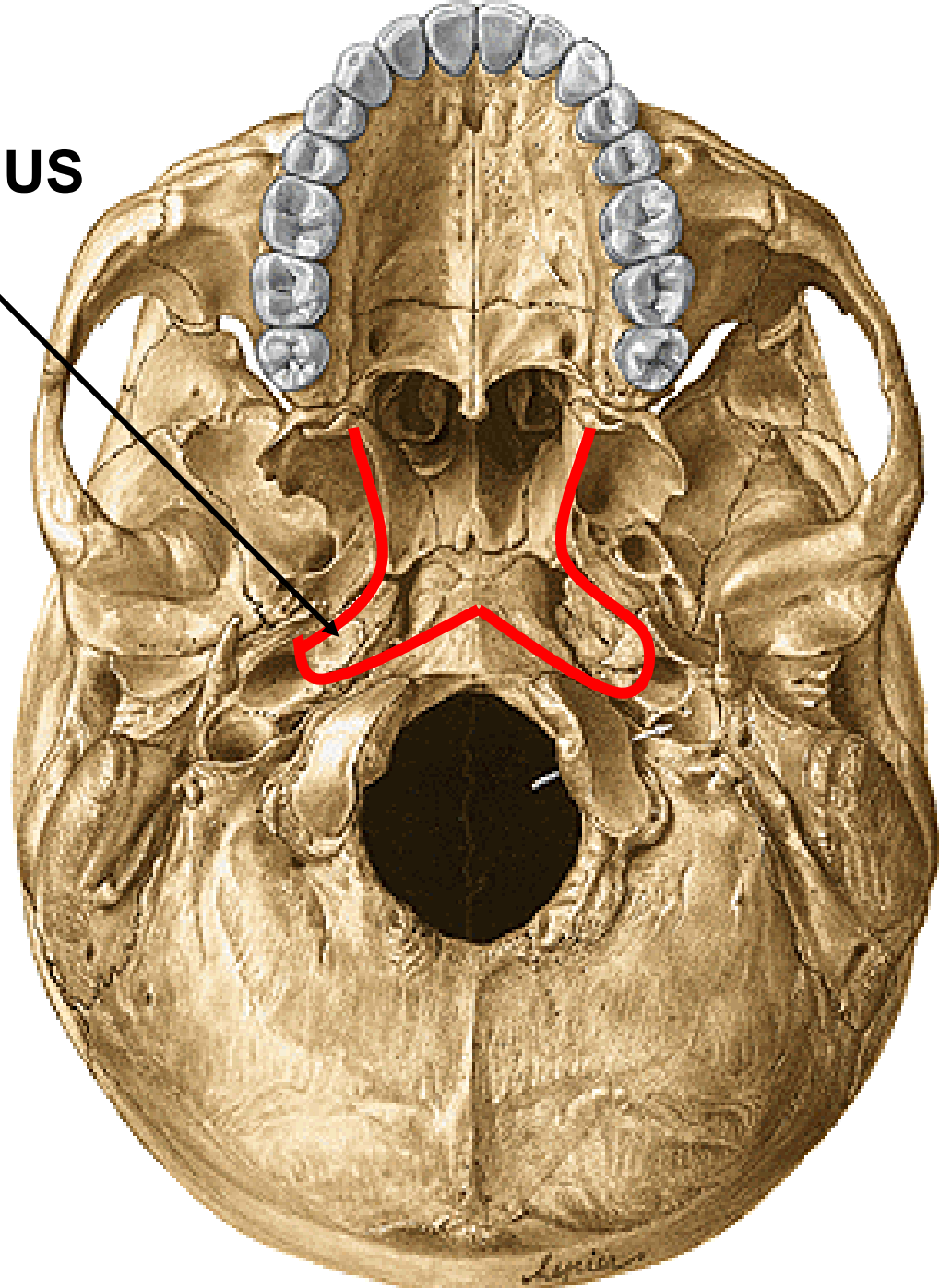
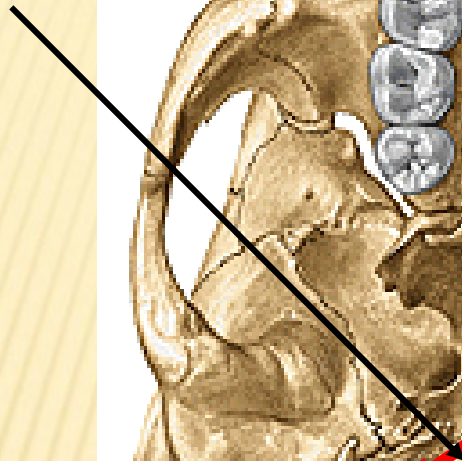
CHOANAE

ISTHMUS FAUCIUM

ADITUS LARYNGIS

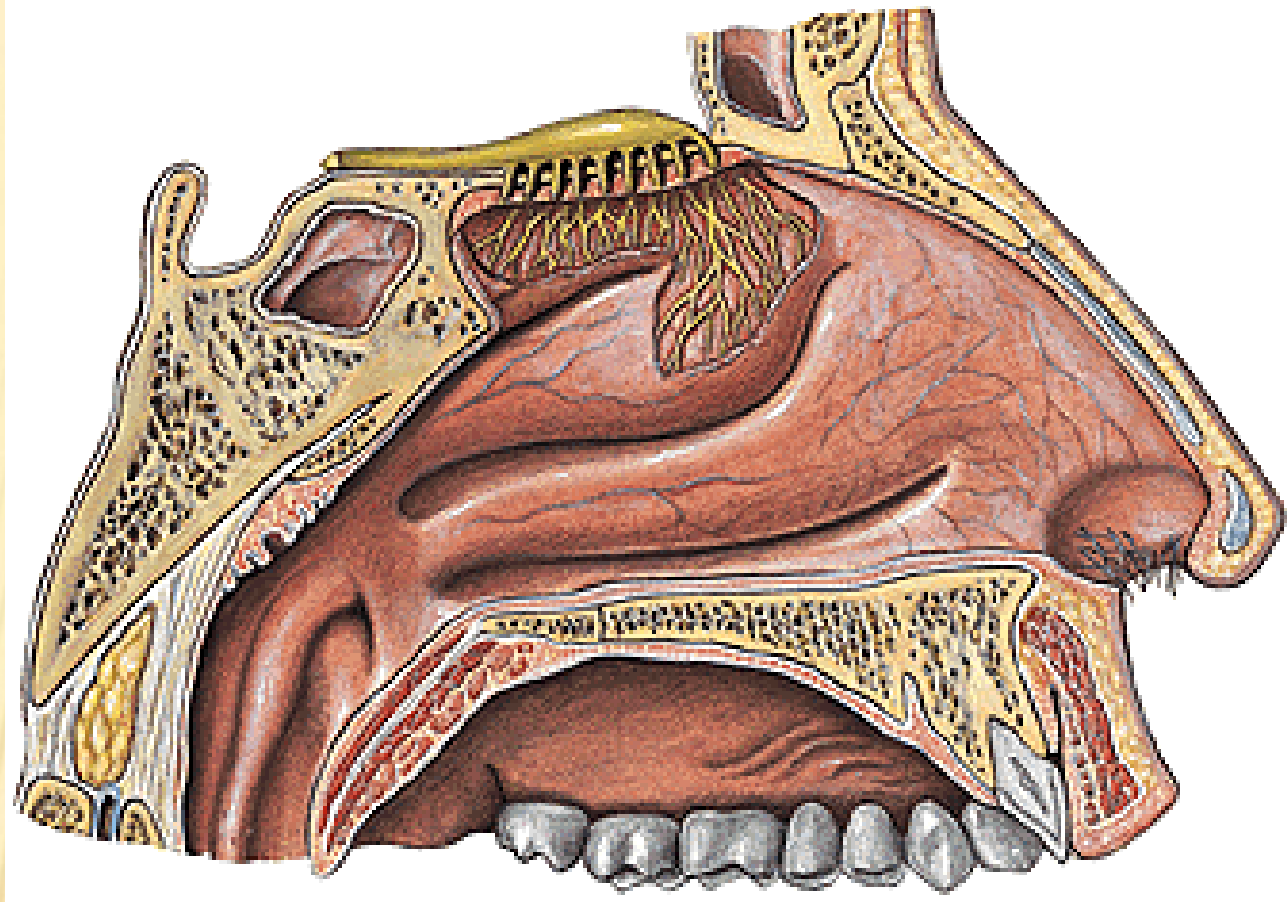


**RECESSUS
PHARYNGEUS**



NASOPHARYNX:

**TONSILLA
PHARYNGEA**



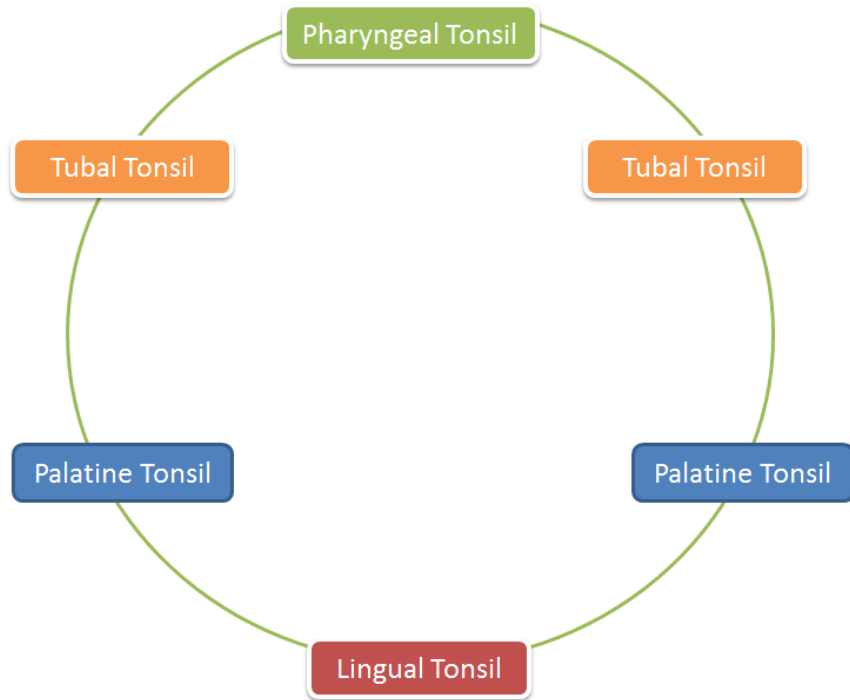
OSTIUM PHARYNGEUM TUBAE AUDITIVAE:

TORUS TUBARIUS

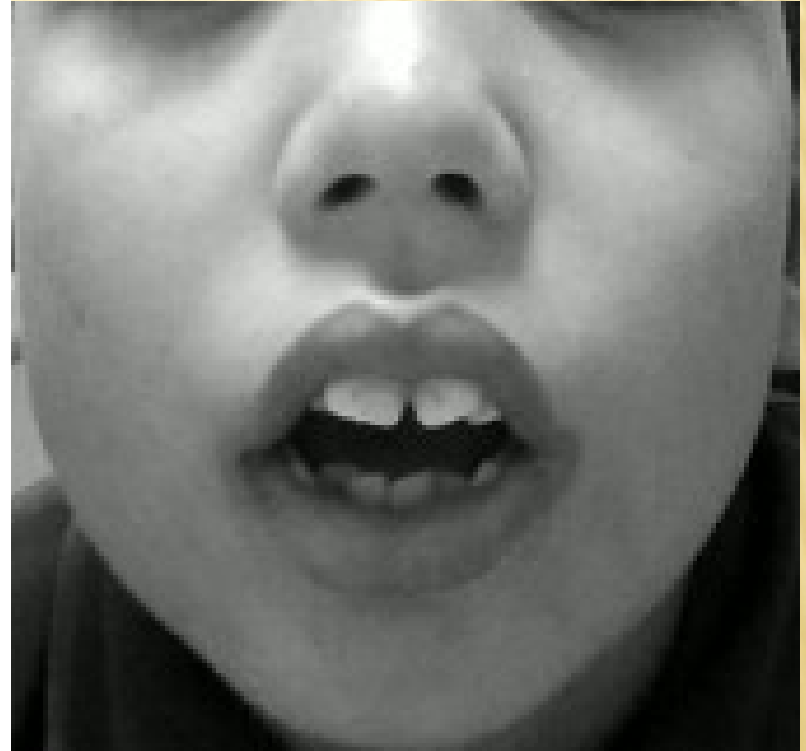TORUS LEVATORIUS

TONSILLA TUBARIA

Waldeyer lymphoepithelial ring

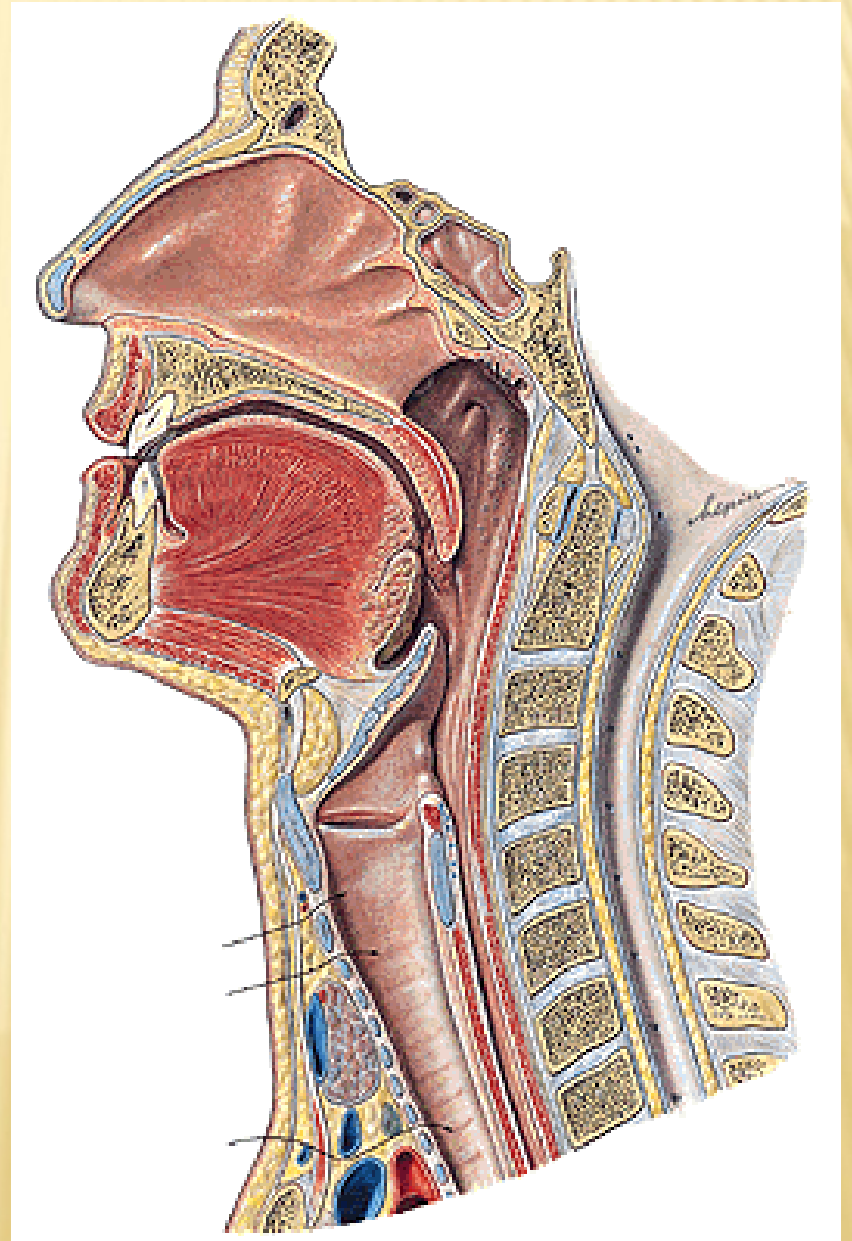
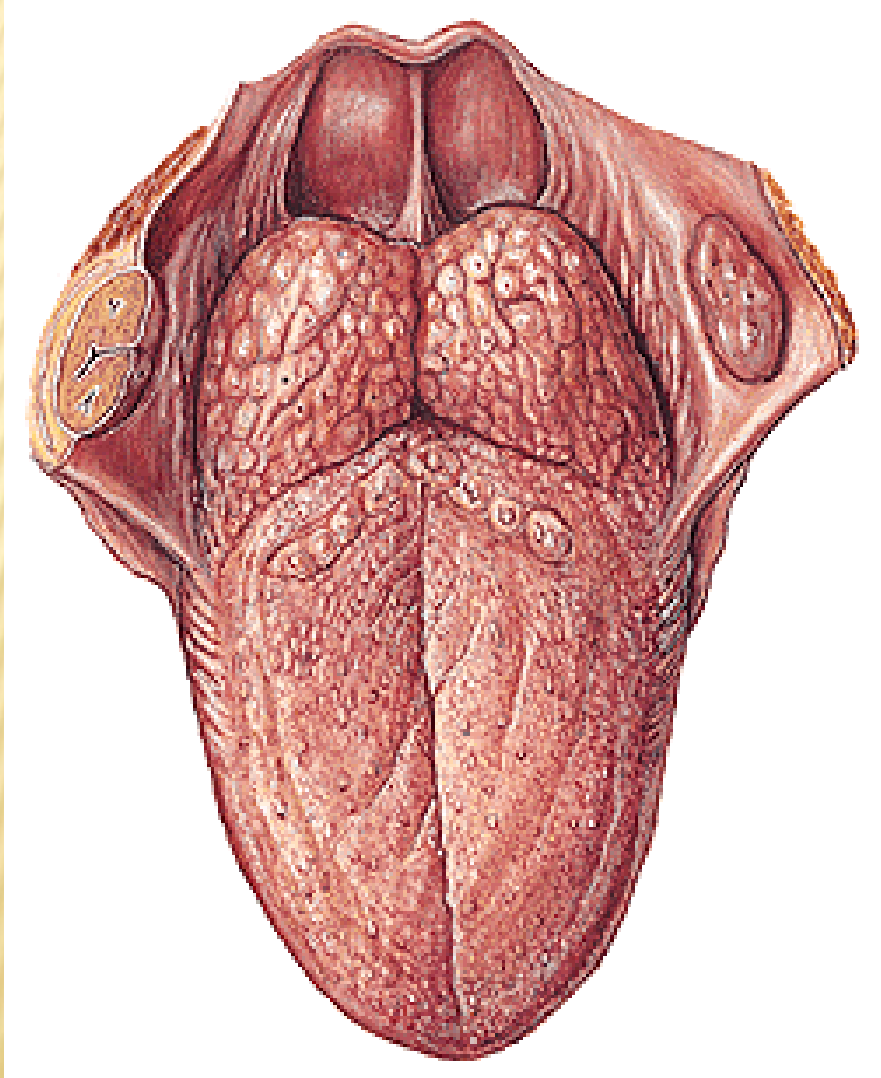


Adenoid facies



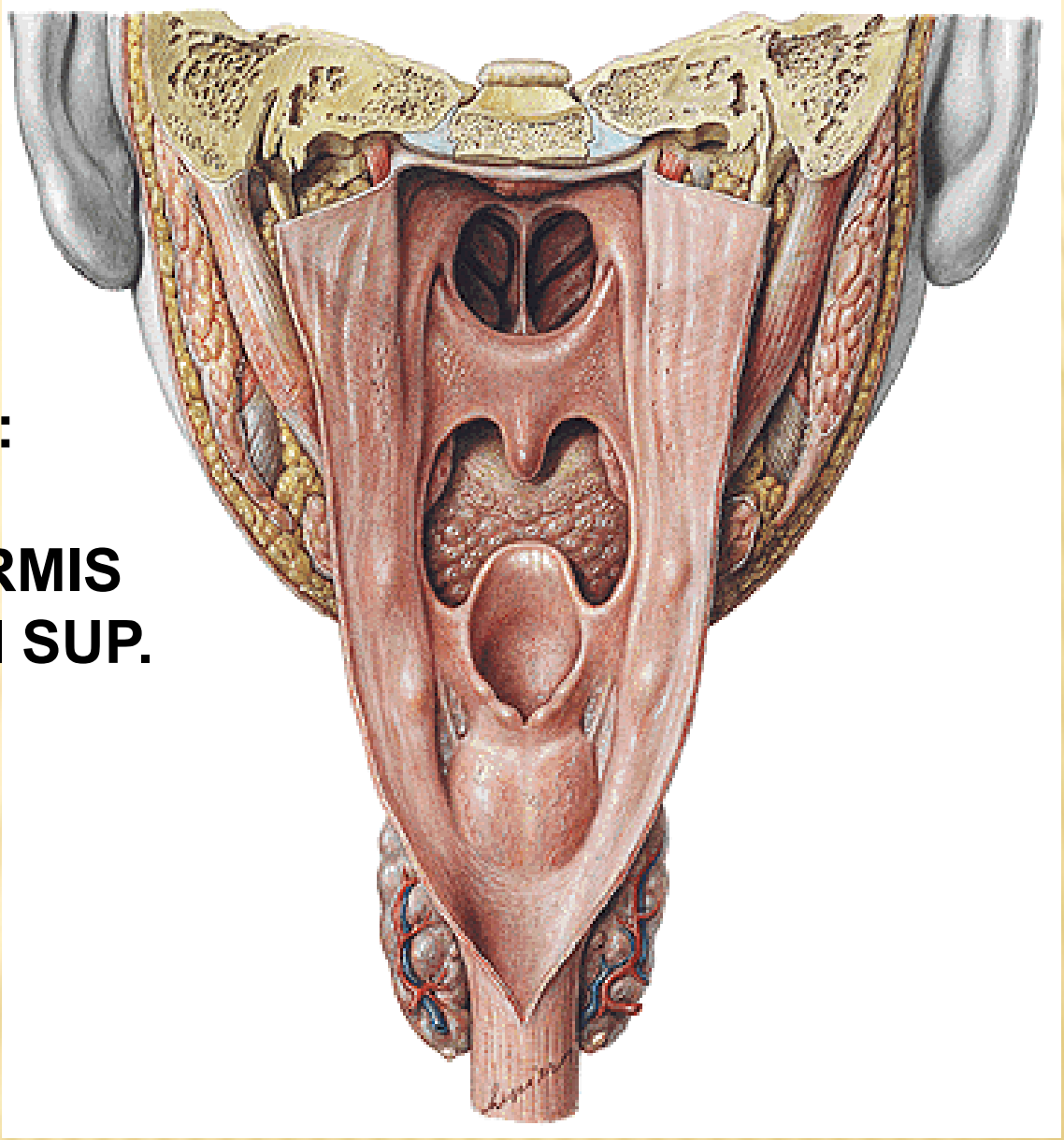
OROPHARYNX:

- Plica glossoepiglottica mediana et lateralis
- Valleculae epiglotticae



LARYNGOPHARYNX:

- RECESSUS PIRIFORMIS**
- PLICA N. LARYNGEI SUP.**

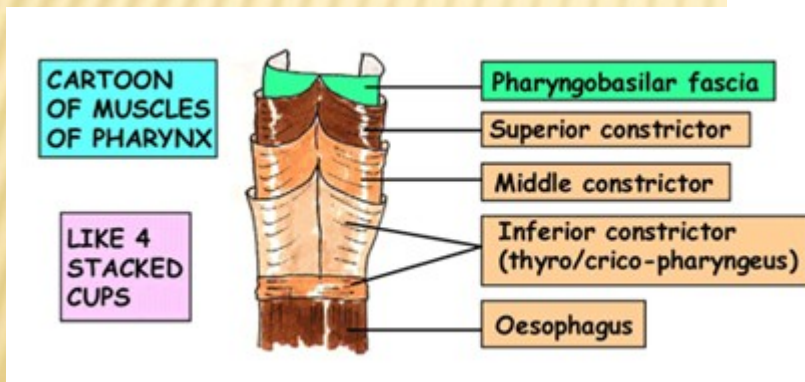
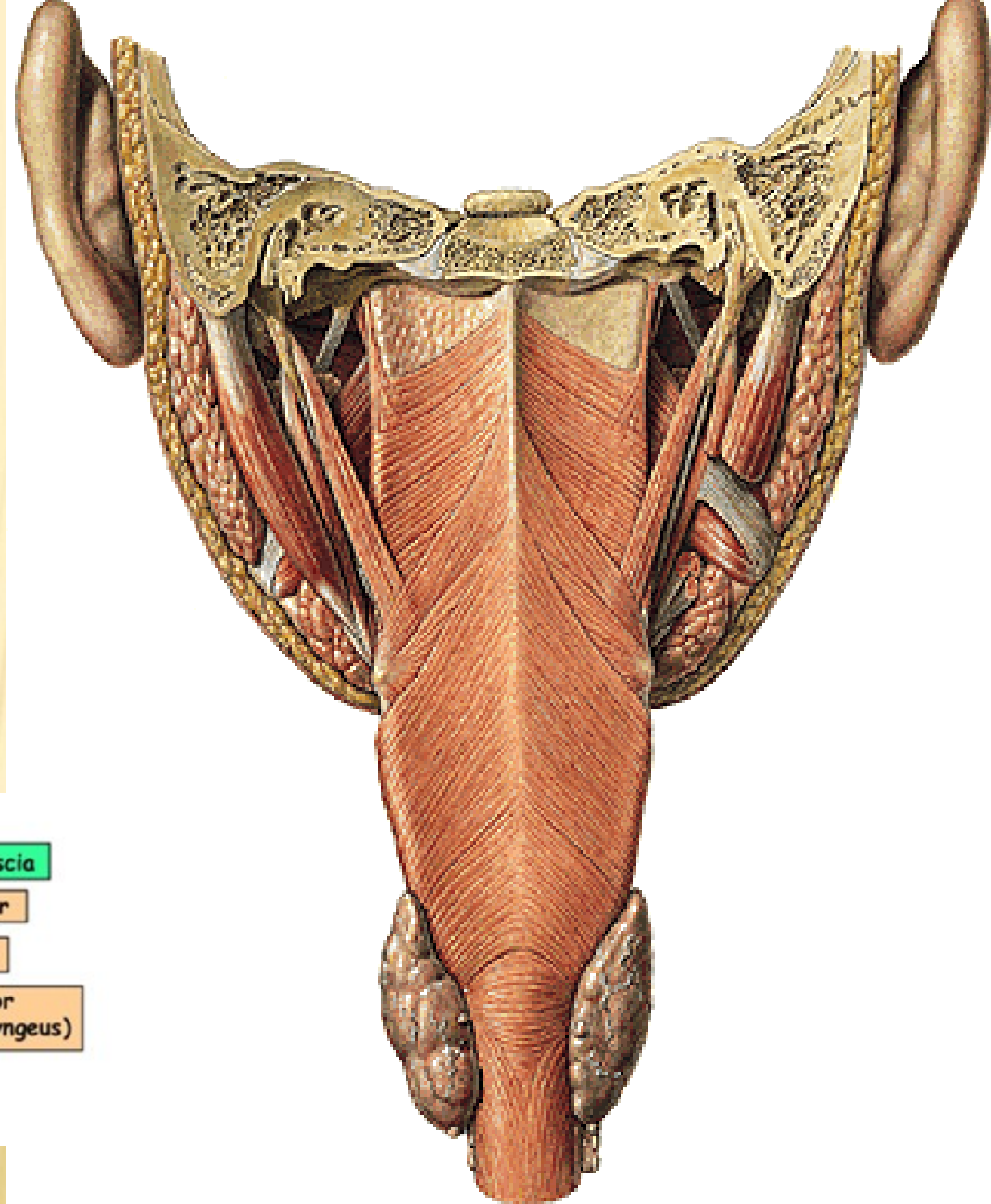


**M. CONSTRICTOR
PHARYNGIS SUP.**

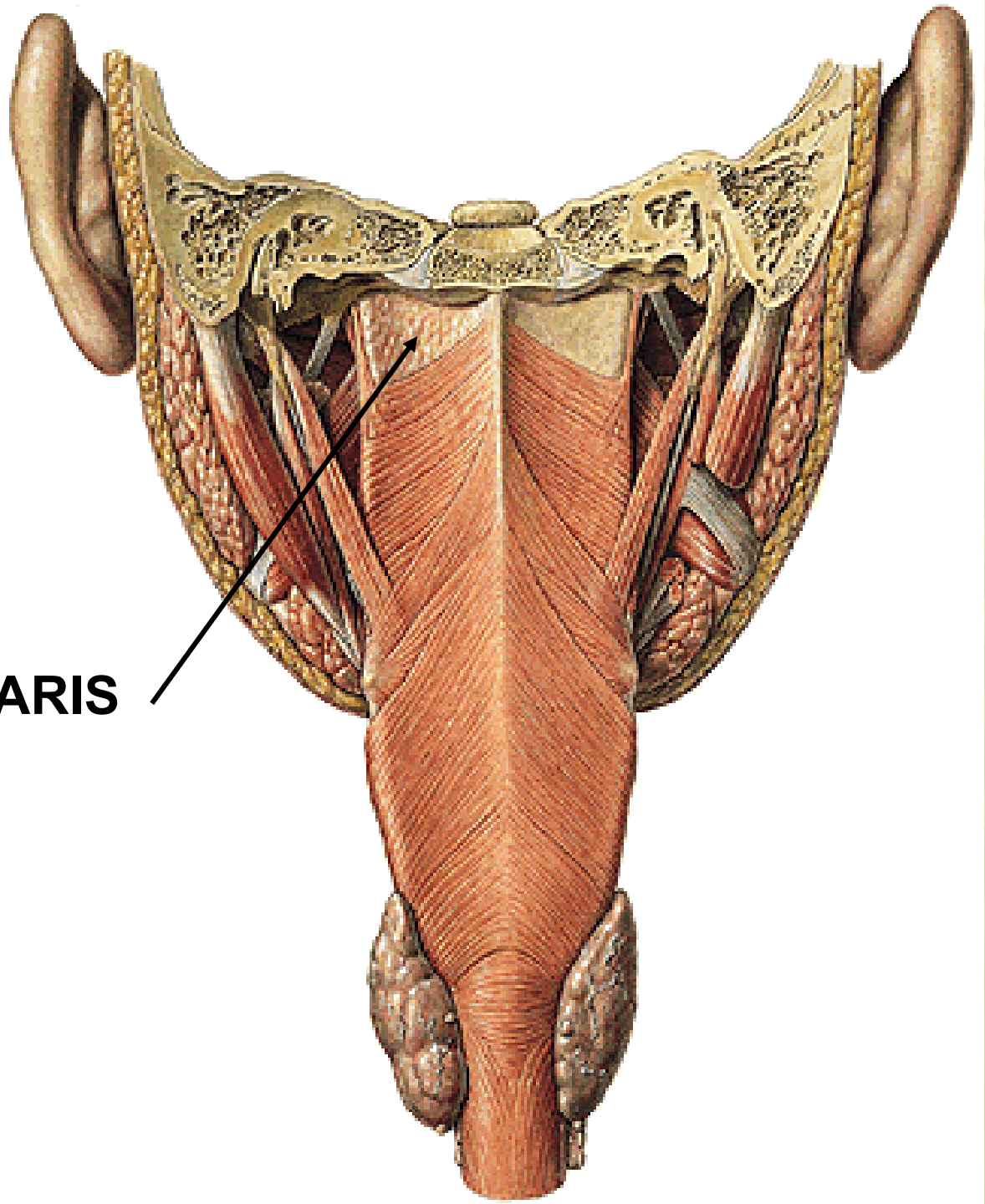
**M. CONSTRICTOR
PHARYNGIS MEDIUS**

**M. CONSTRICTOR
PHARYNGIS INF.**

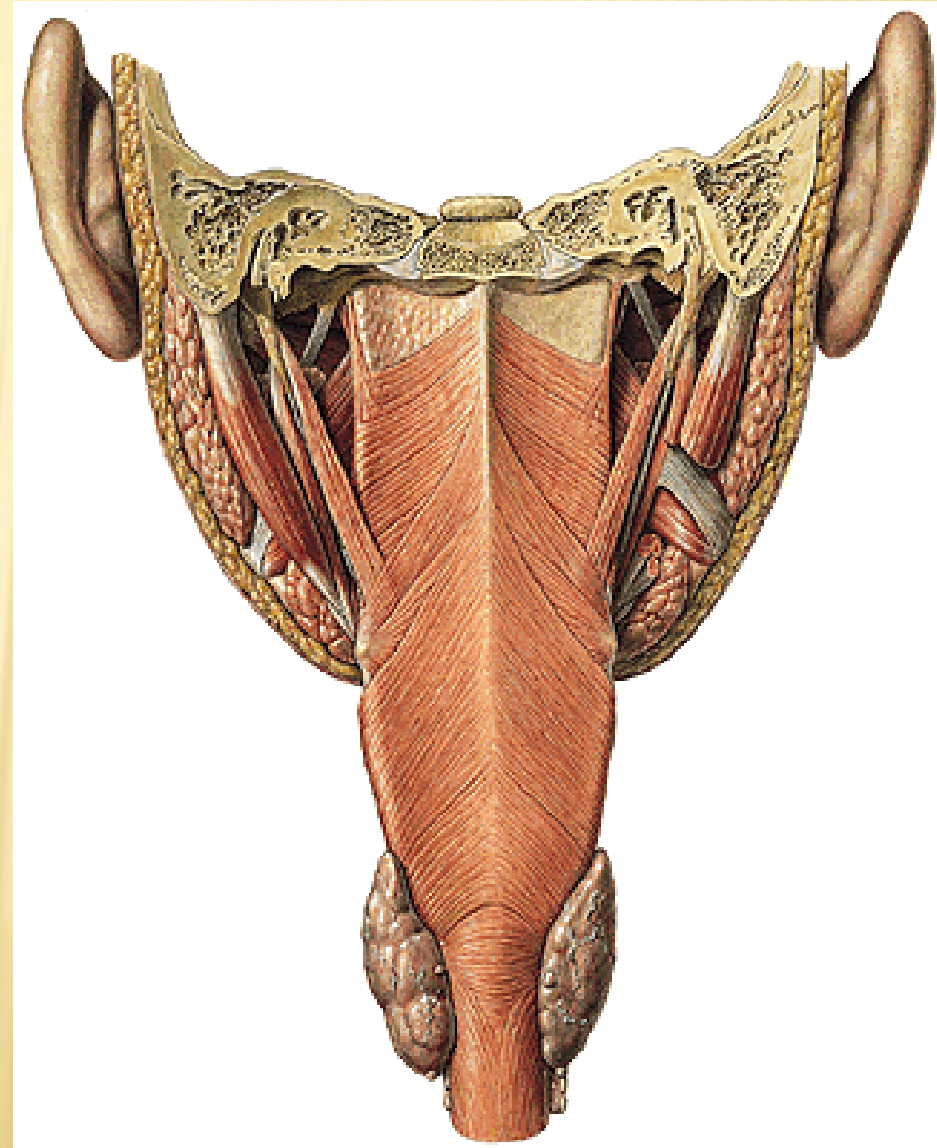
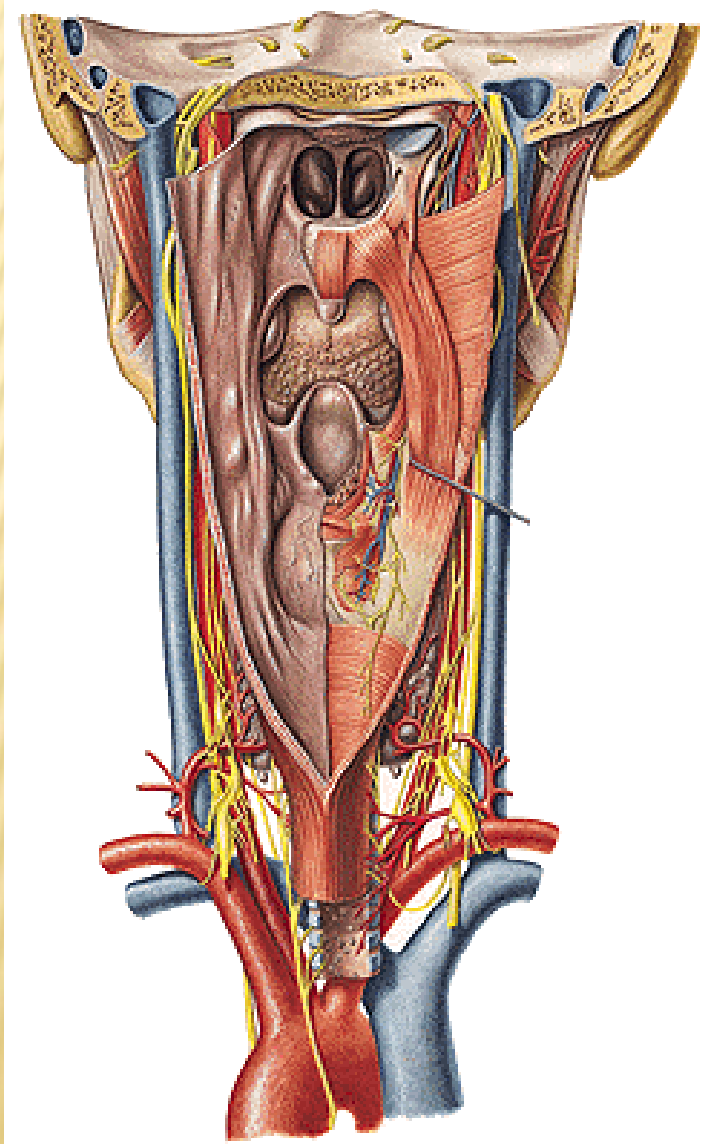
- RAPHE PHARYNGIS



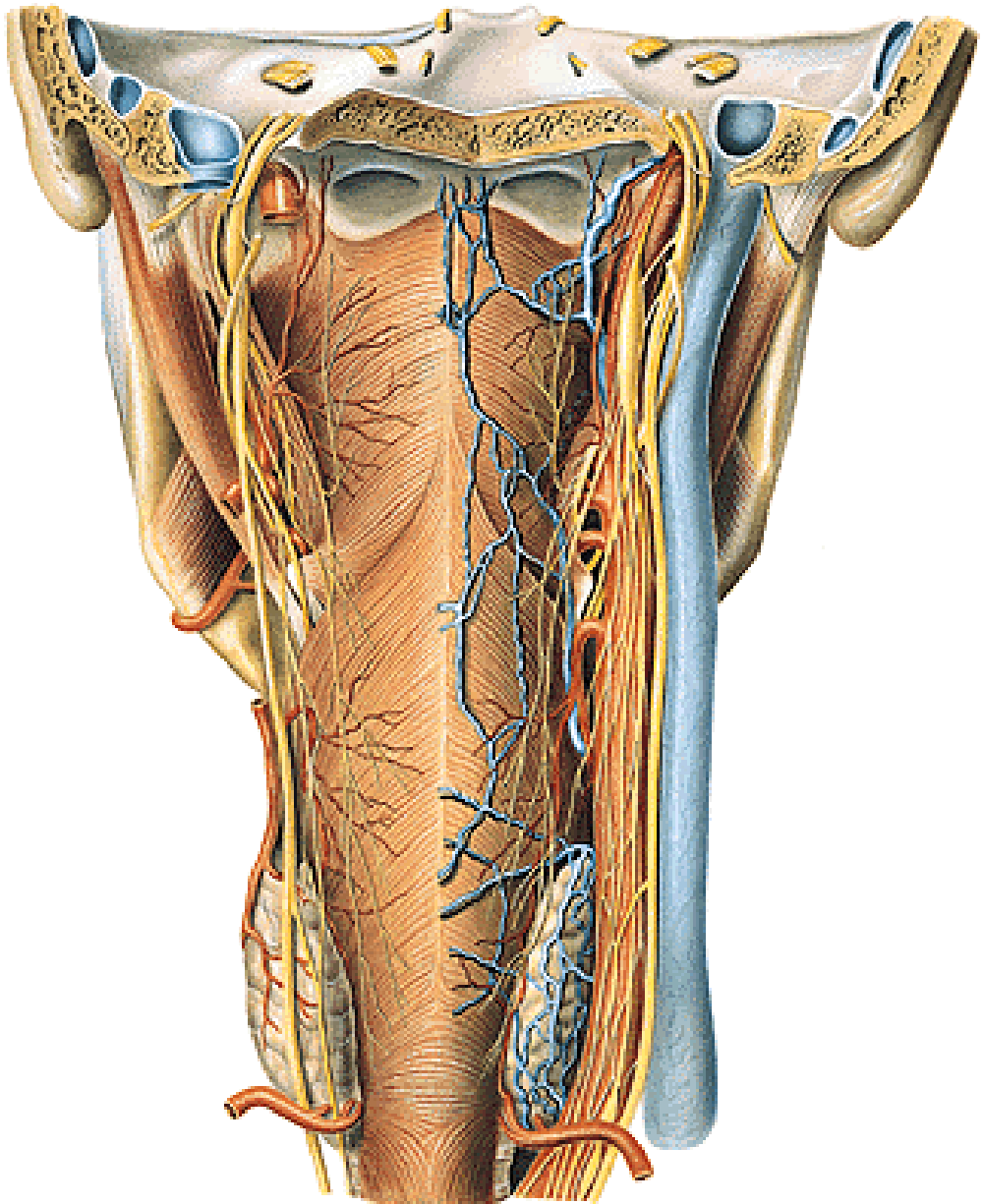
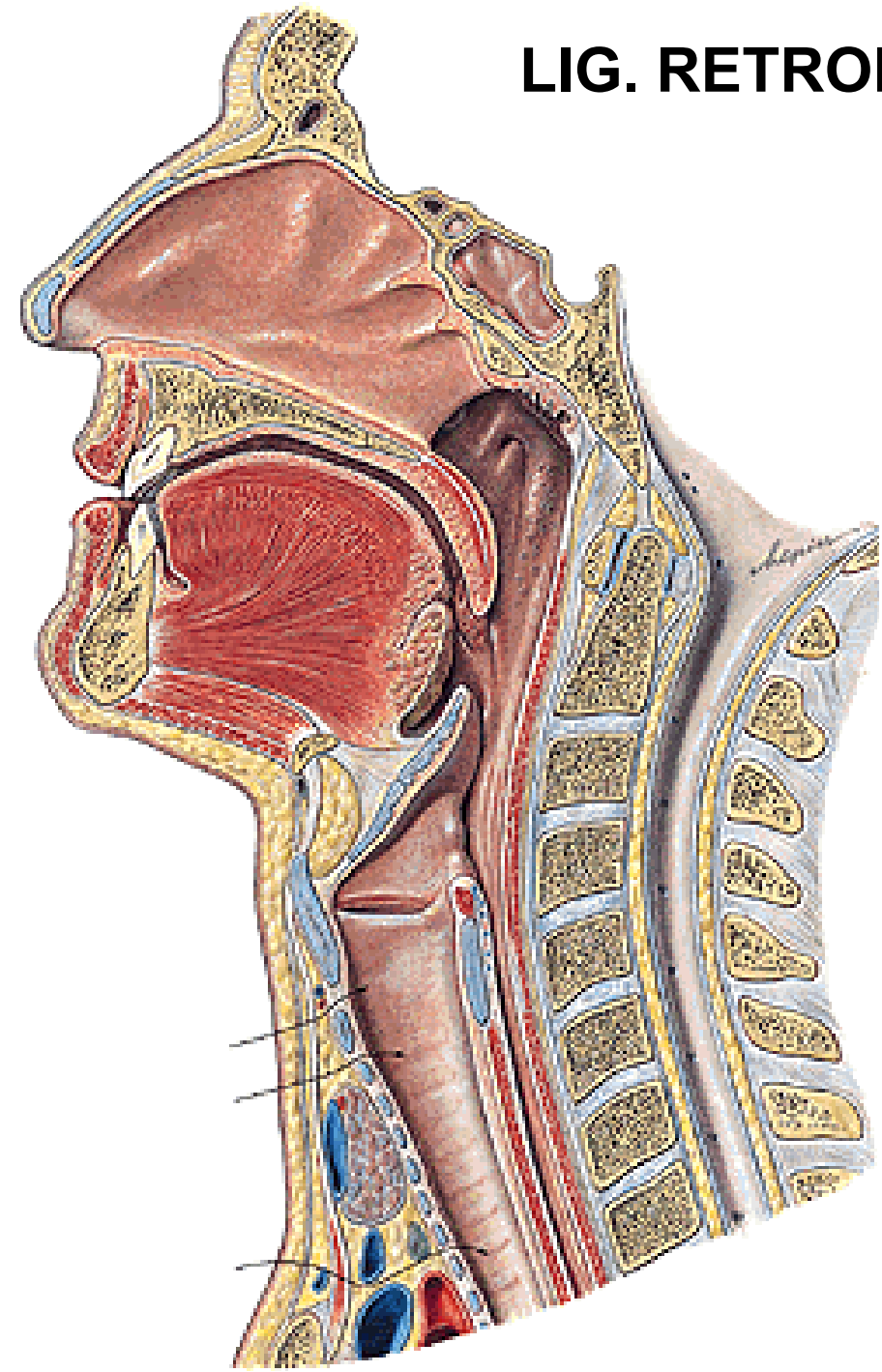
**FASCIA
PHARYNGOBASILARIS**



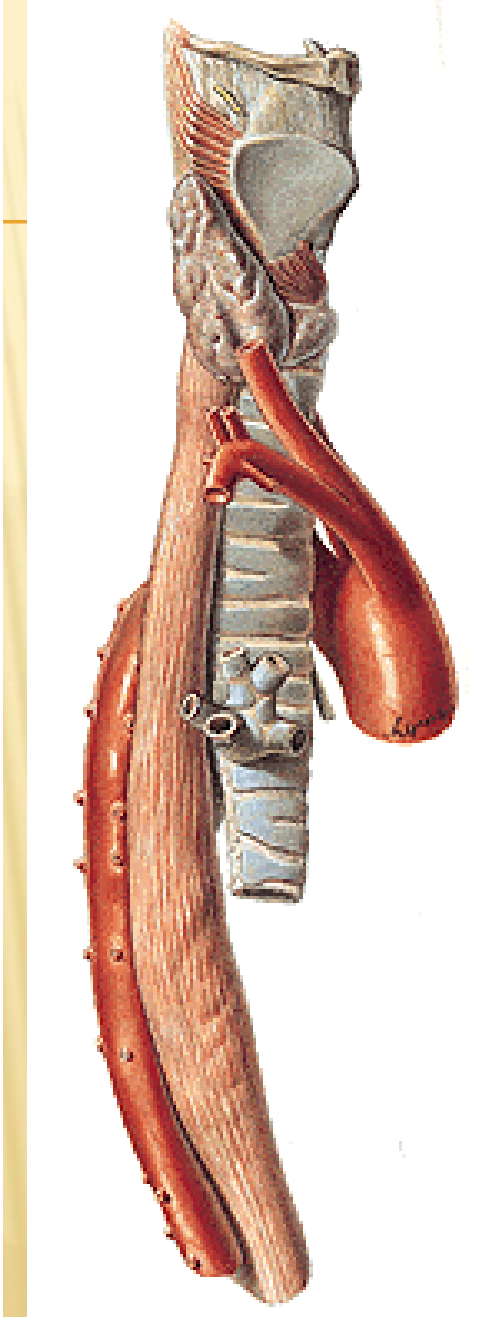
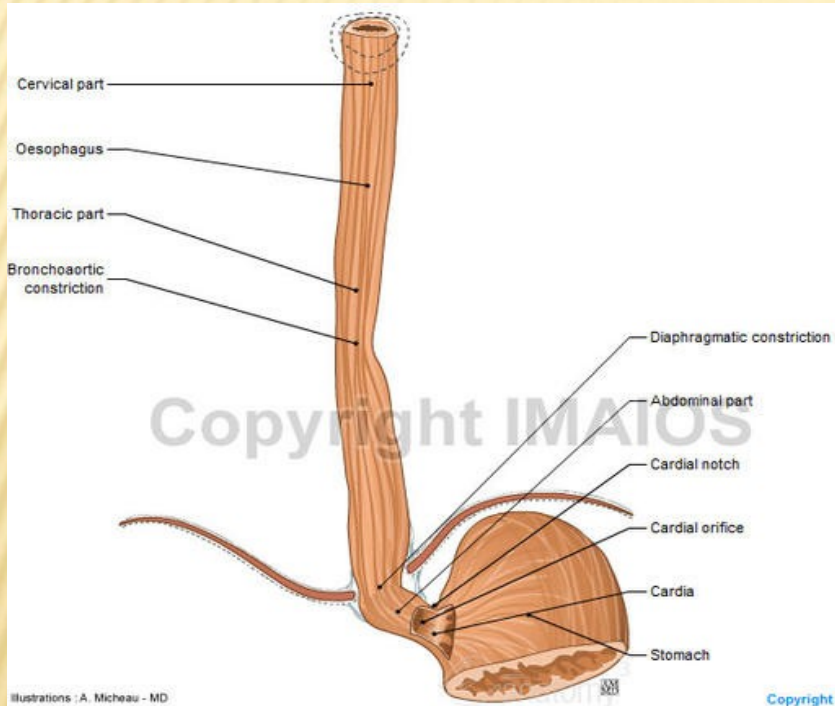
**LEVATORS: M. PALATOPHARYNGEUS
M. SALPINGOPHARYNGEUS
M. STYLOPHARYNGEUS**



LIG. RETROPHARYNGEUM MEDIANUM



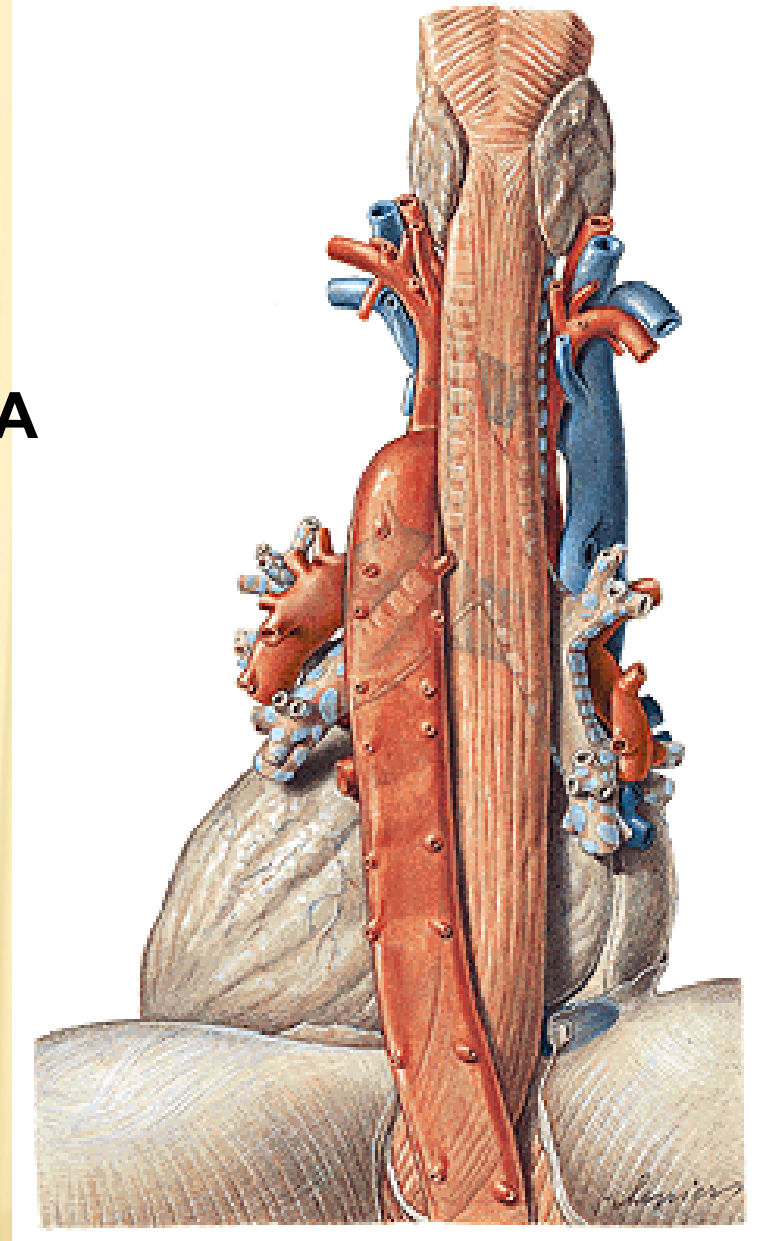
OESOPHAGUS



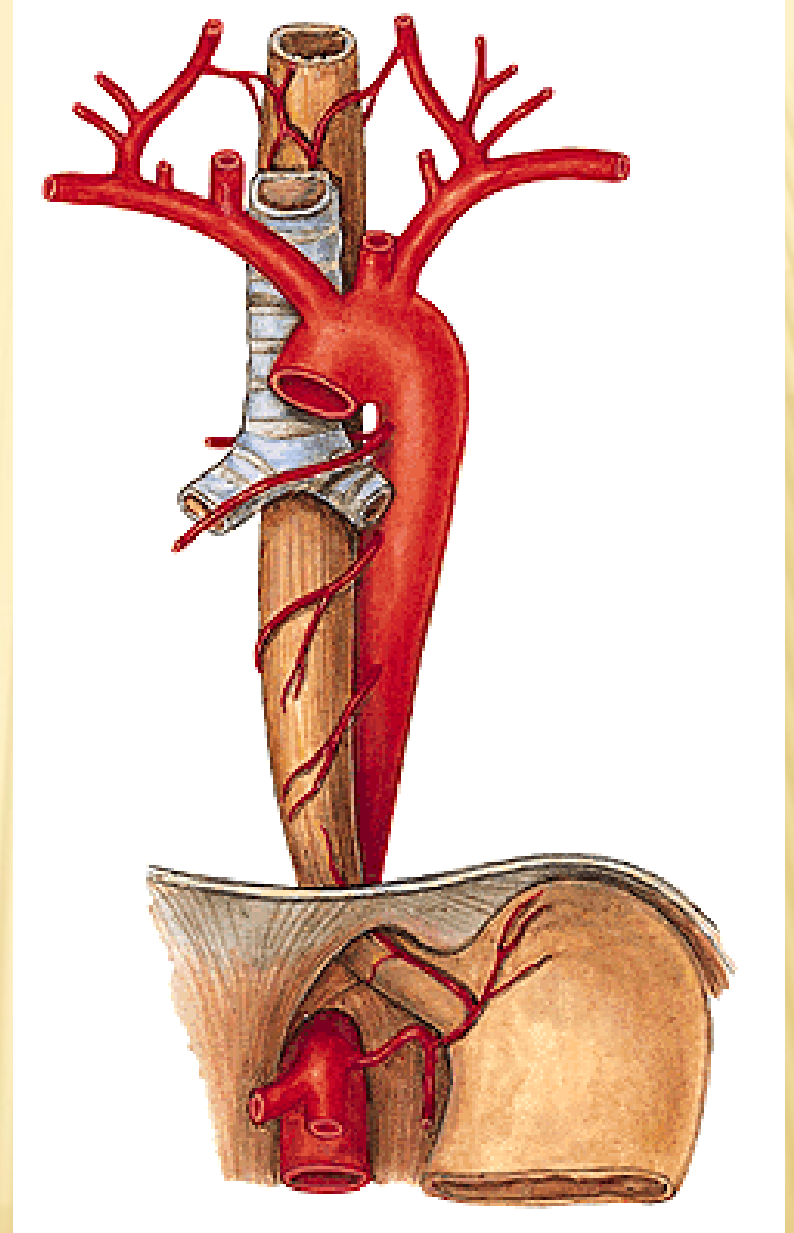
PARS CERVICALIS

PARS THORACICA

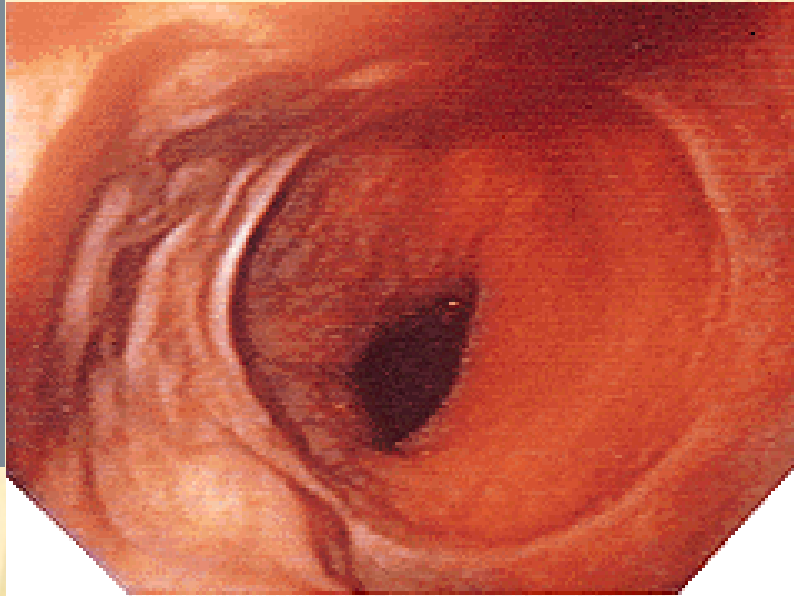
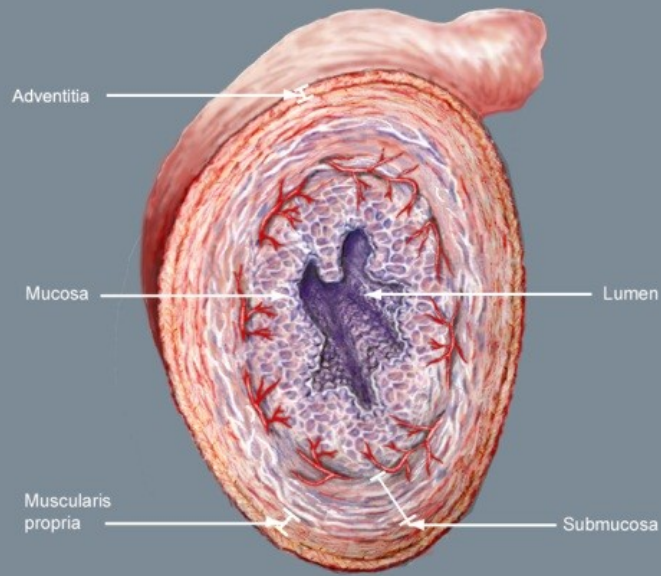
- PARS RETROTRACHEALIS**
- PARS RETROPERICARDIACA**



PARS ABDOMINALIS

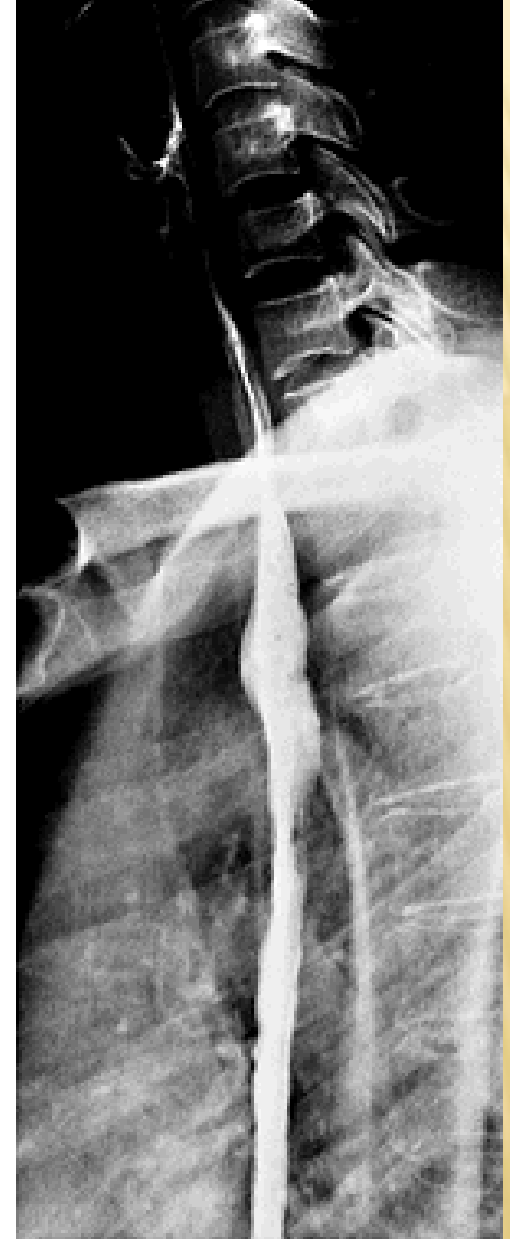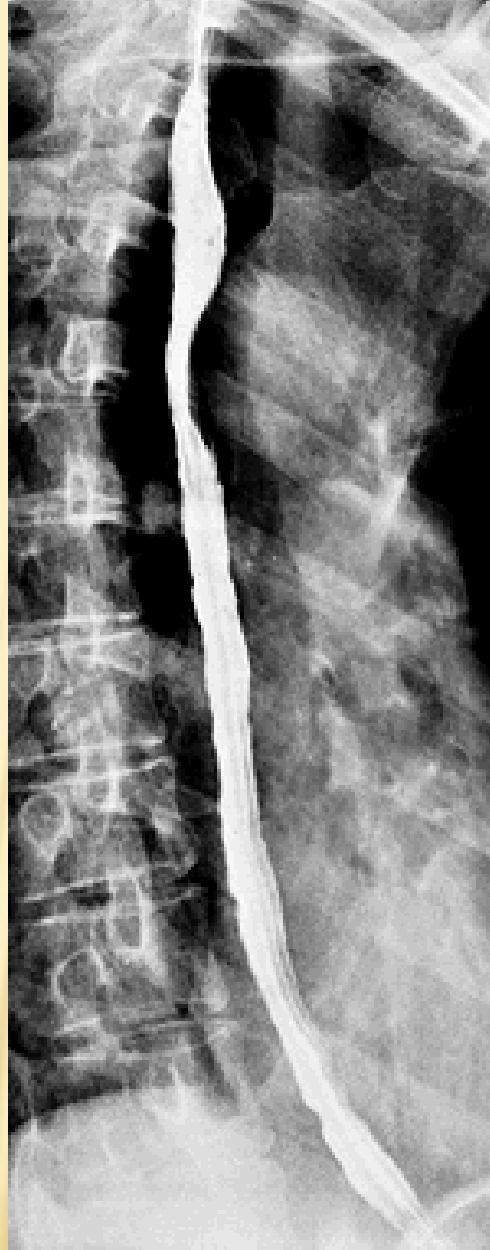


GASTROESOPHAGEAL JUNCTION



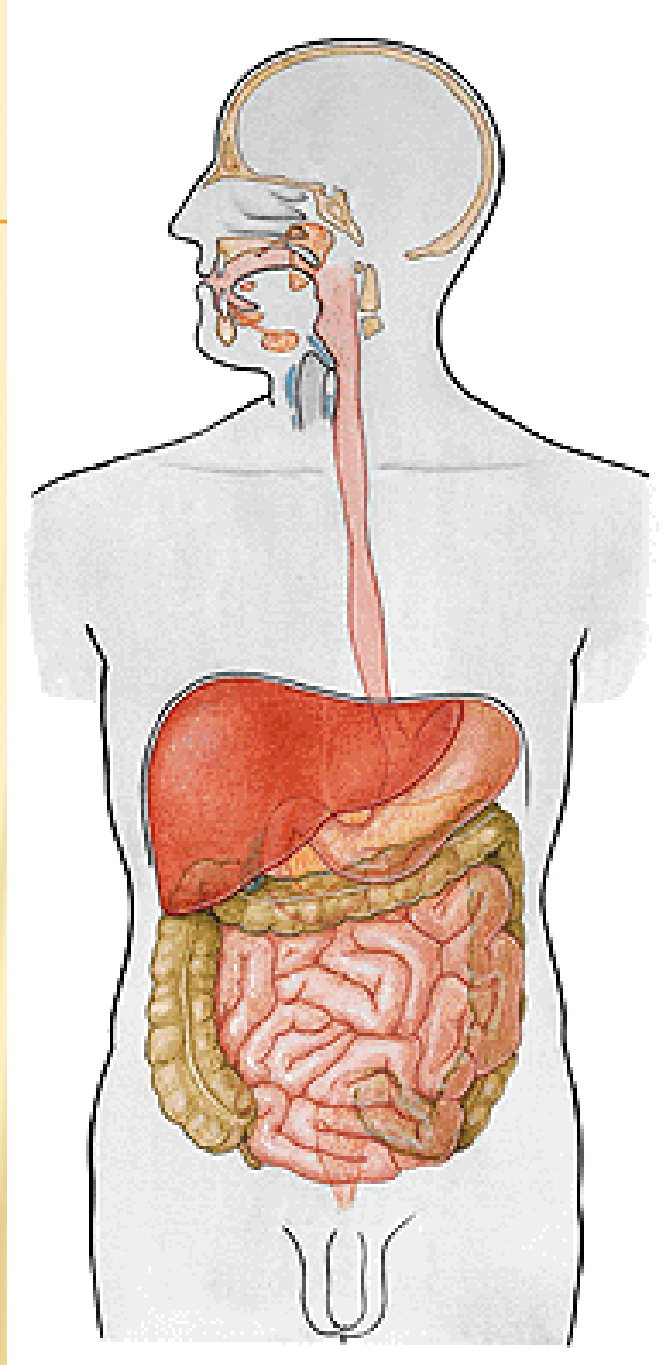
Musculature – striated, smooth

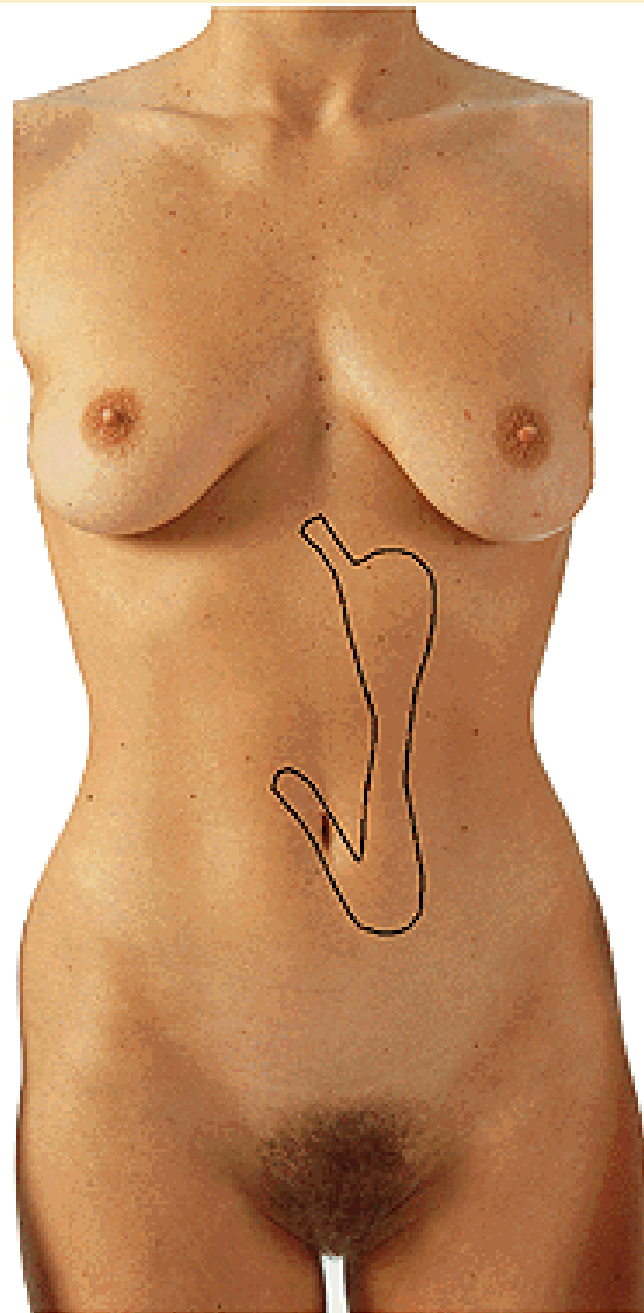
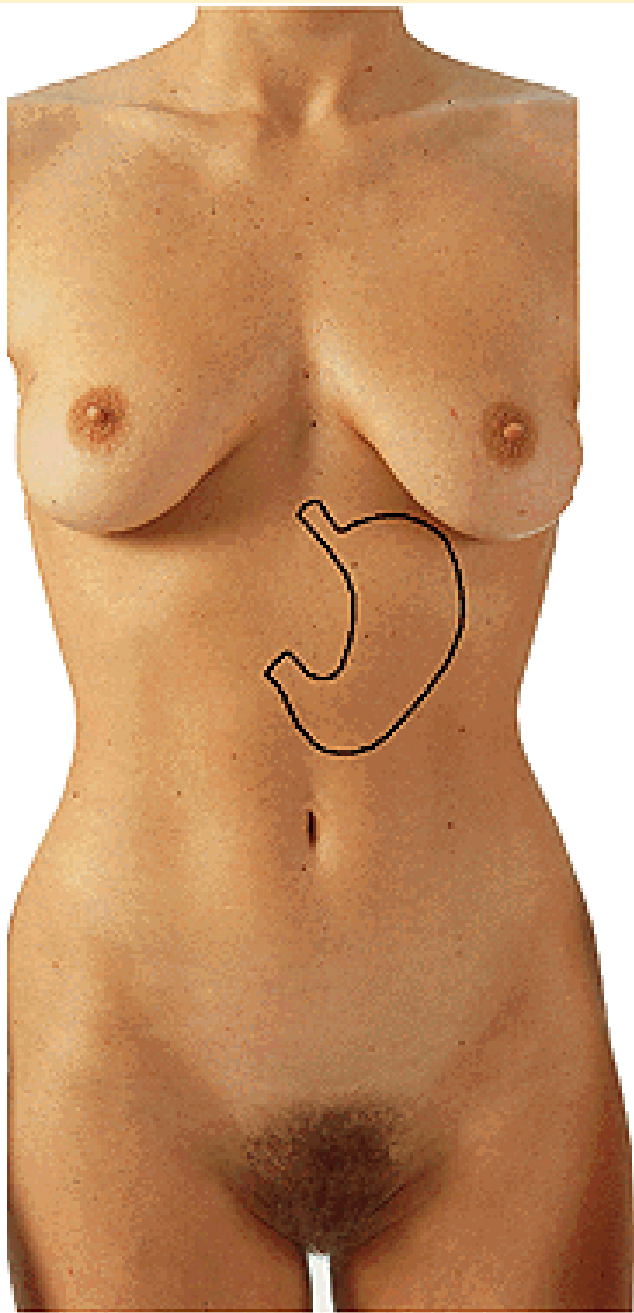
OESOPHAGOGRAPHY



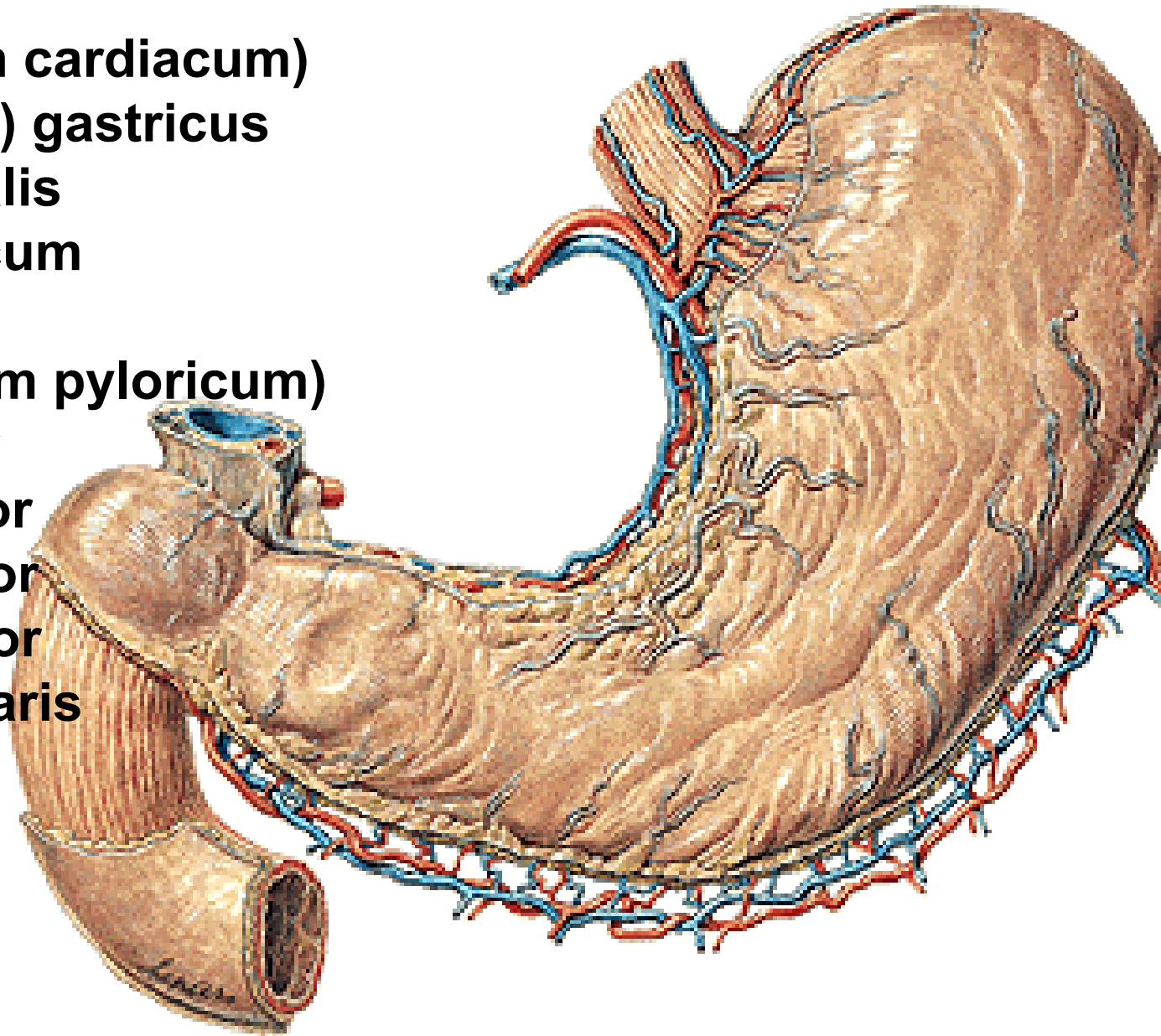
GASTER

Chymus

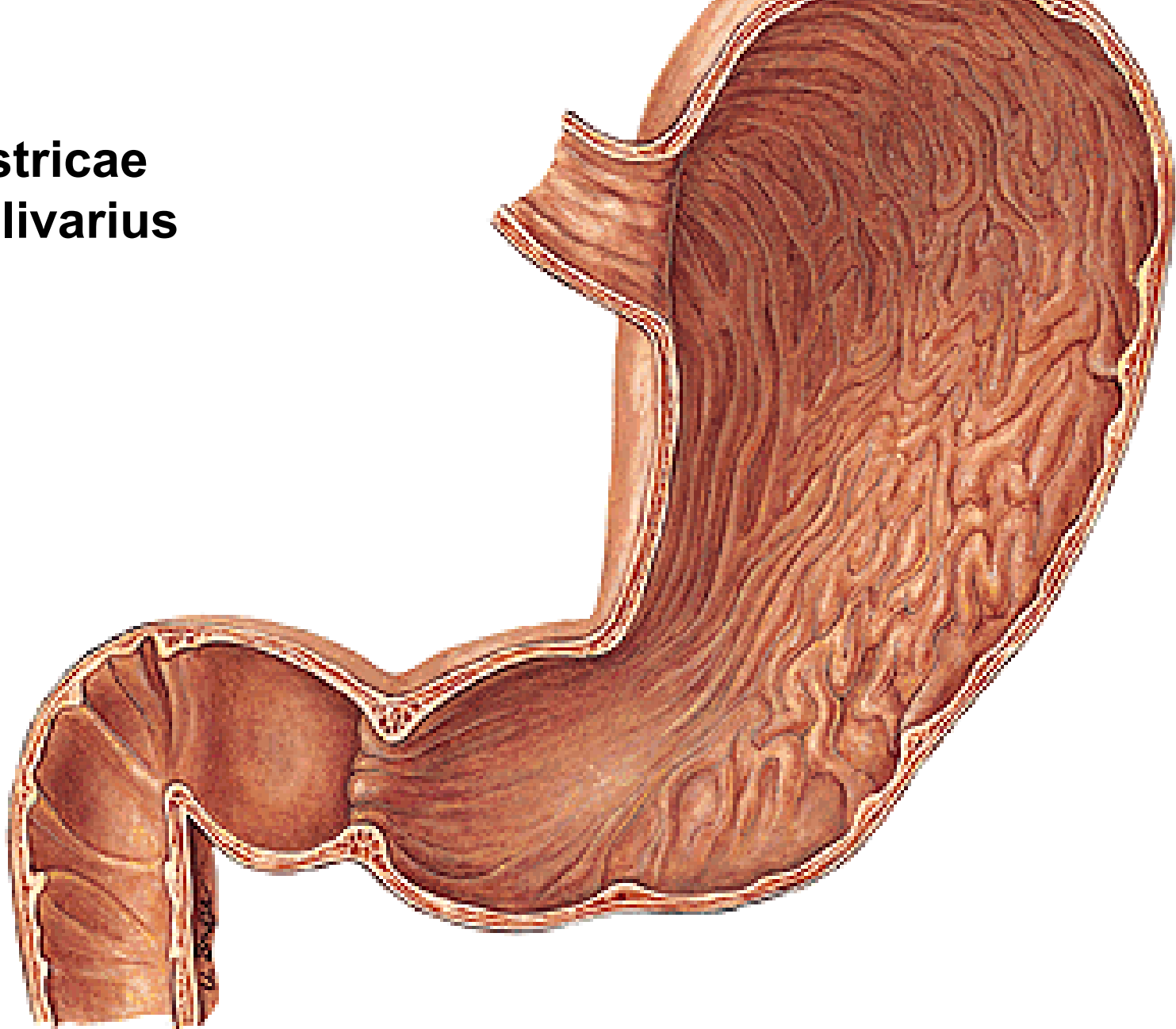




Cardia (Ostium cardiacum)
Fornix (fundus) gastricus
Incisura cardialis
Corpus gastricum
Pars pylorica
Pylorus (Ostium pyloricum)
Paries anterior
Paries posterior
Curvatura major
Curvatura minor
Incisura angularis

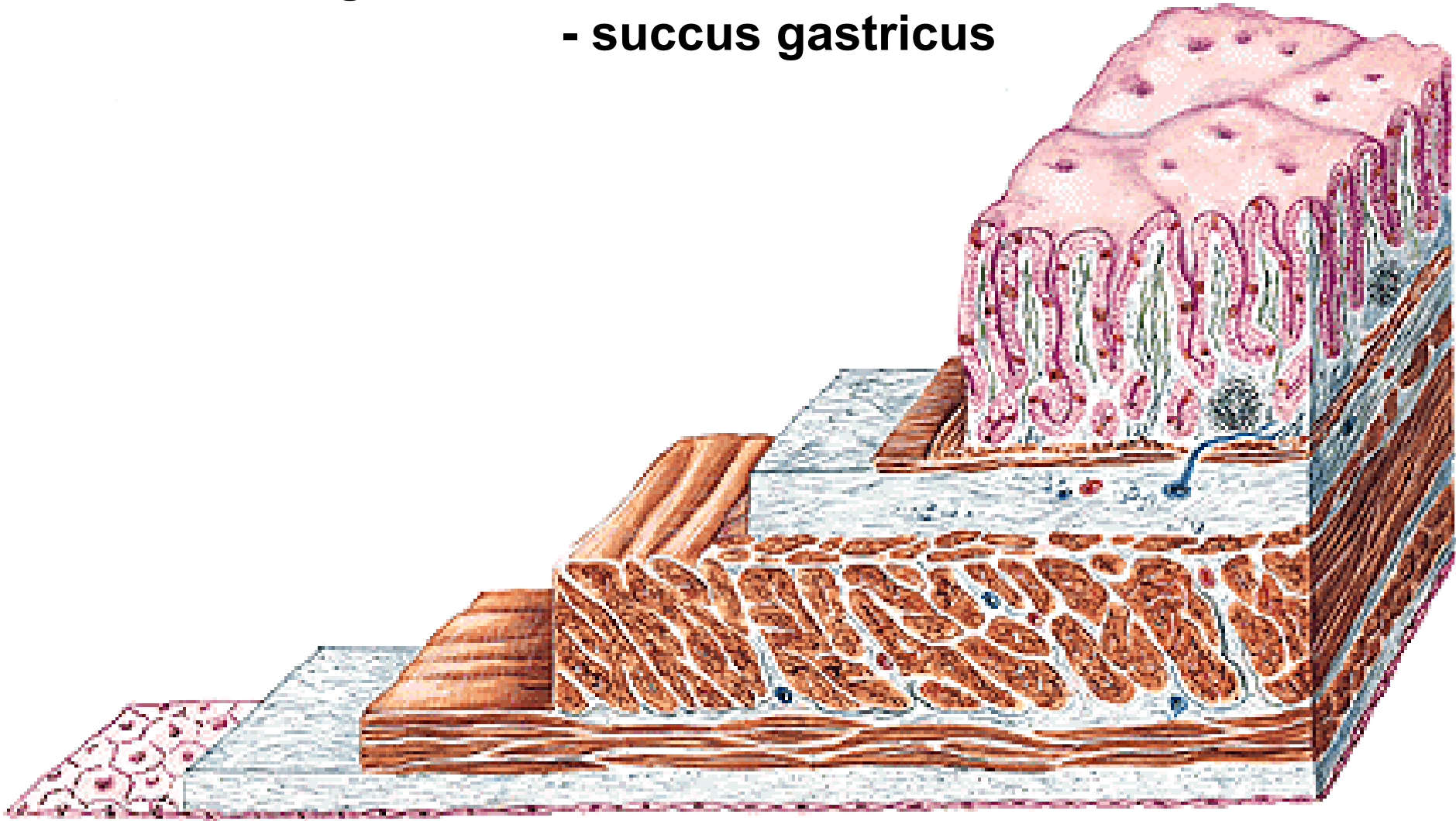


Plicae gastricae
Sulcus salivarius



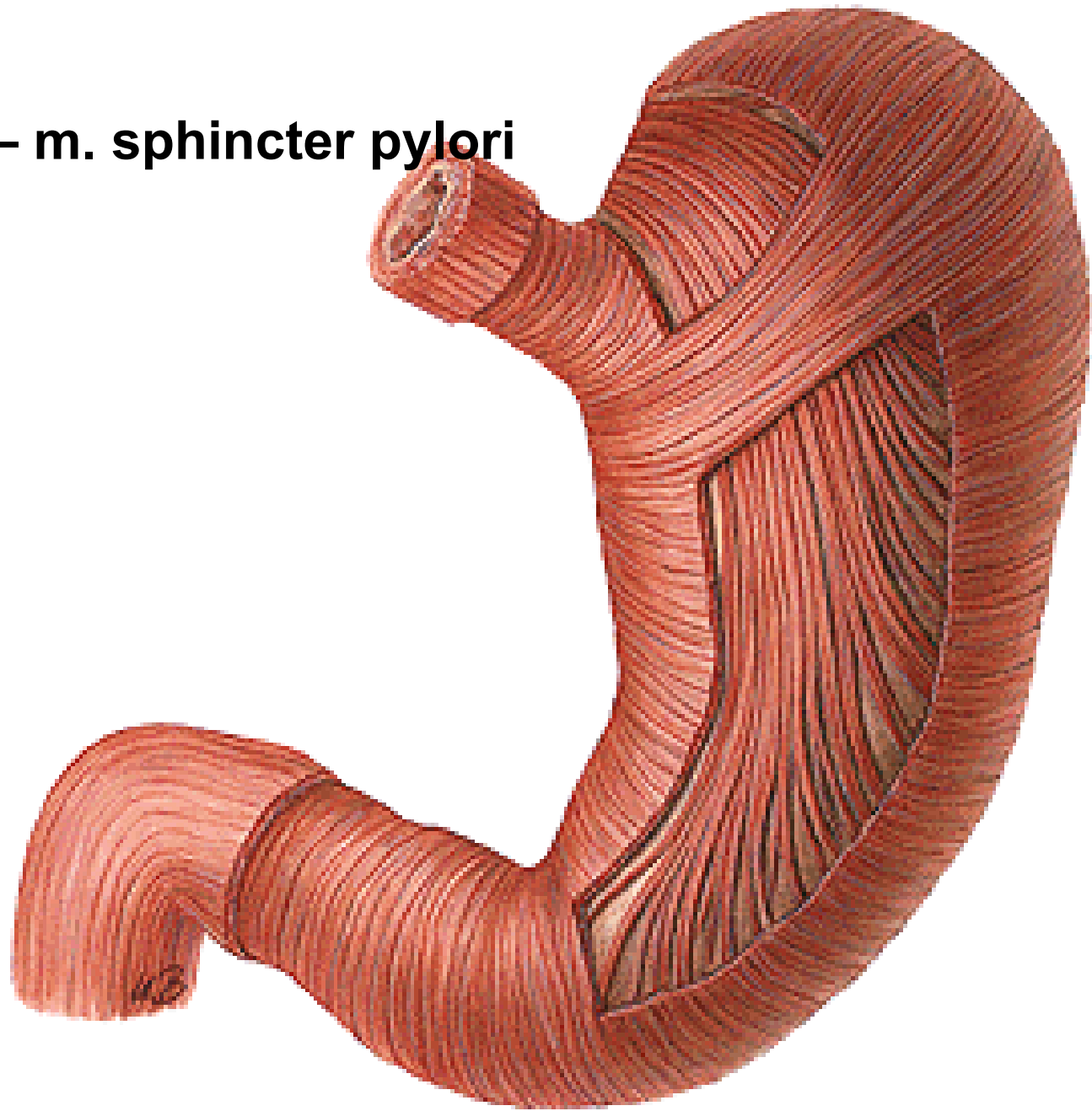
Glandulae gastricae - mucus

- succus gastricus

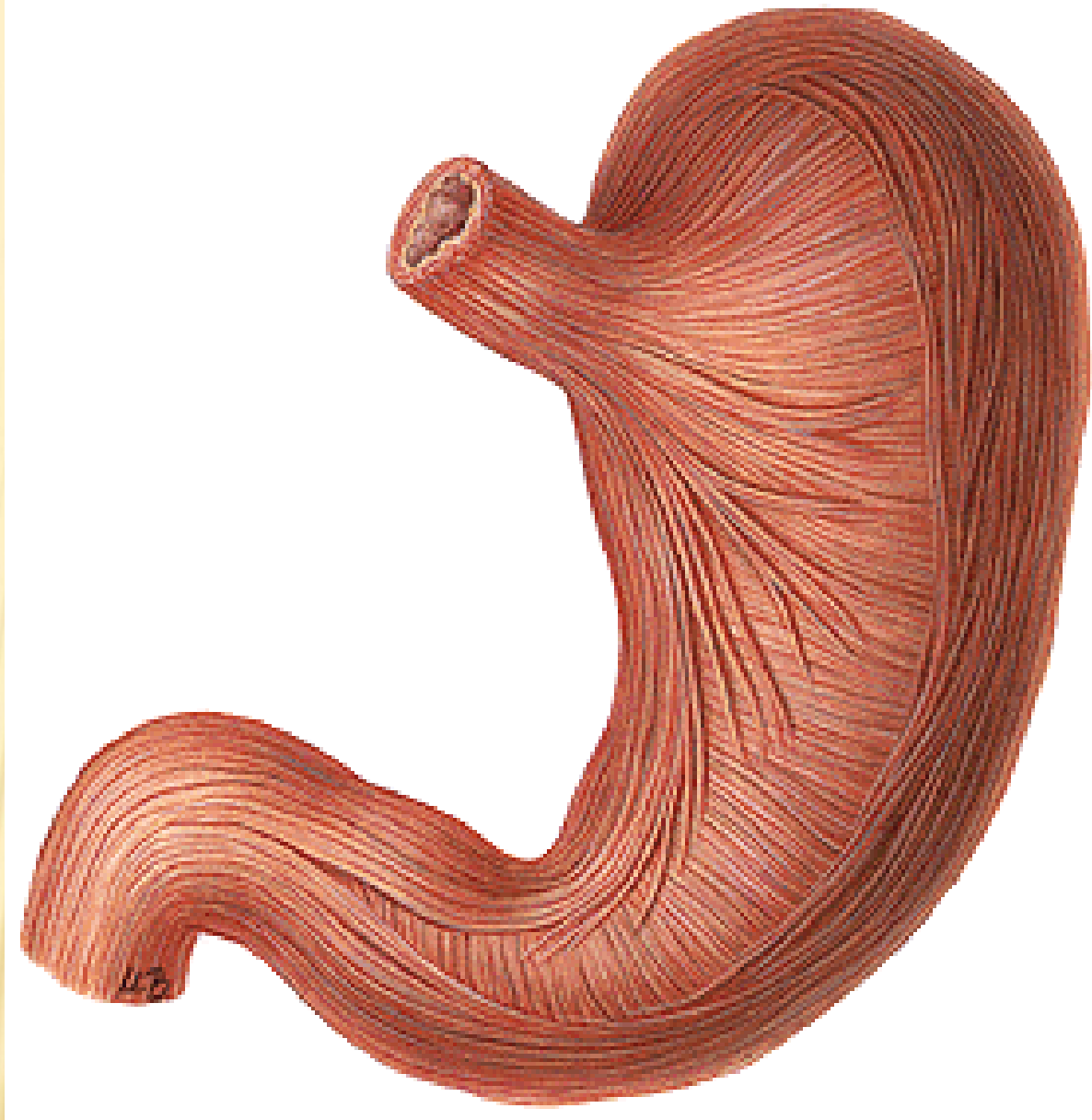


Fibrae obliquae

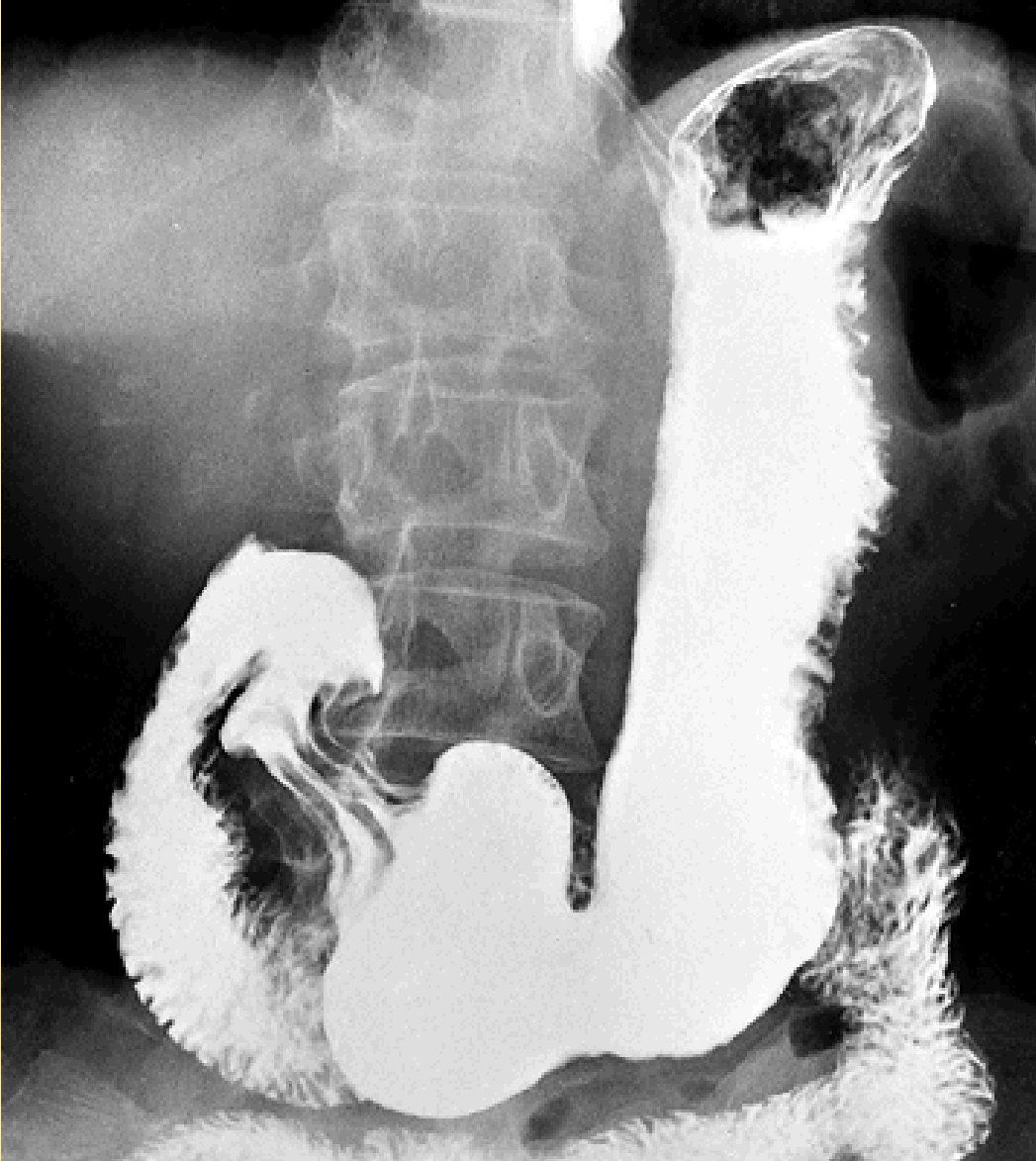
Stratum circulare – m. sphincter pylori



Stratum longitudinale



Incisura angularis



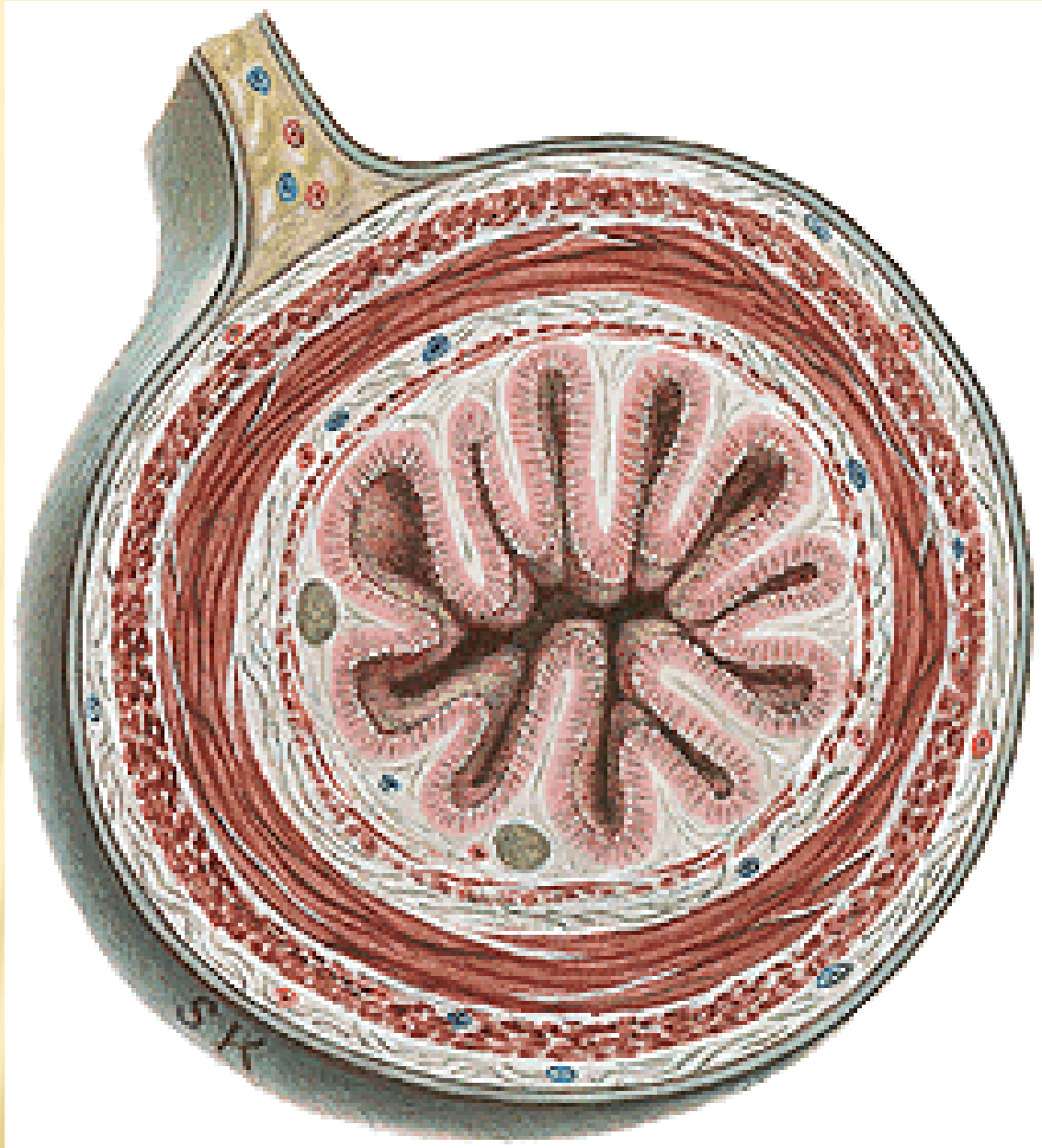
INTESTINUM

- × **INTESTINUM TENUE**
- × **INTESTINUM CRASSUM**

INTESTINUM TENUE

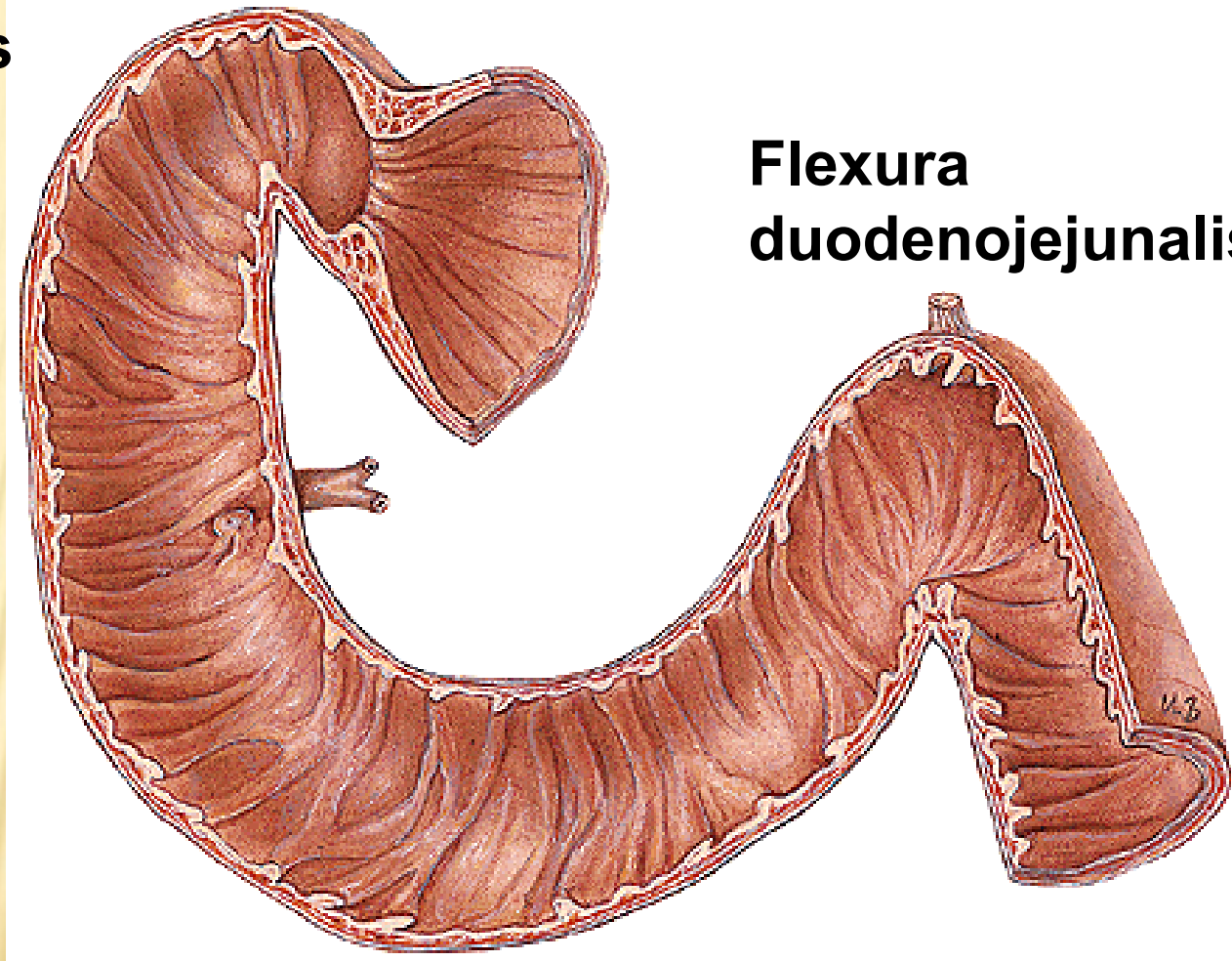
- duodenum
- jejunum
- ileum

Ansae intestinales
Mesenterium



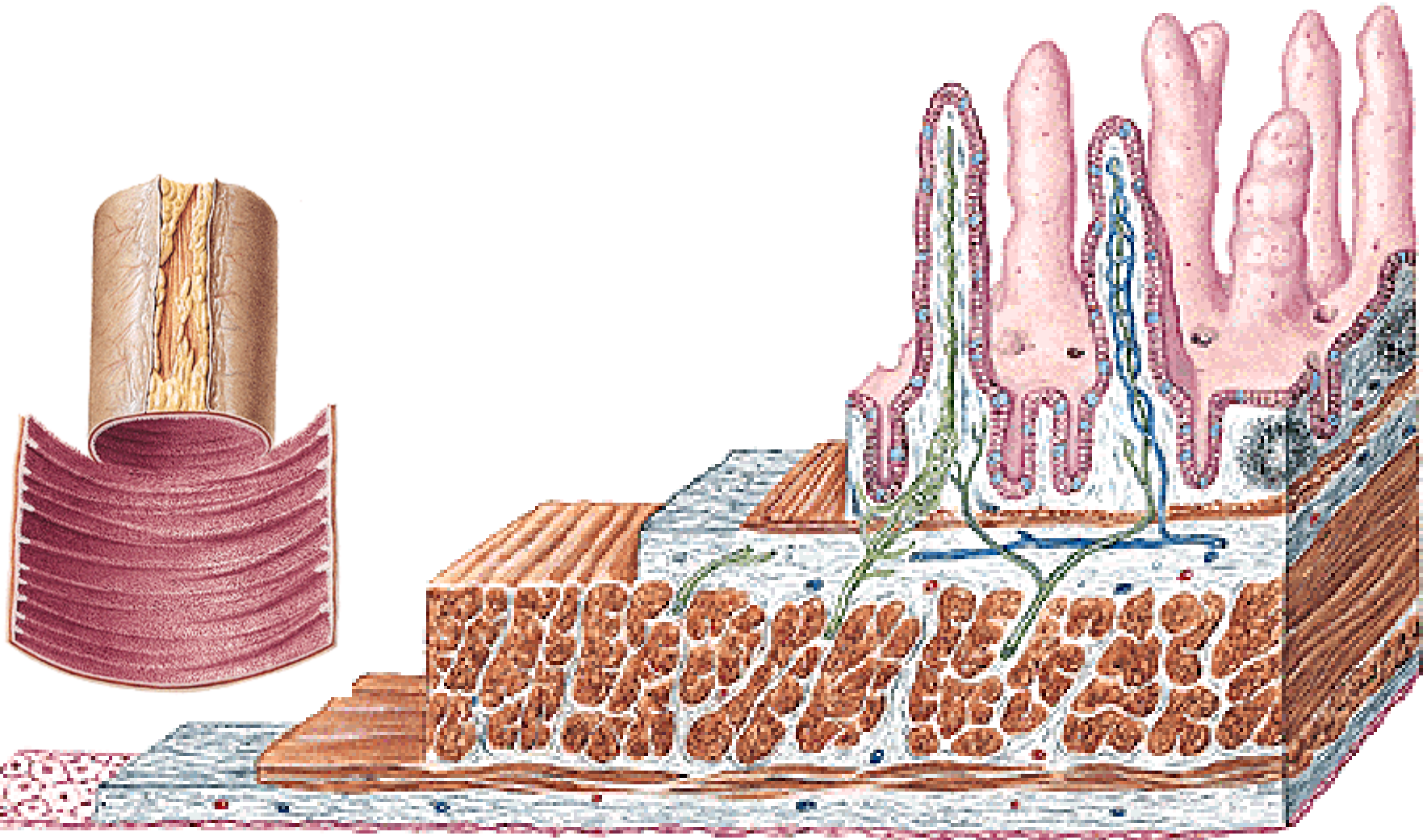
DUODENUM (duodecim /.)

- pars superior (bulbus duodeni)
- pars descendens
- pars horizontalis
- pars ascendens



**Flexura
duodenojejunalis**

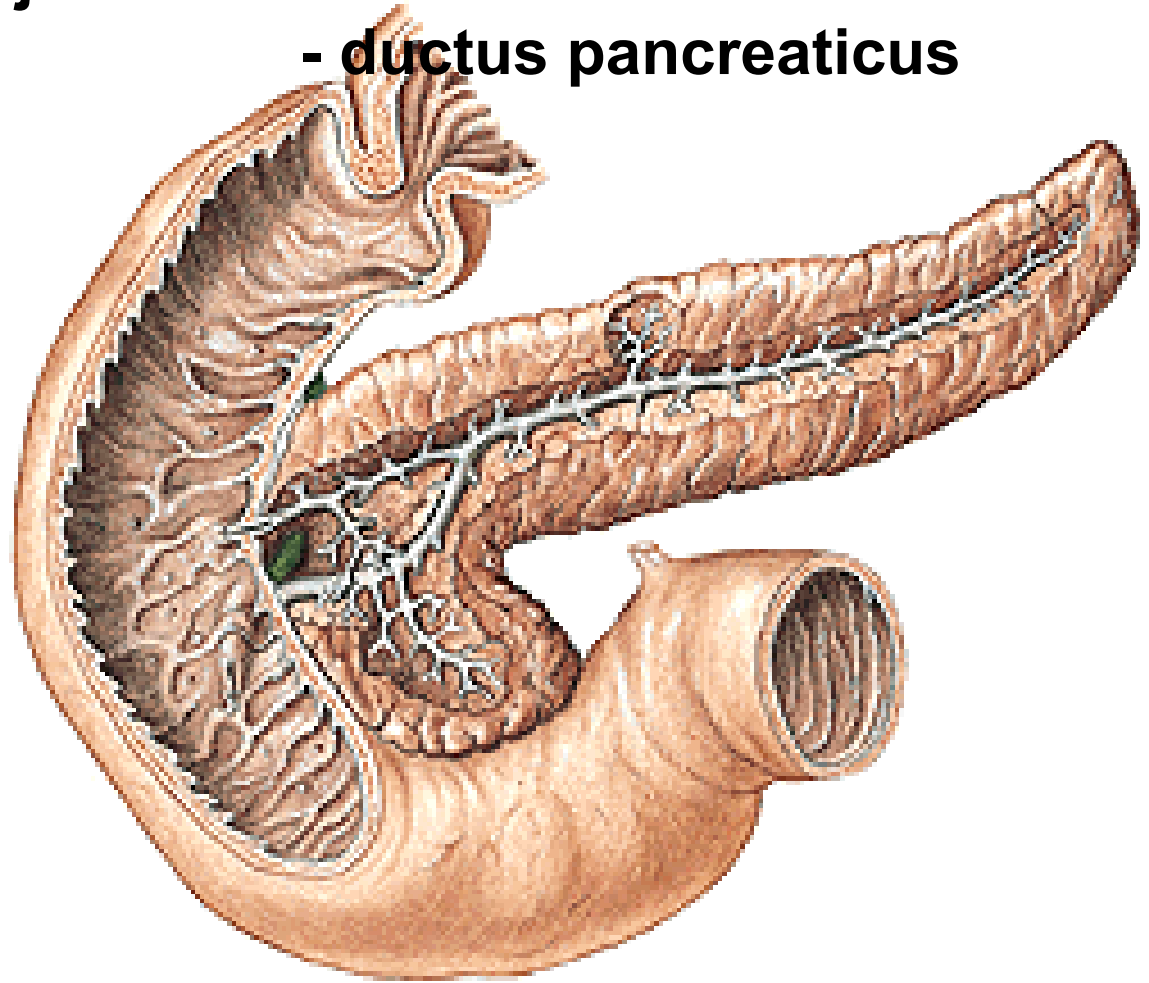
Glandulae duodenales Brunneri



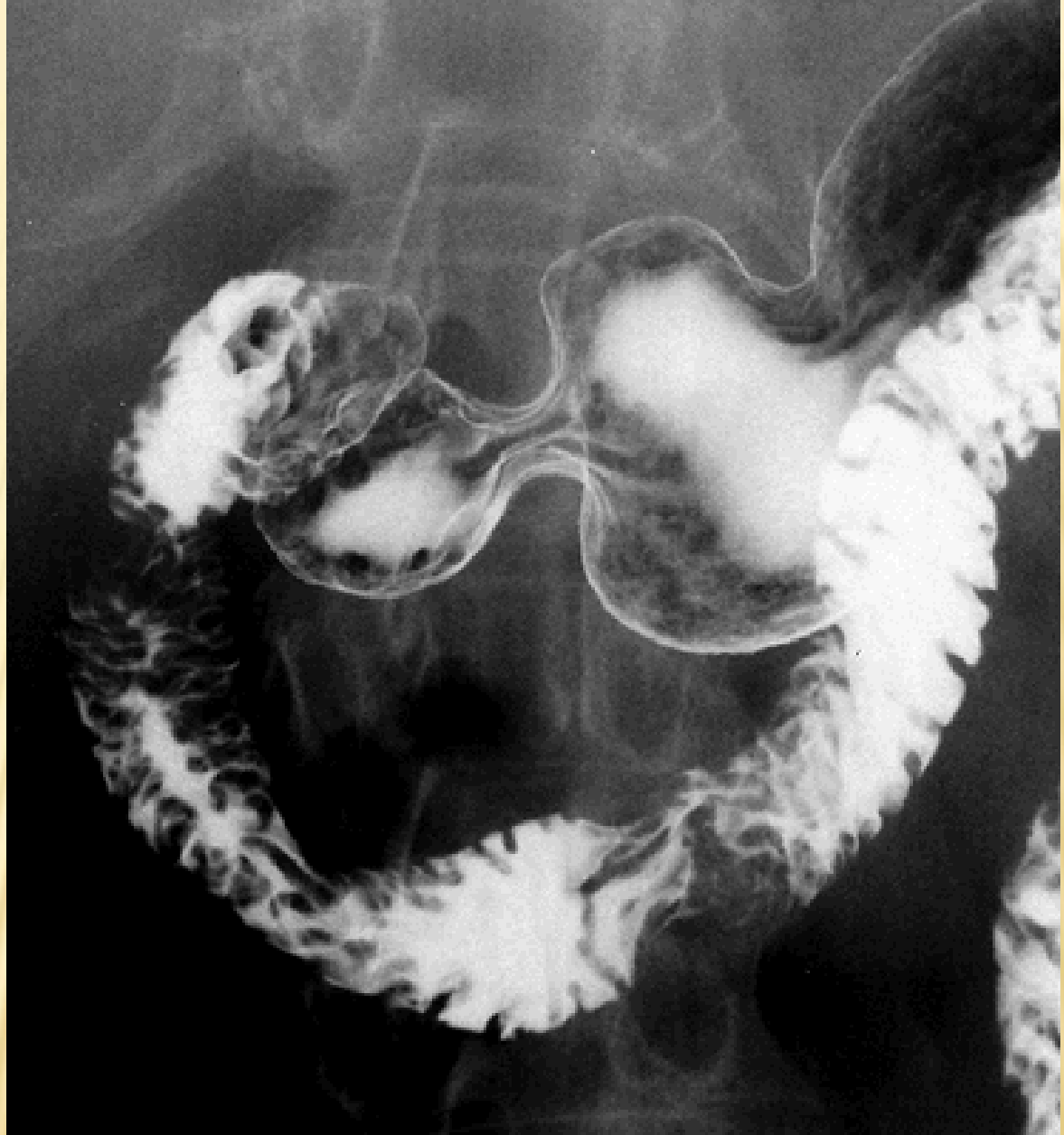
Plica longitudinalis duodeni

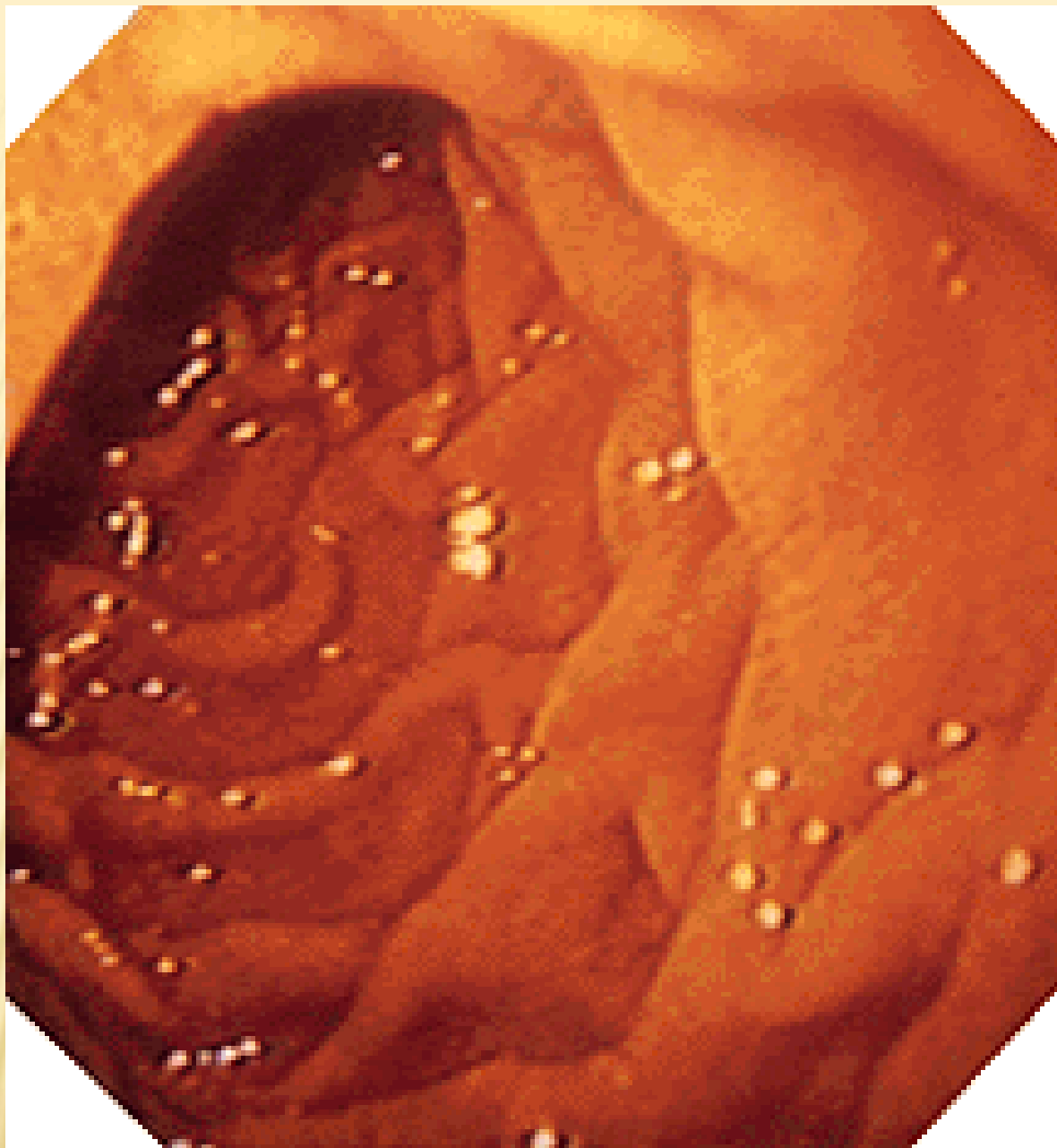
**Papilla duodeni major Vateri - ductus choledochus
- ductus pancreaticus**

**Papilla duodeni
minor-
ductus
pancreaticus
accessorius**

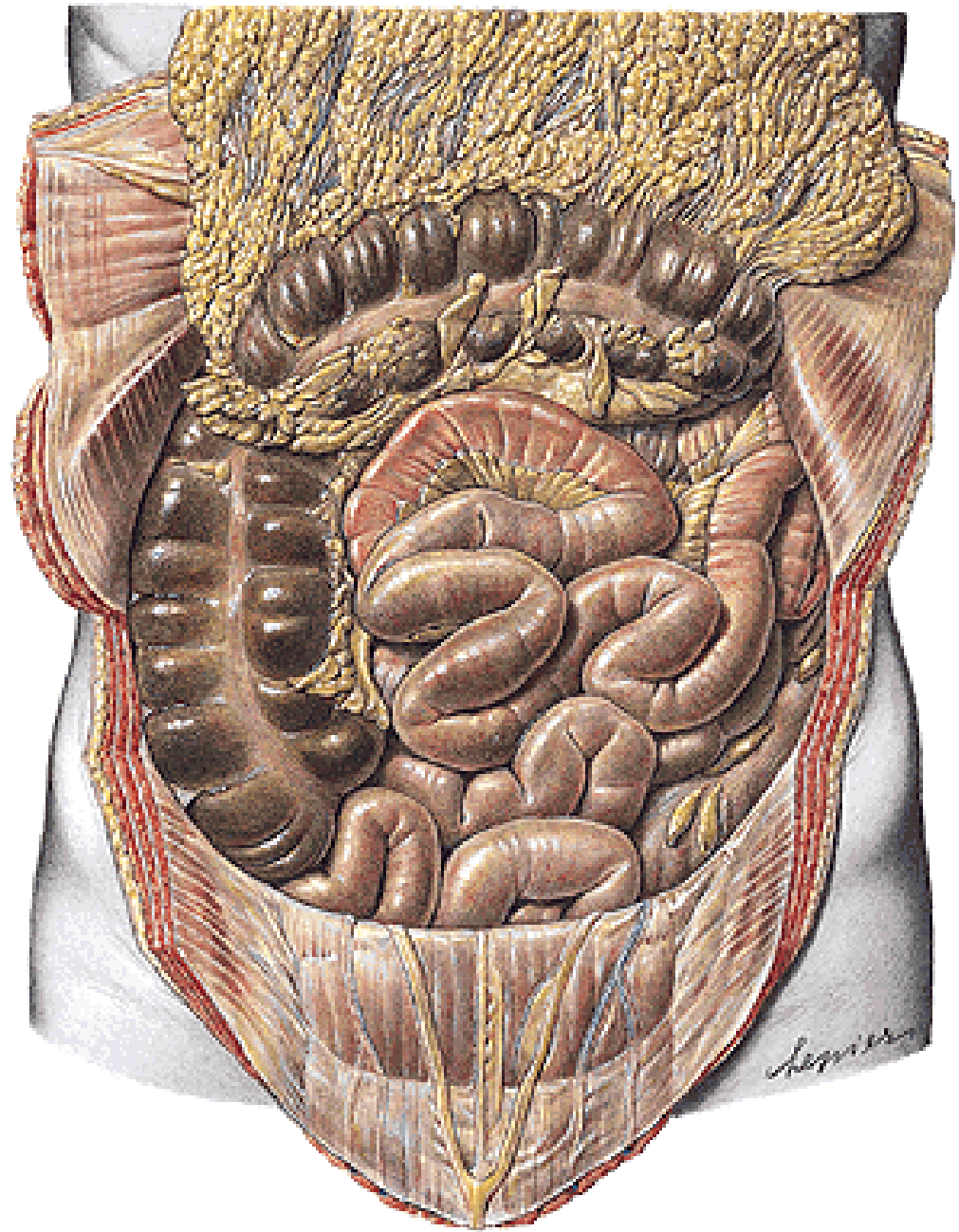


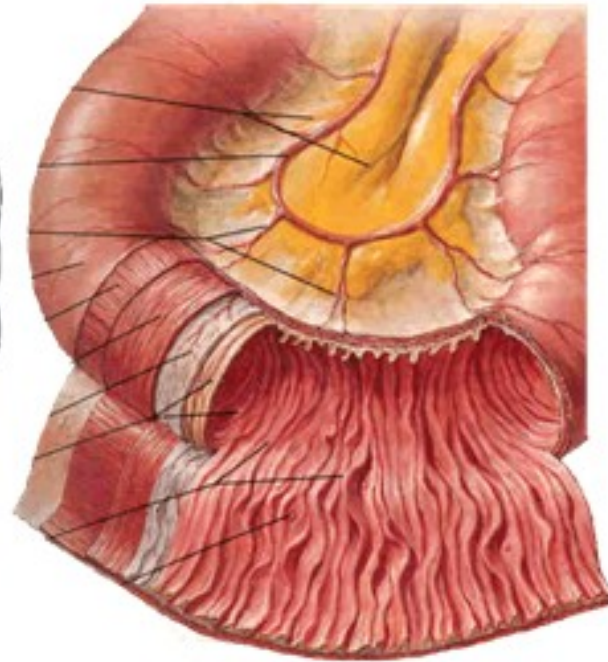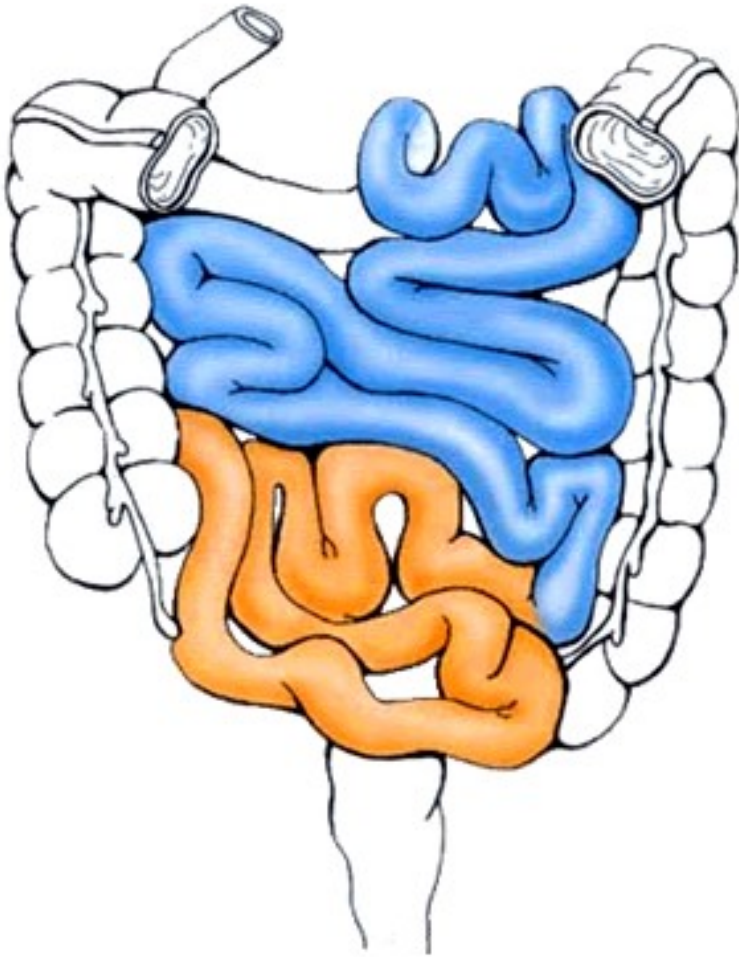
Enteroclysis



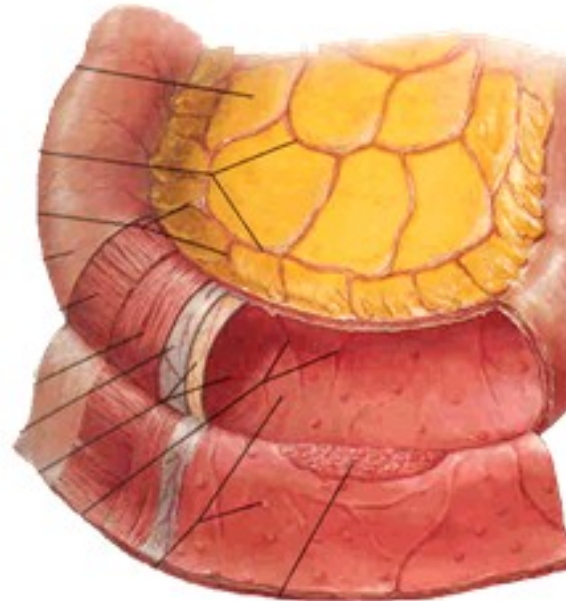


Jejunioileum



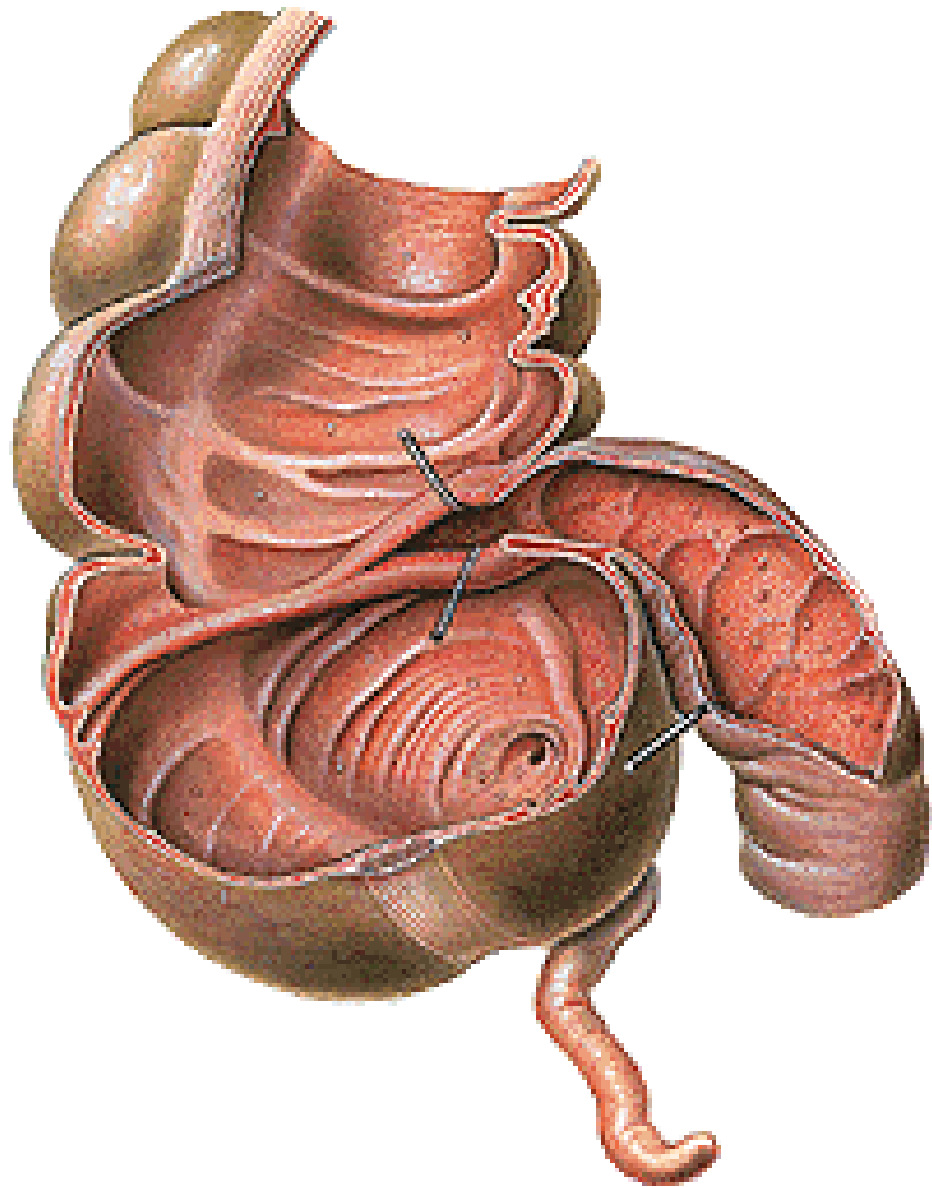


Jejunum



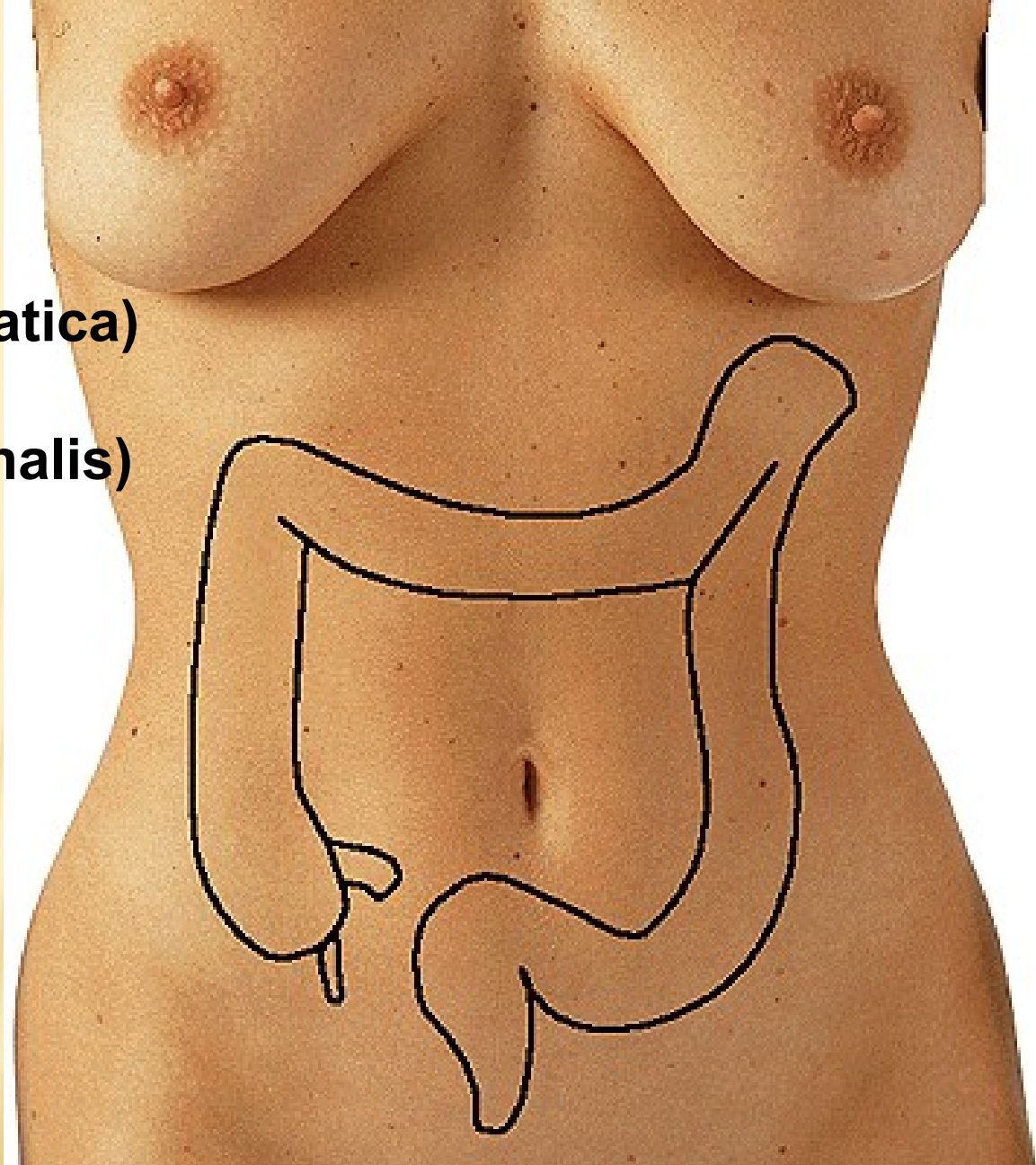
Ileum

Ostium ileale
Papilla ilealis
-labrum superius
-labrum inferius



INTESTINUM CRASSUM

- caecum**
- appendix vermiformis**
- colon ascendens**
- flexura coli dextra (hepatica)**
- colon transversum**
- flexura coli sinistra (lienalis)**
- colon descendens**
- colon sigmoideum**
- rectum**



Plicae semilunares

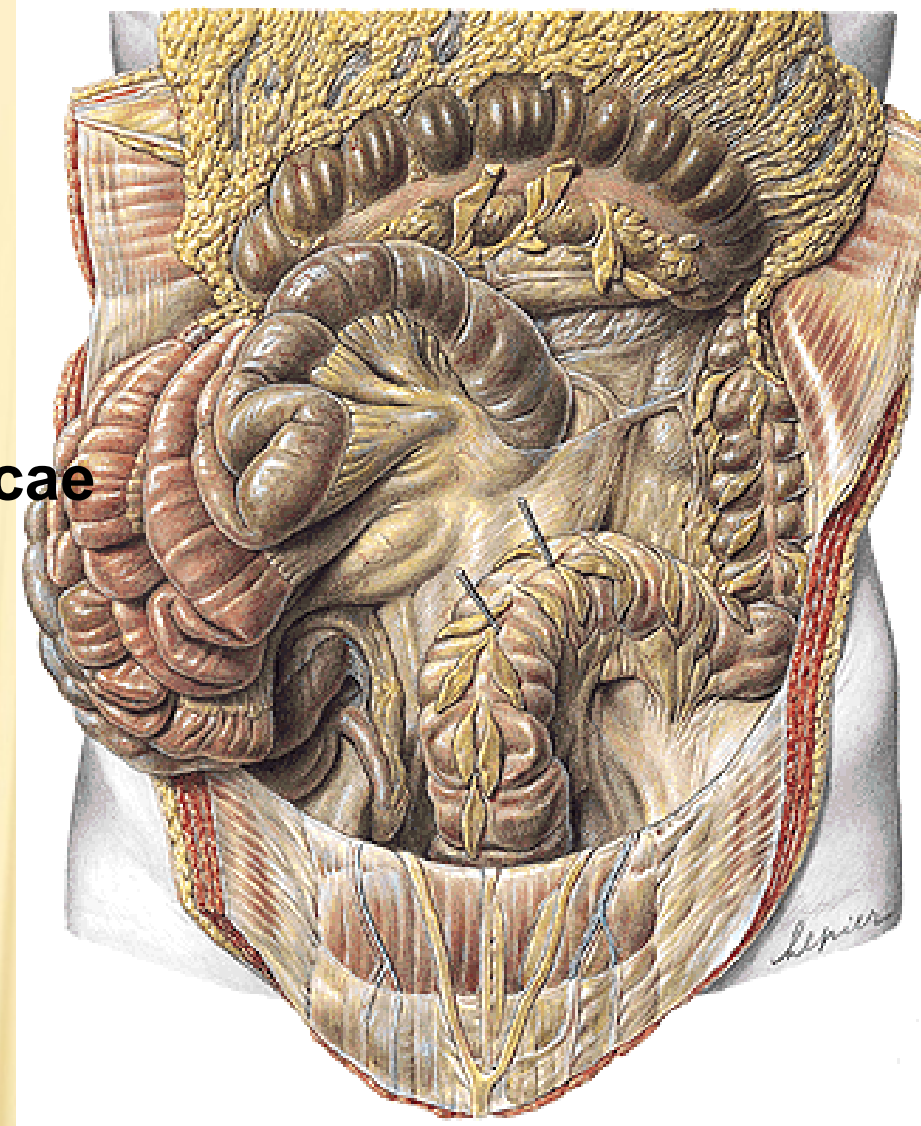
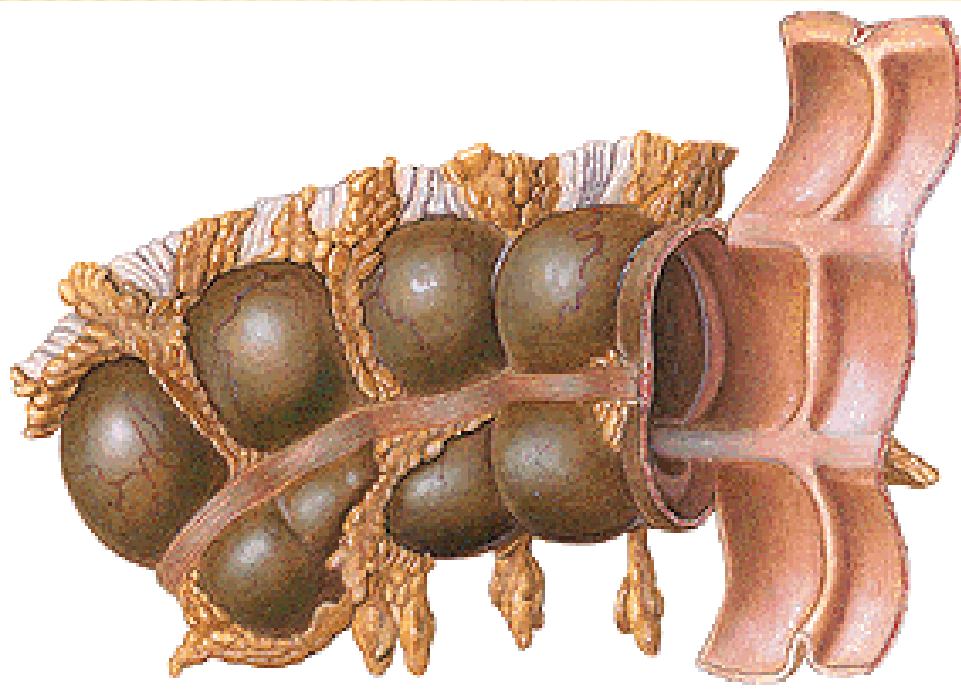
Haustra coli

Taenia mesocolica

Taenia omentalis

Taenia libera

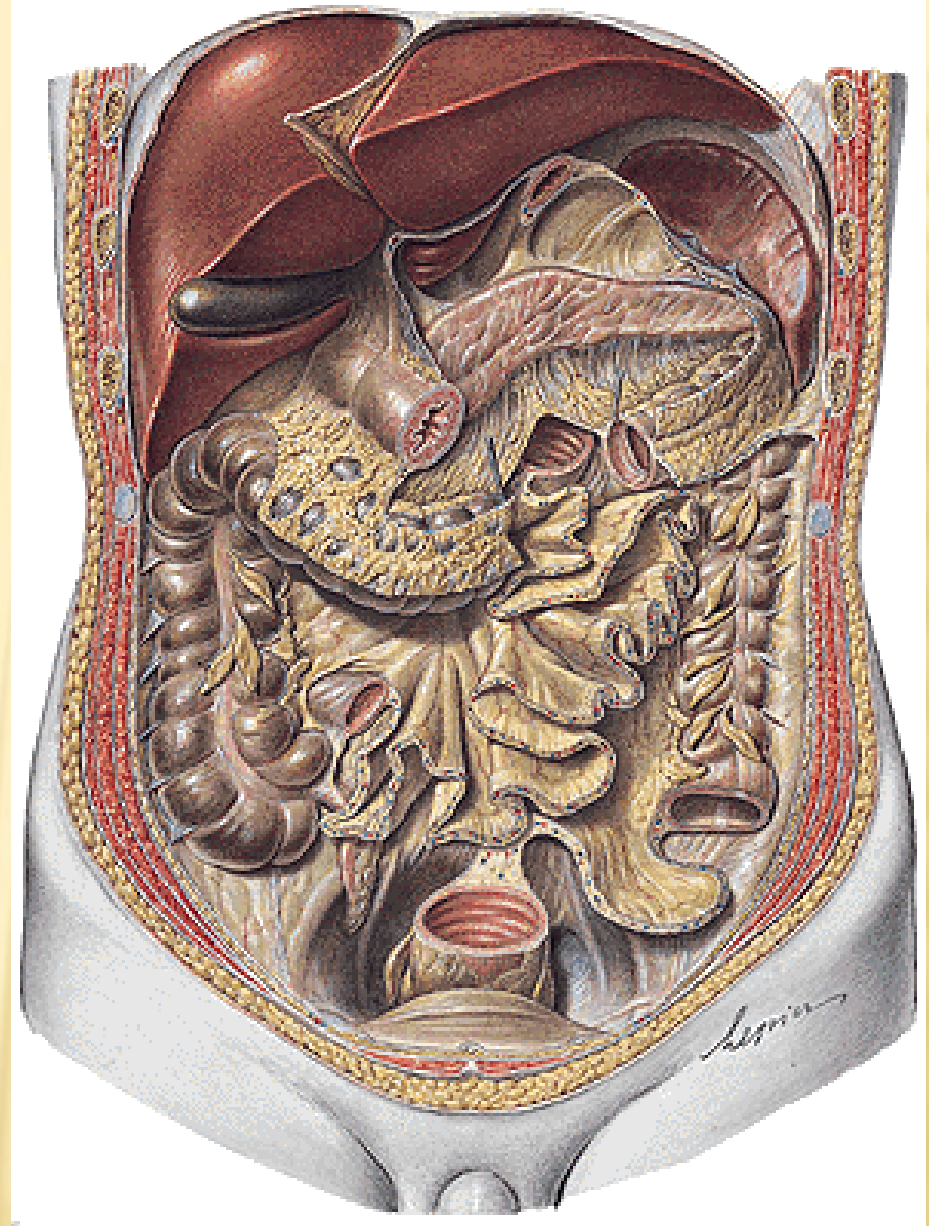

Appendices omentales/epiploicae



CAECUM

Recessus retrocaecalis

Caecum liberum –
mesocaecum



APPENDIX VERMIFORMIS

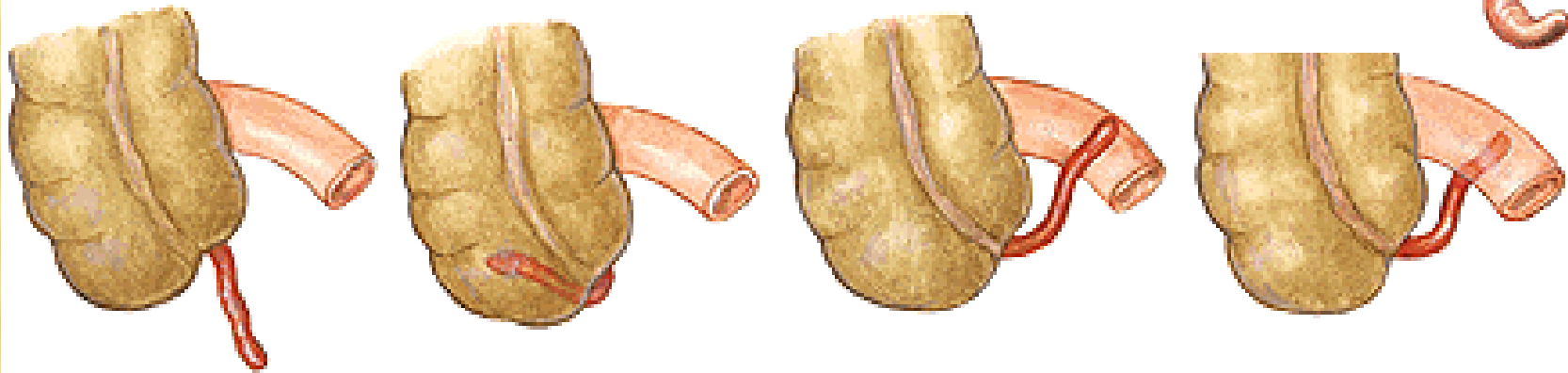
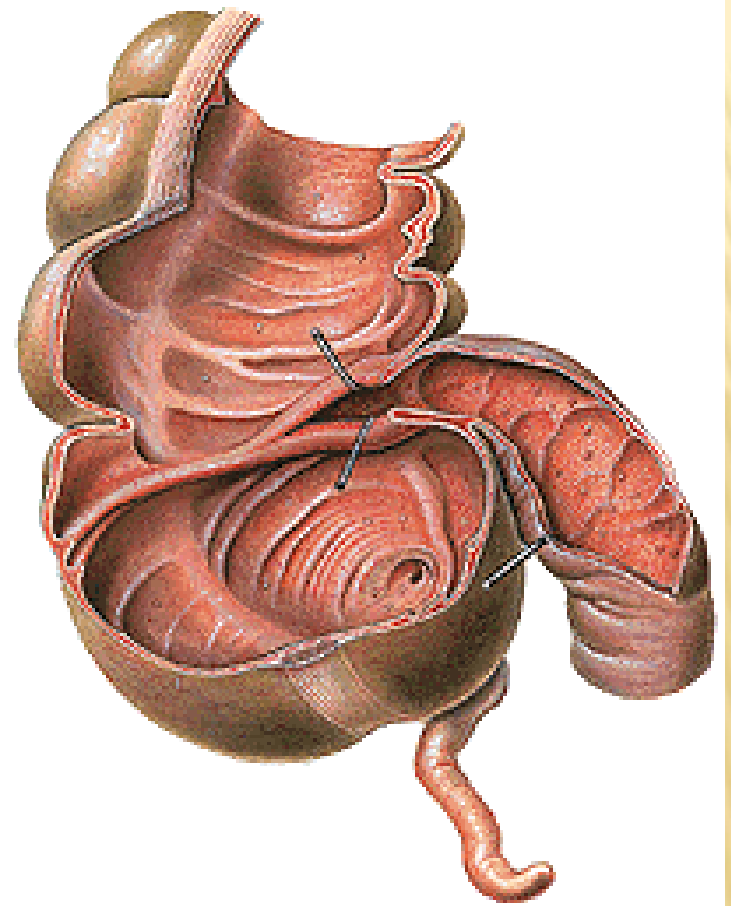
Ostium appendicis vermiformis

Positio pelvina

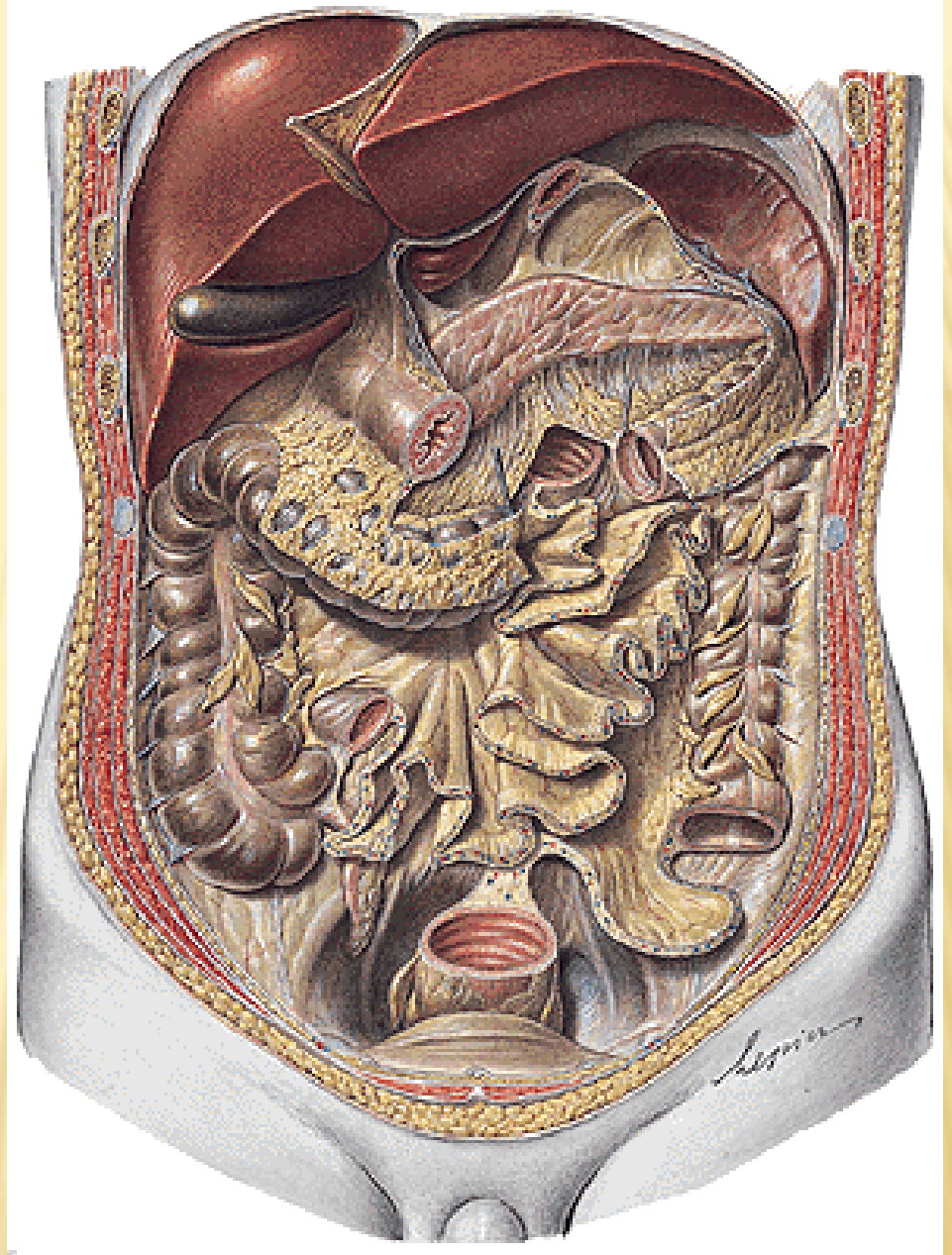
Positio retrocaecalis

Positio ileocaecalis

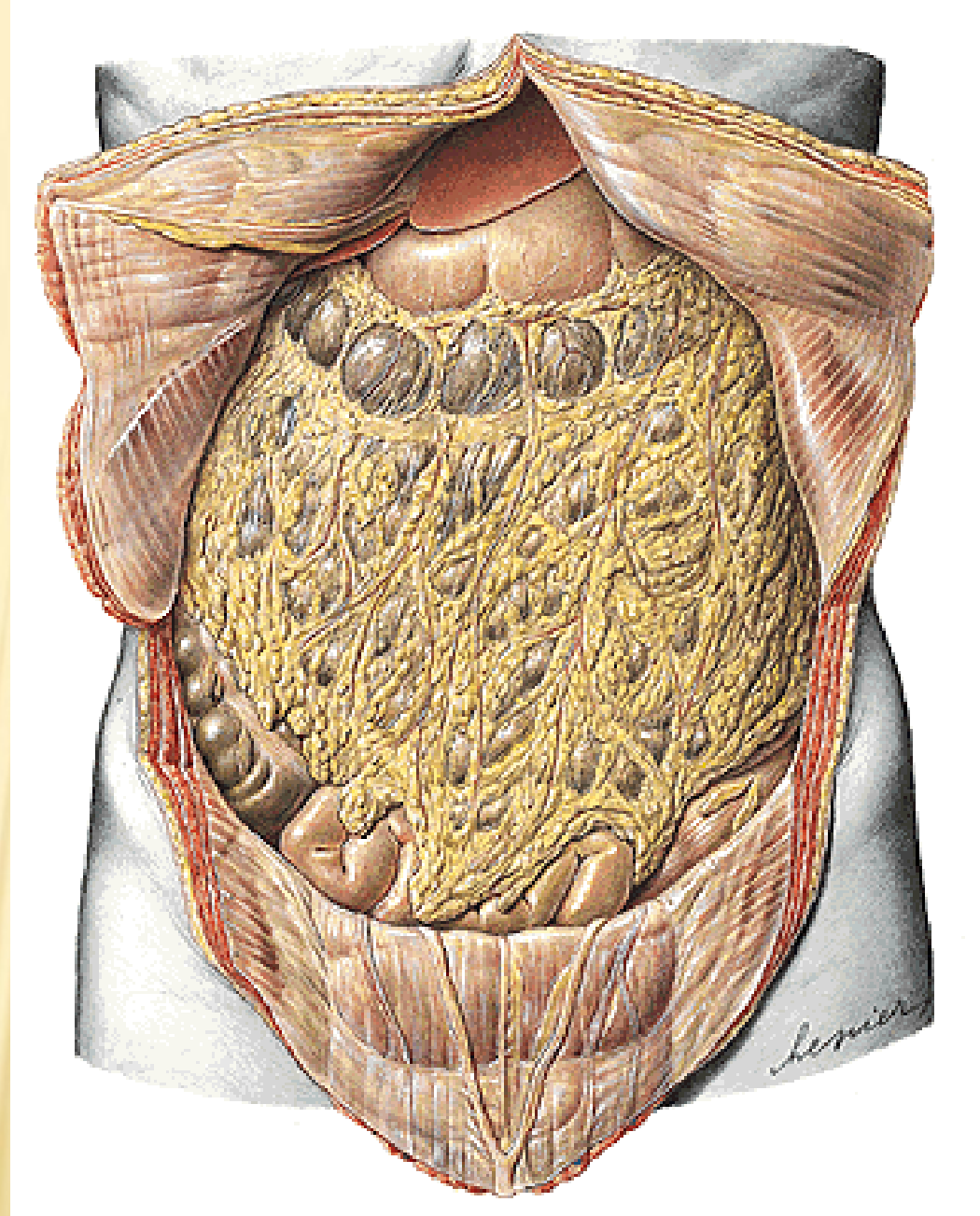
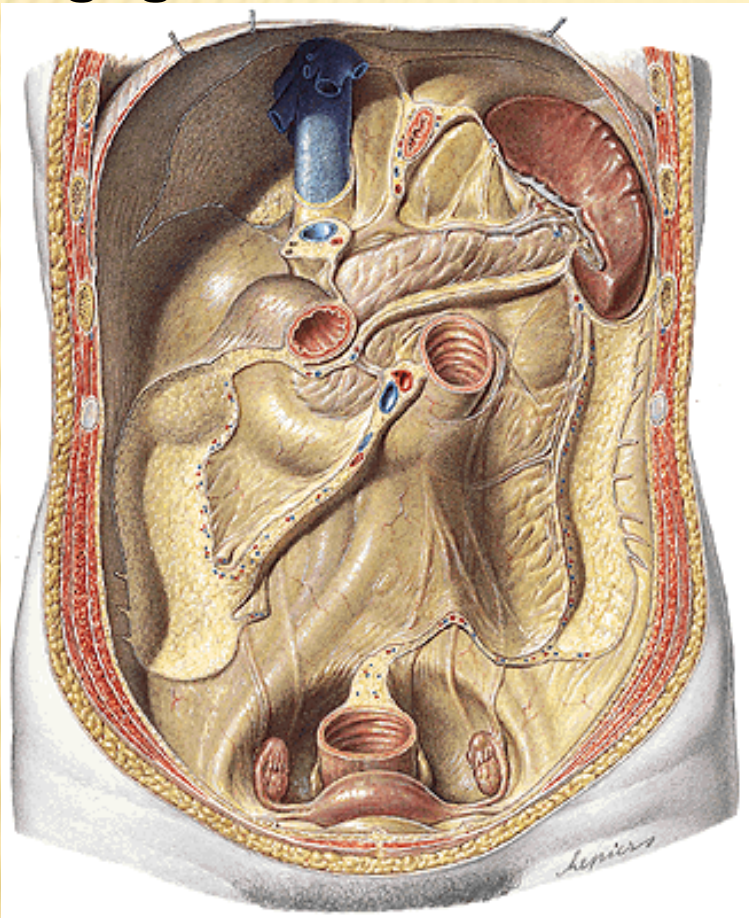
Positio retroilealis



COLON ASCENDENS
Flexura coli dextra
(hepatica)

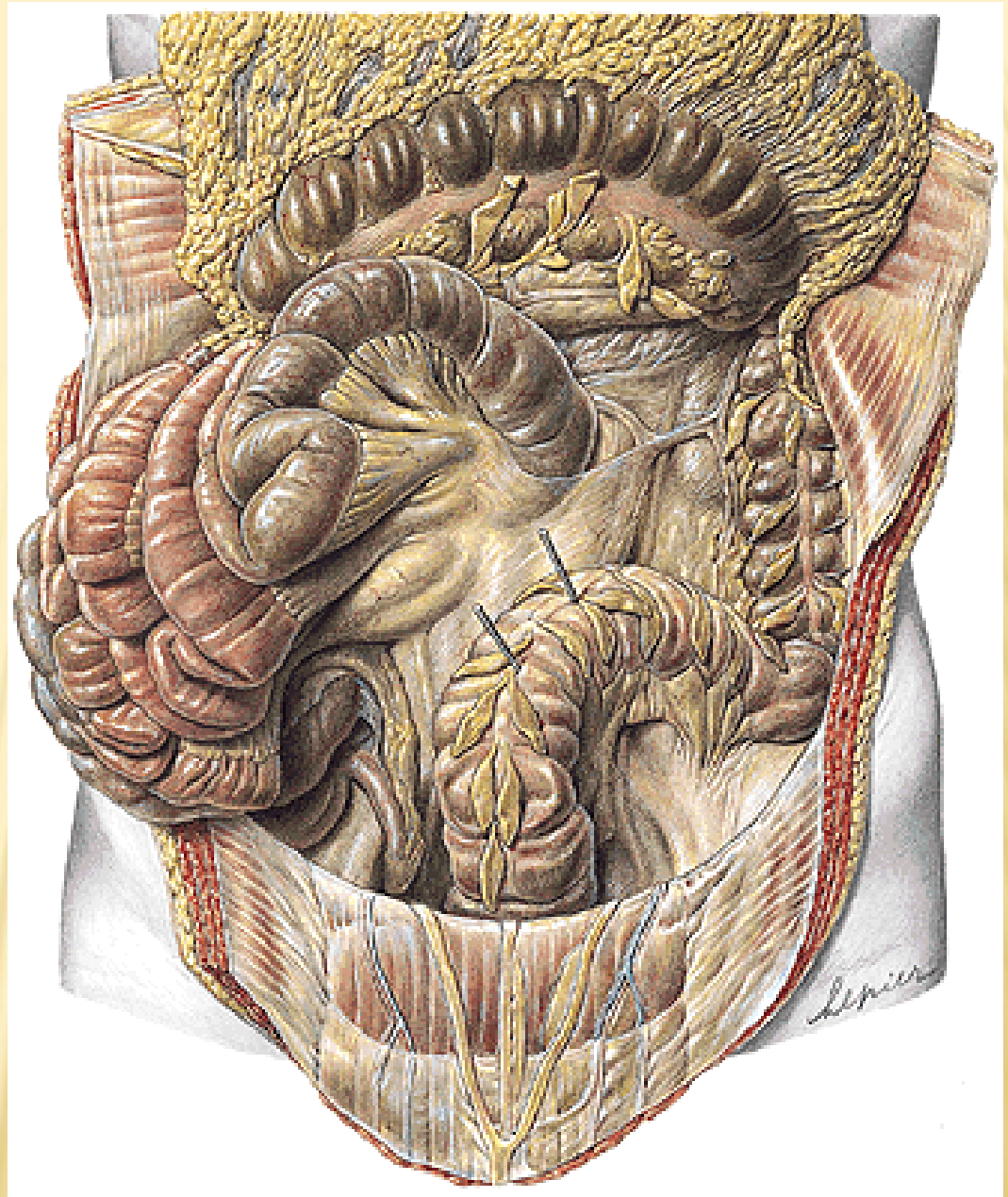


COLON TRANSVERSUM
Mesocolon transversum
Omentum majus
Lig. gastrocolicum

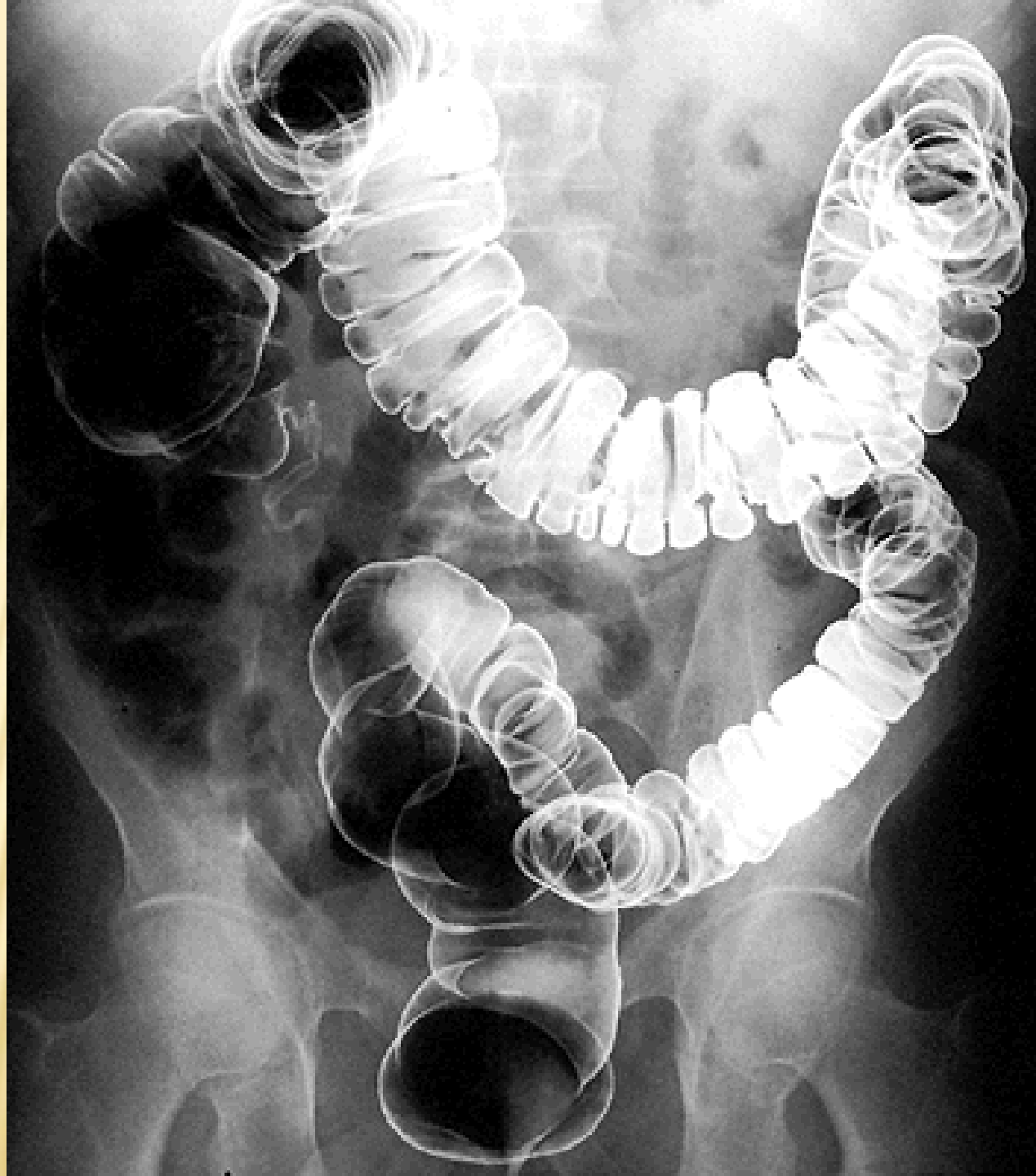

**Flexura coli sinistra
(lienalis)**

**COLON DESCENDENS
COLON SIGMOIDEUM
Mesosigmoideum**



Irigography



RECTUM

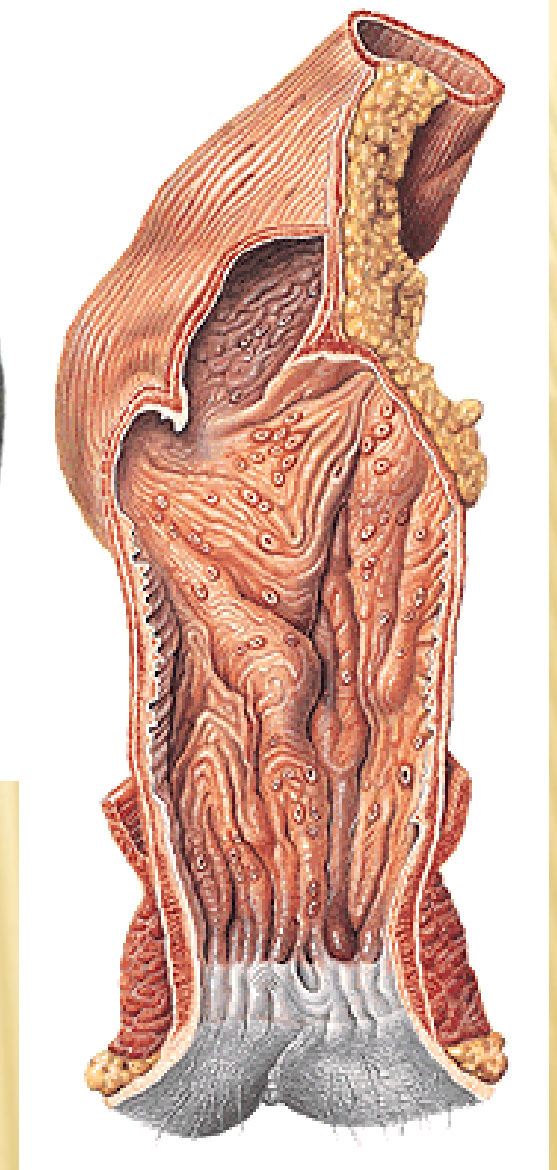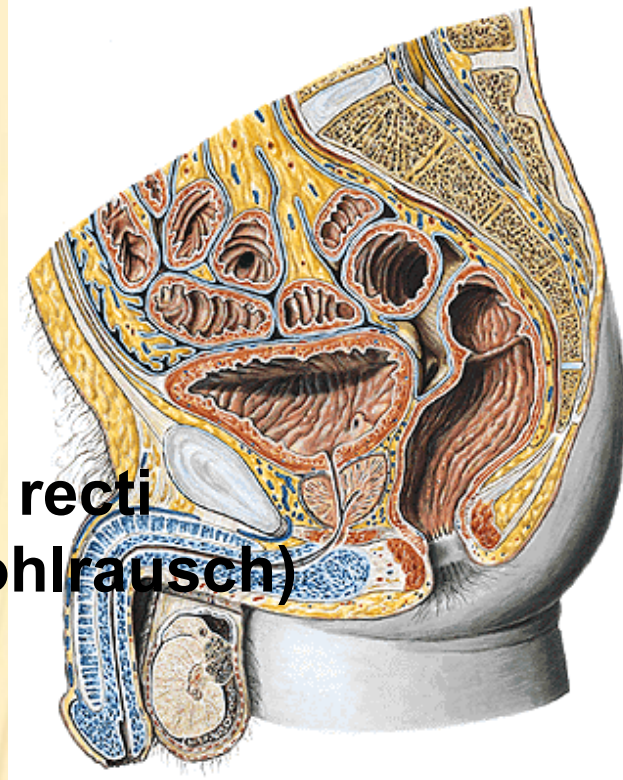Crena ani – anus

Ampulla recti

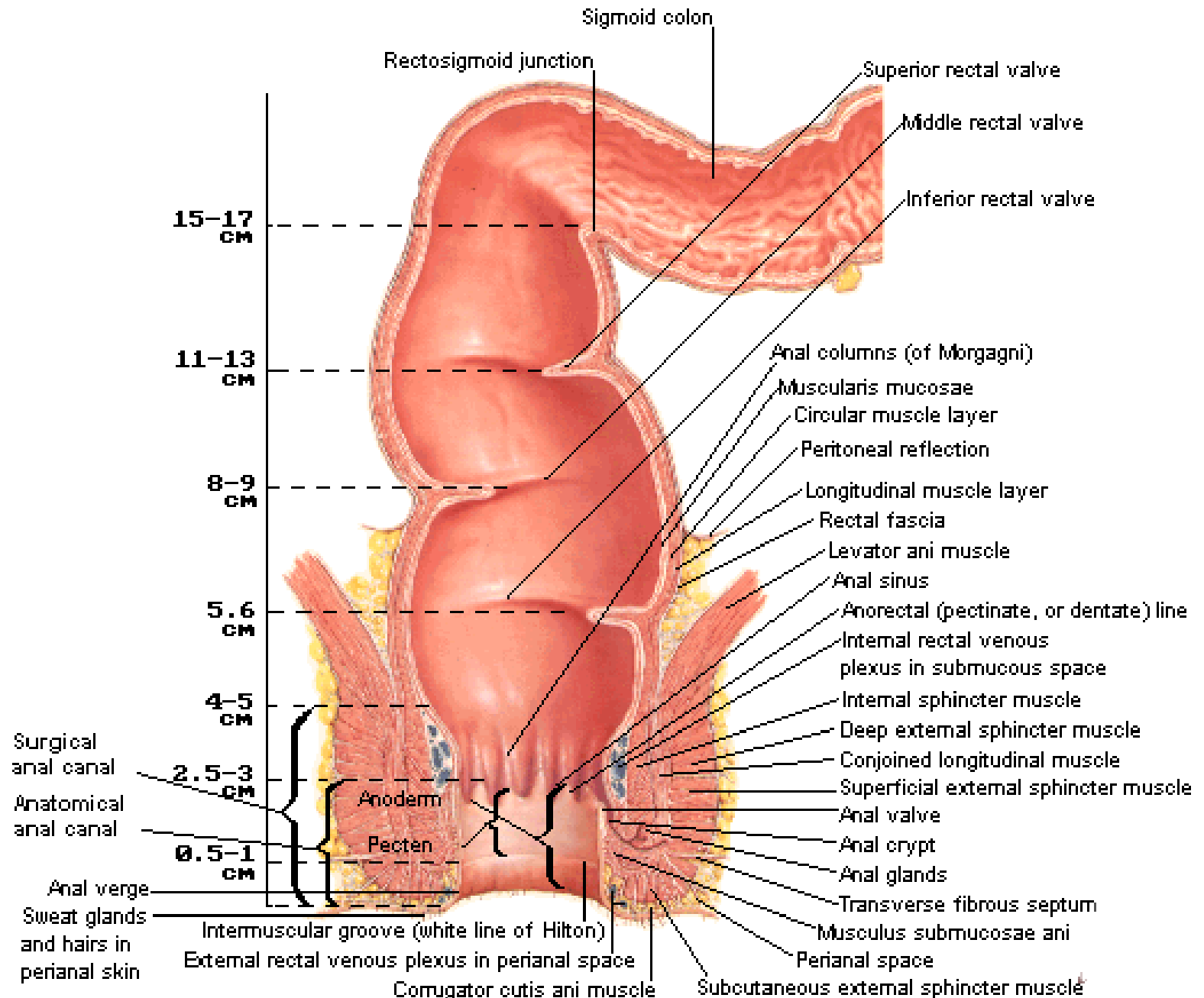
- flexura sacralis
- plicae transversae recti
- plica t.r. media (Kohlrausch)

Canalis analis

- flexura perinealis
- columnae anales
- sinus anales
- valvulae anales
- pecten analis
- linea anocutanea
- zona haemorrhoidalis



Rectum and Anal Canal



Illustrations, photographs, and radiographs were copied from:
Atlas der Anatomie des Menschen/Sobotta.
Putz,R., und Pabst,R. 20. Auflage. München:
Urban & Schwarzenberg, 1993)
Netter: Interactive Atlas of Human Anatomy.
Windows Version 2.0



EAT RIGHT