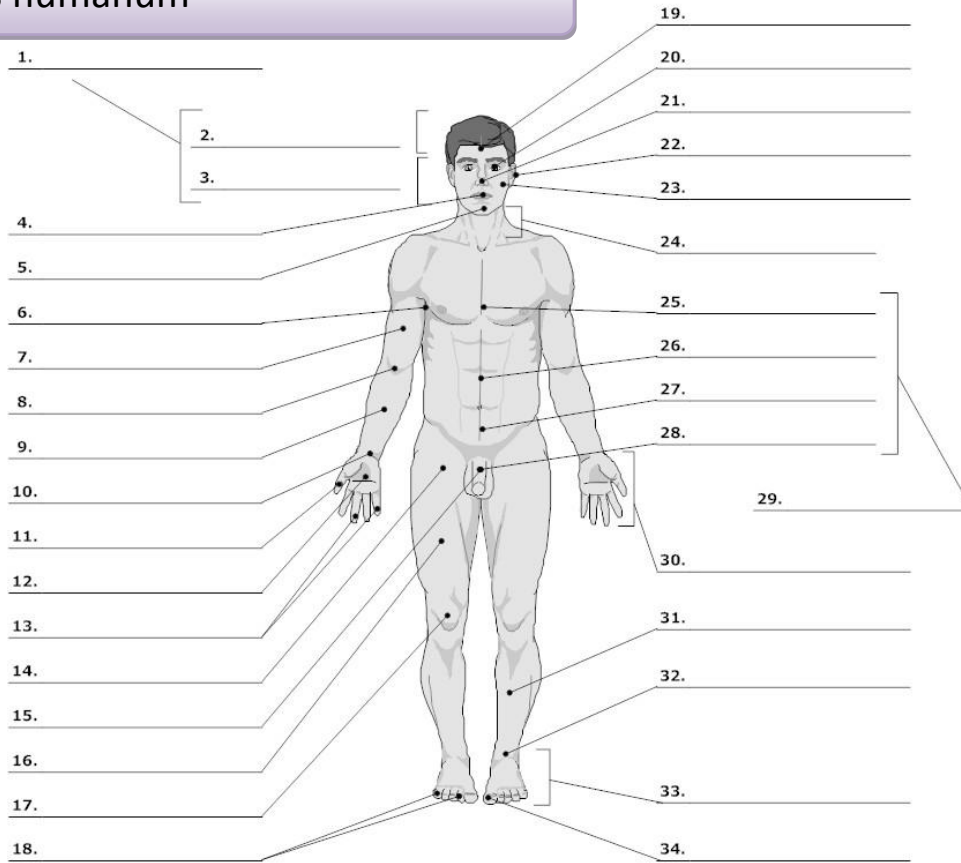


**PART I : EXERCISES/VOCABULARY**

**Corpus humanum**

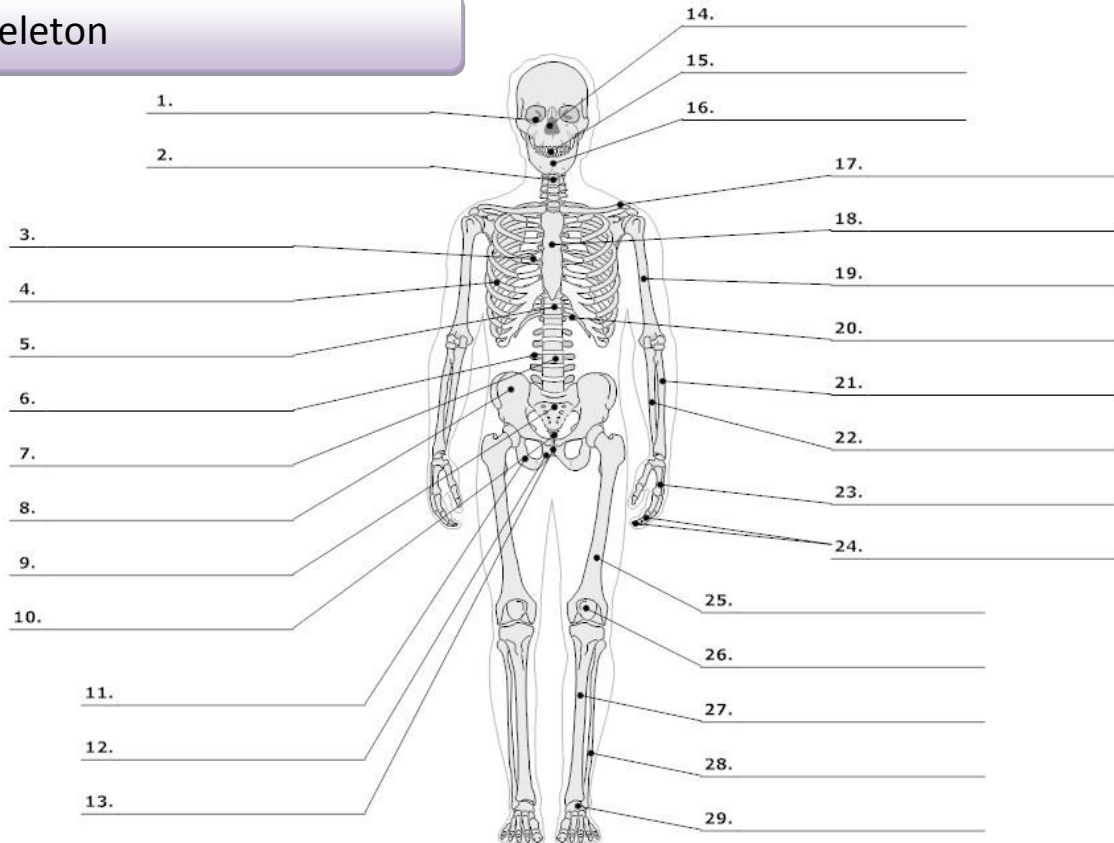


LIFEART Collection Images Copyright © 1999-2001. By Lippincott Williams & Wilkins, Baltimore, MD

- |  |                     |   |  |
|--|---------------------|---|--|
| 0. <b>corpus, oris, n.</b><br><b>cutis, is, f.</b> | body<br>skin        | 16. <b>femur, oris, n.</b>                          | thigh, femur   |
| 1. <b>caput, itis, n.</b>                          | head                | 17. <b>genu, us, n.</b>                             | knee   |
| 2. <b>capilli, orum, m.</b>                        | hair                | 19. <b>frons, frontis, f.</b>                       | forehead   |
| 3. <b>facies, ei, f.</b>                           | face                | 20. <b>oculus, i, m.</b>                            | eye  |
| 4. <b>os, oris, n.</b><br><b>lingua, ae, f.</b>    | mouth<br>tongue     | 21. <b>nasus, i, m.</b>                             | nose   |
| 5. <b>mentum, i, n.</b>                            | chin                | 22. <b>auris, is, f.</b>                            | ear  |
| 6. <b>axilla, ae, f.</b>                           | armpit, axilla      | 23. <b>bucca, ae, f.</b>                            | cheek  |
| 7. <b>brachium, ii, n.</b>                         | upper arm, brachium | 24. <b>collum, i, n.</b><br><b>cervix, icis, f.</b> | neck (mainly on bones)<br>neck, cervix (mainly on soft parts/organs) |
| 8. <b>cubitus, i, m.</b>                           | elbow               | 25. <b>pectus, oris, n.</b>                         | chest  |
| 9. <b>antebrachium, ii, n.</b>                     | forearm             | 26. <b>abdomen, inis, n.</b>                        | belly, abdomen   |
| 10. <b>carpus, i, m.</b>                           | wrist               | 27. <b>hypogastrium, ii, n.</b>                     | hypogastrium   |
| 11. <b>pollex, icis, m.</b>                        | thumb               | 29. <b>truncus, i, m.</b>                           | trunk  |
| 12. <b>palma, ae, f.</b>                           | palm (of the hand)  | 30. <b>manus, us, f.</b>                            | hand   |
| 13.,18. <b>digitus, i, m.</b>                      | finger              | 31. <b>crus, cruris, n.</b>                         | lower leg, shank   |
| 14. <b>sulcus, i, m.</b> <sup>1</sup>              | fold, groove        | 32. <b>tarsus, i, m.</b><br><b>talus, i, m.</b>     | tarsus<br>anklebone, talus   |
| 15.,28. <b>penis, is m.</b>                        | penis               | 33. <b>pes, pedis, m.</b>                           | foot   |
|  |                     | 34. <b>hallux, ucis, m.</b>                         | big toe  |

<sup>1</sup> sulcus glutealis

**Skeleton**



LifeART Collection Images Copyright © 1989-2001 by Lippincott Williams & Wilkins, Baltimore, MD

0.	<b>skeleton, i, n.</b>	skeleton	<b>scapula, ae, f.</b>	shoulder blade, scapula
	<b>os, ossis, n.</b>	bone	18. <b>sternum, i, n.</b>	breastbone, sternum
	<b>cranium, ii, n.</b>	skull	19. <b>humerus, i, m.</b>	arm bone, humerus
1.	<b>orbita, ae, f.</b>	orbit	20. <b>arcus, us, m.<sup>2</sup></b>	arch
2.	<b>collum, i, n.</b>	neck (mainly on bones)	21. <b>radius, ii, m.</b>	radial bone, radius
	<b>cervix, icis, f.</b>	neck, cervix (mainly on soft parts/organs)	22. <b>ulna, ae, f.</b>	elbow bone
3.	<b>thorax, acis, m.</b>	thorax (chest with ribs)	23. <b>metacarpus, i, m.</b>	metacarpus
4.	<b>costa, ae, f.</b>	rib		wrist
5.	<b>discus, i, m.</b>	disc	24. <b>phalanx, gis, f.</b>	one of the finger bones, phalange
6.	<b>processus, us, m.</b>	process (an outgrowth of tissue)	25. <b>femur, oris, n.</b>	thighbone, femur
7.	<b>vertebra, ae, f.</b>	vertebra	26. <b>patella, ae, f.</b>	kneecap, patella
8.	<b>pelvis, is, f.</b>	pelvis	27. <b>tibia, ae, f.</b>	shinbone, tibia
	<b>coxa, ae, f.</b>	hip, hip joint	28. <b>fibula, ae, f.</b>	calf bone, fibula
	<b>os ilii (ilia, ilium, n.)</b>	ilium	29. <b>metatarsus, i, m.</b>	metatarsus
9.	<b>os sacrum (sacer, a, um)</b>	sacral bone		
10.	<b>coccyx, gis, f.</b>	tailbone, coccyx		
11.	<b>os ischii (ischium, ii, n.)</b>	ischium		
12.	<b>os pubis (pubes, is, f.)</b>	pubis		
13.	<b>symphysis, is, f.</b>	symphysis		
14.	<b>nasus, i, m.</b>	nose		
15.	<b>dens, dentis, m.</b>	tooth		
16.	<b>mandibula, ae, f.</b>	jawbone		
17.	<b>clavicula, ae, f.</b>	collarbone, clavicle		

<sup>2</sup> arcus costalis

