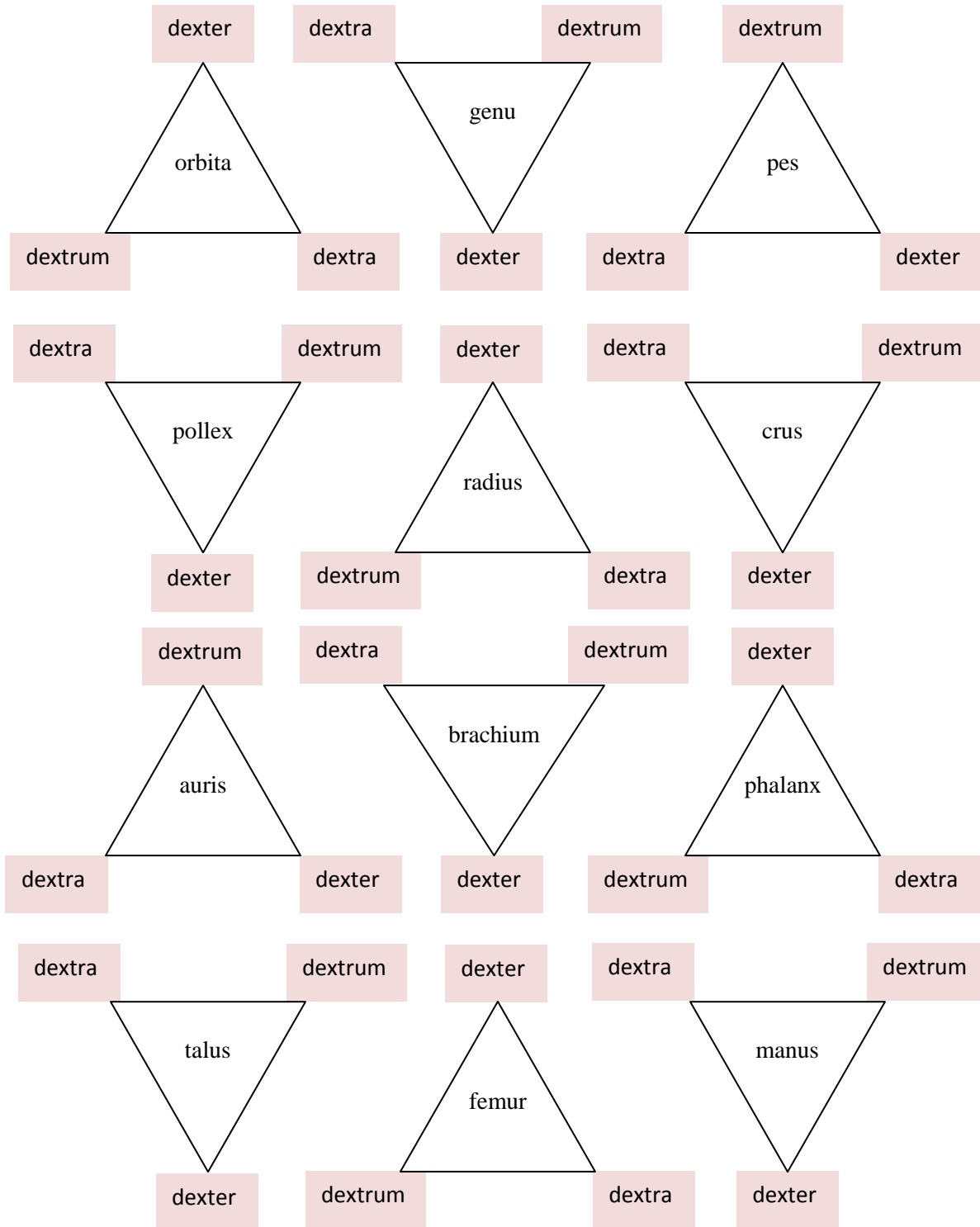


1. Decide what the correct adjective form for the given noun is:



2. Connect the noun with different adjectives in the correct form, translate the phrases:

A

arteria + thoracicus, a, um; iliacus, a, um; uterinus, a, um;

apertura + internus, a, um; externus, a, um; medianus, a, um

rhaphe + medianus, a, um; palatinus, a, um

crista + iliacus, a, um; palatinus, a, um; transversus, a, um

linea + obliquus, a, um; medianus, a, um; transversus, a, um

B

diabetes + mellitus, a, um; secundarius, a, um

diarrhoe + albus, a, um; epidemicus, a, um

therapia + chirurgicus, a, um; complicatus, a, um

fractura + complicatus, a, um; apertus, a, um; clausus, a, um; obliquus, a, um; secundus, a, um; transversus, a, um

3. Connect the phrases from part A of the previous exercise with the preposition. Use both with accusative and ablative.

in + *arteria* + thoracicus, a, um; iliacus, a, um; uterinus, a, um

in + *crista* + iliacus, a, um; palatinus, a, um; transversus, a, um

in + *fascia* + latus, a, um; profundus, a, um; iliacus, a, um

B

Connect the phrases from part B of the previous exercise with the preposition.

propter + *diabetes* + mellitus, a, um; secundarius, a, um

propter + *diarrhoe* + albus, a, um; epidemicus, a, um

propter + *hernia* + obliquus, a, um (=externus, a, um); liber, libera, liberum;
postoperativus, a, um

4. Count ribs and vertebrae:

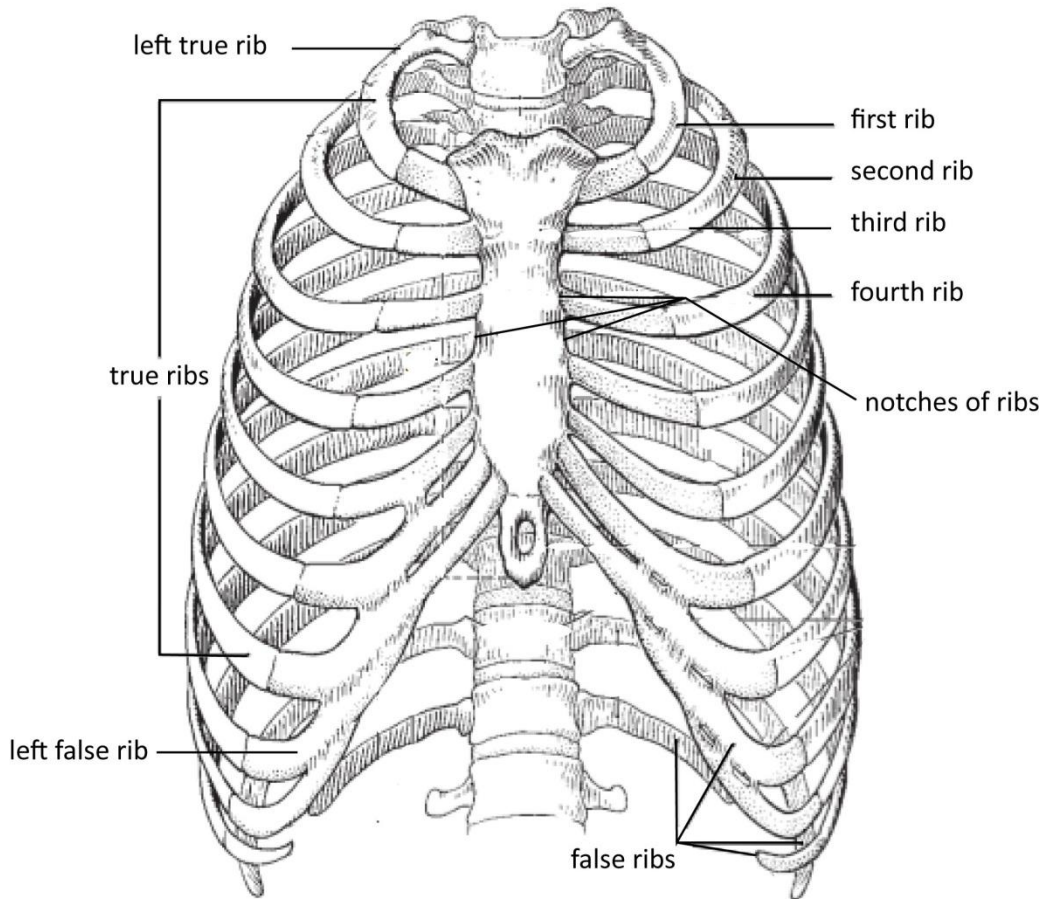
- the first false rib _____
- the second thoracic vertebra _____
- the third right true rib _____
- the fourth coccygeal vertebra _____

the fifth left true rib -----

the sixth thoracic vertebra -----

the seventh true rib -----

5. Translate the legends to the image¹:



¹ Image copied, rearranged and adjusted; source: Feneis, H & Dauber, W.: Pocket Atlas of Human Anatomy, Thieme 2000.

6. Translate the phrases:

subcutaneous bursa

subcutaneous bursa of the shinbone

the second false rib

the fracture of the second false rib

gastric gland

gastric glands

mucous membrane of the urinary bladder

mucous membrane of the gall bladder

suture of the tongue

palatal transverse suture

coccygeal vertebra

fracture of coccygeal vertebrae

fracture of the left shinbone and calf bone

open fracture of the left shinbone

therapy of the open fracture of the left
shinbone

fracture of the backbone

complicated fracture of the backbone

internal iliac artery

into the internal iliac artery

deep vein of the tongue

into the deep vein of the tongue

therapy of diabetes

complicated therapy of secondary diabetes

rupture of the left sclera

after systole and before diastole

because of the complicated therapy of

epidemic scarlatina

therapy of epidemical acne

insufficiency of coronary arteries

bottle of distilled water

7. Give opposites:

anaemia congenita	fractura clausa
diarrhoe acuta	fascia interna
celulla parva	costa spuria
costa dextra	linea nigra
lagoena fusca	

8. Form meaningful phrases. Do not change the word order²:

insufficiencia + valvula + aorta

tunica + serosus, a, um + vesica + felleus, a, um

plica + vena + cavus, a, um + sinister, a, um

causa + anaemia + periculosus, a, um

fractura + complicatus, a, um + maxilla

therapia + chirurgicus, a, um + fractura + complicatus, a, um + coxa + sinister, a, um

insufficiencia + glandula + thyroideus, a, um + acquisitus, a, um

² Borrowed and adopted according to Prucklová, R.; Severová, M.: Introduction to Latin and Greek terminology in Medicine, KLP 2012. page 7, task 3.

lamina + proprius, a, um + tunica + mucosus, a, um

venae + medulla + oblongatus, a, um

fractura + columna + vertebrae + complicatus, a, um

post + pneumonia + tuberculosus, a, um

insufficiencia + tuba + auditivus, a, um + congenitus, a, um

PART II : GRAMMATICAL NOTES**LATIN II. DECLENSION**

In the second Latin declension we decline nouns that have³:

Genitive sg. ending	-I
Nominative sg. ending	-US/-ER
Gender	M

NOTE! Nouns ending in **-er** in nom. sg. are quite rare in medical terminology, however, there are many extremely frequent adjectives having this ending (e. g. dexter, sinister, liber...).

Nouns ending in **-er** lose the vowel **-e-** in all other cases (c.f. cancer (nom. sg.) cancr-i (gen. sg.). Adjectives can lose the vowel (dexter – dextri) or keep it (liber – liberi); this change of the stem is always indicated by the genitive ending. This is why the noun cancer is written in the dictionary as follows: cancer, cri, m.

A few words with the same ending are of the feminine gender, remember especially: **methodus**, i, f. method; **periodus**, i, f. period and **diameter**, tri, f. diameter.

In the second Latin declension we also decline nouns that have⁴:

Genitive sg. ending	-I
Nominative sg. ending	-UM
Gender	N

³ For the whole paradigm check the book p.10; or the chart with Latin and Greek declensions paradigm NERVUS.

⁴ For the whole paradigm check the book p.10; or the chart with Latin and Greek declensions paradigm SEPTUM.

PART III : VOCABULARY

accessorius, a, um	accessory	medicamentum, i, n.	remedy, medicament
adultus, a, um	adult	morbis, i, m.	disease
anatomicus, a, um	anatomical	musculus, i, m.	muscle
anomalia, ae, f.	anomaly	neonatus, i, m.	new born child
bronchus, i, m.	bronchus	nervus, i, m.	nerve
bulbus, i, m.	bulb	nodus, i, m.	node
caecus, a, um	blind	nucleus, i, m.	nucleus
calcaneus, i, m.	heel bone, calcaneus	oesophagus, i, m.	gullet, oesophagus
cancer, cri, m.	cancer	organum, i, n.	organ
cardiacus, a, um	cardiac	ostium, ii, n.	orifice, ostium
cerebrum, i, n.	brain	ovarium, ii, n.	ovary
contagiosus, a, um	contagious	palatum, i, n.	palate
crassus, a, um	thick	periodus, i, f.	period
curvatura, ae, f.	curvature, curve	pharyngeus, a, um	pharyngeal
diameter, tri, f.	diameter	pylorus, i, m.	pylorus
dorsum, i, n.	back	radiatus, a, um	radiate, radiating
duodenum, i, n.	duodenum	rectum, i, n.	rectum
durus, a, um	hard, stiff	rectus, a, um	direct, straight
fissura, ae, f.	cleft, fissure	ruber, a, um	red
fundus, i, m.	base, bottom, fundus	septum, i, n.	septum
interosseus, a, um	interosseous	signum, i, n.	sign
intestinum, i, n.	intestine	sympathicus, a, um	sympathetic
jejunum, i, n.	jejunum	truncus, i, m.	1. trunk, torso; 2. stem (of the brain)
ligamentum, i, n.	ligament	tuberculum, i, n.	tubercle
lobus, i, m.	lobe	uterus, i, m.	uterus
longus, a, um	long	vagus, a, um	wandering, vagus
lymphaticus, a, um	lymphatic	ventriculus, i, m.	1. stomach; 2. ventricle
malleolus, i, m.	malleolus		

COLLOCATIONS:

<i>(intestinum) caecum</i>	c(a)ecum
<i>intestinum crassum</i>	large intestine
<i>(intestinum) rectum</i>	rectum