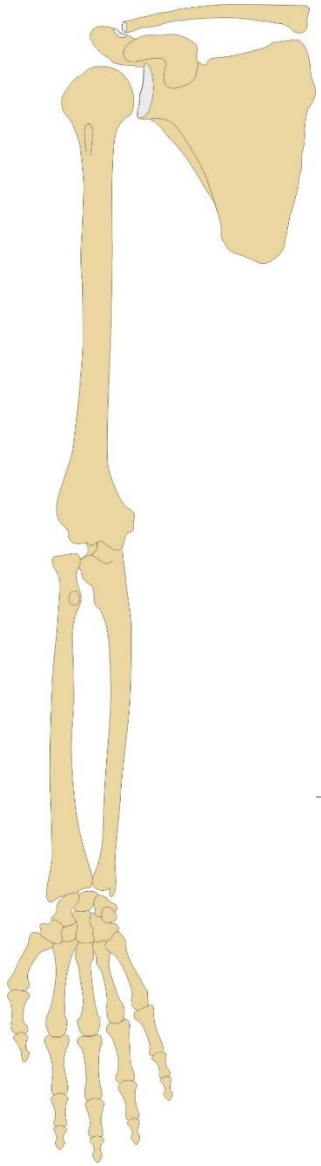

SKELETON OF THE UPPER LIMB

LECTURE 2

DENTISTRY 2015

RNDr. MICHAELA RAČANSKÁ, Ph.D.

Skeleton of the upper limb (*ossa membri superioris*)

Thirty-four bones form the skeletal framework of each upper limb

I. Shoulder girdle (*cingulum membri superioris*)

Collar bone, clavicle – *clavicula*

Shoulder blade – *scapula*

II. Bones of free part of the upper limb (*ossa membri superioris liberi*)

Arm bone – *humerus*

Radius – *radius*

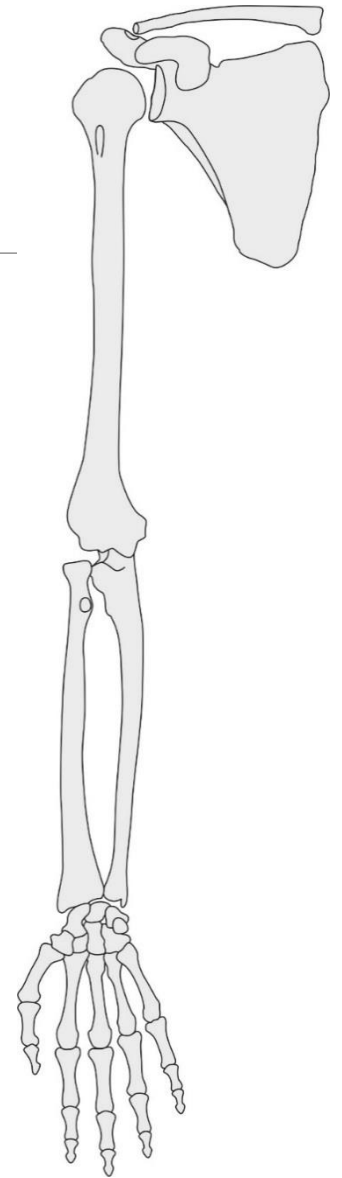
Ulna – *ulna*

Carpal bones – *ossa carpi* 8

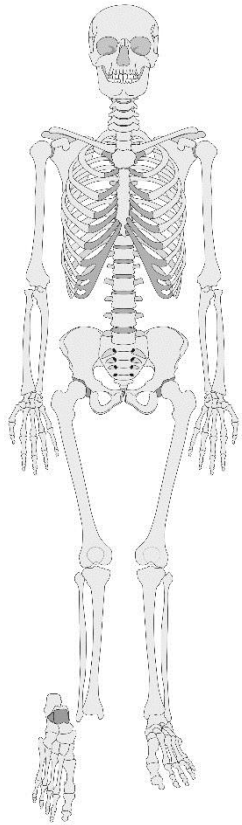
Metacarpal bones – *ossa metacarpi* 5

Phalanges, hand digits – *ossa digitorum manus* 14

Sesamoid - 2



Clavicula (collar bone)

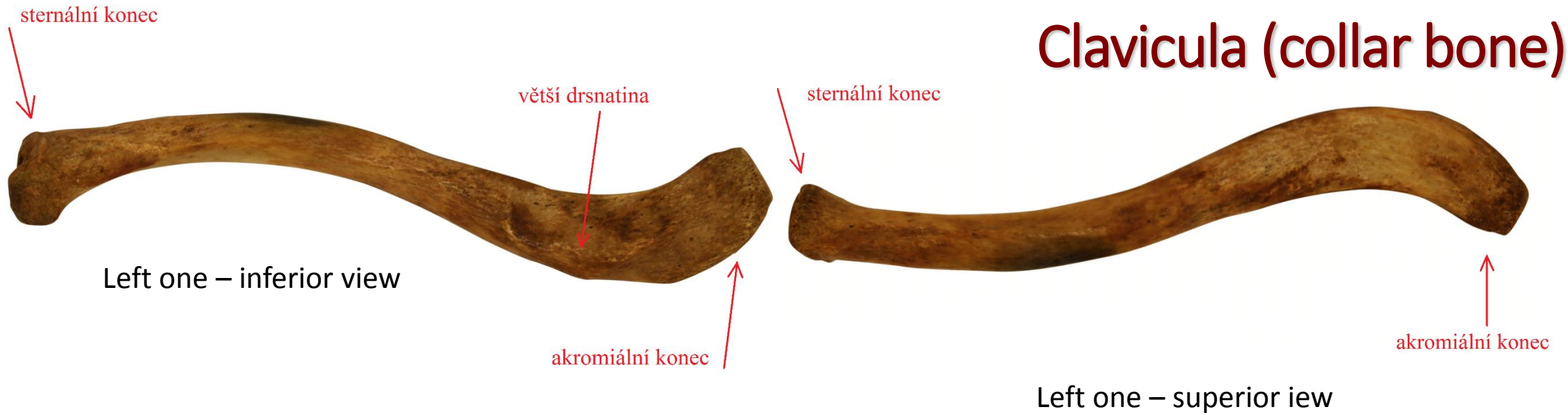


Connects upper limb with the trunk

Connection with the shoulder blade

Connection with the breast bone

Clavicula (collar bone)



Medial end (sternal end)

extremitas sternalis - sternal articular facet (*facies articularis sternalis*)

Costal tuberosity - *tuberositas costalis* (impression for costoclavicular ligament - *impressio ligamenti costoclavicularis*)

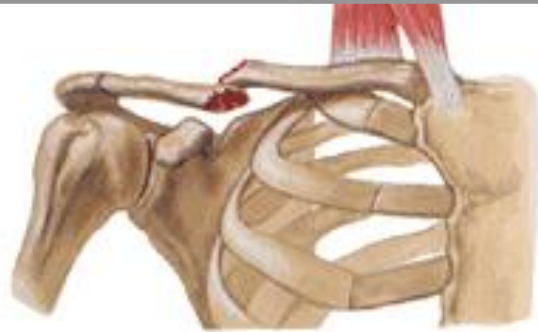Lateral (acromial) end

extremitas acromialis (*facies articularis acromialis*)

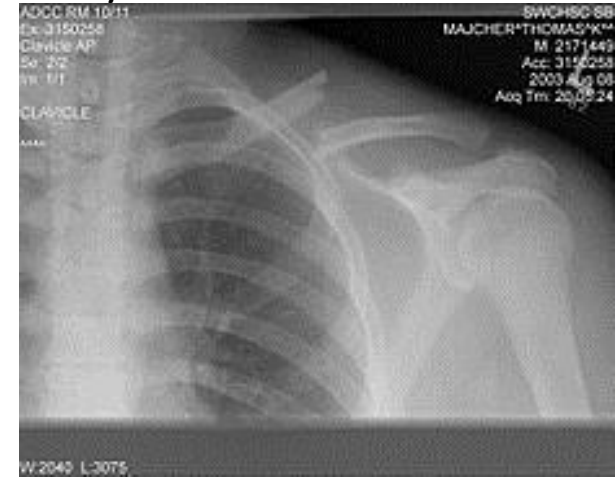tuberositas coracoidea (conoid tubercle - *tuberculum conoideum* + trapezoid line - *linea trapezoidea*)

Side orientation

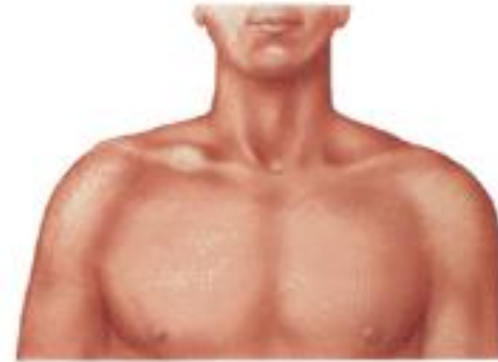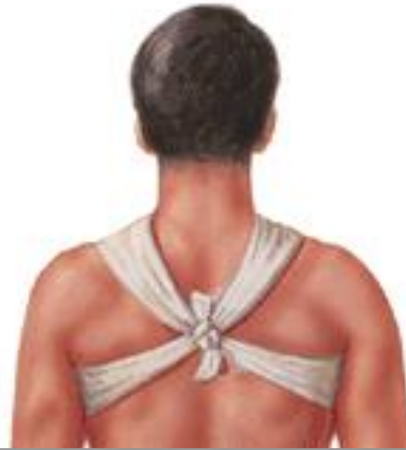Fracture of the collar bone

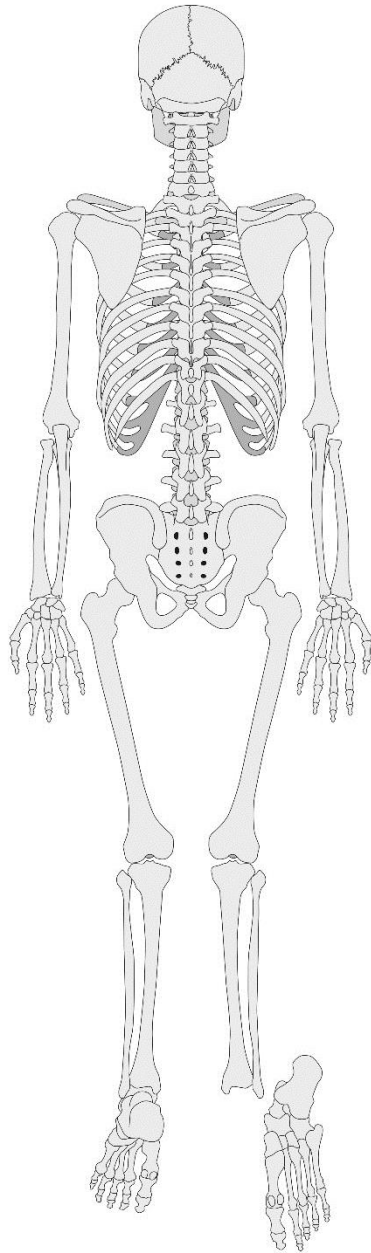


X-ray of a left clavicle fracture



https://en.wikipedia.org/wiki/Clavicle_fracture





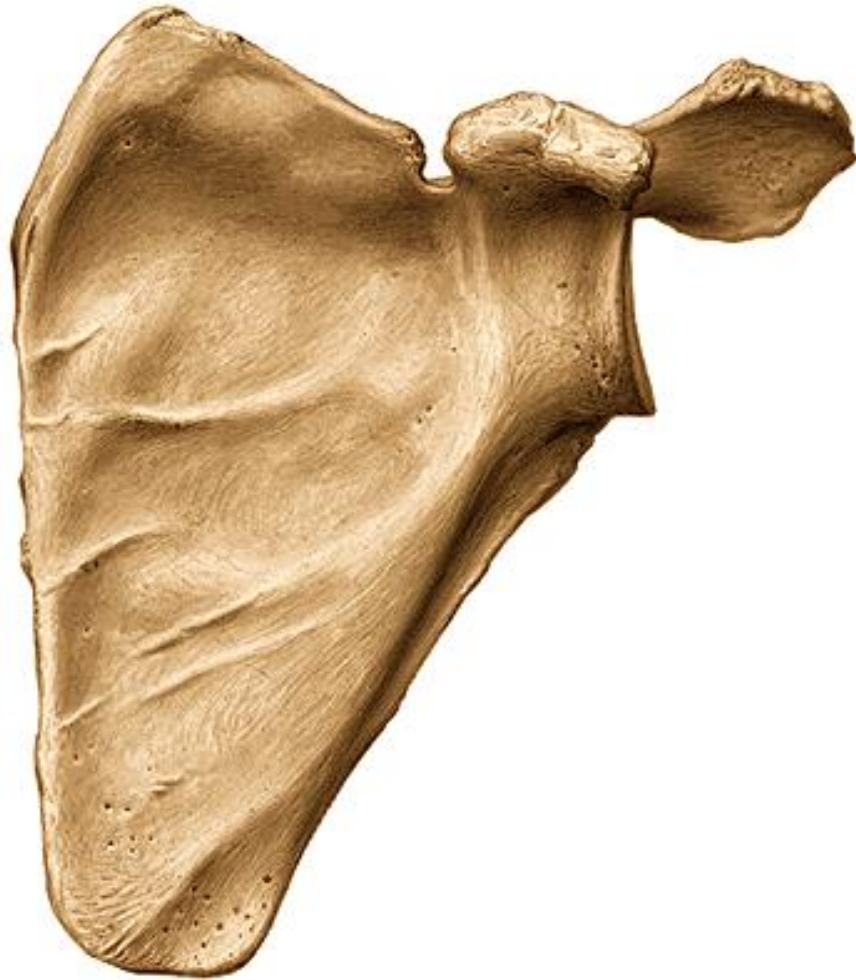Scapula

Margo: superior
medialis
lateralis

angulus: superior
inferior
lateralis

facies: costalis
dorsalis

Facies costalis scapulae



Lineae musculares (transversae)

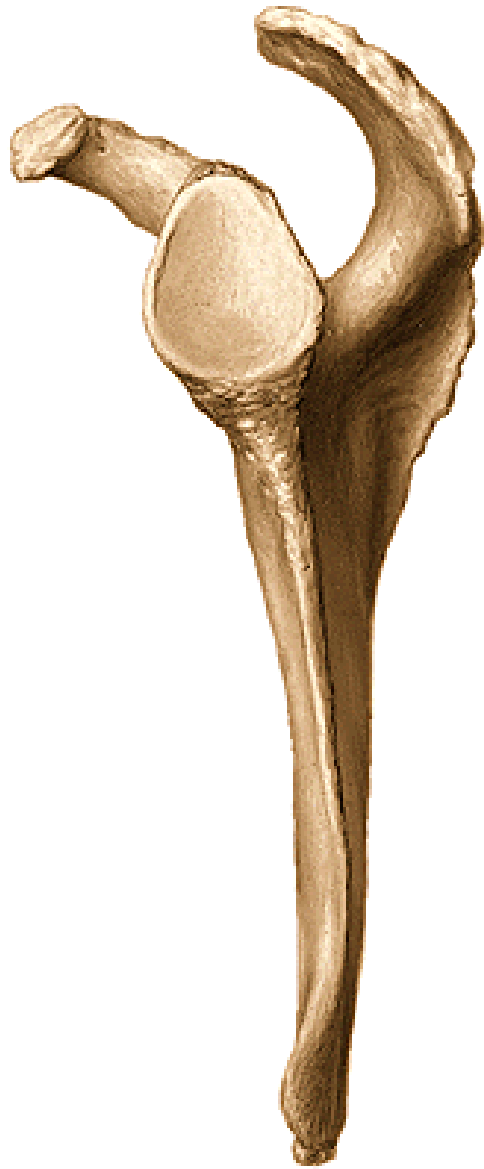Fossa subscapularis

Incisura scapulae
(ligamentum transversum scapulae)

Processus coracoideus

Collum scapulae

Cavitas glenoidalis



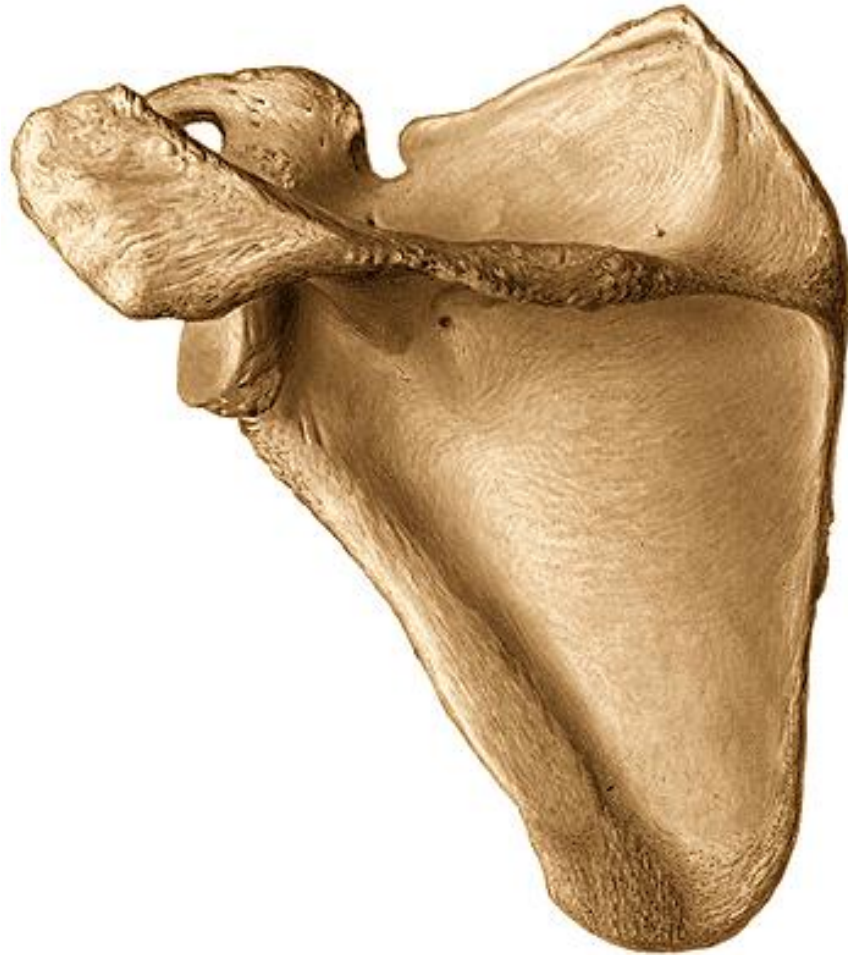cavitas glenoidalis

tuberculum supraglenoidale
(musculus biceps brachii)

tuberculum infraglenoidale
(musculus triceps brachii)

collum scapulae

Facies dorsalis scapulae



spina scapulae

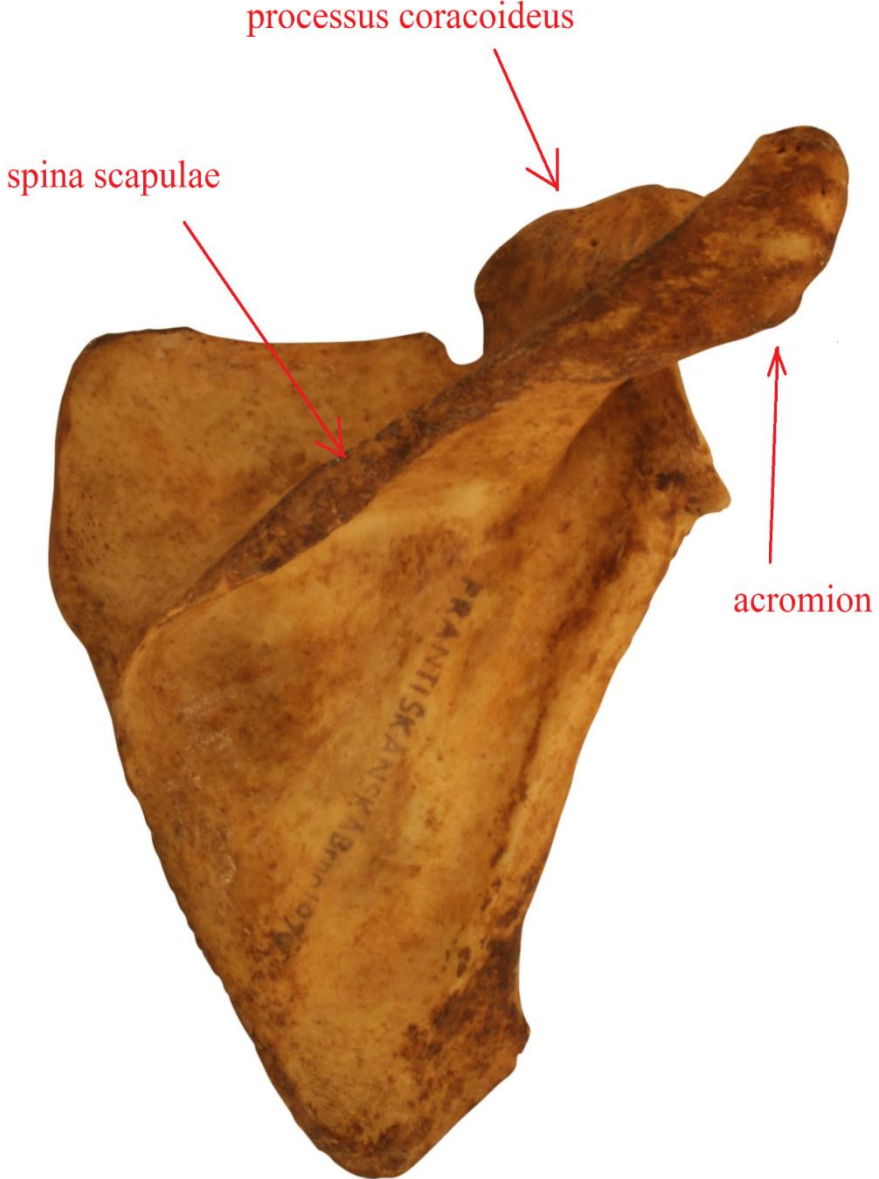
acromion

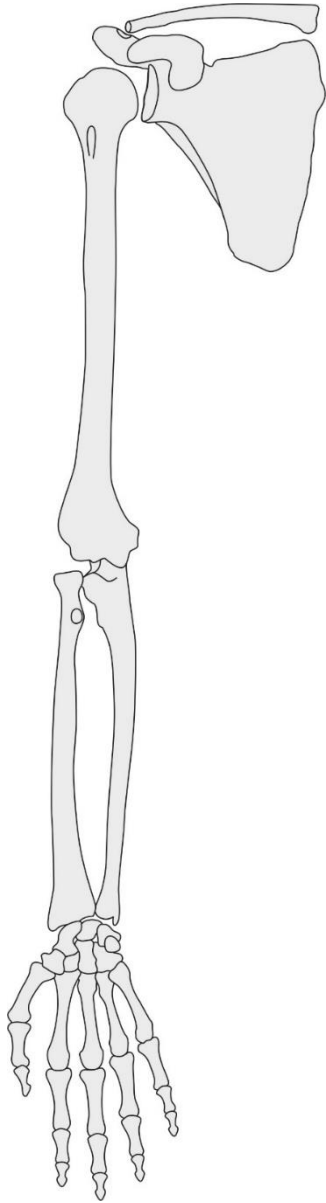
facies articularis acromii

fossa suprascapularis

fossa infrascapularis

Side orientation





Humerus (arm bone)

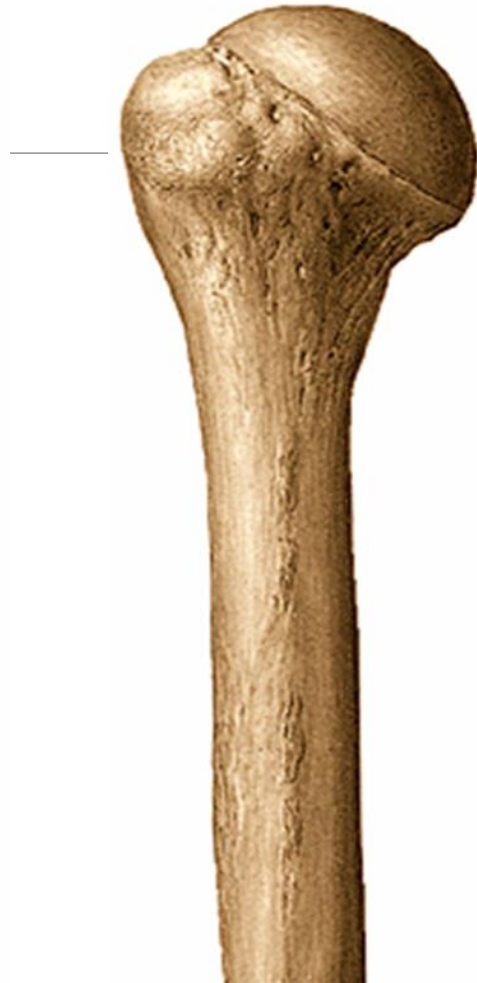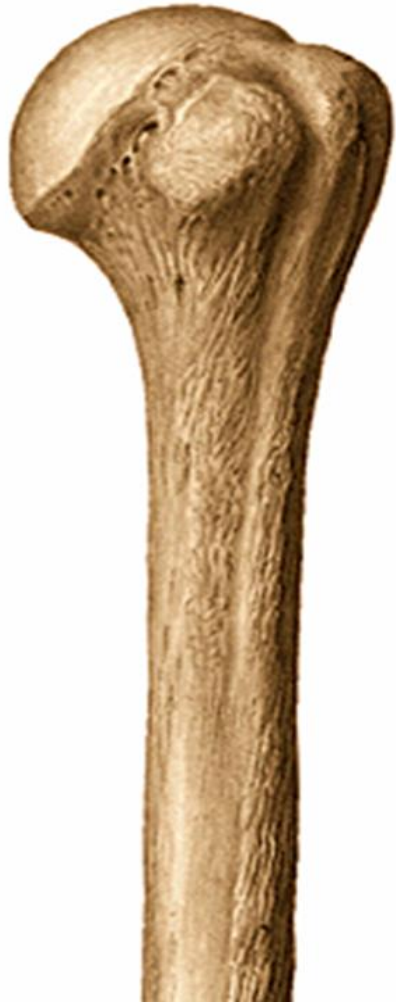Connects shoulder blade and forearm bones

Proximal end

Body

Distal end

Humerus



Proximal end:

caput humeri

collum anatomicum

tuberculum majus

tuberculum minus

crista tuberculi majoris et minoris

sulcus intertubercularis

collum chirurgicum

Humerus

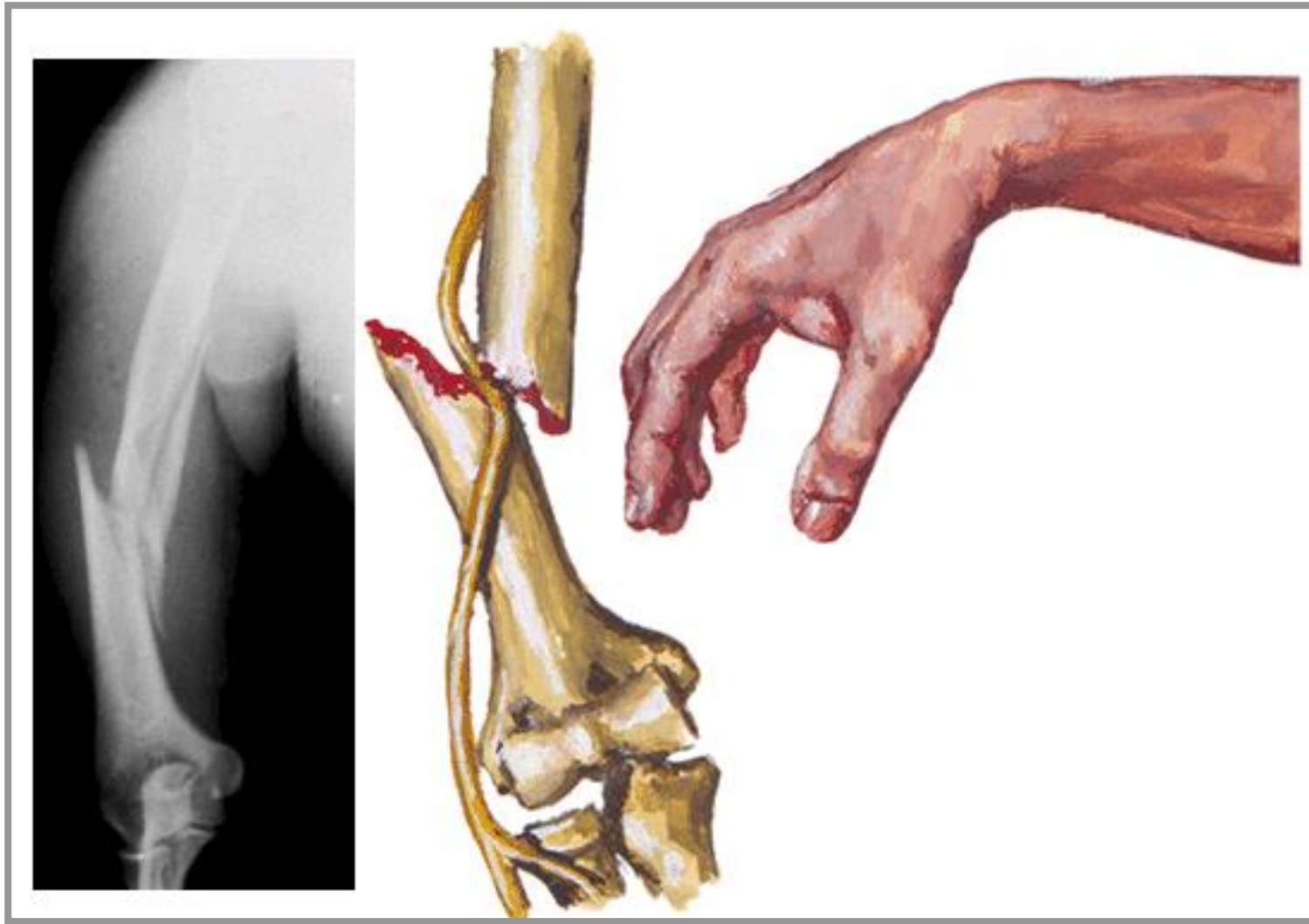


corpus - body

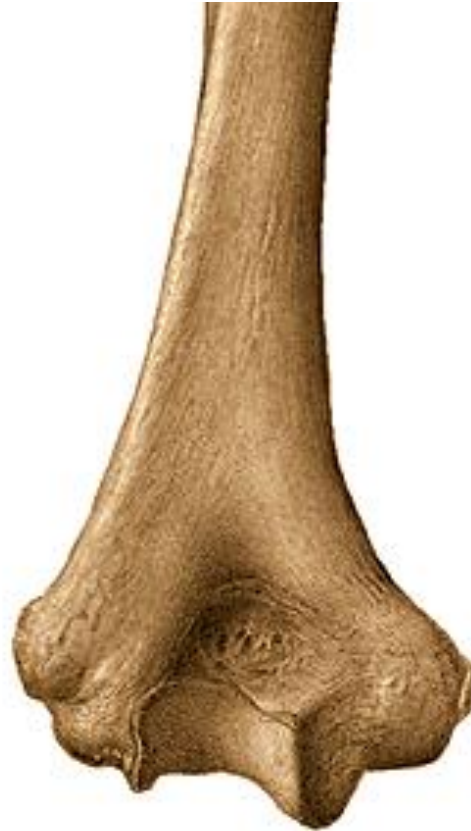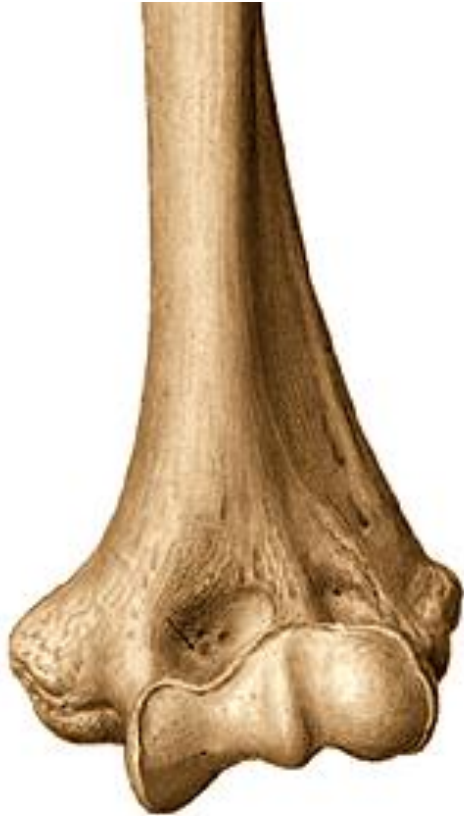tuberositas deltoidea

sulcus nervi radialis
(nervus radialis)

Fracture of the midshaft of the humerus (entrapment of radial nerve)



Humerus



Distal end:

epicondylus medialis

sulcus nervi ulnaris

epicondylus lateralis

trochlea humeri

fossa coronoidea

capitulum humeri

fossa radialis

fossa olecrani

Side orientation



Radius

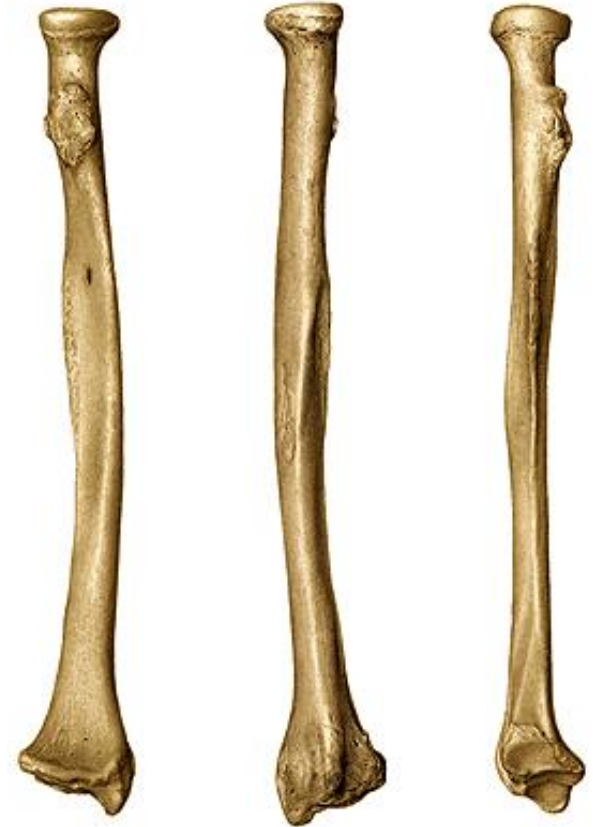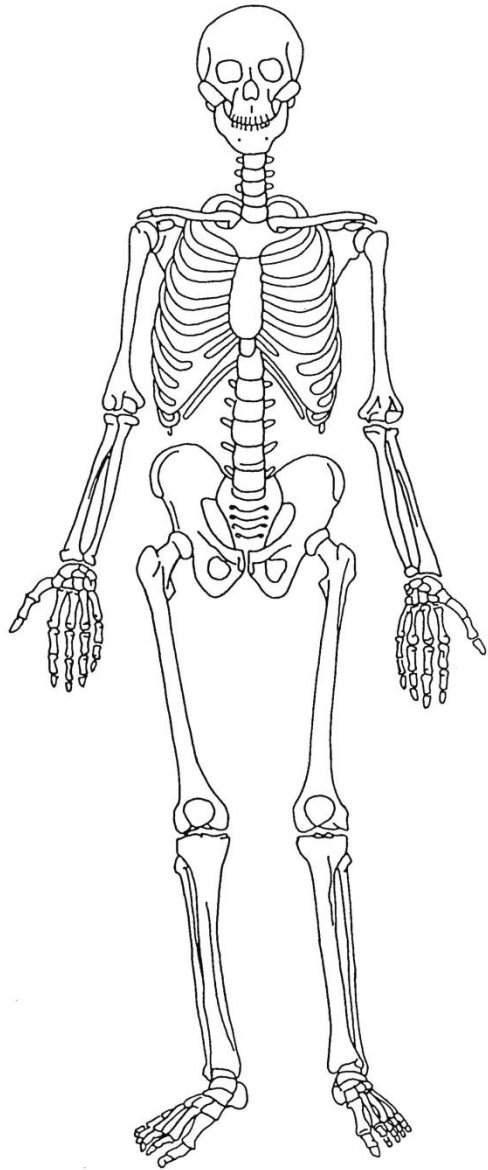
Forarm (lateral side)

Connects with humerus, ulna and carpal bones



Proximal end

Body

Distal end



Radius



Proximal end:

caput radii

fovea capitis radii

circumferentia articularis capitis radii

collum radii

Body:

tuberositas radii

margo interosseus

Radius

Distal end:



processus styloideus radii

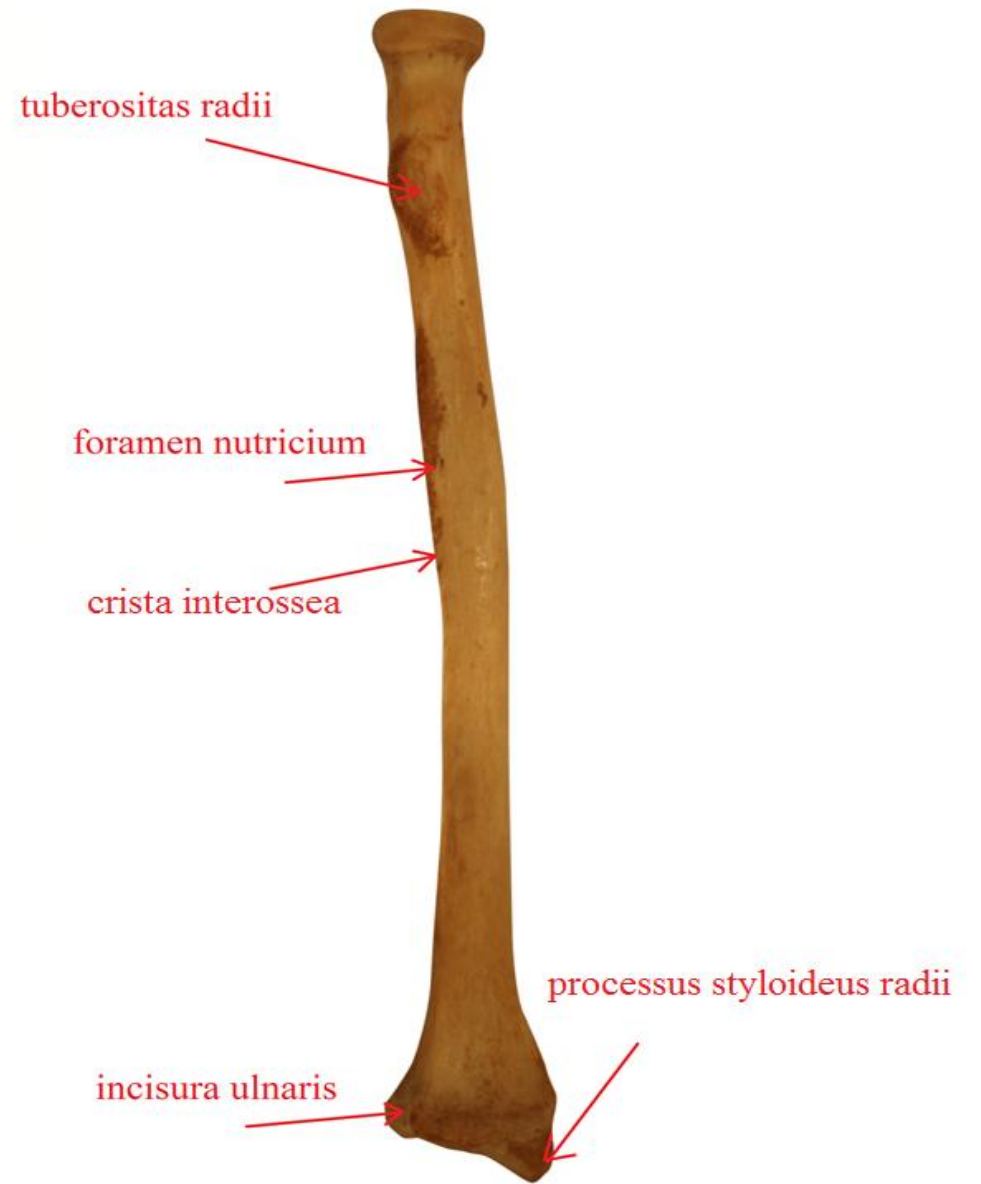
facies articularis carpea radii

incisura ulnaris radii

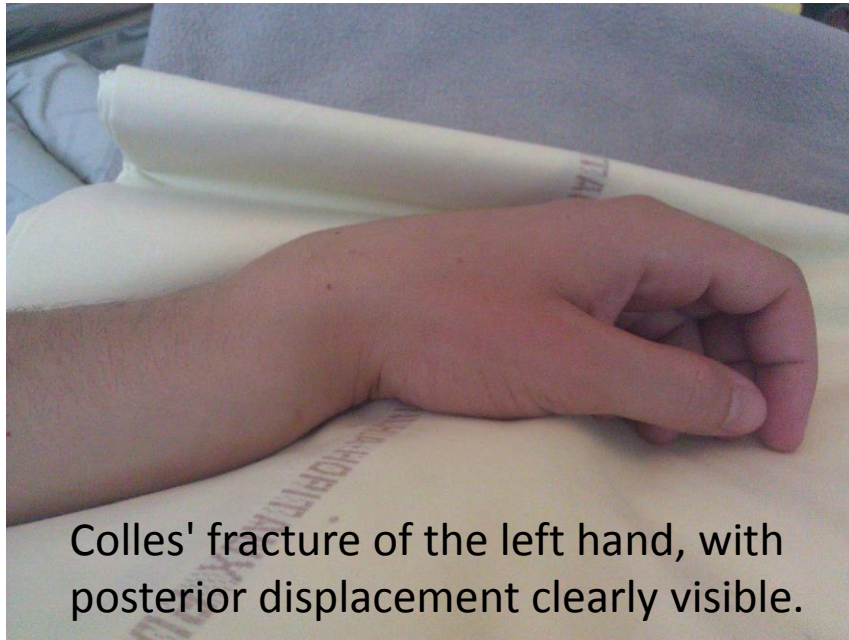Dorsal side – grooves for extensors tendons

Side orientation

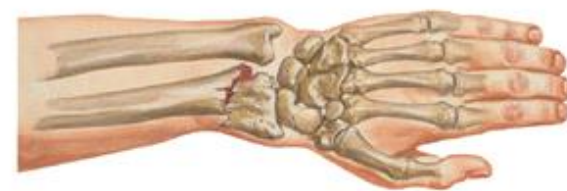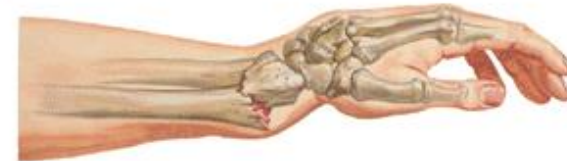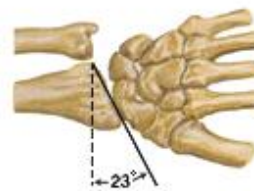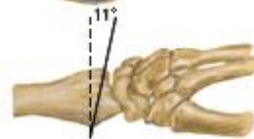
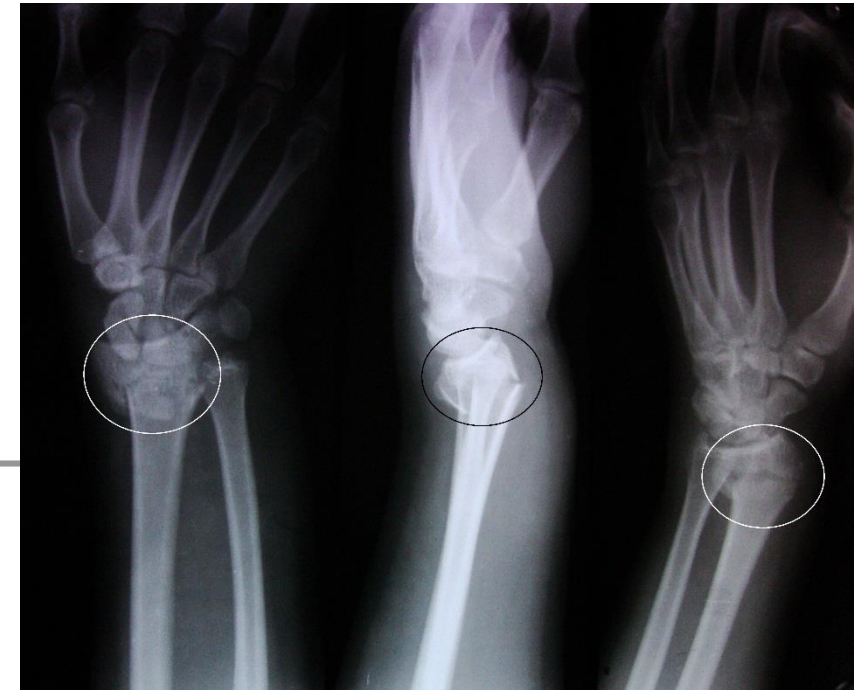-



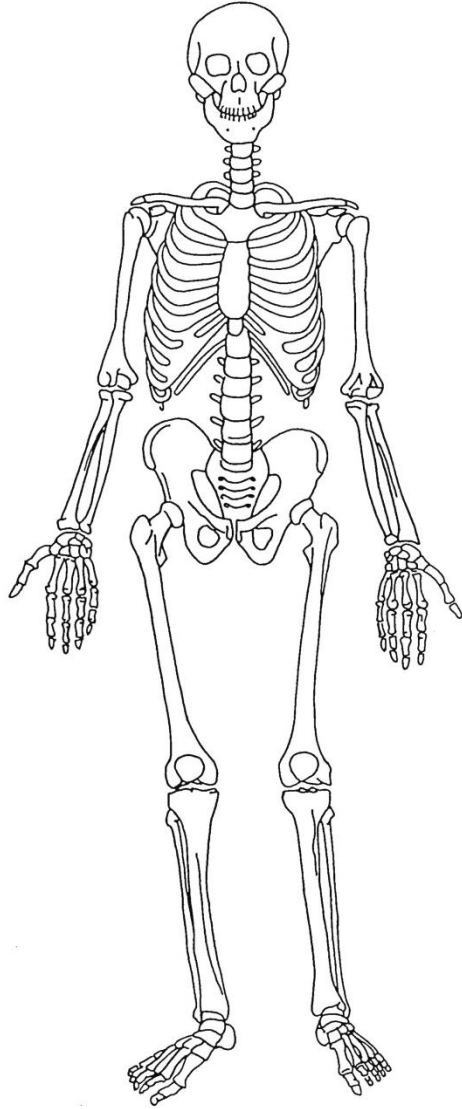
Fracture of the distal end of radius (Colle's fracture)



An X-ray image of a fractured radius showing the characteristic Colle's fracture with displacement and angulation of the distal end of the radius.



Ulna



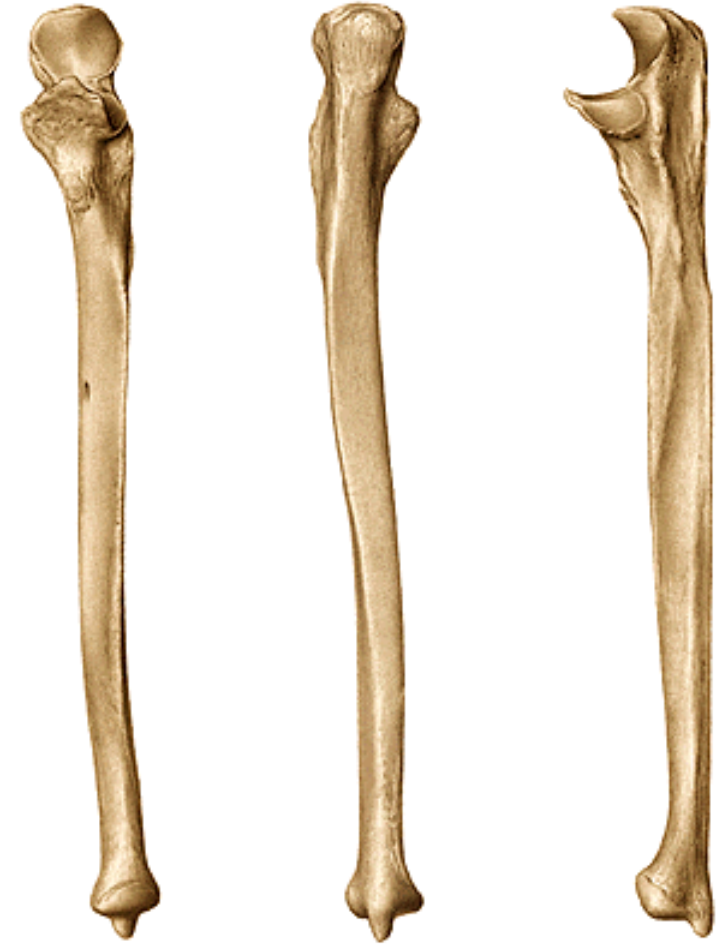Forarm (medial side)

Connects with humerus and radius

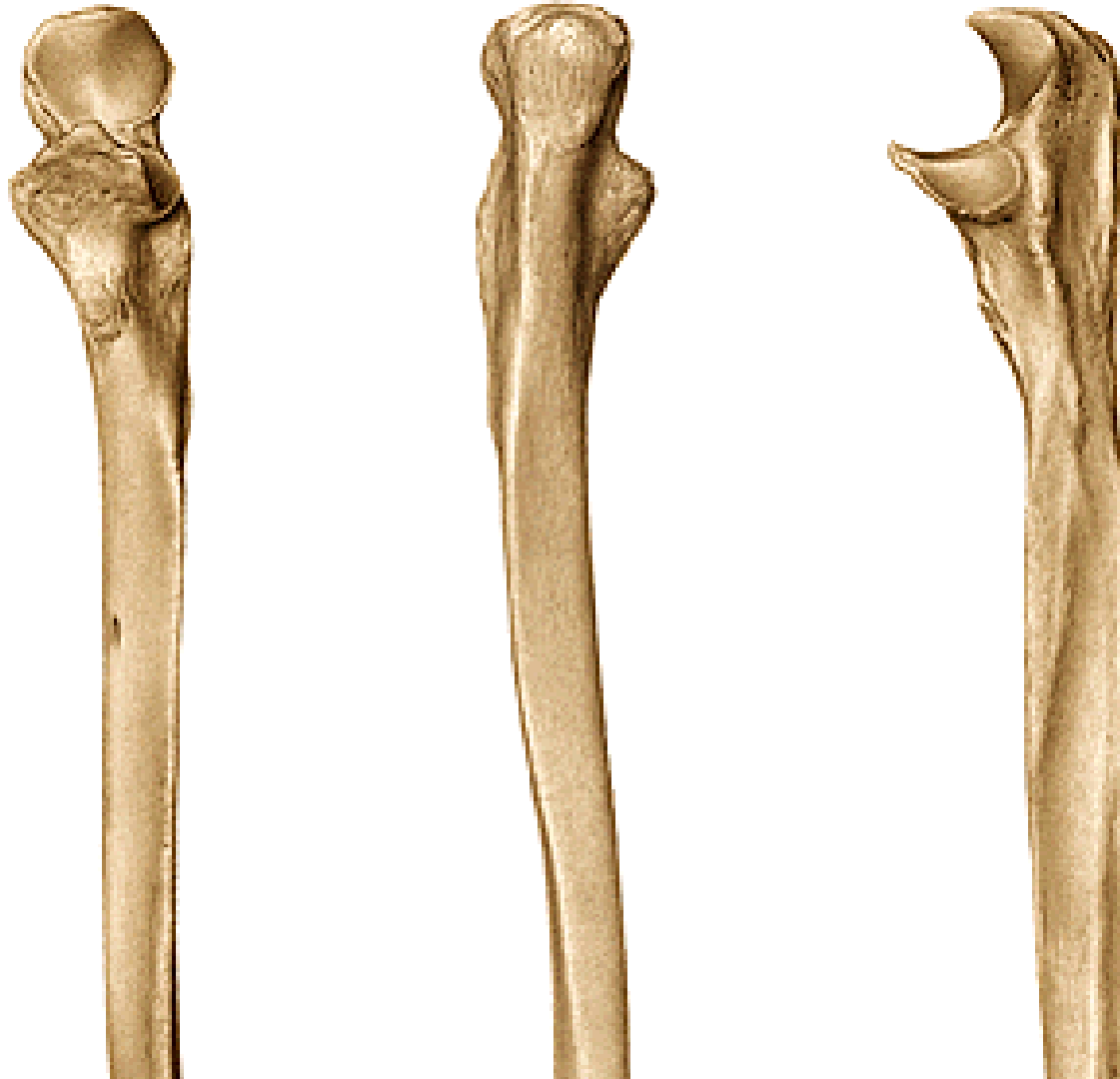Proximal end

Body

Distal end



Ulna



Proximal end:

olecranon ulnae

incisura trochlearis

processus coronoideus

incisura radialis ulnae



body:

tuberositas ulnae

margo interosseus

crista musculi supinatoris

Ulna



Distal end:

caput ulnae

circumferentia articularis capitis ulnae

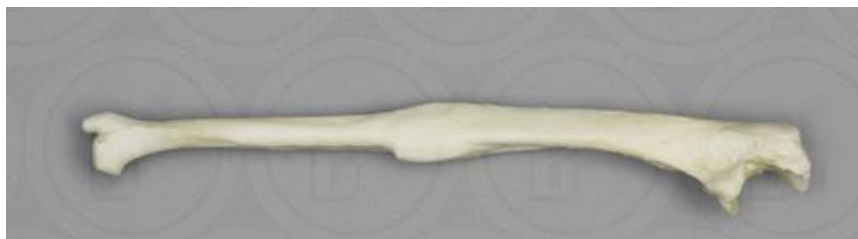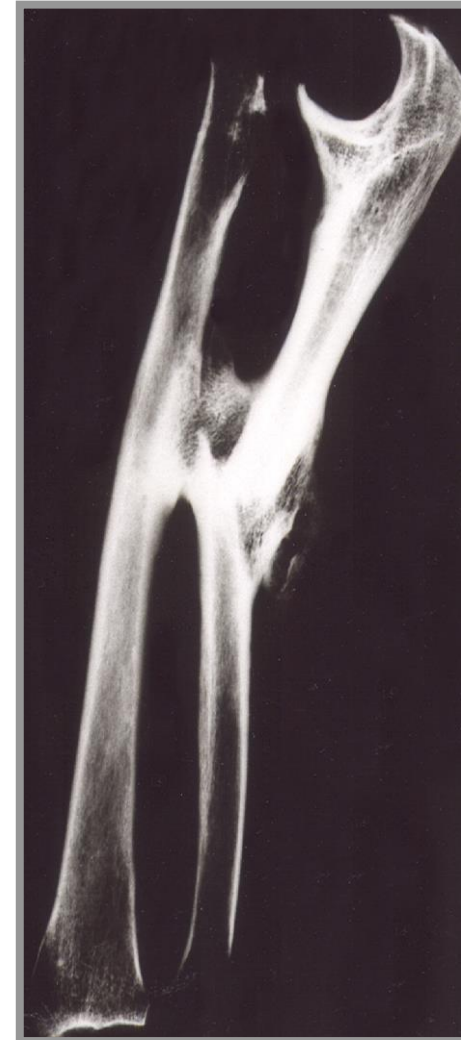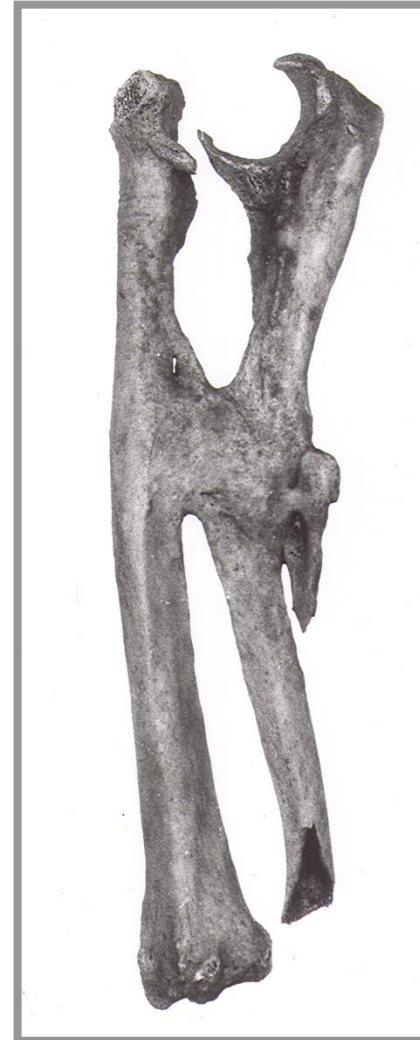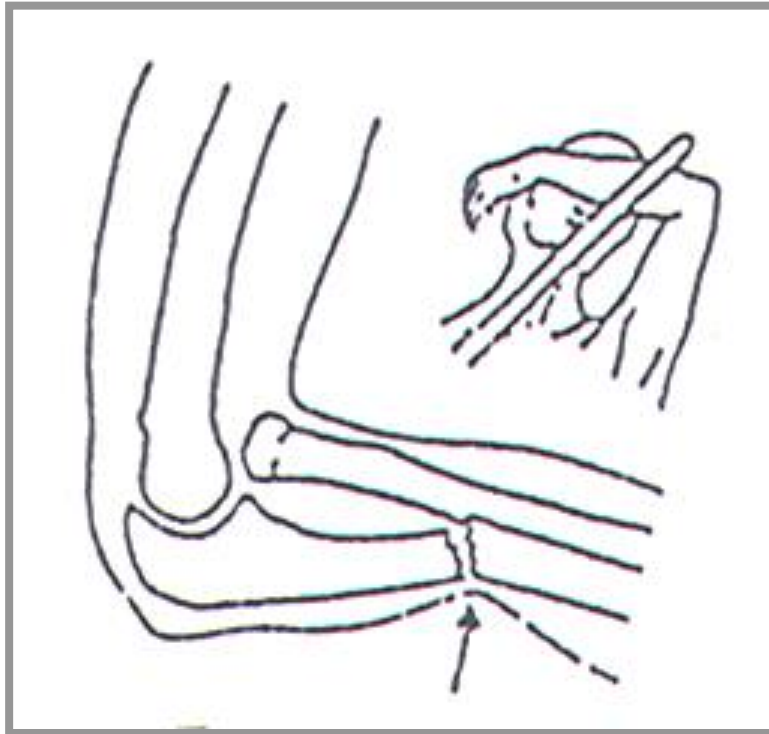
processus styloideus ulnae

Side orientation

-



Fracture of the ulna („parry fracture“)



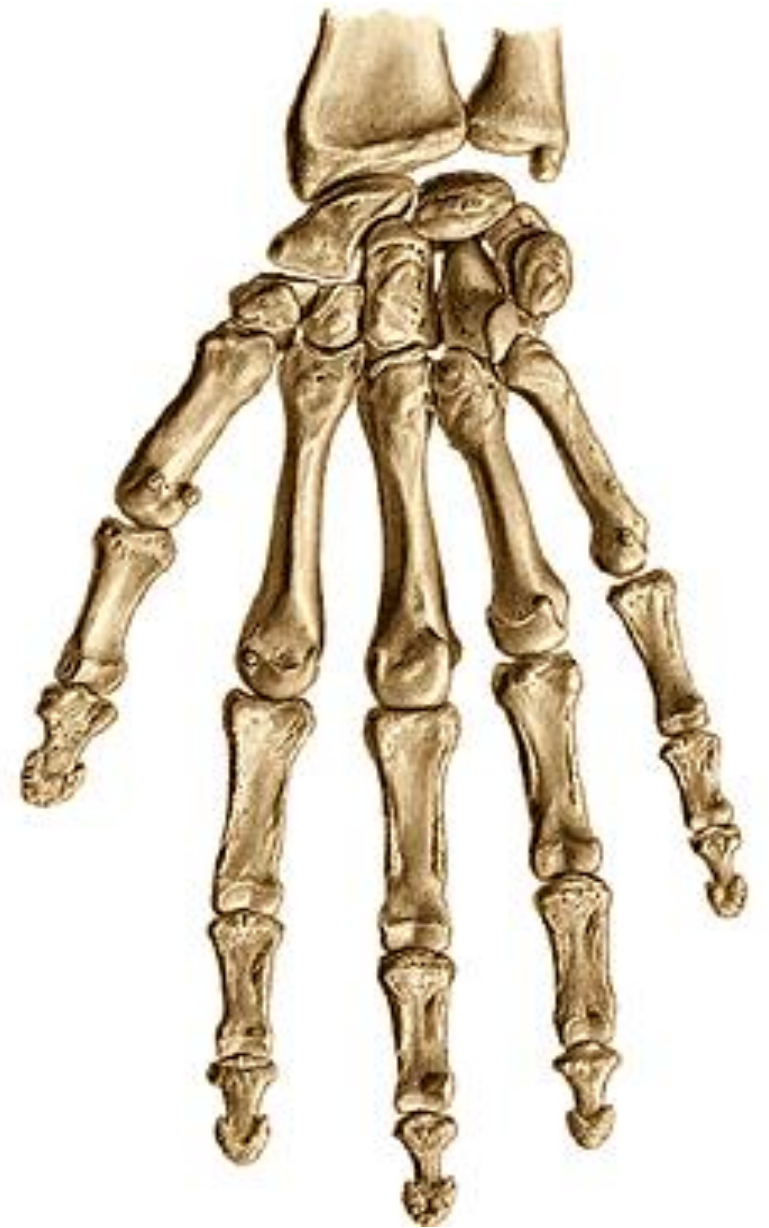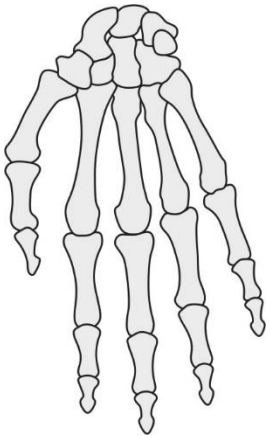
Bones of the hand

Ossa carpi (carpal bones)

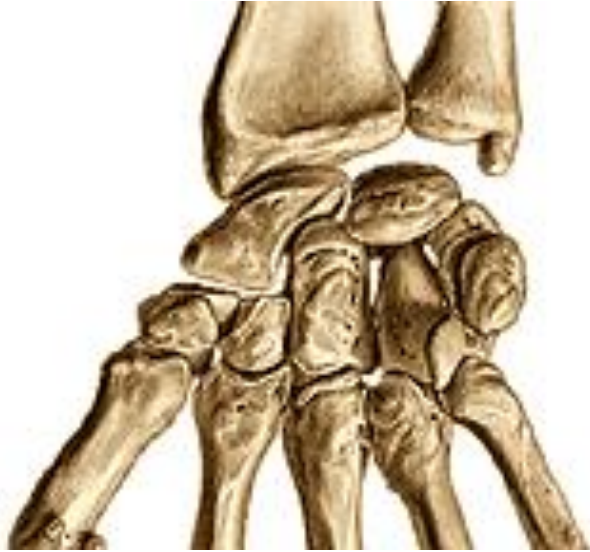Ossa metacarpi (metacarpal bones)

Ossa digitorum manus, phalanges
(phalanges, digits)

Sesamoid bones



Carpal bones - Ossa carpi (8)



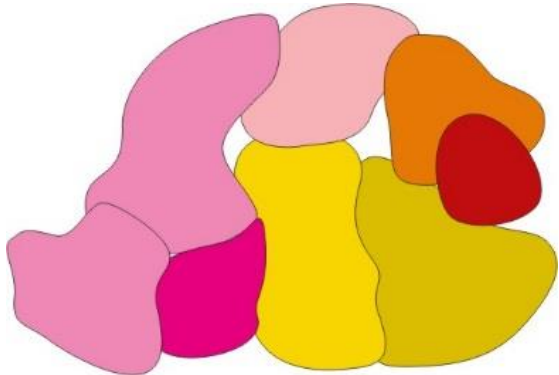
Proximal row (from the thumb side):

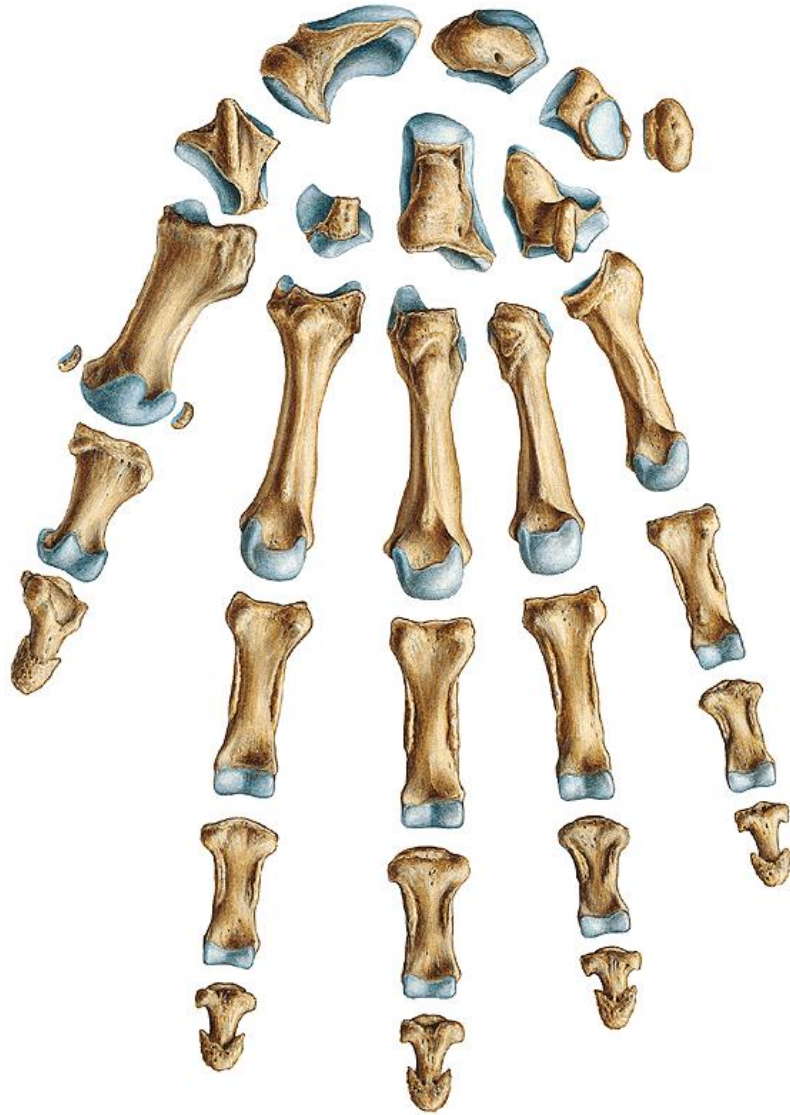
os scaphoideum (scaphoid)
(tuberculum ossis scaphoidei)

os lunatum (lunate)

os triquetrum (triquetrum)

os pisiforme (pisiform)





Ossa carpi (8)

Distal row:

os trapezium (trapezium)
(tuberculum ossis trapezii)

os trapezoideum (trapezoid)

os capitatum (capitate)

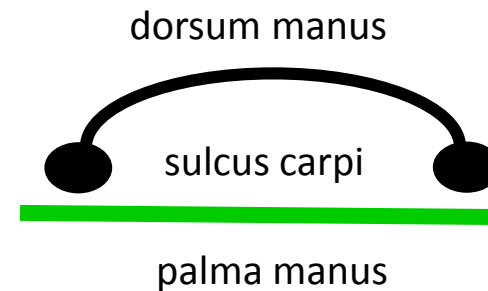
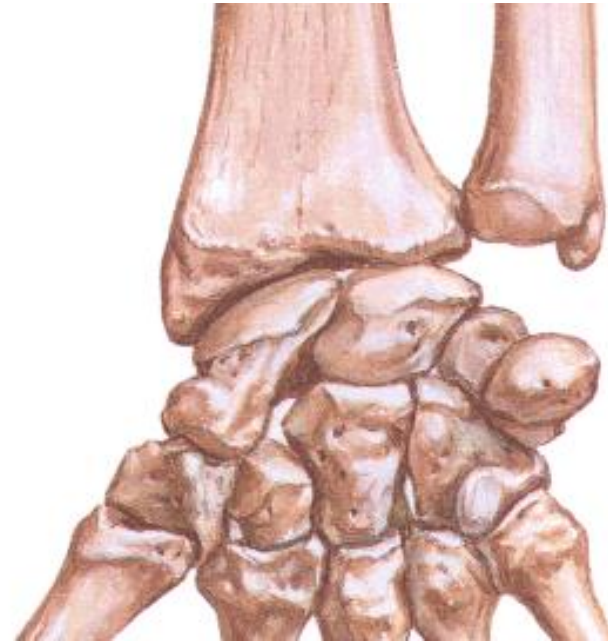
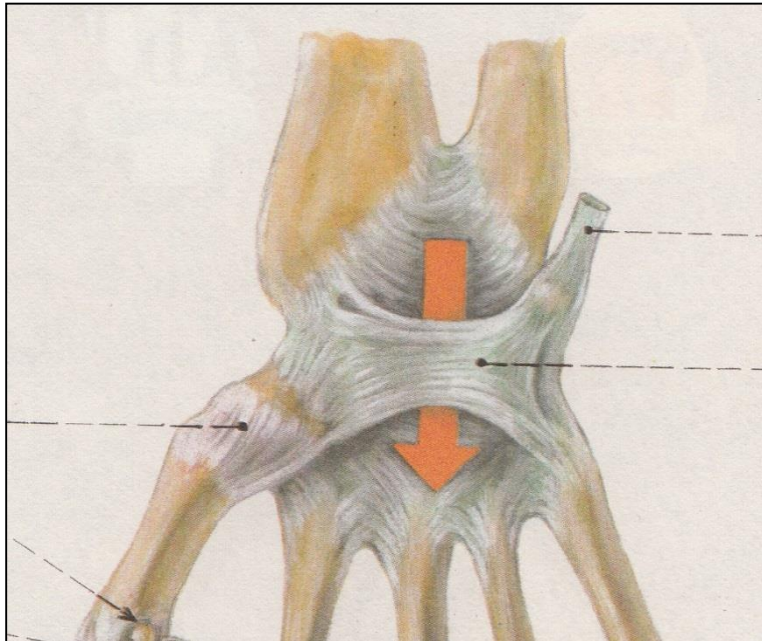
os hamatum (hamate)
(hamulus ossis hamati)

eminentia carpi radialis
(tuberculum ossis scaphoidei et trapezii)

eminentia carpi ulnaris
(hamulus ossis hamati et os pisiforme)

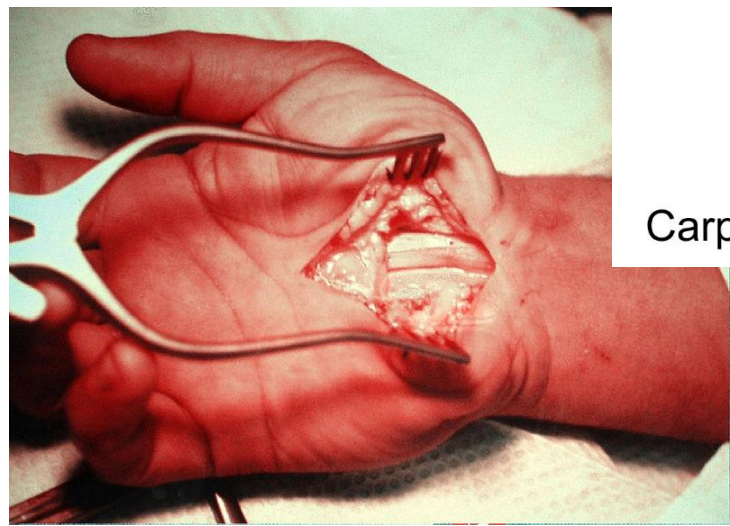
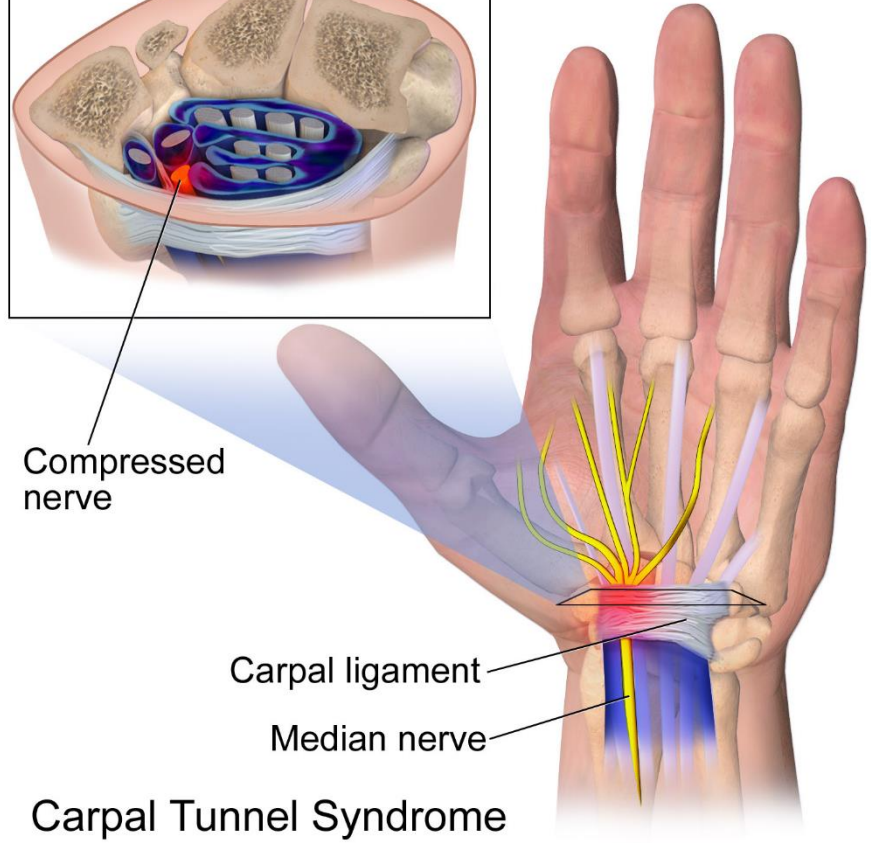
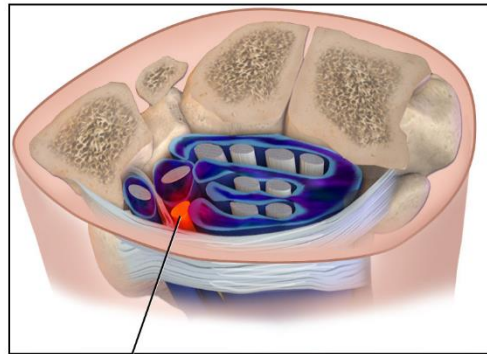
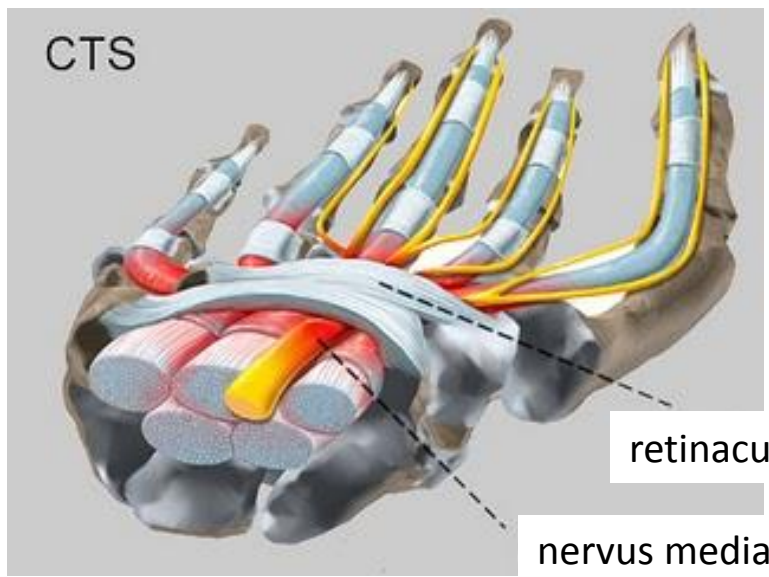
sulcus carpi (retinaculum flexorum)

canalis carpi

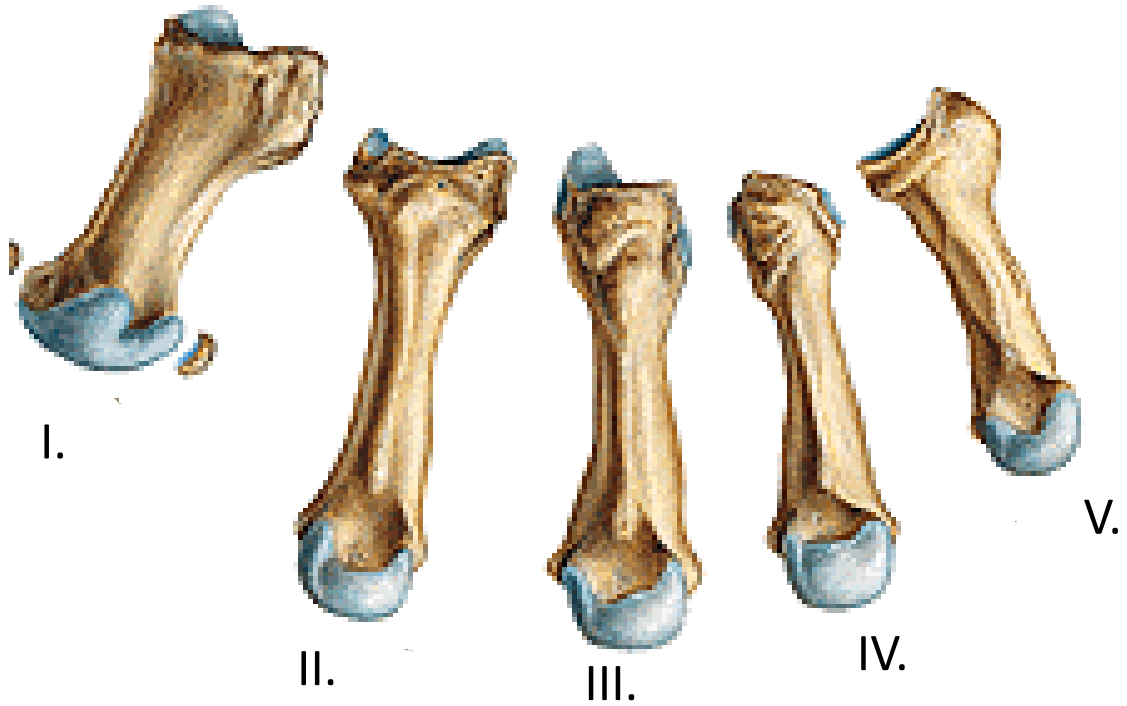


Both rows of carpal bones form together **an arch** and with flexor retinaculum (*retinaculum flexorum*) form **carpal tunnel** for tendons of flexor muscles and median nerve (*nervus medianus*).

Carpal tunnel syndrom



Ossa metacarpi (metacarpal bones I.-V.)



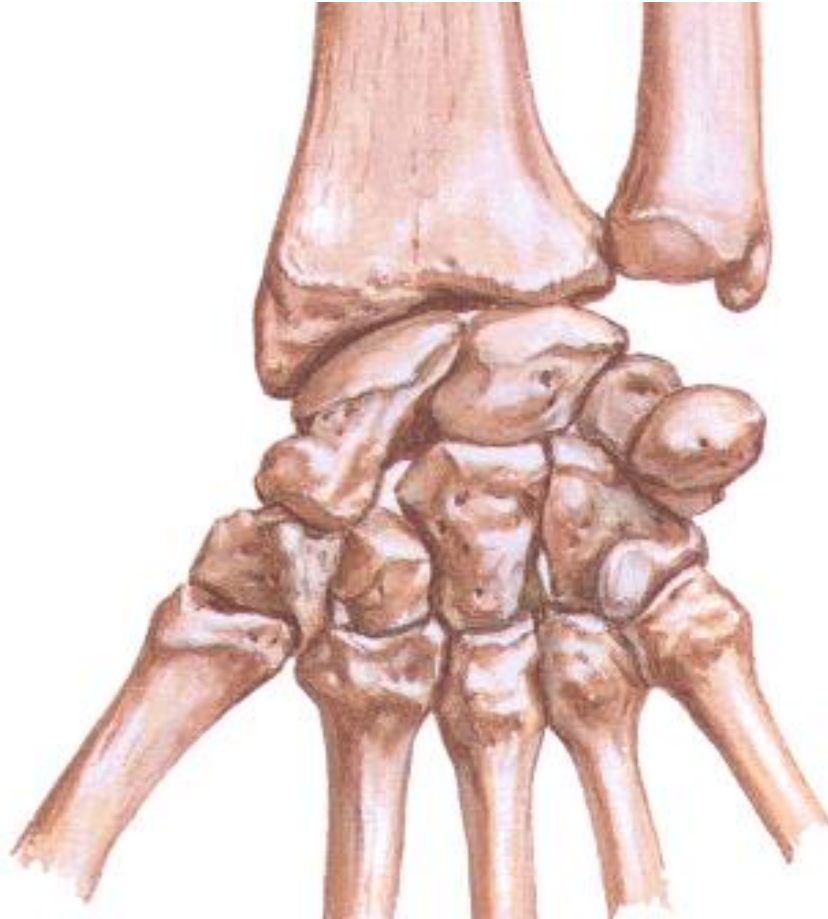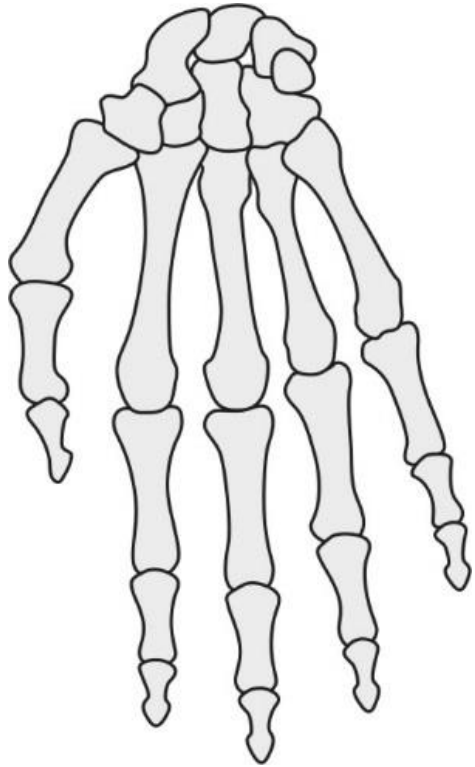
Base - Basis ossis metacarpalis (III. MC – processus styloideus)

Body - Corpus ossis metacarpalis

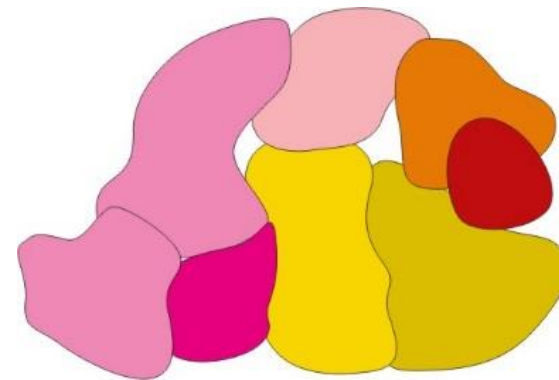
Head - Caput ossis metacarpalis

Ossa sesamoidea - Sesamoid bones - in the joints between metacarpal and the basis of proximal phalanx of the thumb.

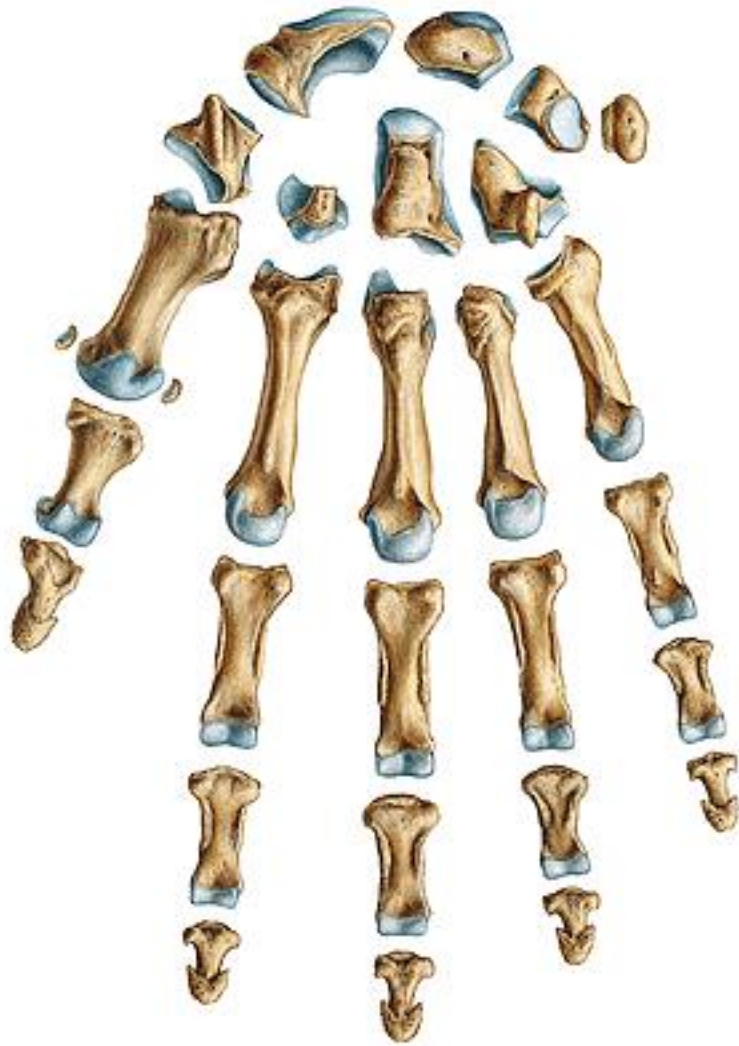Connections with basis ossis metacarpi



- I. MC– trapezium
- II. MC– trapezium, trapezoid, capitate
- III. MC– capitate
- IV. and V. MC – hamate



Ossa digitorum manus, phalanges digitorum manus (phalanges of the hand, bones of the digits)



Each digit (II.–V.)

– 3 phalanges : phalanx proximalis, media et distalis

Thumb – 2 phalanges - phalanx proximalis et distalis

Base - Basis phalangis (prox., media, dist.)

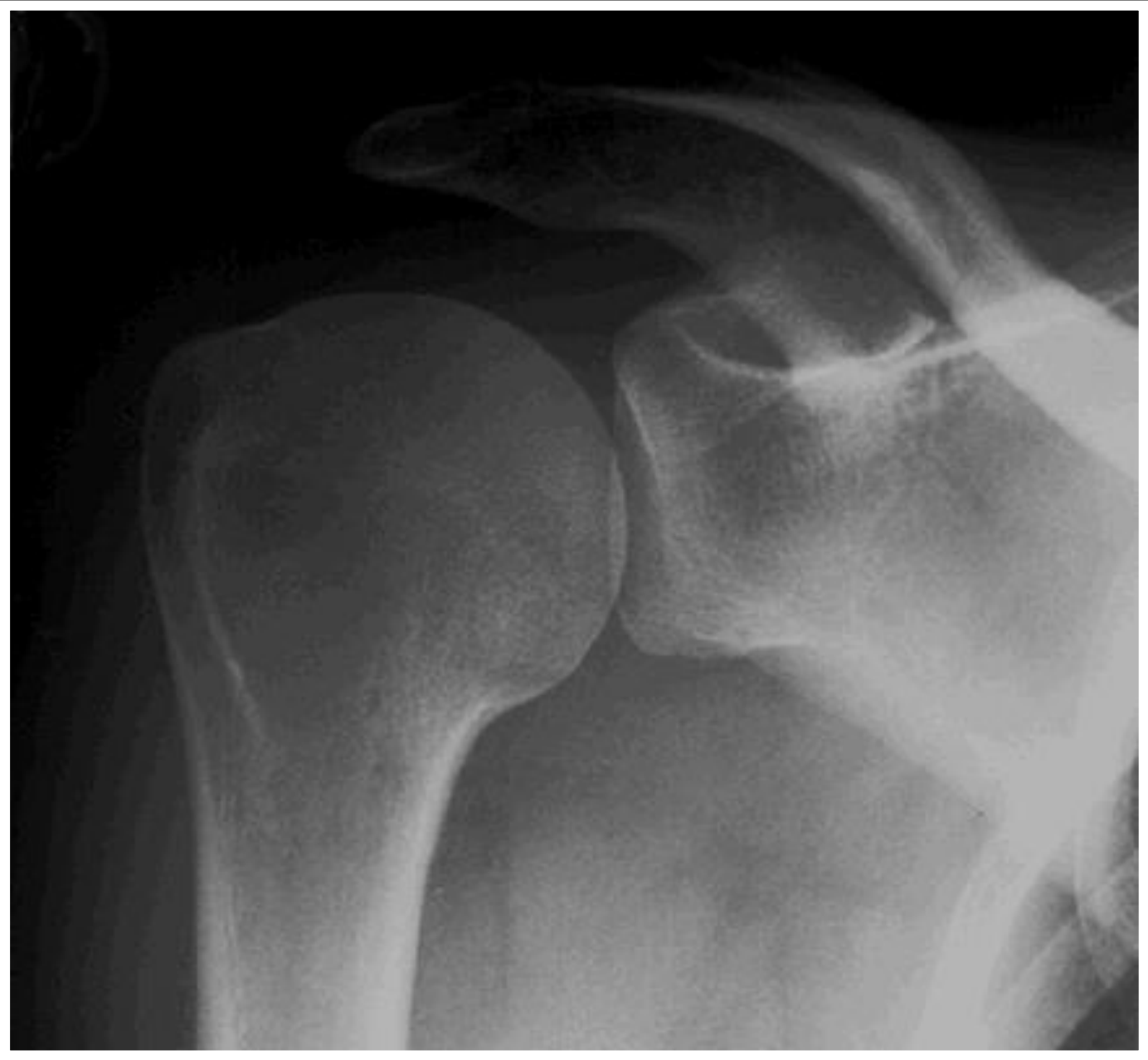Shaft, body - Corpus phalangis (prox., media, dist.)

head, trochles - Trochlea phalangis (prox., media, dist.)

Tuberositas phalangis distalis - at the distal end there is a rough palmar surface for insertion of the tendon of the muscle – the tuberosity of the distal phalanx

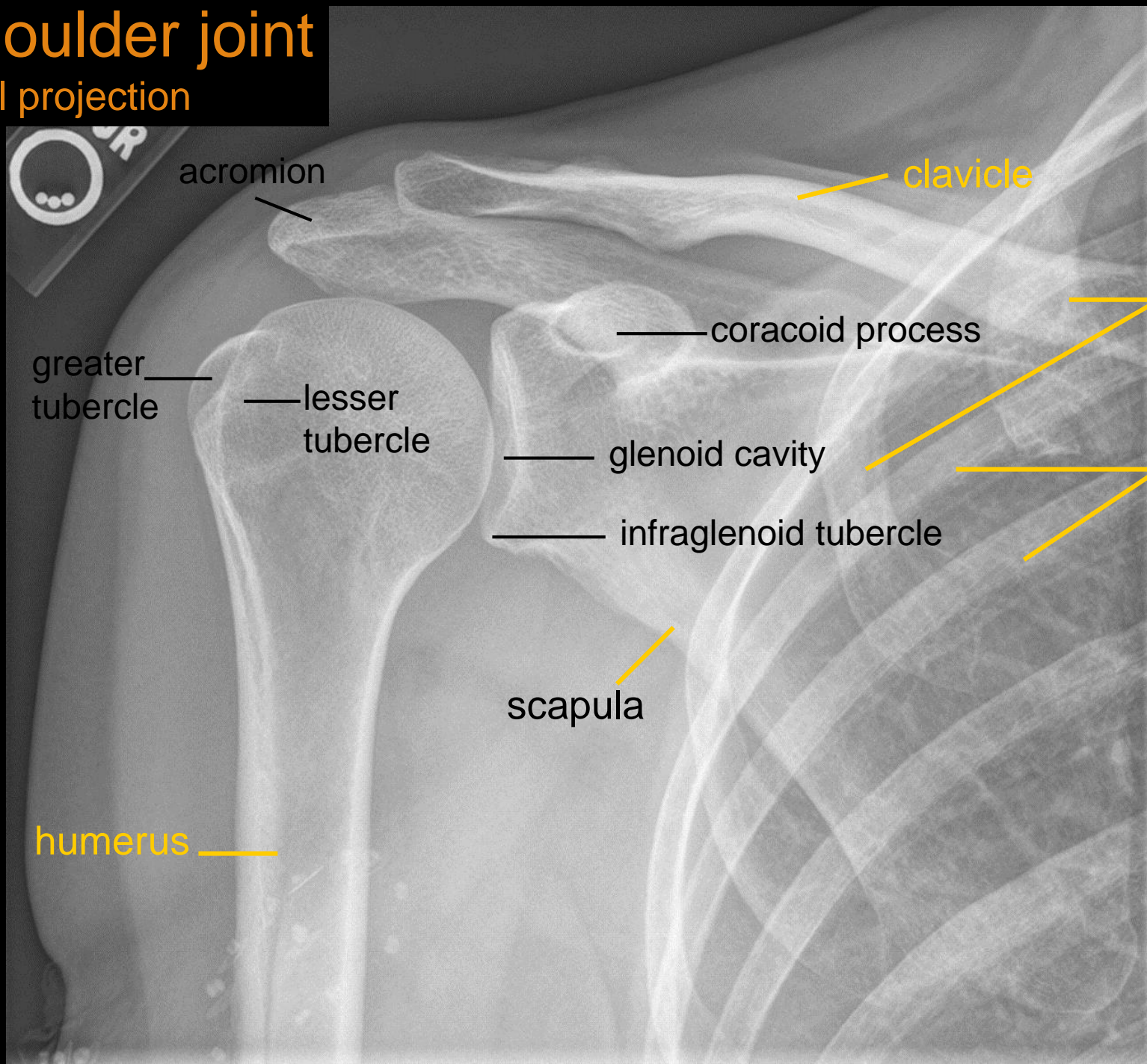
X-rays





Shoulder joint

axial projection



acromion

clavicle

coracoid process

anterior ribs

greater tubercle

lesser tubercle

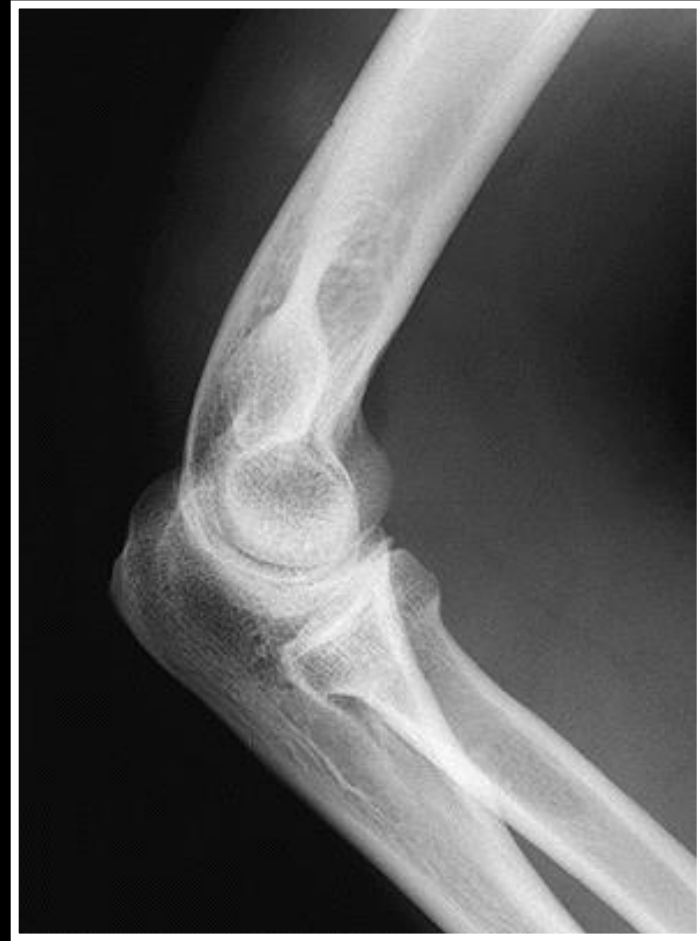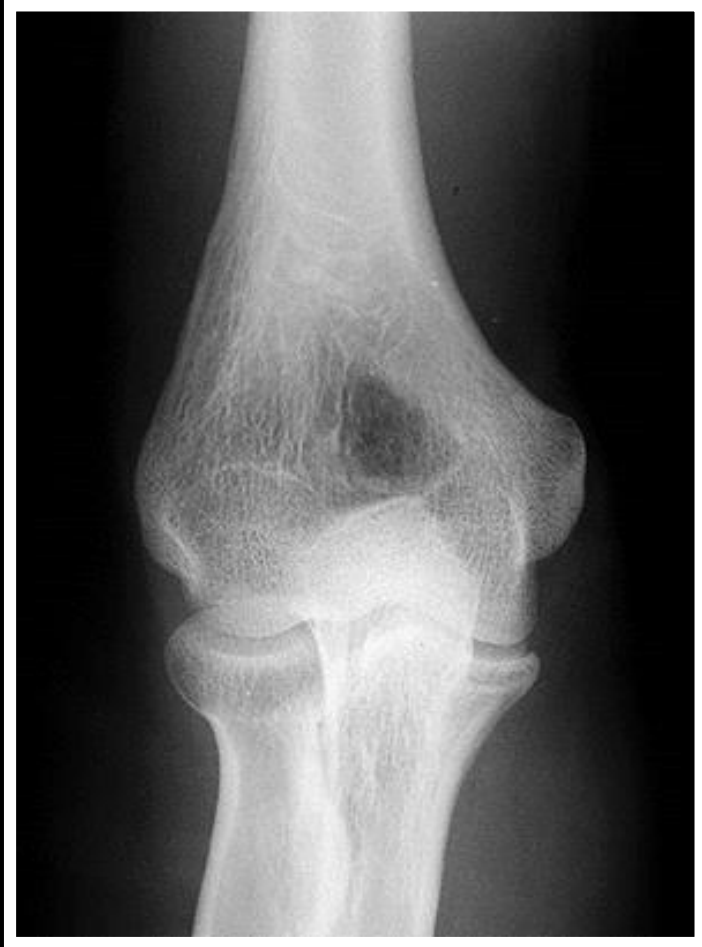glenoid cavity

posterior ribs

infraglenoid tubercle

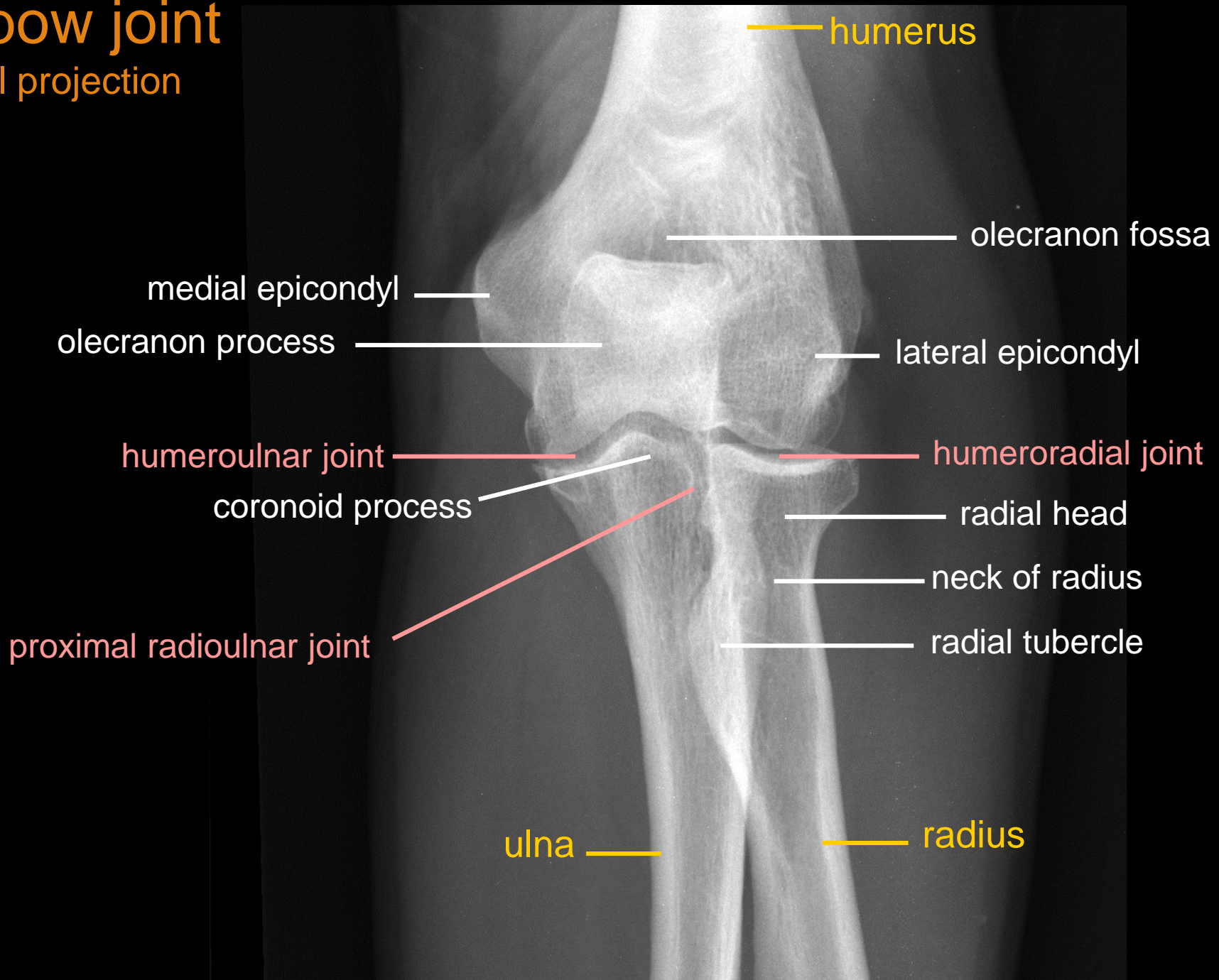
scapula

humerus



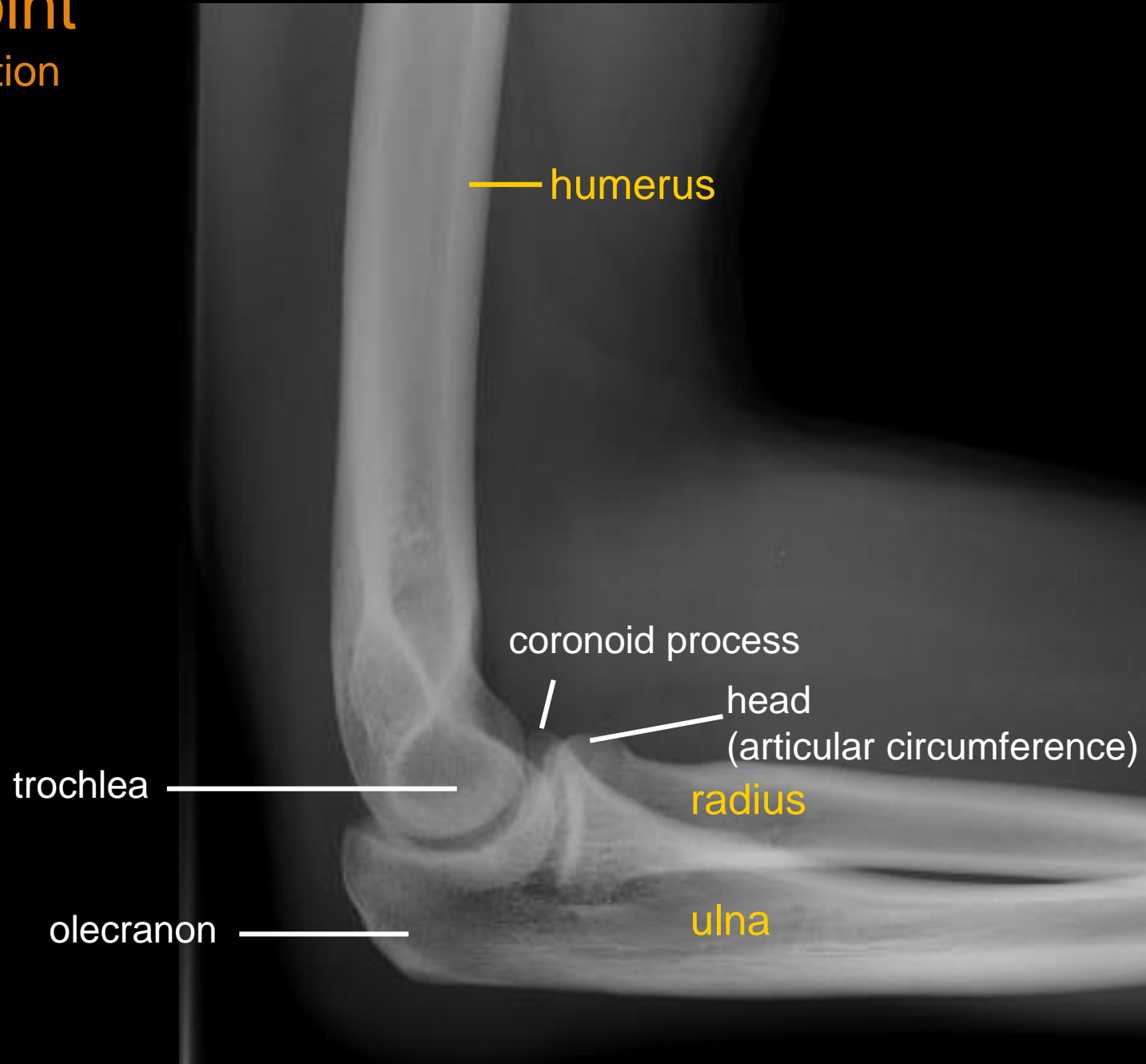
Elbow joint

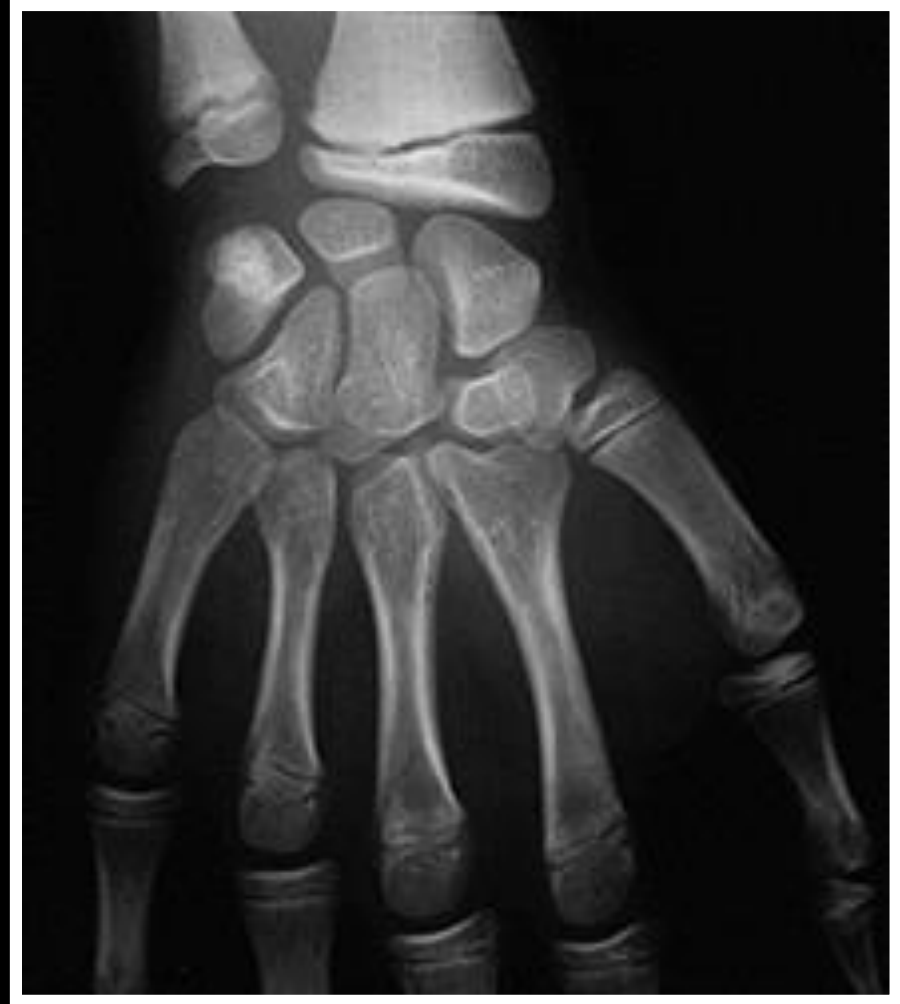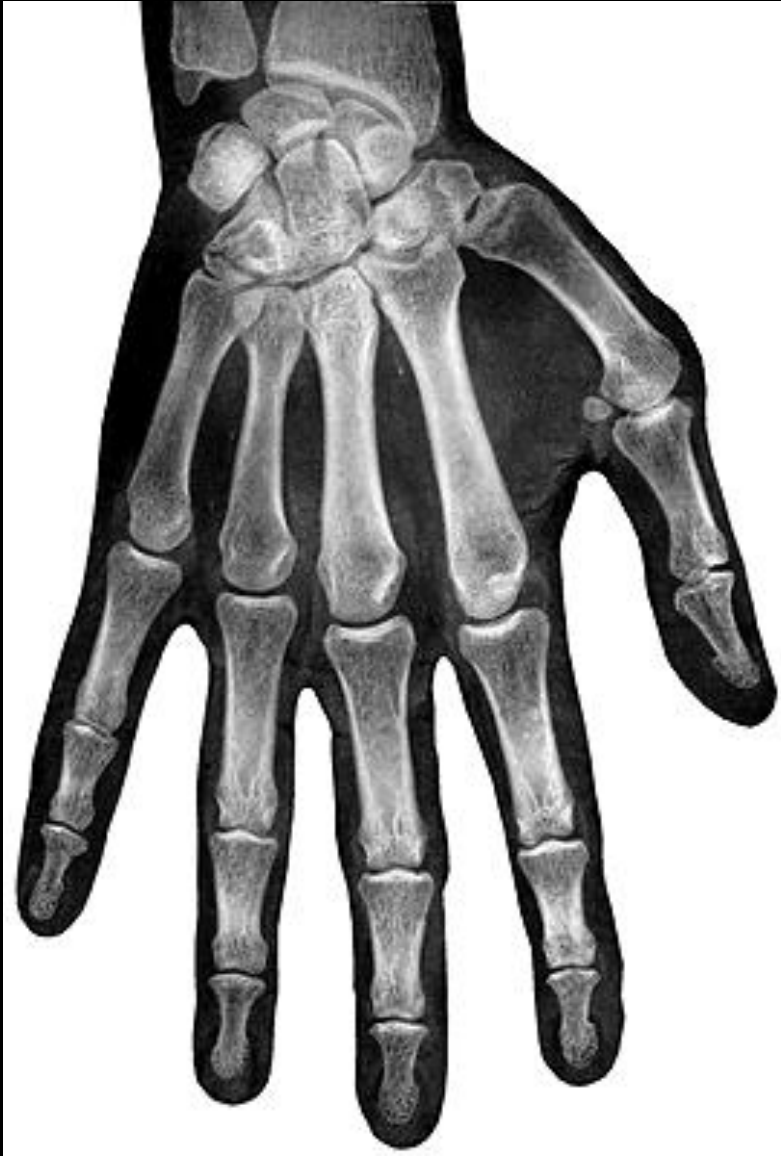axial projection



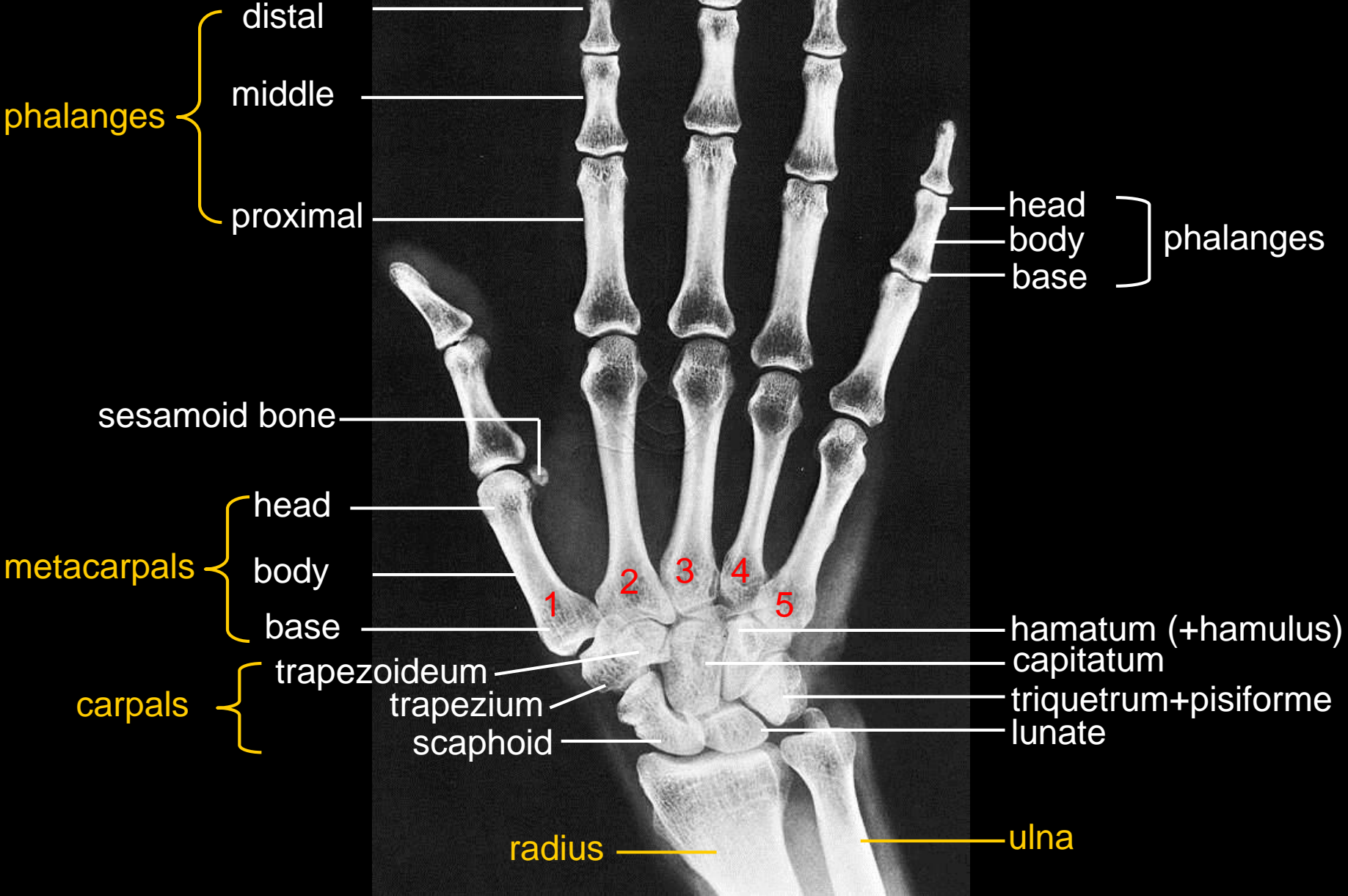
Elbow joint

lateral projection

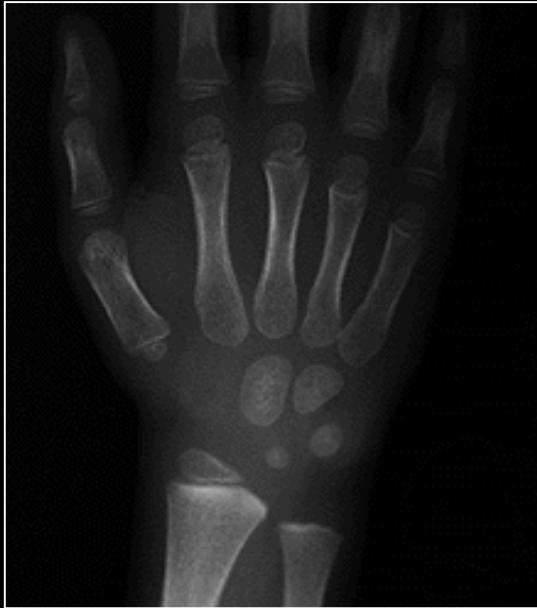



Hand and wrist adult

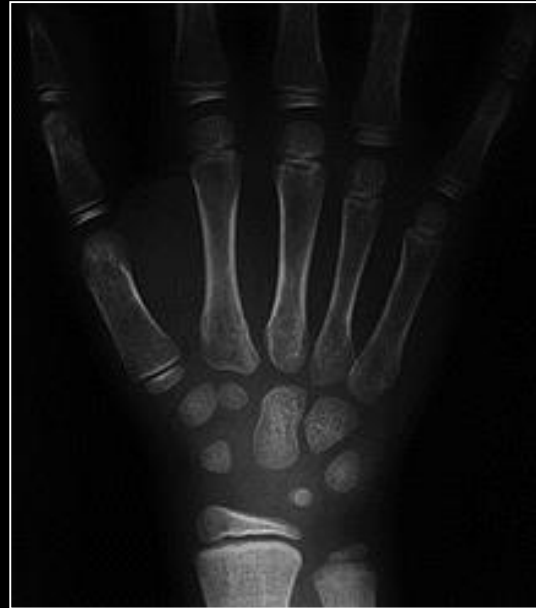

Hand and wrist child



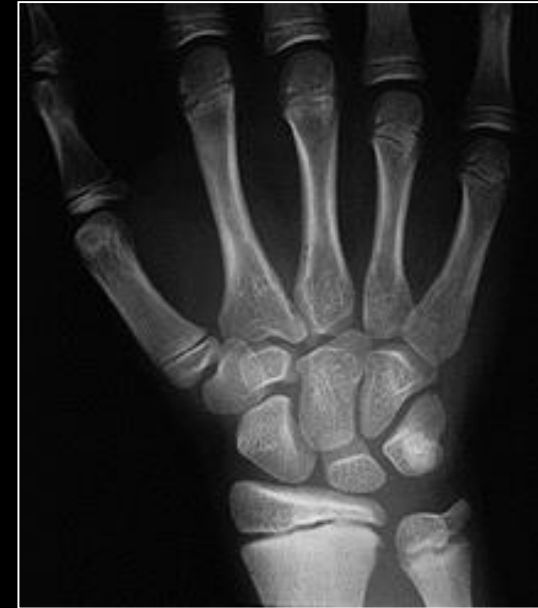4,5 years old child

(4 carpal bones are
ossificated)



7 years old child

(7 carpal bones are
ossificated)



13 years old child

The pictures used in this lecture were taken from following sources:

- **Atlas der Anatomie des Menschen/Sobotta. Putz,R., und Pabst,R. 20. Auflage. München:Urban & Schwarzenberg, 1993**
- **Netter: Interactive Atlas of Human Anatomy.**
- **Naňka, Elišková: Přehled anatomie. Galén, Praha 2009.**
- **Čihák: Anatomie I, II, III.**
- **Drake et al: Gray's Anatomy for Students. 2010**
- **Own archiv of the lecturer**