

TRANSVERSE PALATINE FOLD?



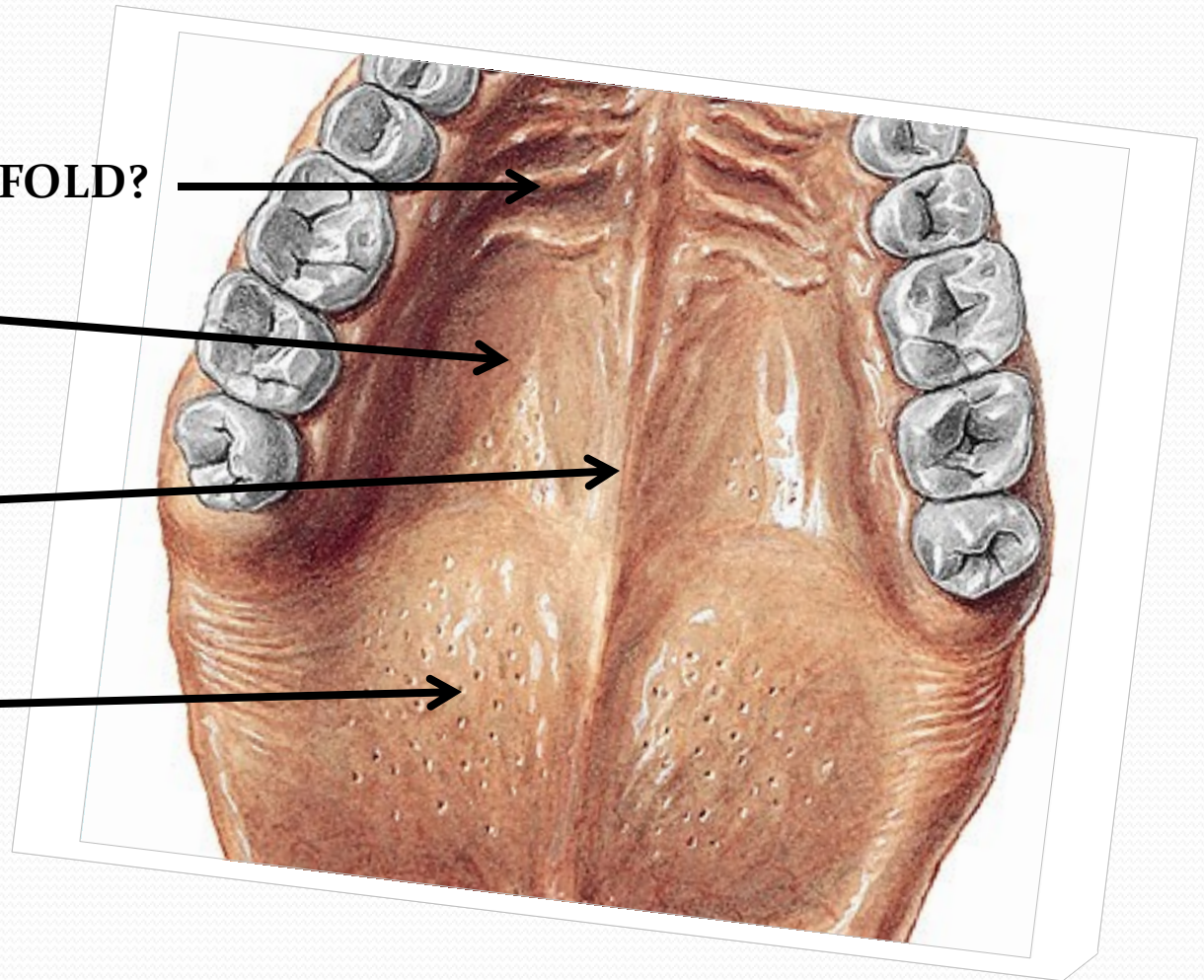

HARD PALATE?

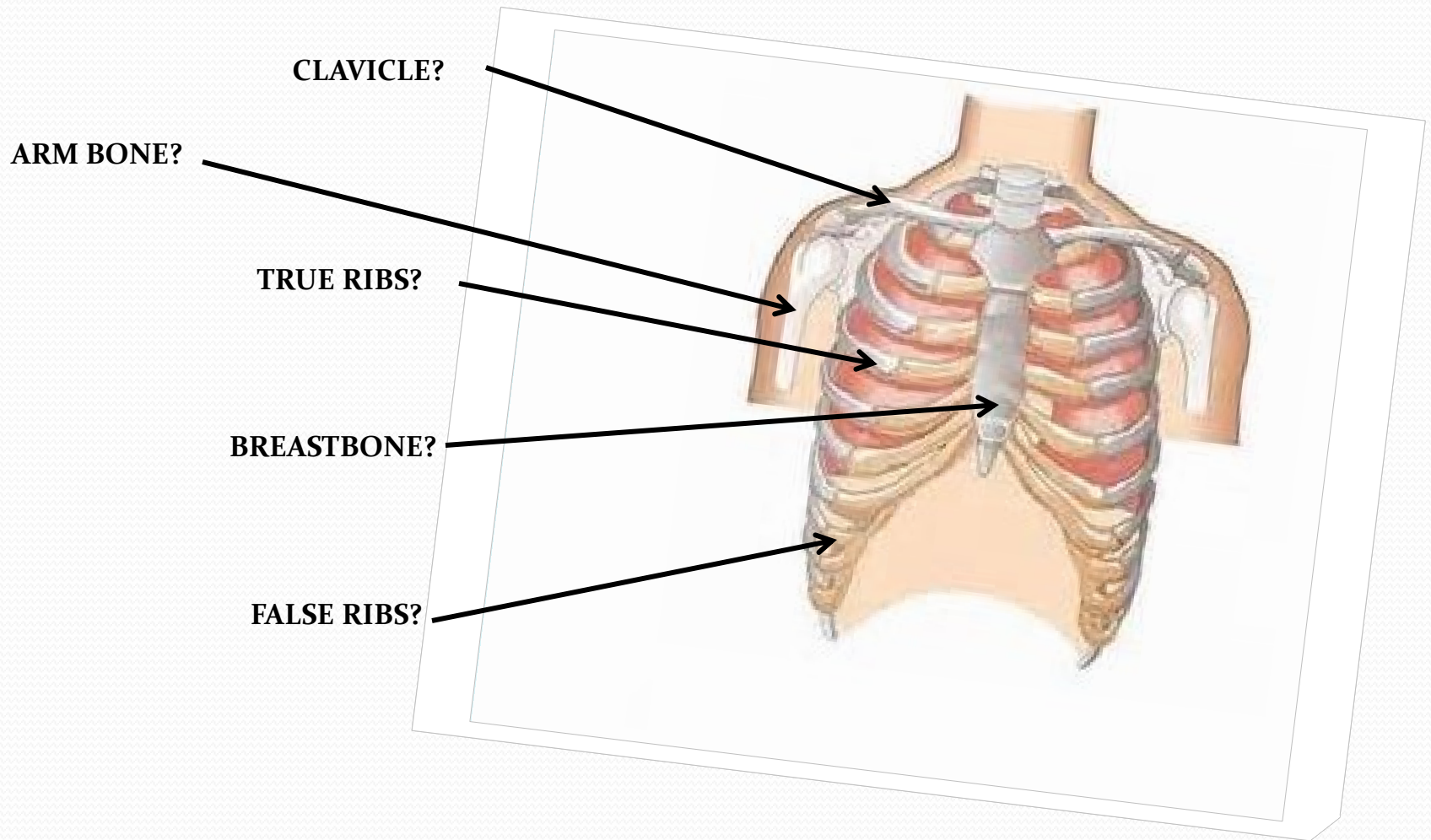


MEDIAN RAPHE?



SOFT PALATE?

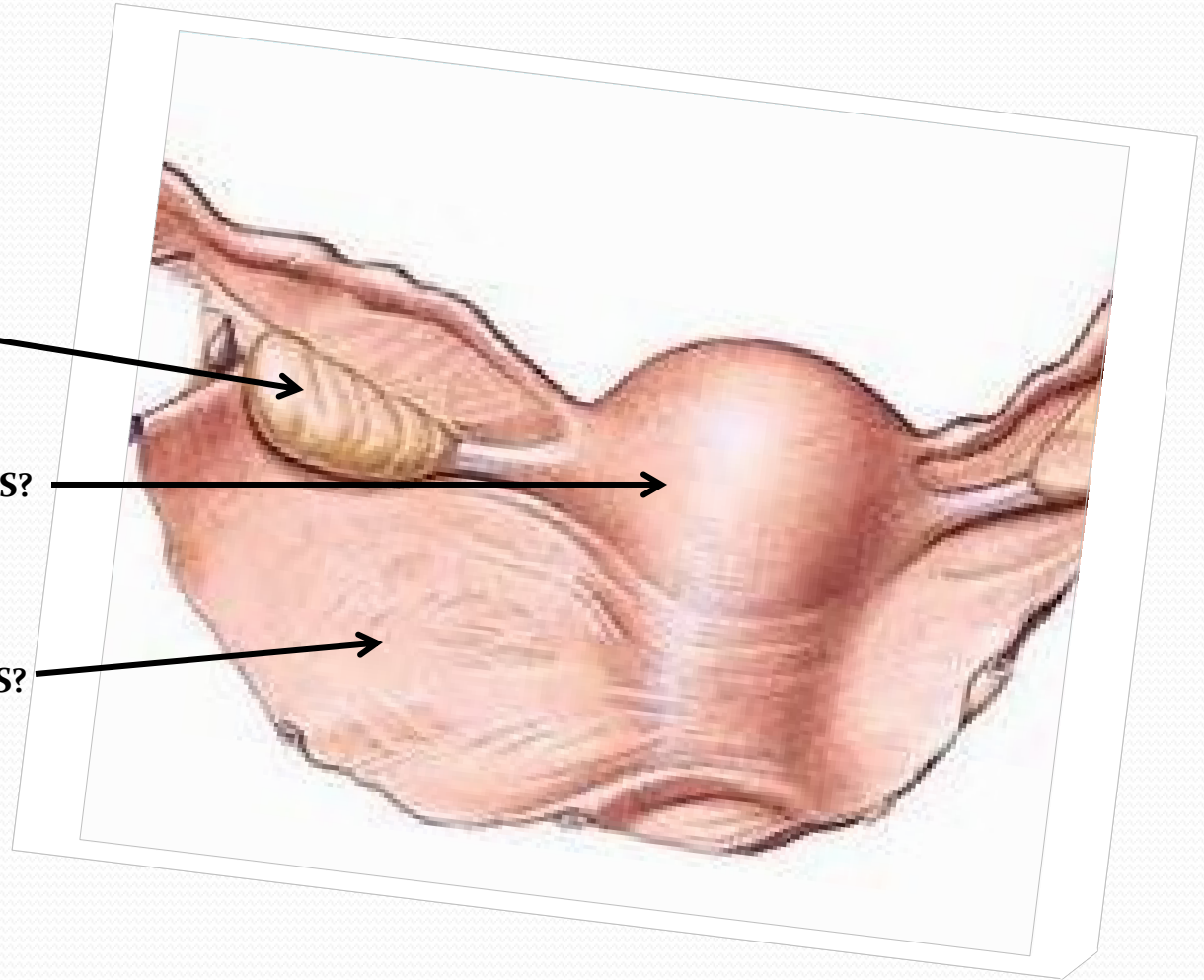




OVARY?

UTERUS?

WIDE LIGAMENT OF UTERUS?

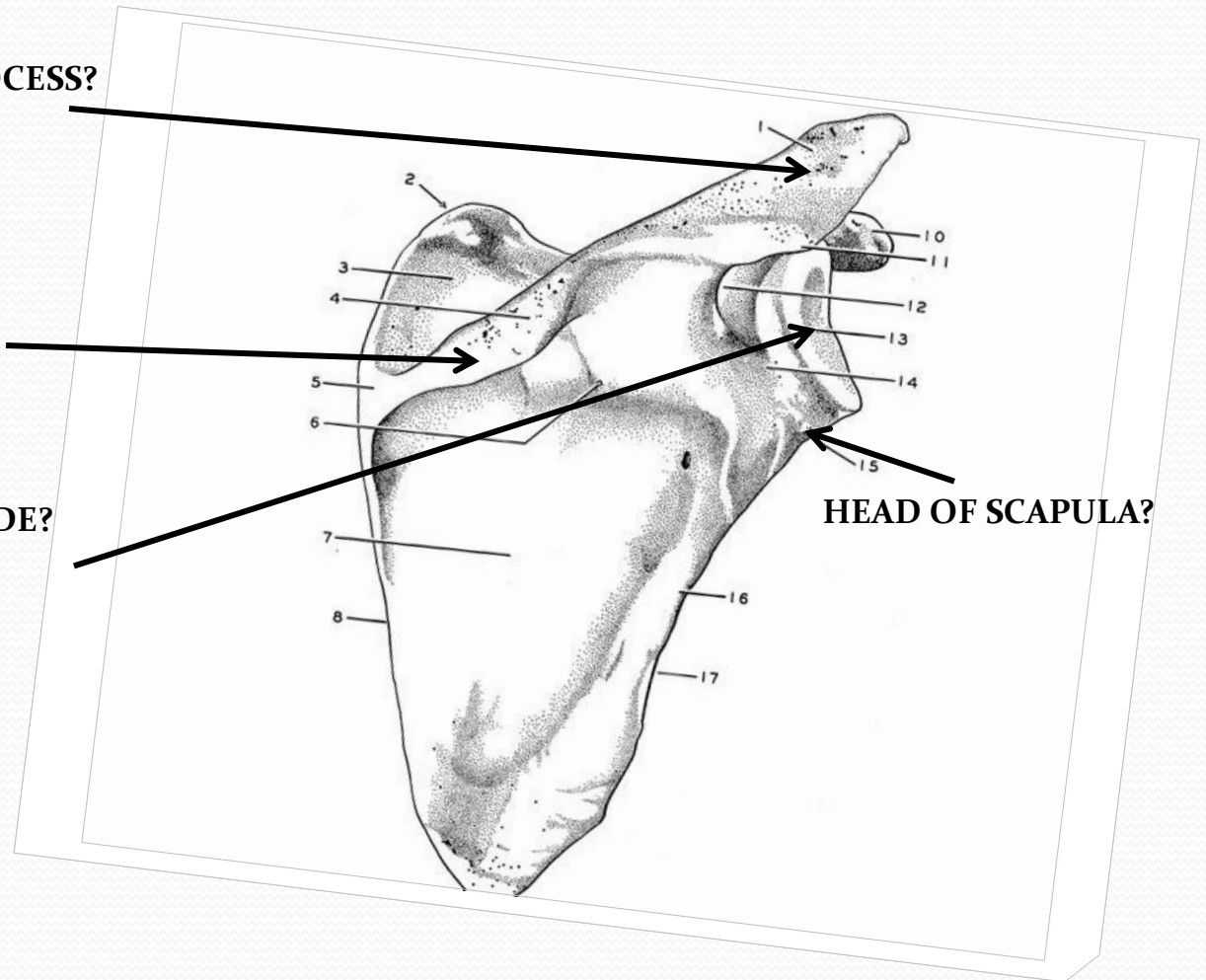


ACROMION PROCESS?

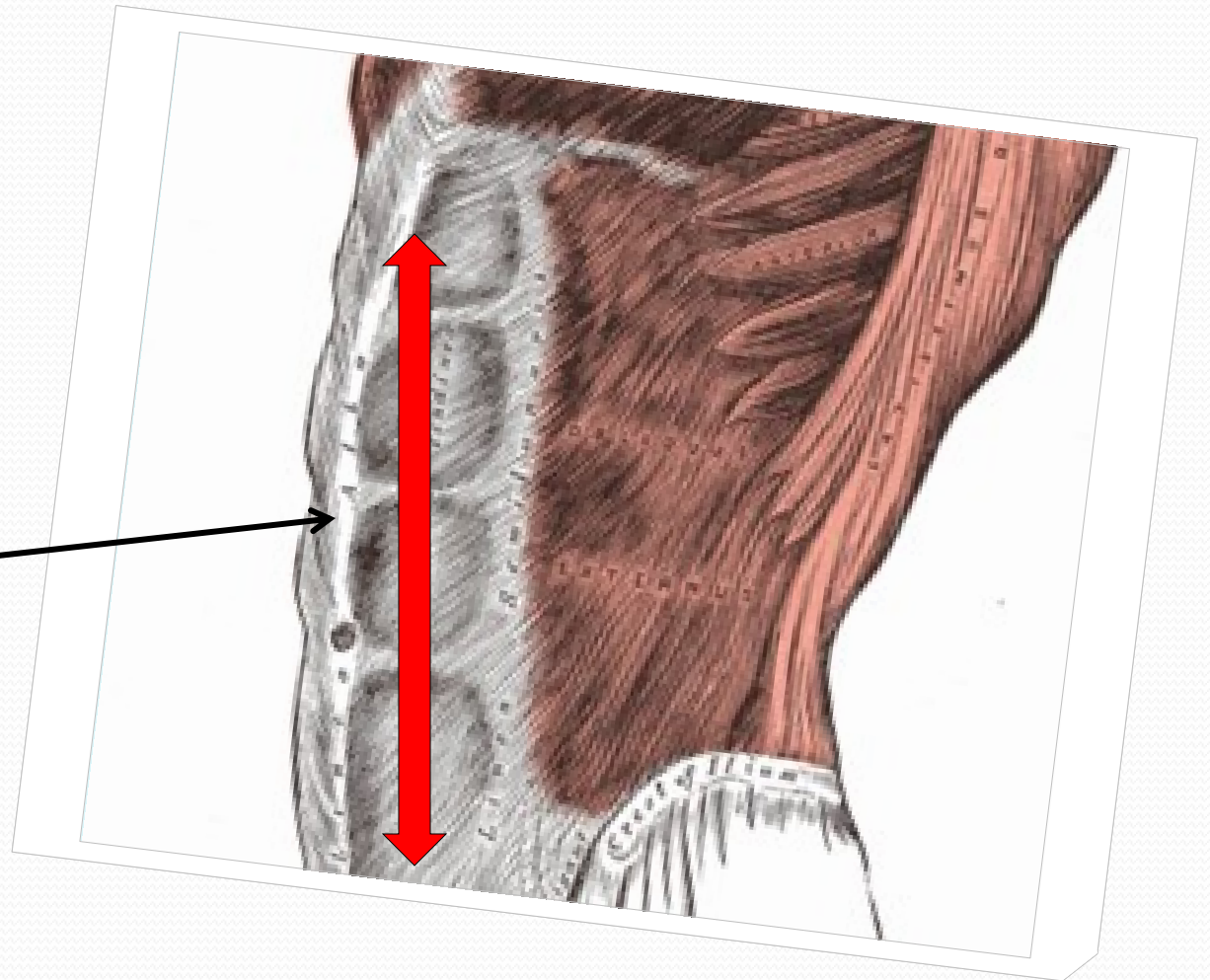
SPINE OF SCAPULA?

**FOSSA OF SHOULDER BLADE?
(or GLENOID FOSSA)**

HEAD OF SCAPULA?



WHITE LINE?

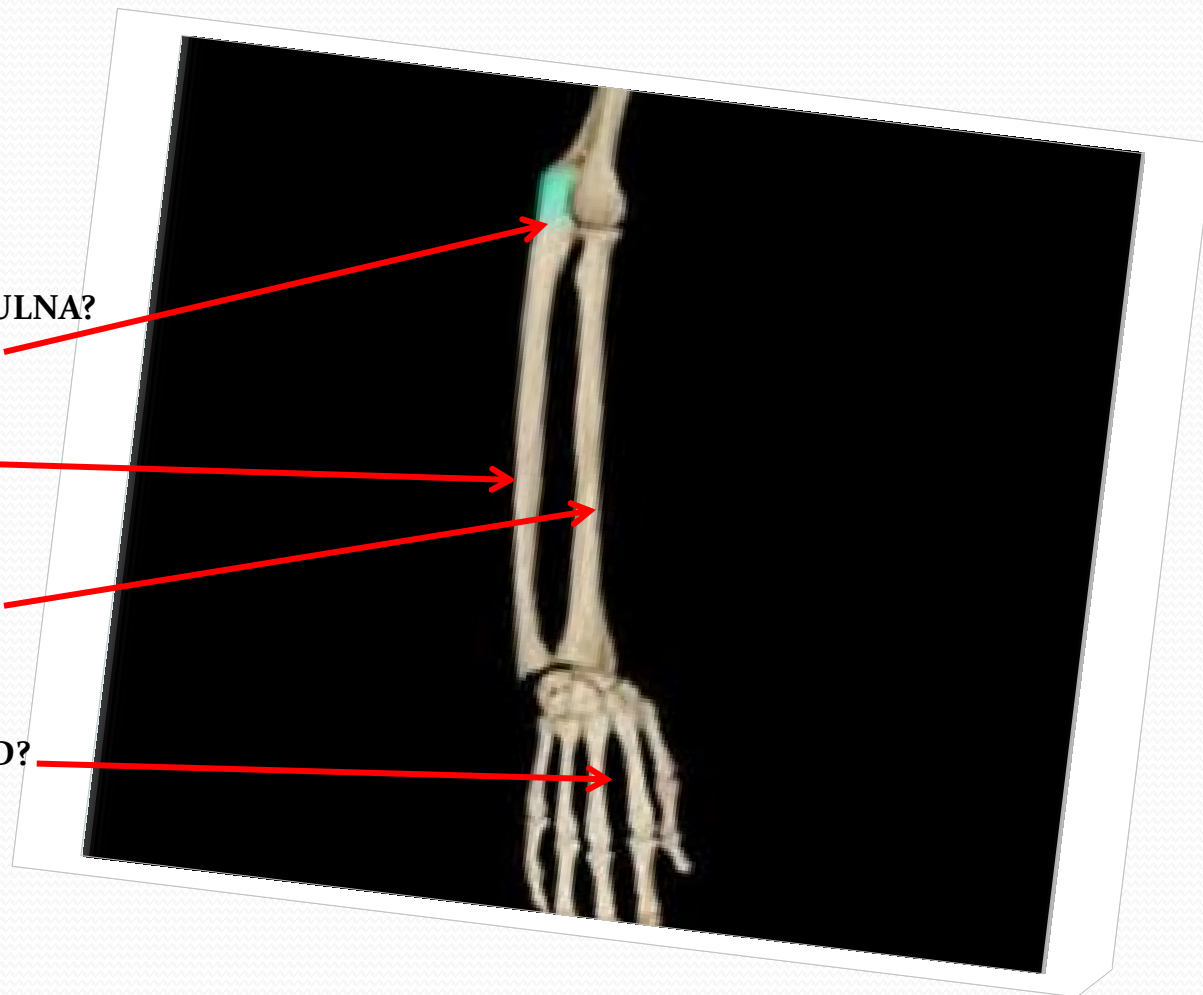


OLECRANON PROCESS OF ULNA?

ULNAR BONE?

RADIAL BONE?

FINGERS OF HAND?

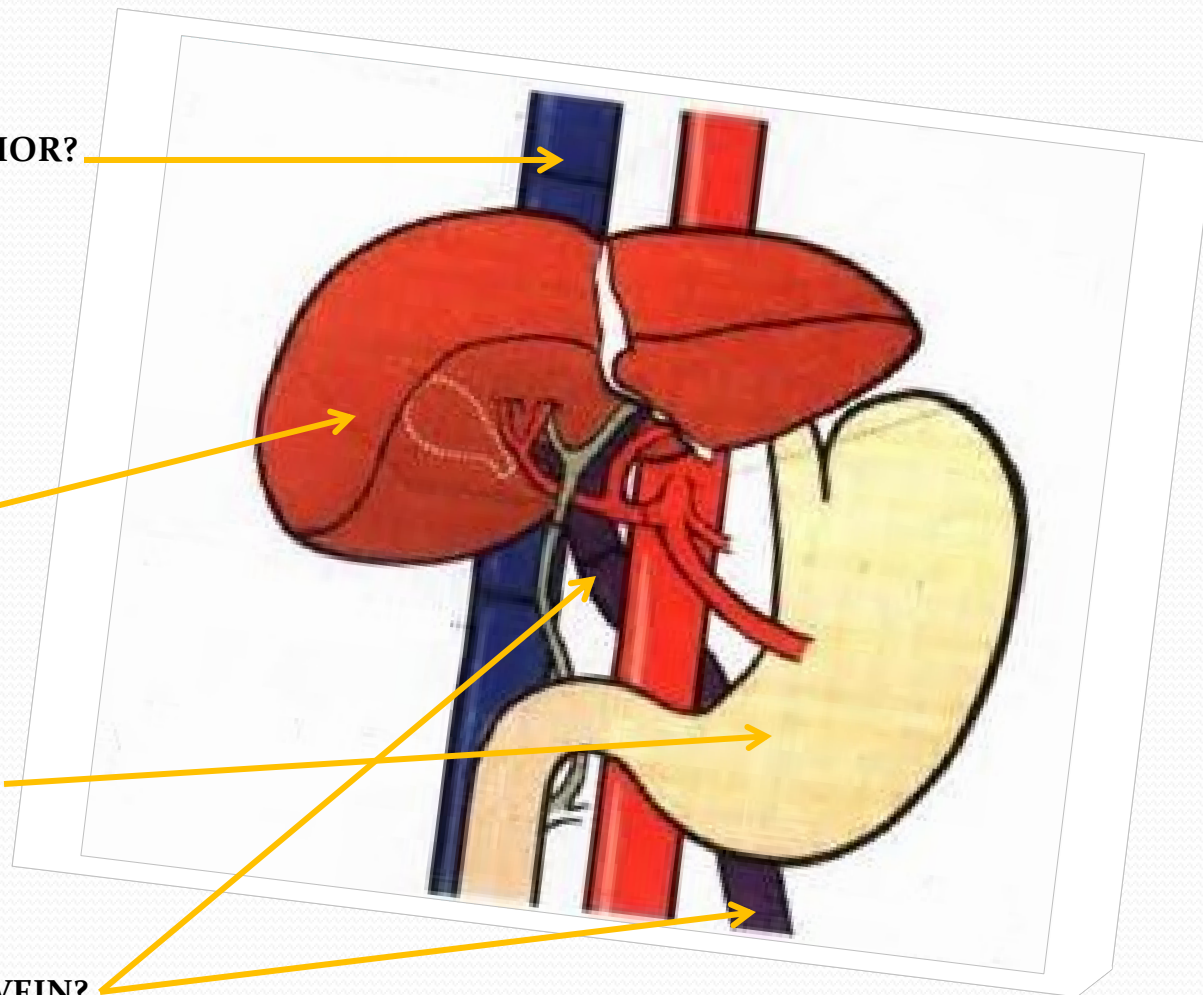


VENA CAVA INFERIOR?

LIVER?

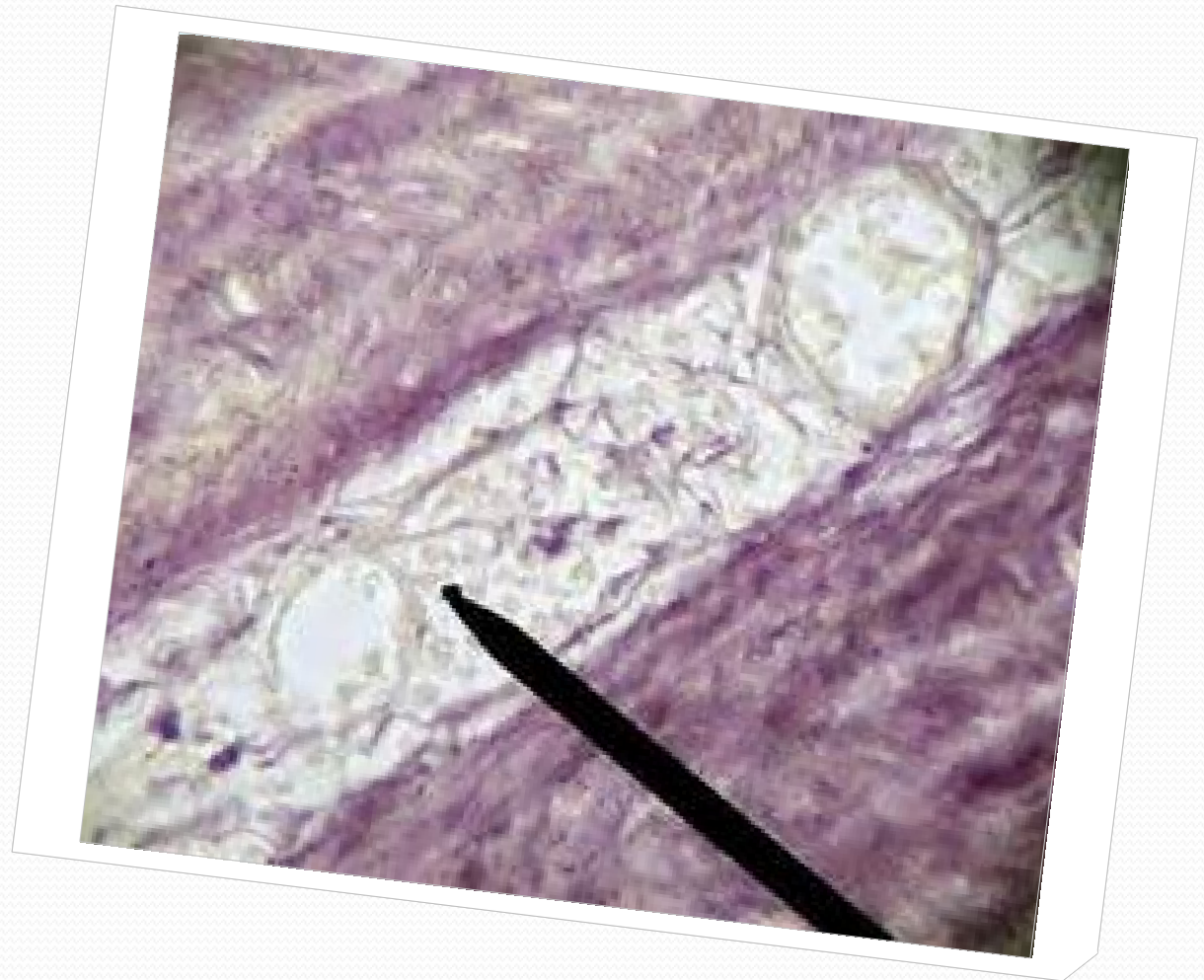
STOMACH?

HEPATIC PORTAL VEIN?

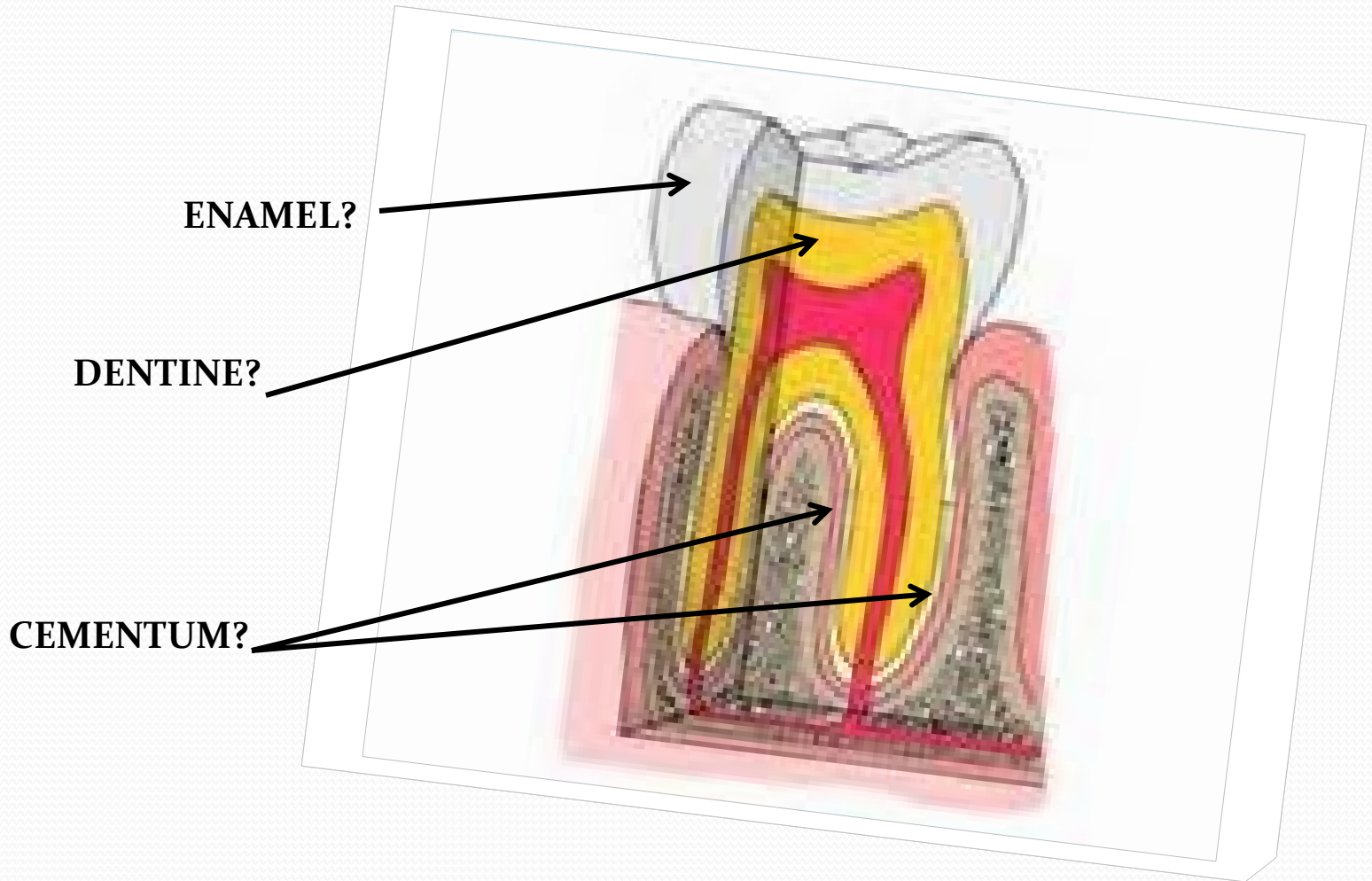


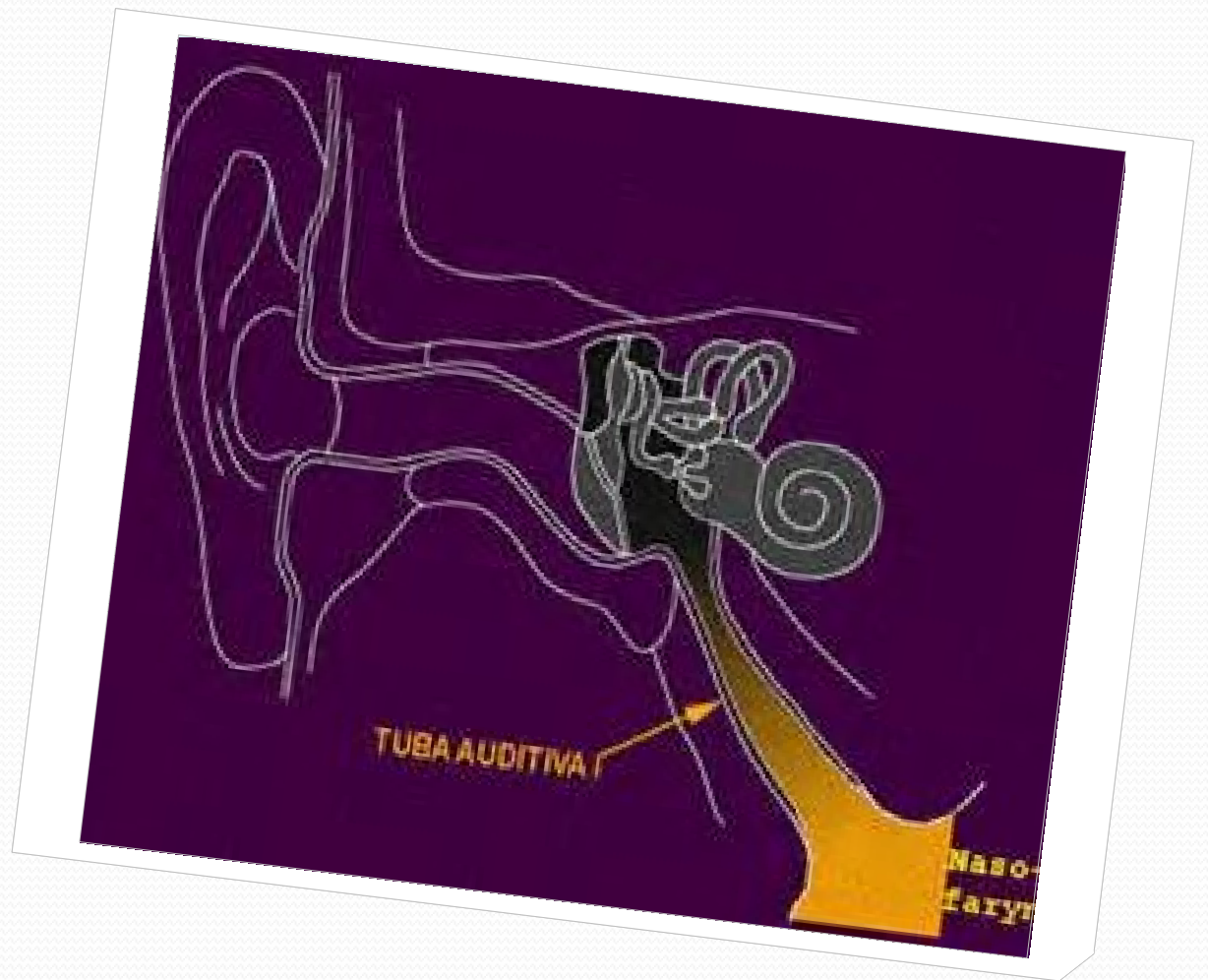
V____V_____??

*small blood vessels
that supply or drain
the walls of the larger
arteries and veins
and connect with a
branch of the same
vessel or a
neighboring vessel*

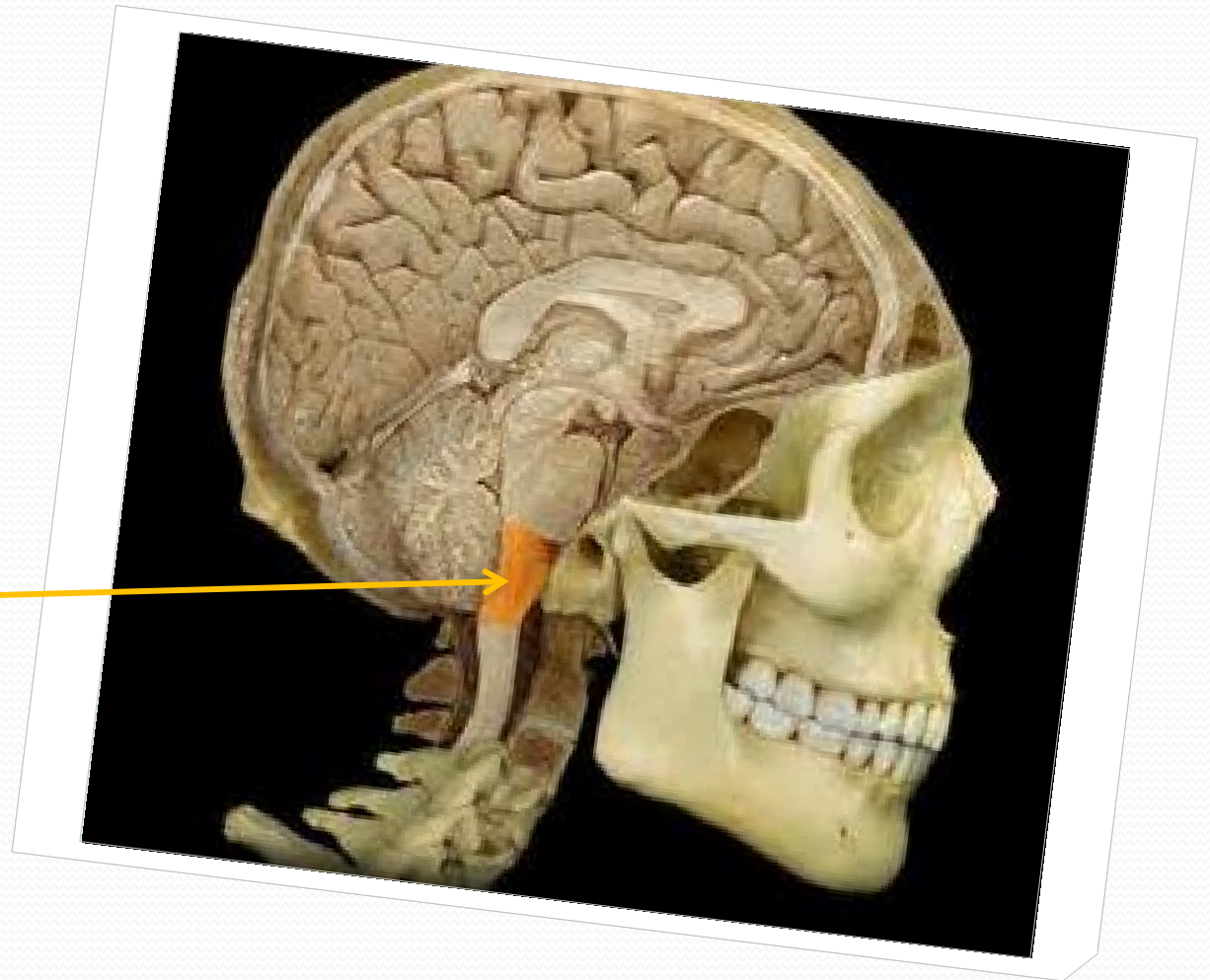


TOOTH?





**PROLONGATION OF
SPINAL CORD?**



SHINBONE?

CALF BONE?

