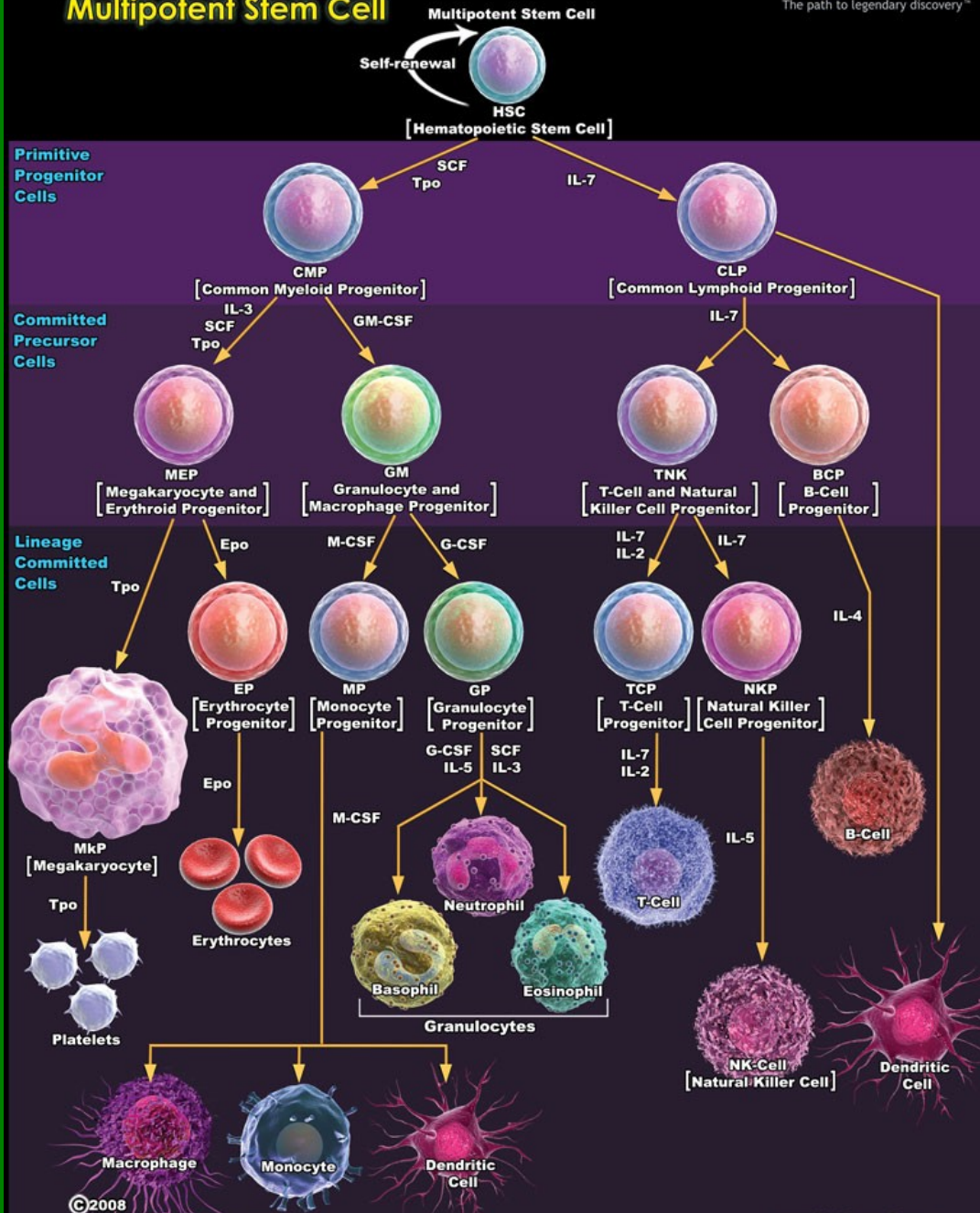
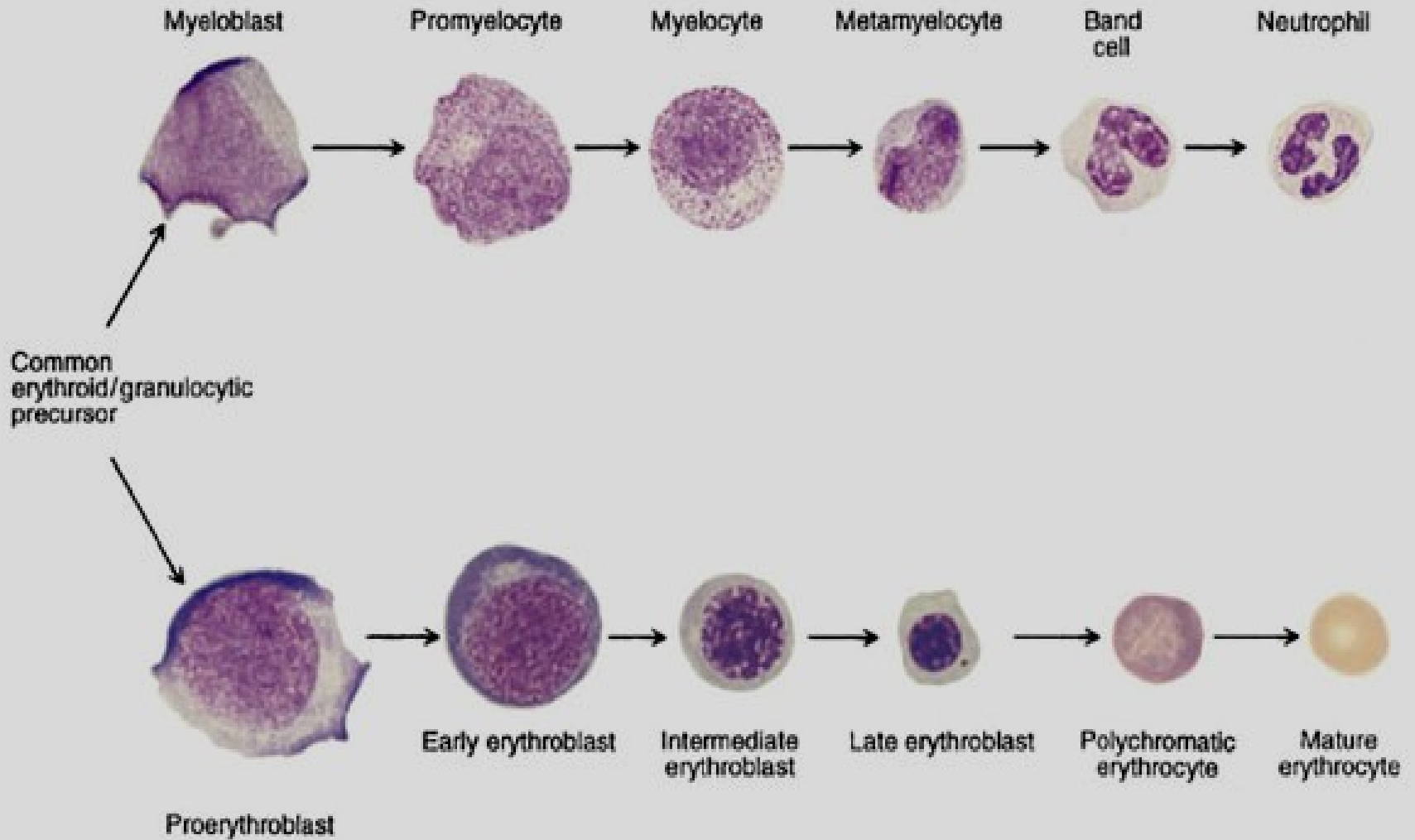


Hematopoéza

Bourková L., OKH FN Brno

Hematopoiesis from Multipotent Stem Cell






Sledování buněčných morfologických změn



A Cell size and cytoplasm color

zbarvení, obsah
cytoplazmy



B Nuclear size and color

velikost, tvar
jádra



C Nuclear chromatin structure

struktura chromatinu,
jadérka



D Composite (Left to right: Rubriblast, Pro-rubricyte, Rubricyte, Metarubricyte, Diffusely basophilic erythrocyte, Erythrocyte)

komplexní hodnocení

KOSTNÍ DŘEŇ

myeloblast

promyelocyt

neutrofilní myelocyt

eozinofilní myelocyt

bazofilní myelocyt

neutrofilní metamy

eozinofilní metamy

bazofilní metamy

proerythroblast

časný erythroblast
(bazofilní normoblast)

středně zralý erythroblast
(polychromní normoblast)

pozdní erythroblast
(ortochromní normoblast)

monoblast

promonocyt

makrofág

magakaryoblast

promegakaryocyt

megakaryocyt

lymfoblast

prolymfocyt

plazmat. b.

PERIFERNÍ KREV

neutrofilní tyč

eozinofilní tyč

bazofilní tyčí

retikulocyt

monocyt

trombocyty

lymfocyt

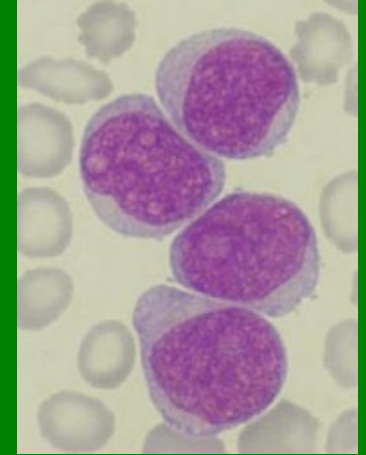
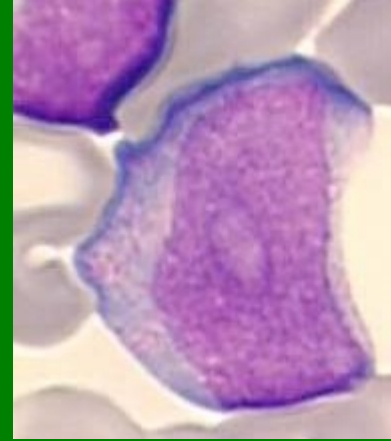
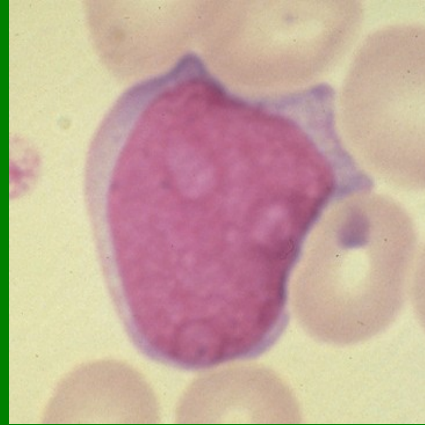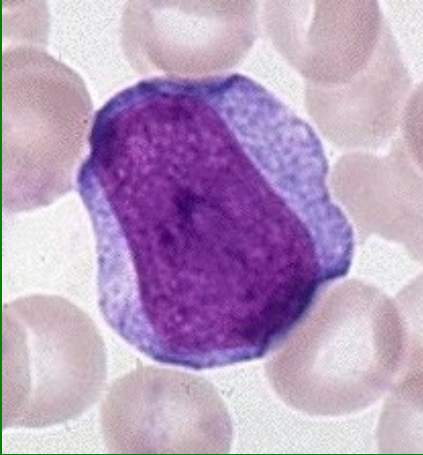neutrofilní segment

eozinofilní segment

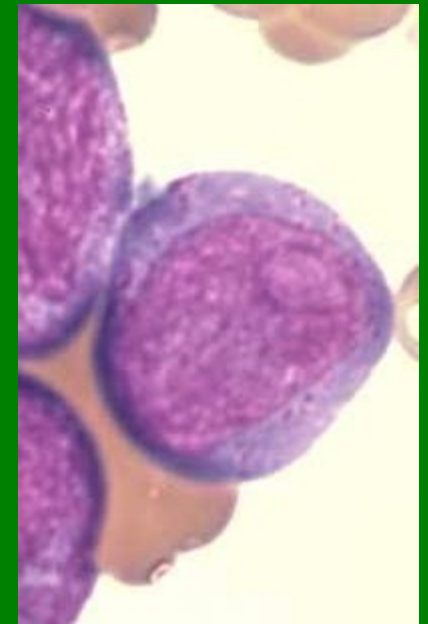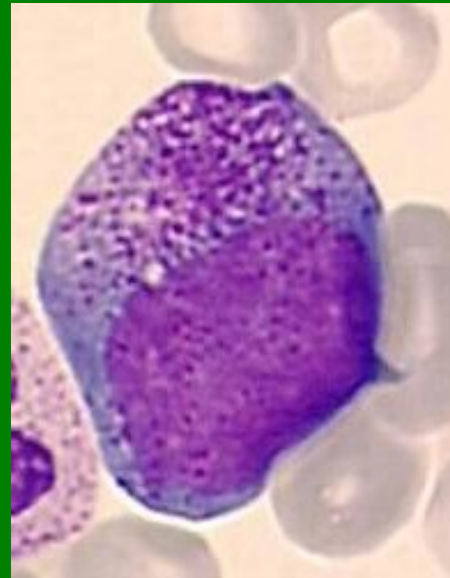
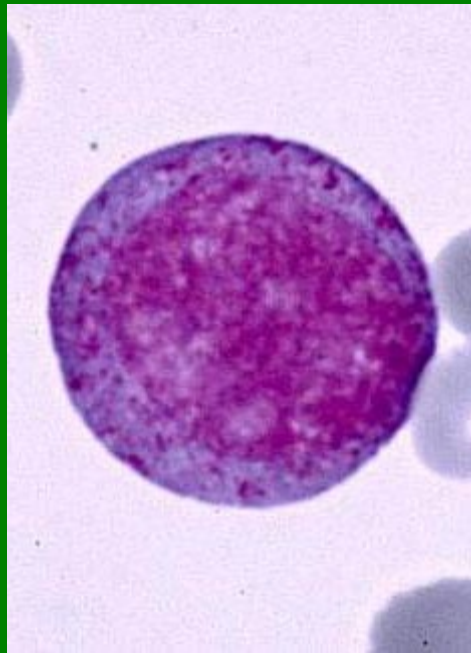
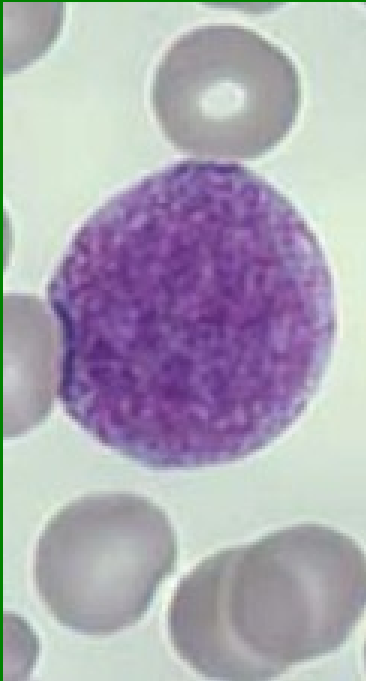bazofilní segment

erythrocyt

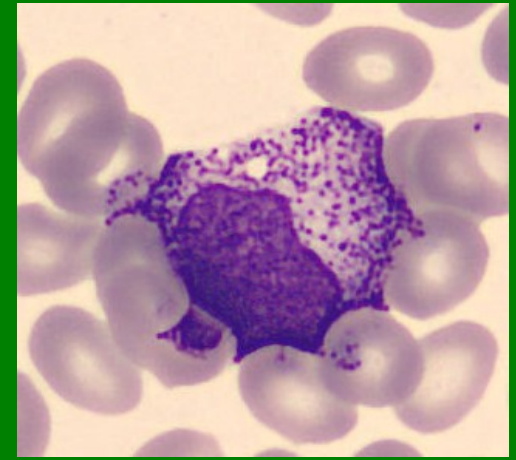
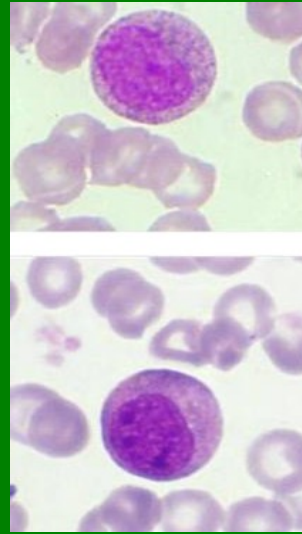
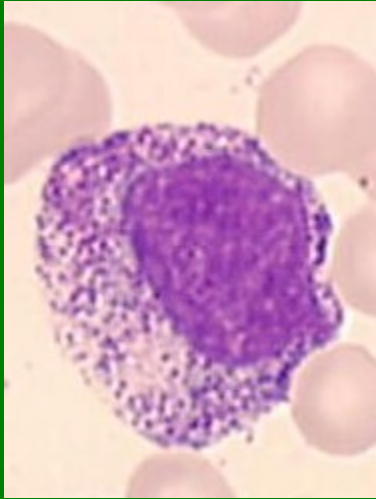
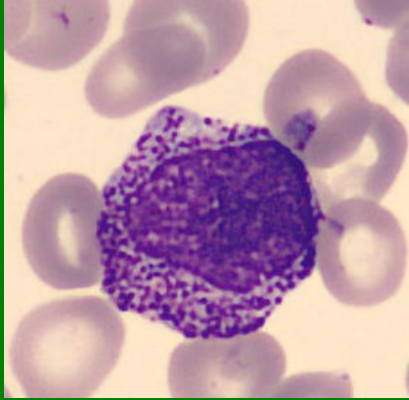
Myeloblasty



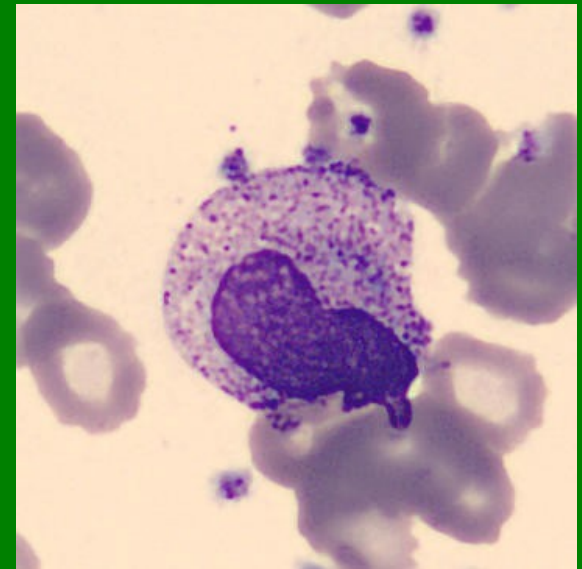
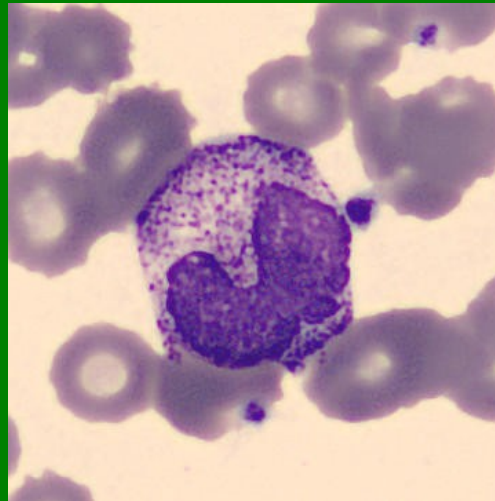
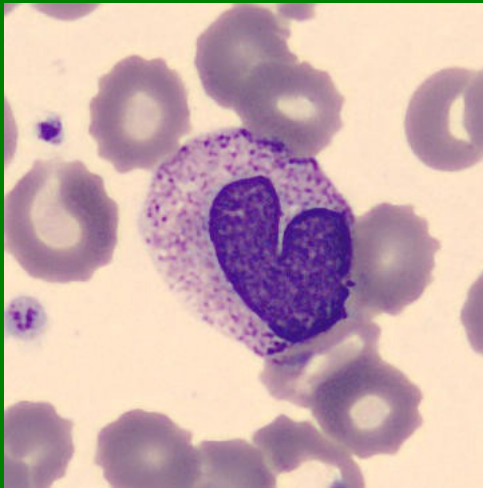Promyelocyty



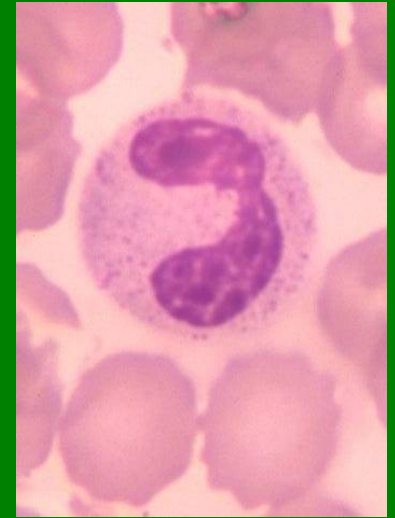
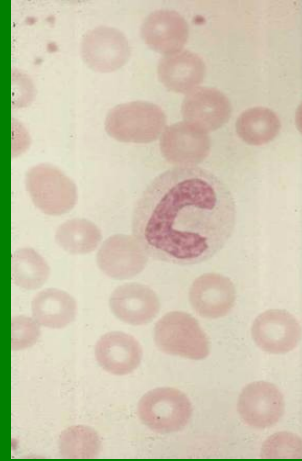
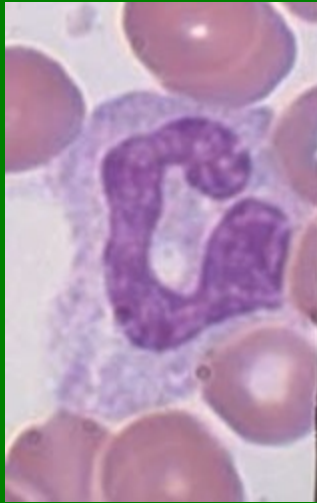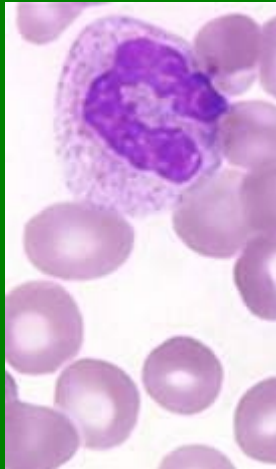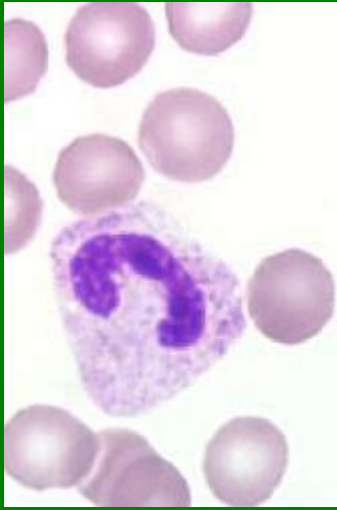Myelocyty - Ne



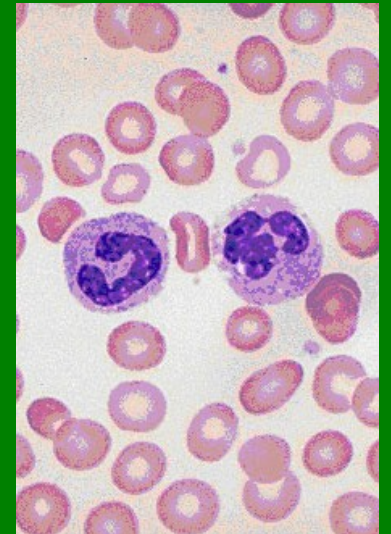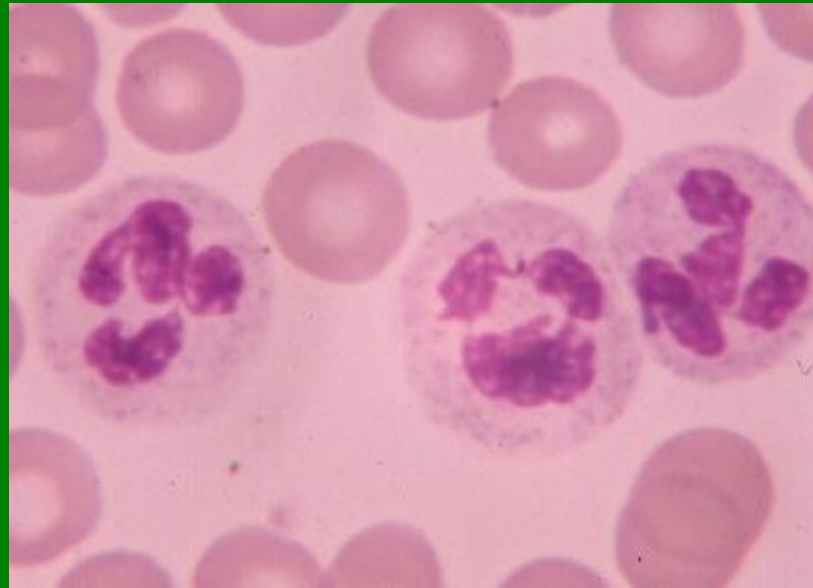
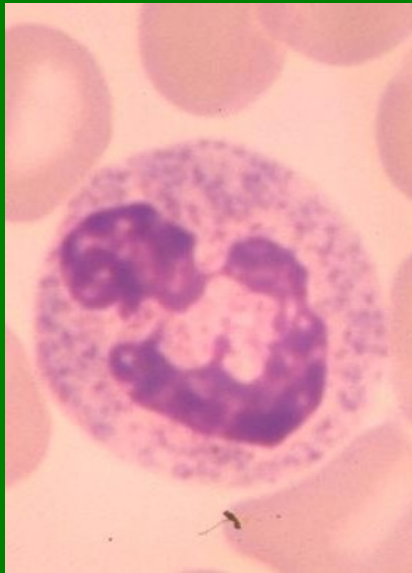Metamyelocyty - Ne



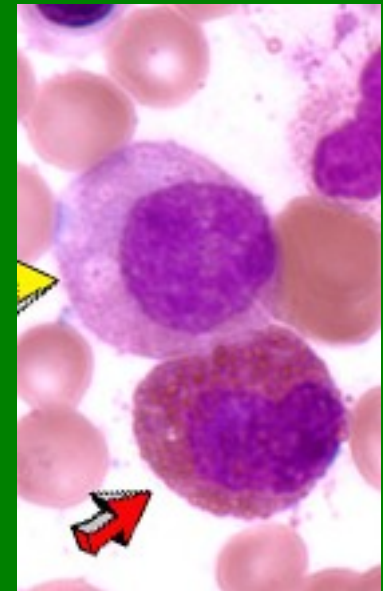
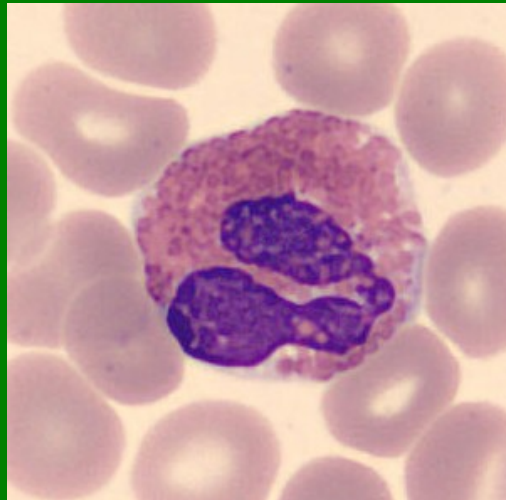
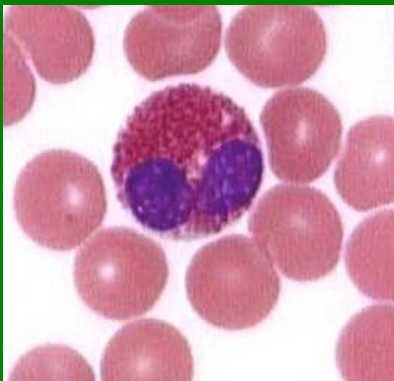
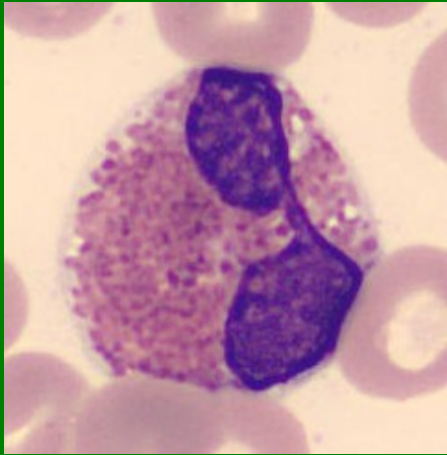
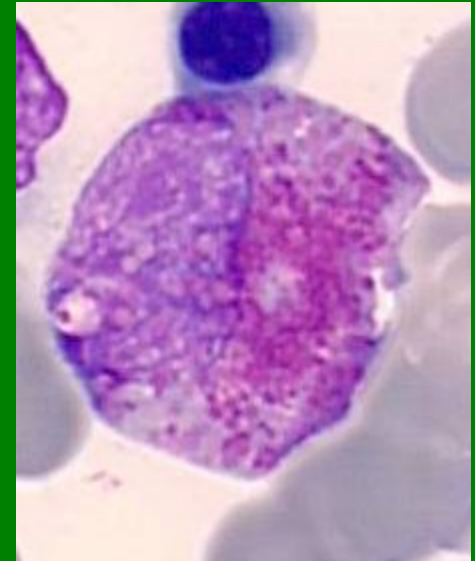
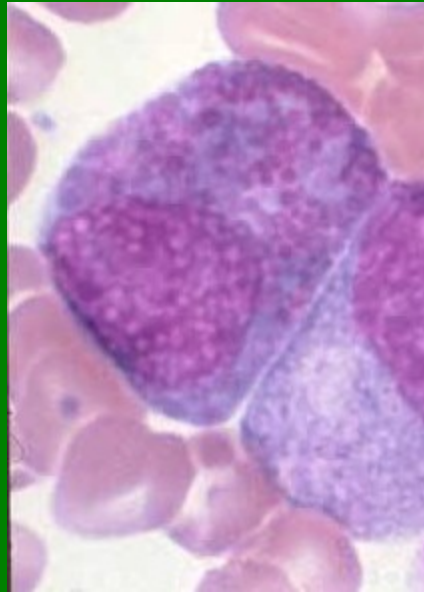
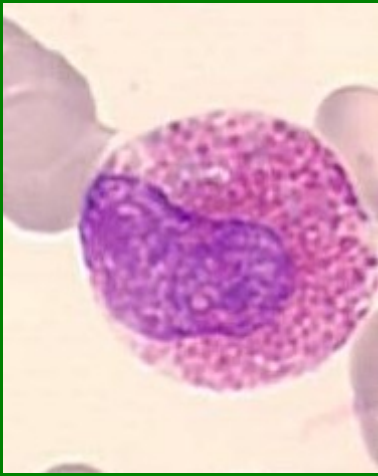
Tyč – Ne (rozdíl mezi nejširším a nejužším tvarem jádra je 1/3 až 1/2)



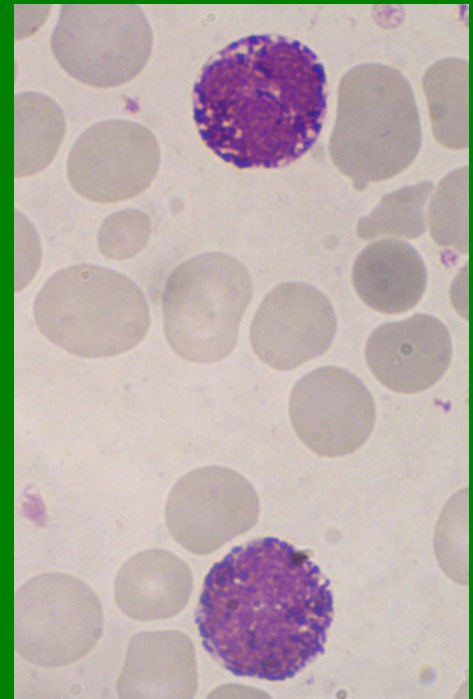
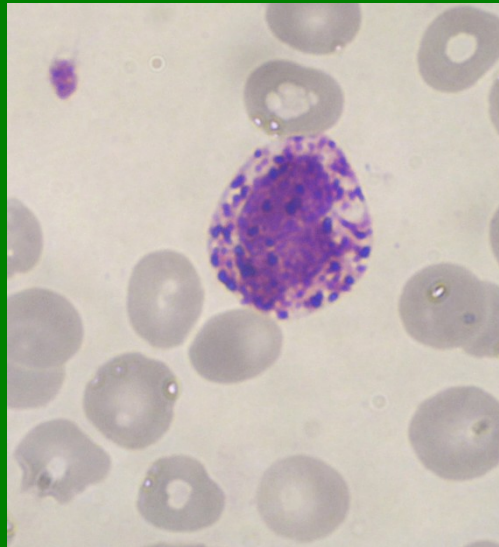
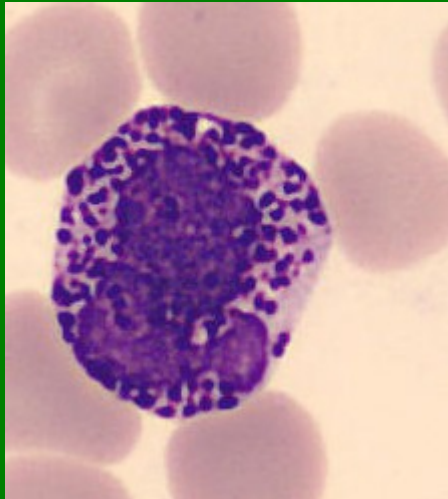
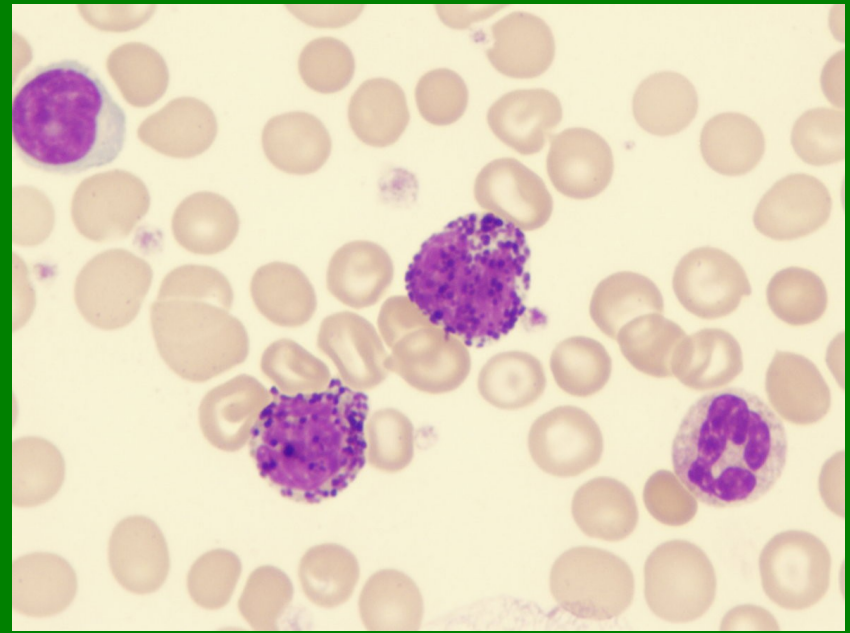
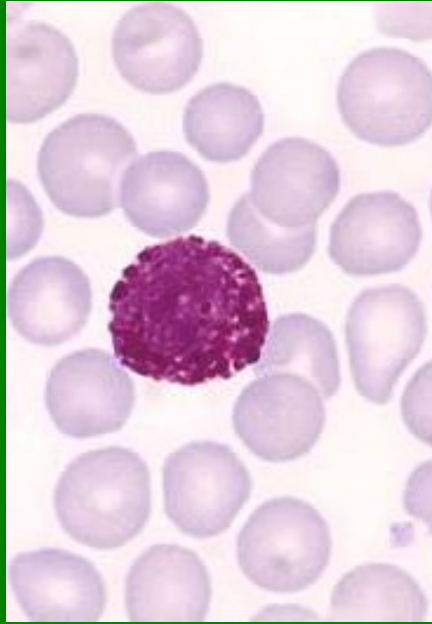
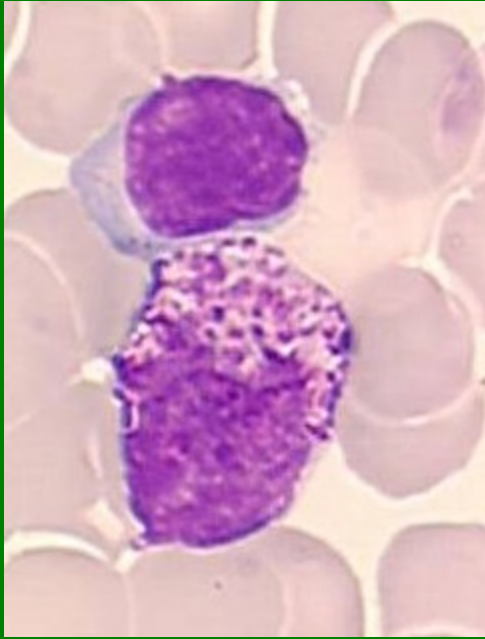
Segment - Ne



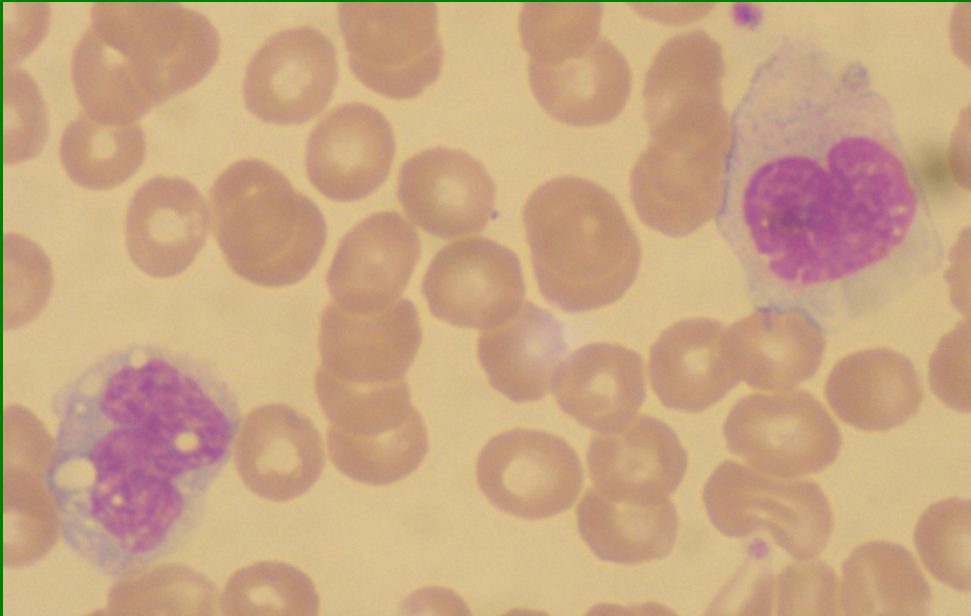
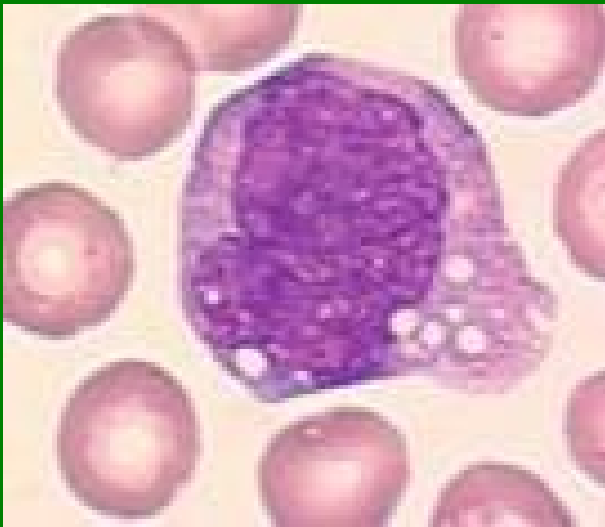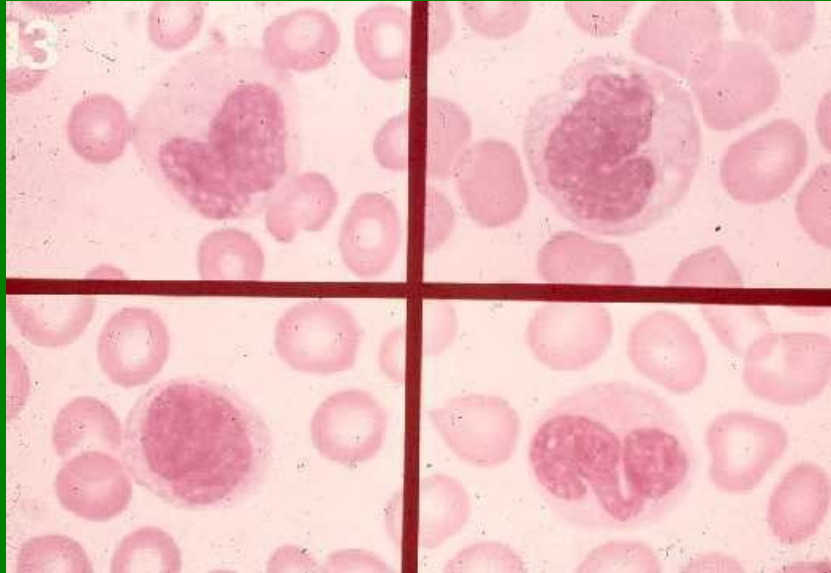
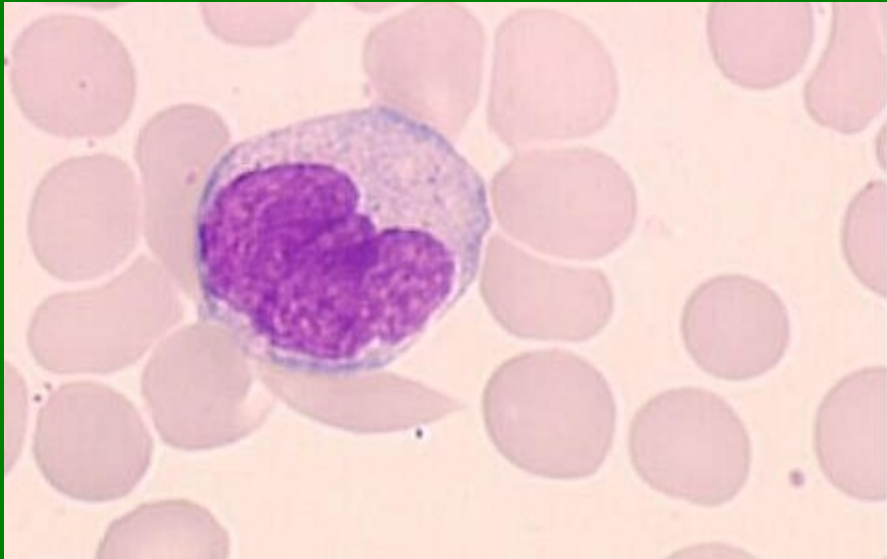Eozinofily



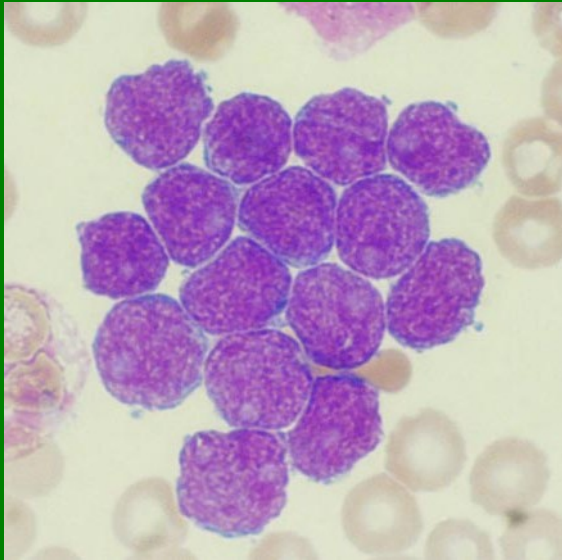
Bazofily



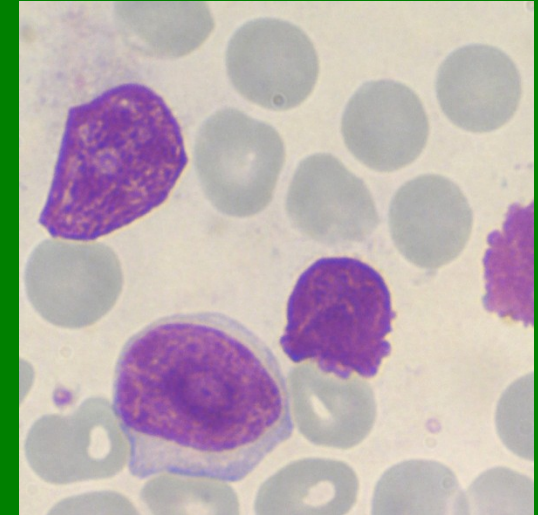
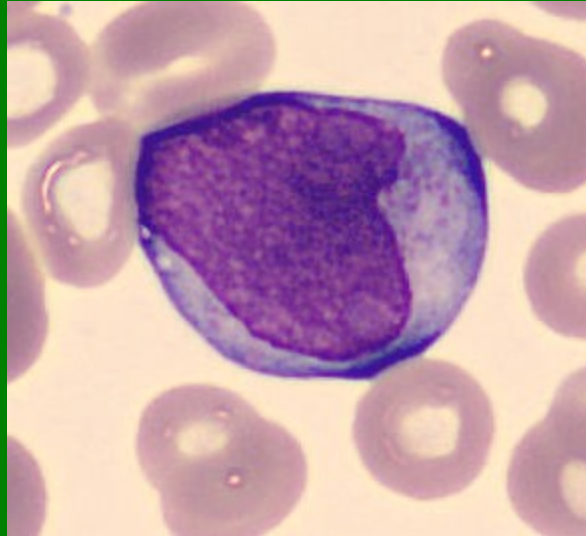
Monocyty



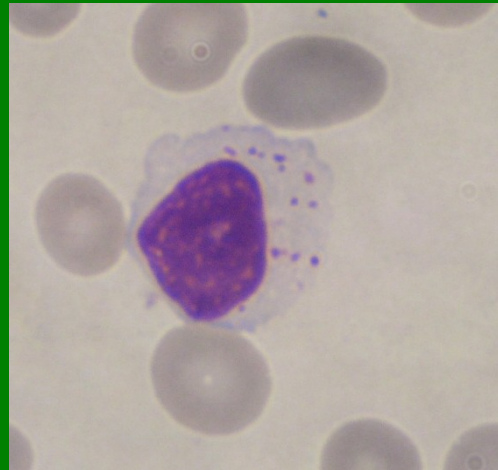
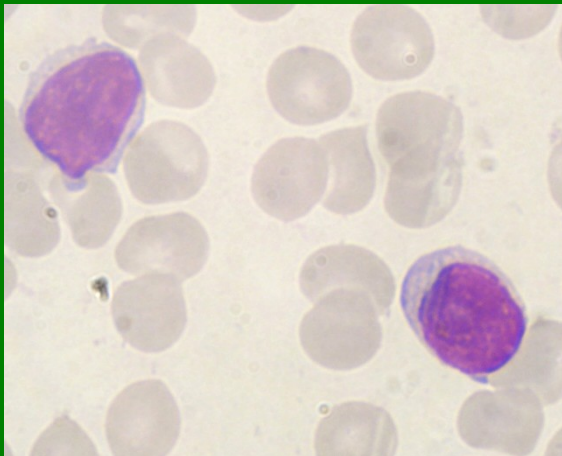
Lymfoblasty



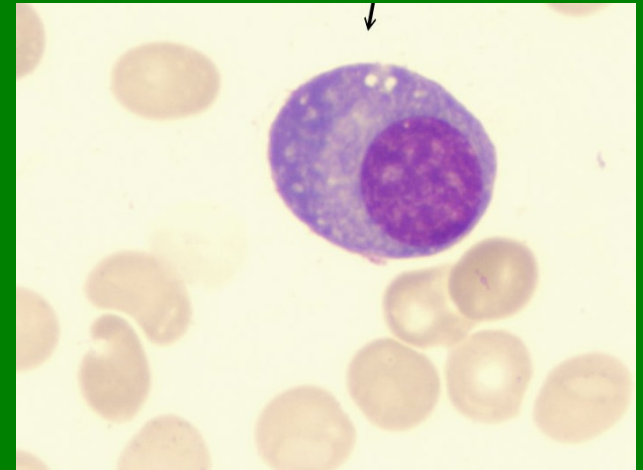
Prolymfocyt



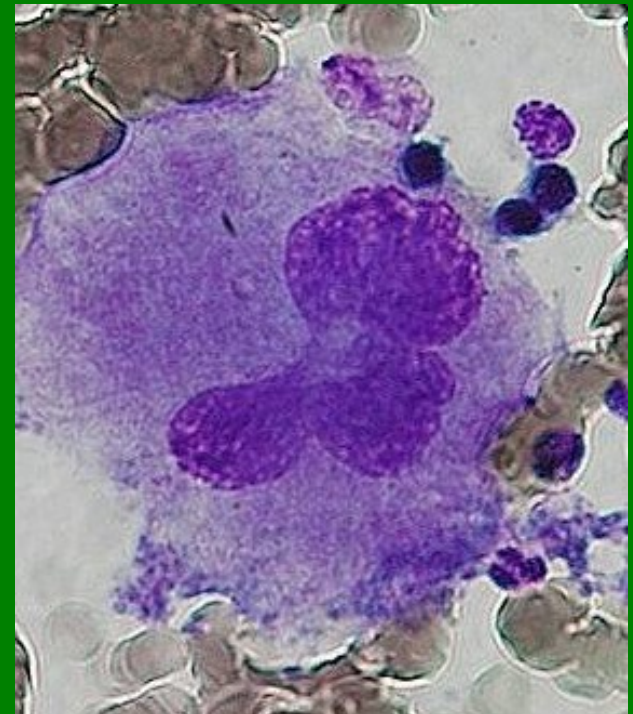
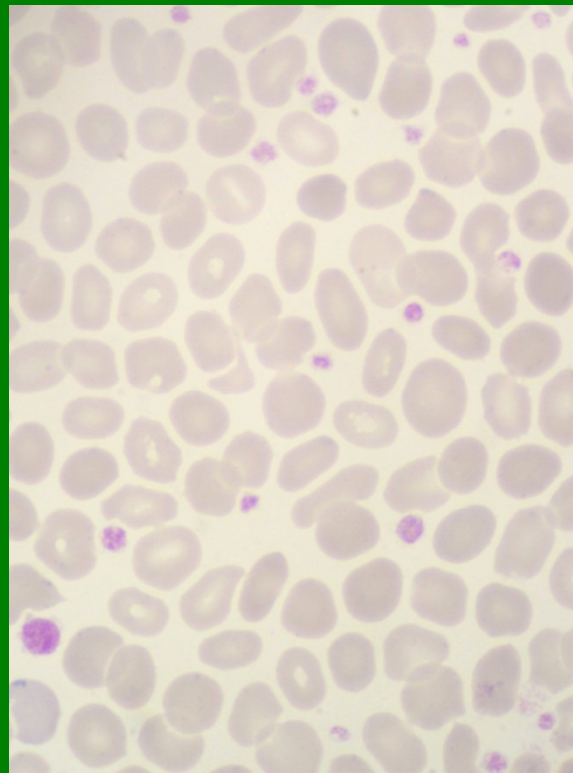
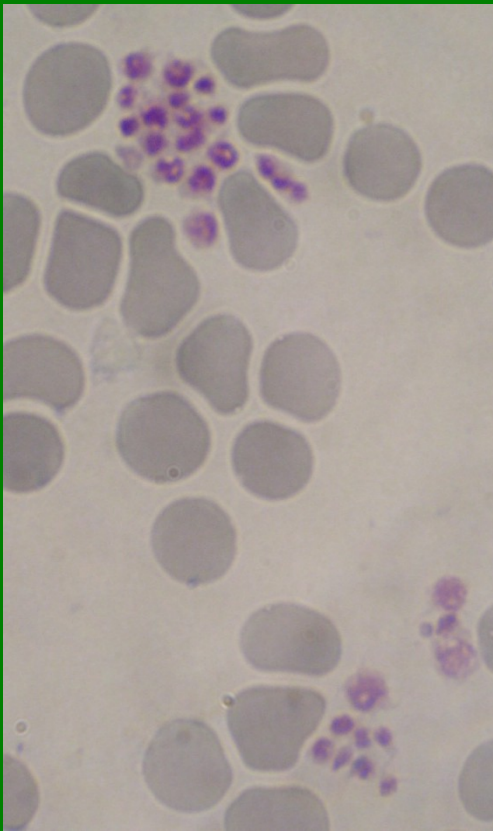
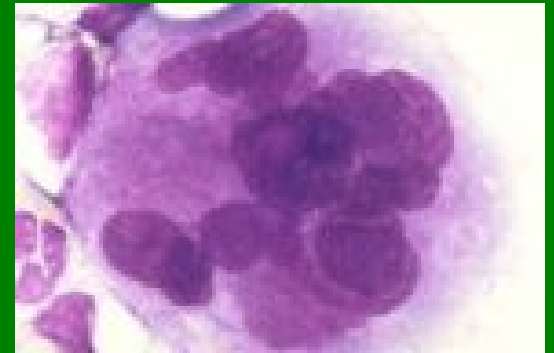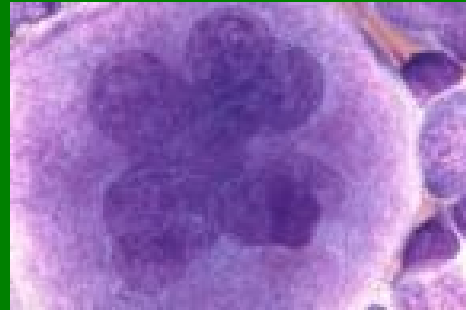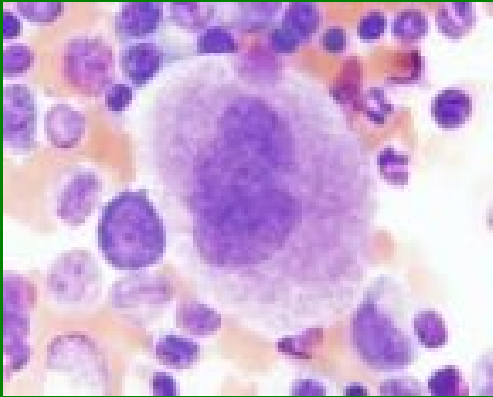
Lymfocyty



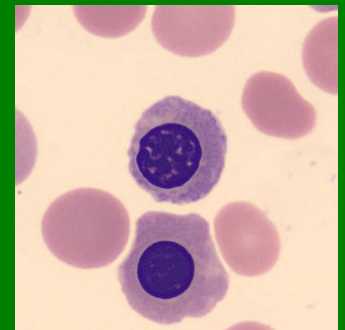
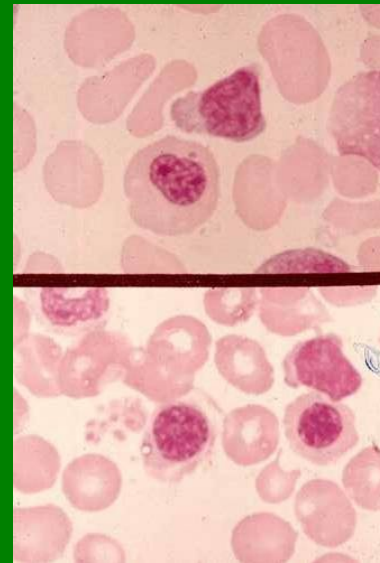
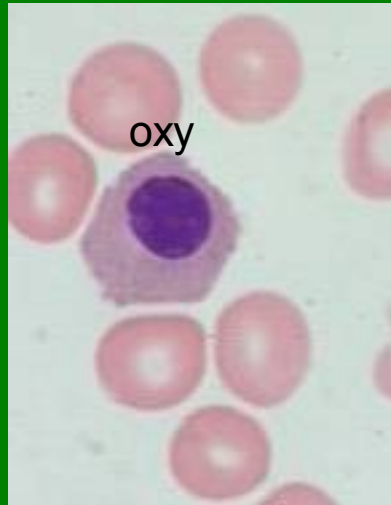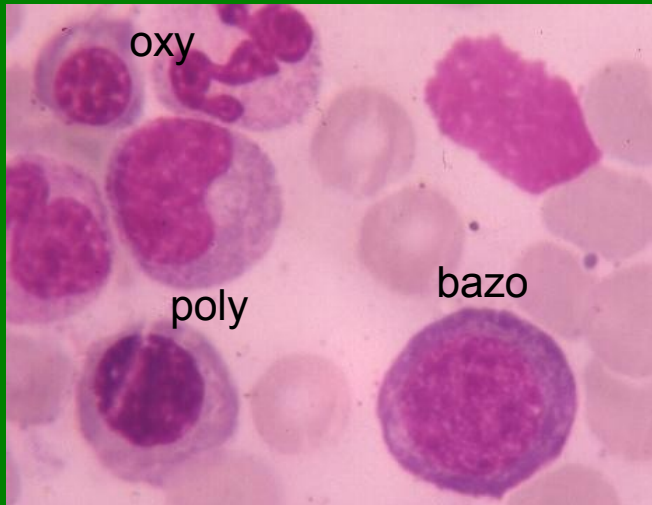
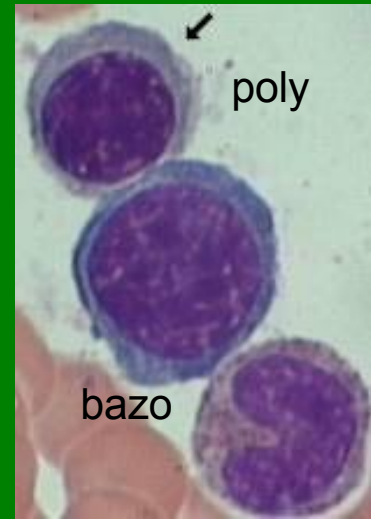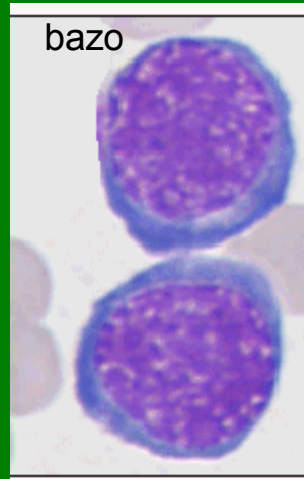
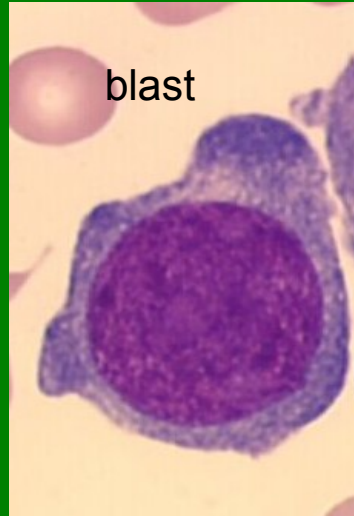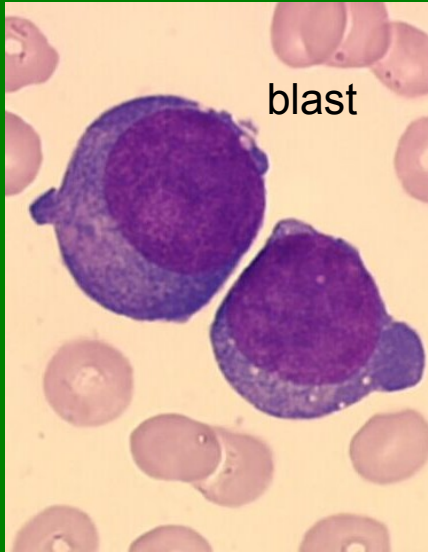
Plazmatická buňka



Megakaryocyty, PLT

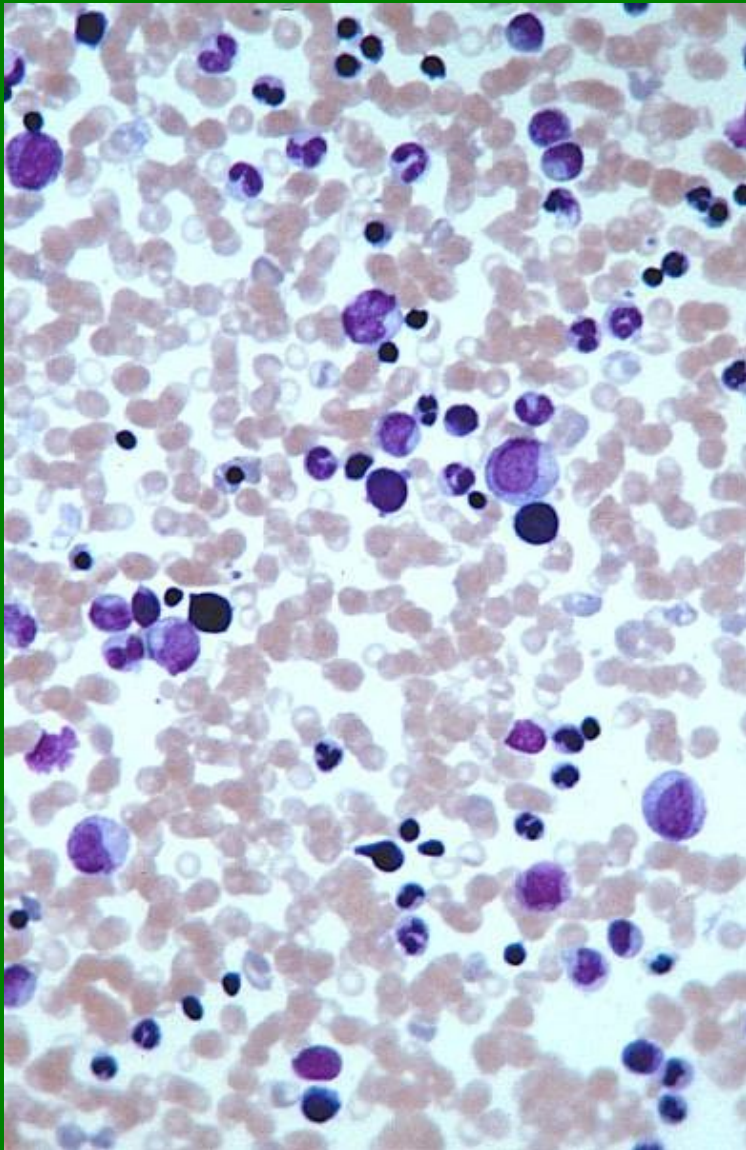


NRBC



Kostní dřeň - buněčnost

normální



vysoká

