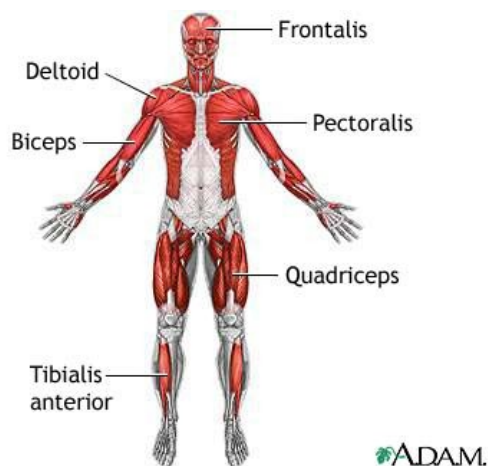


MUSCULAR SYSTEM

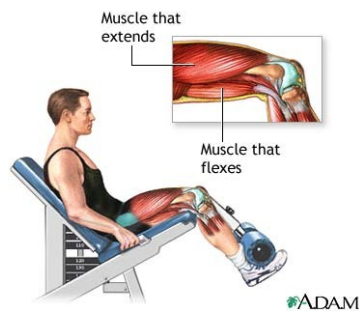
Skeletal Muscles

There are over 600 **skeletal muscles** that serve for **body movement** through **contraction** and **relaxation**. These muscles are **voluntary** (under conscious control), made up of **striated muscle fibres** (of two types: fast-twitch and slow-twitch), and attached to bones by **tendons**. The kinds of body movement include **locomotion, facial expressions, posture**, and other movements. Skeletal muscles also have **muscle tone** (partial contraction), maintained by ongoing signals from the nervous system, which helps maintain body posture and readiness for physical activity. Muscles account for approximately 40 per cent of body weight and the metabolism that occurs in this large mass produces the heat that is essential to the maintenance of body temperature.



Skeletal muscles form largely a system of pairs of muscles that contract and relax to move or bend a joint. For instance, when the anterior thigh muscle (the **quadriceps**) contracts, the knee straightens whilst the posterior thigh muscle (the **biceps**) relaxes. In this instance, the quadriceps of the thigh is referred to as the **agonist** (or prime mover), i.e. the muscle in state of contraction producing the prime, first motion. To bend the knee back again and return it to its original bent position, the biceps of the thigh contracts (pulls) whilst the quadriceps relaxes. Then, the contracting biceps is termed the

antagonist as it produces the opposing motion. Similar opposition is found in the upper arm between the biceps and the triceps (they bend the elbow joint). There are also **synergists**, muscles that help other skeletal muscles in their actions, and **fixators**, muscles that stabilise, or fix, ends of other muscles. Some skeletal muscles are also classified for their ability to straighten (**extend**) or bend (**flex**) joints, and thus whole limbs, as **extensors** and **flexors**, respectively.



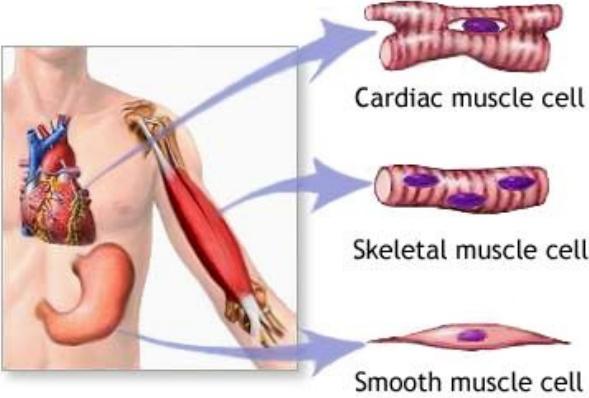
The Cardiac Muscle

The cardiac muscle (or **myocardium**, the middle muscular layer of the heart) is found only in the heart and it forms the **atria** (sing. atrium) and **ventricles**, i.e. the walls of the organ. Like the skeletal muscles, the cardiac muscle contains **striated fibres**, but unlike the skeletal muscles it is **involuntary** (not under conscious control). The muscle cells of the myocardium maintain a consistent **heartbeat** (or **heart rate**). The heart rate as observed in the arteries of the body is termed **pulse rate**, and it is recorded as the number of **beats per minute**.

Smooth Muscles

Smooth muscles are found throughout the body: in **internal organs**, **blood vessels**, and various **glands**. Similarly to the cardiac muscle, smooth muscles are **involuntary**, but in contrast to skeletal muscles and the cardiac muscle, they are not striated (or **nonstriated**). Smooth muscles within the walls of the digestive tract organs cause **peristalsis** (or vermiculation) which is the wave-like, worm-like movement of the intestine consisting of alternate circular contractions that aids in intestinal digestion and transport of food. Other examples of involuntary activities of smooth muscles are

constriction (closing) of the bronchioles, pupils of the eye or skin contraction in cold conditions (called colloquially **gooseflesh** or **goose pimples**; also goosebumps in American English).



ADAM.