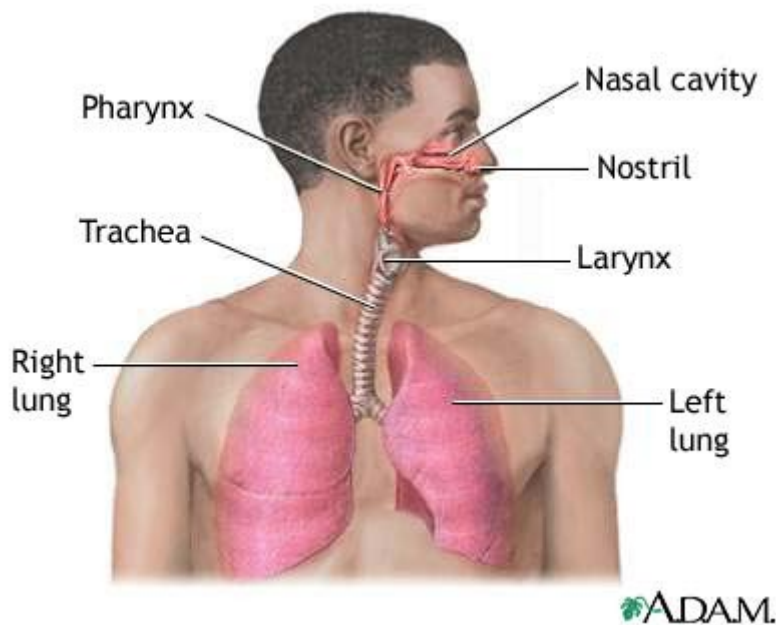


Respiratory System

Introduction

All the body cells metabolically consume oxygen, and **discharge** carbon dioxide. To cover this need, respiration takes place internally (at the cellular level) and externally (ventilation/breathing). **Ventilation** involves the **inhalation** of atmospheric air into the lungs via the nose and mouth through branching passageways, and the **exhalation** of carbon dioxide. The lung **key function** is to bring air and blood into intimate contact in **the alveolar air sacs** so that oxygen can enter the blood, and carbon dioxide can leave. **At rest**, humans breathe about twelve times a minute, bringing in approximately a pint of air. Exercise and certain diseases result in a marked increase of breathing. The respiratory system also is vital in maintaining normal blood pH and body temperature.



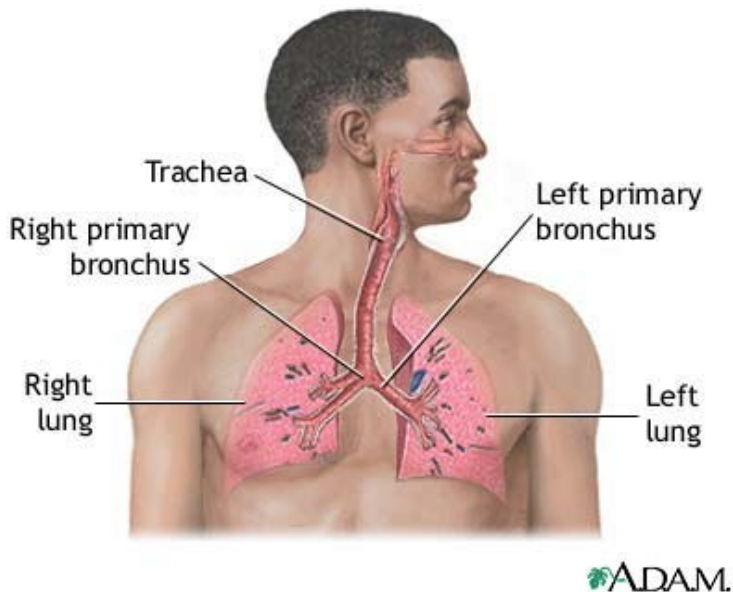
Lungs and air passages

The lungs are paired organs that lie on either side of the heart and fill up the thoracic (chest) cavity. Inferior to (below) the lungs is the **diaphragm**, a broad thin muscle that separates the thoracic cavity from the abdominal (**gut**) cavity. On the medial (inner) surface of each lung is the **hilus**, where blood vessels, nerves, and **bronchi** (air passages) enter the lungs.

The lungs differ in size and shape. Because the heart is slightly larger on the left side, the left lung has a **cardiac notch** (indented border). The left lung is also slightly smaller than the right. Each lung is divided into **lobes** (partitions) by **fissures**. The right lung has three lobes:

lower, middle, and upper. These horizontal and oblique fissures create these lobes. The left lung has upper and lower lobes that are divided by the oblique fissure.

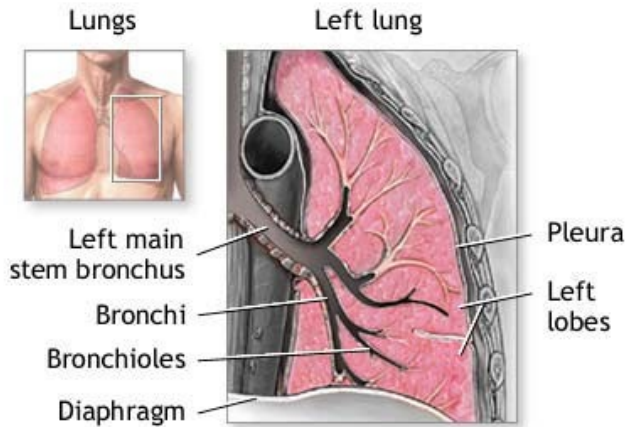
Air enters the body through the mouth or nose. In the nose, thick hairs lining the **nostrils** prevent small objects from entering the **nasal cavity**. This cavity is lined with cells that produce **mucus**. Small foreign matter that enters the nasal cavities is trapped in the mucus, while tiny cilia (small hair-like projections) push the mucus to the pharynx (throat), where it is swallowed and digested in the stomach or **expectorated**.



From the **pharynx**, the air passes to the **larynx**, which is called the **voice box** because it contains the **vocal cords**. To prevent food or liquid from entering the larynx, the **epiglottis** (a small flap of tissue) closes over the opening of the larynx during **deglutition** (swallowing). If this process works improperly, a cough reflex **expels** the foreign material.

When air travels past the larynx, it enters the **trachea (windpipe)**. The trachea is a strong tube containing rings of **cartilage** that prevents it from collapsing. The **mucosa** that lines the airway warms and **moistens** the air before it reaches the trachea.

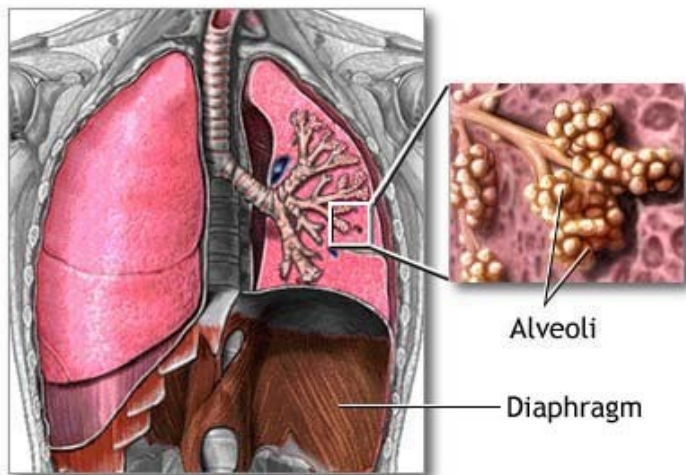
Within the lungs, the trachea **branches into** a left and right **bronchus**, which divide into increasingly smaller branches called **bronchioles**. The smallest bronchioles end in a cluster of air sacs, collectively called an **acinus**. The acinus comprises individual air sacs called **alveoli**. Alveoli are like small balloons that **inflate** and deflate with air during respiration.



ADAM.

Gas exchange

Gas exchange occurs in the lungs between the alveoli and a capillary network within the alveolar wall. Capillaries are microscopic blood vessels that exchange material between the blood and body tissues. In the lung capillaries, blood from tissues where cellular metabolism is occurring is called deoxygenated blood because it contains many carbon dioxide molecules and few oxygen molecules.

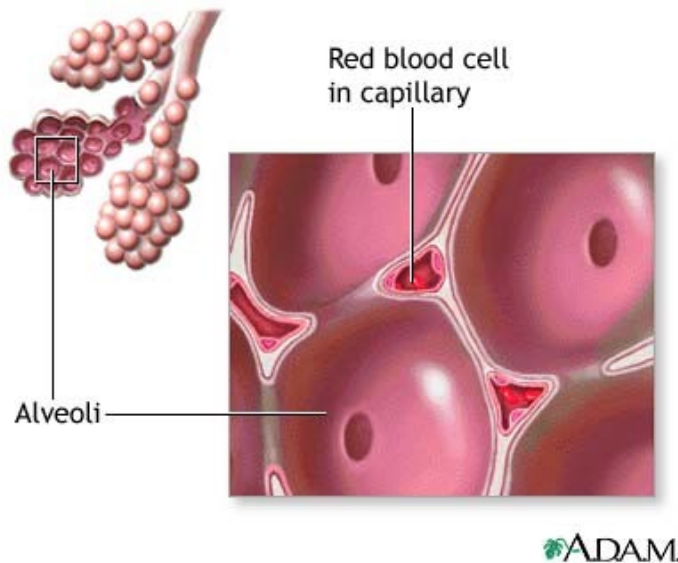


ADAM.

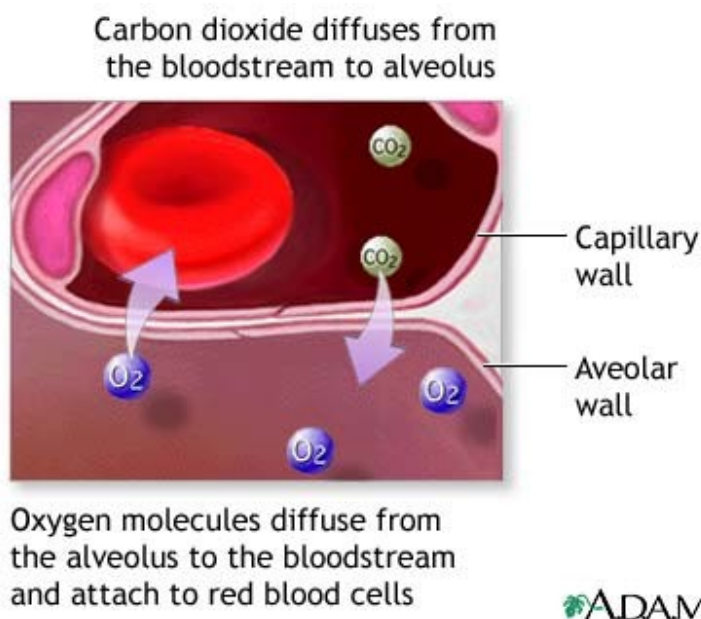
Respiration

The respiration process has two parts: **inspiration** (inhaling) and **expiration** (exhaling). During inspiration, the **diaphragm** contracts, moves downward, and causes the **thoracic cavity** volume to increase. Because the lungs are closely associated with the interior chest wall, they expand as the thoracic cavity expands. When the diaphragm relaxes (upward

position), the thoracic volume decreases and the lungs partially **deflate**. This process is called expiration. The elastic recoil of the expanded thoracic wall and lungs also helps expiration.



After inhalation, the alveoli contain many oxygen molecules. The alveoli are in close contact with the capillary network. This **proximity** enables the **minuscule** oxygen molecules to diffuse (pass freely) from the alveolus to the bloodstream, flowing from a region of higher concentration to a region of lower concentration. In the bloodstream, the oxygen attaches to red blood cells and is transported to the rest of the body. Likewise, carbon dioxide diffuses from the bloodstream into the alveolus where it is transported out of the body during exhalation.



During respiration, the **pleurae** (pleural membranes) help the lungs to expand and contract. These membranes are sacs that tightly cover the lungs and the chest inside wall. Between these two linings is a space called the **pleural cavity** that contains a thin layer of fluid. This fluid allows the lungs to move freely against the thoracic cavity inside.