

Mechanical Ocular Trauma

Došková Hana, MD.

Department of Ophthalmology

Medicine Faculty of Masaryk University Brno

General Considerations

- Ocular trauma constitute about 6% of all injuries, but eyes set up only 0,1% from the surface of human body.
- Ocular trauma can result in a wide spectrum of tissue lesions of the globe, optic nerve and adnexa, ranging from relatively superficial to vision threatening.
- Consequently, the socioeconomic impact of ocular trauma can hardly be overestimated. Those affected often have to face:
 - loss of career opportunities
 - major lifestyle changes
 - permanent physical disfigurement

Ocular Trauma Epidemiology

Who is at Risk

- approximately 80% of injured are males

The Site

- the workplace has been most common site
- domestic injuries has been increasing

The Source

- blunt objects (rocks, fists, wood branches, baseballs, champagne corks)
- work-related injuries
- sports and recreational activities
- hammering on metal and nails
- firearms and fireworks

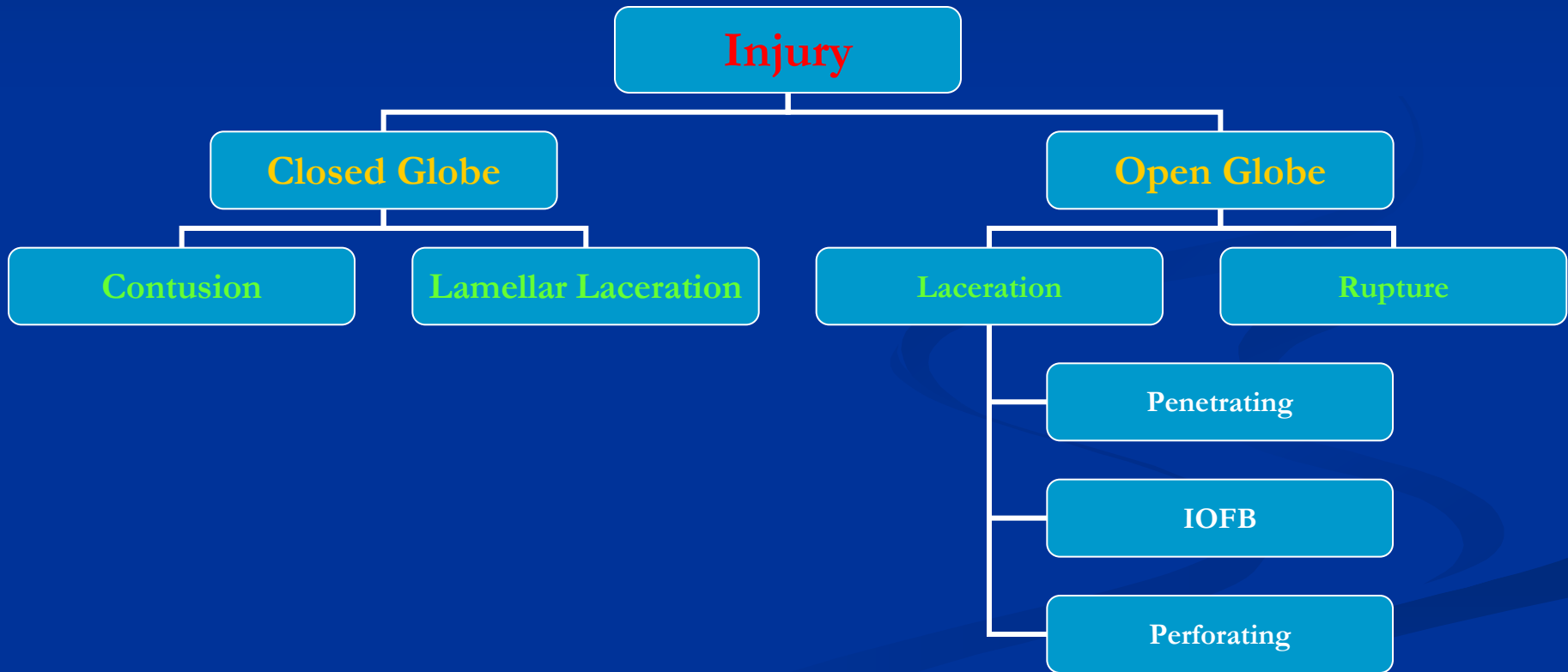
Terminology of Ocular Trauma

Without a standardized terminology of eye injury types, it is impossible to communicate between ophthalmologists.

BETT – Birmingham Eye Trauma Terminology

BETT satisfies all criteria for standard terminology by providing a clear definition for all injury types and placing each injury type within the framework of all comprehensive system.

BETT



Terms and Definitions in BETT

■ Eyewall

Sclera and cornea.

■ Closed Globe Injury

No full-thickness wound of the eyewall.

■ Open Globe Injury

Full-thickness wound of the eyewall.

■ Contusion

No wound.

The injury is due to either direct energy delivery by the object or changes in the shape of the globe.

■ Lamellar laceration

Partial-thickness wound of the eyewall.

■ Rupture

Full-thickness wound of the eyewall caused by a blunt object.

Because the eye is filled with incompressible liquid, the impact results in momentary increase in intraocular pressure (IOP). The eyewall yields at its weakest point. The actual wound is produced by an „inside-out“ mechanism.

Terms and Definitions in BETT

■ Laceration

Full-thickness wound of the eyewall caused by a sharp object.

The wound occurs at the impact site by an „outside-in“ mechanism.

■ Penetrating injury

Entrance wound of the eyewall.

If more than one wound is present, each must have been caused by a different agent.

■ IOFB

Retained foreign object.

■ Perforating injury

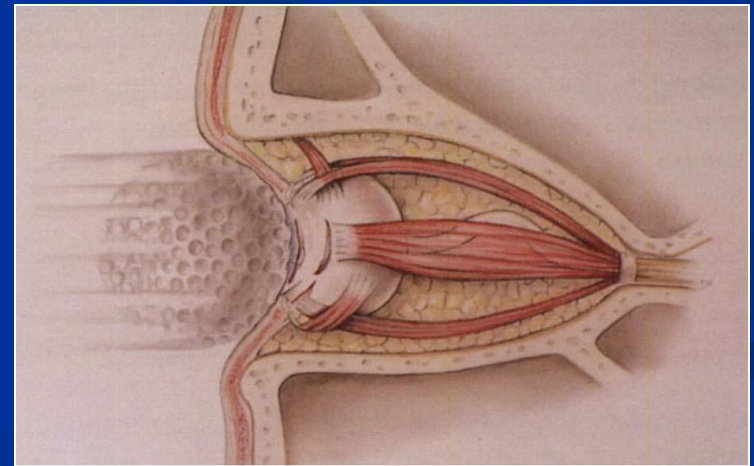
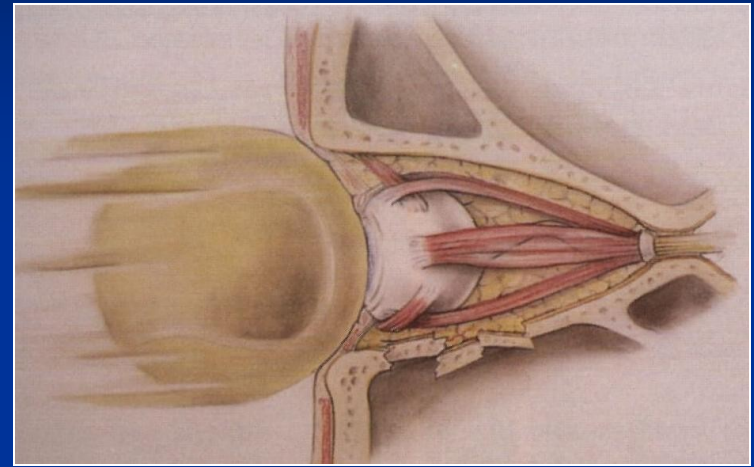
Entrance and „exit“ wound.

Both wounds caused by the same agent.

Closed Globe Contusion

Etiology

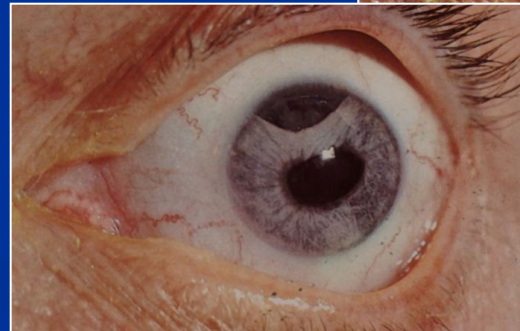
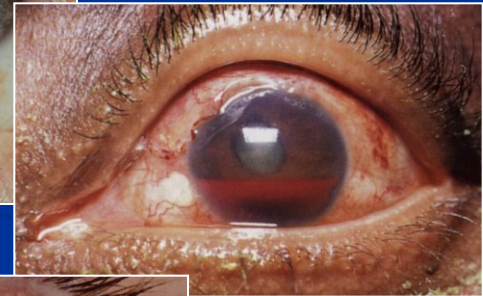
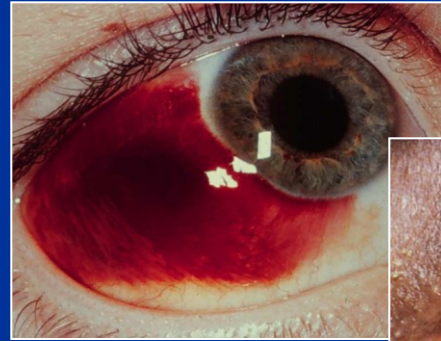
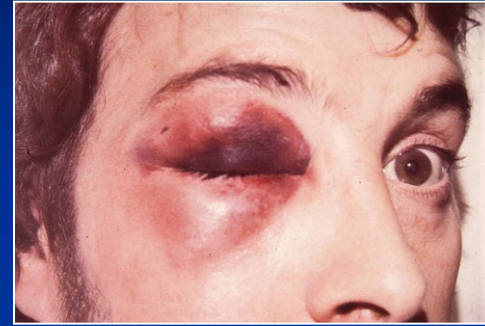The injury is due to either direct energy delivery by the object or changes in the shape of the globe (*flying objects, falls on the blunt objects, manual forces..*).



Contusion

Clinical findings

- Swelling and haematoma of the lids
- Subconjunctival haemorrhage
- Hyphaema
- Iridodialysis and plegia of the pupil
- Secondary glaucoma



Contusion

Clinical findings

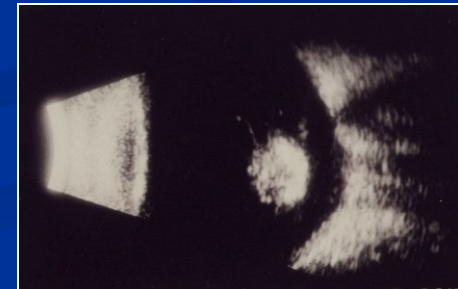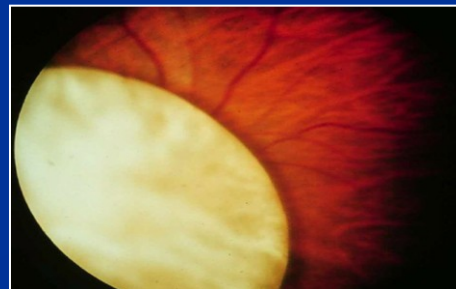
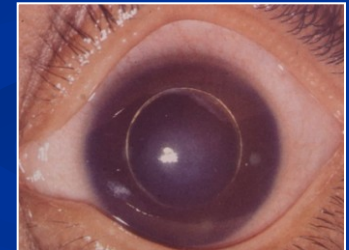
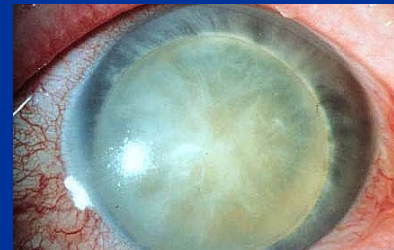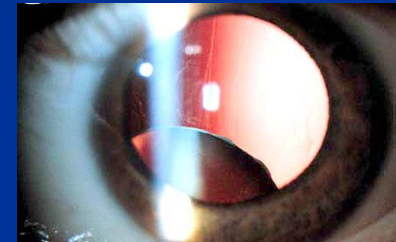
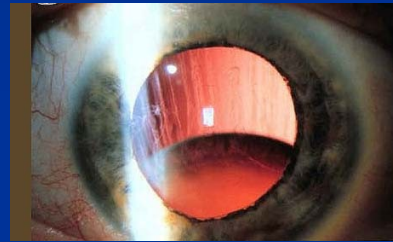
■ Disorders of the lens

subluxation

luxation

✓ *anterior (in anterior chamber)*

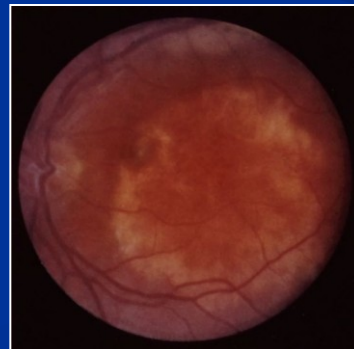
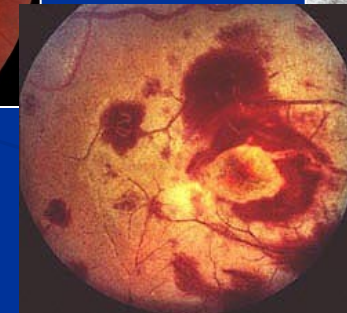
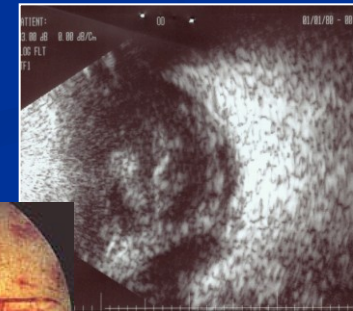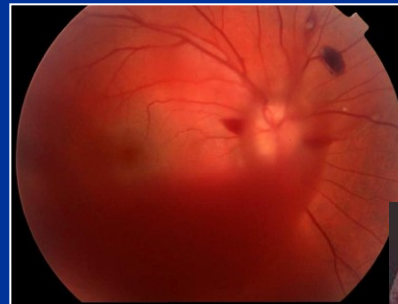
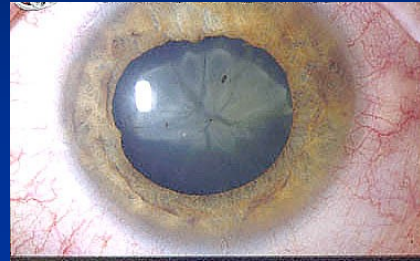
✓ *posterior (in vitreous body)*



Contusion

Clinical findings

- Disorders of the lens
traumatic cataract
- Haemorrhage in vitreous body
(haemophthalmus)
- Retinal haemorrhage
- Ischemic swelling of the retina



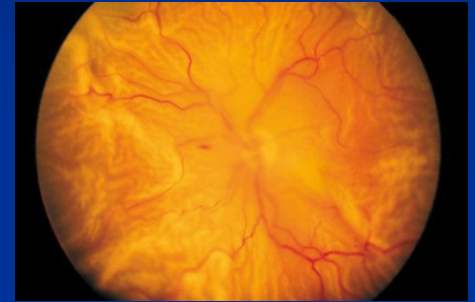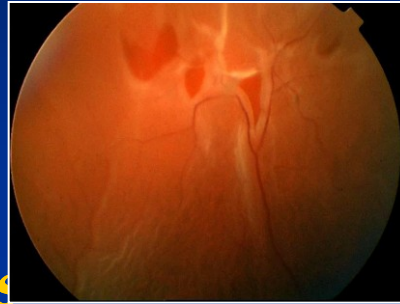
Contusion

Clinical findings

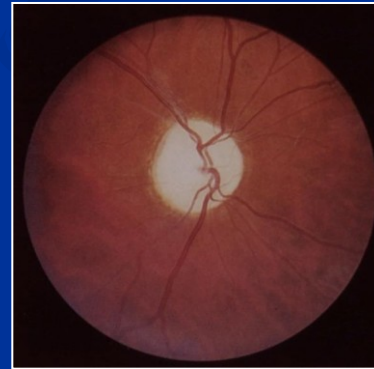■ Retinal detachment

✓ *retinal breaks and holes*

✓ *detachments*



■ Optic nerve atrophy



Contusion

Examination:

Case and personal history, visual acuity, intraocular pressure measurement, slit lamp, ophthalmoscopy, ultrasound B mode, CT scan.

Treatment:

- **medical** - antiglaucoma therapy, reabsorb therapy
- **surgical** - lavage of anterior chamber (bleeding without spontaneous resorbence), lens extraction (subluxation, luxation or cataract), pars plana vitrectomy (haemophthalmus, retinal detachment).

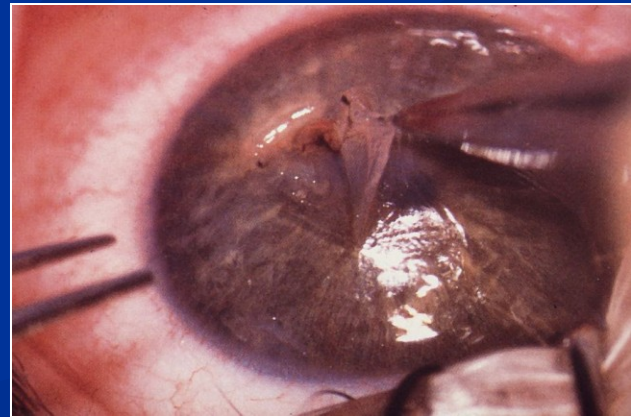
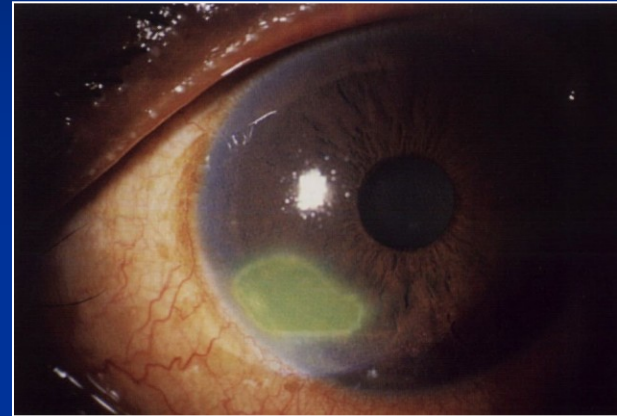
Lamellar laceration

Partial-thickness wound
of the eyewall
(conjunctiva, sclera or
cornea).

Etiology:

Abrasion of the cornea,
section and slash
wound (conjunctiva,
cornea, sclera)

Clinical findings:



Lamellar laceration

Examination:

Visual acuity, slit lamp, intraocular pressure (non contact tonometry), ophthalmoscopy, ultrasound.

Treatment:

- **medical** - antibiotic therapy (drops and ointments), contact lens
- **surgical** – wound suture

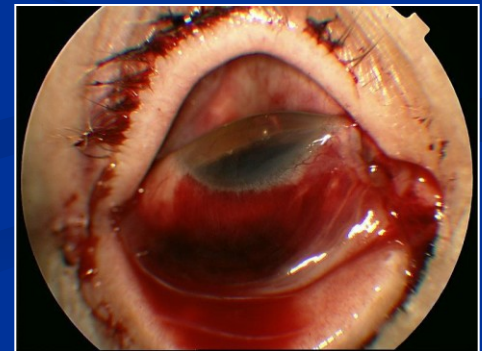
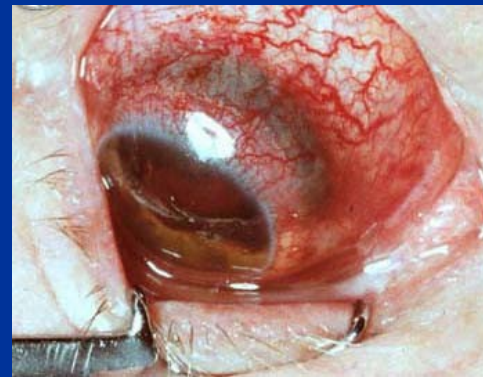Open Globe Rupture

Etiology:

Full-thickness wound of the eyewall caused by a blunt object.

Clinical findings:

- **Cover rupture** - prolapsus of intraocular tissue is beneath conjunctiva
- **Uncover rupture** – prolapsus is over conjunctiva



Rupture

Clinical findings:

Low visual acuity, hypotony of the eye, bleeding in anterior chamber and vitreous body, perilimbal wound, prolapsus of intracocular tissue (iris, lens, vitreous body...).

Examination:

Visual acuity, slit lamp, ultrasound

Treatment:

Only surgical with systemic and topical antibiotics.

Open Globe

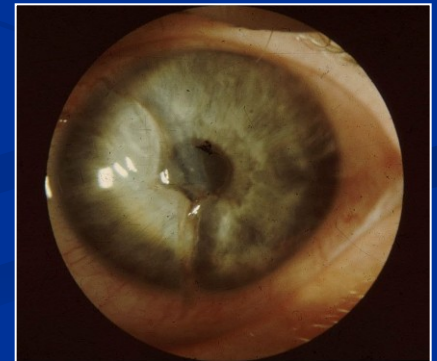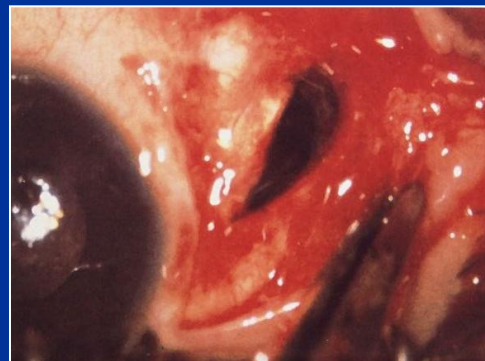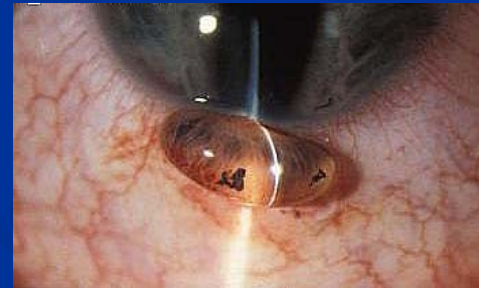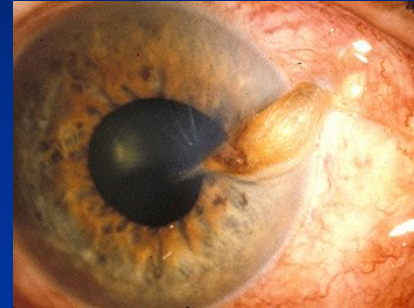
Laceration – penetrating injury

Etiology:

One entrance wound of the eyewall (section and slash wound of conjunctiva, cornea, sclera).

Clinical findings:

- with prolapsus of intraocular tissue
- without prolapsus of intraocular tissue



Laceration – penetrating injury

Examination:

Visual acuity, slit lamp, ophthalmoscopy, ultrasound, CT or x-ray (for elimination of the foreign body).

Treatment:

- **surgical** – suture immediately
- **medical** - contact lens (only if the wound is small and edges of the wound are adapted) + systemic and topical antibiotics

Open Globe

Laceration + IOFB

IntraOcular Foreign Body is defined as intraocularly retained material.

Cause:

Hammering in 80%, power or machine tools in 25%, weapon-related in 20%.

Terminology of IOFB:

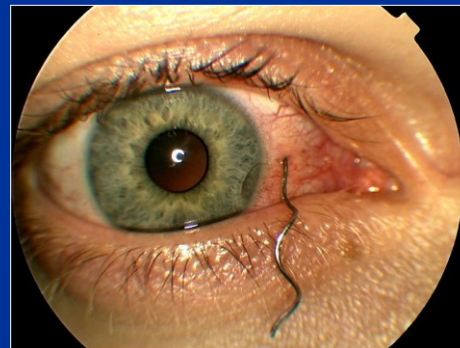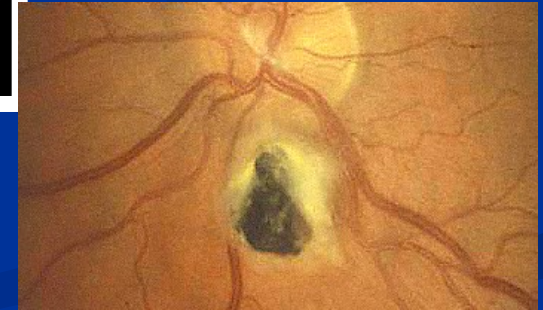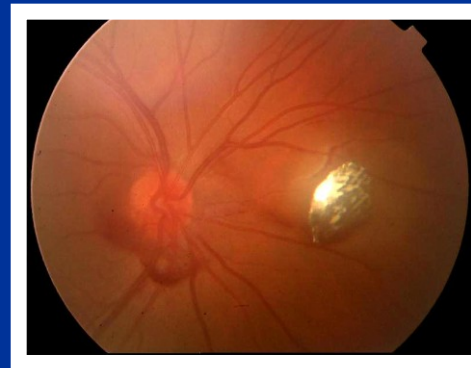
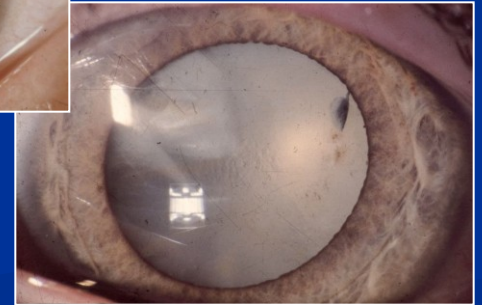
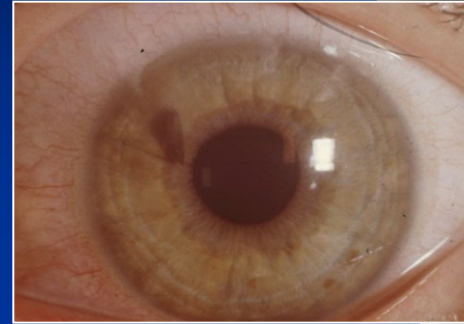
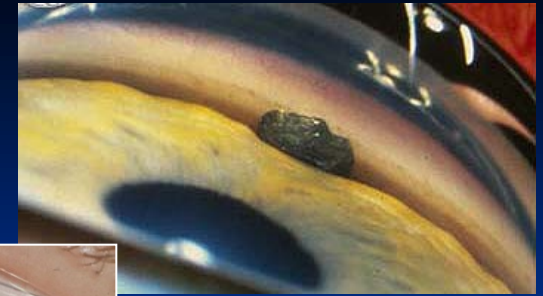- metallic or non metallic
- x-ray contrast or x-ray noncontrast
- magnetic or non magnetic

IOFB

Clinical findings:

Depends on localization of foreign body inside the eye.

Clinical features range between no visual impairment to blindness.



IOFB

Examination:

Slit lamp, ophthalmoscopy,
ultrasound, x-ray, CT scan.

Detection of IOFB by x-ray method:

- anterior and lateral projection with prosthesis on the cornea
- Comberg-Baltin method = exact calculation of localization IOFB inside the eye.

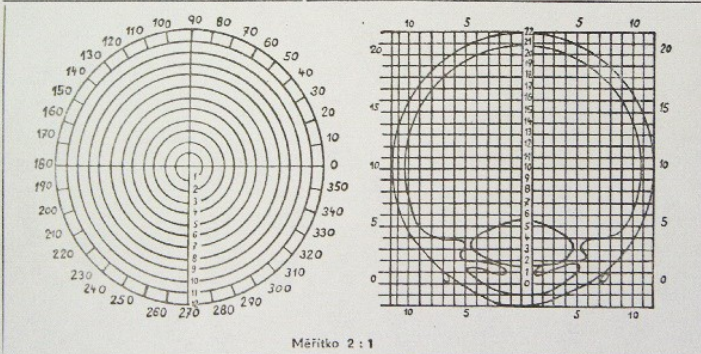


LOKALISAČNÍ SCHEMA (Comberg)

Příjmení a jméno:

Označení ústavu, oddělení Čís. prot.:

Poloha tělíska ve front. řezu Poloha tělíska v merid. řezu



Měřitko 2 : 1

Dne: Vyšetřil:

IOFB

Ocular damage

■ Entrance Wound

The IOFB must possess certain energy to perforate the eye's protective wall. The length of the entry wound is predictive of the risk of retinal damage: the shorter the wound, the less energy to be lost during penetration.

■ Mechanical Intraocular Damage

Little or no damage is expected if the IOFB has completely lost its kinetic energy upon entry. The primary impact may be followed by additional impaction via ricocheting.

■ Inflammation

Breach of the eyewall, intraocular haemorrhage and vitreous/lens admixture incite an inflammatory response.

■ Chemical Implications

Metallic IOFB's are rarely pure.

■ Siderosis

IOFB - related corrosion is caused by interaction between trivalent iron ions and proteins in the eye's epithelial cells. The cytotoxicity involves enzyme liberation leading to cell degeneration. The ferric iron is thought to be toxic by generating free radicals.

IOFB

Ocular damage

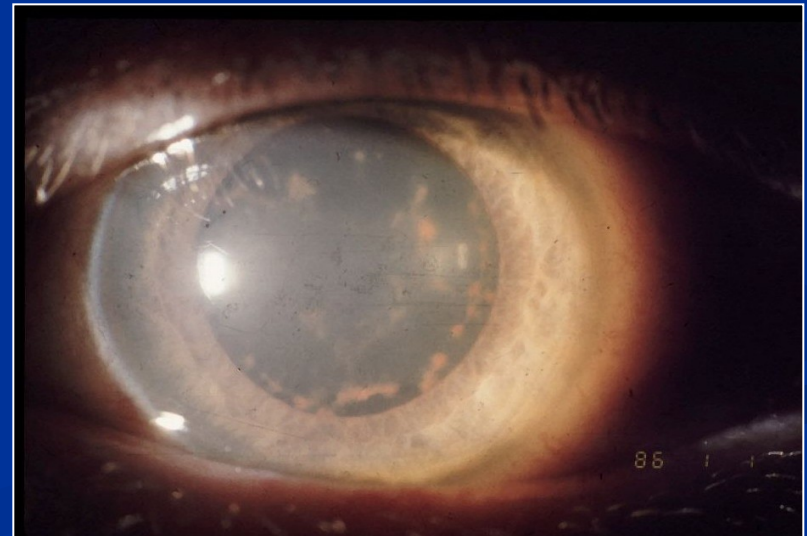
■ Siderosis

Siderotic changes include the following clinical findings:

- ✓ Chronic open-angle glaucoma
- ✓ Brownish discoloration of the iris
- ✓ Dilated, nonreactive pupil
- ✓ Yellow cataract with brown deposits on the anterior capsule
- ✓ Pigmentary retinal degeneration withg visual field loss
- ✓ Visual impairment

The clinical diagnosis is confirmed by characteristic ERG changes such as:

- ✓ Increased A wave initially
- ✓ Progressive reduction of the B wave subsequently



IOFB

Ocular damage

■ Chalcosis

Copper IOFBs cause rapid, sterile endophthalmitis-like reaction including corneal/scleral melting, hypopyon (inflammatory exudation in anterior chamber) and retinal detachment.

Copper tends to deposit in membranes and causes destruction by increasing lipid peroxidation.

The typical clinical findings include:

- ✓ Green discoloration of the iris
- ✓ Greenish/brown – colored cataract with spokes of copper deposits
- ✓ Copper particles in the vitreous and copper particles on the retinal surface

IOFB

Treatment:

All the IOFB 's must be removed from the eye!
Retained IOFB = high risk of endophthalmitis and siderosis

Timing of removal:

- ✓ Immediately
- ✓ Delayed – between 5 and 10 days after injury

- **Surgical treatment** – extraction by pars plana vitrectomy with forceps or intraocular magnet
- **Medical treatment** – systemic antibiotics, topic antibiotics and corticosteroids, mydriatics.

Open Globe

Laceration – perforating injury

Entrance and „exit“
wound.

*Both wounds caused by
the same agent.*

Etiology:

Section, puncture, splash
wound (f.e.wire, knife)
or entrance and exit
wound caused by
IOFB.

Specificity of perforating injury

- ✓ Entrance wound is smaller than exit wound (cases caused by IOFB)
- ✓ In most cases exit wound is technically impossible to suture (exit wound located in posterior pole)

Perforating injury

Clinical findings:

Same as the penetrating injury

Examination:

Slit lamp, IOP measurement, ophthalmoscopy, ultrasound, x-ray, CT

Treatment:

Suture of the entrance wound (exit wound if it is technically possible), cataract extraction, pars plana vitrectomy...

Thank You For Your Attention

