

# Head injuries

Z. Rozkydal

# Head injury

Skull fractures

Brain lesion or damage

Scalp wounds

Injury to the spine in the neck

# Signs

History of a severe blow

Increasing drowsiness

Headache, unequal pupil size

Confusion, dizziness

Loss of balance, loss of memory

Difficult speaking, difficult walking

Vomiting, double vision

Seizures

Bleeding, leakage of blood or watery fluid from the ear or nose

Loss of consciousness

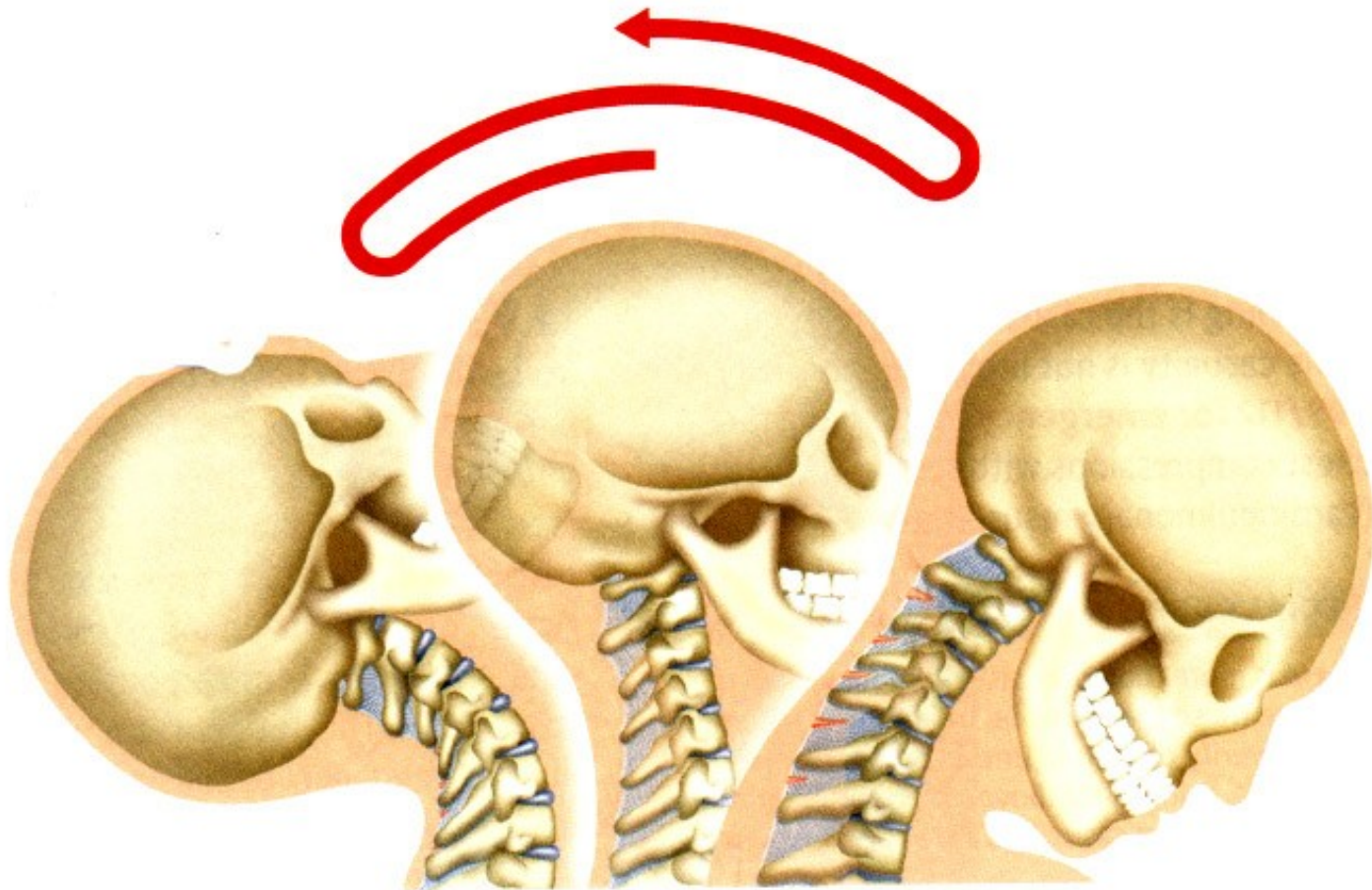
# Assesment of level of consciousness

A Alert, respond to questions  
eyes are open

V Voice, respond to voice, obey commands

P Pain, respond to pain

U Unresponsive to any stimulus



Whiplash injury





Recovery position



Log- roll technique



First aid:

Free airways

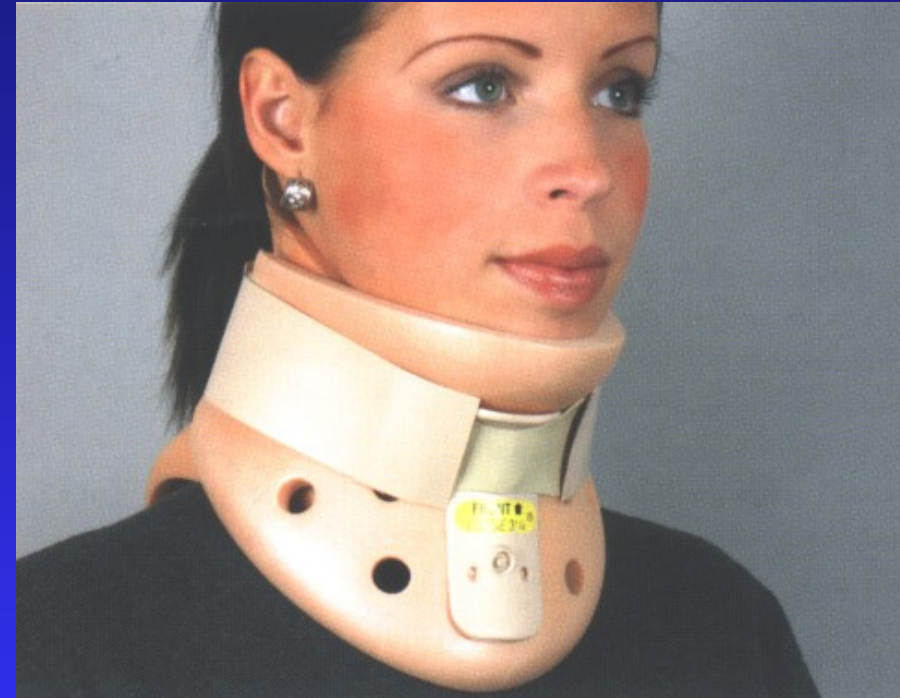Cold compresses at the site  
of injury

Monitor vital signs

CPR

Stabilisation of cervical spine  
(Philadelphia collar)

Sterile dressing of the ear  
or nose



Philadelphia collar

# Brain lesion

Concussion (commotio cerebri)

Contusion of the brain (contusio cerebri)

Epidural haematoma

Subdural haematoma

Subarachnoideal bleeding

Intracerebral bleeding

Intraventricular bleeding

# Concussion (commotio cerebri)

Temporary loss of consciousness

Nausea, vomiting, retrograde amnesia

Rapid pulse, flat breathing, pale

Functional lesion of neurons

# Management of concussion

Admission to the hospital

Sedatives

Prevention of epilepsy (Sanepil)

Postconcussion syndrom:

Headache, vertigo, fatigue, desorientation  
sleep problem

# Contusion of the brain (contusio cerebri)

Structural damage of the brain

Unconsciousness two hours or more

Impaired motor function

Impairment of sensation

# Epidural haematoma

Between the skull and hard tissue

Artery or vein

# Symptoms:

Short period of unconsciousness after head injury

Free interval (minutes or hours)- minimal problems

Headache, nausea, vomiting

Coma, seizures

Unequal pupils- mydriasis on the site of bleeding

First aid

Rescue position

Free airways

Management

Neurosurgery, craniotomy, stop bleeding

Removal of haematoma



# Subdural haematoma

## Symptoms:

Unconsciousness immediately

No free interval

Seizures, motor collision