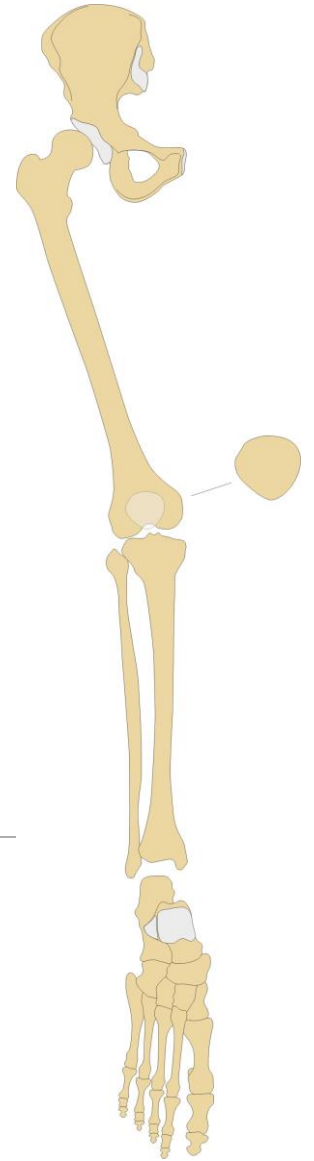


# Skeleton of the lower limb (*ossa membri inferioris*)

---

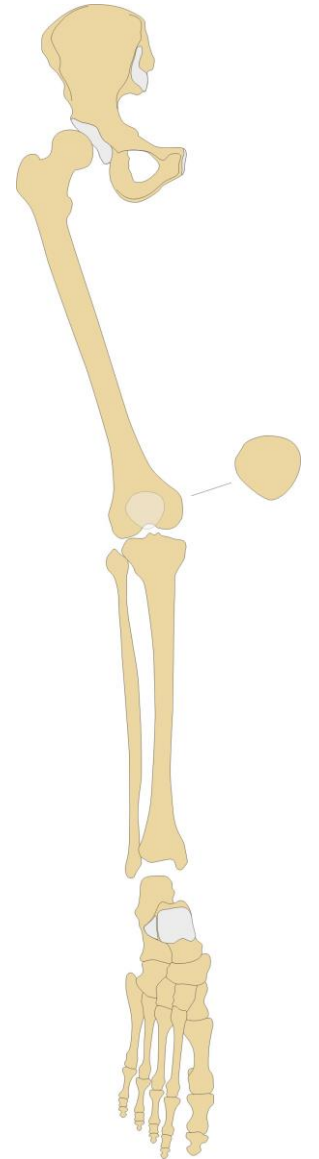
RNDr. Michaela Račanská, Ph.D.

Lecture 3 – DENTISTRY – Autumn 2016



# Skeleton of the lower limb

- support the weight of the body and transfers that support to the axial skeleton across the hip and sacro-iliac joints
- Stability and balance thanks to the hip and knee joints lock, long standing in anatomical position
- less mobility but more stability than the pectoral girdle of the upper limb thanks to anchoring to the axial skeleton by the pelvic girdle



**Skeleton of the pelvic (hip) girdle:  
the hip bone – *os coxae***

(the ilium – *os ilium*, the ischium – *os ischii*, the pubis – *os pubis*)

---

**Skeleton of the free part of the lower limb:**

The thigh bone – *femur*

The knee cap – *patella*

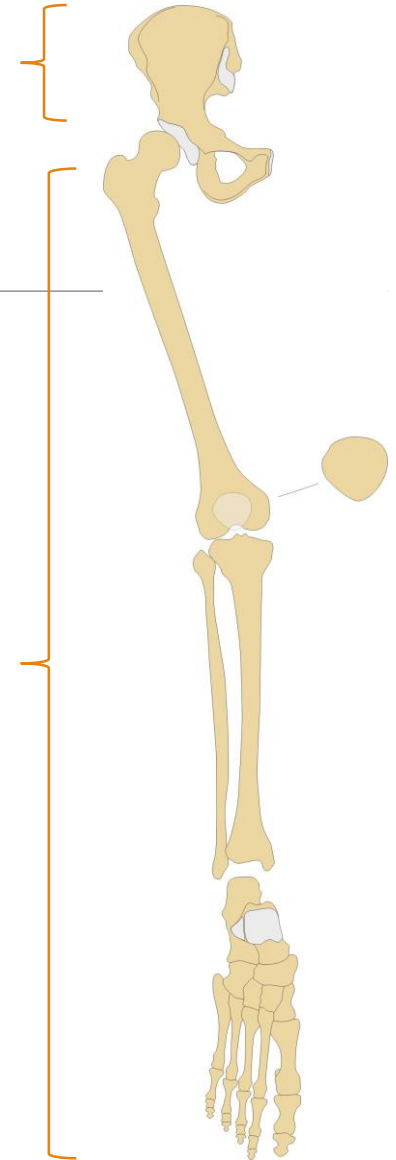
The shinbone – *tibia*

*Fibula*

The tarsus – *ossa tarsi*

The metatarsus – *ossa metatarsi*

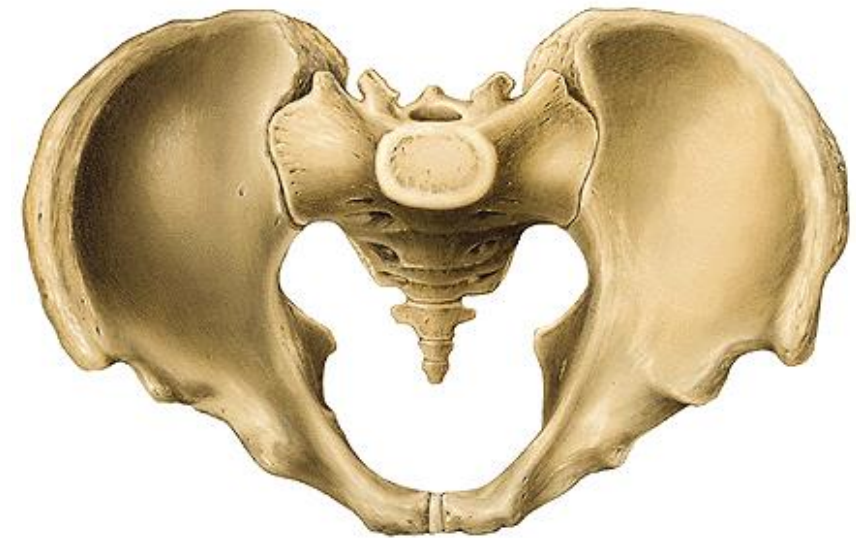Bones of digits (*ossa digitorum pedis* – *phalanges*)



# Bones of the pelvic girdle

---

- Attaches the lower limbs to the axial skeleton
- Transmits the weight of the upper body to the lower limbs
- Supports the visceral organs of the pelvis
- Formed by a pair of “hip” bones called **coxal bones**, and the sacrum

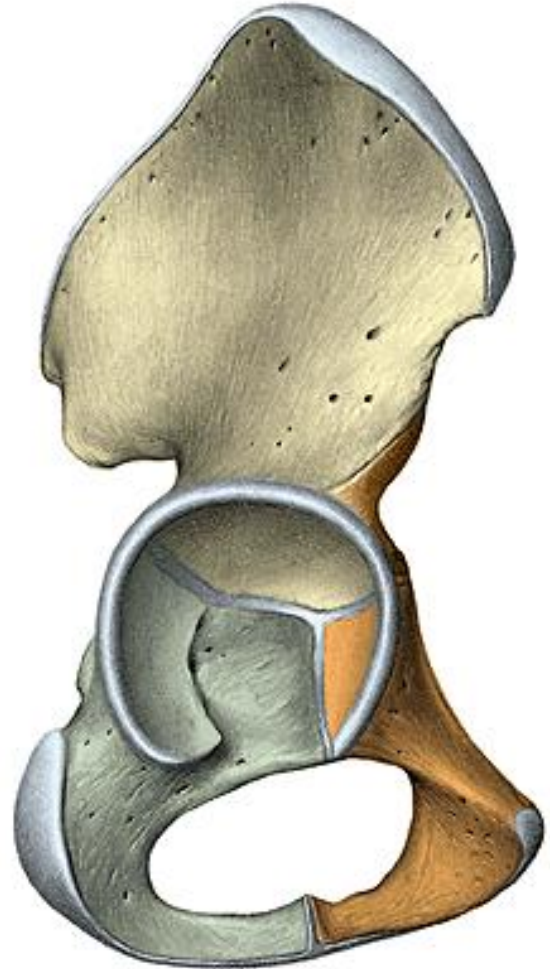


# Os coxae

(os ilium, os pubis, os ischii)

Each os coxae has an:

- **Ilium**: The large upper portion, often called your “hip bone”.  
os ilium – corpus, ala
- **Ishium**: The posterior/inferior bone, often called your “seat bone”.  
os ischii – corpus, ramus
- **Pubis**: The anterior/inferior bone, which connects in front at the pubic symphysis. os pubis – corpus, ramus sup. et inf.
- **Acetabulum**: point of fusion of all three, also called your “hip socket”.  
facies lunata  
fossa acetabuli  
incisura acetabuli  
**foramen obturatum**



# Os ilium

**corpus ossis ilii**

**ala ossis ilii**

fossa iliaca

facies auricularis

tuberositas iliaca

linea arcuata

sulcus praeauricularis

tuberculum m. piriformis

**crista iliaca**

labium externum

linea intermedia

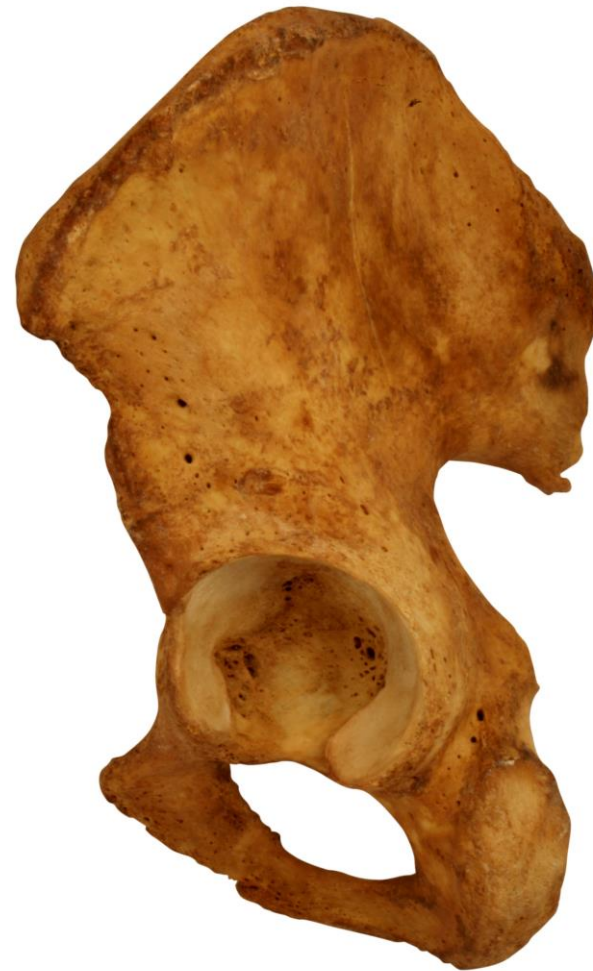labium internum

**spinae iliacae**

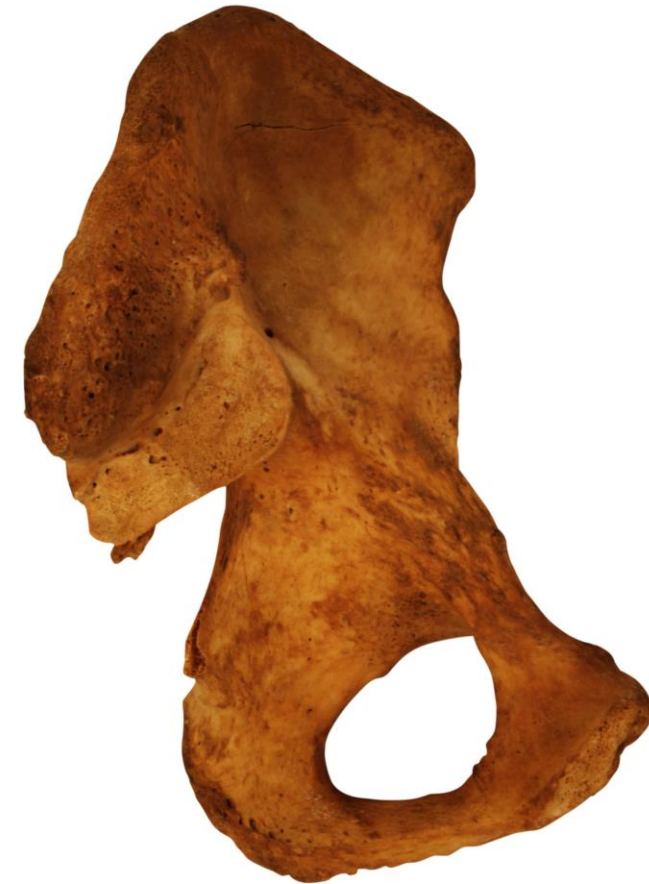spina iliaca anterior superior et inferior

spina iliaca posterior superior et inferior

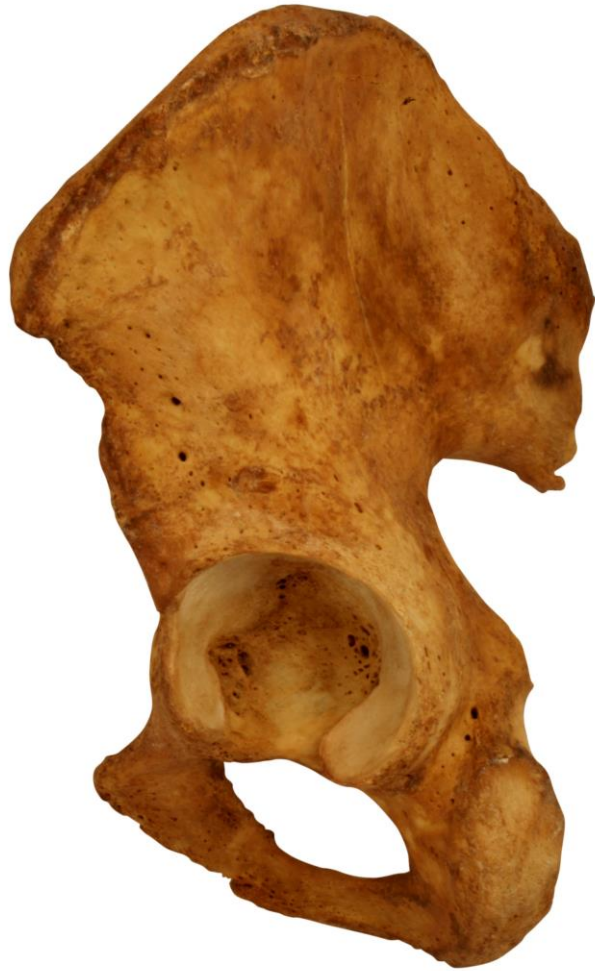**linea glutea** posterior, anterior et inferior



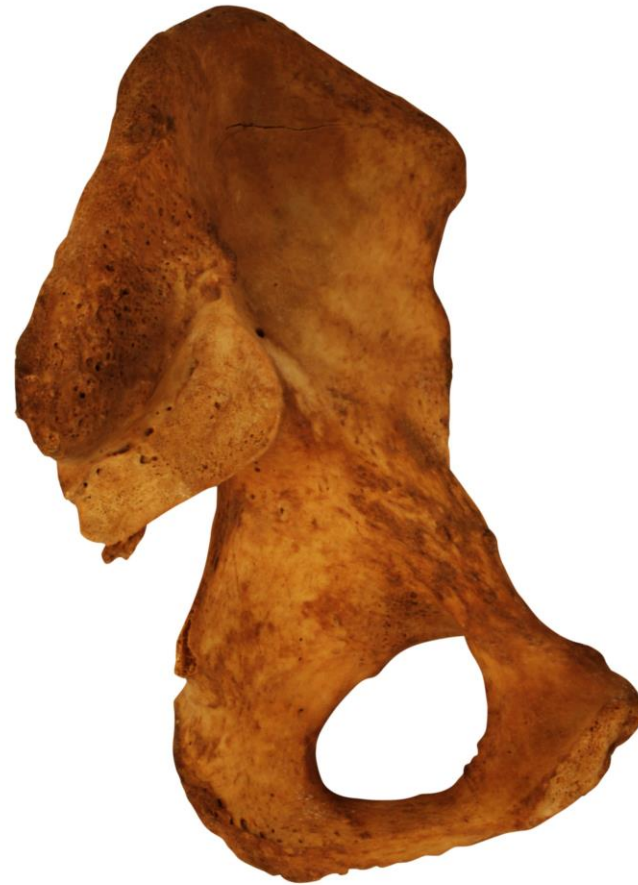LATERAL VIEW



MEDIAL VIEW



**LATERAL VIEW**



**MEDIAL VIEW**

## **Os ischii**

**corpus ossis ischii**

**ramus ossis ischii**

**tuber ischiadicum**

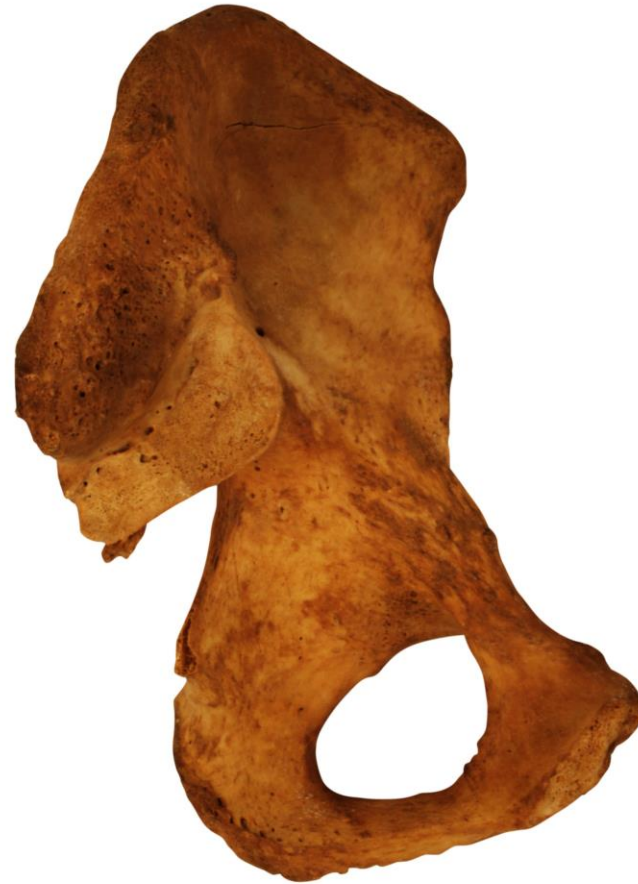**spina ischiadica**

**incisura ischiadica major**

**Incisura ischiadica minor**



**LATERAL VIEW**



**MEDIAL VIEW**

## **Os pubis**

**corpus ossis pubis**

**ramus superior ossis pubis**

**eminentia iliopubica**

**pecten ossis pubis**

**tuberculum pubicum**

**sulcus obturatorius**

**ramus inferior ossis pubis**

**facies symphysealis**

**crista phallica**



# Femur – the thigh bone

Proximal end  
head



corpus (body)



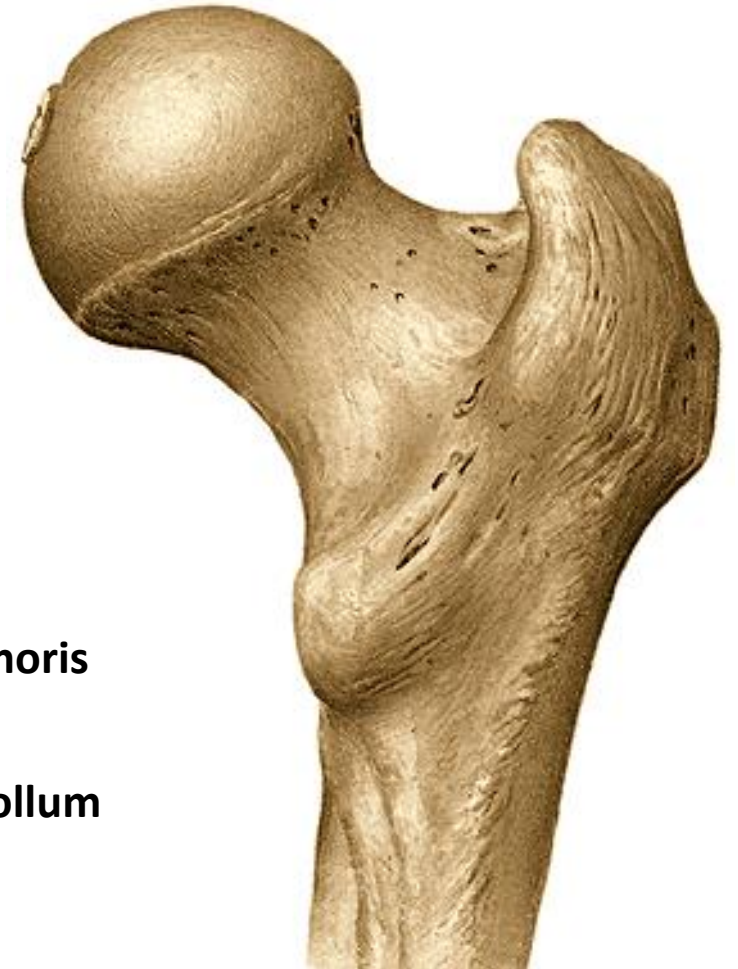
Distal end

Proximal end

caput femoris

fovea capitis femoris

Neck of the femur (collum femoris)



## Femur

**corpus femoris**

**trochanter major et minor**

**linea intertrochanterica**

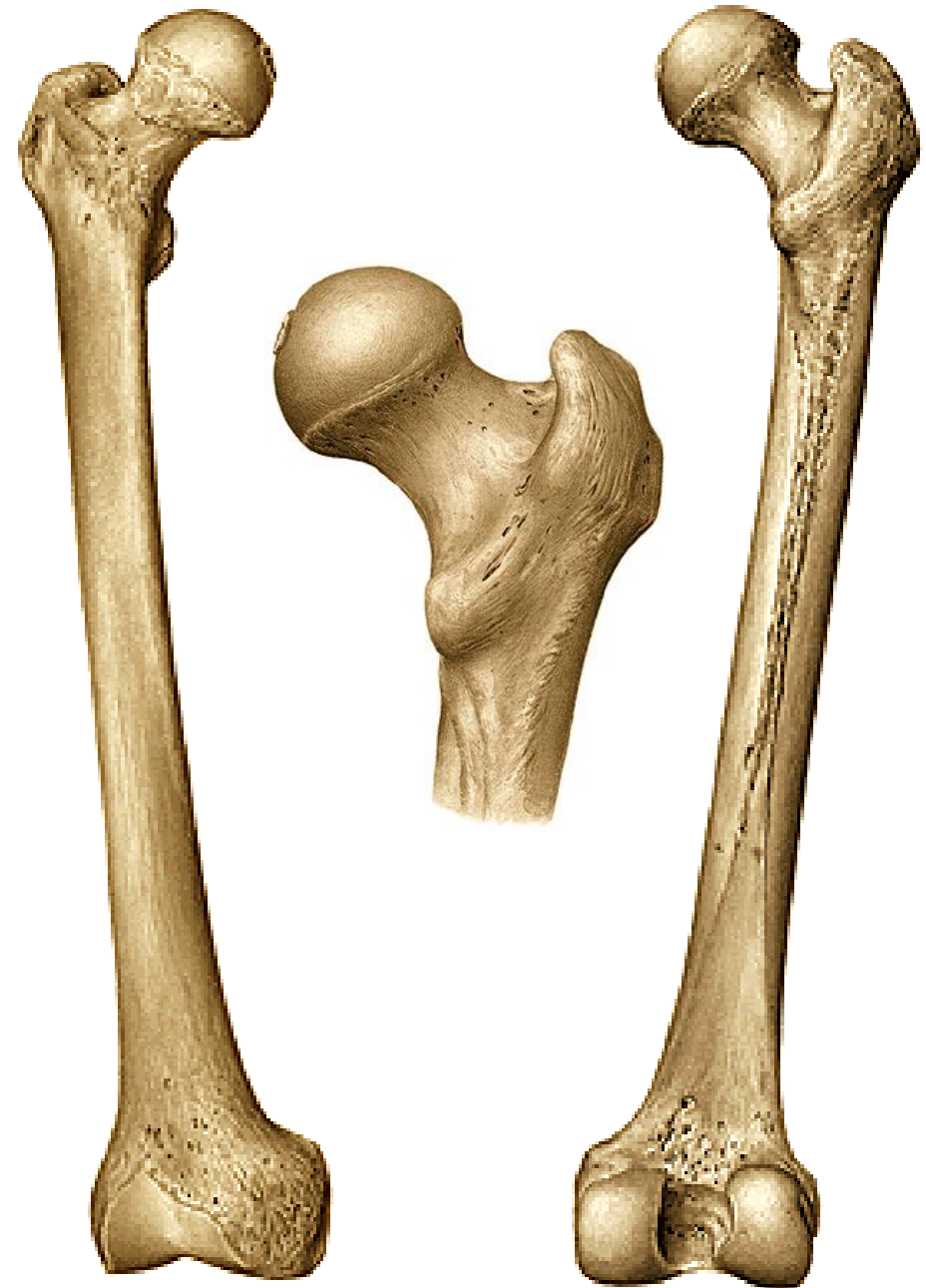**crista intertrochanterica**

**fossa trochanterica**

**linea aspera**

**labium mediale (linea pectinea)**

**labium laterale (tuberositas glutea)  
Trochanter tertius**



## Distal end

condylus medialis

condylus lateralis

epicondylus medialis

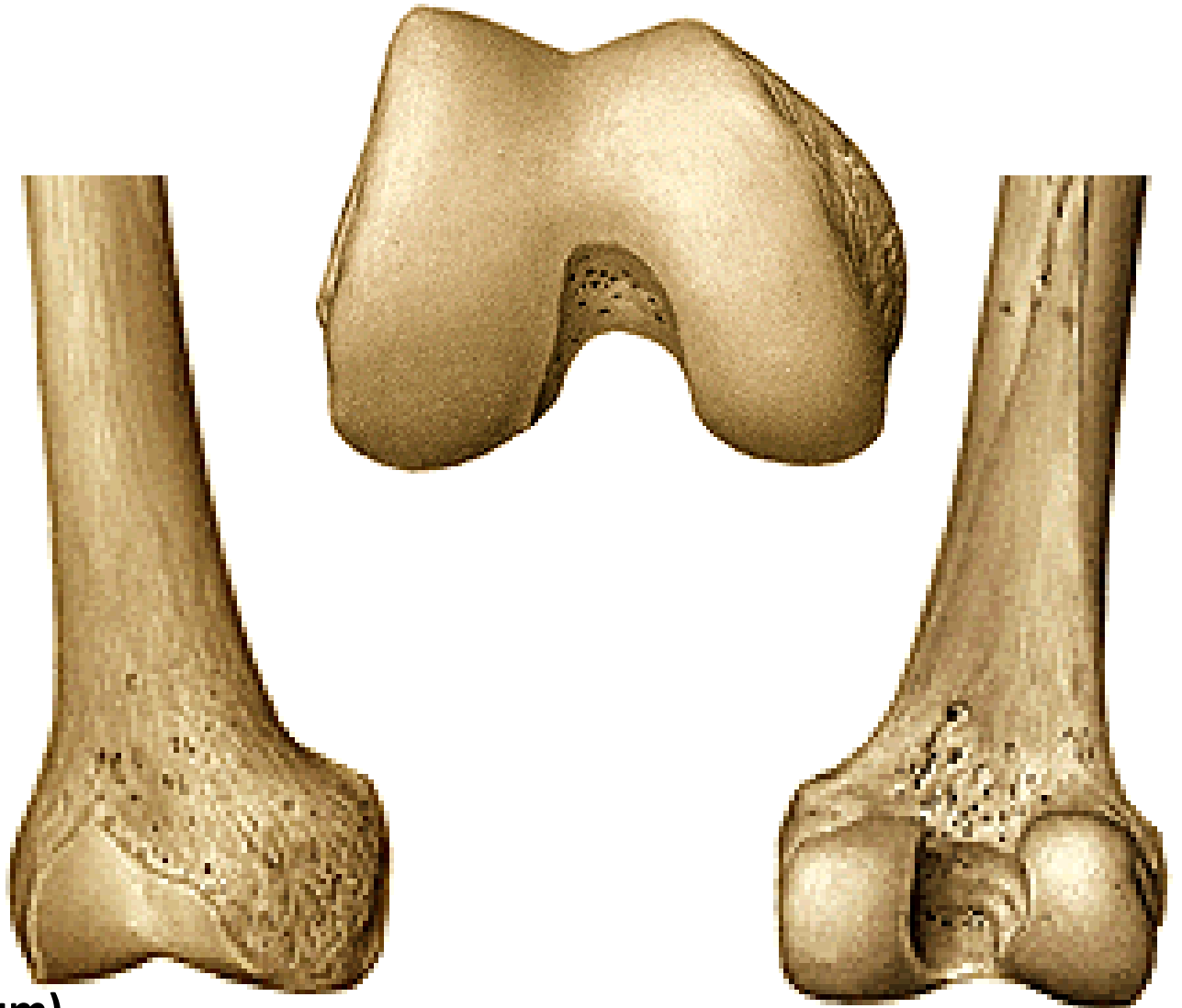
epicondylus lateralis

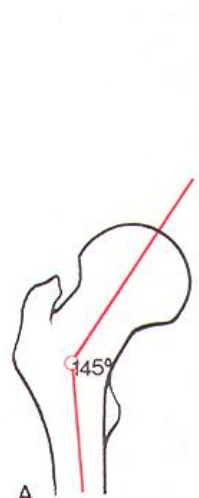facies patellaris

fossa intercondylaris

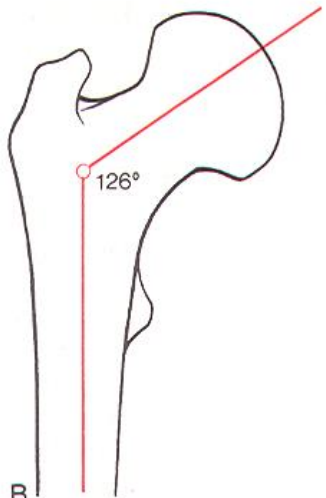
linea intercondylaris

facies poplitea (planum popliteum)

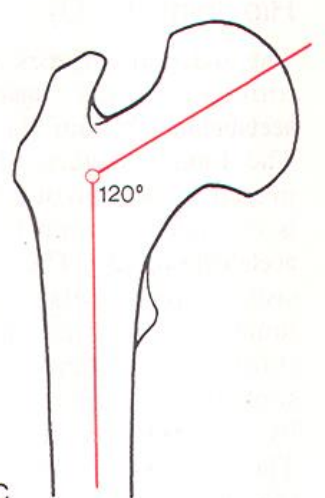




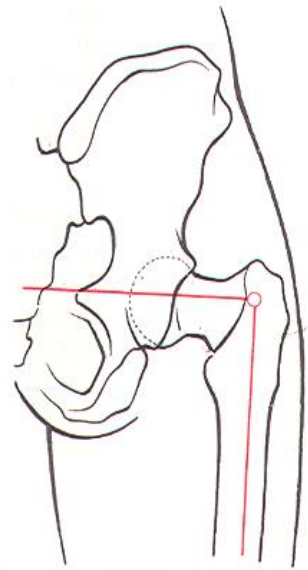
A  
Angle of inclination  
in 3-year-old child



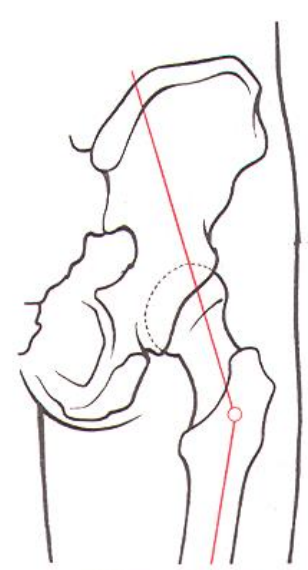
B  
Angle of inclination  
in adult



C  
Angle of inclination  
in old age



D Coxa vara



E Coxa valga

## PATELLA (knee cap)

sesamoid bone encased in the patellar tendon

**Basis**

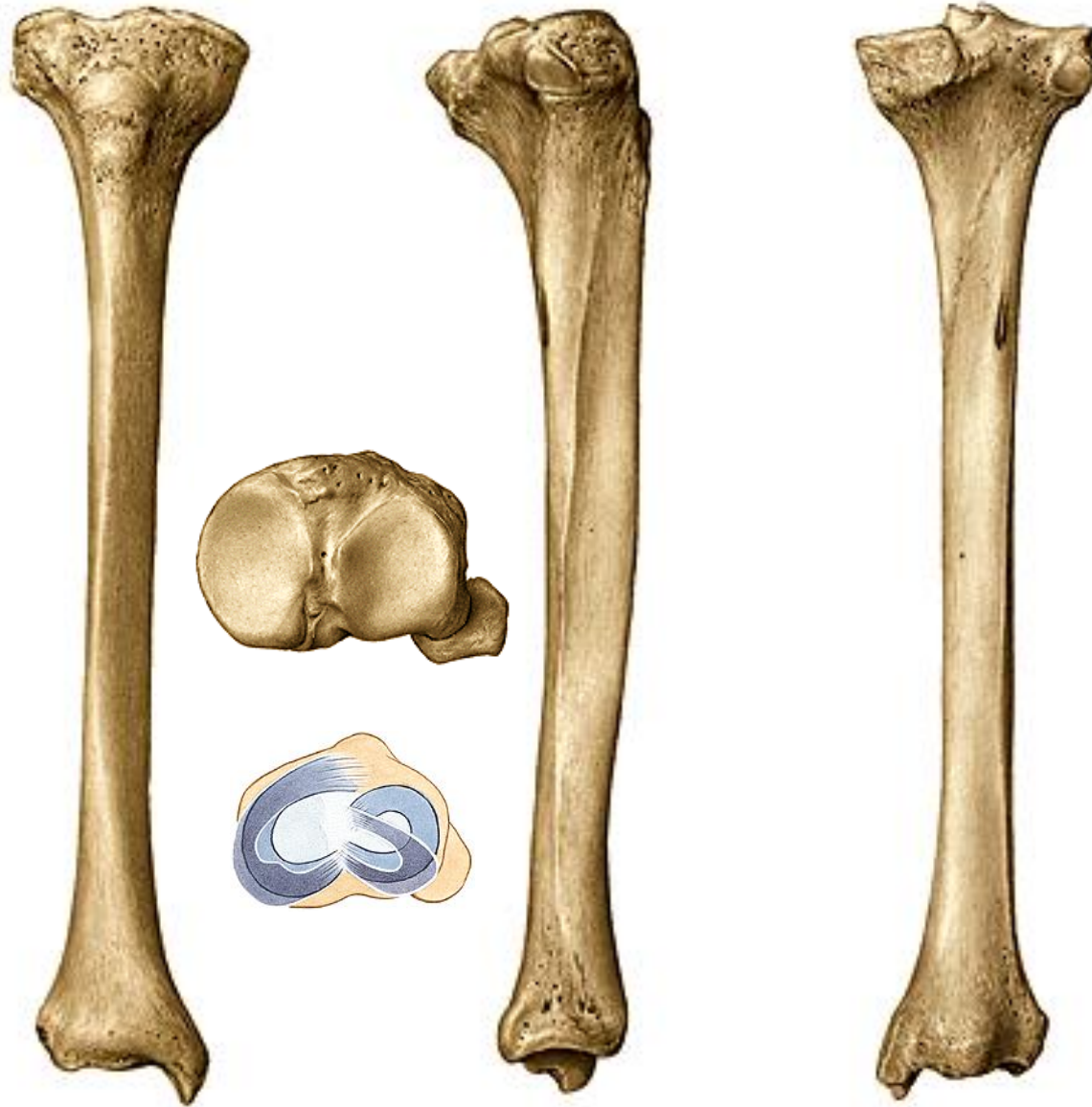
**Apex**

**Facies posterior (smooth articular surface)**

**facies art. medialis (smaller) et lateralis (larger)**

**Facies anterior (the rounded, convex anterior surface)**





## Tibia (shin bone)

Proximal end, body, distal end

### Proximal end

condylus medialis et lateralis

facies articularis superior medialis, lateralis

eminentia intercondylaris

tuberculum intercondylare mediale

tuberculum intercondylare laterale

area intercondylaris anterior et posterior

facies articularis fibularis

# Tibia (shin bone)

## Corpus (body)

tuberositas tibiae

linea musculi solei

margo medialis

margo anterior

margo interosseus



# Tibia (shin bone)

## Distal end

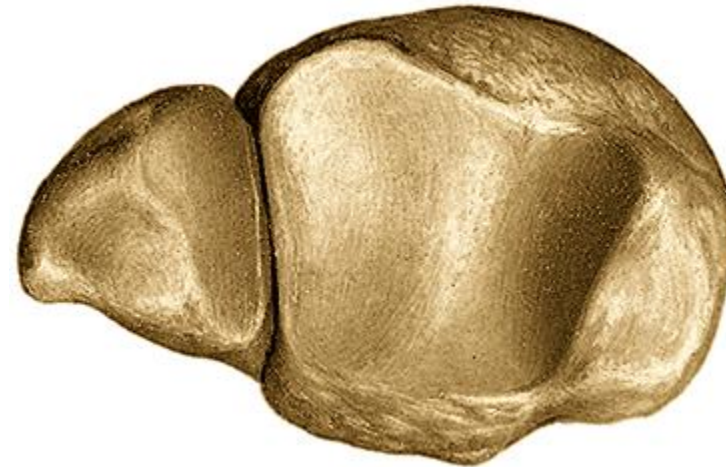malleolus medialis

facies articularis malleoli medialis

incisura fibularis tibiae

facies articularis inferior tibiae


sulcus malleolaris







## Fibula



**Proximal end**

**caput fibulae**

**facies articularis capitis fibulae**

**apex capitis fibulae**



# Fibula

## Corpus (body, shaft)

margo anterior et posterior

margo medialis et interosseus

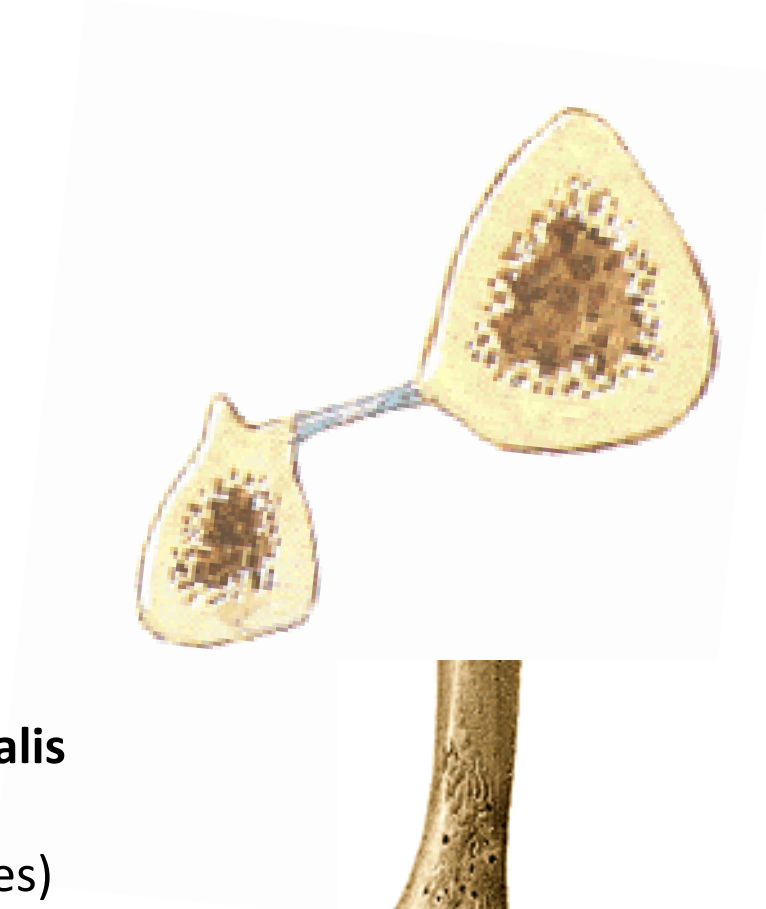## Distal end

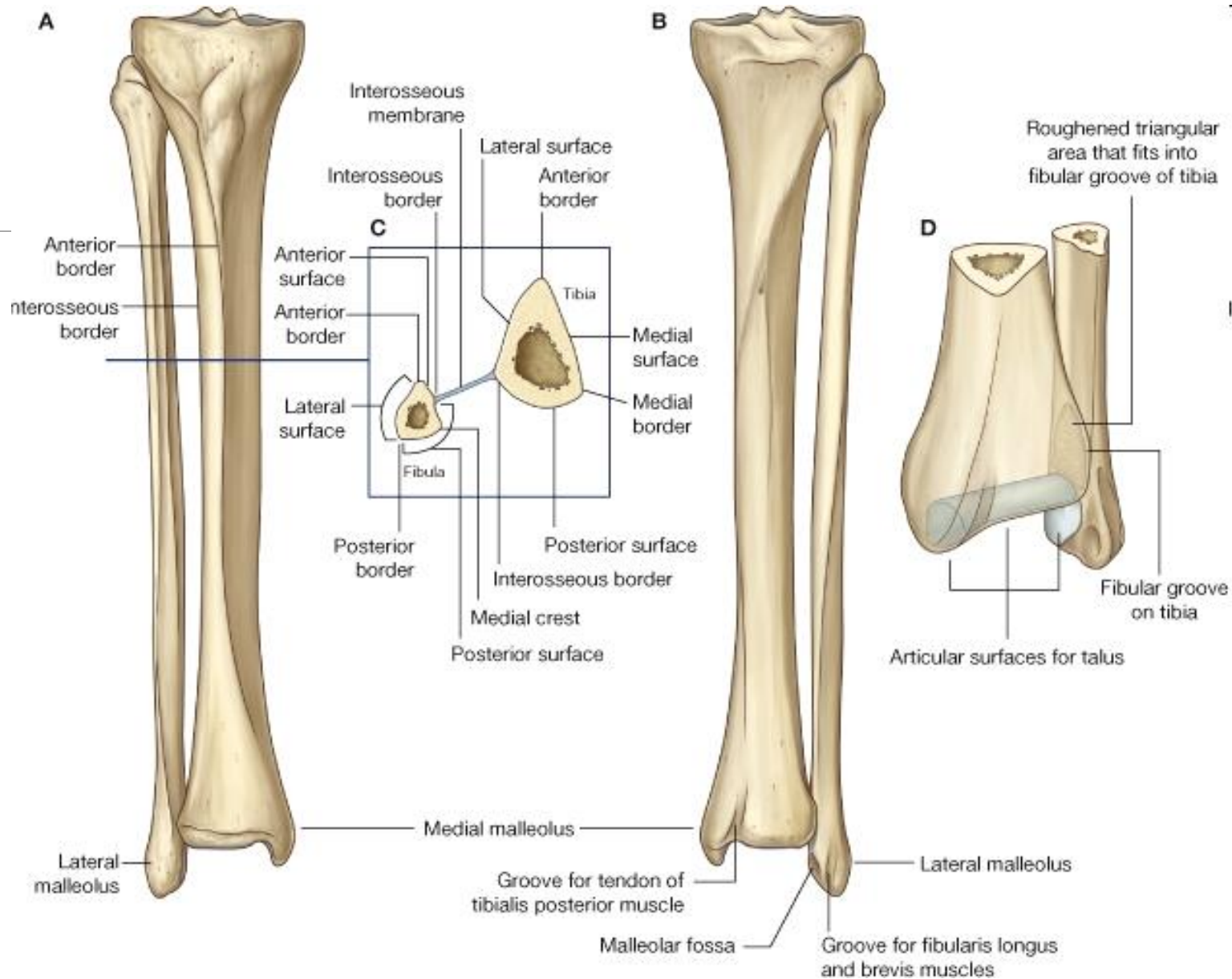
malleolus lateralis

facies articularis malleoli lateralis

sulcus malleolaris (mm.fibulares)

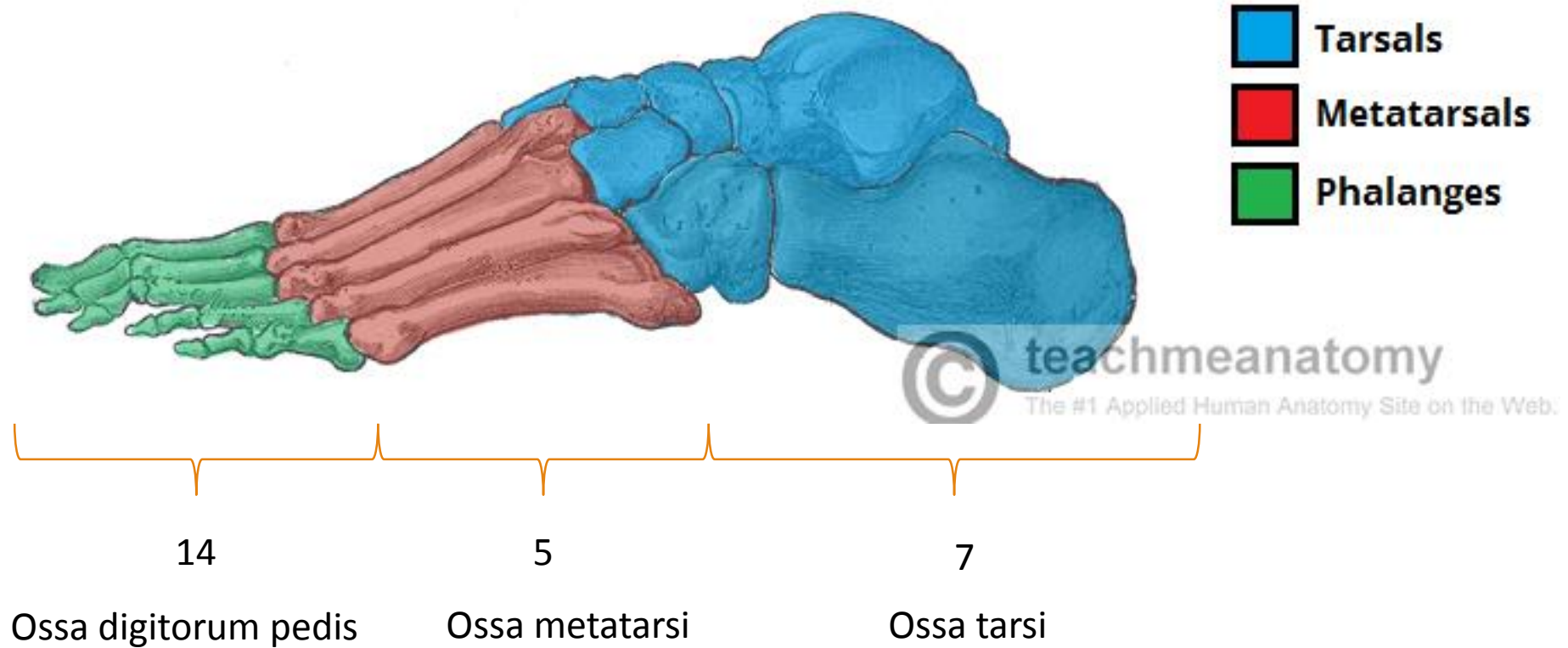
fossa malleoli lateralis (lig. talofibulare post.)

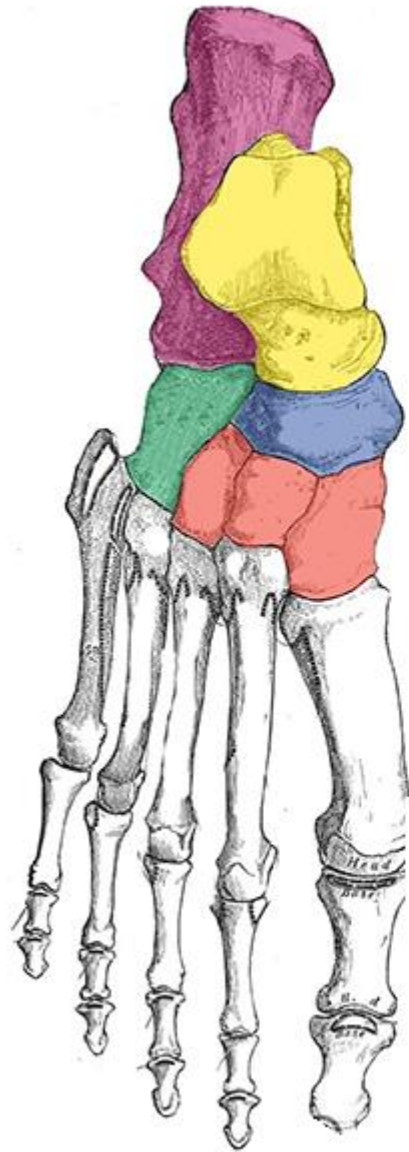








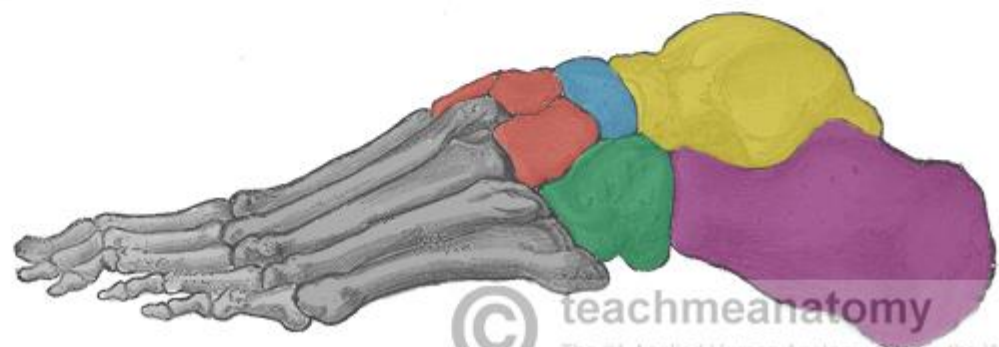
# FOOT

## Ossa pedis

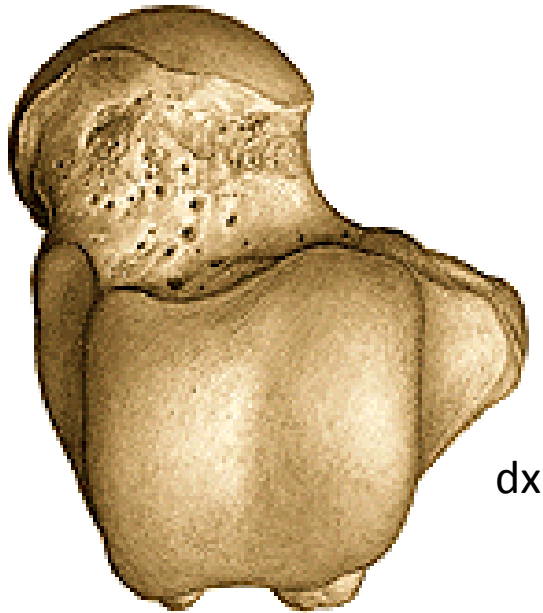




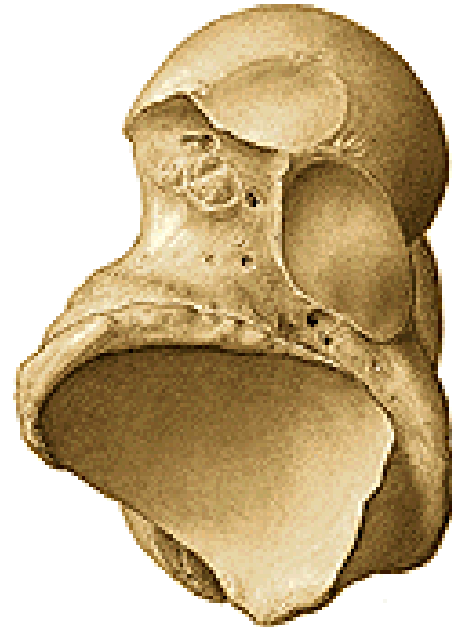
-  **Calcaneus**
-  **Talus**
-  **Navicular**
-  **Cuboid**
-  **Cuneiforms**



## Talus (ankle bone)



dx



**Caput tali (facies articularis navicularis)**

**Collum tali**

**Corpus tali**

**Trochlea tali - facies articularis superior**

**Facies articularis malleolaris lateralis et medialis**

**Facies articularis calcanea posterior, media, anterior**

**Sulcus tali (sinus tarsi -  
lig. talocalcaneare interosseum)**

**Processus lateralis tali**

**Processus posterior tali (tuberculum laterale,  
mediale)**

**Sulcus tendinis musculi flexoris hallucis longi**

# Calcaneus (heel bone)

tuber calcanei (processus medialis et lateralis)

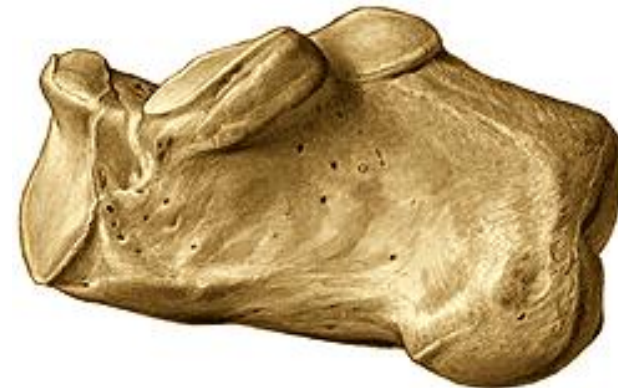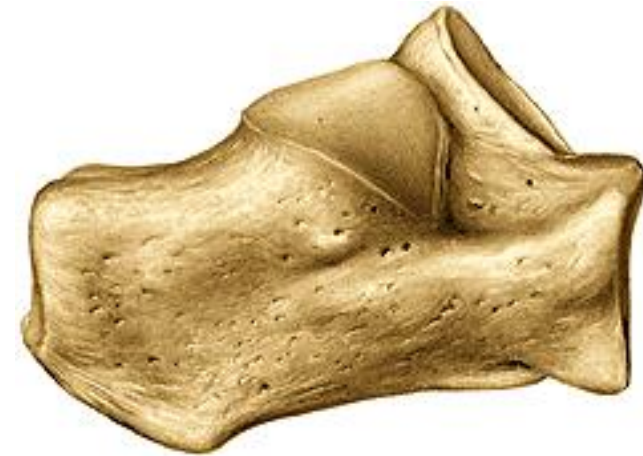facies articularis talaris posterior, media et anterior

sulcus calcanei (**sulcus calcanei + sulcus tali = sinus tarsi**)

sustentaculum tali (medial)  
(sulcus tendinis musculi flexoris hallucis longi)

trochlea fibularis (lateral)  
(sulcus tendinis musculi fibularis longi)

facies articularis cuboidea



## Os naviculare (navicular)

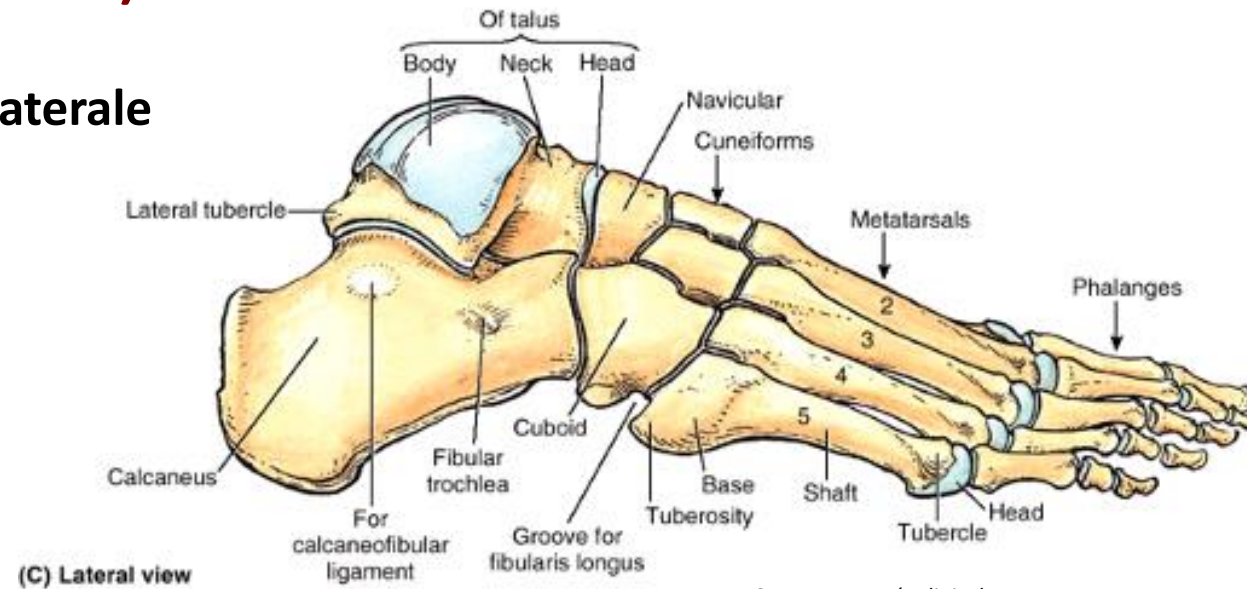
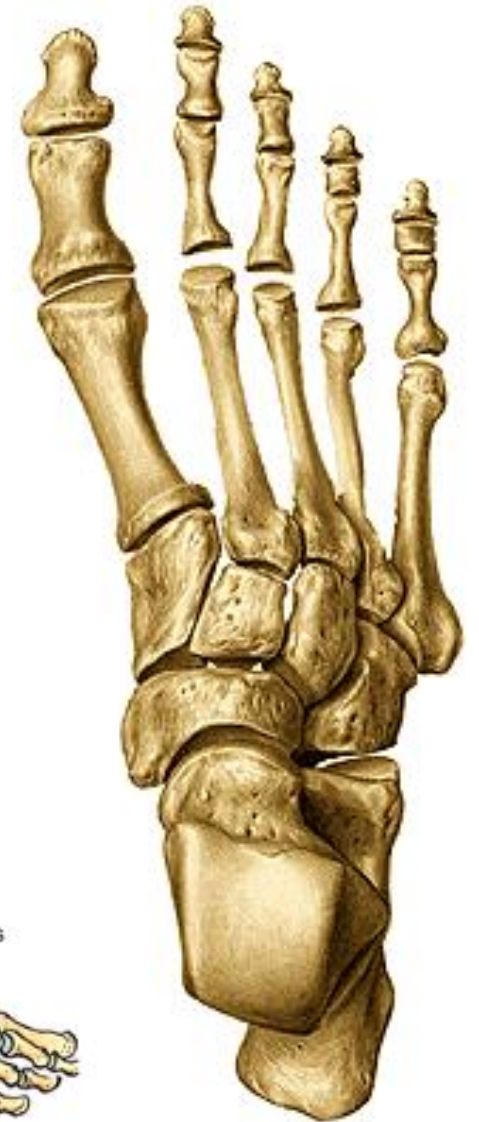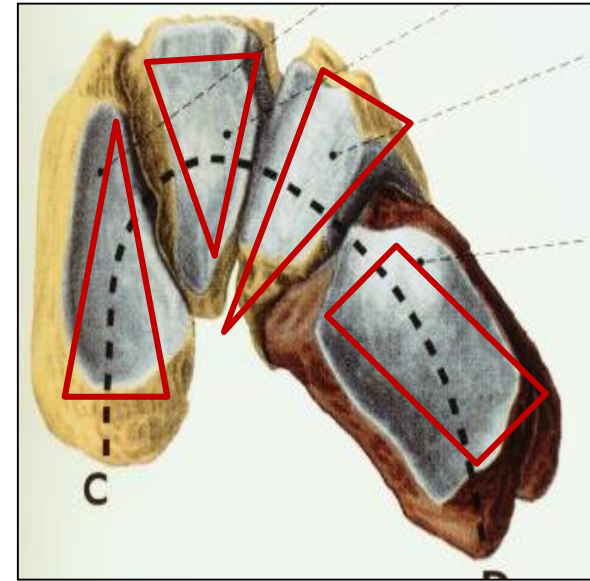
tuberositas ossis navicularis

## Os cuboideum (cuboid)

sulcus tendinis musculi fibularis longi

## Ossa cuneiformia (cuneiforms)

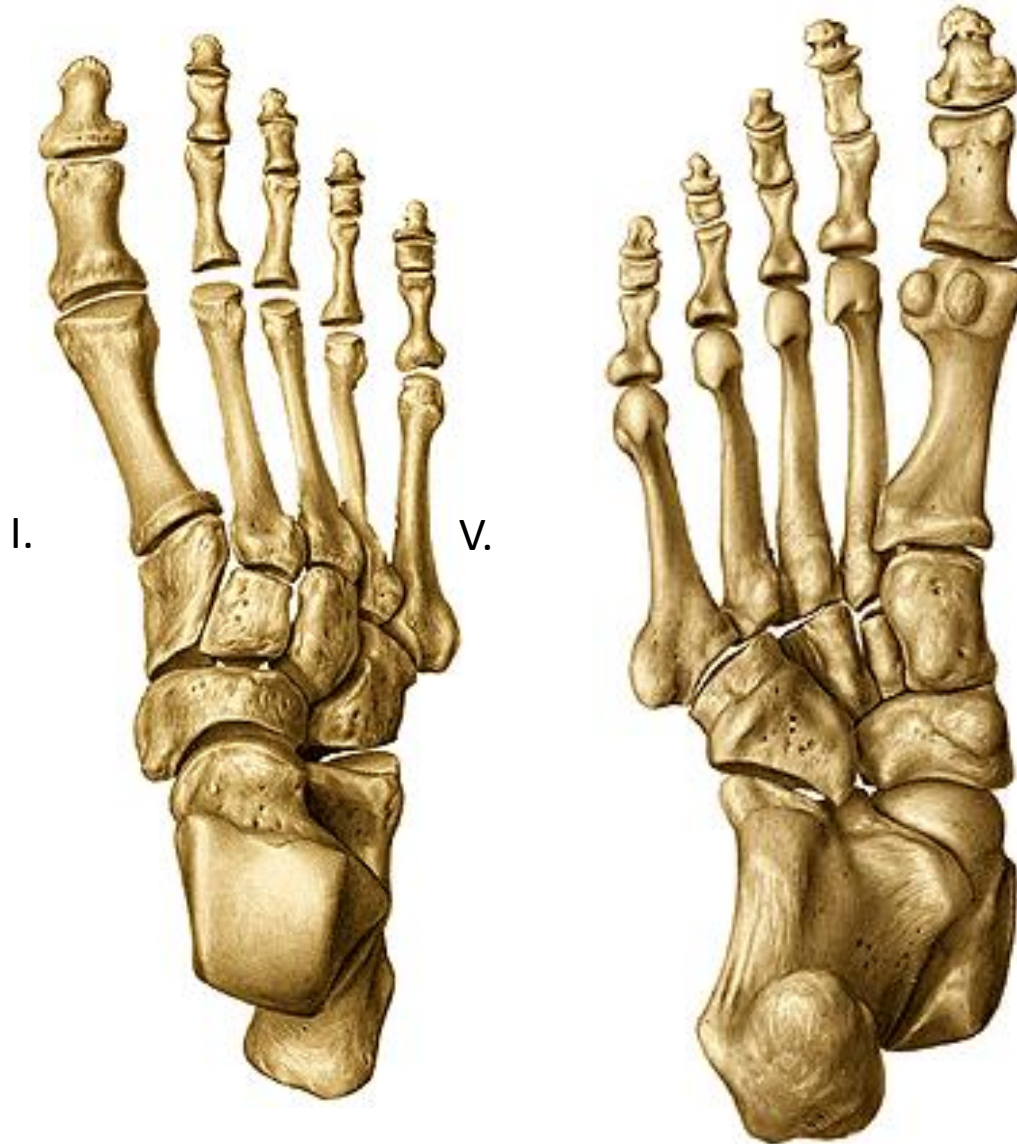
mediale, intermedium et laterale



Source: Netter's clinical anatomy



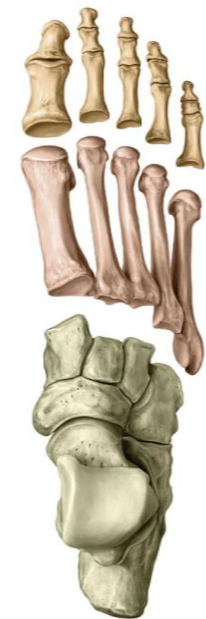## Ossa metatarsi I. – V. (metatarsals)



**basis (base)**  
**(tuberositas ossis metatarsi I. et V.)**

**Corpus (body)**

**caput (head)**



# Ossa digitorum pedis, phalanges

Hallux (big toe) – phalanx proximalis et distalis

II. – V. digit – phalanx proximalis, media et distalis

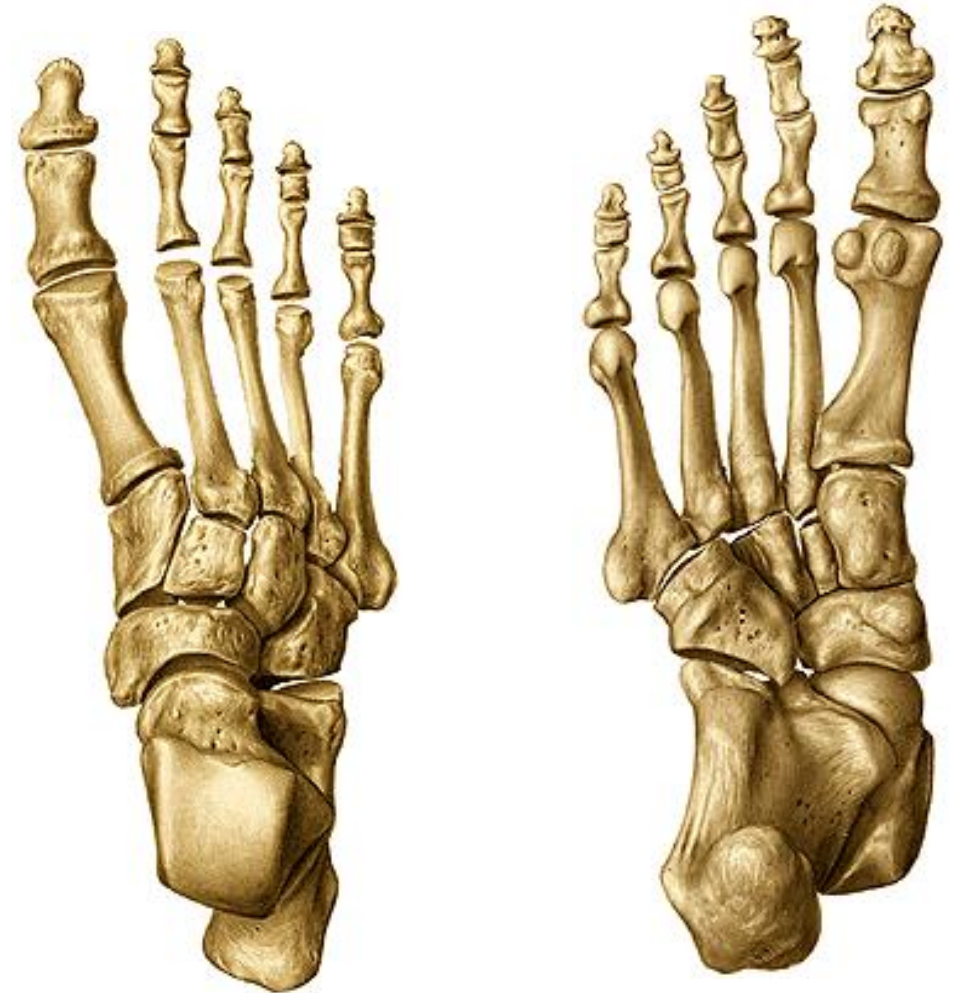basis phalangis (base)

corpus phalangis (body)

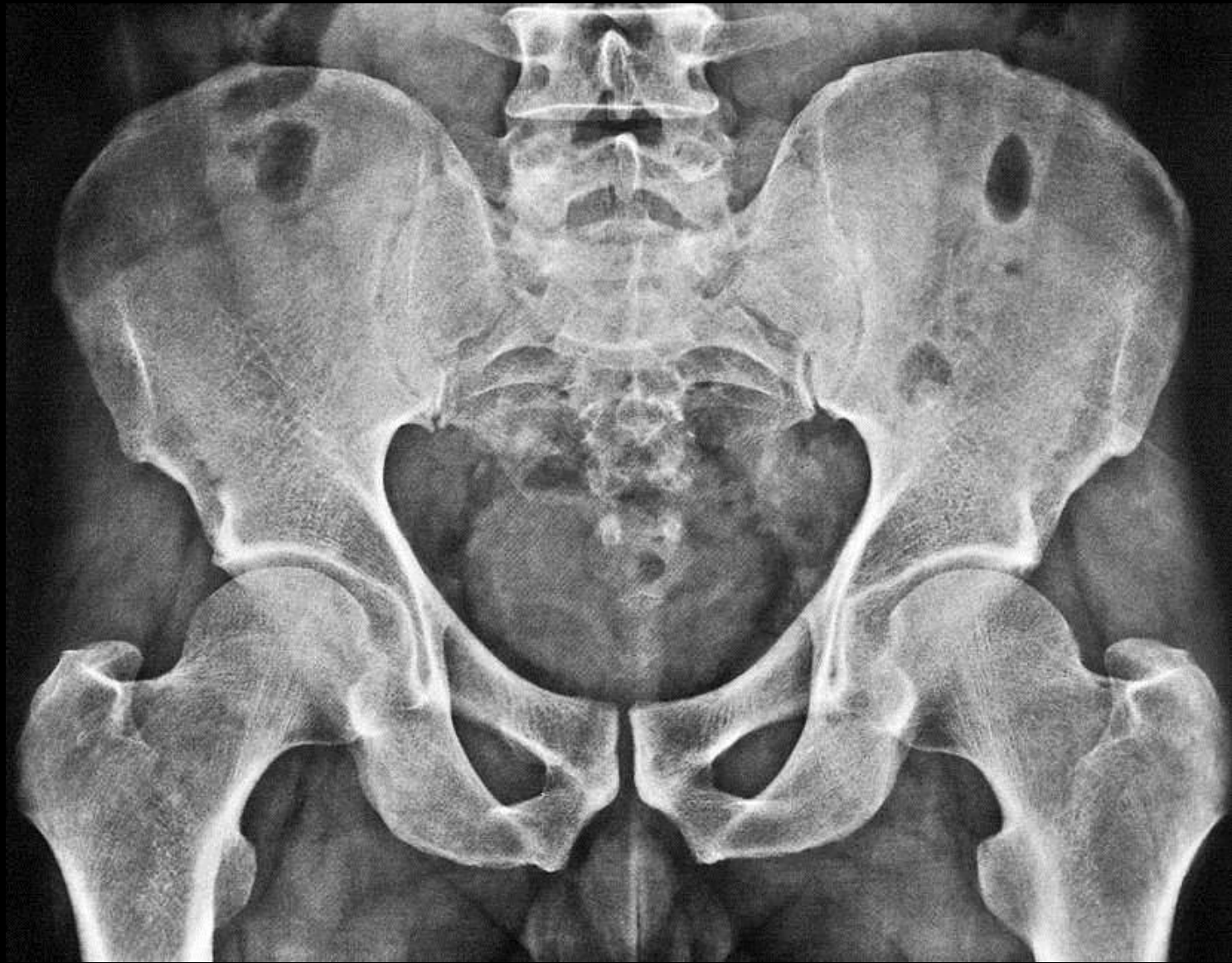caput/trochlea (head, trochlea)

tuberositas phalangis distalis

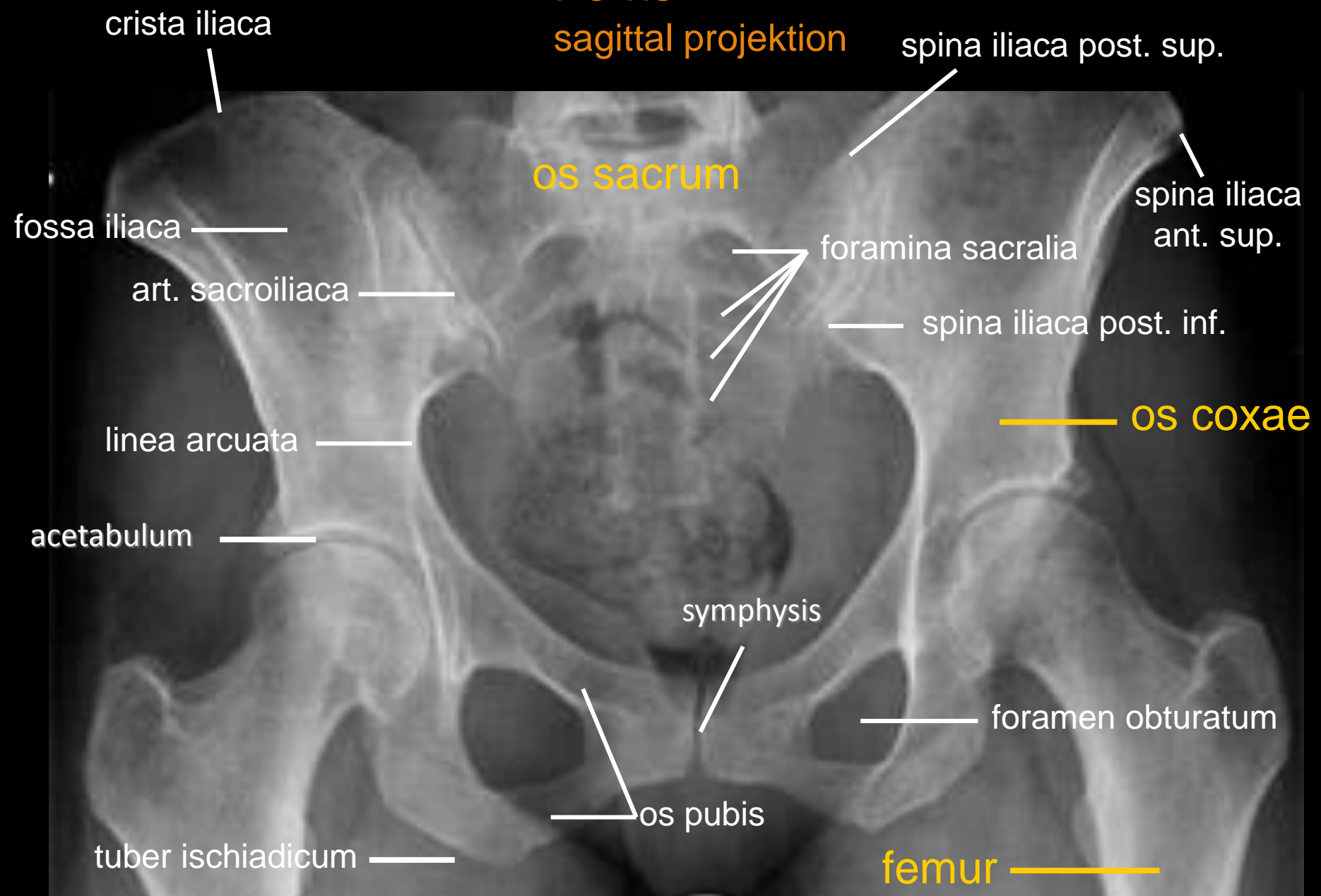
Ossa sesamoidea



**X-rays**



**Pelvis**  
**sagittal projektion**



crista iliaca

spina iliaca post. sup.

os sacrum

spina iliaca ant. sup.

fossa iliaca

foramina sacralia

art. sacroiliaca

spina iliaca post. inf.

linea arcuata

os coxae

acetabulum

symphysis

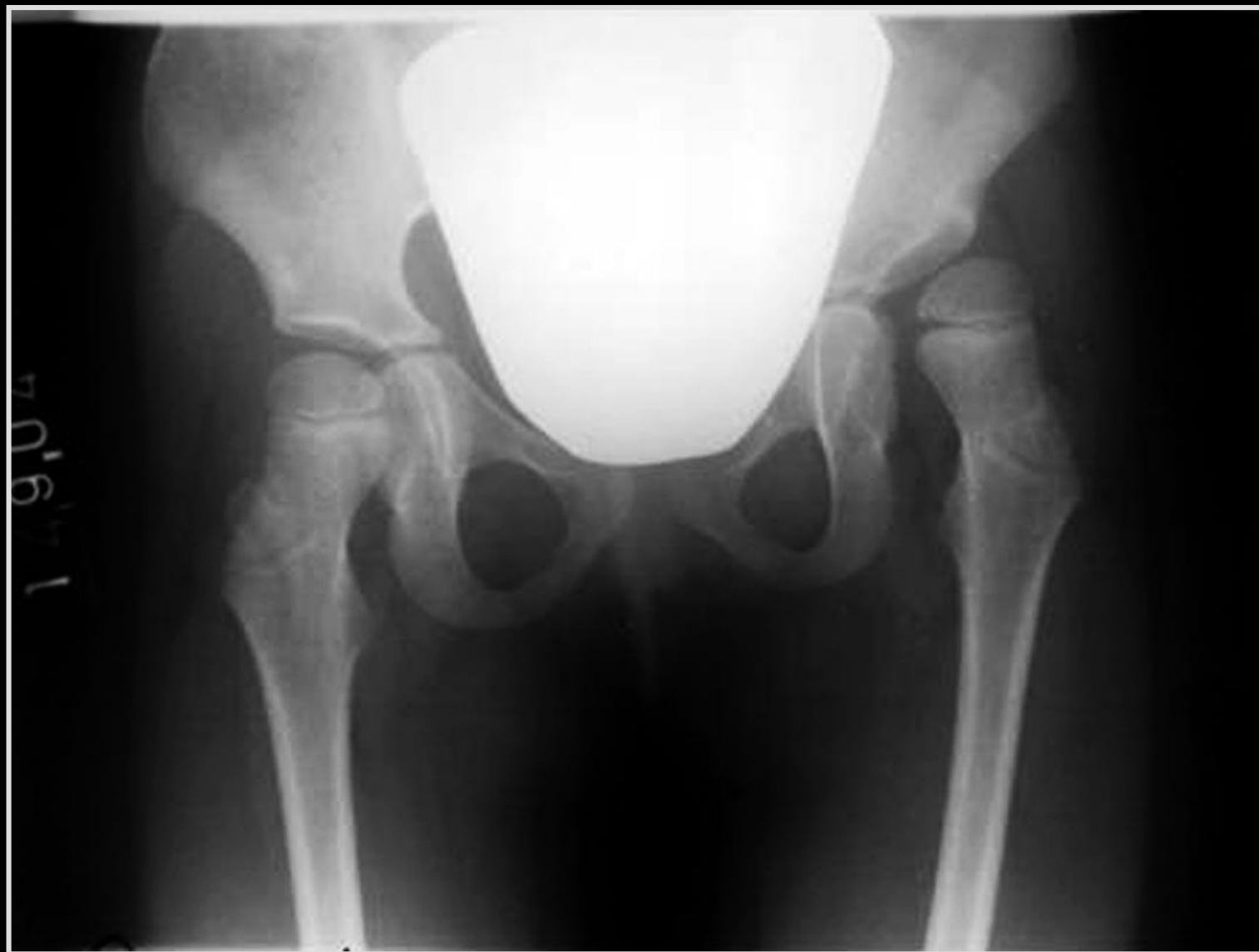foramen obturatum

os pubis

tuber ischiadicum

femur

# X-ray of the pelvis of an child



# Hip joint

sagittal projection

os coxae

fossa trochanterica

trochanter major

crista intertrochanterica

femur

collum femoris

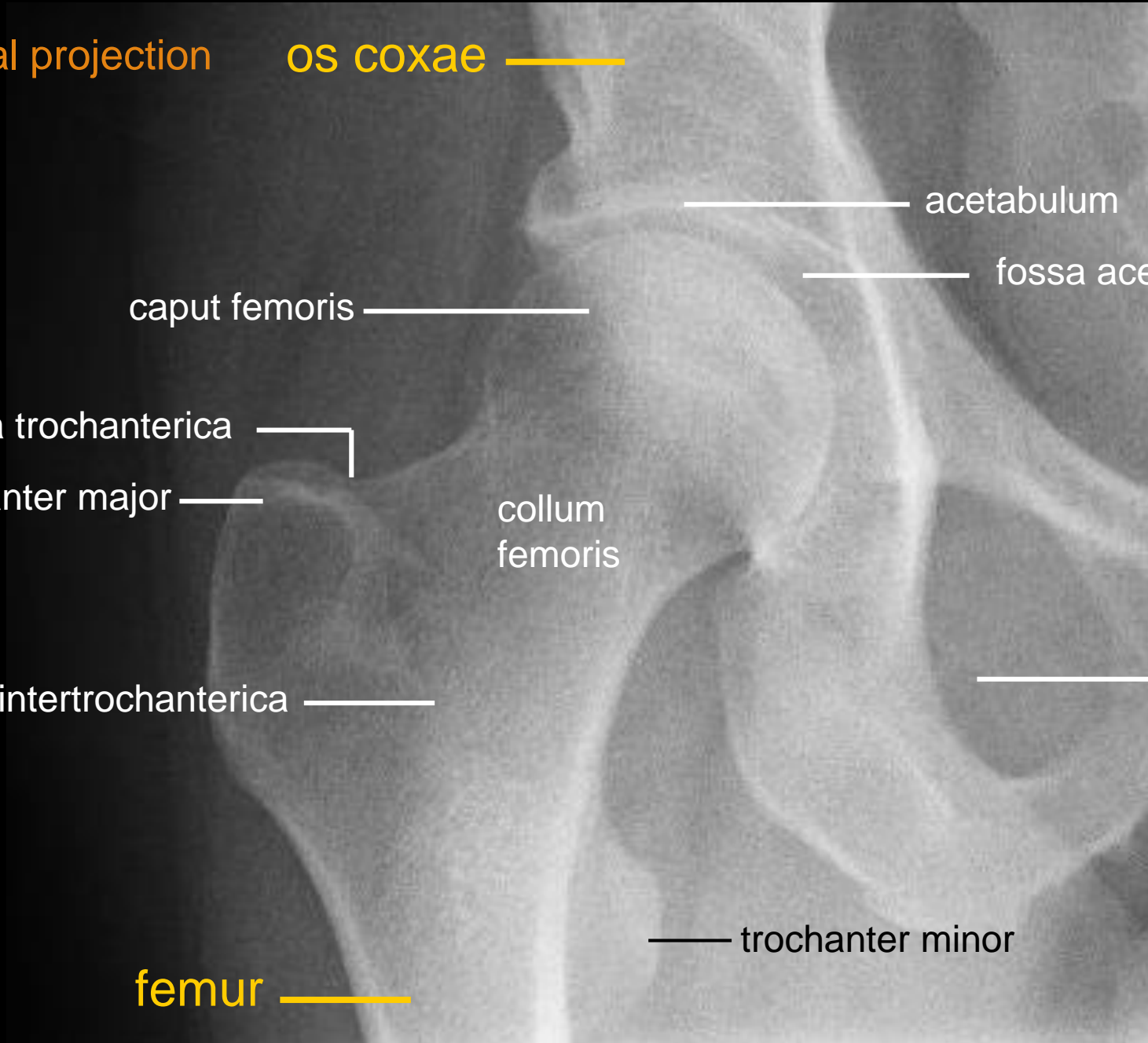
caput femoris

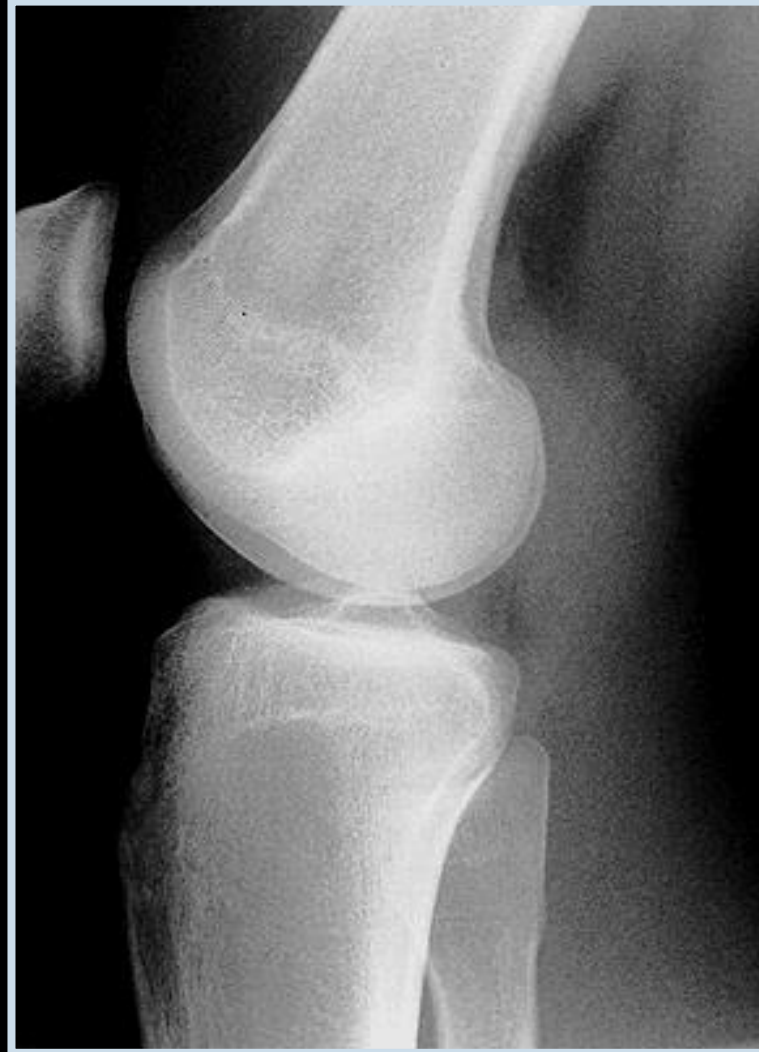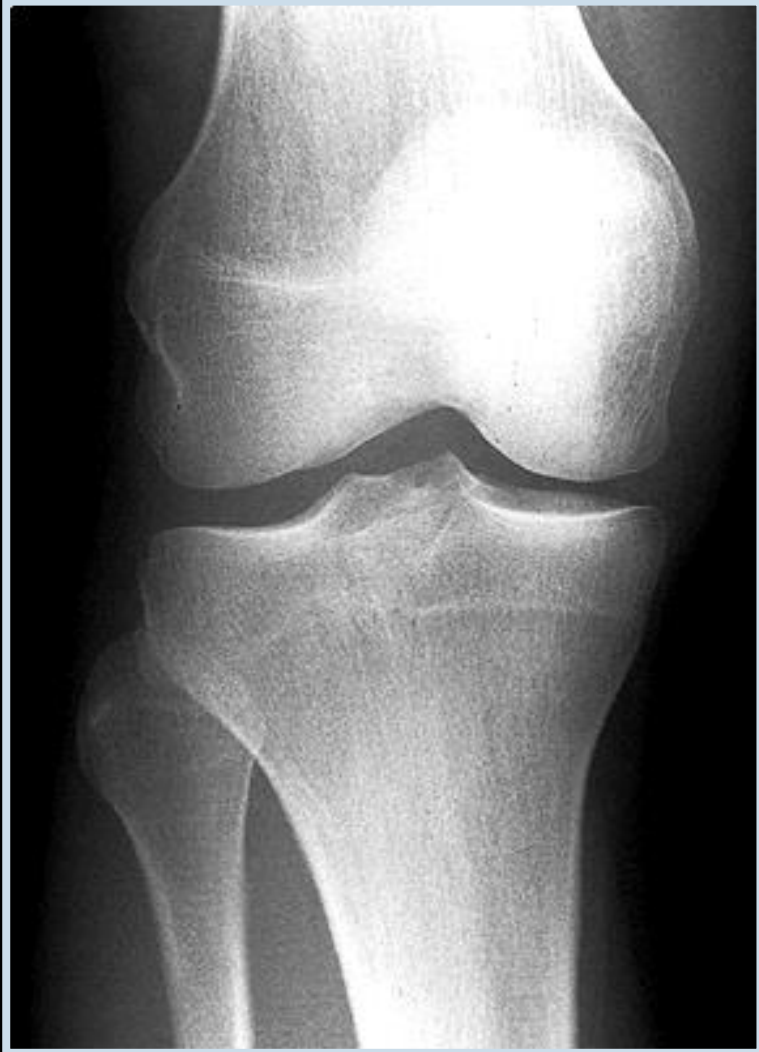trochanter minor

acetabulum

fossa acetabuli

foramen obturatum

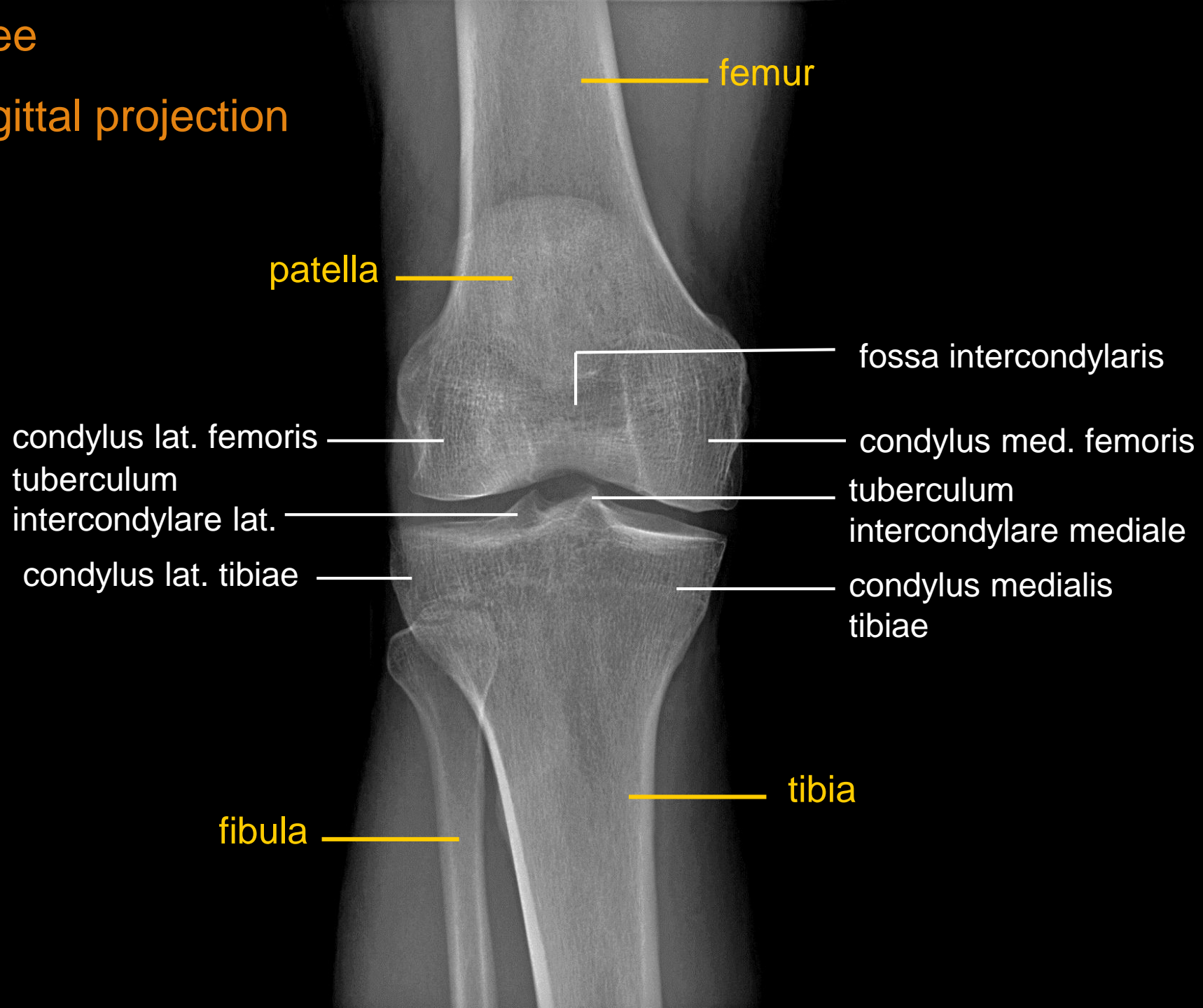






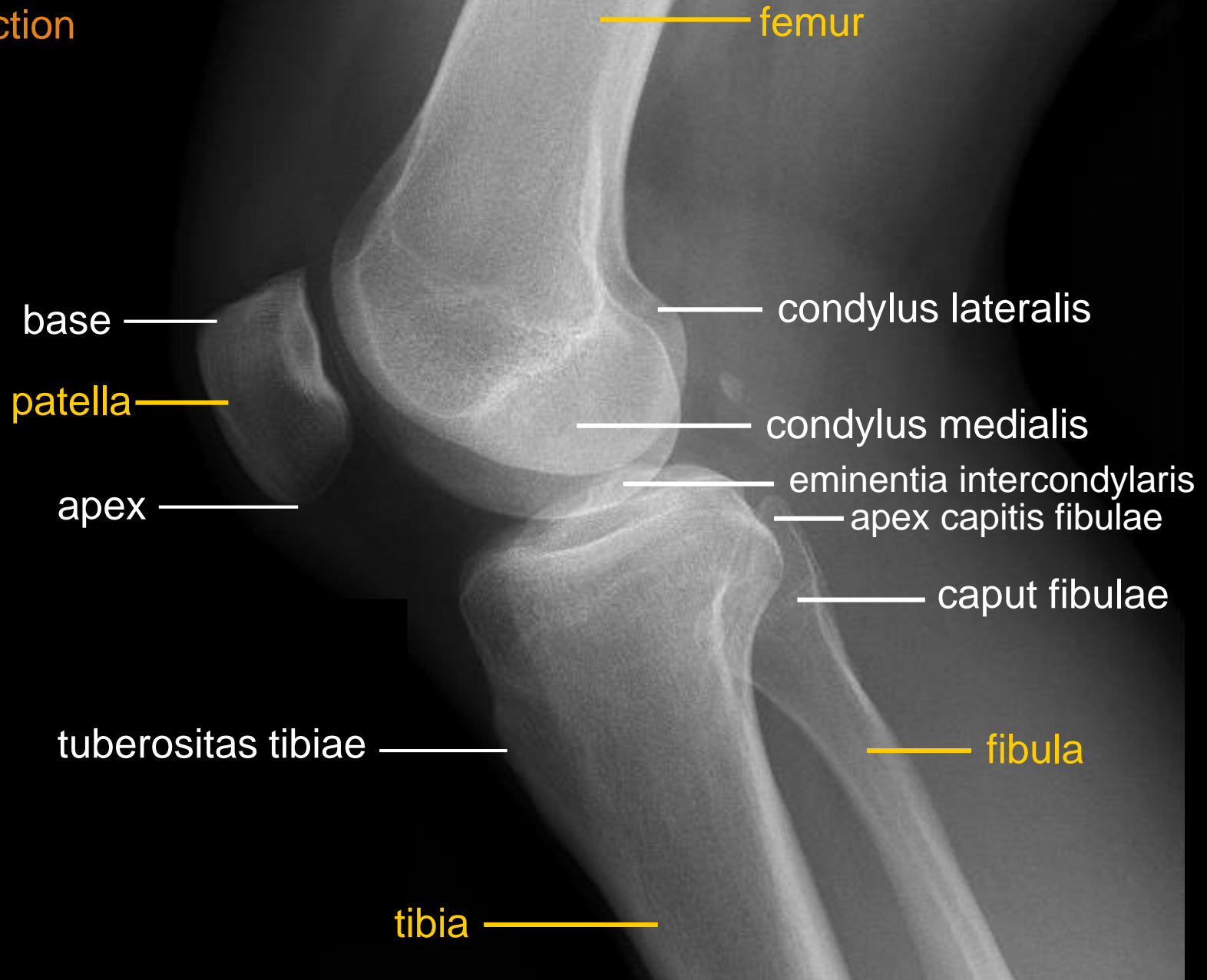
# Knee

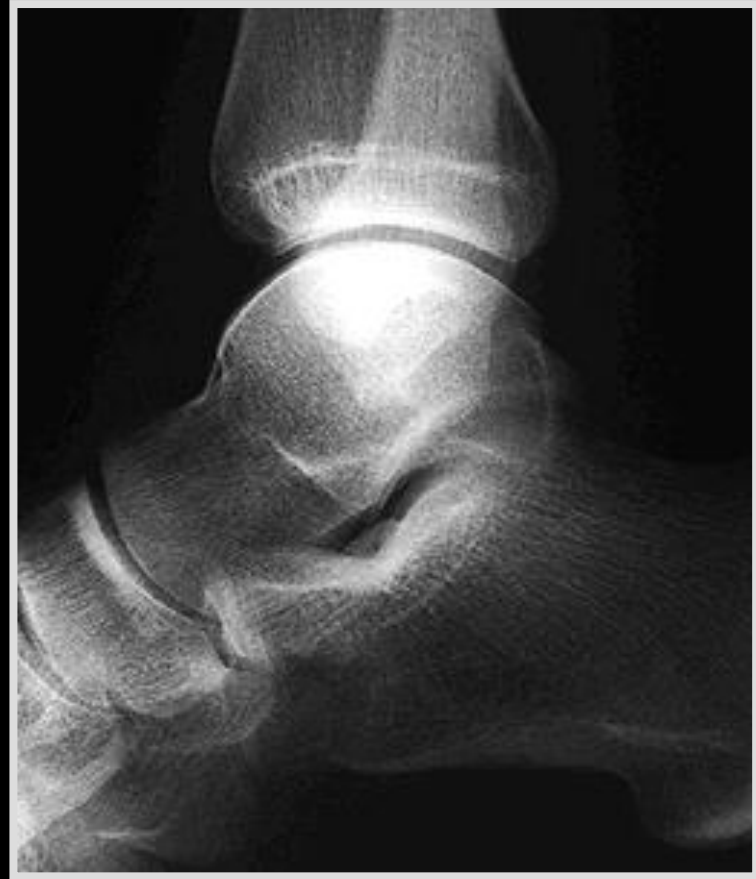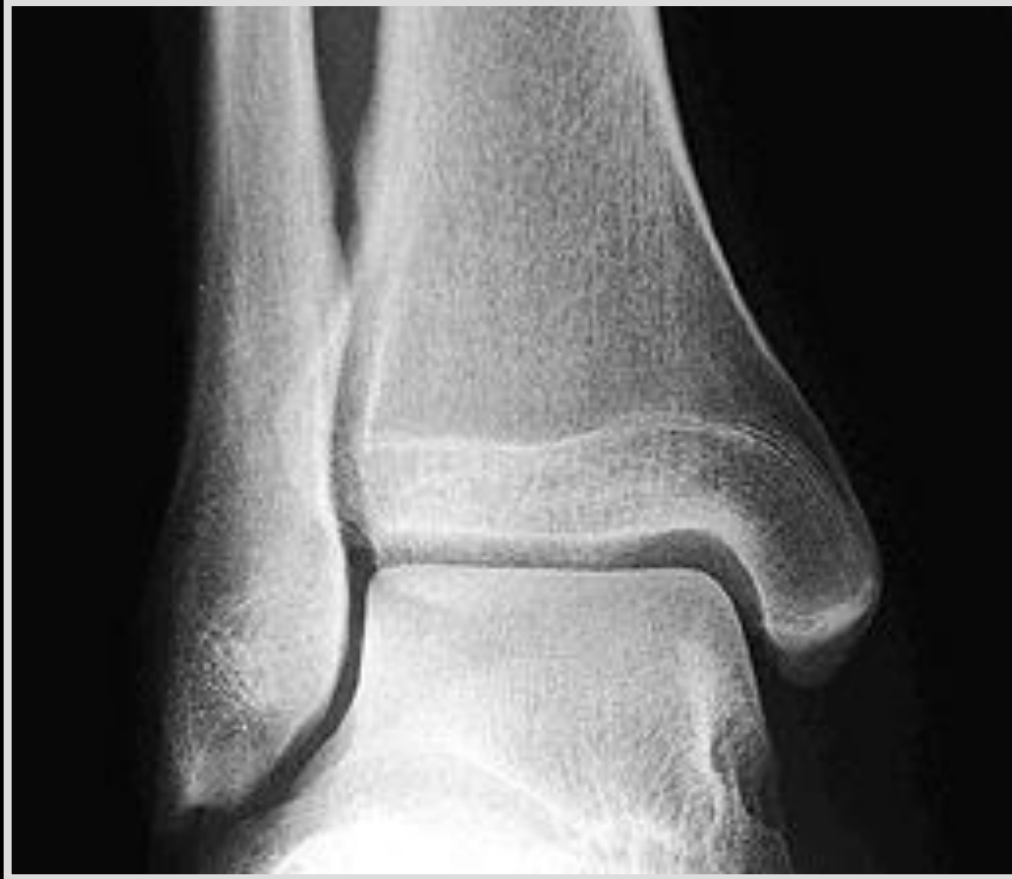## Sagittal projection

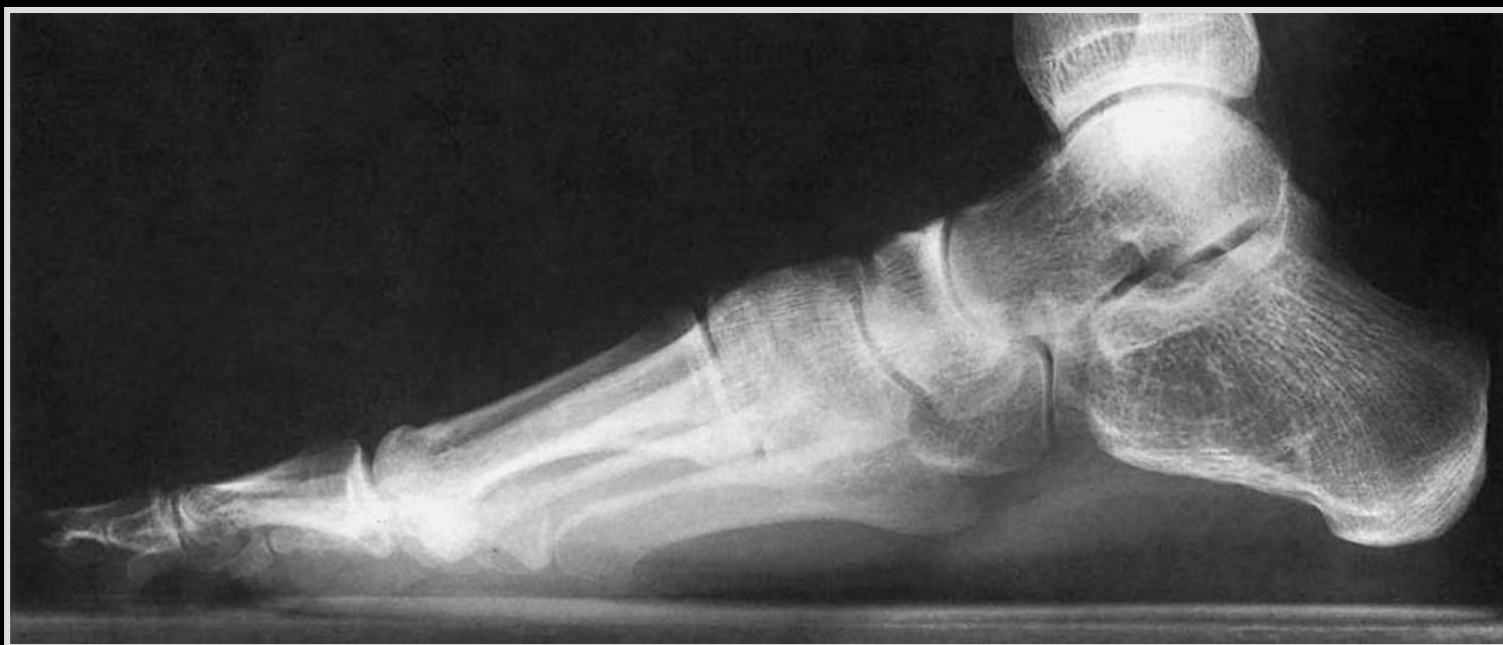
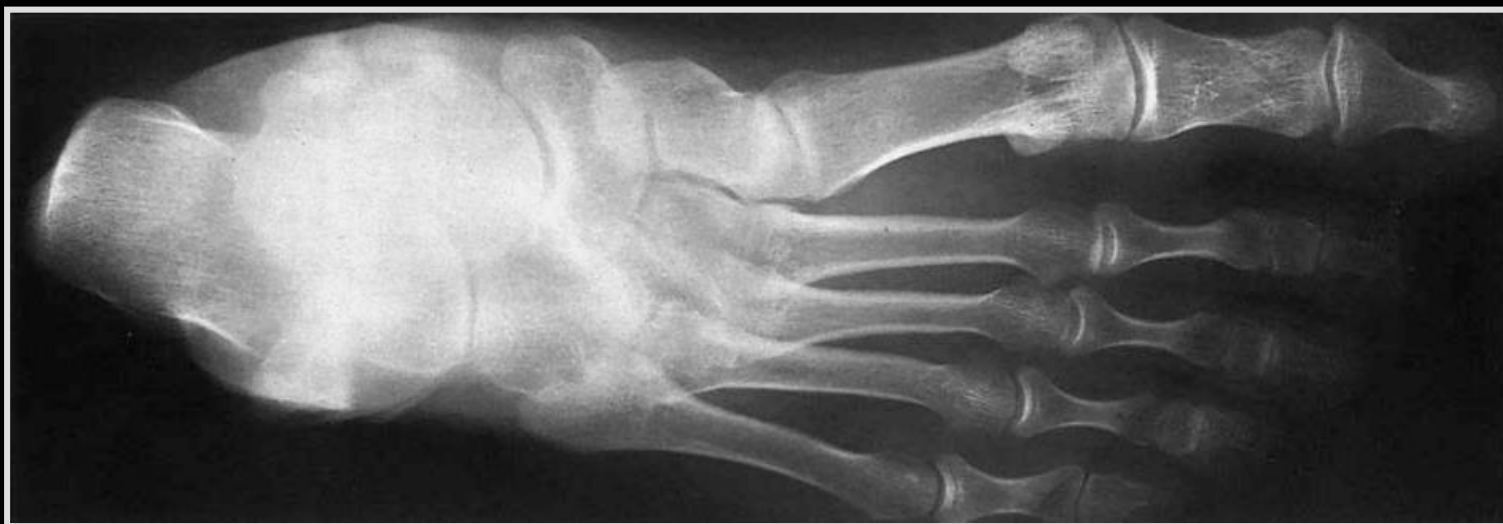
# Knee

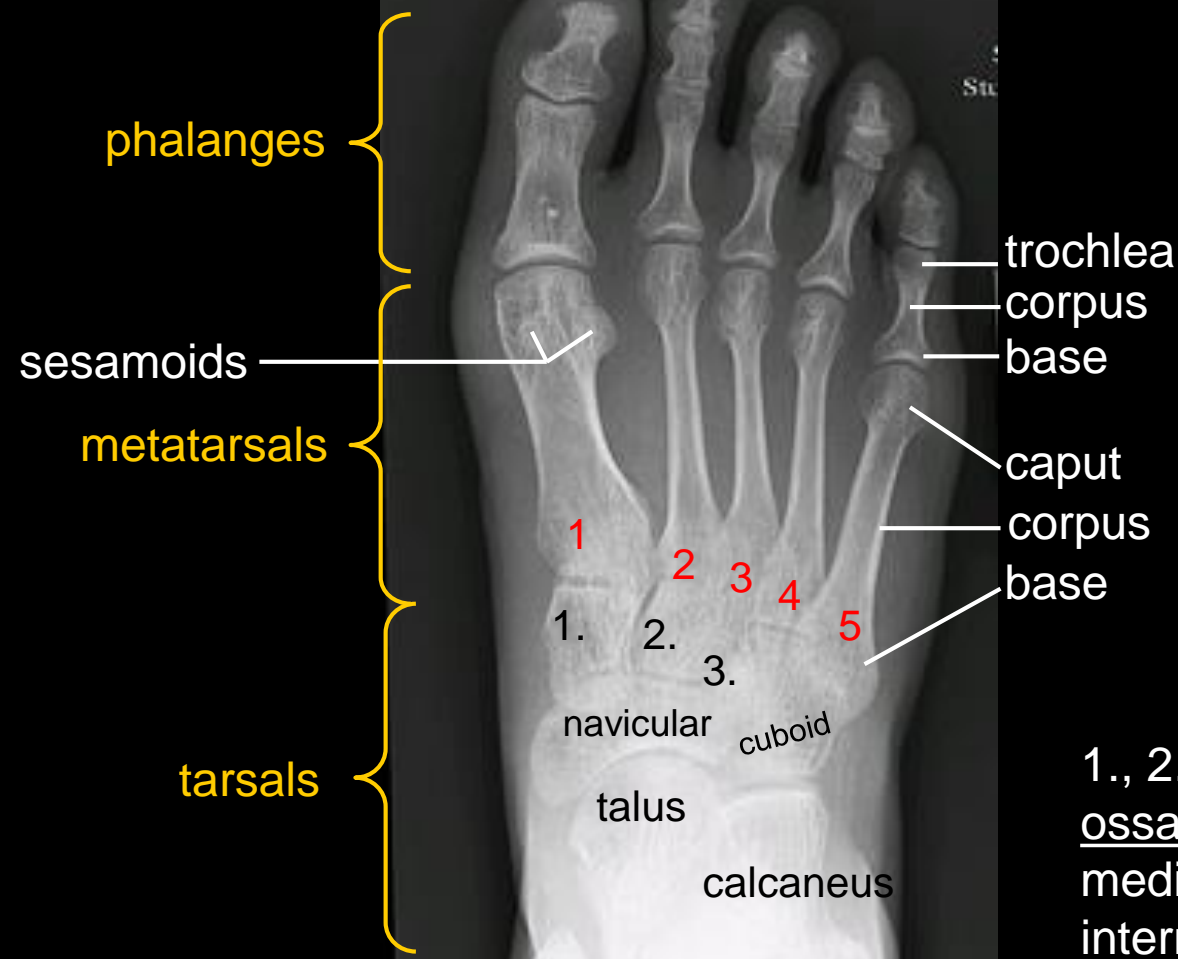
Lateral projection







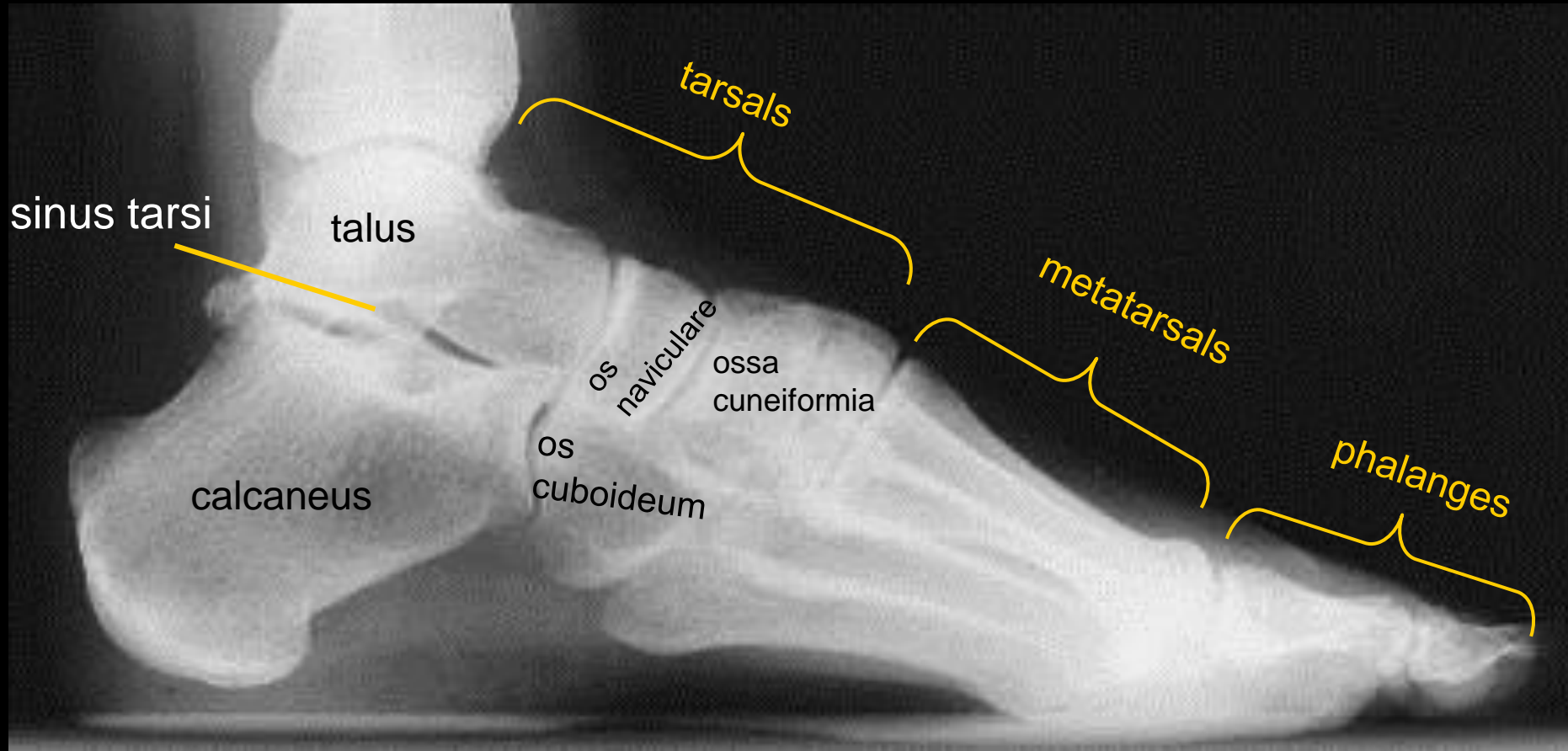
**FOOT**  
dorsoplantar  
projection



1., 2., 3. =  
ossa cuneiformia  
mediale,  
intermedia et  
laterale

# Foot

## Lateral projection



**The pictures used in this lectures were taken from following sources (if it was not written under the picture else):**

- **Atlas der Anatomie des Menschen/Sobotta. Putz,R., und Pabst,R. 20. Auflage. München:Urban & Schwarzenberg, 1993**
- **Netter: Interactive Atlas of Human Anatomy.**
- **John T. Hansen Netter´s clinical anatomy, Elsevier, 2014**
- **Drake et al: Gray´s Anatomy for Students. 2010**
- **Naňka, Elišková: Přehled anatomie. Galén, Praha 2009.**
- **Čihák: Anatomie I, II, III.**
- **Own archiv of the lecturer, archiv of Department of Anatomy, LF MU BRNO**

# Thank you for your attention

---

