

GENERAL ARTHROLOGY

RNDr. Michaela Račanská, Ph.D.

Lecture 7 – DENTISTRY – Autumn 2016

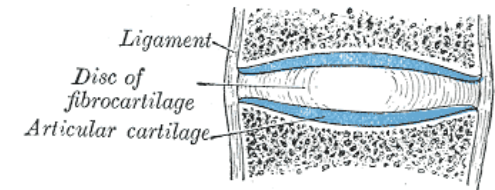
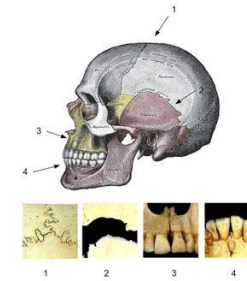
Skeletal junctions

Juncturae *seu* Systema articulare

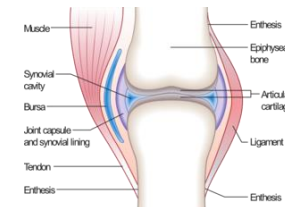
Two main types of connections:

1. Synathrosis /fibrous joint, fluent connection/ - union by some kind of the connective tissue

(fibrous tissue, cartilage, bone)



2. Diarthrosis /synovial joint, connection by touch/ - union by touch (by articular surfaces and another additional features)

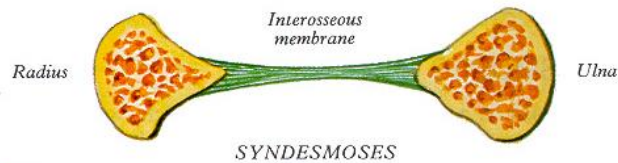


Fibrous joint (synarthrosis)

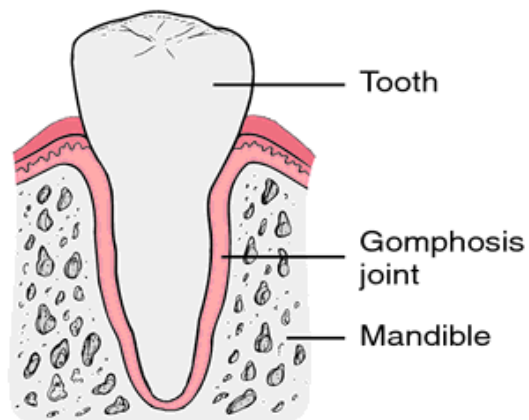
- Continuous connections by a layer of connective tissue between bones nearly immobile
- The articulare surface are missing!
- Differentiation according the type of connective tissue
 - 1) **Syndesmosis** – *articulatio fibrosa*, bones are joined by **fibrous tissue**
 - 2) **Synchondrosis** – *articulatio cartilaginea*, bones are joined by **cartilage**
 - 3) **Synostosis** – *articulatio ossea*, bones are joined by **bone tissue**

Syndesmosis (*art. fibrosa*)

1) connective tissue (*ligaments*), band of collagen fibrous tissue, (like a rope, ribbon or flat membrane)



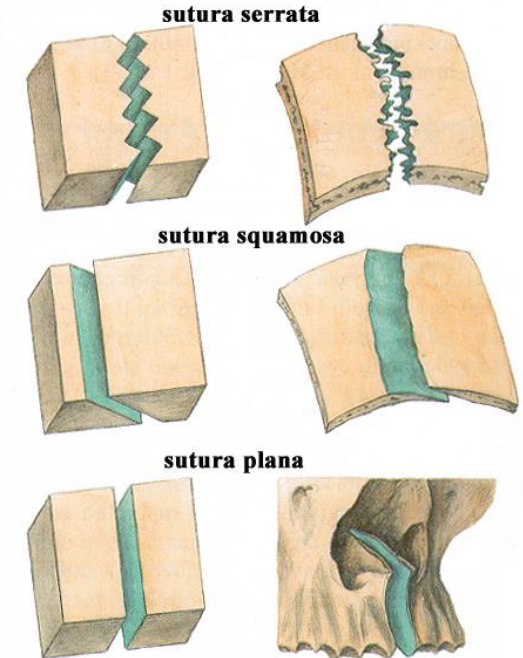
2) wedging (*gomphosis*): fixation of tooth to the alveolus



3) sutures between flat skull bones (*suturae*).

The main types of sutures:

- **serrated suture (*sutura serrata*)**
- **squamous suture (*sutura squamosa*)**,
- **flat suture (*sutura plana*)**

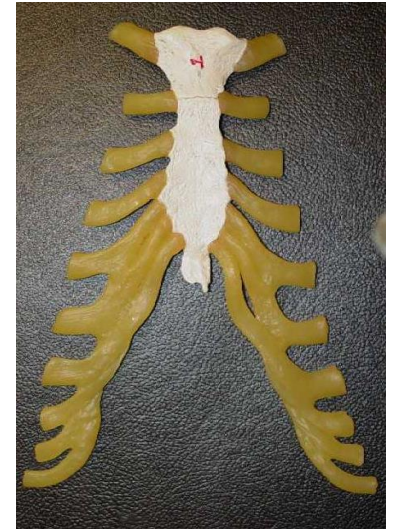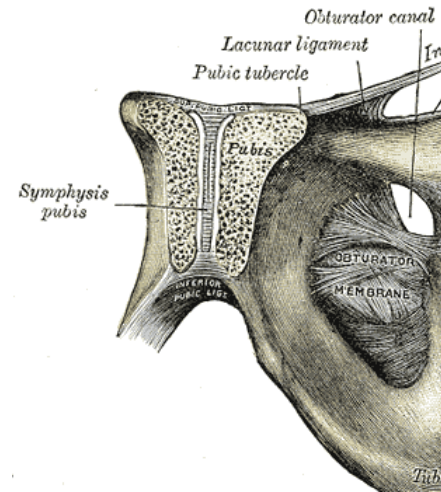


Source: anatomie Čihák

Synchondrosis (*art. cartilaginea*)

bones are joined by **cartilage**

- Connection using **hyaline** cartilage (connection of ribs and sternum, between bones of the skull base- in child)
- connection using **fibrous** cartilage (**SYMPHYSIS**) (intervertebral discs, pubic symphysis (*symphysis pubica*) between both pelvic bones)



Source:<http://www.wikiskripta.eu/index.php/Soubor:Gray394.png>

Synostosis (*art. ossea*)

- bones are joined by **bone tissue**, for example *synostosis sphenoccipitalis*
Connection of the bones using the bone tissue, the result is growing of two or more bones
- Examples: sacral bone, coccygeal bone, coxal bone, some skull bones
- In adulthood: synostosis of skull sutures - physiological, pathological



DIARTHROSIS (*junctura synovialis, articulatio*)

Articulation (joint) is **movable union** of two or more bones by touch of contact articular surfaces covered by the articular cartilage.

General features of a joint

➤ **Articular surfaces=*facies articulares***

(articular fossa=*fossa articularis*, articular head=*caput articulare*)

➤ **Joint capsule=*capsula articularis***

(*stratum fibrosum* and *stratum synoviale*)

➤ **Joint cavity=*cavitas articularis***

articular fissure filled by synovial fluid (*synovia*)

Synovial fluid (*synovia*) – nourishes an articular cartilage,

increases adhesion and decreases friction of contact surfaces

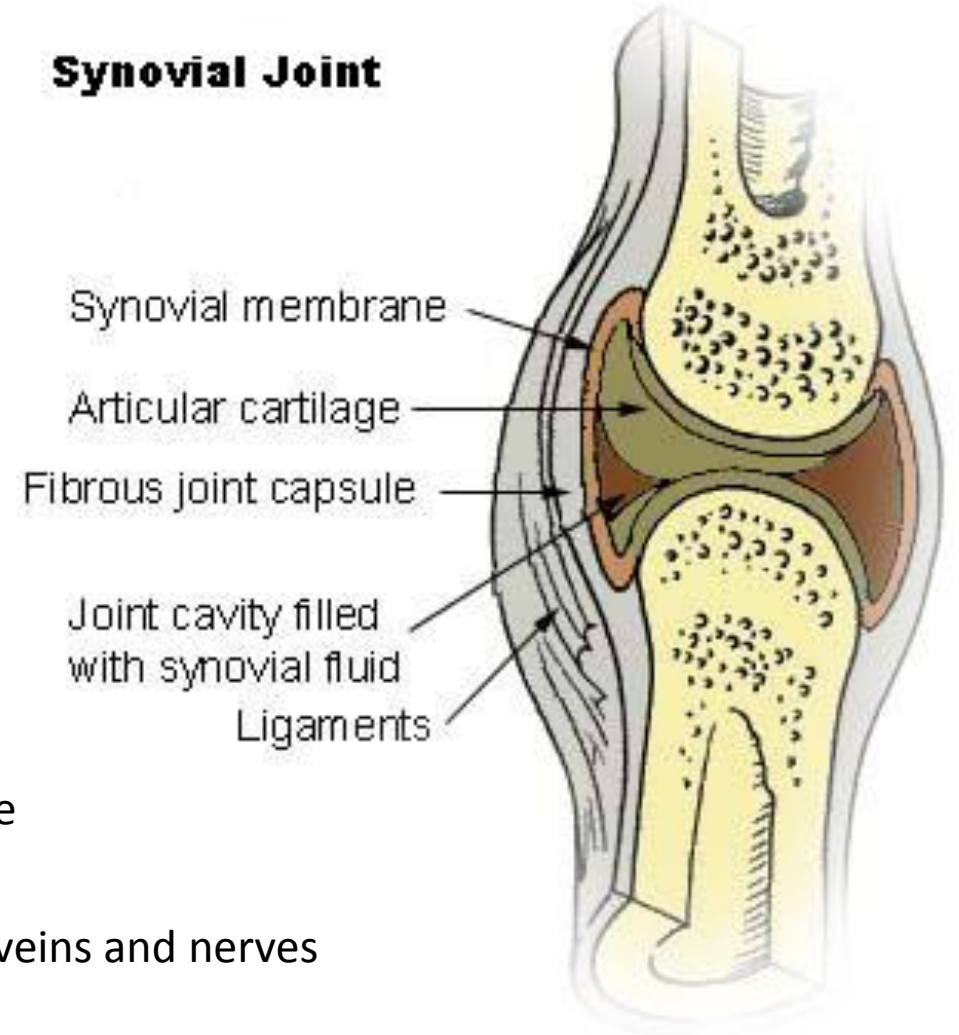
(*plicae*) or (*villi*) – are folds of the synovial layer of the articular capsule

and increase inner surface of articular capsule (*capsula articularis*)

➤ **Articular network (*rete articulare*)** – supplying of joint by arteries, veins and nerves

➤ **Special joint apparatus**

Synovial Joint



Additional features of the joints

- a) ***labrum articulare*** – fibrocartilaginous ring - broadening of a shallow articular fossa by a strip of cartilage
- b) **articular discs and menisci (*disci* and *menisci articulares*)** – plates of cartilage, which serves as elastic pads, discs divide the articular cavity into two parts, *menisci* only partly
- c) **ligaments (ligamenta)** are present in the most joints as extracapsular, capsular or intracapsular ligaments
- d) **articular muscles (*musculi articulares*)** – prevent of a strangulation of articular capsules
- e) **bursae and synovial pockets (*bursae synoviales*)** – are small cavities close to the joint. They are constructed by synovial membrane and synovial fluid. Usually may communicate with the joint cavity.

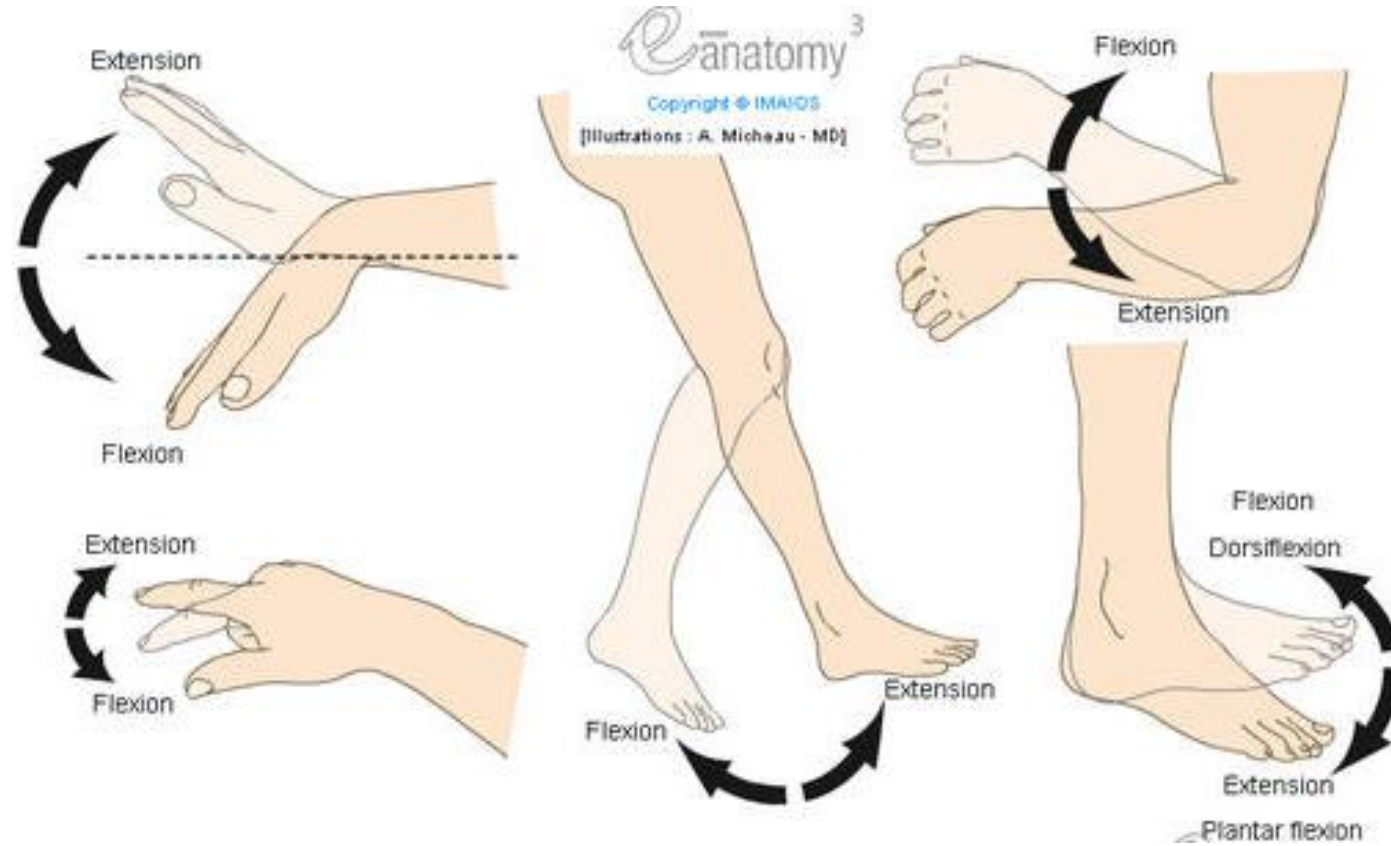
Movements in joints

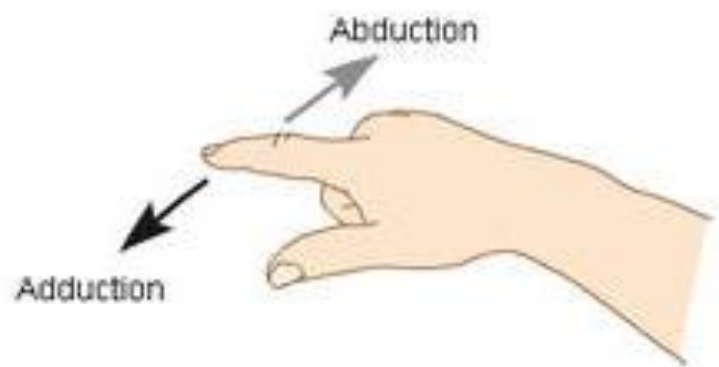
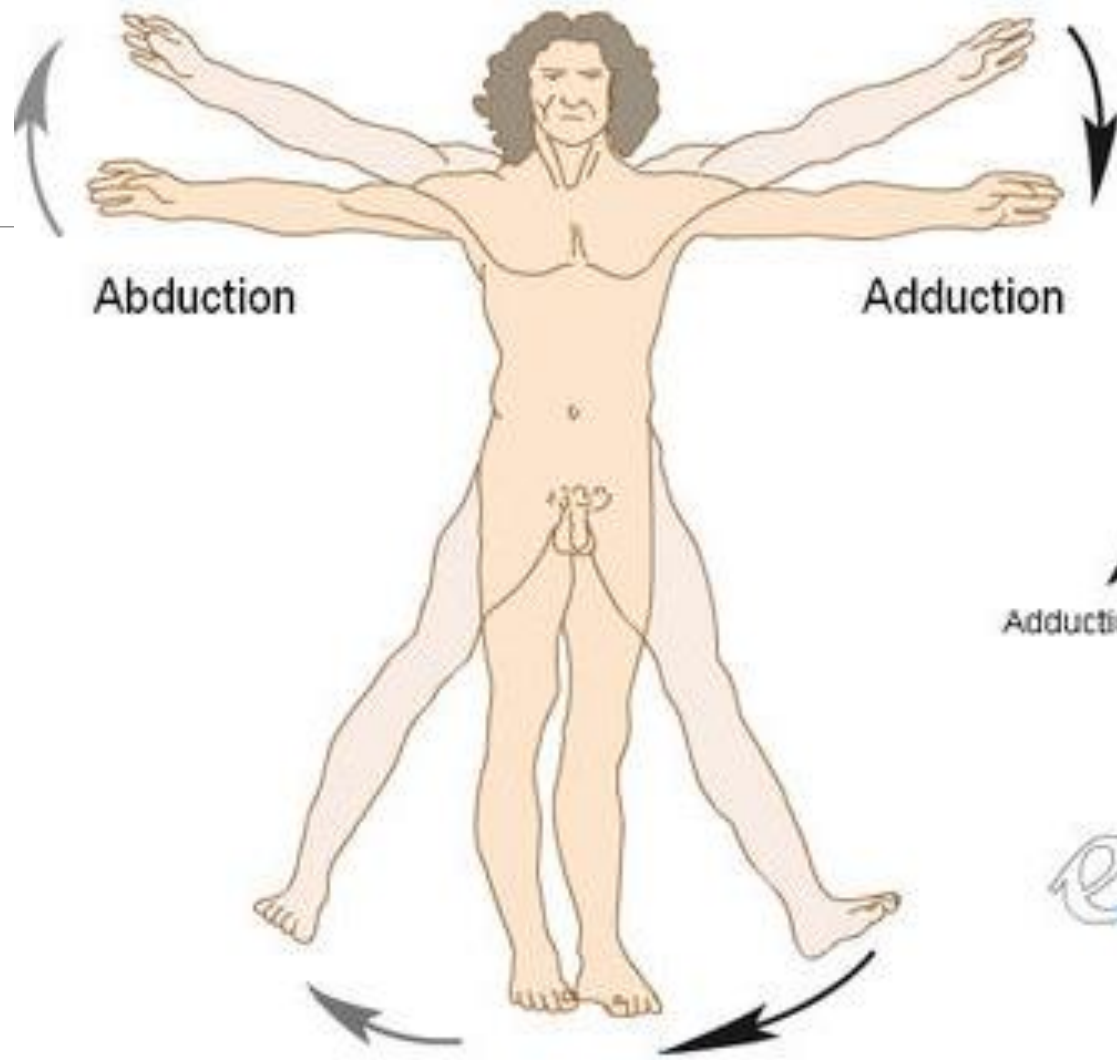
- Possible according to the shape of articulation surfaces and on position of muscles attachments around the joints
- Joints monoaxial, biaxial, multiaxial

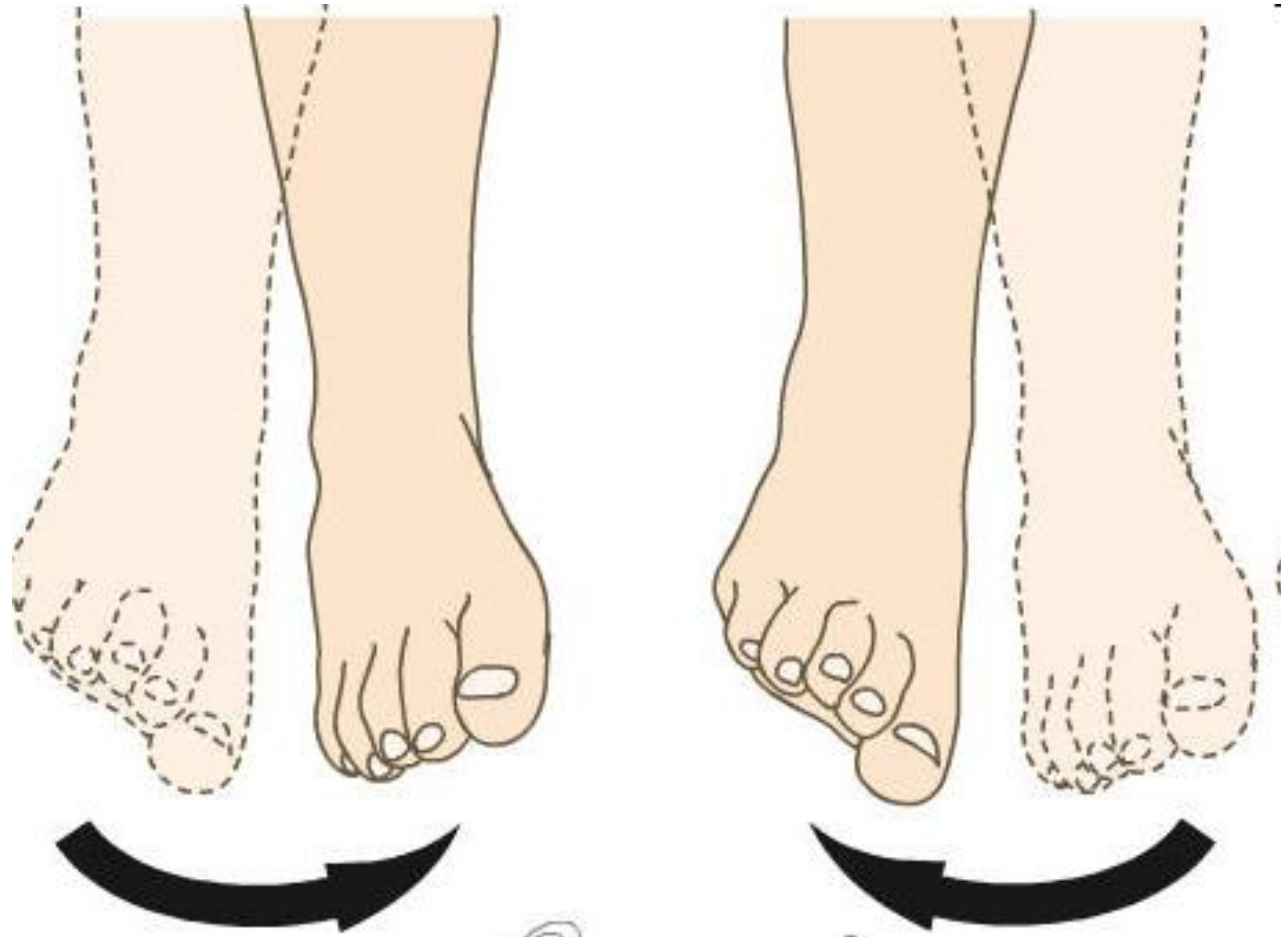
Basic position of the joint - basic anatomical position

Middle position of the joint - most relaxed joint capsule

Movements in joints







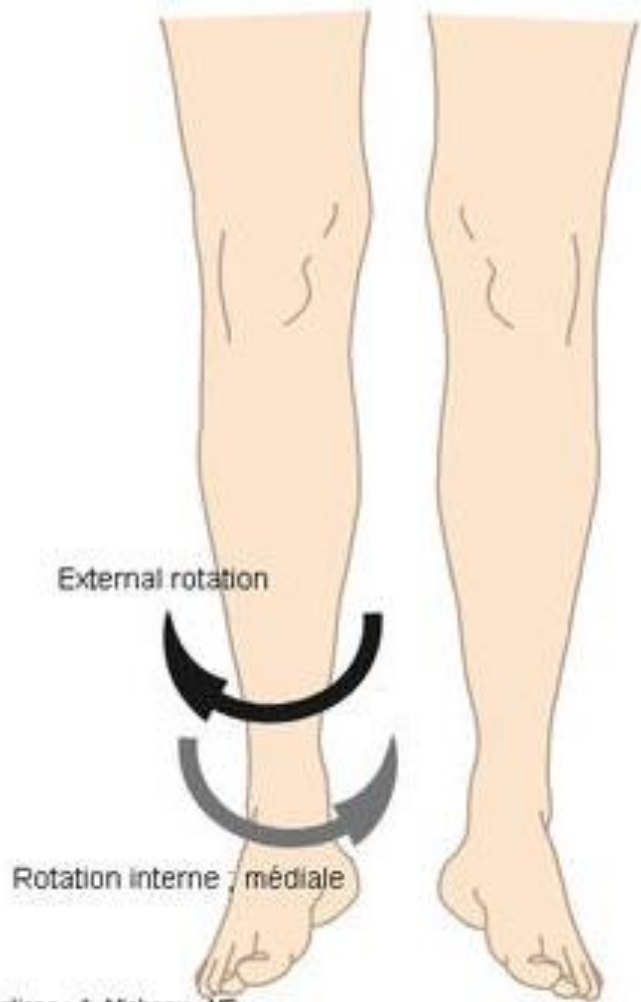
Inversion

e³anatomy

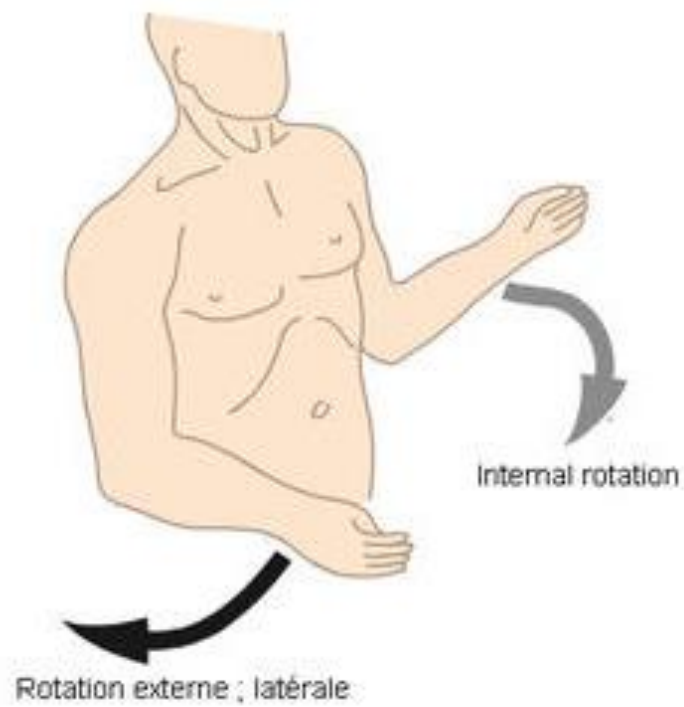
Copyright © IMAIOS

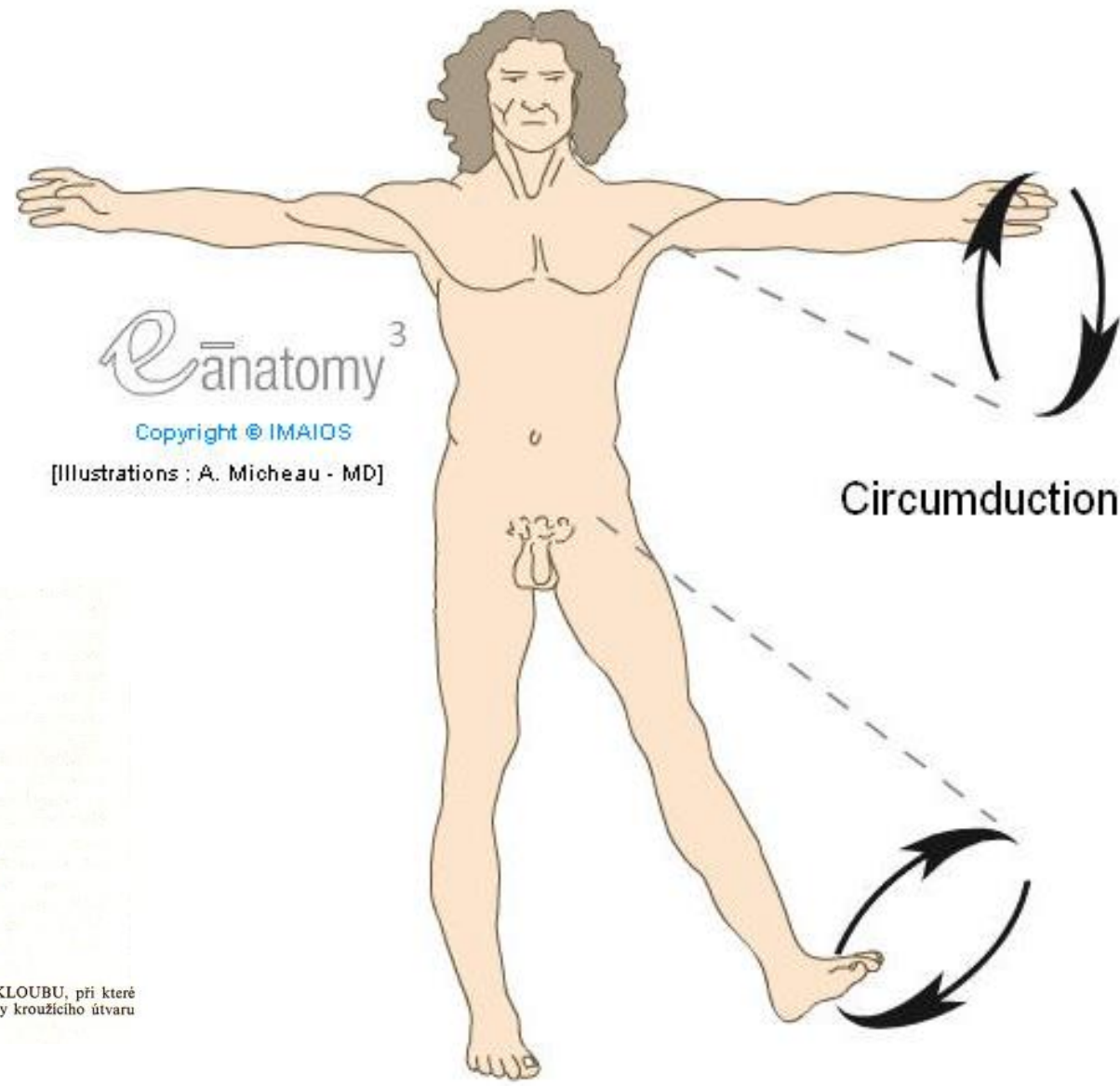
Eversion

[Illustrations : A. Micheau - MD]



Illustrations : A. Micheau - MD

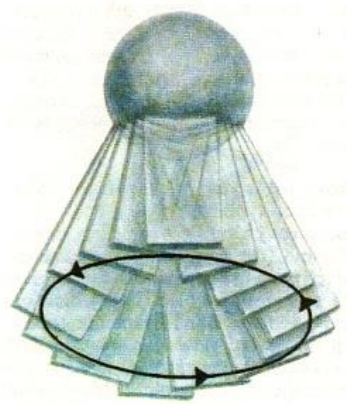




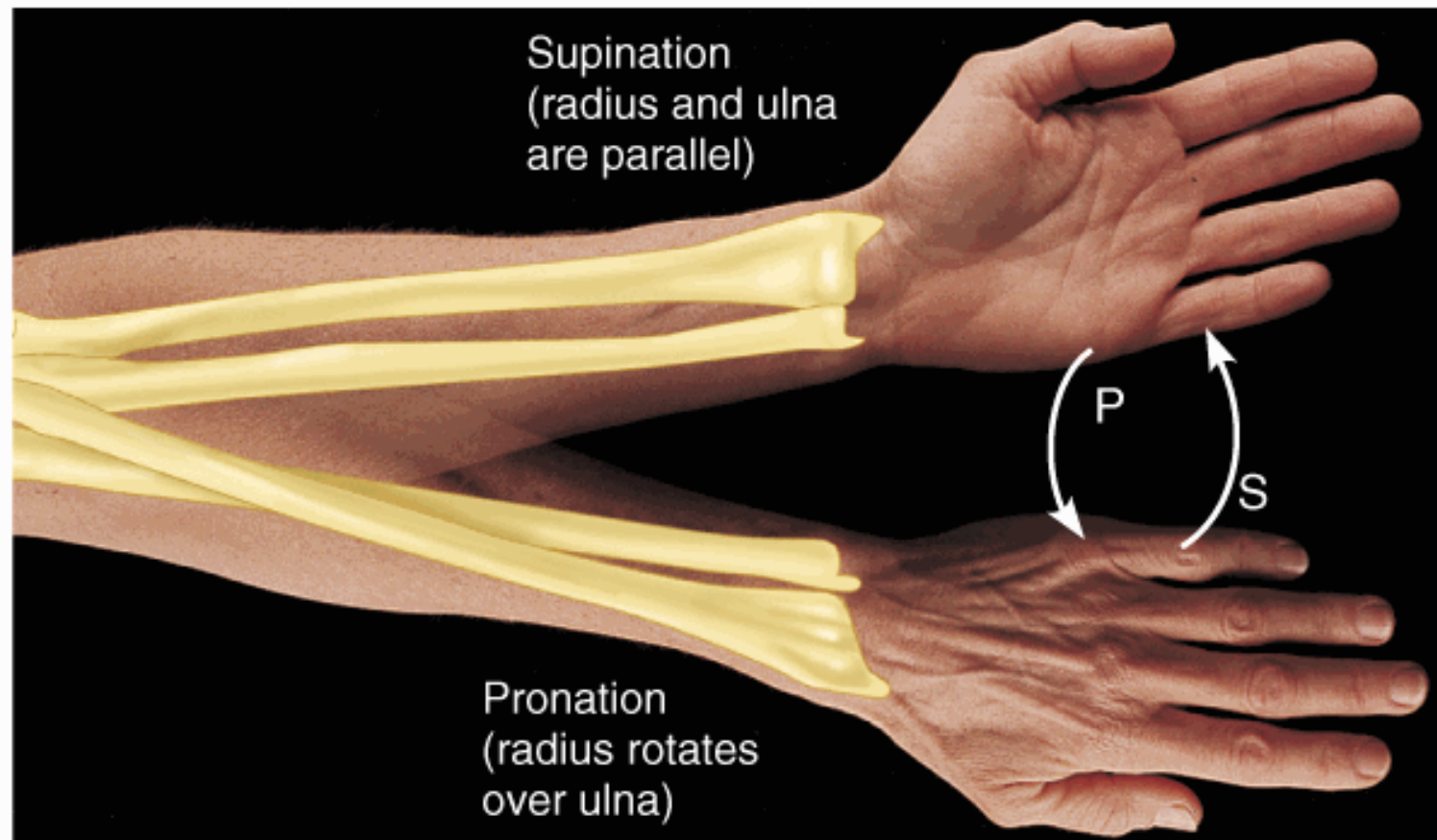
eānatomy³

Copyright © IMAIOS

[Illustrations : A. Micheau - MD]



100. CÍRKUMDUKCE KULOVITÉHO KLOUBU, při které chybí rotace (srov. obr. 101); jednotlivé strany kroužičho útvaru jsou obráceny stále stejným směrem



(a) Supination (S) and pronation (P)

Copyright © 2001 Benjamin Cummings, an imprint of Addison Wesley Longman, Inc.

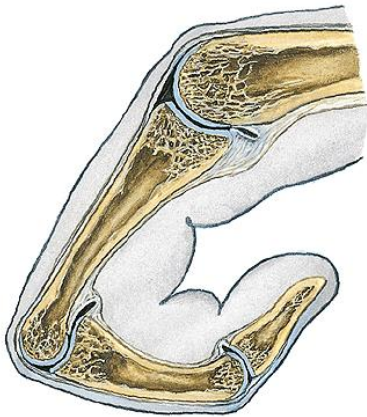
Types of joints

Joints may be classified from various points of view.

According to a number of articular surfaces:

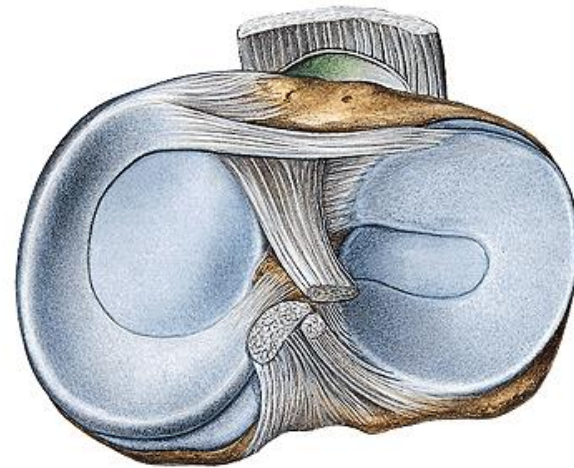
a) Simple joints

- only two bones are in contact



b) Compound joints

- more than two bones are in contact
- two bones and between them is located disk (*discus*) or menisk (*meniscus articularis*).

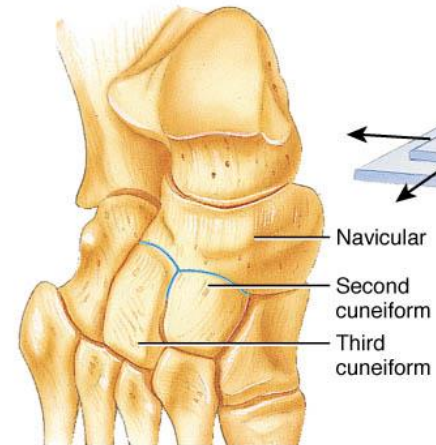
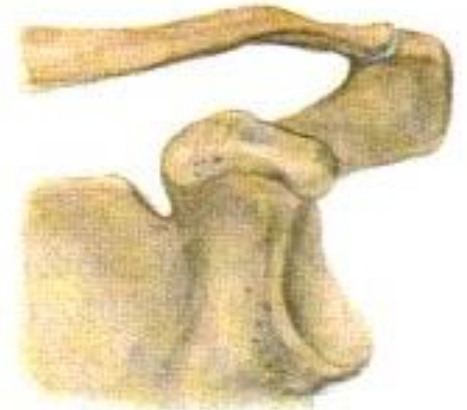

Classification of joints according to the shape of articular surfaces:

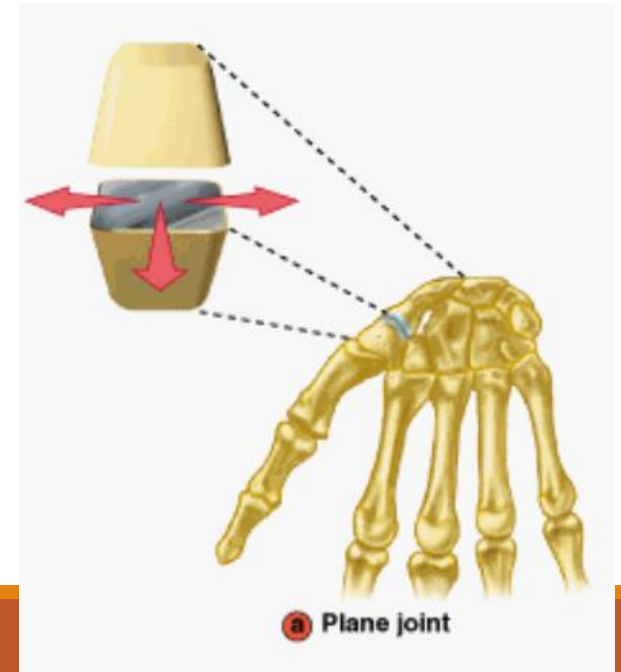
- **spheroidal joint (ball-and-socket joint)** (*articulatio spheroidea*) – head has shape like a sphere or its part,
free spheroid joint (*arthrodia*)
spheroid joint with restricted movements (*enarthrosis*)
- **ellipsoidal (condyloid) joint** (*articulatio ellipsoidea*)
- **cylindrical joint:**
 - pivot joint (trochoid)** (*articulatio trochoidea*), wheel joint - the axe of movement is parallel with the longitudinal axe of bone
 - hinge joint** (*articulatio trochlearis*); *ginglymus* - the axe of movement is in the right angle to the longitudinal axe of bone
- **saddle joint (sellar)** (*articulatio sellaris*)
- **plane joint** (*articulatio plana*)
- **amphiartrosis**

ART. PLANA

AMPHIARTROSIS



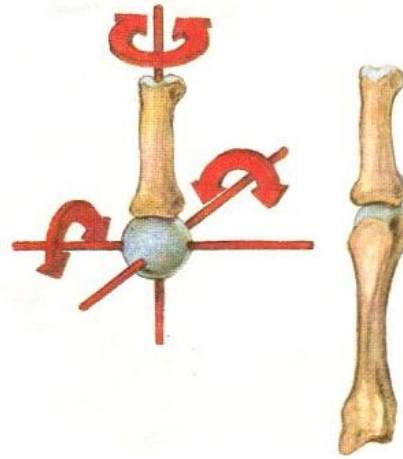
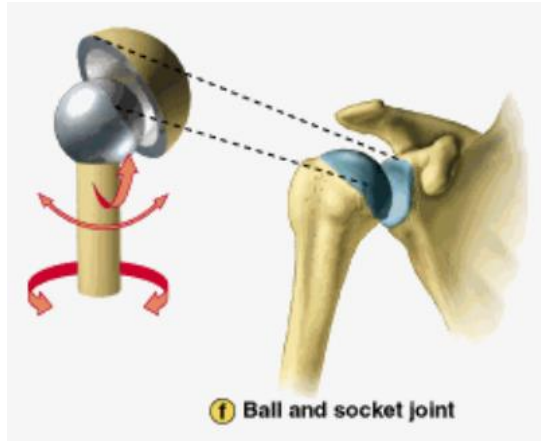
(a) Planar joint between the navicular and second and third cuneiforms of the tarsus in the foot



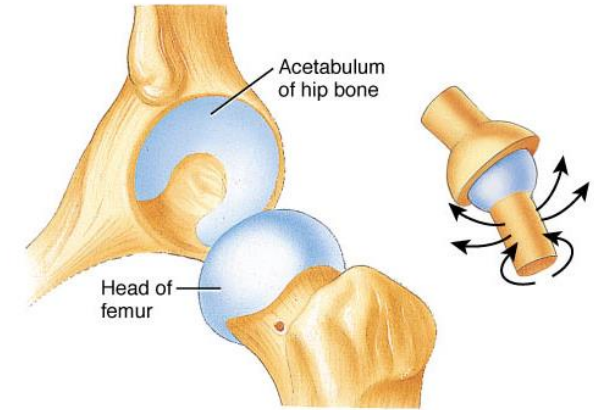
a Plane joint

BALL AND SOCKET

ARTHRODIA



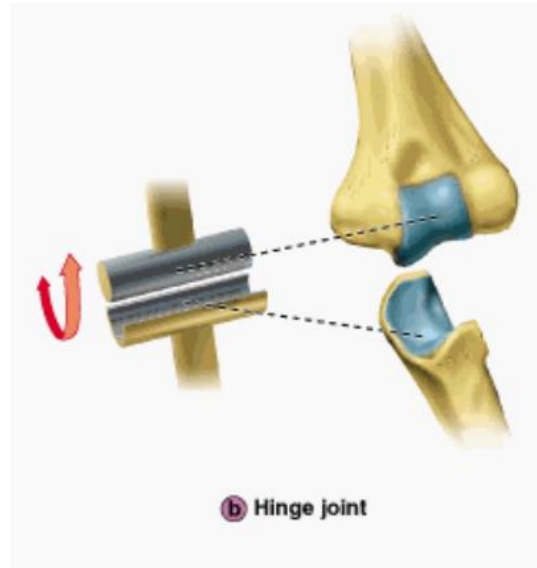
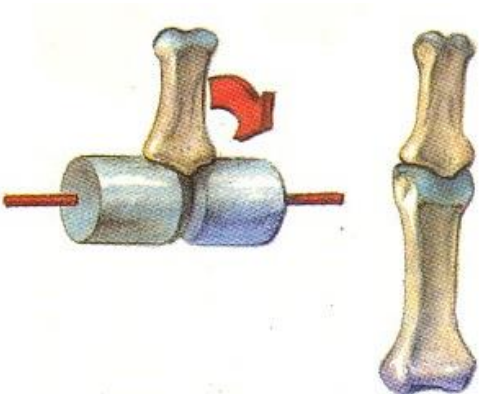
ENARTHROSIS



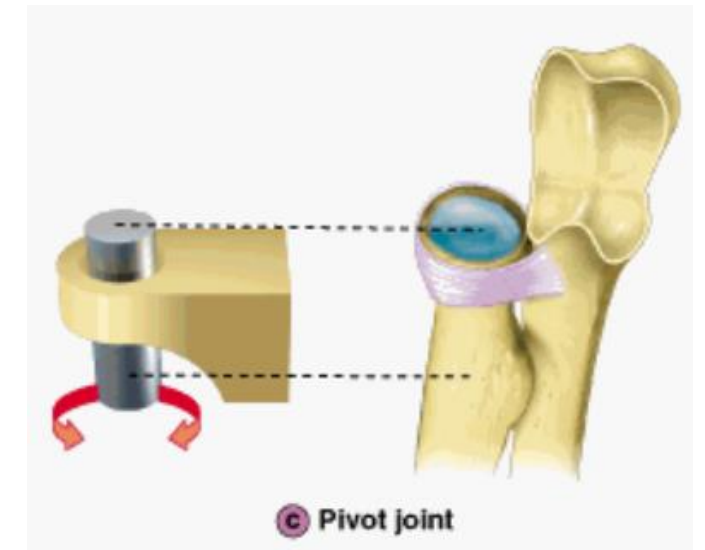
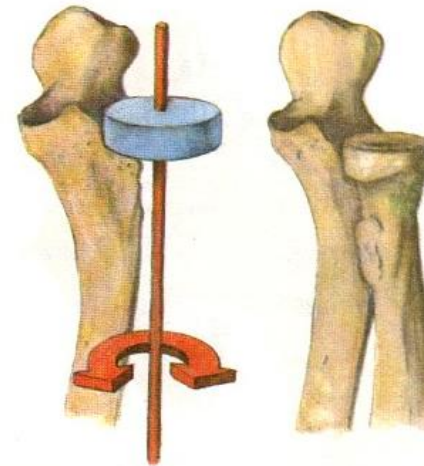
(f) Ball-and-socket joint between head of the femur and acetabulum of the hip bone

CYLINDRICAL JOINT:

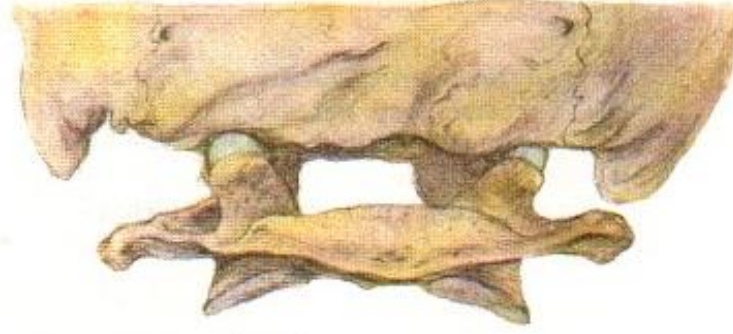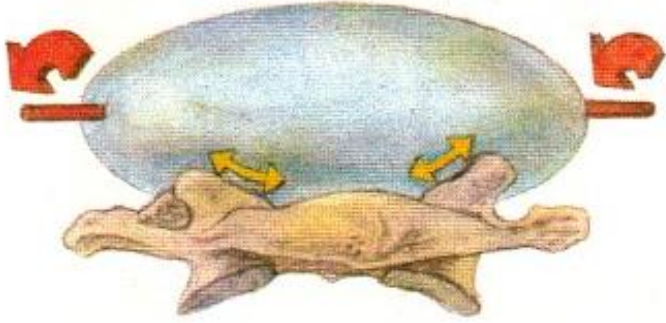
HINGE JOINT



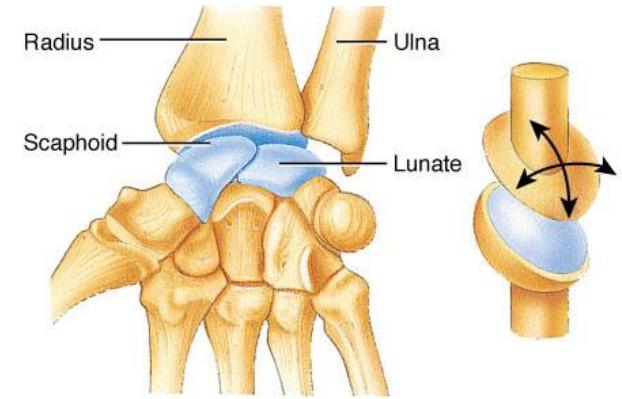
PIVOT JOINT



ART. ELLIPSOIDEA (CONDYLOID)

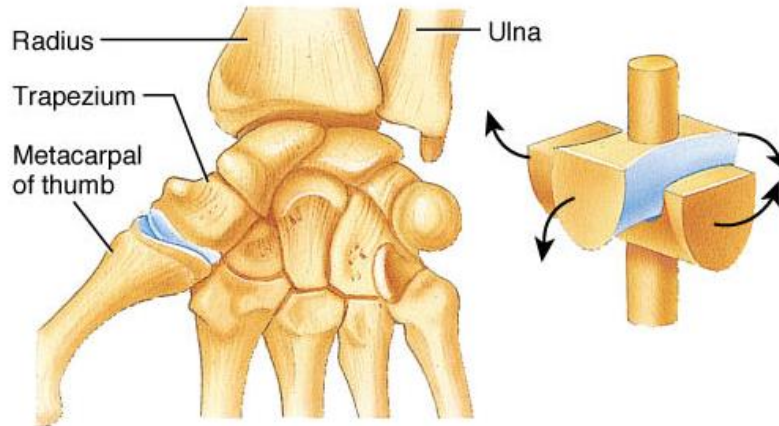
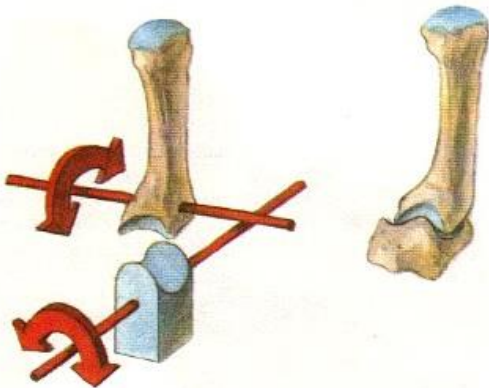


No rotation!
Movements according to the long axis

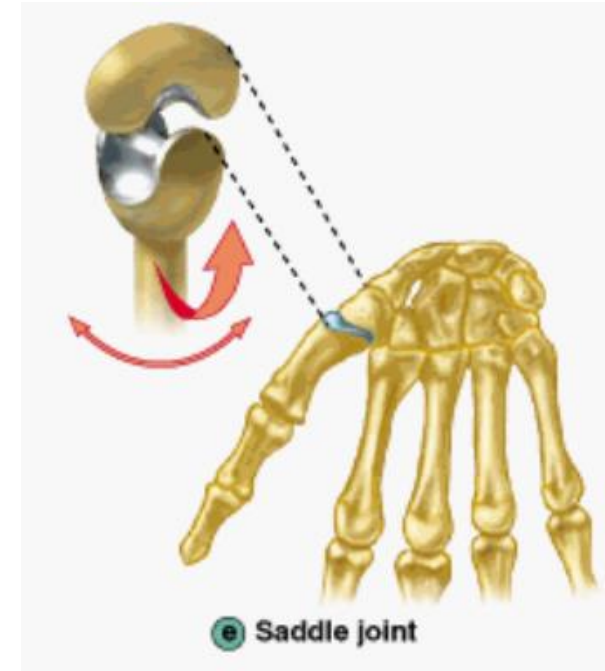


(d) Condyloid joint between radius and scaphoid and lunate bones of the carpus (wrist)

SADDLE JOINT



(e) Saddle joint between trapezium of carpus (wrist) and metacarpal of thumb



e Saddle joint

Classification of joints according to the level of moveability and number of axis of movements:

Joints with minimal movement:

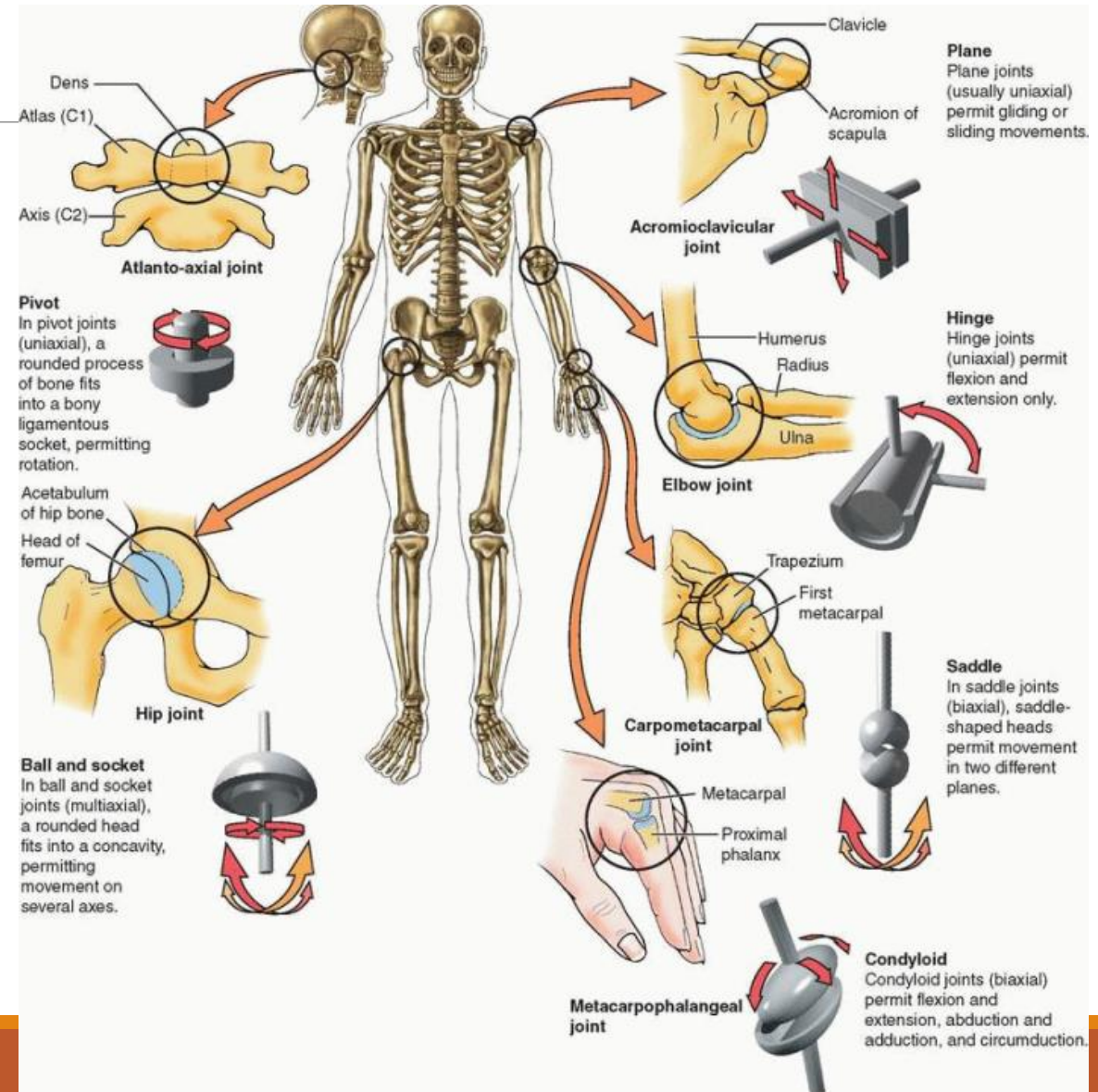
With irregular surfaces – **amphiarthrosis**

Joints with sliding movements:

- Flat joints - **articulatio plana**

Joints with rotational movements:

- Joint surfaces allow rotation along one to three axis
- One-axis joints (art. cylindroidea and art. trochlearis)**
- Two-axis joints (art. ellipsoidea and art. sellaris)**
- Triaxial joints (art. sphaeroidea)**



How to describe joints

Obvious are theoretical knowledges of the general arthrology, the knowledges of the special osteology is obvious.

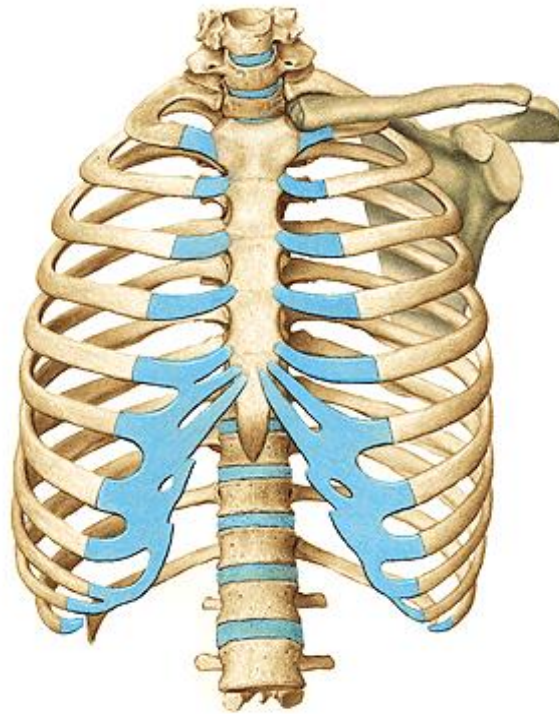
We are following this outline :

1. **Name** of the joint,
2. Names of the **articular surfaces**,
3. Characteristic of the **joint capsule**
4. Joint **auxiliary equipment**,
5. **Type of the joint**,
6. **Movements** in the joint.

An integral part is the description of the joints at the plain x-rays in sagittal and lateral projection

Special arthrology

Connections of the spine and thorax



Spine (columna vertebralis)

We can observe all types of junctiones on the spine
Synartroses and diarthroses as well

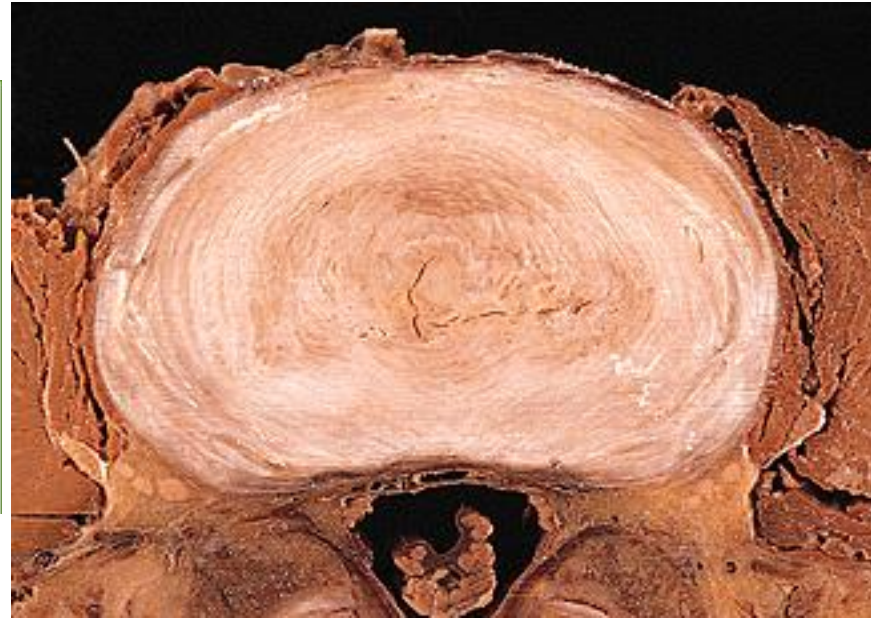
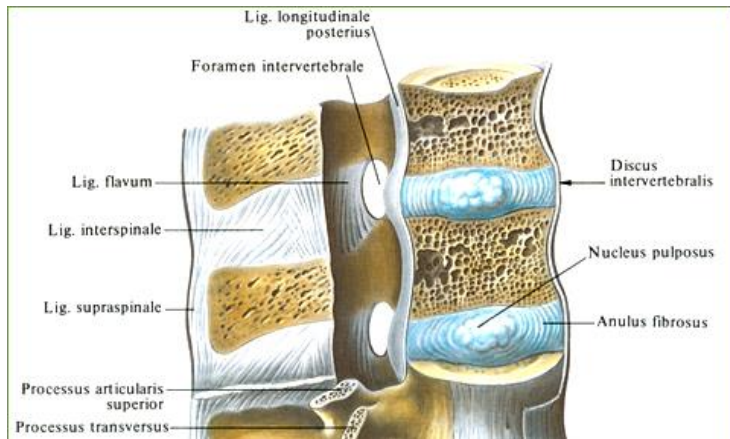
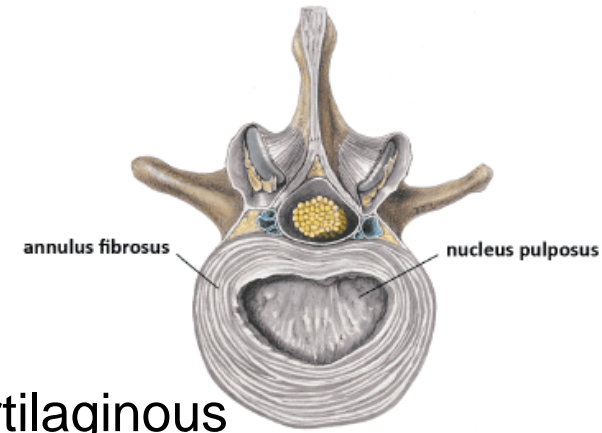
Synarthrosis

- syndesmosis- ligaments
- synchondrosis- disci intervertebrales
 - synchondrosis sacrococcygea
- synostosis- os sacrum, os coccygis

Diarthrosis- articulationes intervertebrales

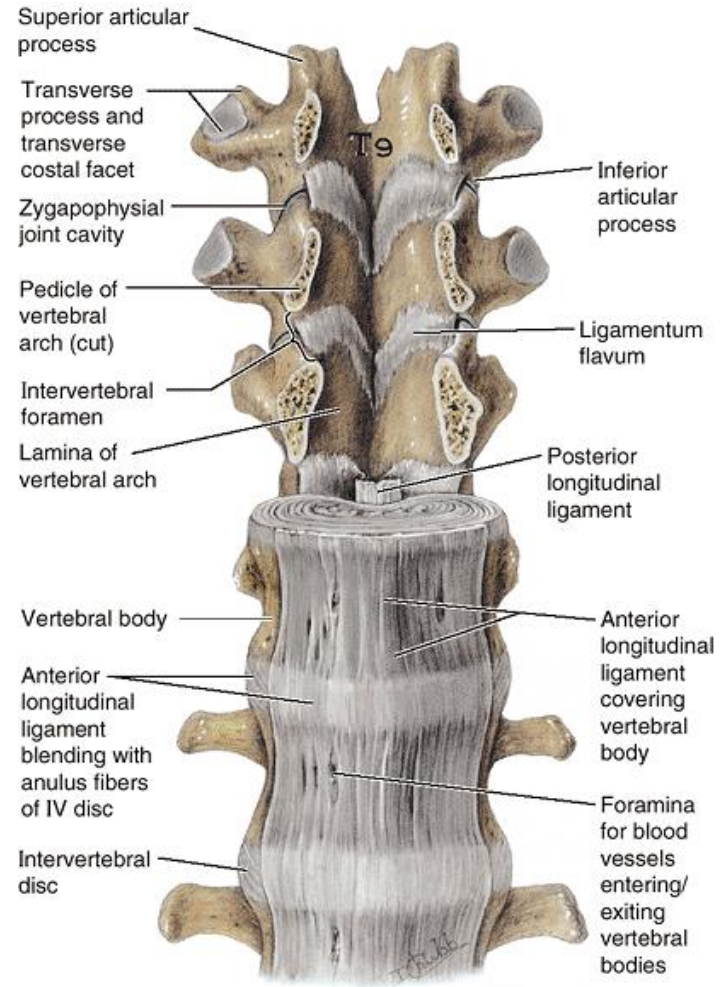
Joints of the Vertebral Bodies

- disci intervertebrales: altogether 23,
- cartilaginous (symphysis) connection, discus
- (anulus fibrosus – hyaline and fibrous cartilage - Concentric layers of fibrocartilaginous fibers, nucleus pulposus – fibrous tissue)



Junctions of vertebral arches

- elastic ligaments – ligamenta flava (interarcualia)



Anterior view

Junctions of articular processes of vertebrae

• articulationes intervertebrales

between the superior and inferior articular processes of adjacent vertebrae - **zygapophysial/facet joints**

sliding movements

angulations of the articular facets

determine types of movements

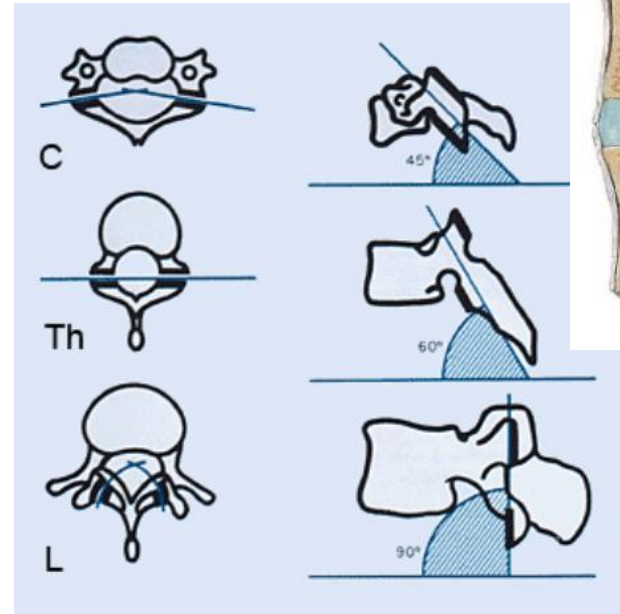
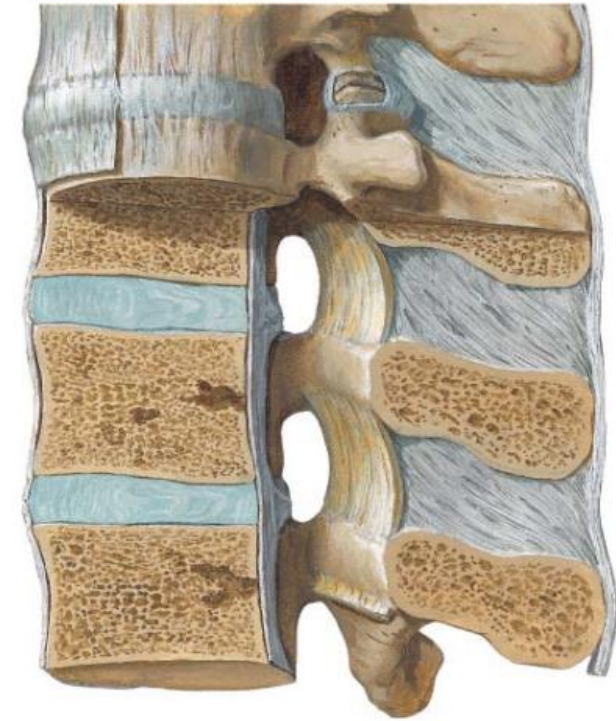
- short ligaments:

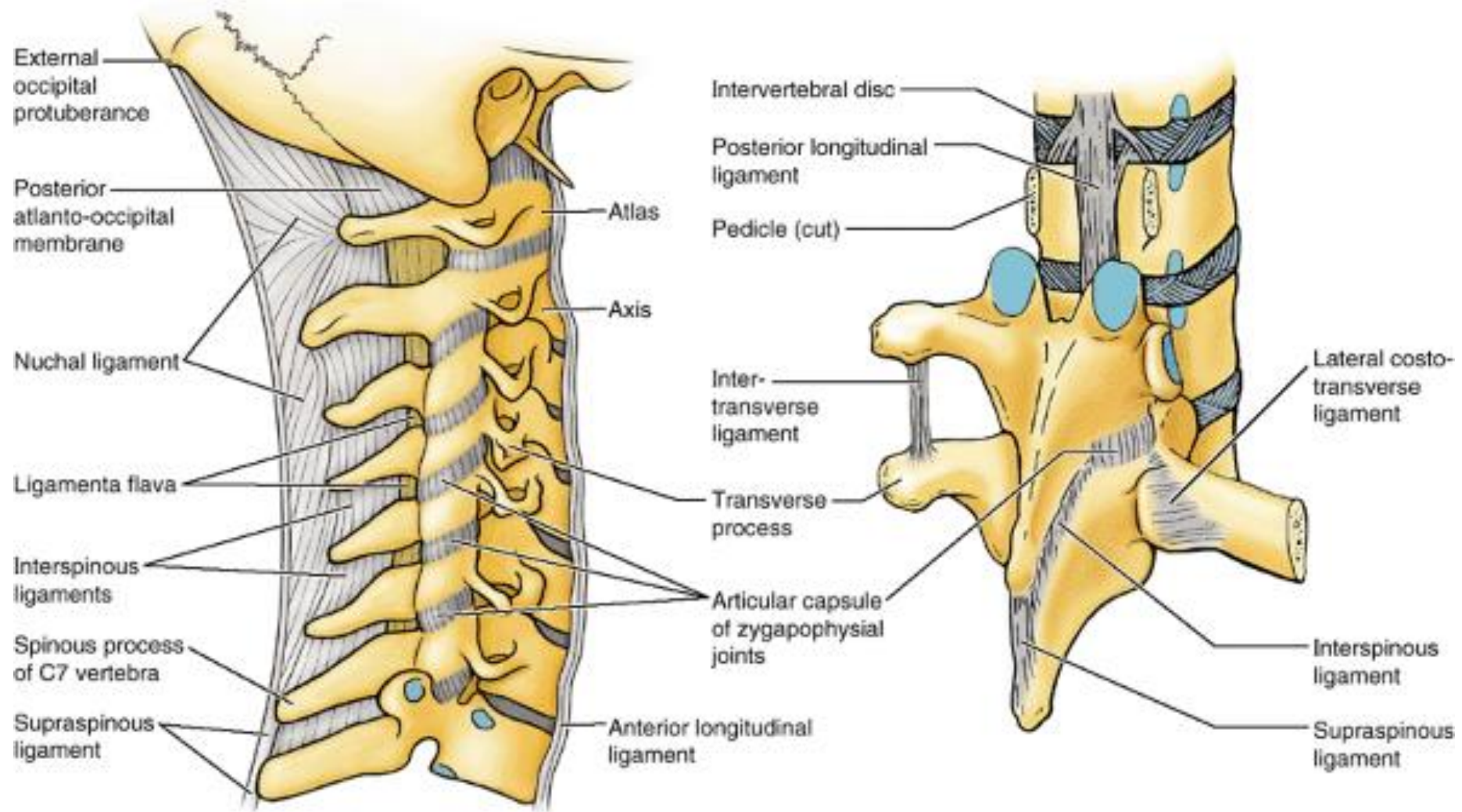
- **ligg. intertransversaria**

- **ligg. interspinalia**

- **lig. supraspinale** (cervical area) – as

sagittally oriented **ligamentum nuchae** which is going to the occipital bone





(A) Right lateral view

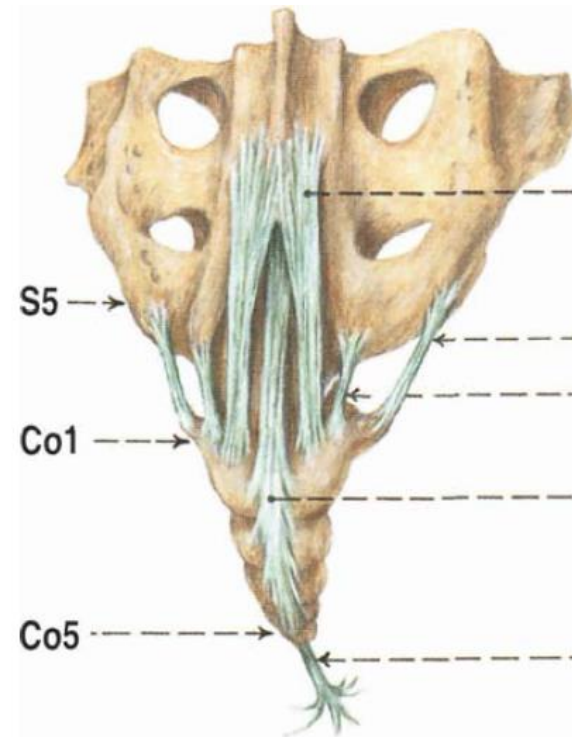
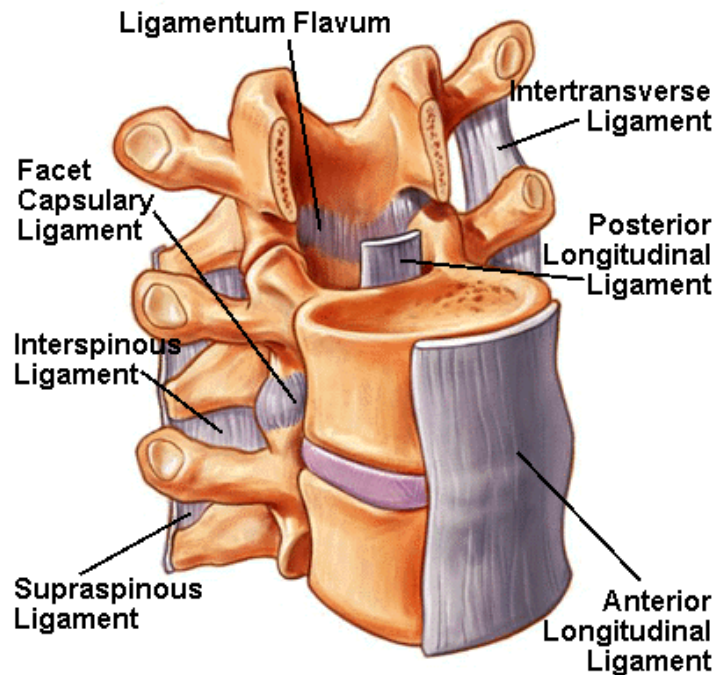
(B) Right posterior oblique view

Junctions common for all vertebrae

a) lig. longitudinale anterius

b) lig. longitudinale posterius

- They continue also to the sacral and coccygeal bone



Synostosis

- Connection using the bone tissue

Sacral bone: fusion of five sacral vertebrae

Coccygeal bone: fusion of 3 - 5 coccygeal vertebrae



Curvature of vertebral column

1. In the sagittal plane

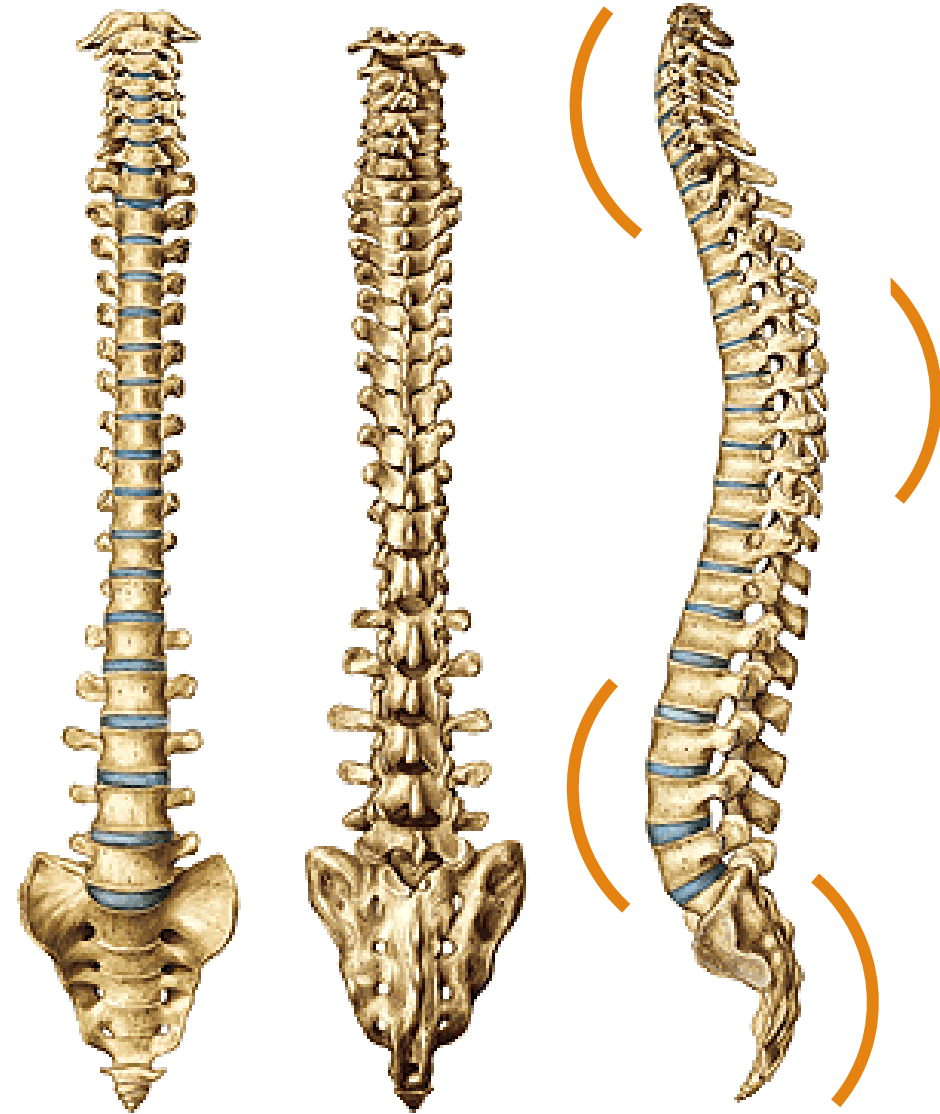- double S-shaped:

lordosis: curvature forwards, cervical C4-5 and lumbar L3-4

kyphosis: curvature backwards, thoracic Th6-7 and sacral

2. Curvature in the frontal plane

- Skoliosis, mild skoliosis is physiological and it is present in all people – in most mild right, in some mild left (if you are right or left-handed)



SHAPE AND MOVEMENTS OF THE SPINE

- 35% of body height

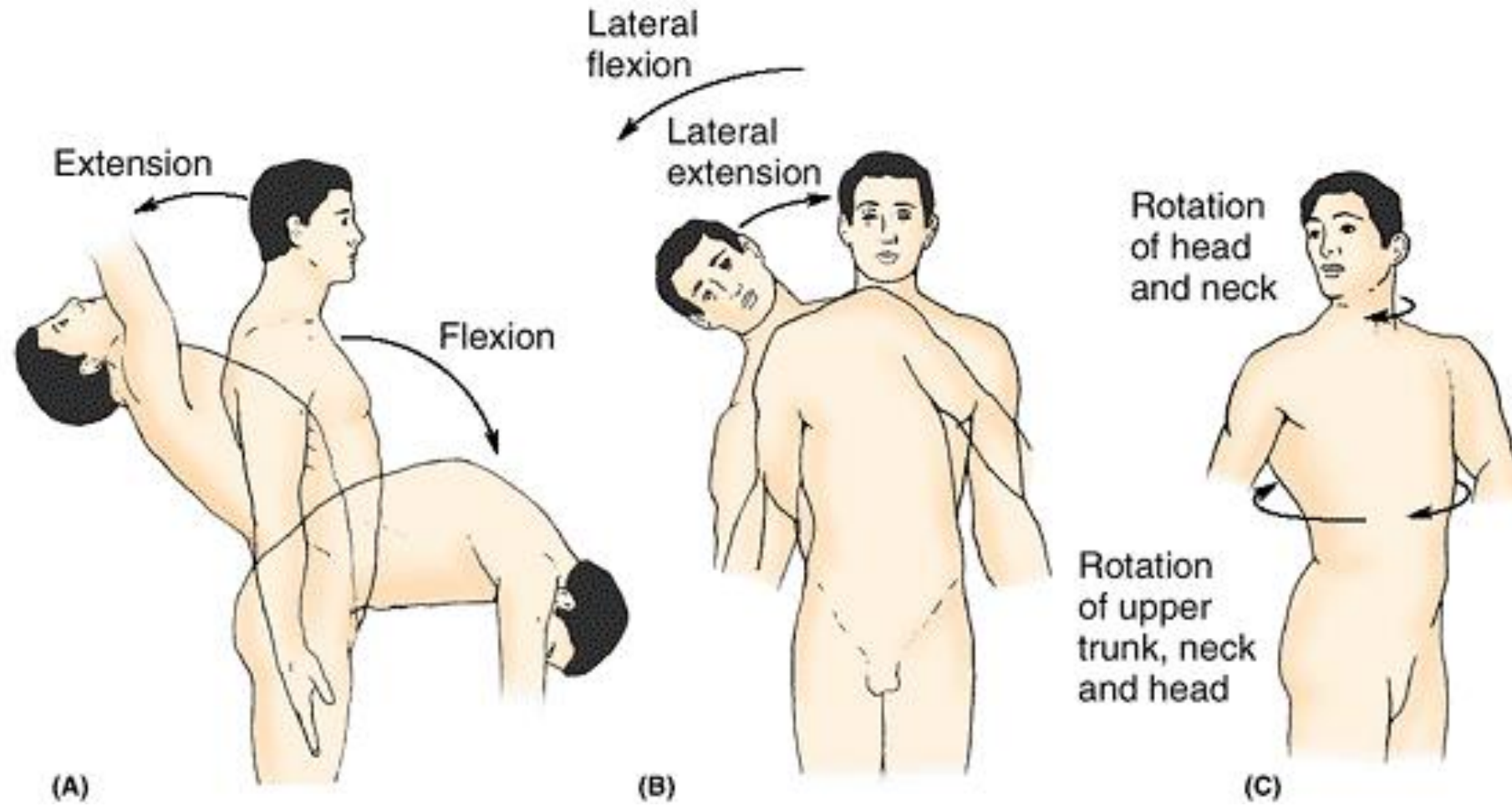
Movements

- **anteflexion, retroflexion**, 90° cervical, 23° lumbar, most stressed and vulnerable is part of the lower cervical vertebrae, Th11-12, L4-S1
- **lateroflexion**, 30° cervical, 35° lumbar
- Rotation and torsion, 60-70° cervical, 25-35° thoracic
- Springing movements

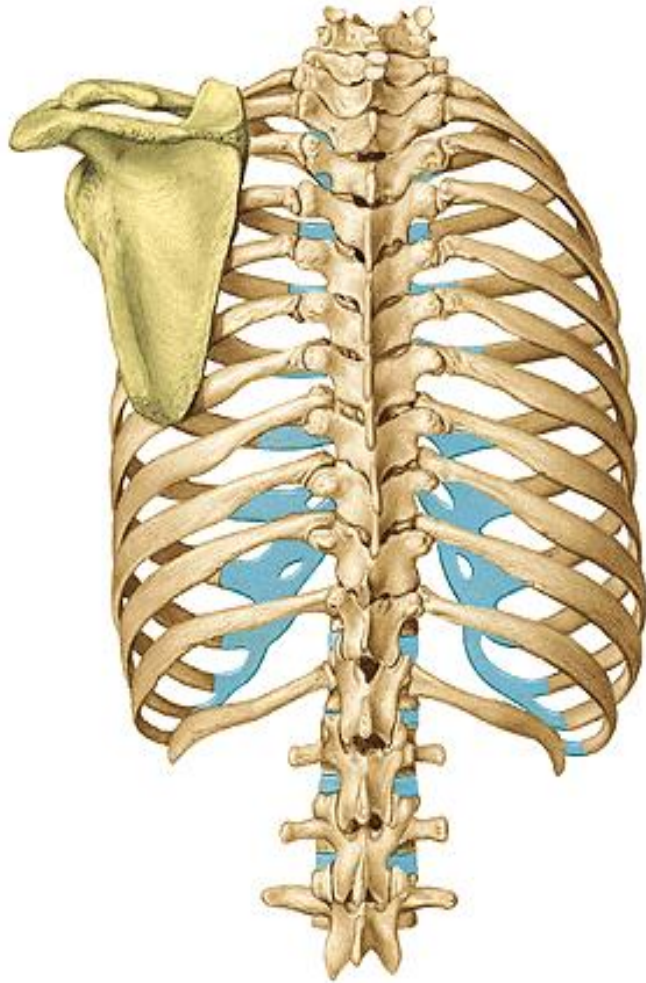
Mobility of the vertebral column

- depends on the size of intervertebral disc
- the mobility is restricted by: ligaments, articular capsules and muscles

- the cervical vertebrae allow a range of **flexion, lateroflexion** and **rotation** coupled with lateroflexion
- the thoracic should be **particularly mobile in rotation** (is limited by the attachment of ribs)
- in the lumbar region - **anteflexion, retroflexion, lateral flexion**



Junctions of the thorax



- **costovertebral joints**

art. capitis costae

art. costotransversarium

- **costochondral joints and interchondral joints**

artt. interchondrales (6th-9th)

membrana intercostalis externa, interna

- **sternocostal joints**

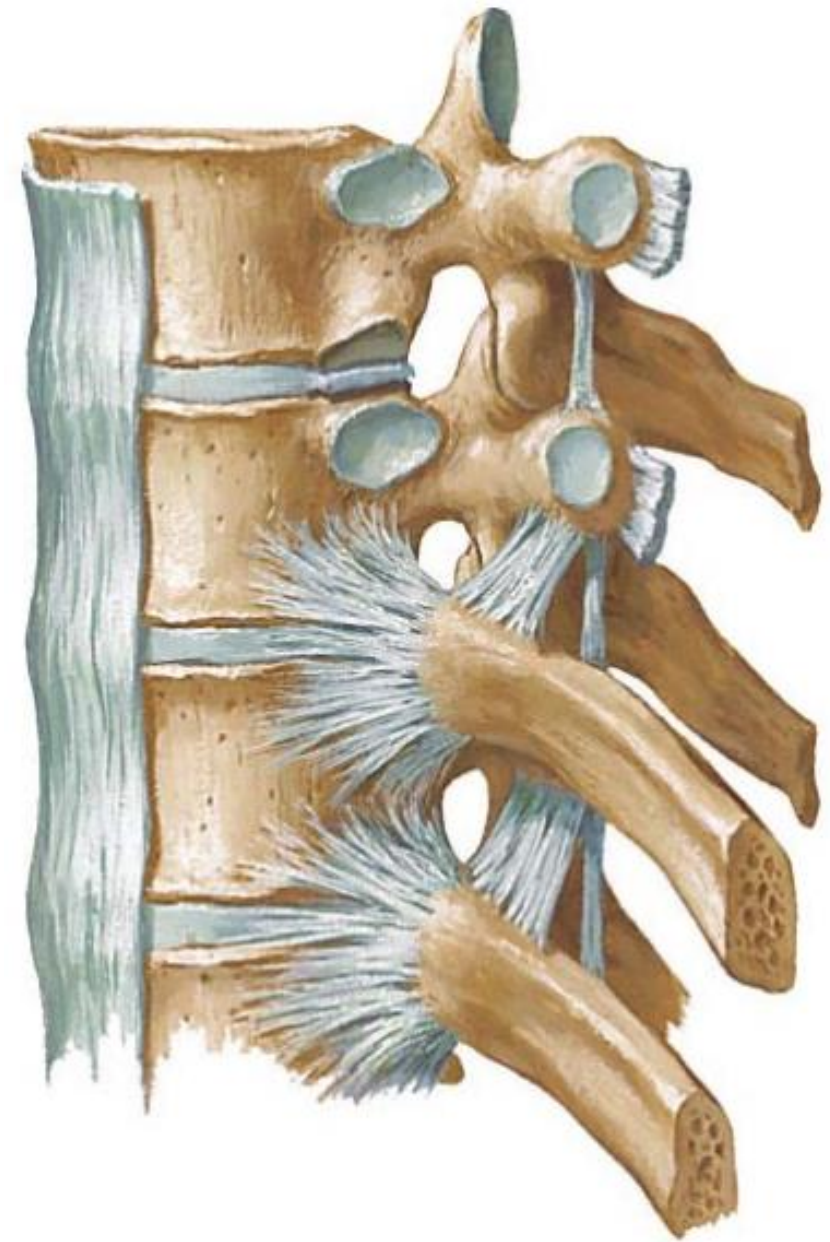artt. sternocostales (2nd-5th)

synchondrosis (1st, 6th, 7th)

Costovertebral Joints

Articulationes capitis costae

- **AF:** head of the rib articulates with the inferior and superior costal facets of two adjacent thoracic vertebral bodies and the intervening intervertebral disc
- **AC:** firm and it is attached to the margins of AF
- **special apparatus:** lig. capitis costae radiatum, at 2nd – 10th rib: capitis costae intraarticulare
- **movements:** along axis parallel with the neck of the rib
- allow elevation and depression of the ribs



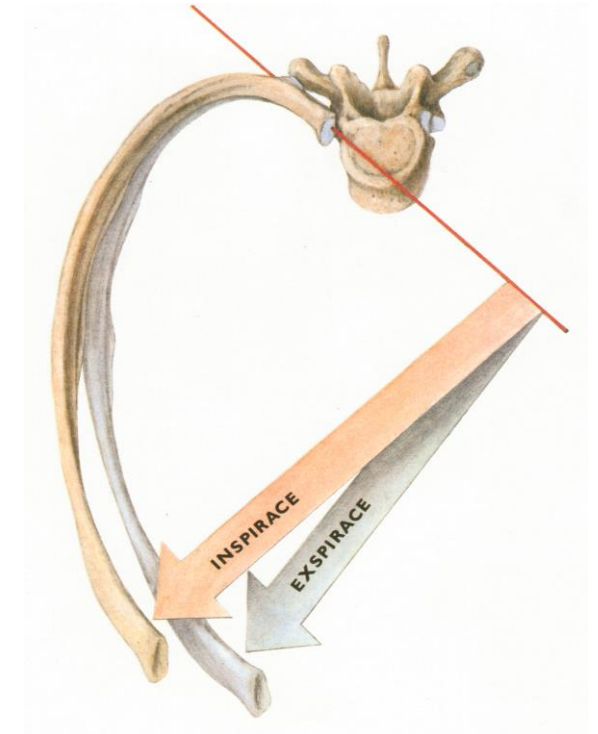
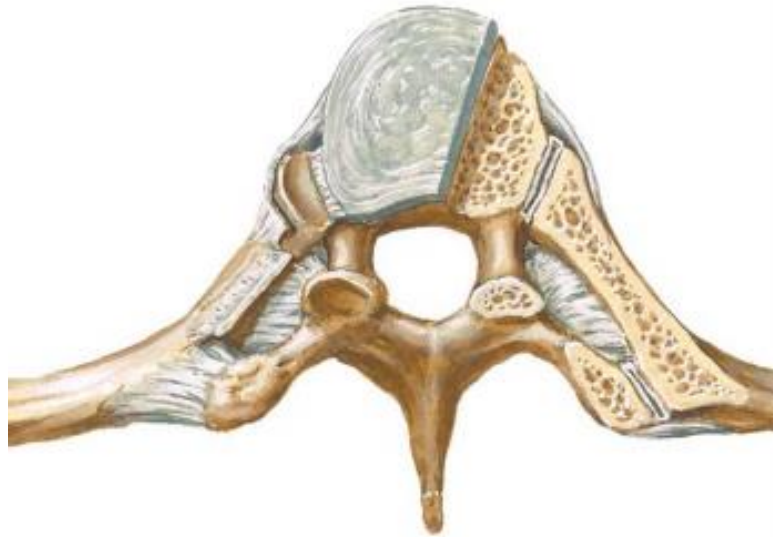Articulationes costotransversariae

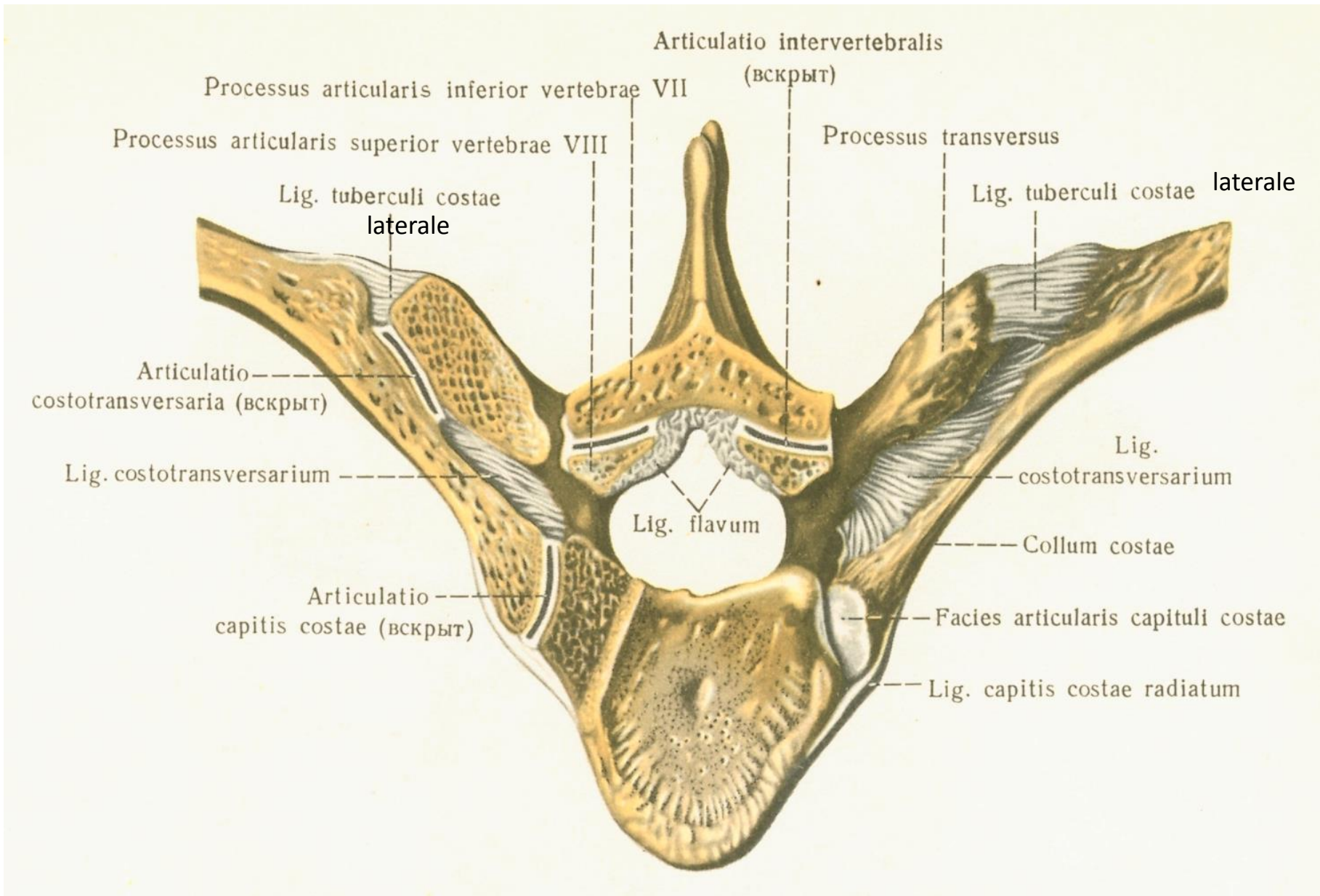
AS: foveae costales transversales and art. surface on tuberculum costae

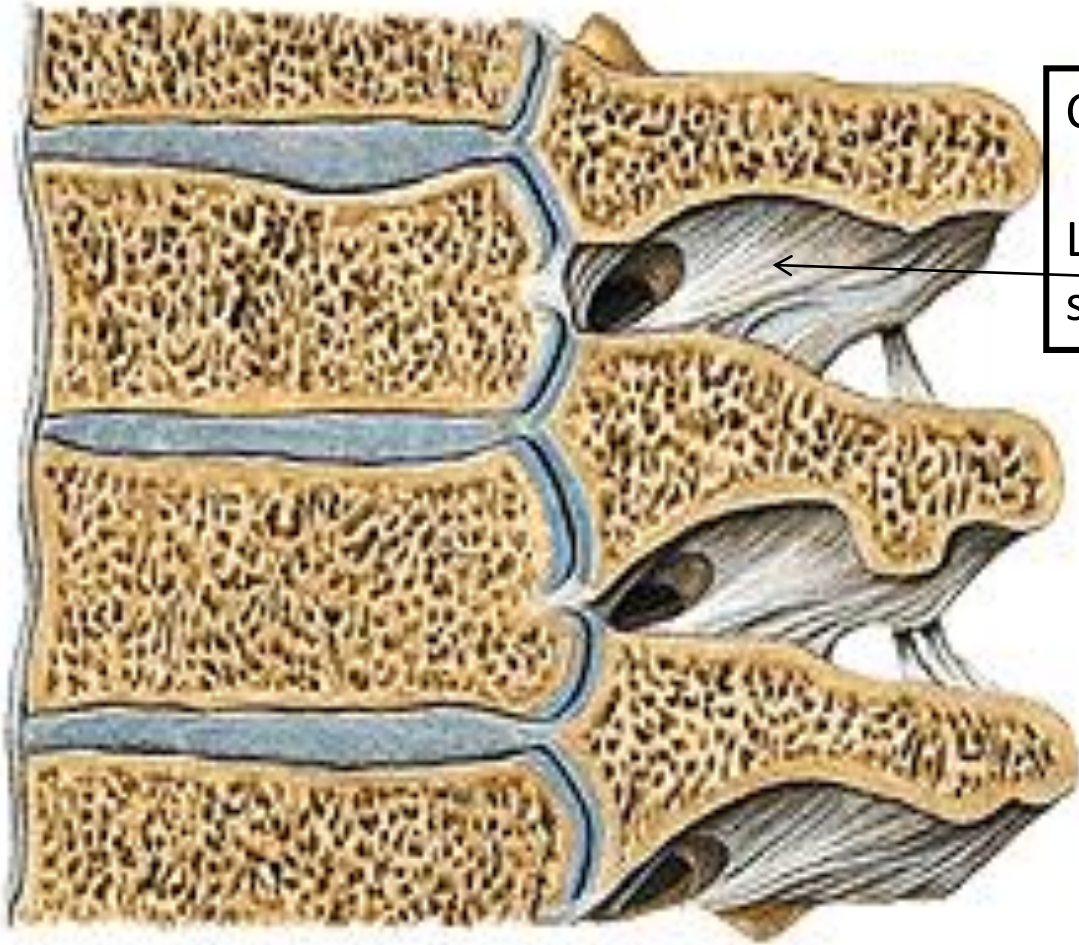
AC: margins of the articular surfaces

special apparatus: lig. costotransversaria, between collum costae and transversal process of the vertebra

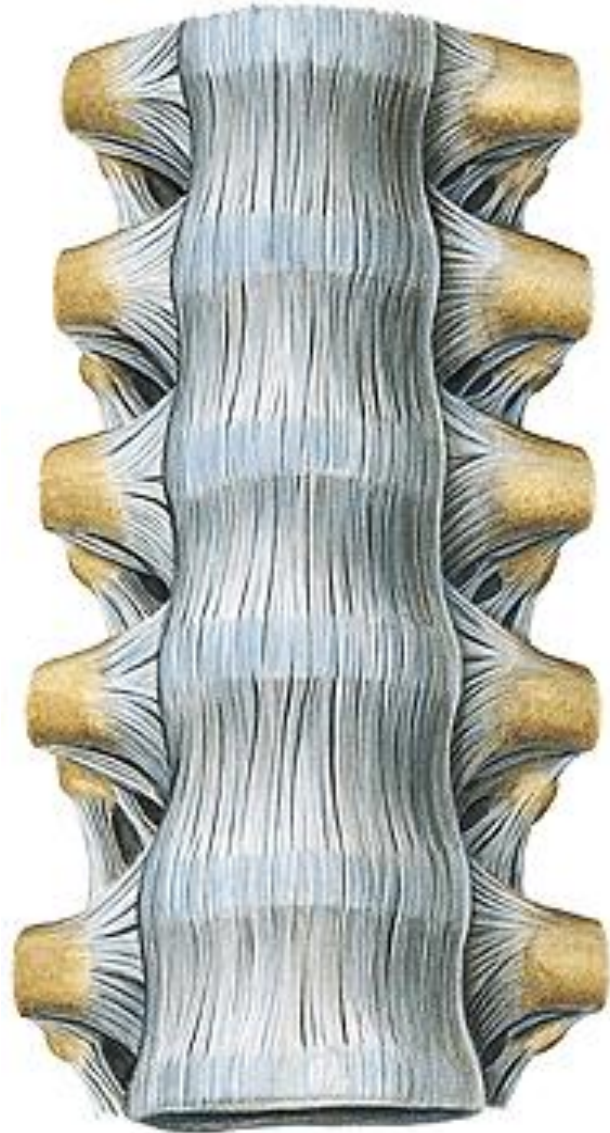
Movements: along axis which is parallel with collum costae







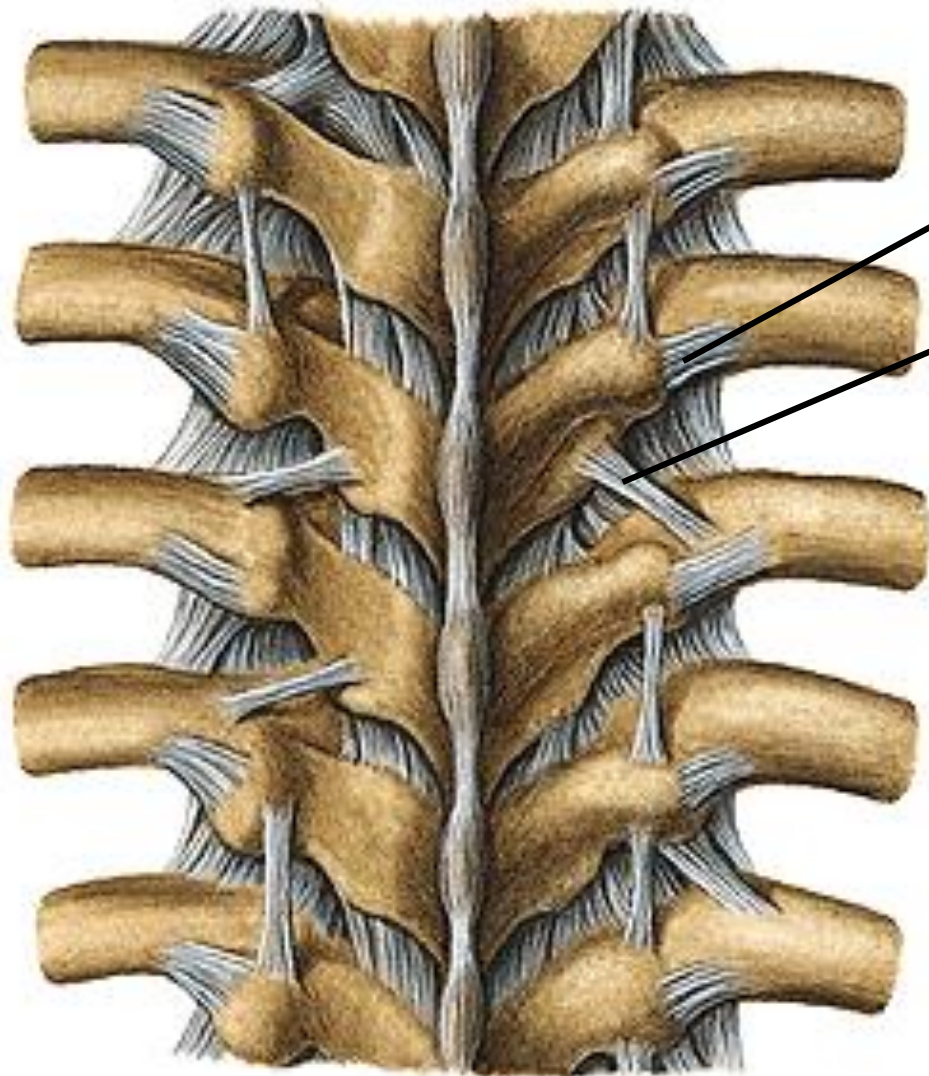
Caput costae + lig.radiatum
Lig.costotransversarium
superius



Lig. capitis costae radiatum

Lig. costotransv. sup.

Lig. longitudin. ant.



Lig.costotransv.lat.
superius

Lig. intertransversaria
interspinale (nuchae)

Juncturae sternocostales

- Connections between costal cartilages and sternum

1. Synchondrosis sternocostalis: cartilaginous connection with incisura costalis sterni, regularly at 1st often at 6th and 7th rib

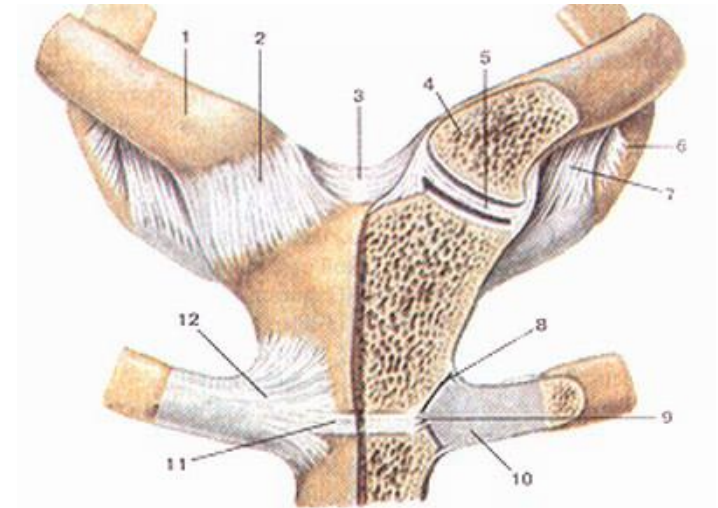
2. Artt. sternocostales:

between 2nd to 5th rib and sternum

AS: sternal end of costal cartilage, incisura costalis sterni

AC: to the margins of the articular surfaces

Special apparatus: ligg. sternocostalia radiata – they form membrana sterni externa and interna



Junctions of adjacent ribs

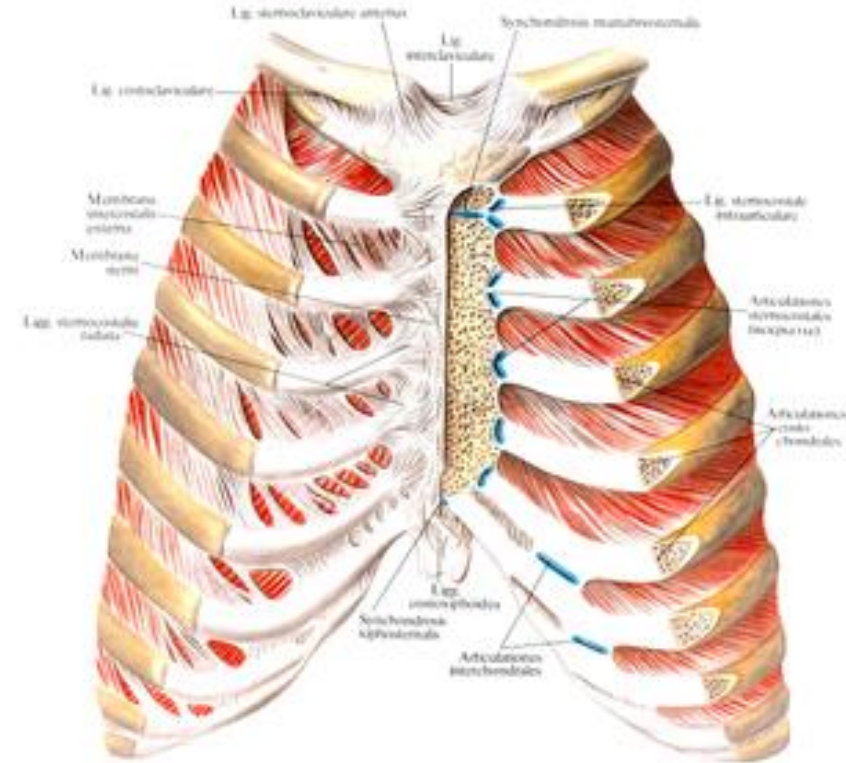
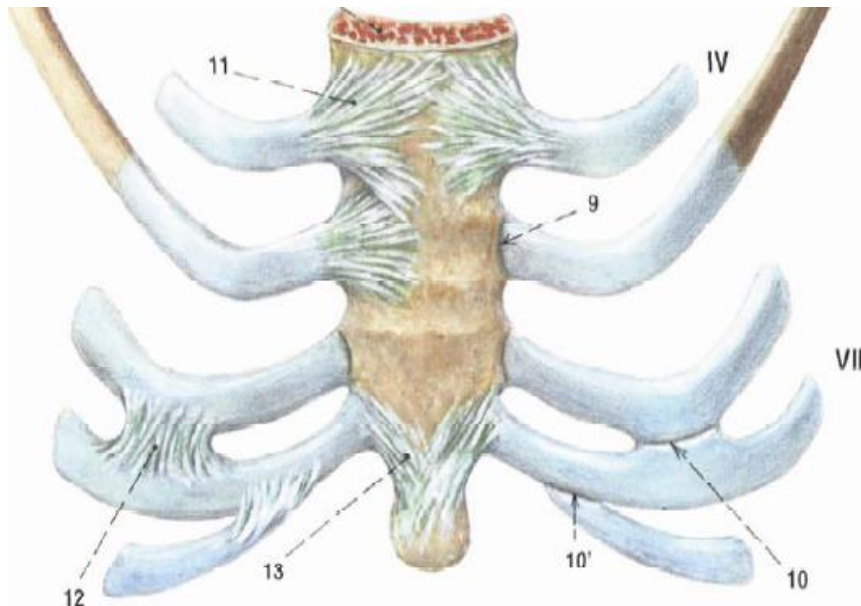
1. Articulationes interchondrales

joint connection between costal cartilages of 5th to 9th rib, covered by short articular capsule

2. Membranae intercostales – fibrous membranes connecting adjacent ribs

Membrana intercostalis externa

Membrana intercostalis interna

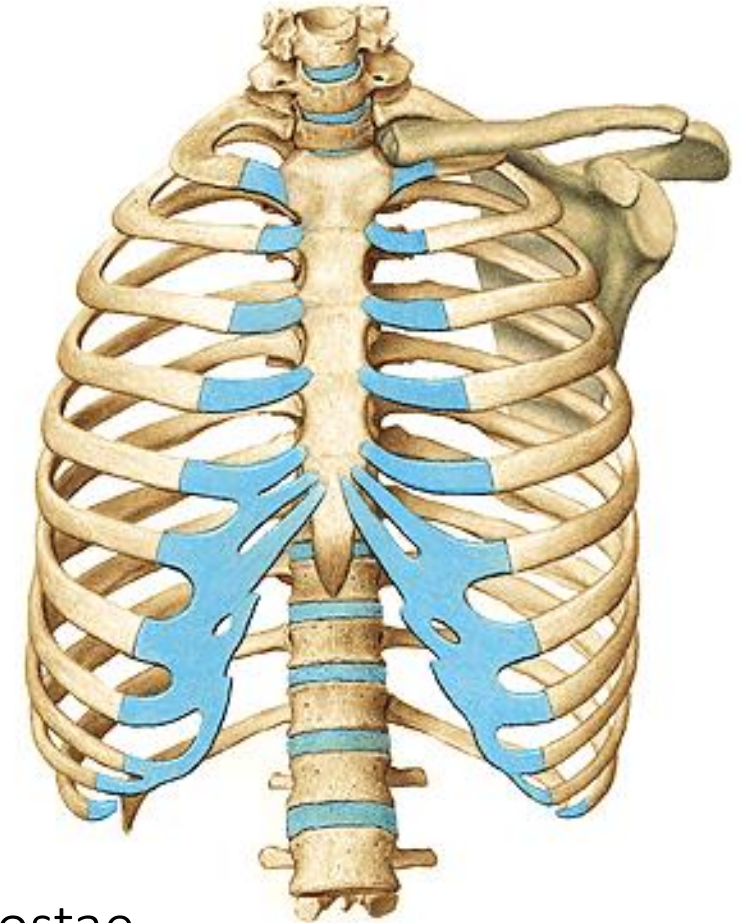


Chest cage shape and movements

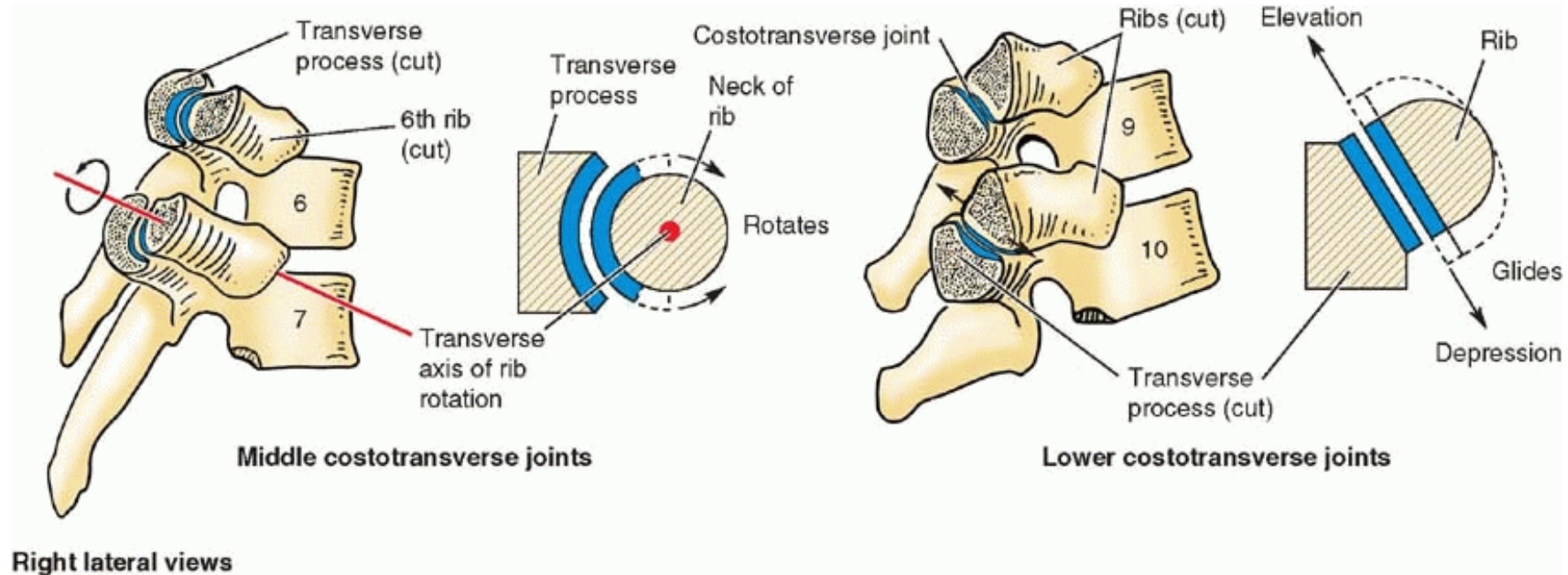
- Shape of truncated cone
 - base (apertura thoracis inferior)
 - apex (apertura thoracis superior)
 - walls – frontal, dorsal, lateral
- cavitas thoracis
spatia intercostalia
arcus costarum
angulus infrasternalis

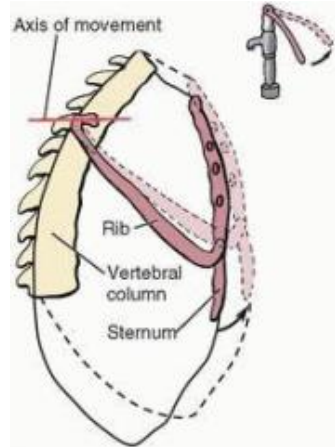
Movements

- in costovertebral connections, axis runs parallel with collum costae
- Upward rotation - inspirium
downward rotation- exspirium

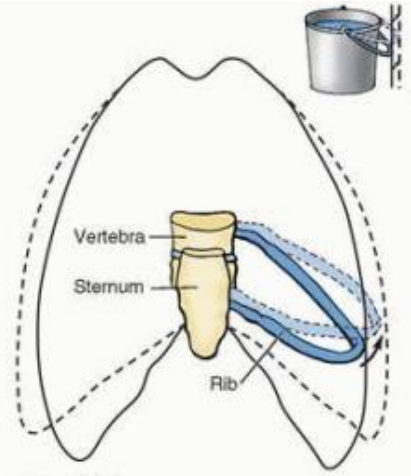


Movements of the thoracic wall during inspiration produce increases in the intrathoracic volume and diameters of the thorax

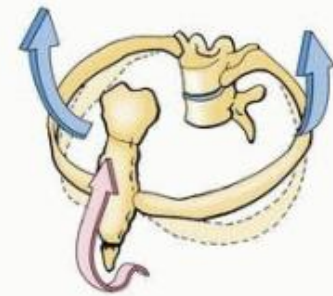




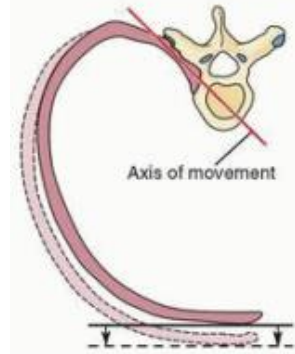
Right lateral view



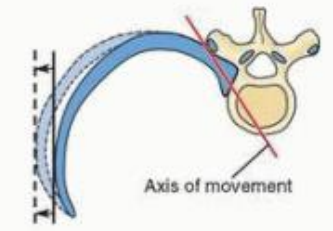
Anterior view



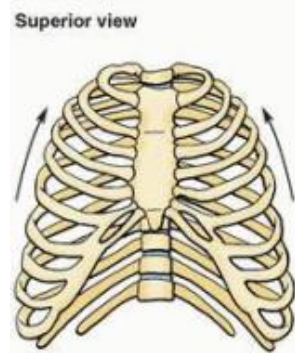
(C) Left anterior oblique view



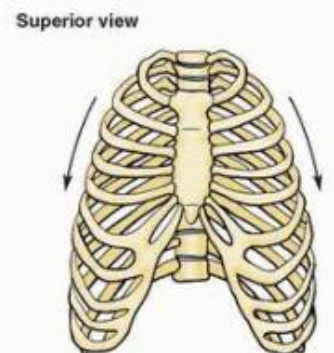
(A) Upper ribs



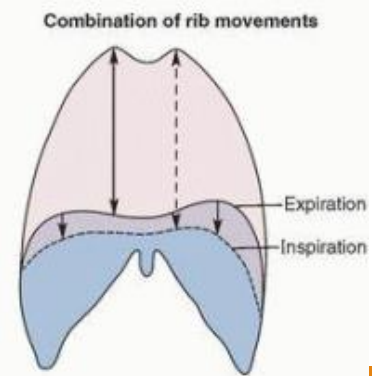
(B) Lower ribs



(D) Forced inspiration



(E) Forced expiration



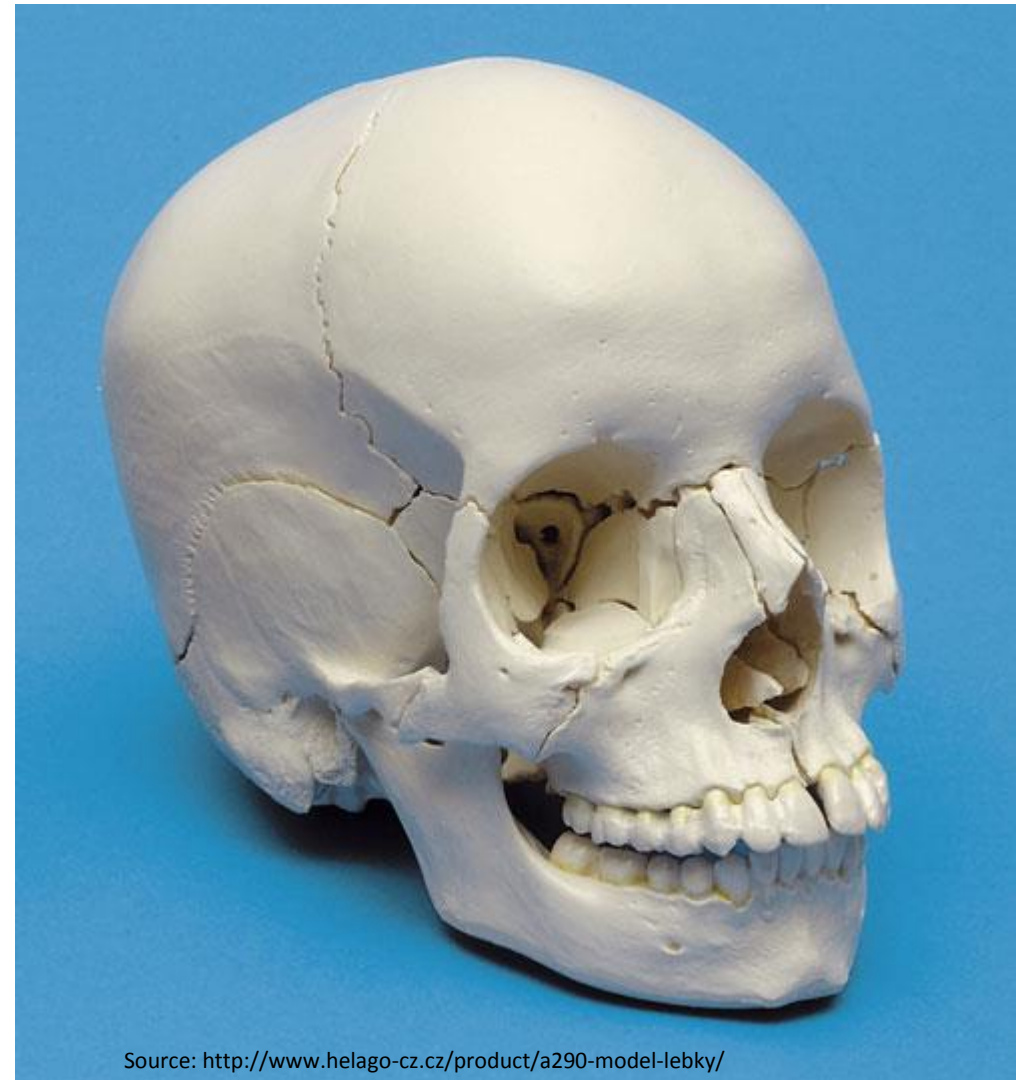
(F)

Combination of rib movements

Connections of the skull (juncturae cranii)



- craniovertebral junctions
- syndesmoses
- synchondroses
- temporomandibular joint
- hyoid junctions



Source: <http://www.helago-cz.cz/product/a290-model-lebky/>

Craniovertebral junctiones

➤ Connection of the skull with the C1 and C2

1. *Articulatio atlantooccipitalis*

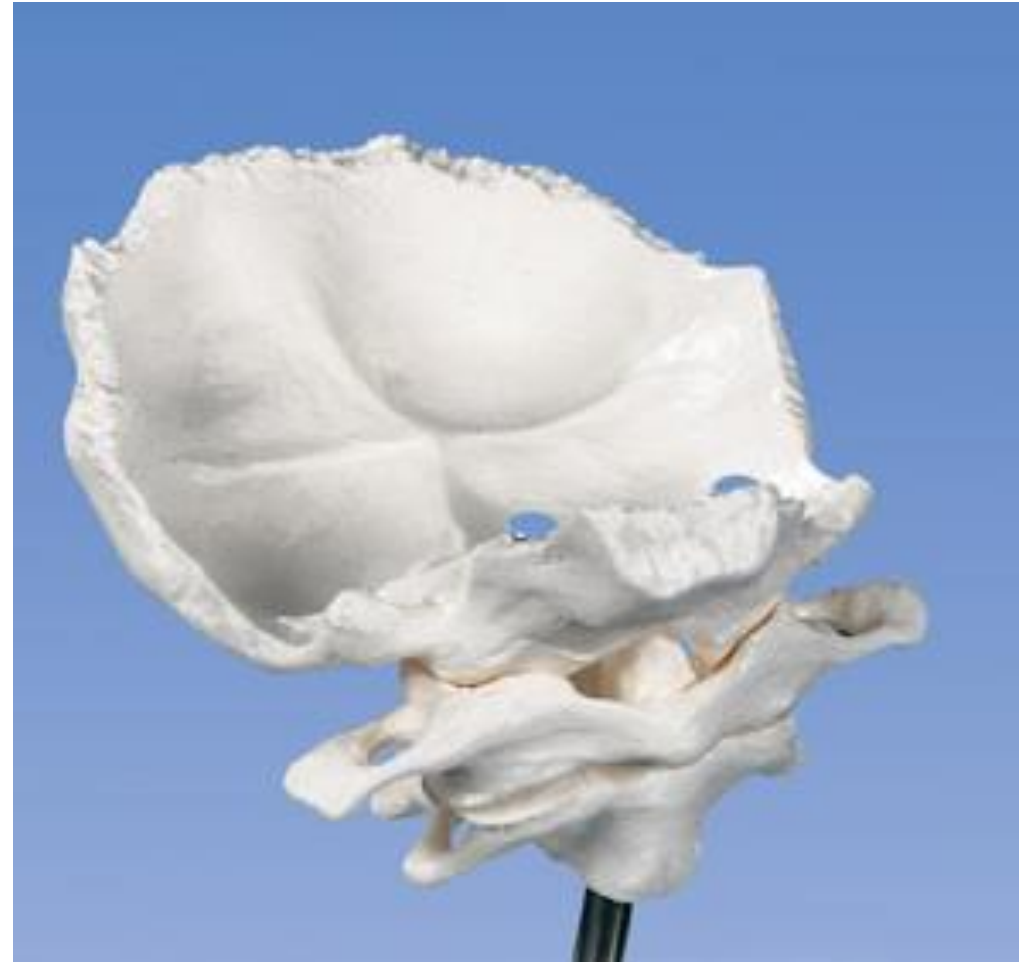Paired joint

AS:

condyli occipitales and
foveae articulares superiores
of atlas

AS:

Is attached to the margins of
the articular surfaces



Special apparatus:

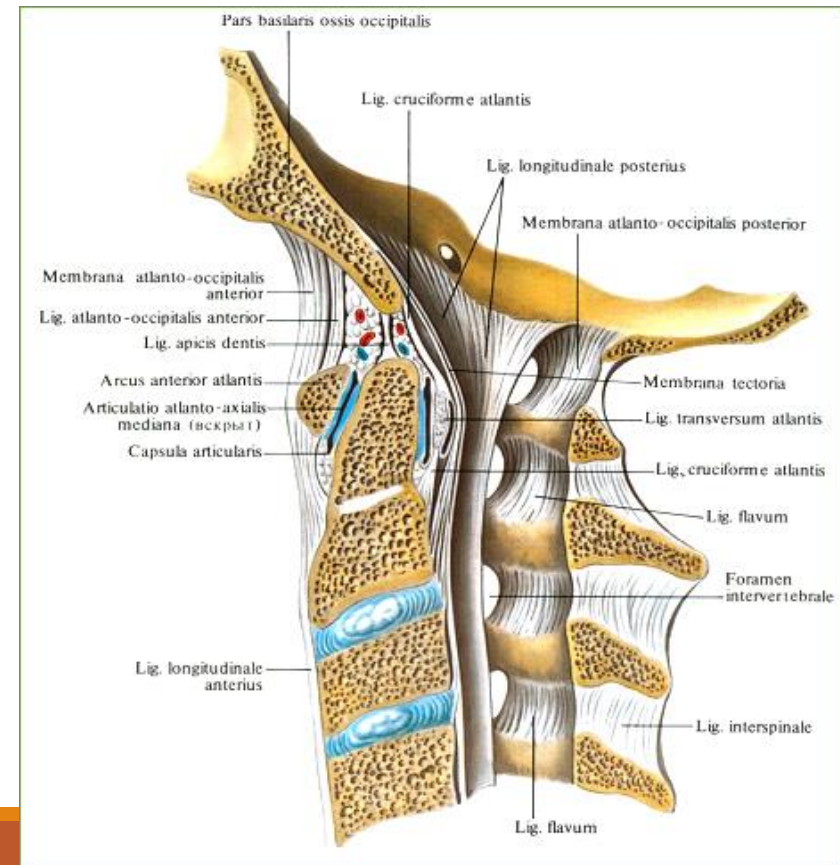
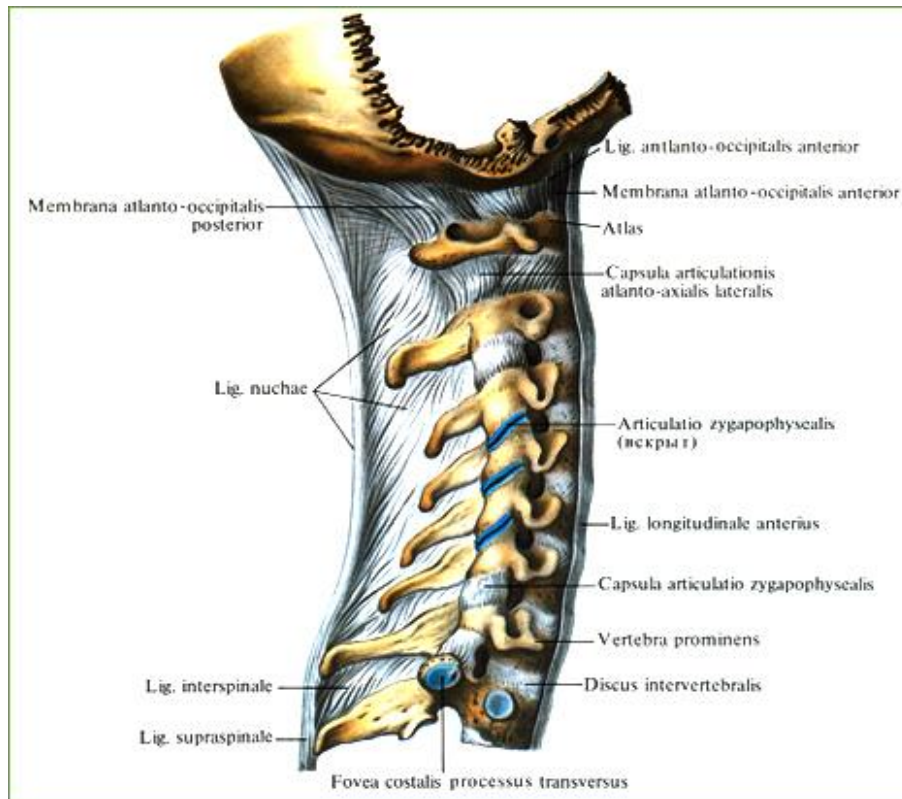
membrana atlantooccipitalis anterior and posterior

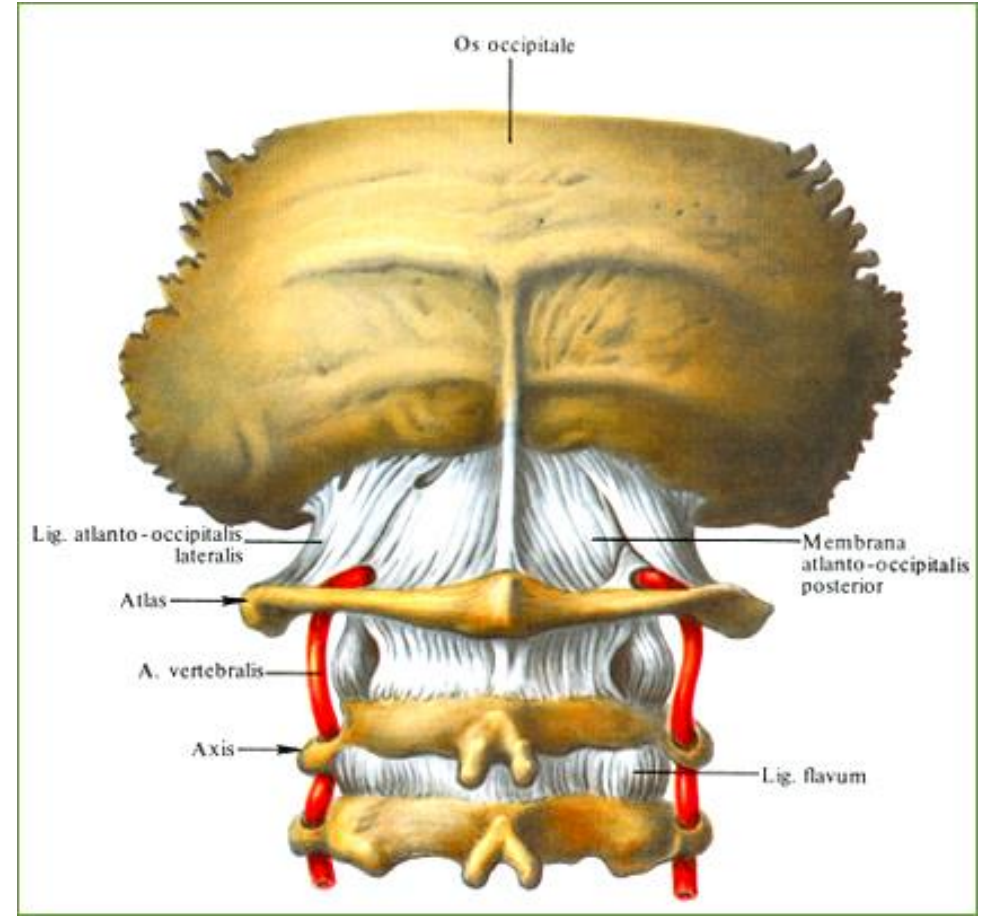
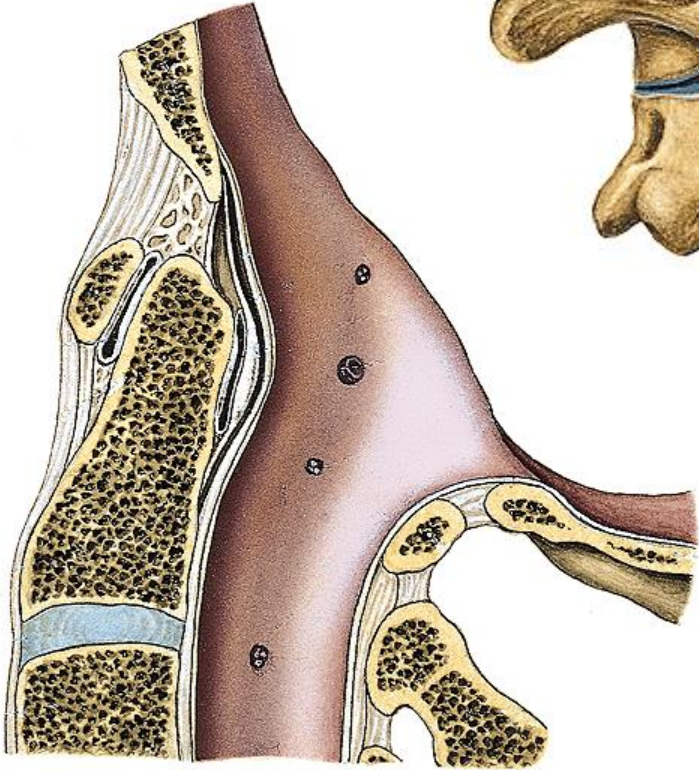
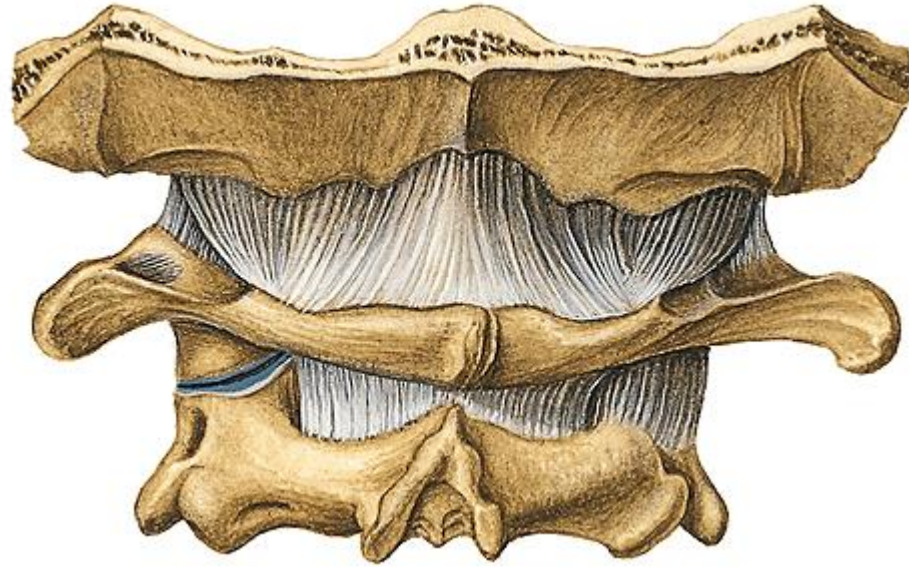
(between arches of atlas and occipital bone)

membrana tectoria

(cranial continuation of *lig. longitudinale posterius*, it reaches to *clivus*)

Type of joint: **elipsoidal** with possibility of flexion and extension of the head and there are also possible smaller movements sideways





2. Articulatio atlantoaxialis

a) articulatio atlantoaxialis lateralis

- Paired joint

AS:

facies articulares inferiores of atlas

facies articulares superiores of axis

b) articulatio atlantoaxialis mediana

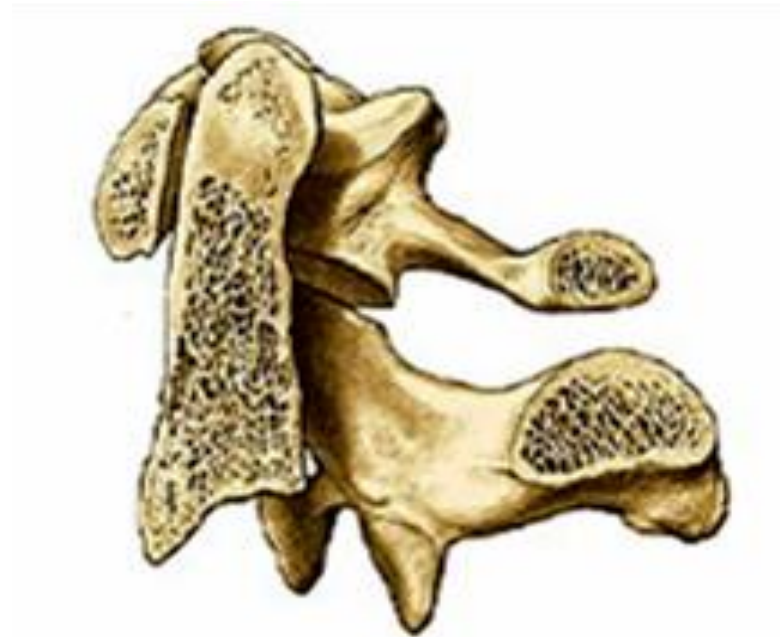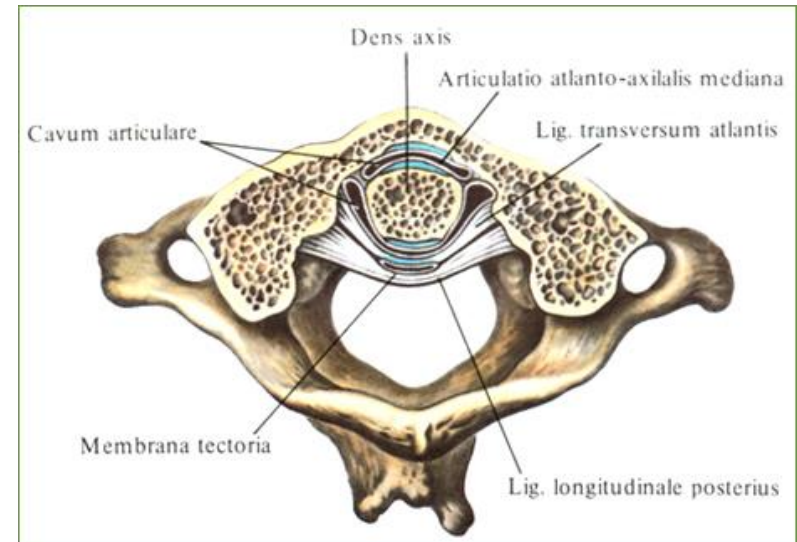
- Unpaired joint

AS:

facies articularis anterior on frontal side of *dens axis* with *fovea dentis* of atlas and

facies articularis posterior on dorsal side of *dens axis* with *lig. transversum atlantis*

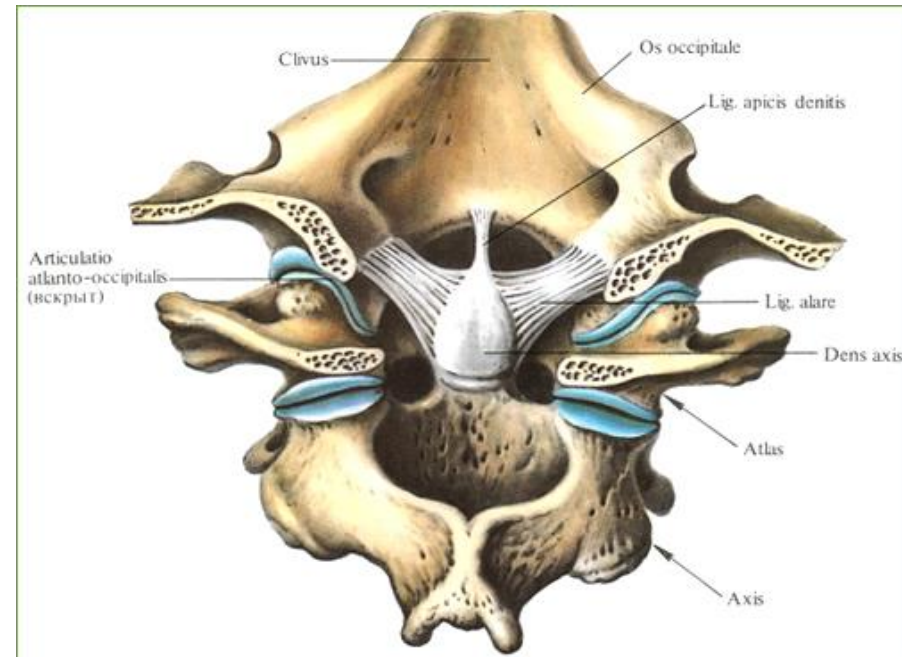
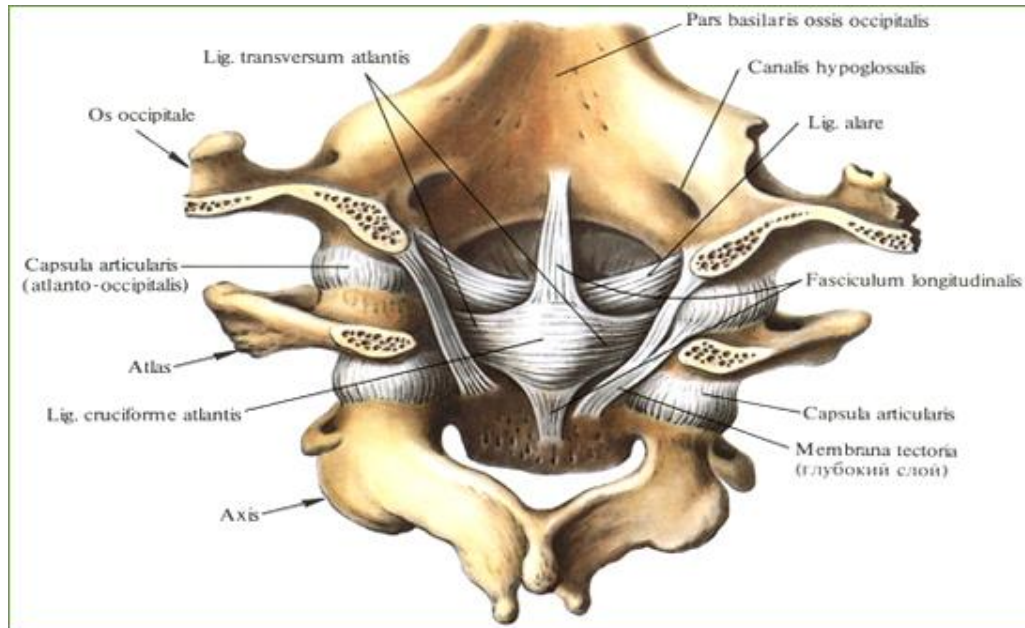
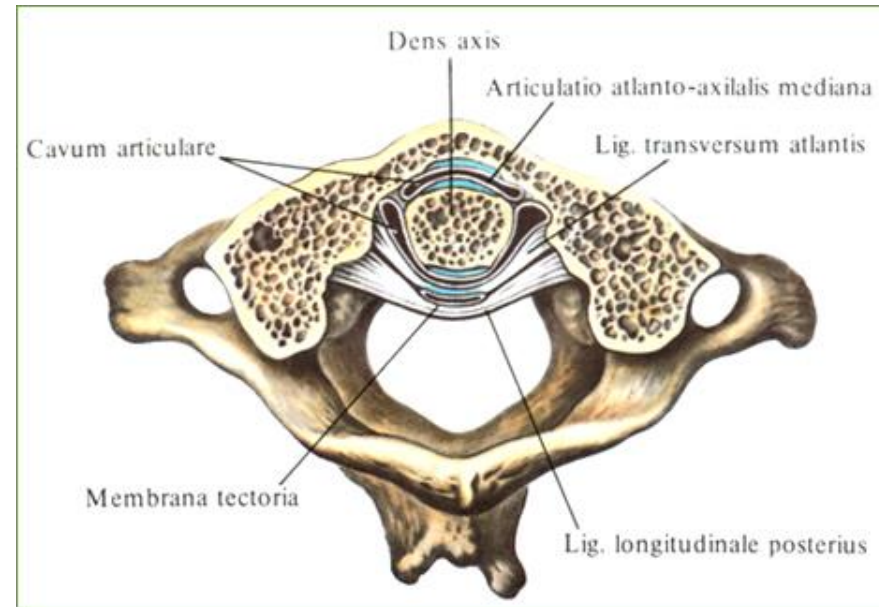
AC: is common and is attached to the margins of the articular surfaces

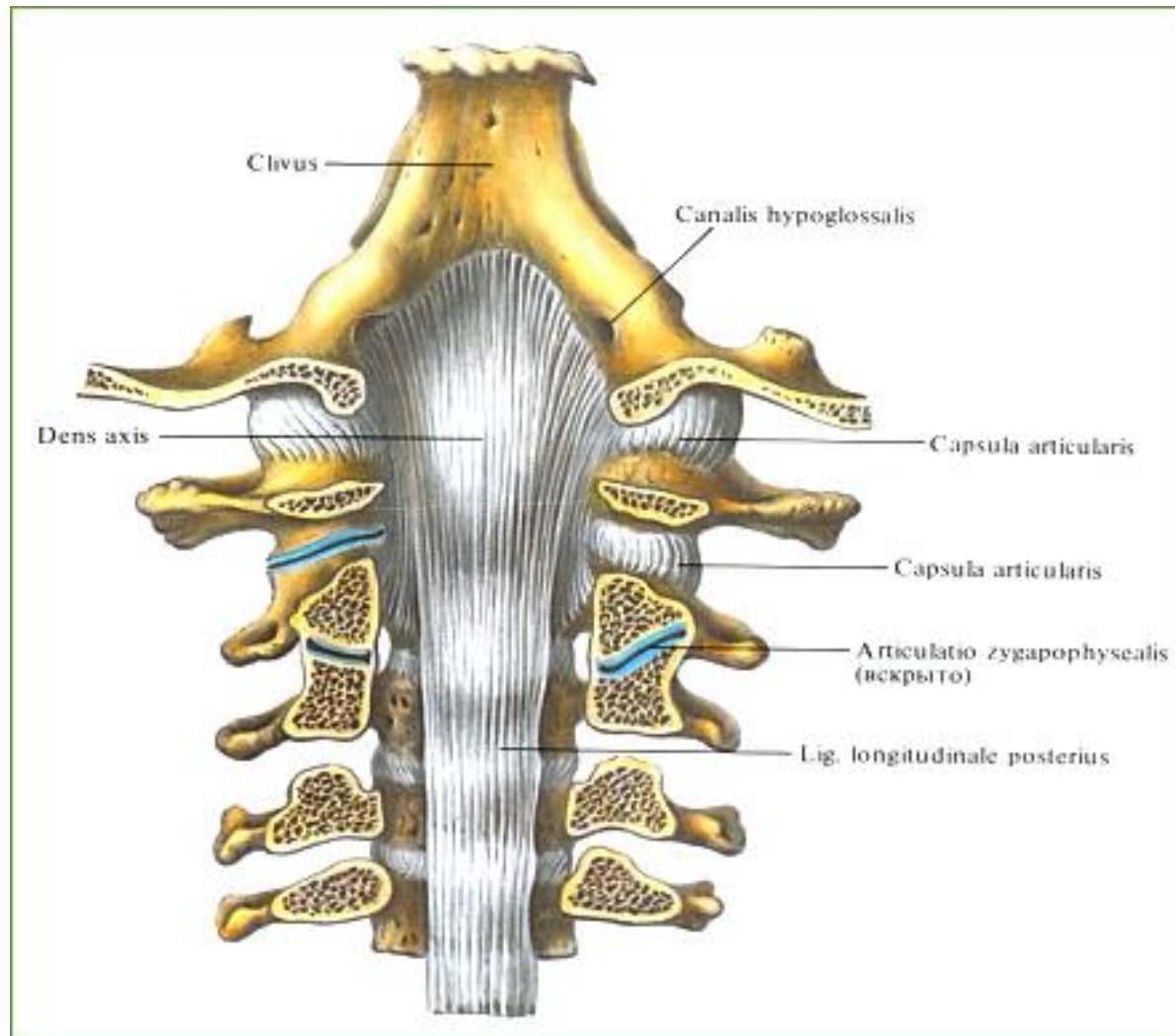


Special apparatus:

lig. apicis dentis, *ligg. alaria*,
lig. cruciforme atlantis, formed by
lig. transversum atlantis and *fasciculi*
longitudinales (vertical fibrous bands going
from axis to occipital bone)

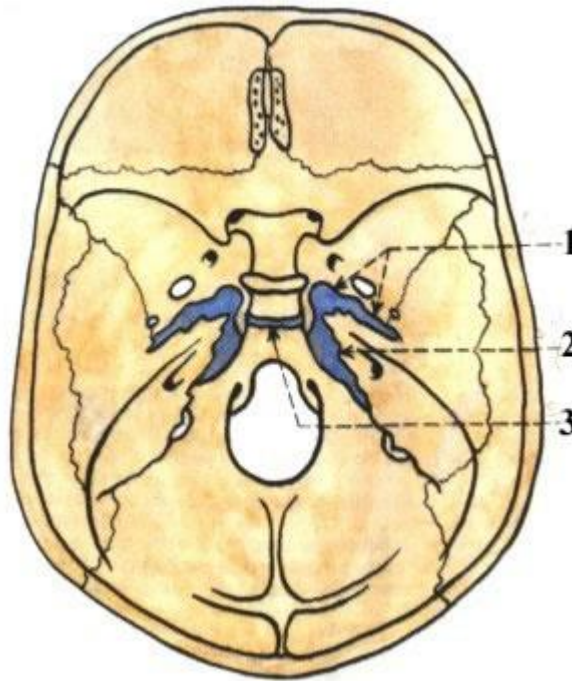
Type of joint: both joints form one
mechanical unit, atlas is rotating along *dens*
axis in range of 60°





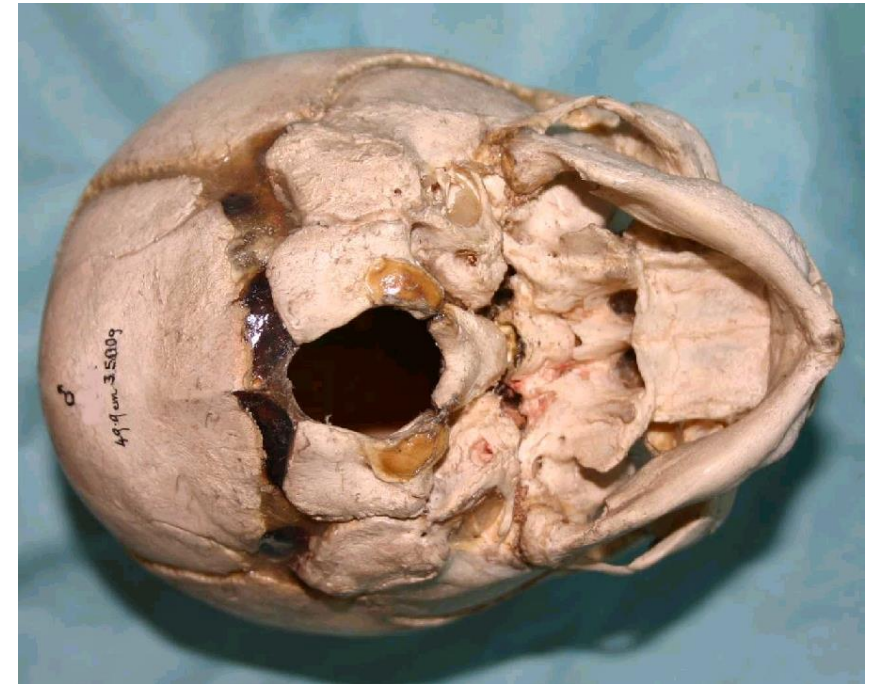
Skull syndesmoses

Present sutures (suturae), between the margins of the bones, there is a layer of fibrous tissue



Skull synchondroses

- s. sphenopetrosa
- s. petrooccipitalis
- s. Interoccipitalis - anterior et posterior
- s. intersphenoidalis,
- s. sphenoccipitalis
- synchondrosis sphenoccipitalis



Temporomandibular joint (articulatio temporomandibularis)

AS: *caput mandibulae* connects with *fossa mandibularis* and *tuberculum articulare* of temporal bone

AC: is attached to the margins of the articular surfaces, its medial part is very strong, it rows together with *discus articularis*

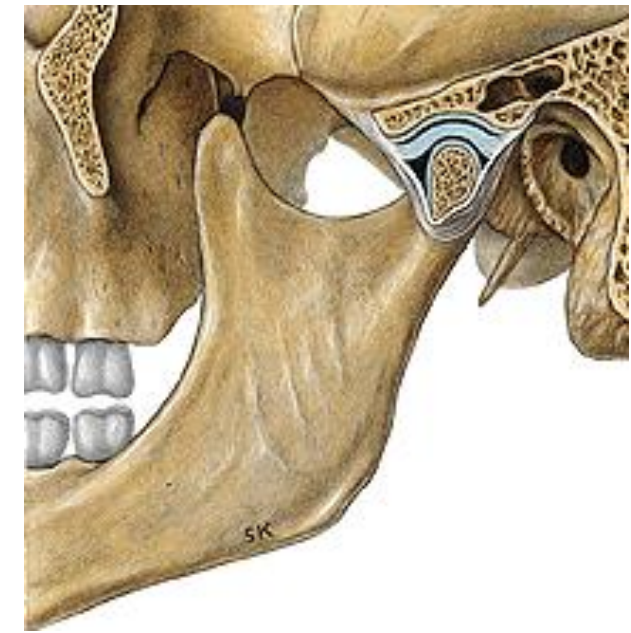
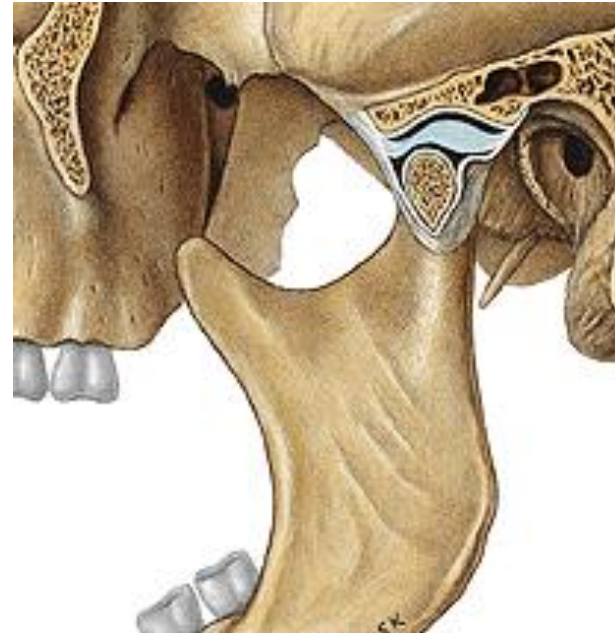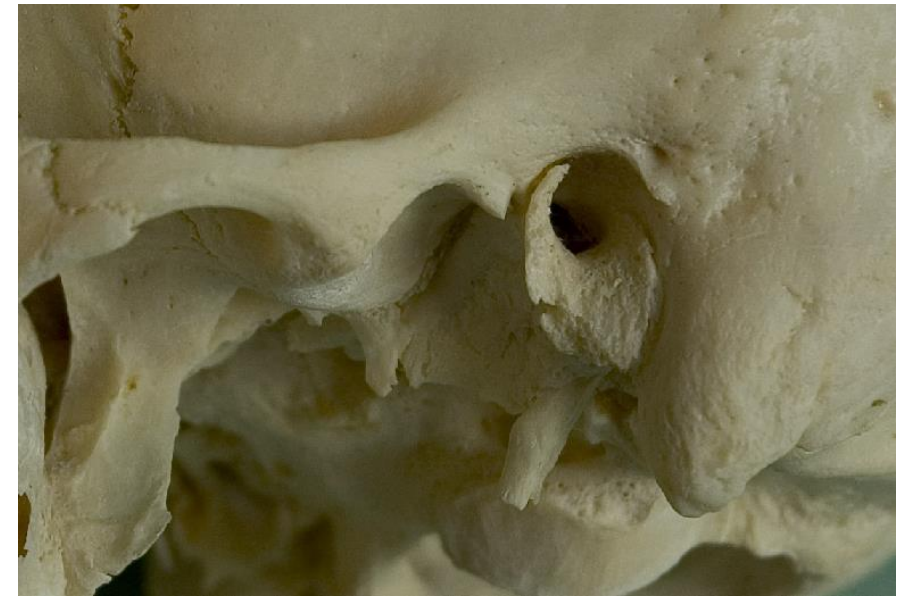Type of joint: **gynghimus (hinge)**

Elevation – closing of the mouth

Depression – opening of the mouth

Protraction – shifting of the chin forwards

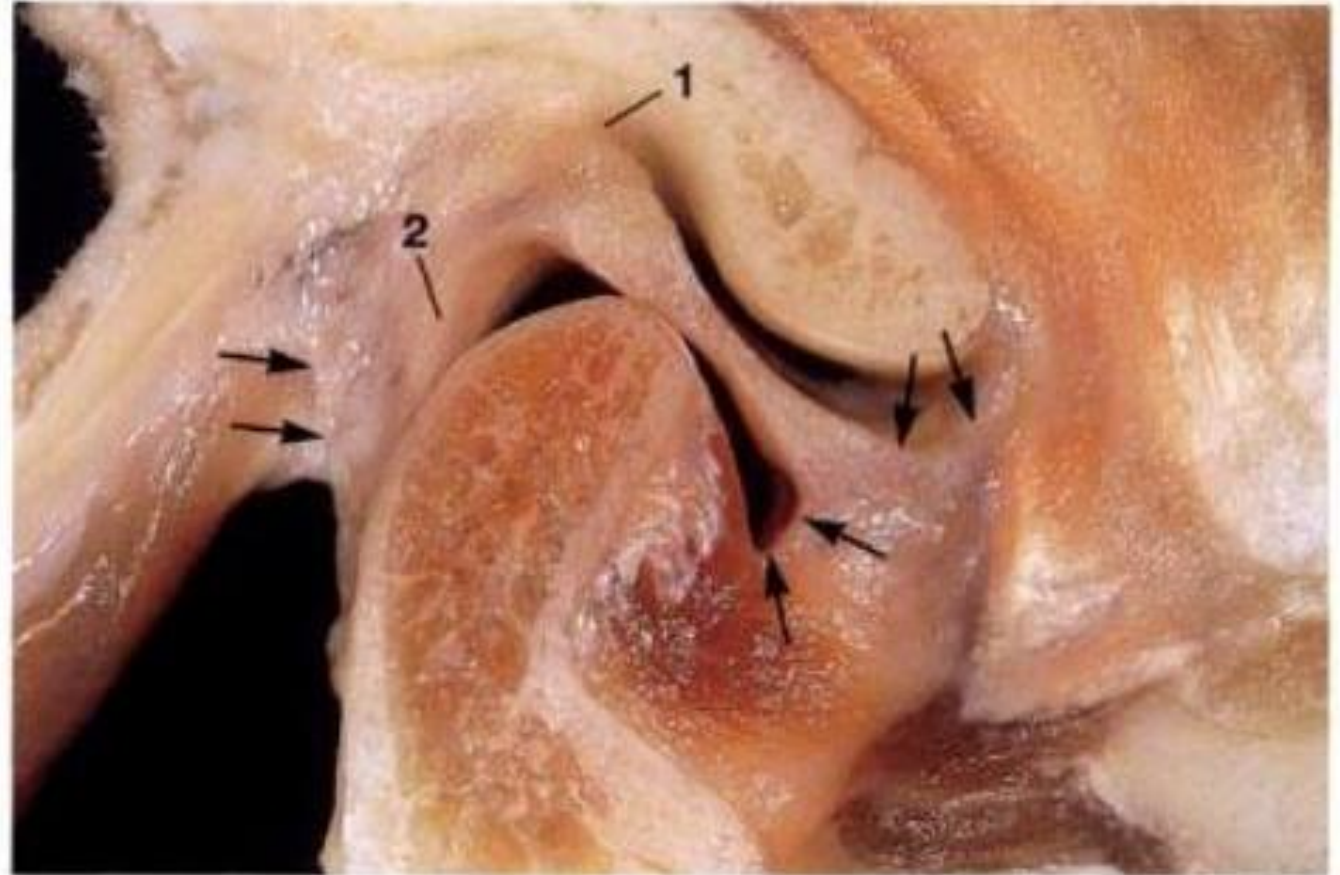
Retraction – shifting of the chin backwards



Special apparatus:

discus articularis (fibrous cartilage):

- its middle part is thinner and the margins are thicker,
- it grows together with articular capsule,
- It reduce sliding friction
- allow the mouth open and close
- it divides articular cavity into:
 - *pars discotemporalis* –
between the mand.fossa and disc (1,2ml)
 - - *discomandibularis* -
between the disc and condyle (0,9ml)

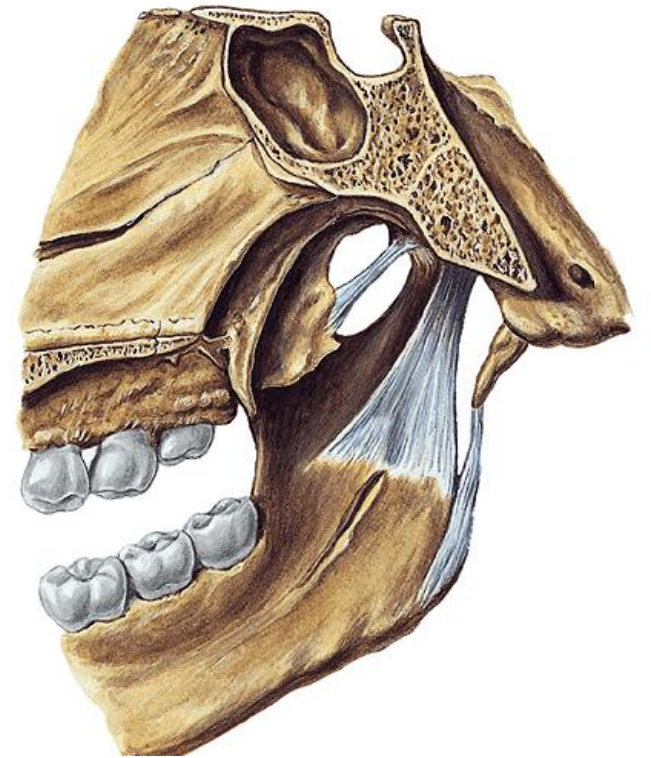
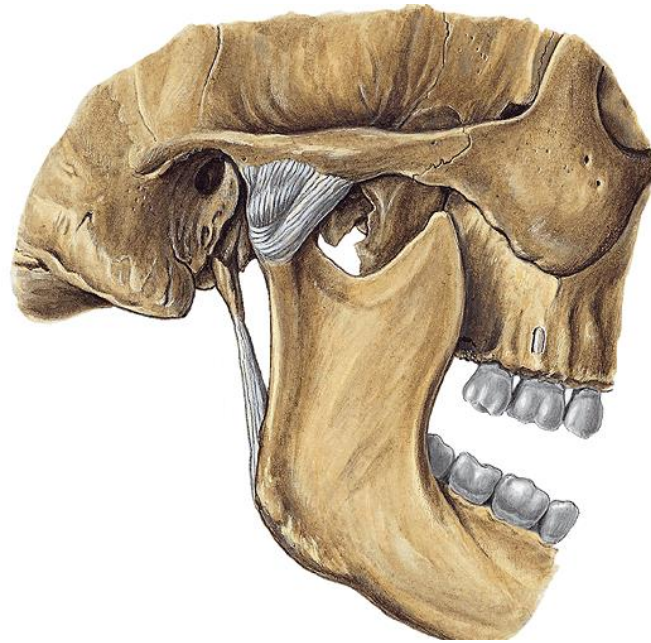
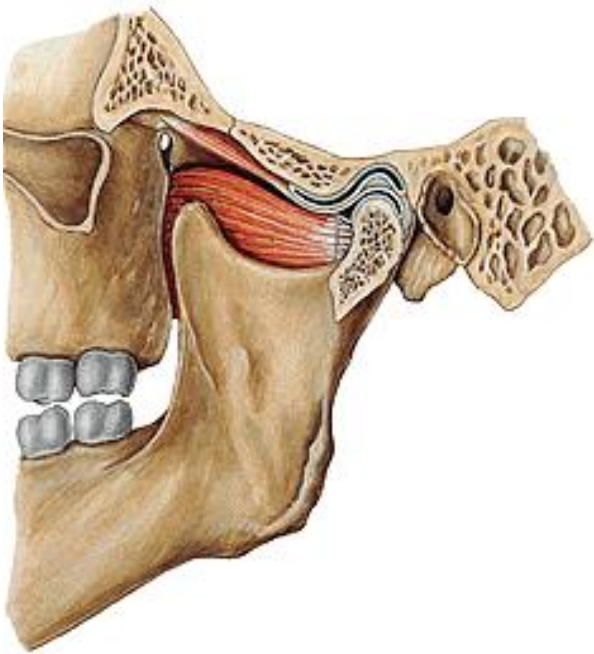


Ligaments - extraarticular

on lateral side: *lig. laterale*

around the joint: *lig. sphenomandibulare* (runs from the spina ossis sphenoidalis to the mandible)

lig. stylomandibulare (runs from the styloid process → the posterior edge of the angle of the mandible)



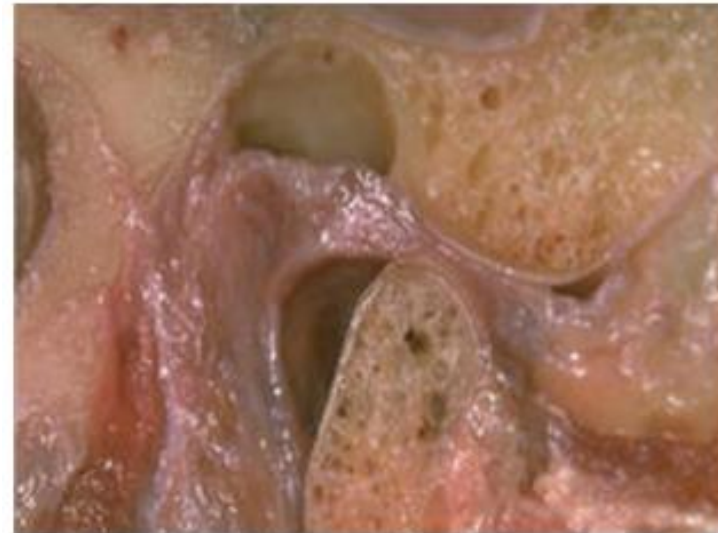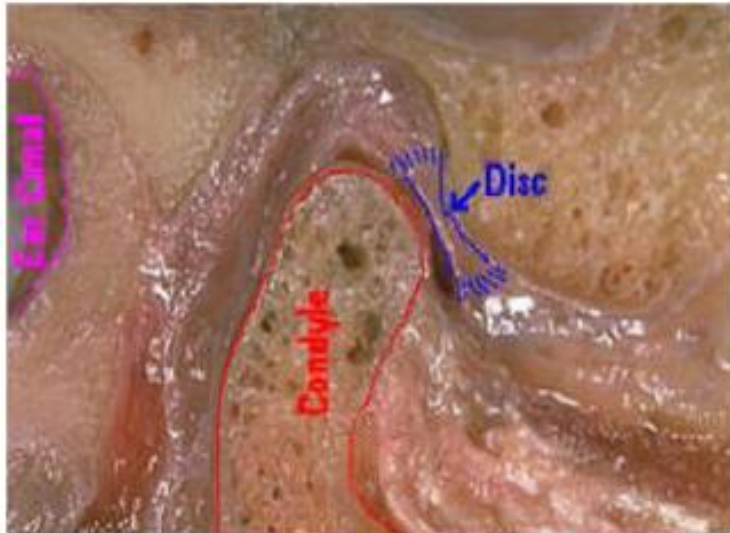
Movements at the TMJ

Hinge movement

- type of rotation takes place in the **lower** compartment between the stationary disc and the moving condyle

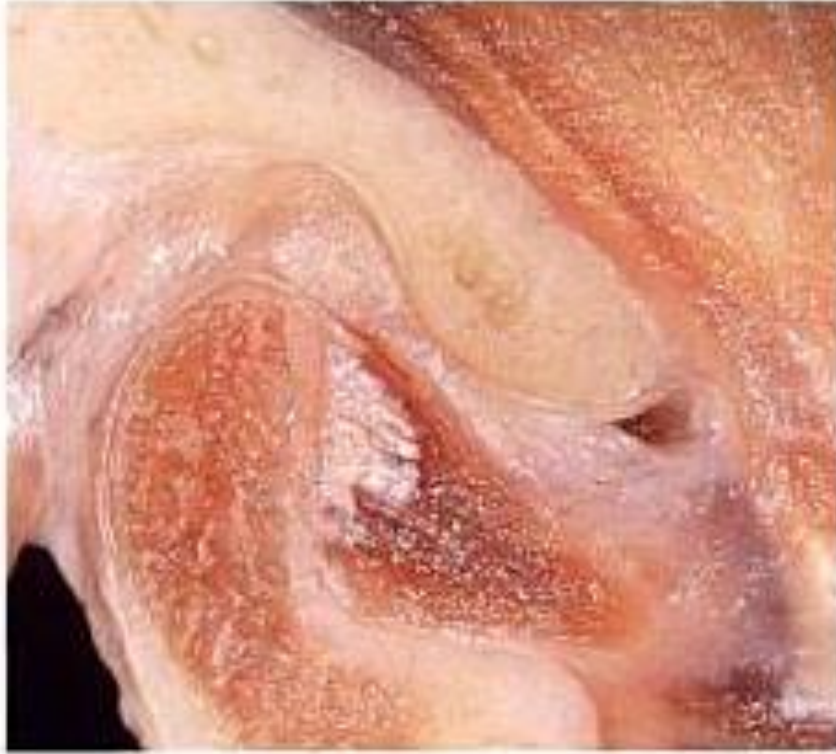Gliding movement

- takes place in the **upper** compartment between the superior surface of the disc, which is moving, and mandibular fossa



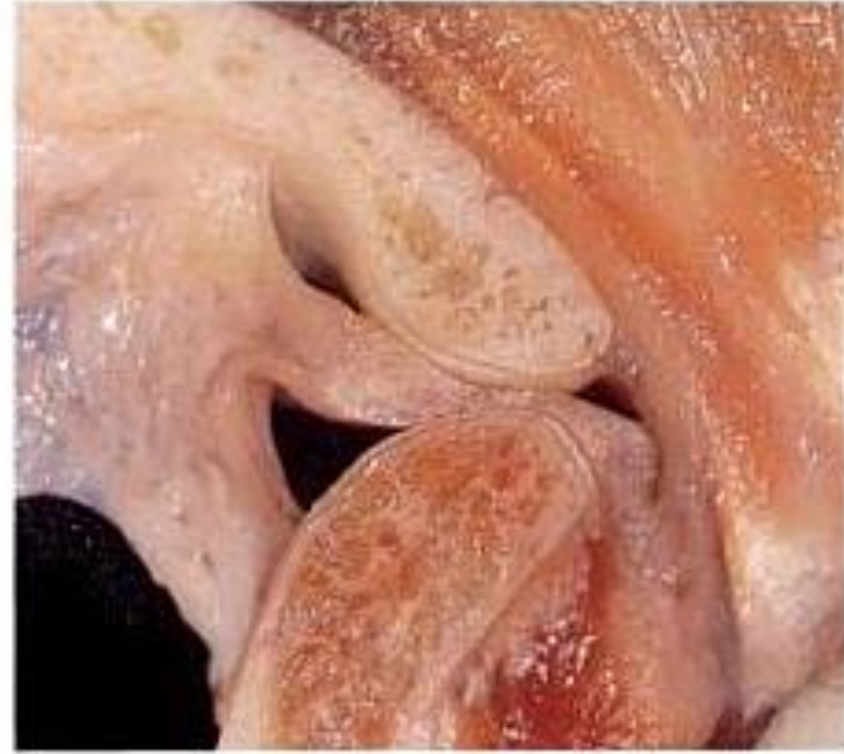Depression - the opening

- with simple rotation at the joint can be achieved 15 - 20mm intericisor distance
- during translation, the disc and condyle move under the articular eminence



Elevation – the closing

- translation - the condyles move backward and upward along the articular eminence
- rotation upward to attain final position



Protrusion

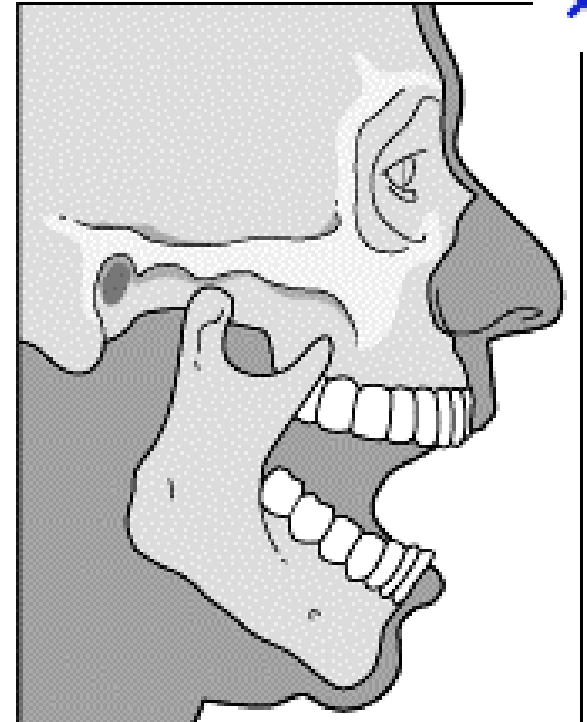
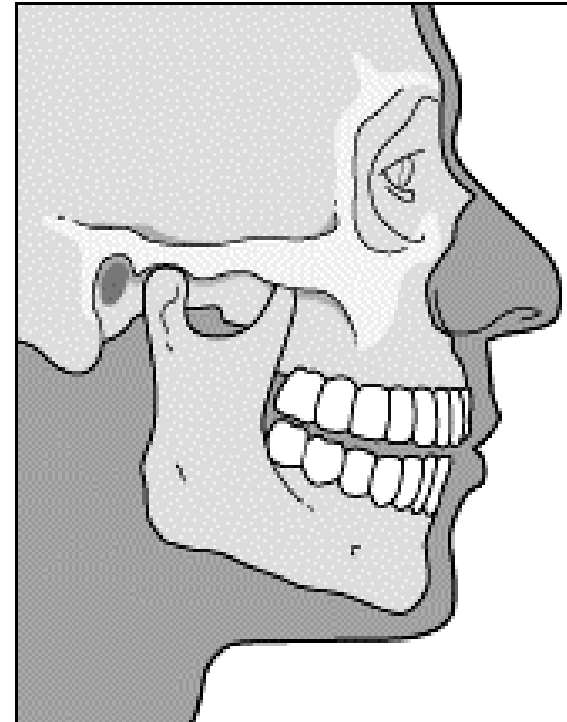
- slide the mandible forward
- maximal protrusion results in the lower incisors being a few mm anterior to the maxillary incisors

Retrusion

- move the mandible posteriorly
- condyles move backward and upward and reoccupy the mandibular fossa

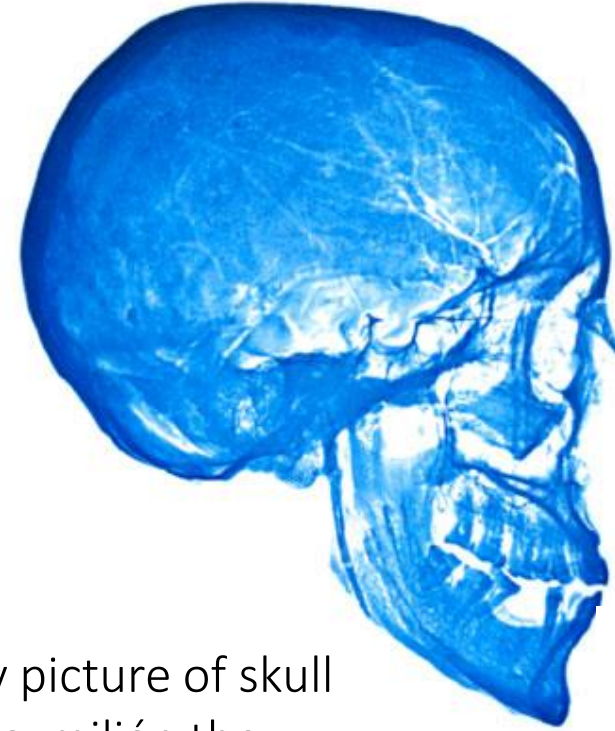
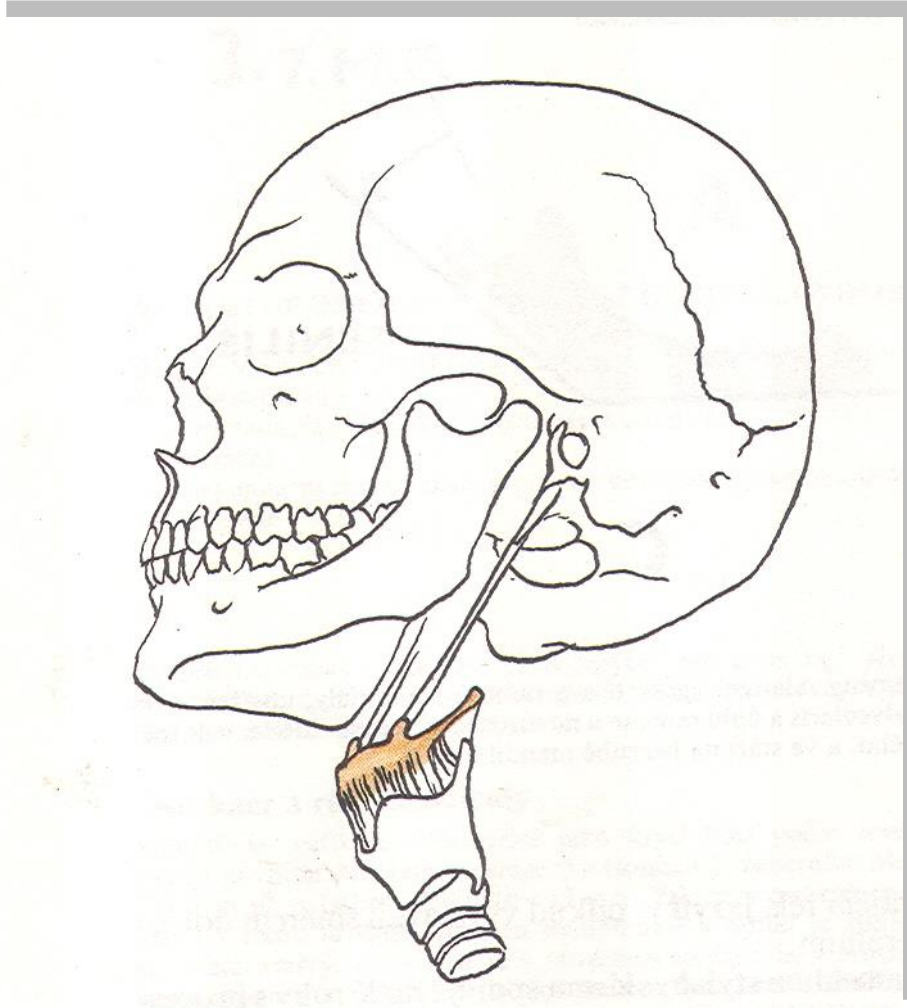
Laterotrusion

- the condyle move to the right or to the left side

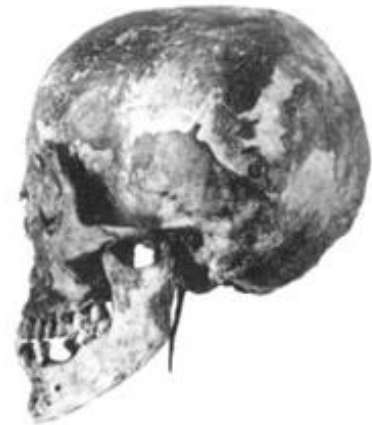

Hyoid junctions

The skull and hyoid bone connects using muscle and *lig. stylohyoideum*



X-ray picture of skull of Maximilian the 2nd with good visible processus styloideus elongatus, 7 cm long



Illustrations were copied from:

**Atlas der Anatomie des Menschen/Sobotta. Putz,R., und Pabst,R. 20. Auflage. München:
Urban & Schwarzenberg, 1993)**

Netter: Interactive Atlas of Human Anatomy. Windows Version 2.0

Čihák R: Anatomie 2 (Splanchnologia). Avicenum, zdravotnické nakladatelství, Praha, 1988.

Drake et al: Gray's Anatomy for Students. 2010

Archiv of the lecturer