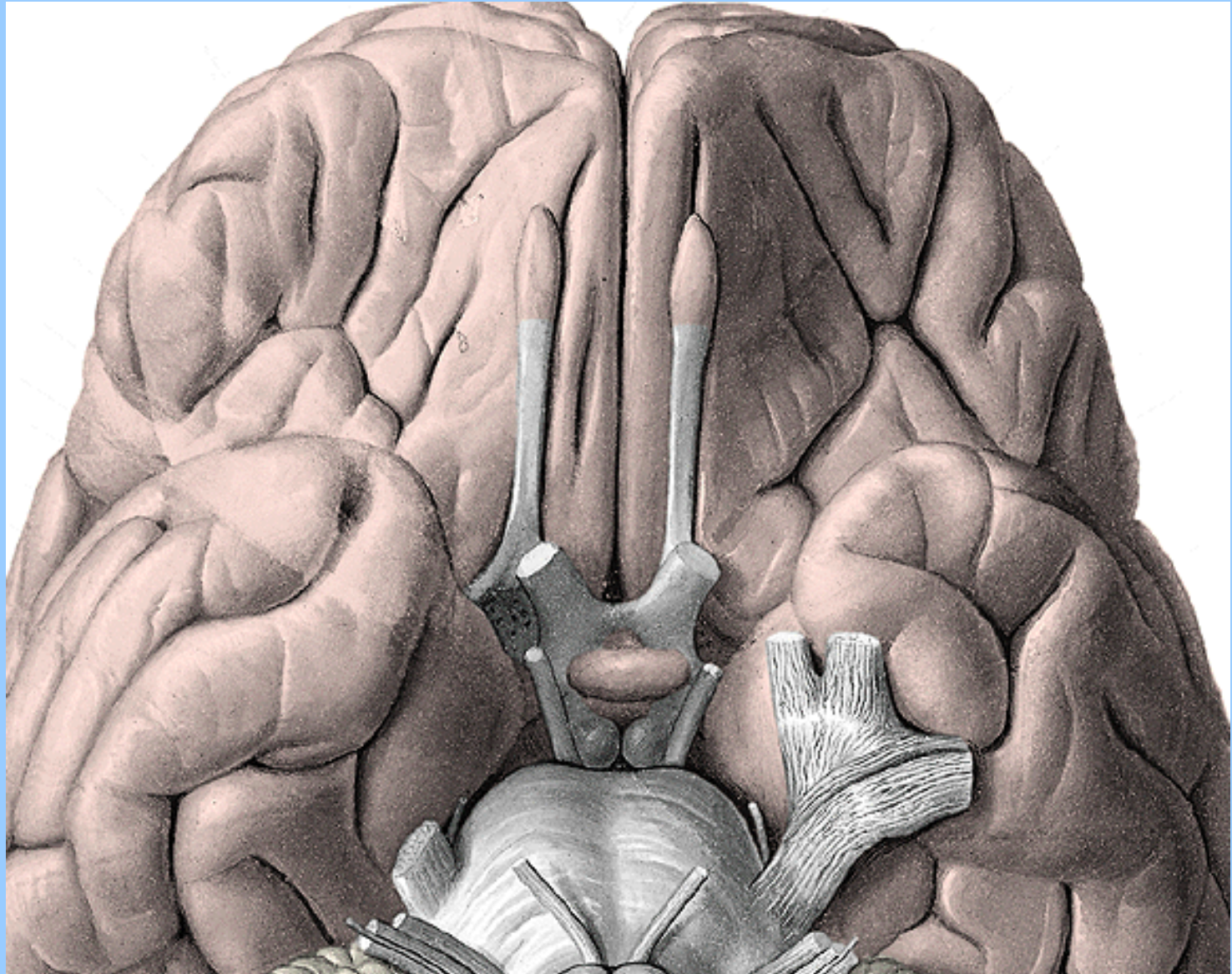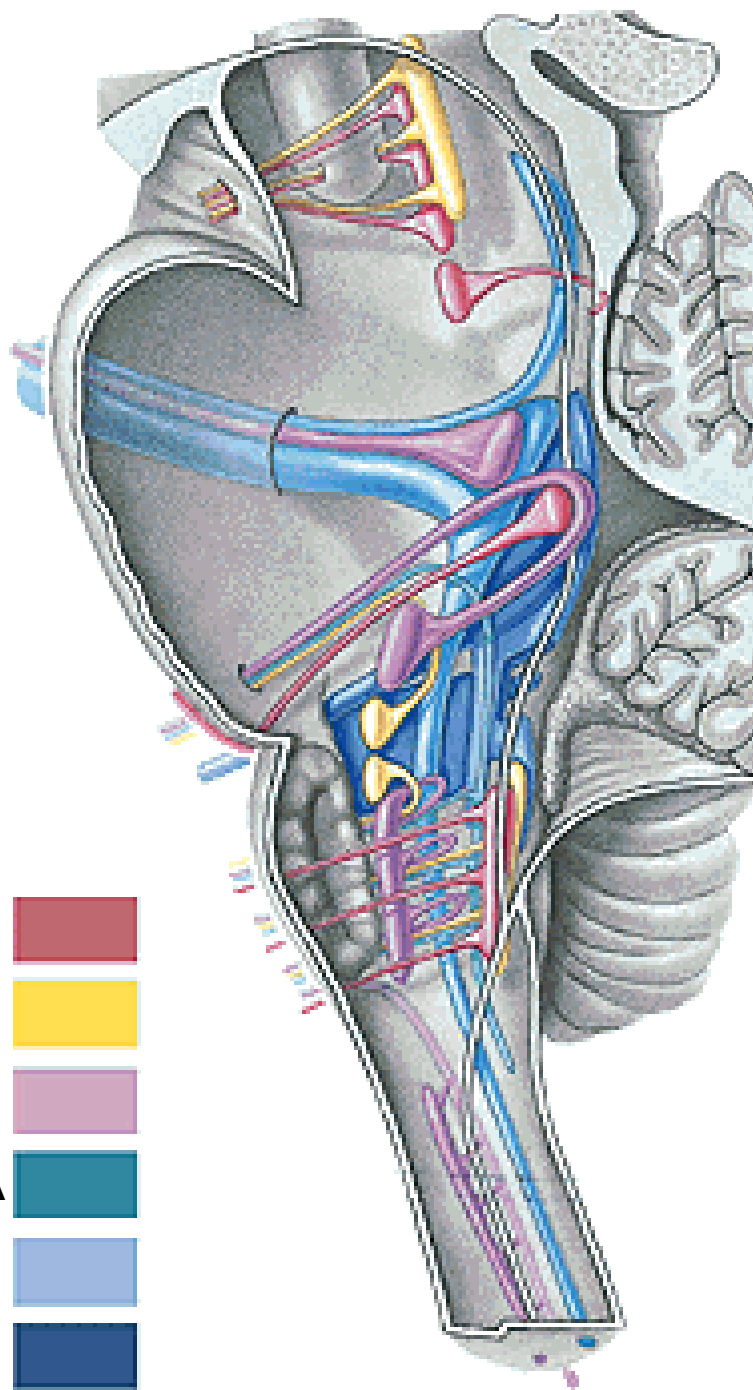








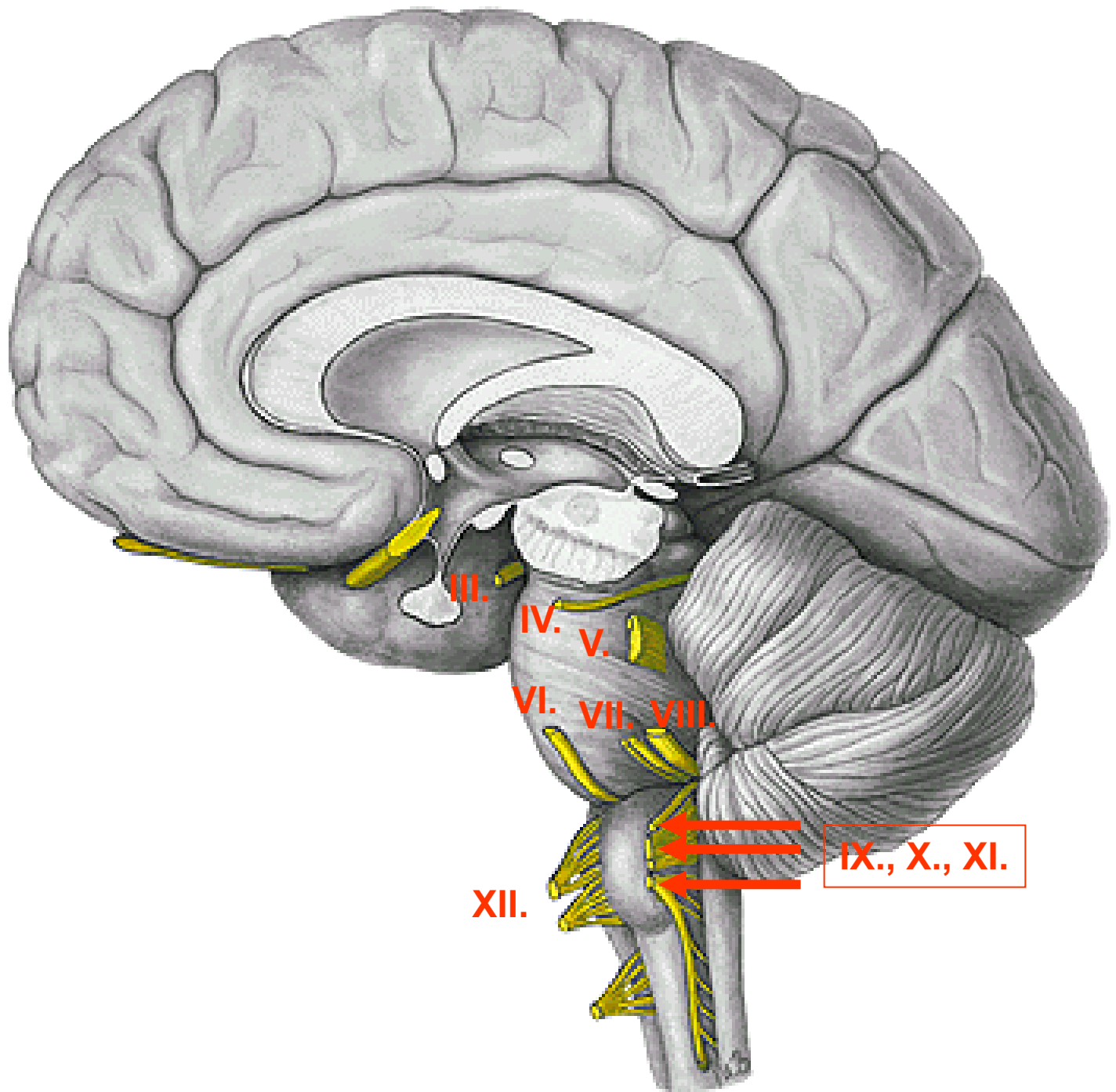
CRANIAL NERVES I

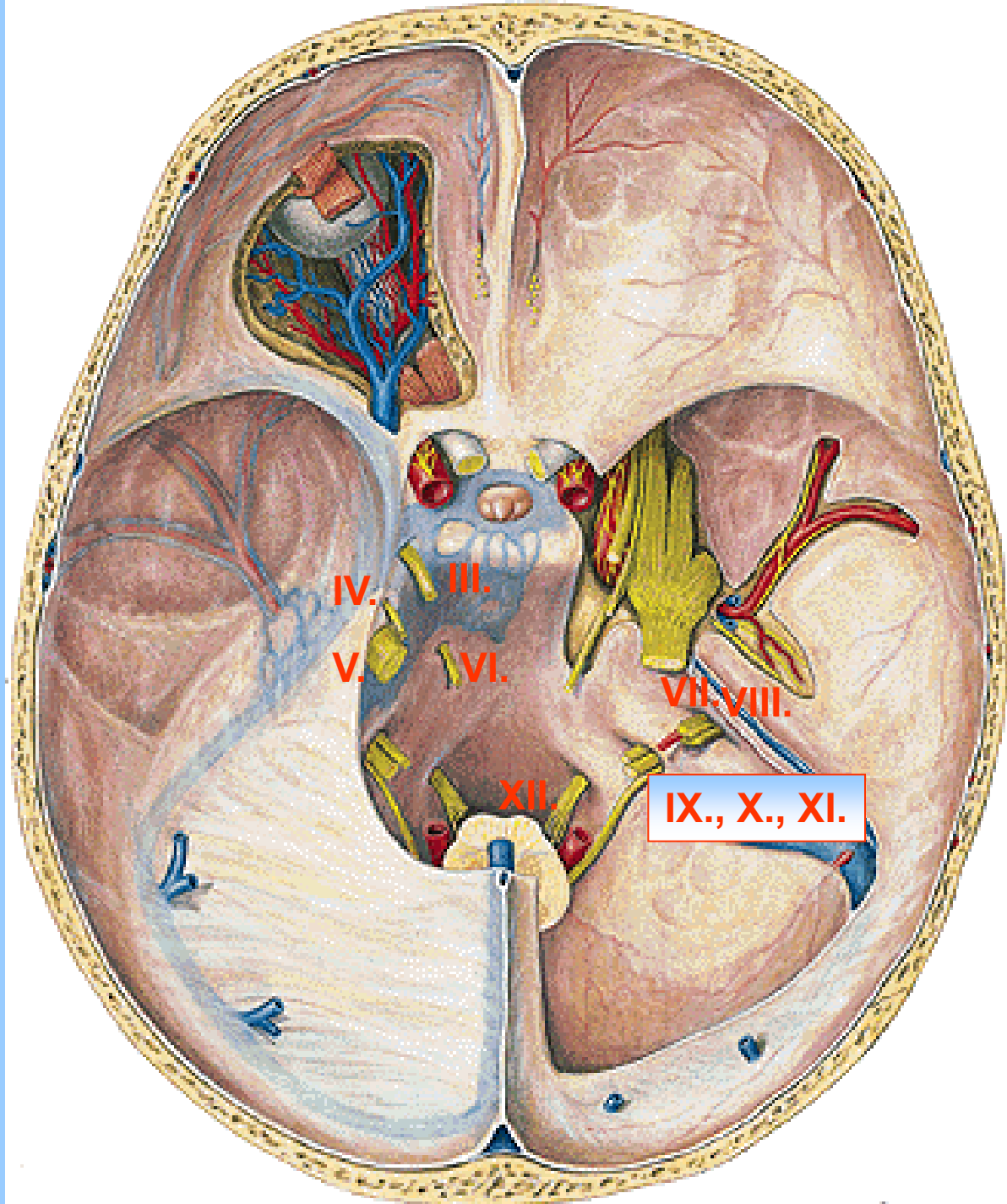
CN I – NN. OLFACTORII
CN II – N. OPTICUS





SOMATOMOTOR	- GSE	
VISCEROMOTOR	- GVE	
BRANCHIOMOTOR	- SSE	
SOMATOSENSORY	- GSA	
VISCEROSENSORY	- GVA	
SPECIAL SENSORY	- SA	





IV.

III.

V.

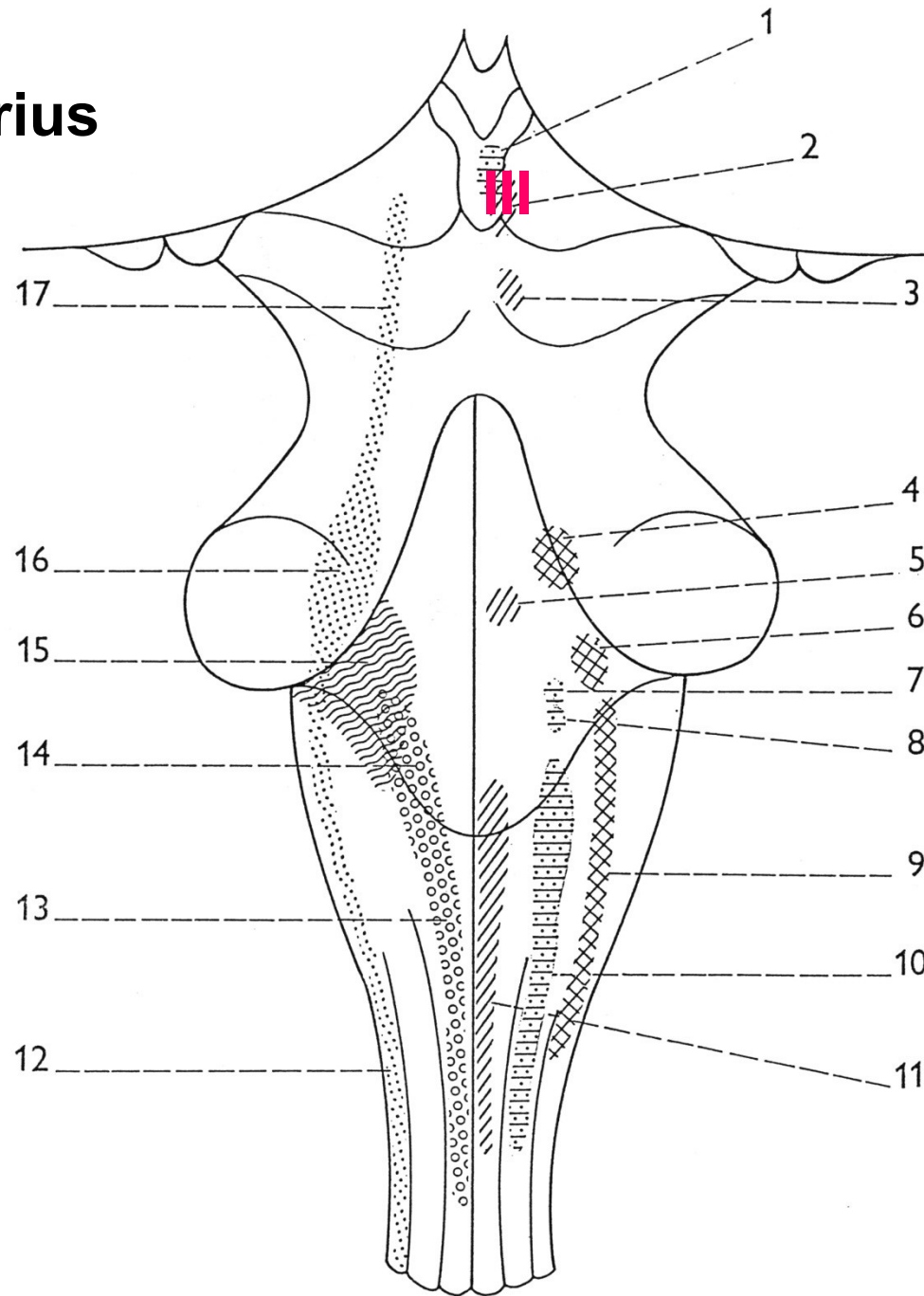
VI.

VII, VIII.

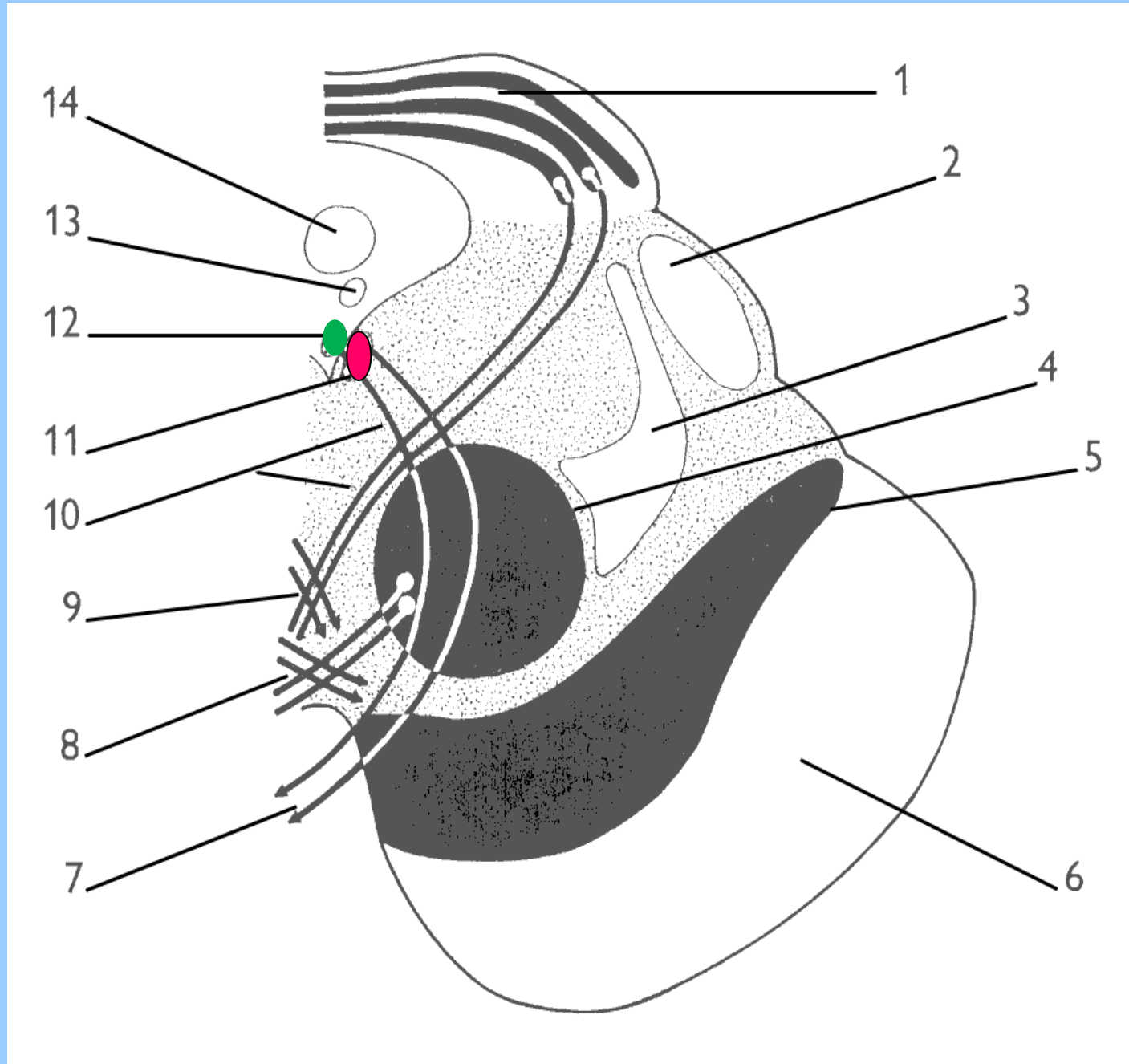
XII.

IX., X., XI.

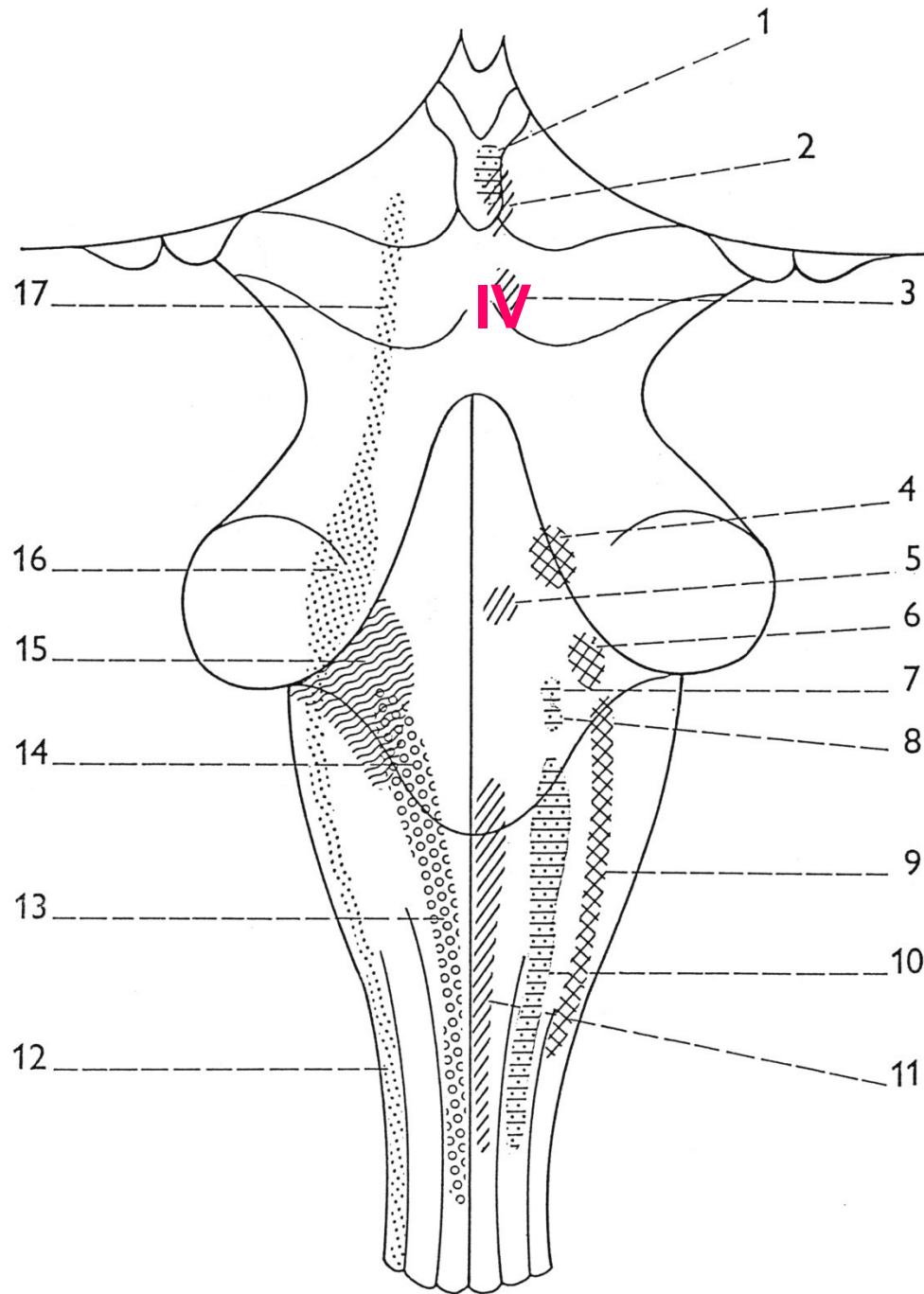
CN III – n. oculomotorius



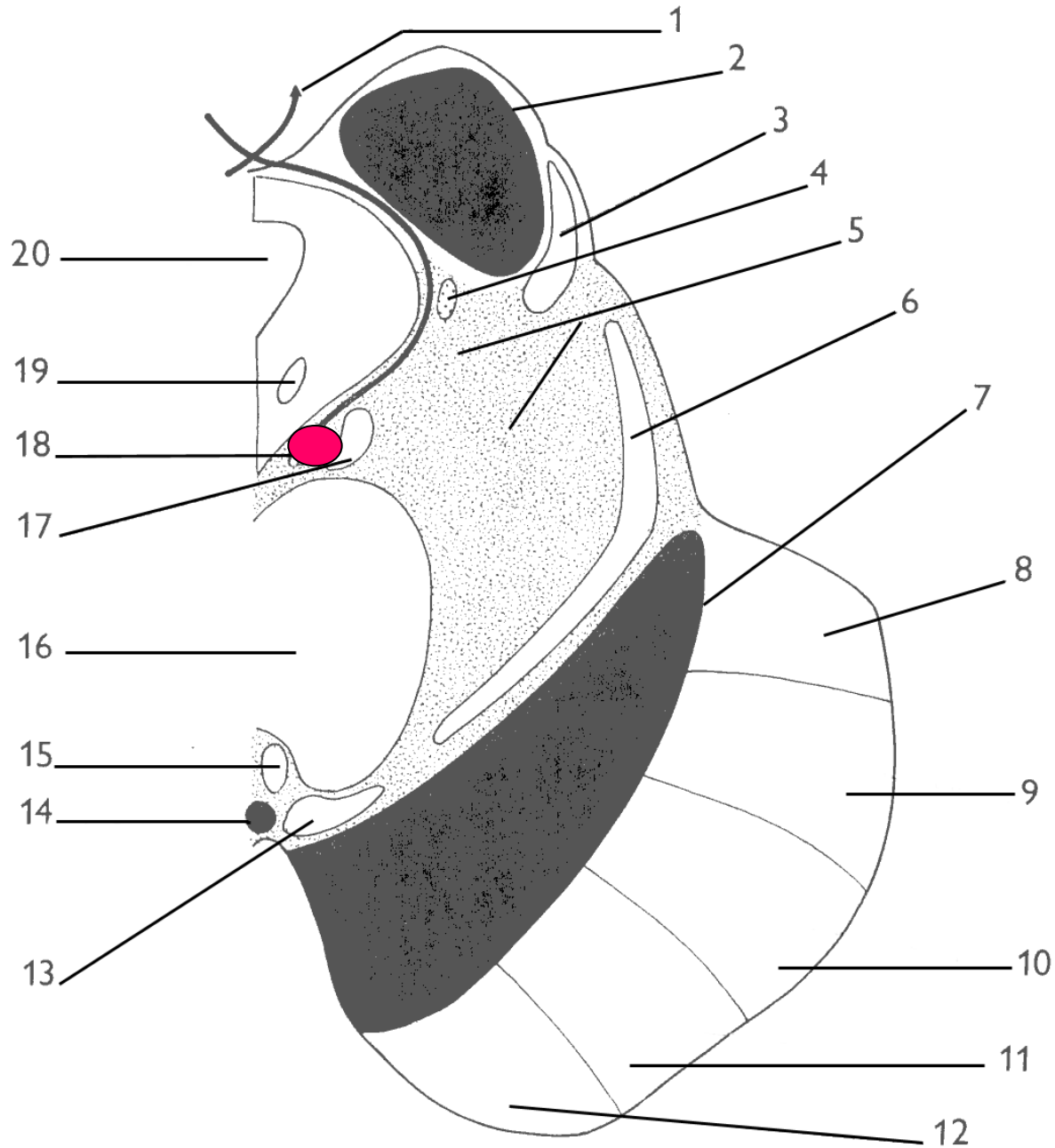
Ncl. originis CN III + ncl. parasympathicus CN III (E-W ncl.)



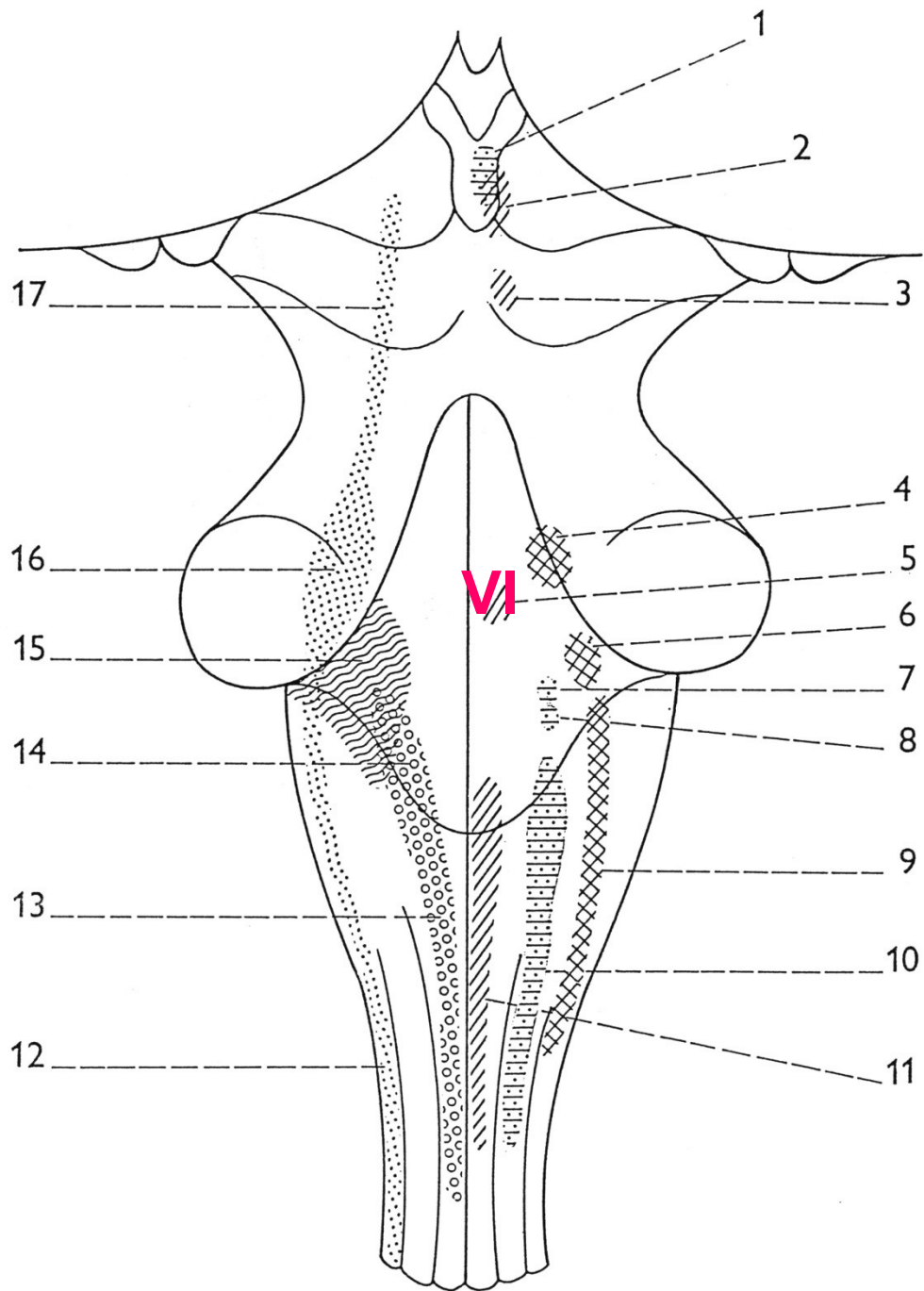
CN IV – n. trochlearis



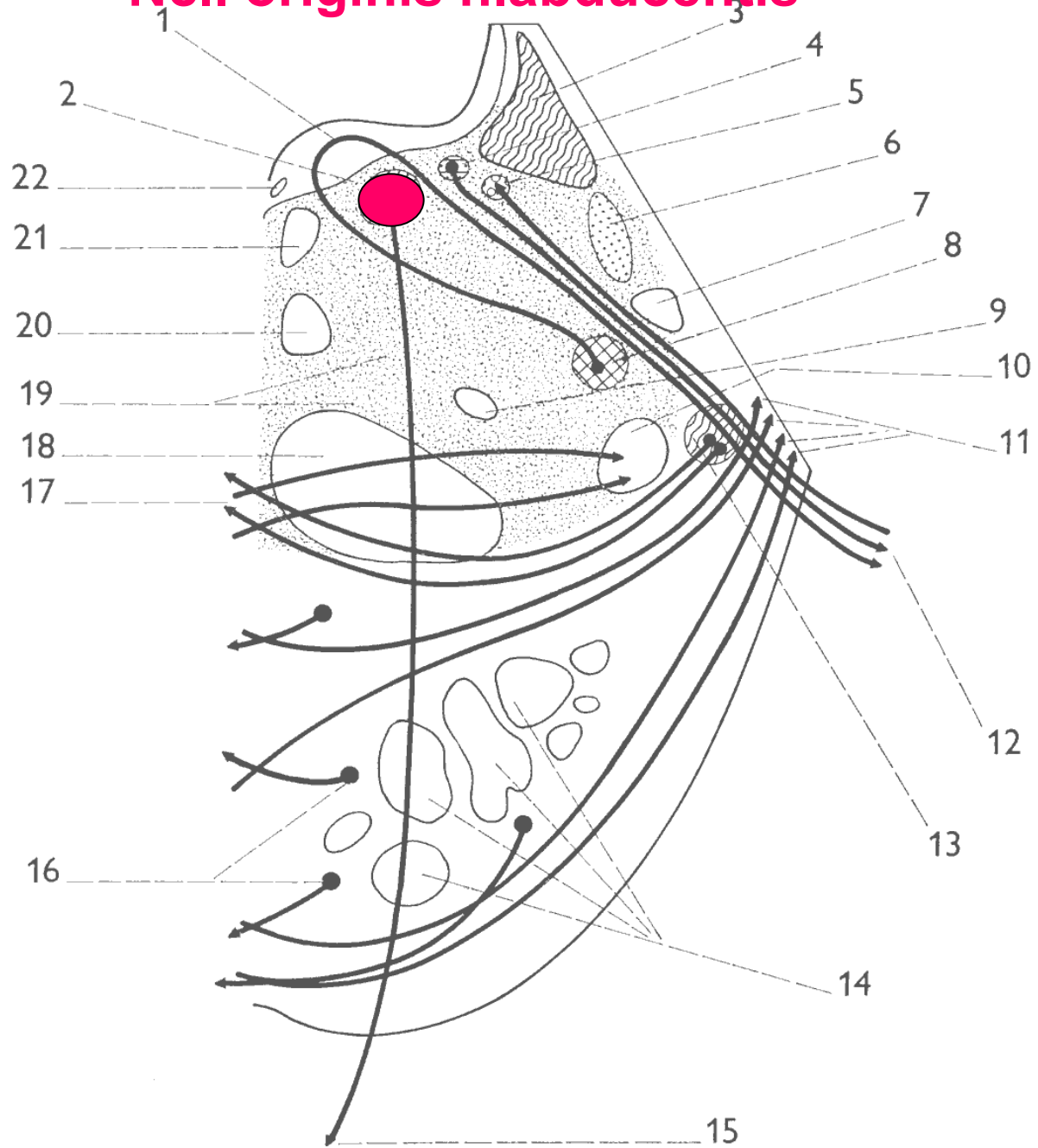
Ncl. originis n. trochlearis

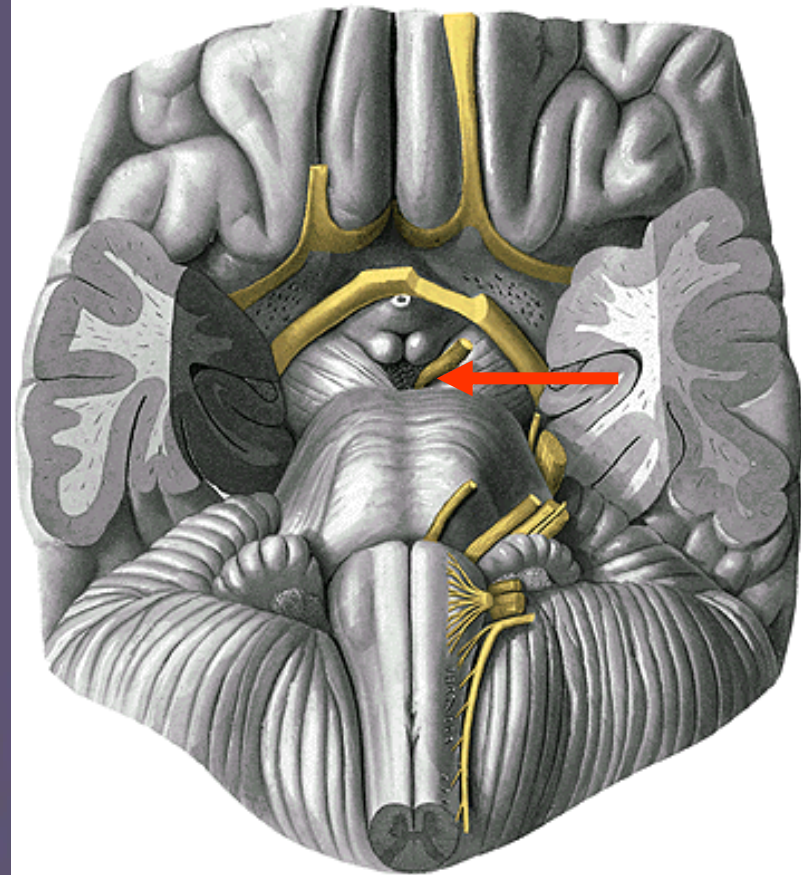
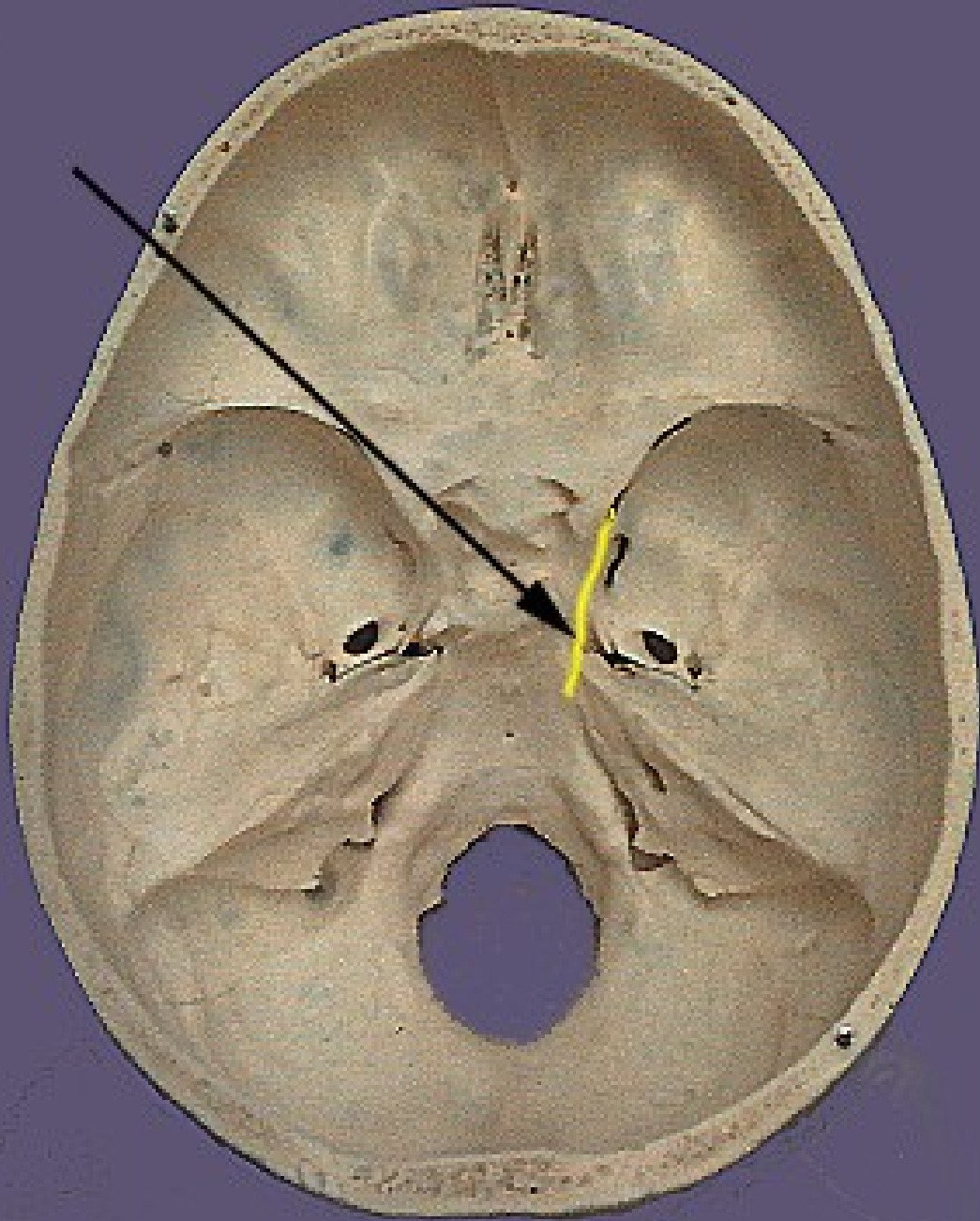


CN VI – n. abducens

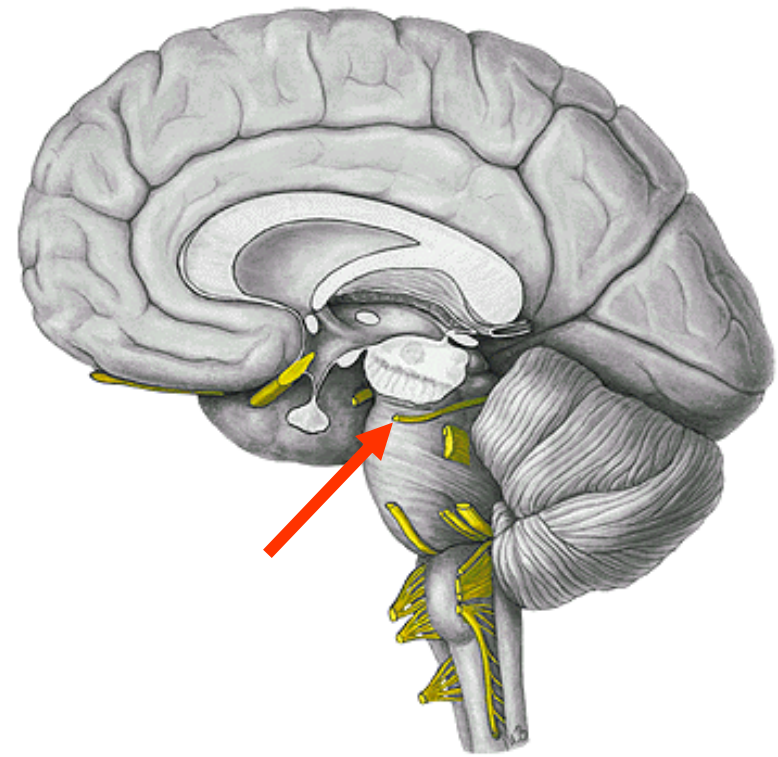
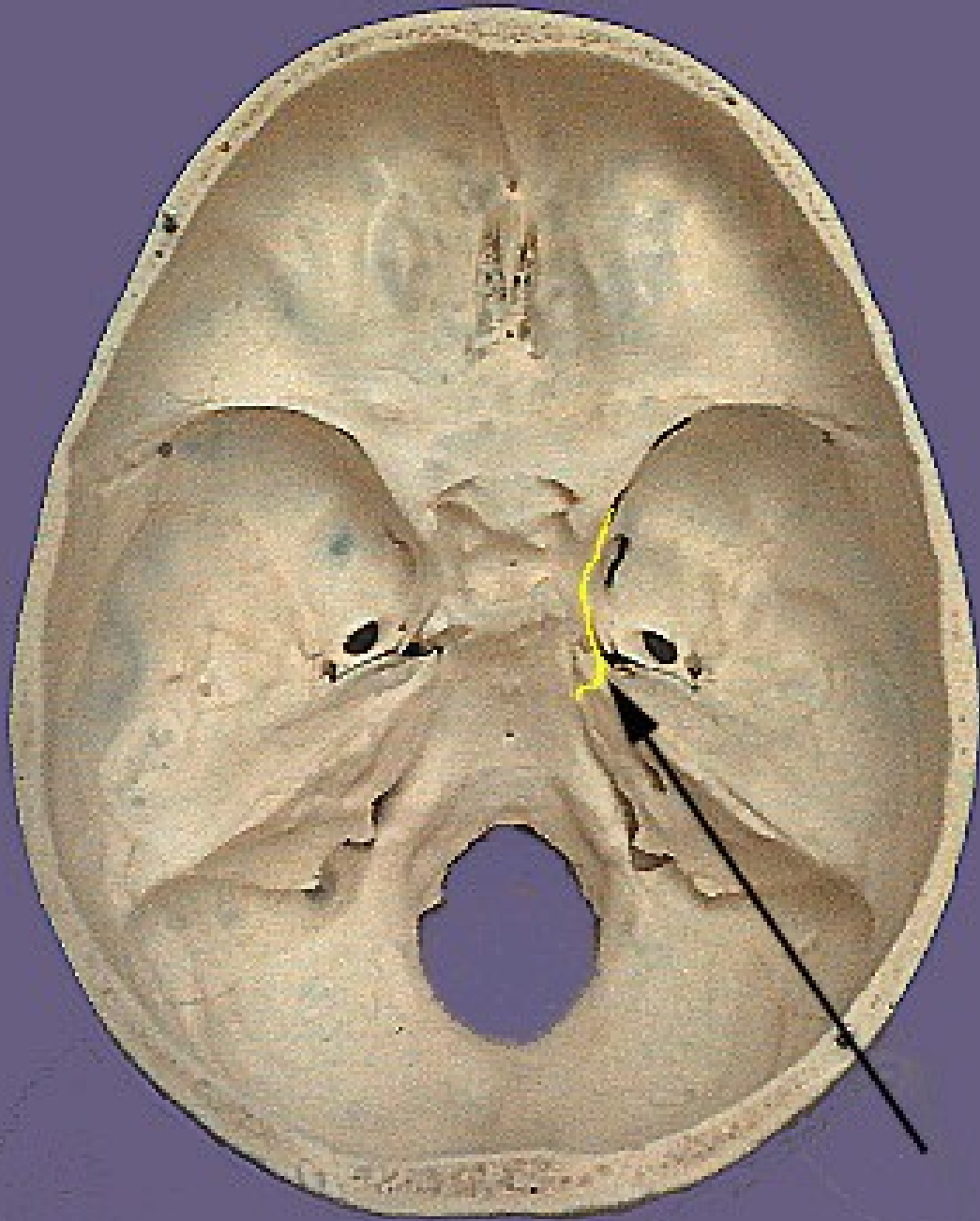


Ncl. originis n.abducentis



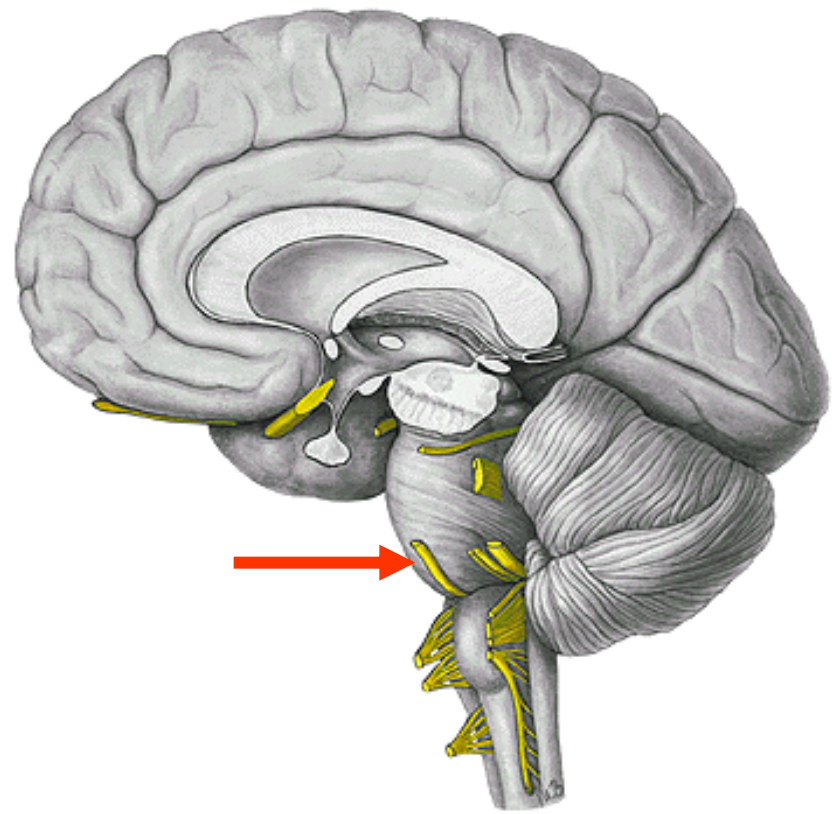
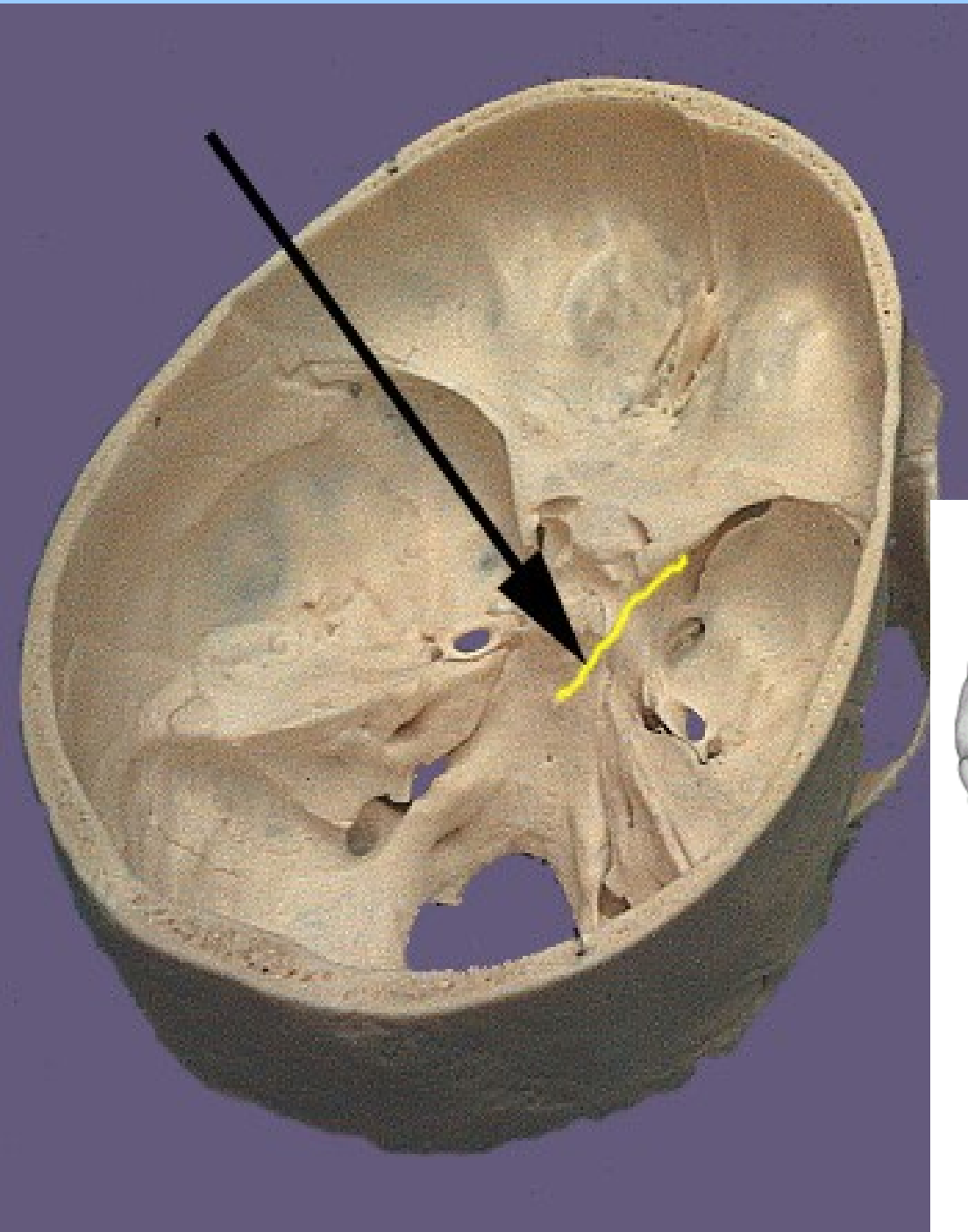


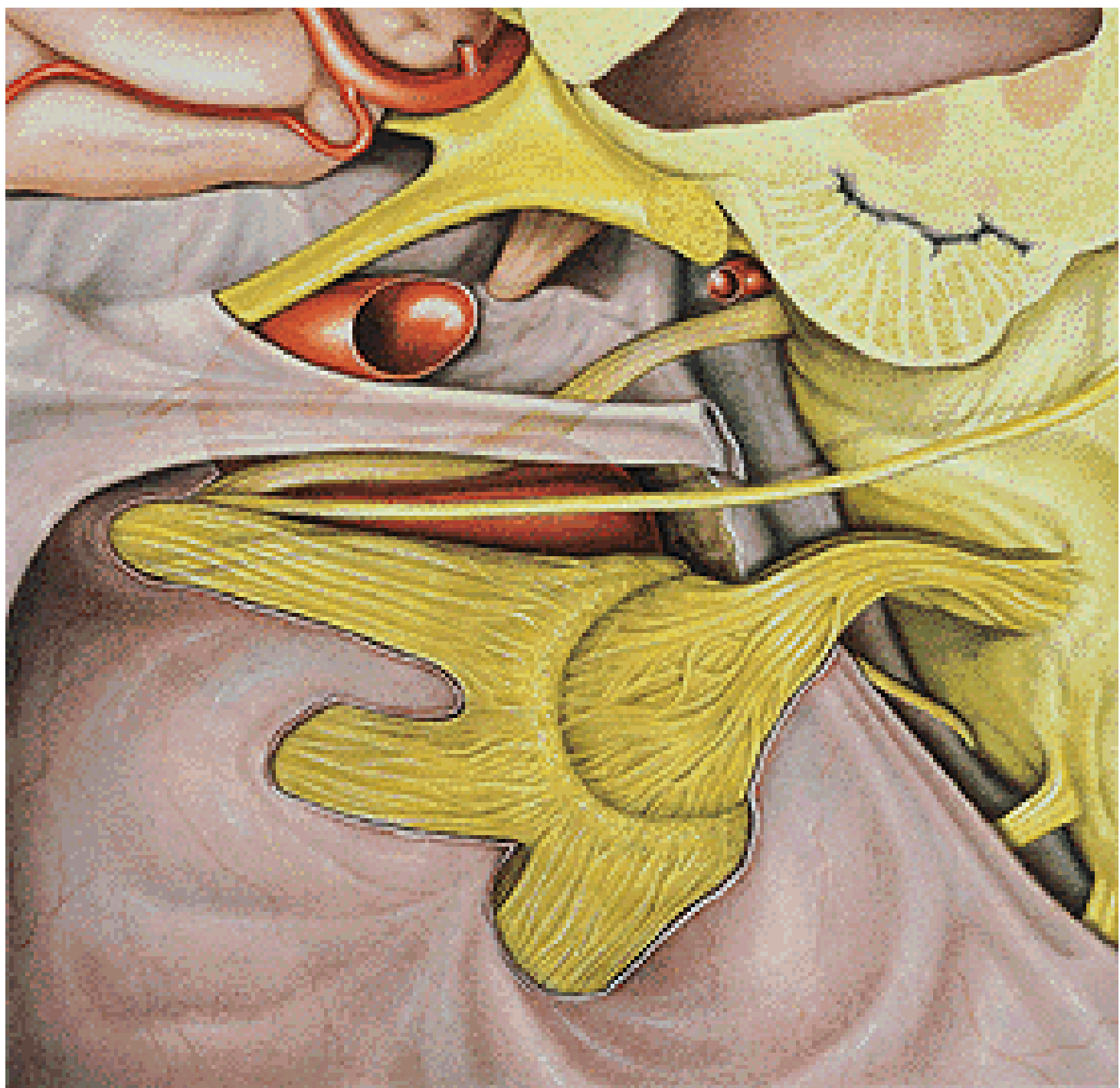
CN III



CN IV

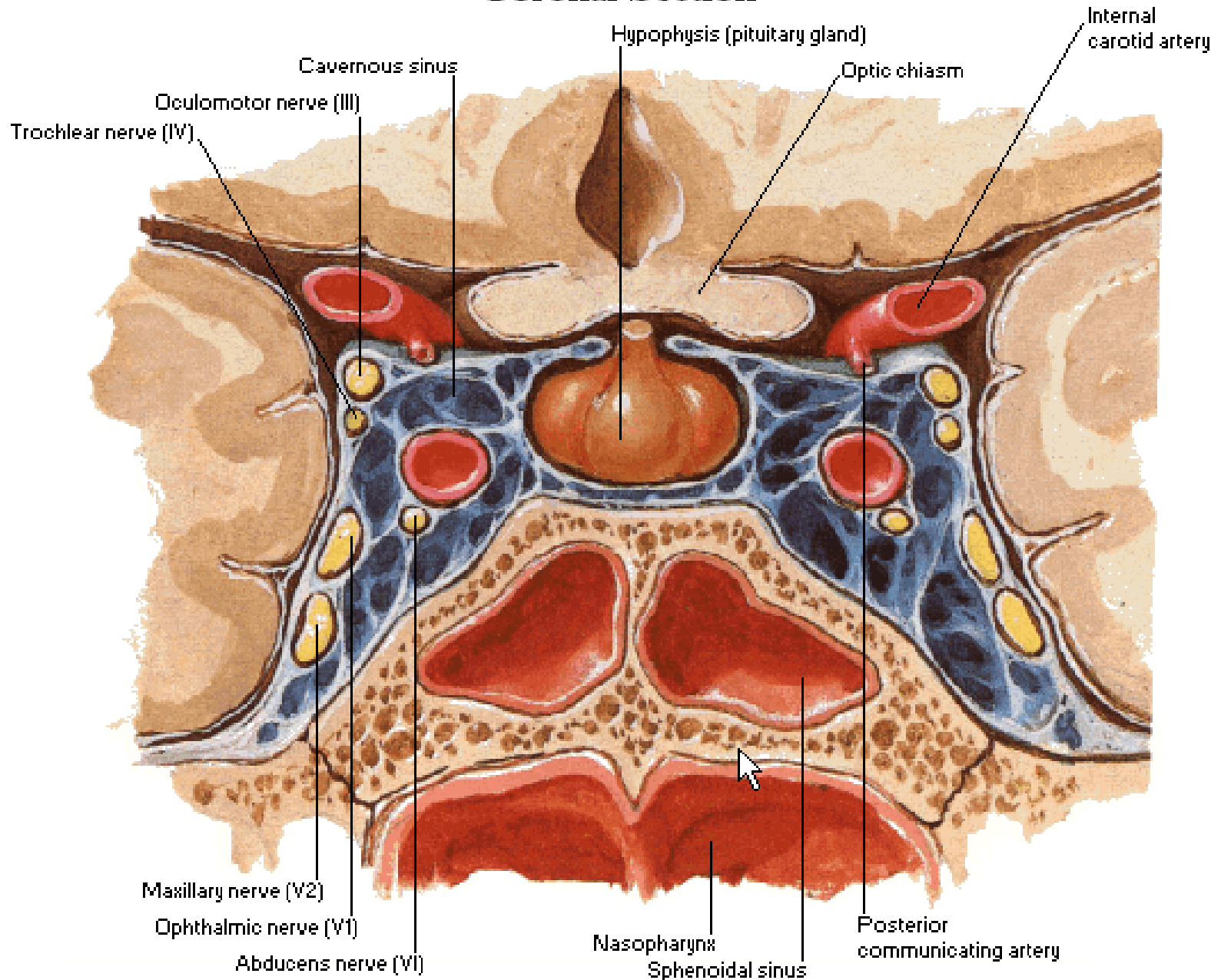
CN VI

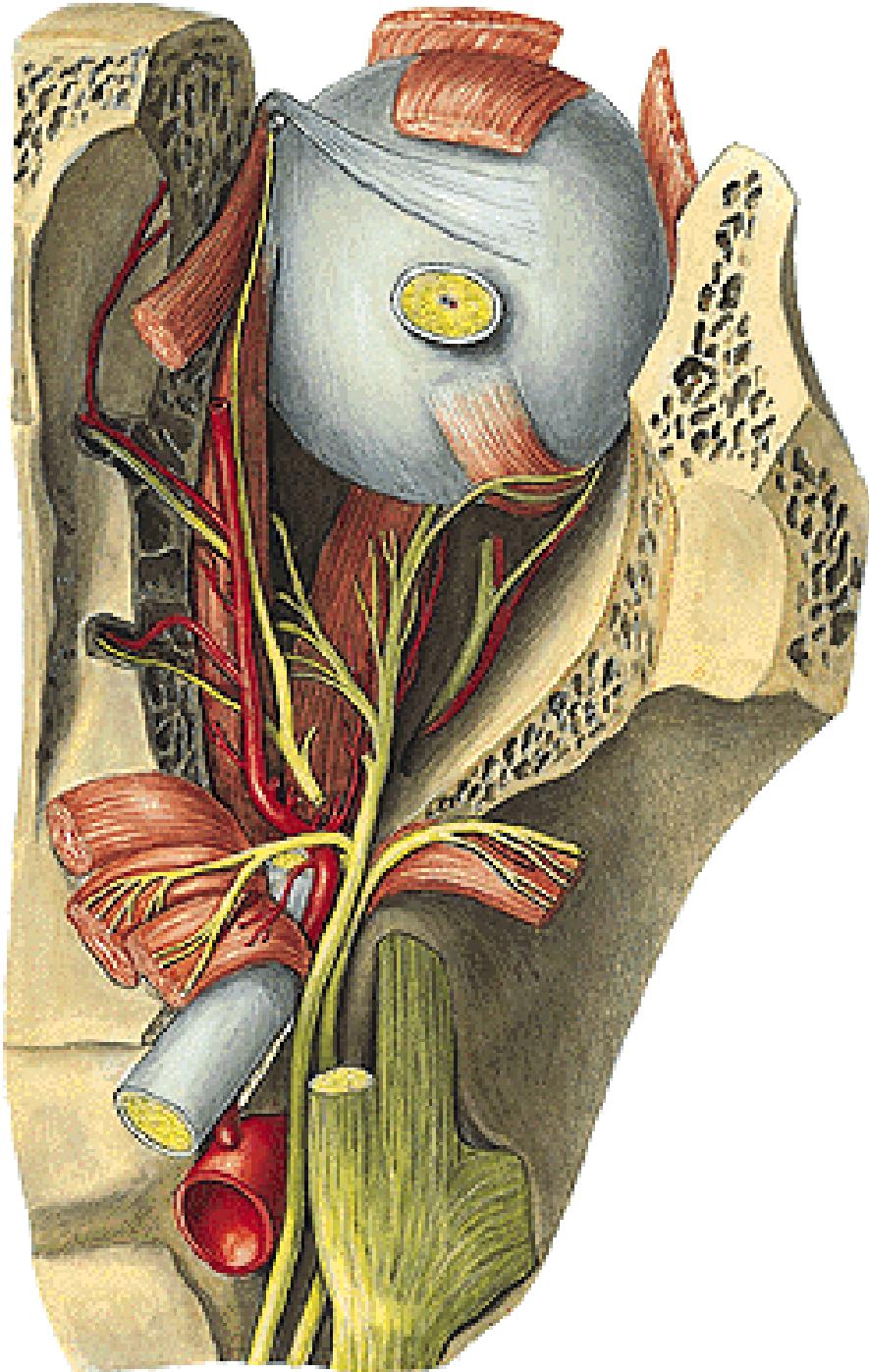




Cavernous Sinus

Coronal Section

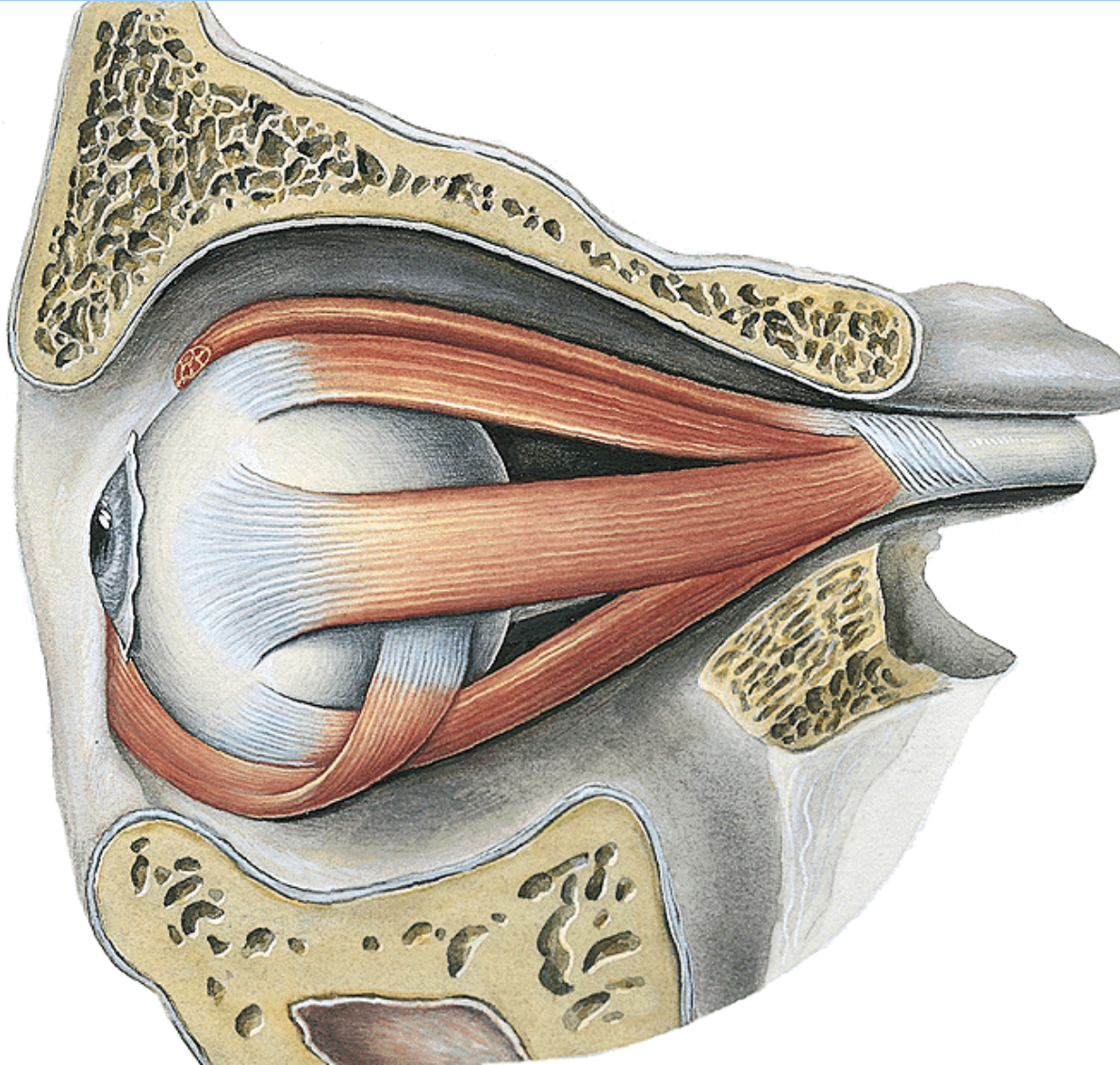




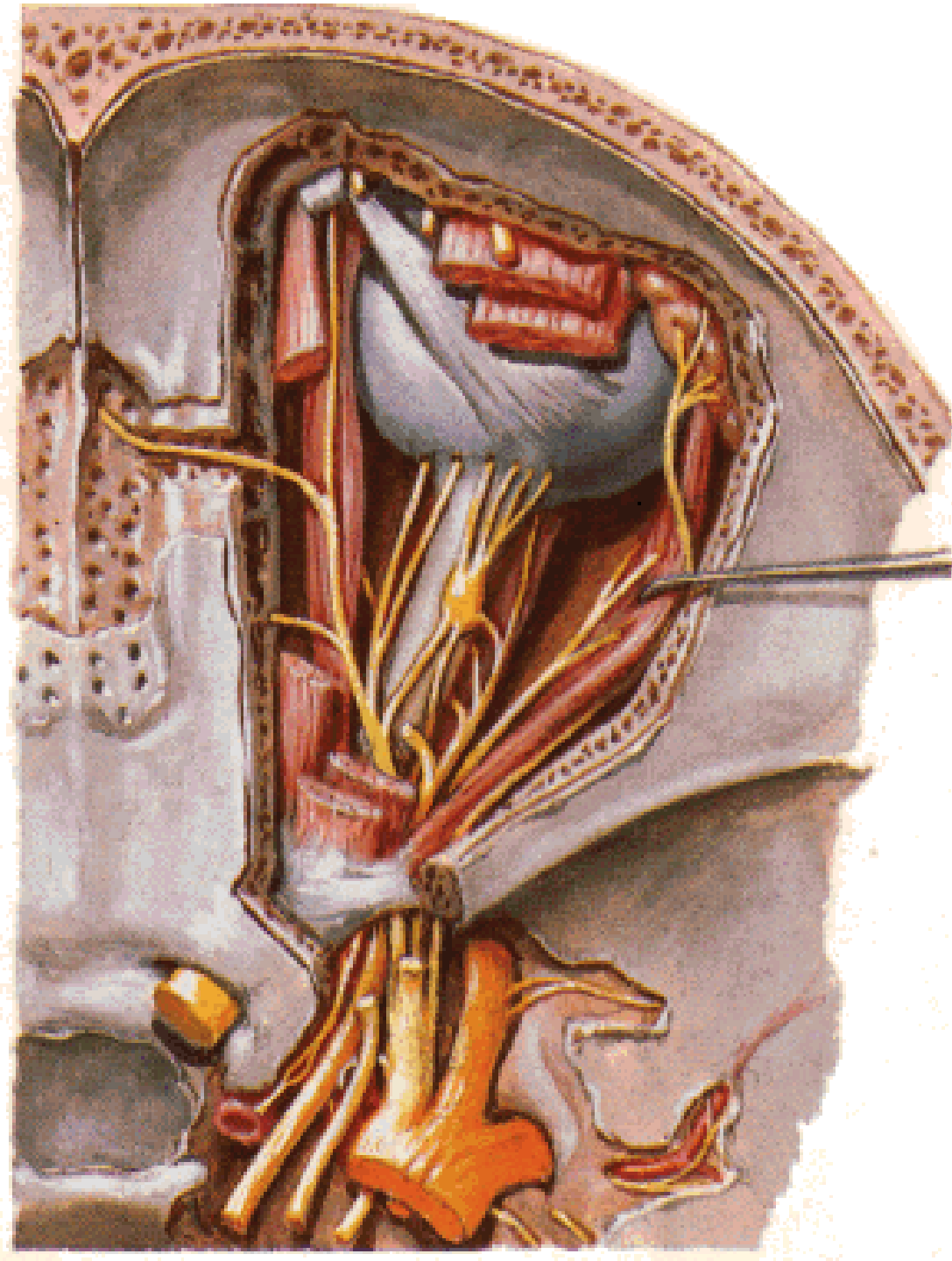
N. oculomotorius

- **r. superior:**
m. levator palpebrae sup.
m. rectus sup.

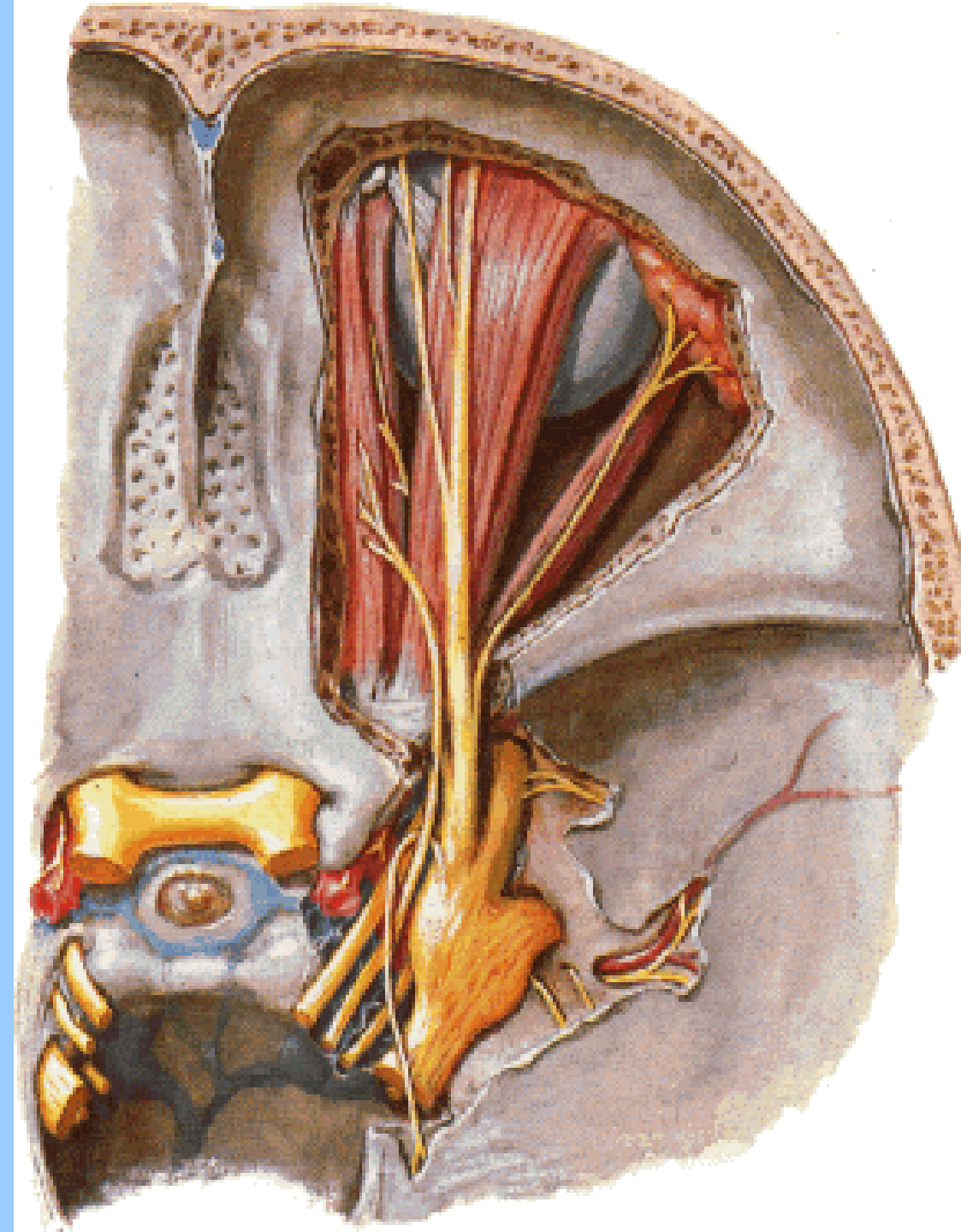
- **r. inferior:**
m. rectus inf.
m. obliquus inf.
m. rectus med.
radix parasympathica



Anulus tendineus communis

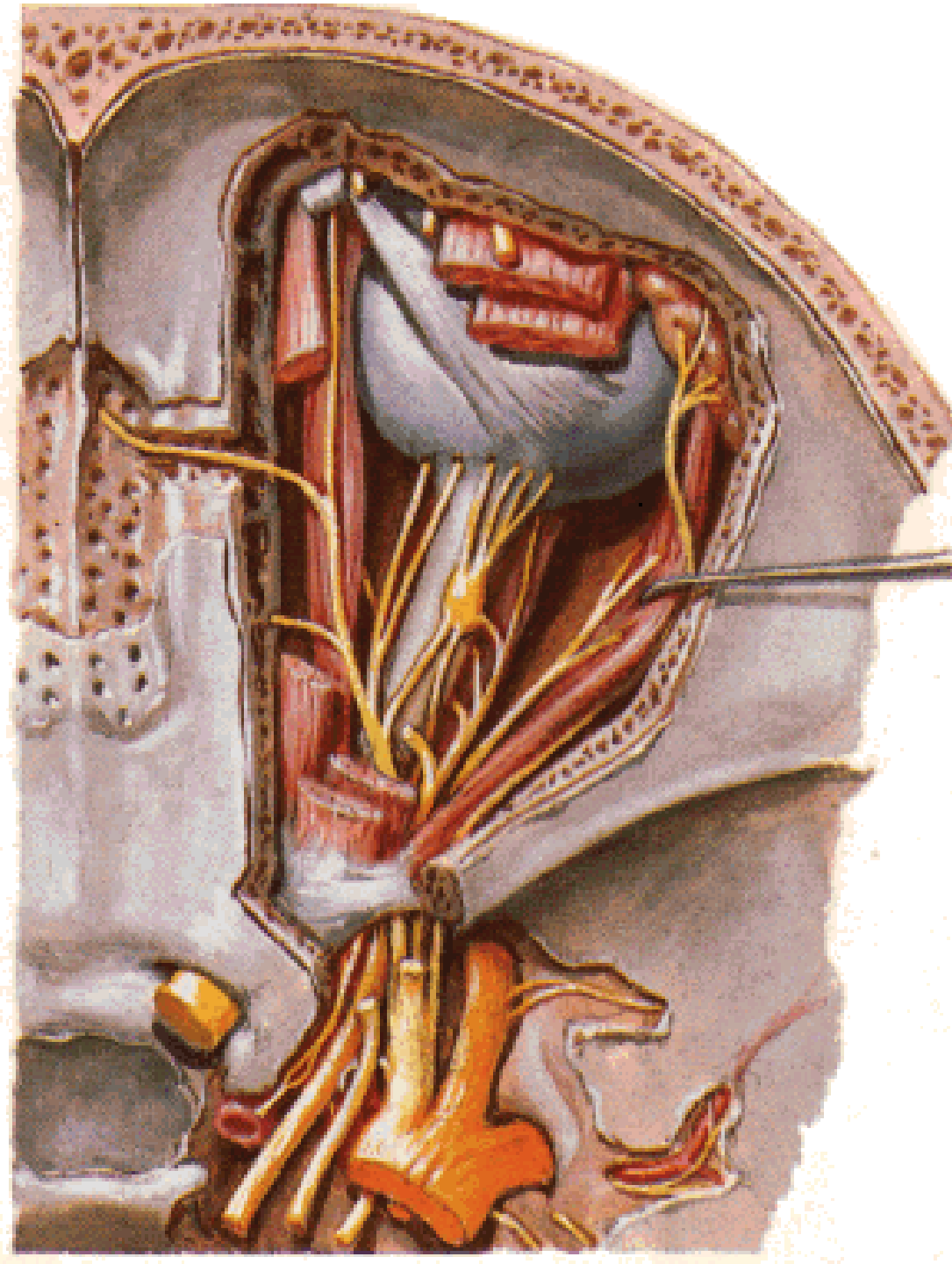


Ggl. ciliare
- nn. ciliares breves



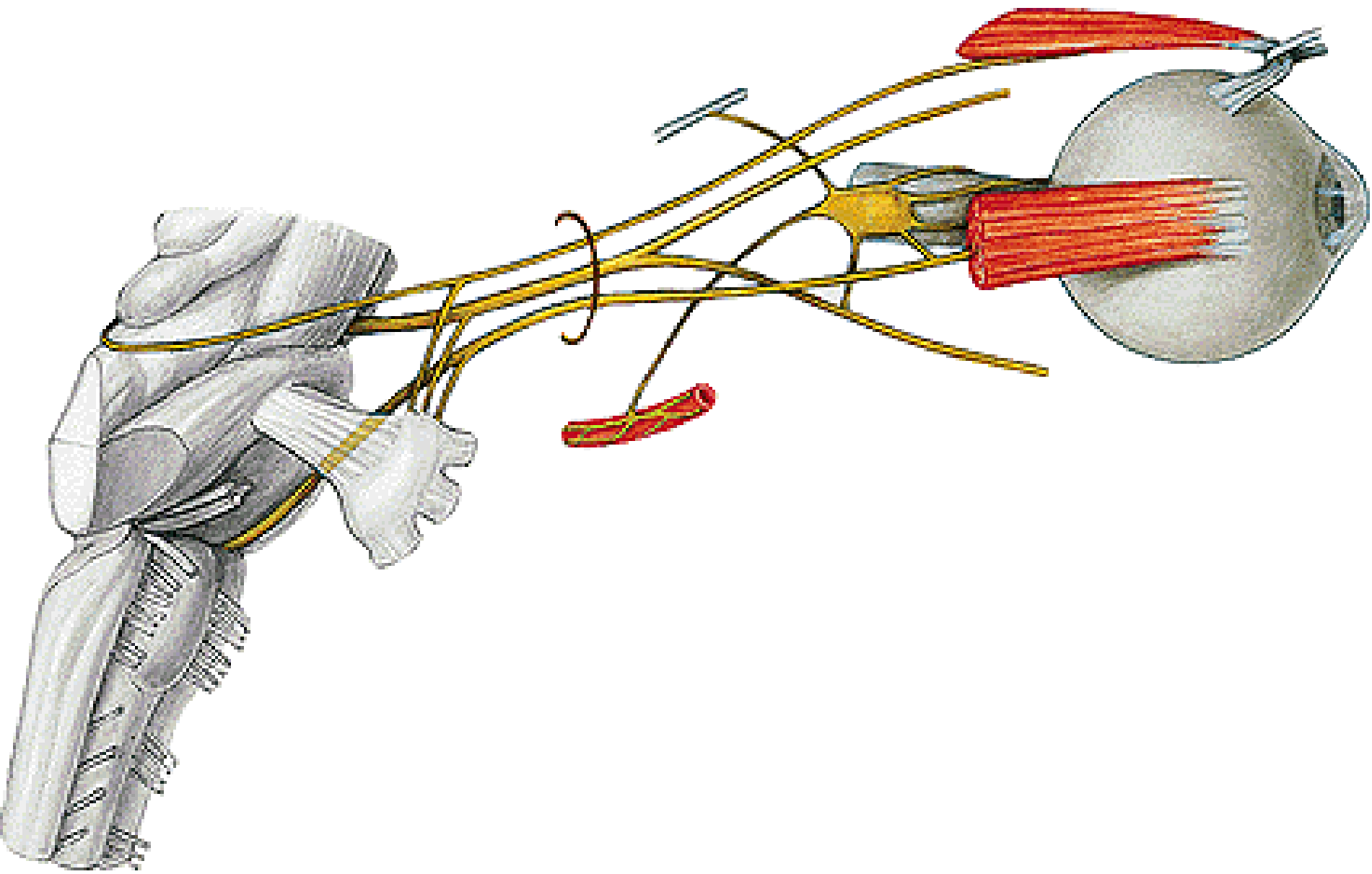
N. trochlearis

- m. obliquus bulbi superior

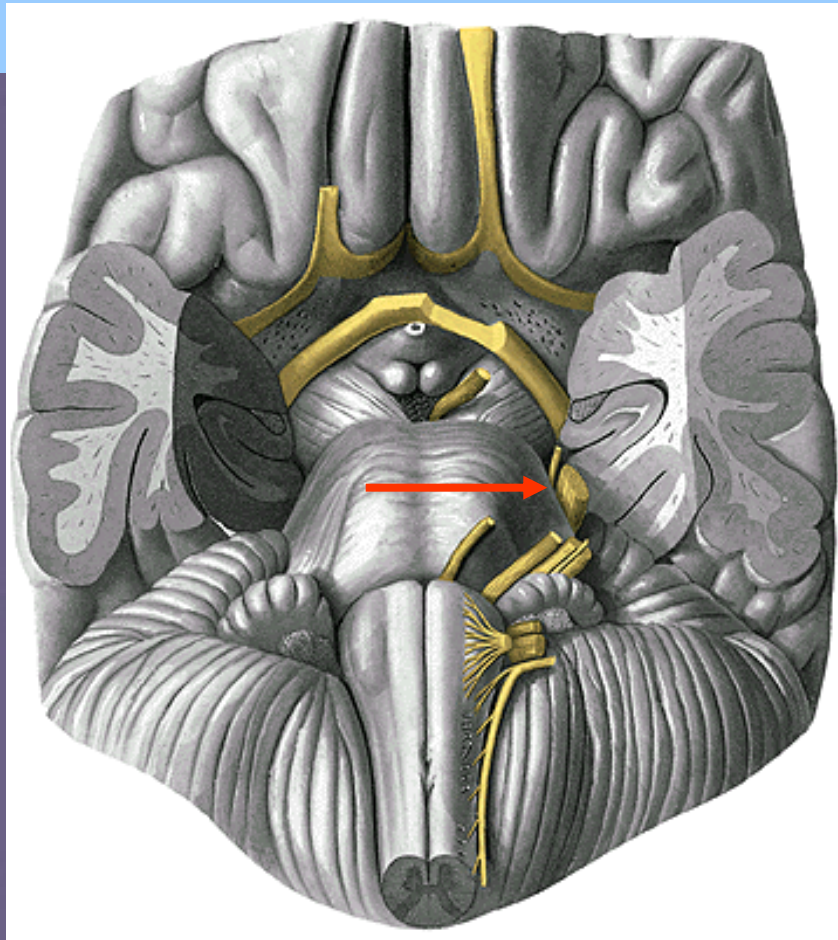
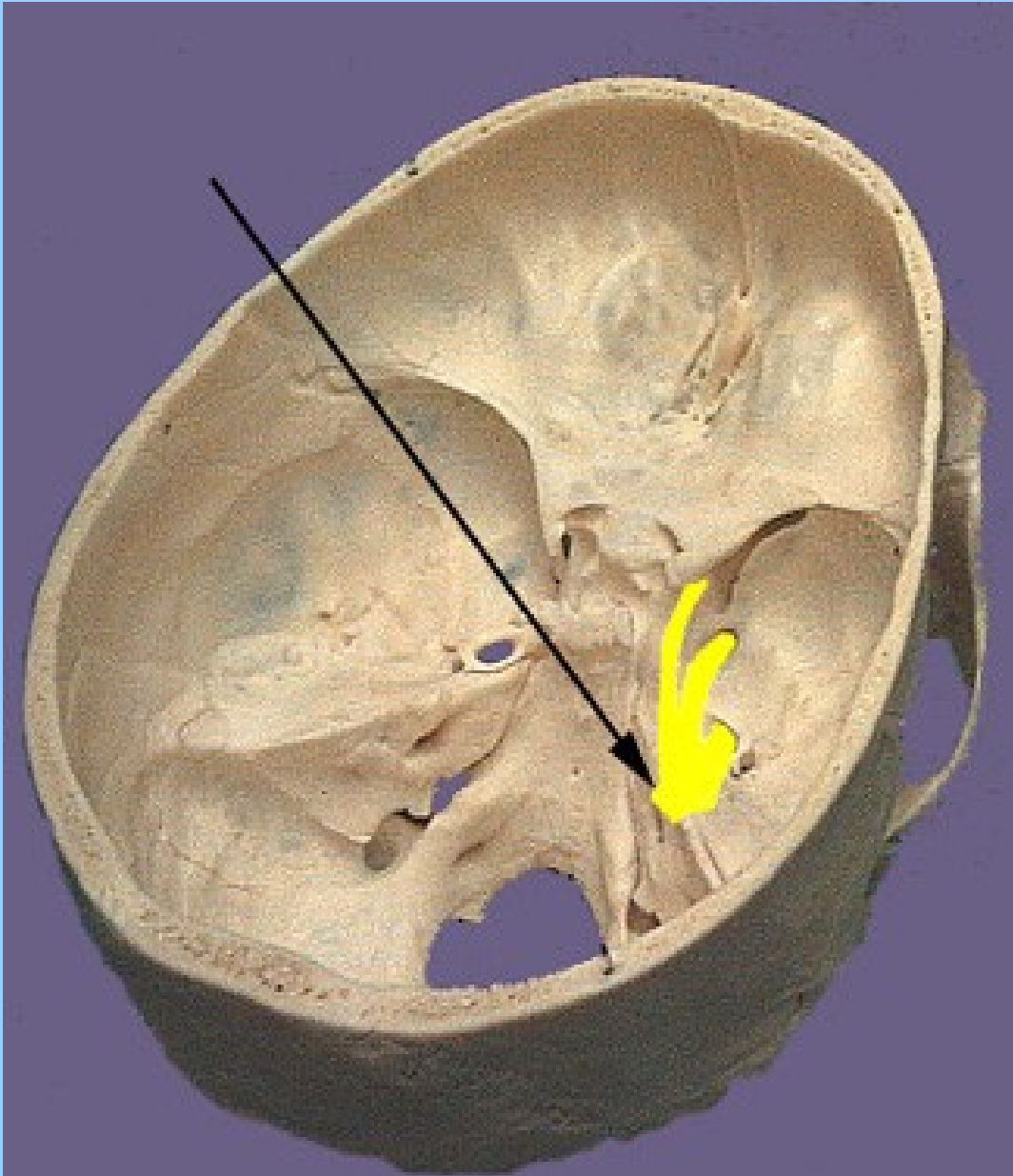


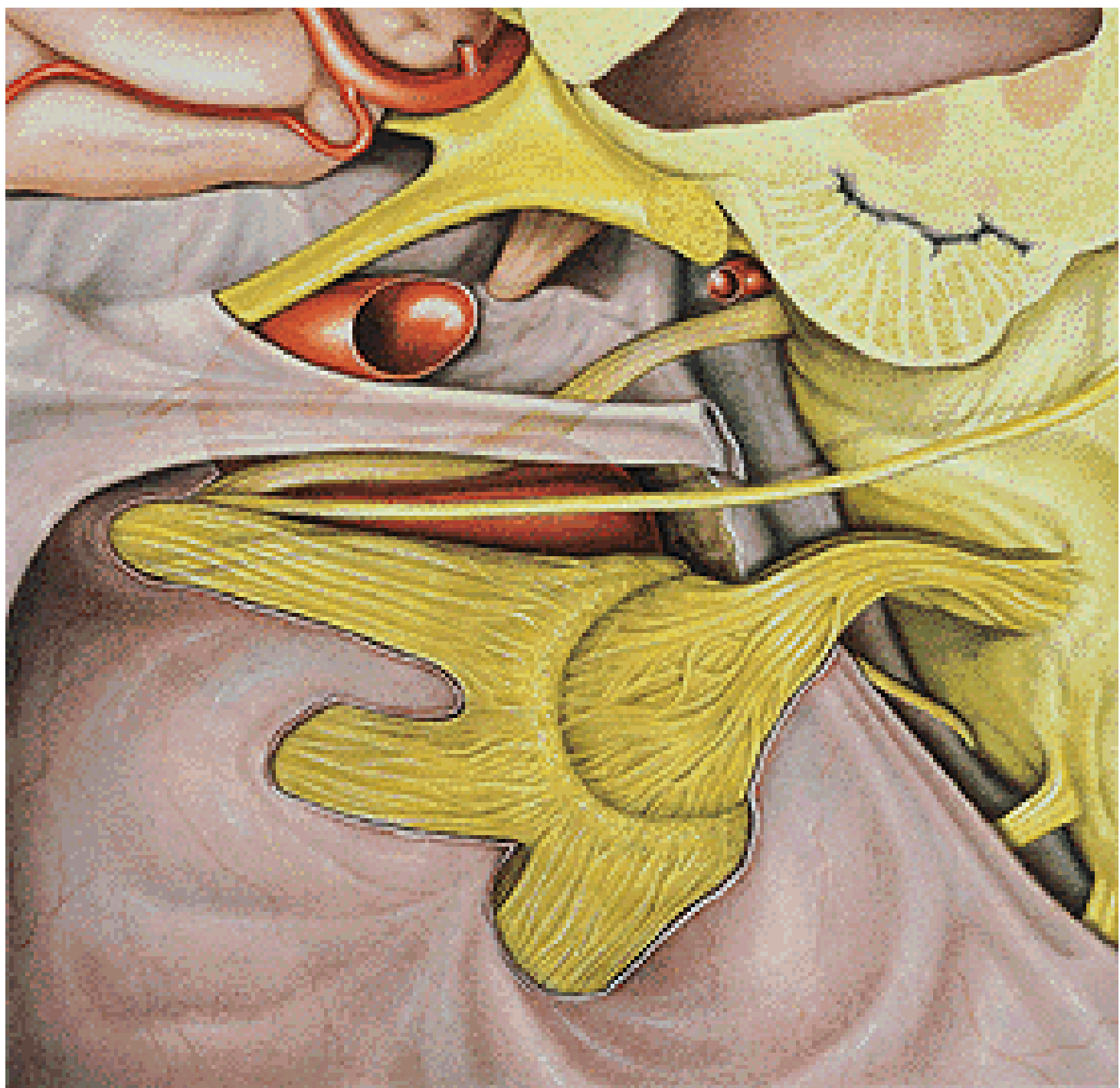
N. abducens

- m. rectus lateralis



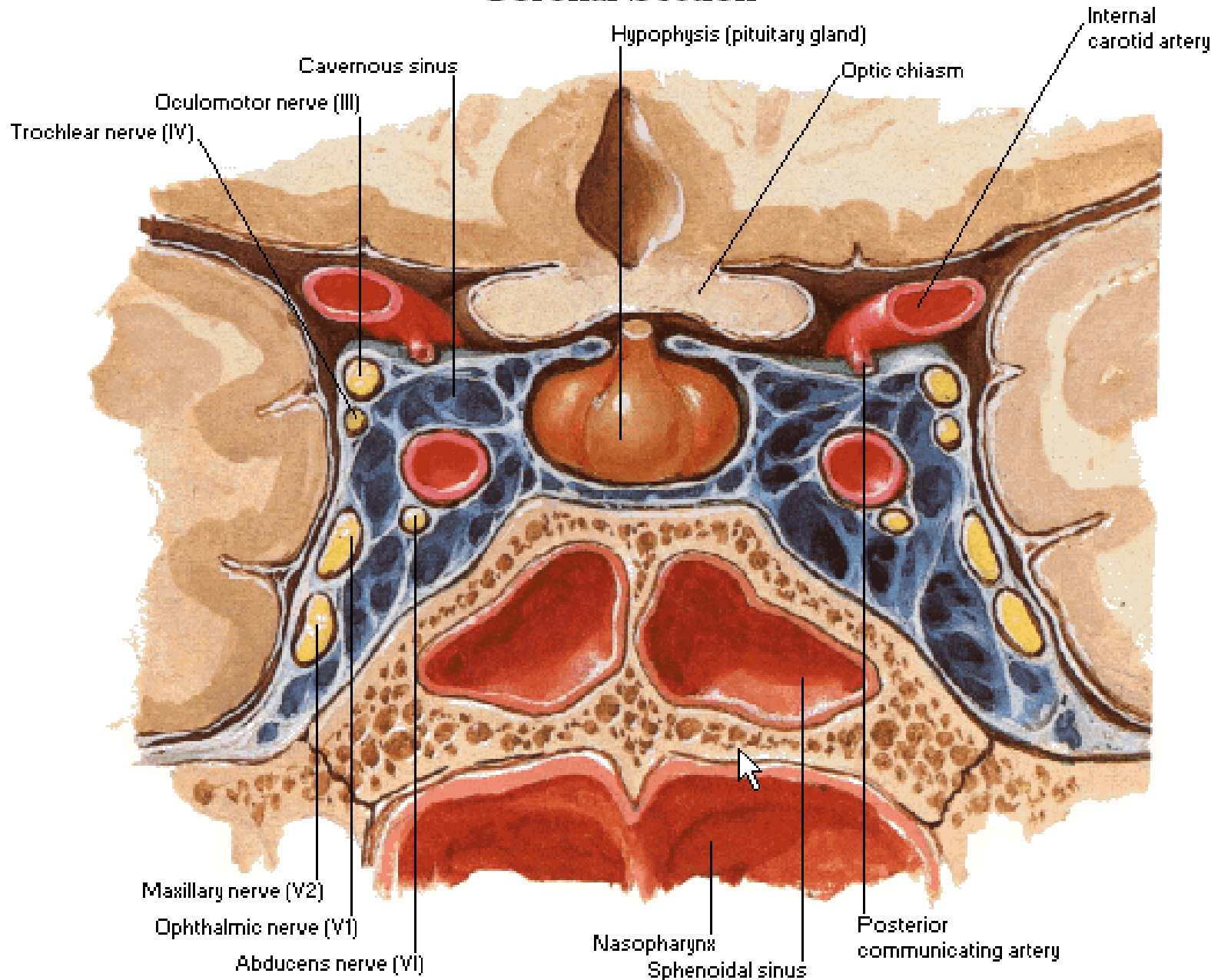
CN V



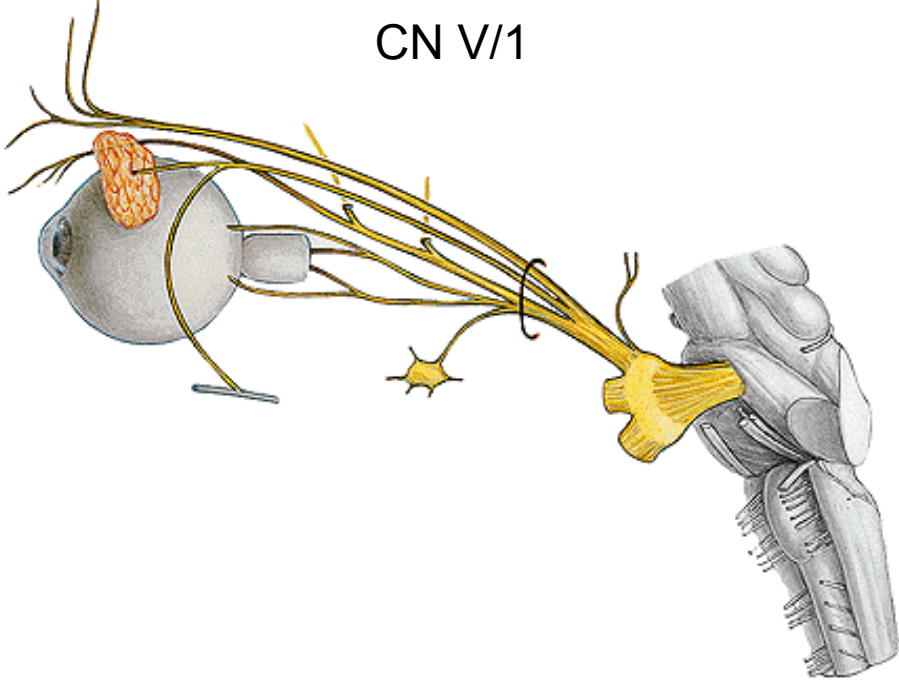


Cavernous Sinus

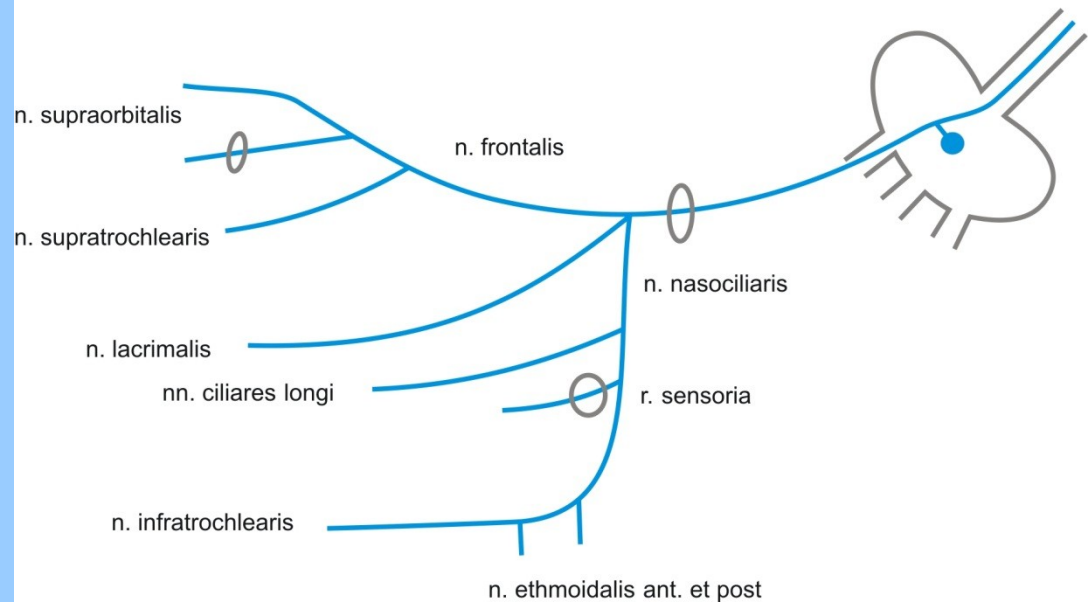
Coronal Section

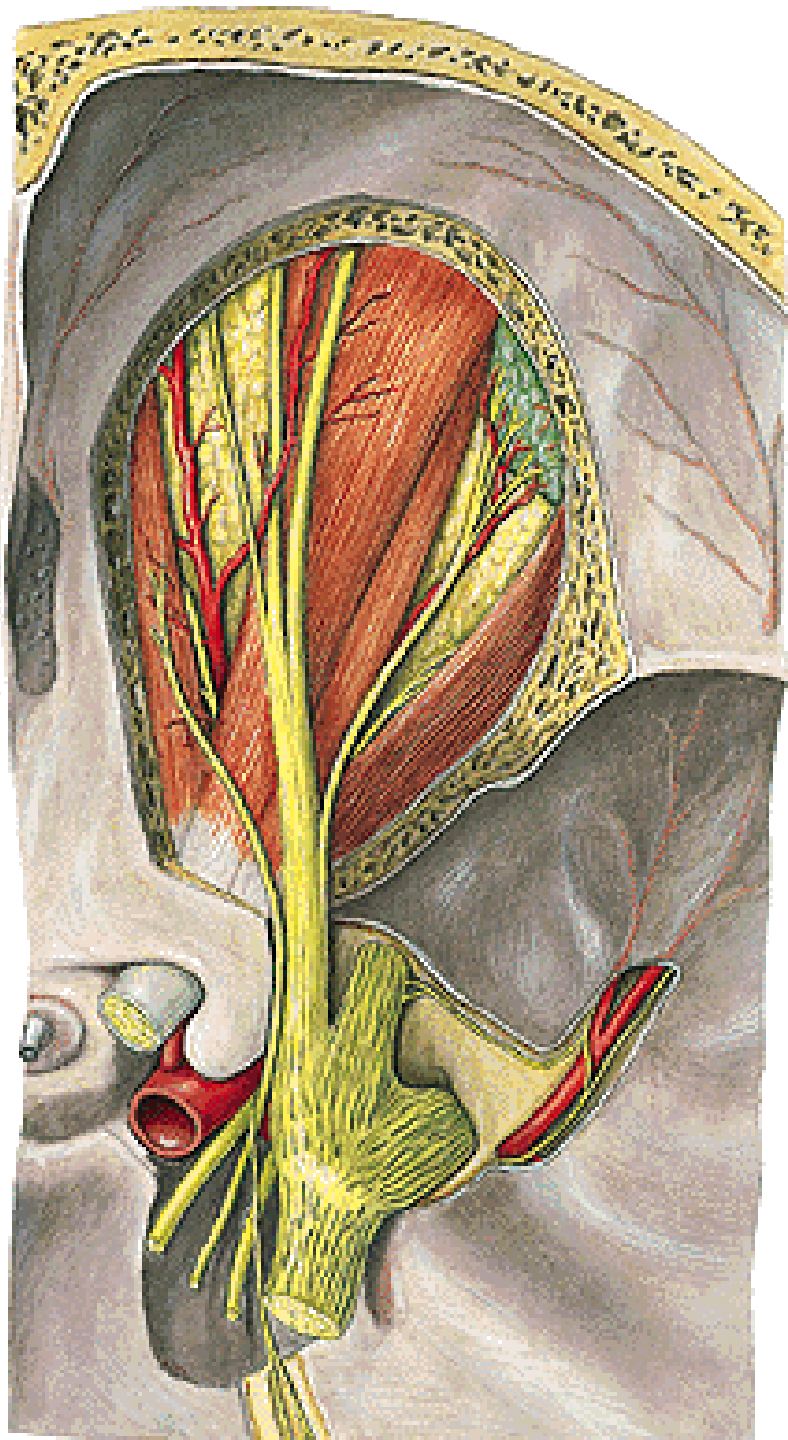


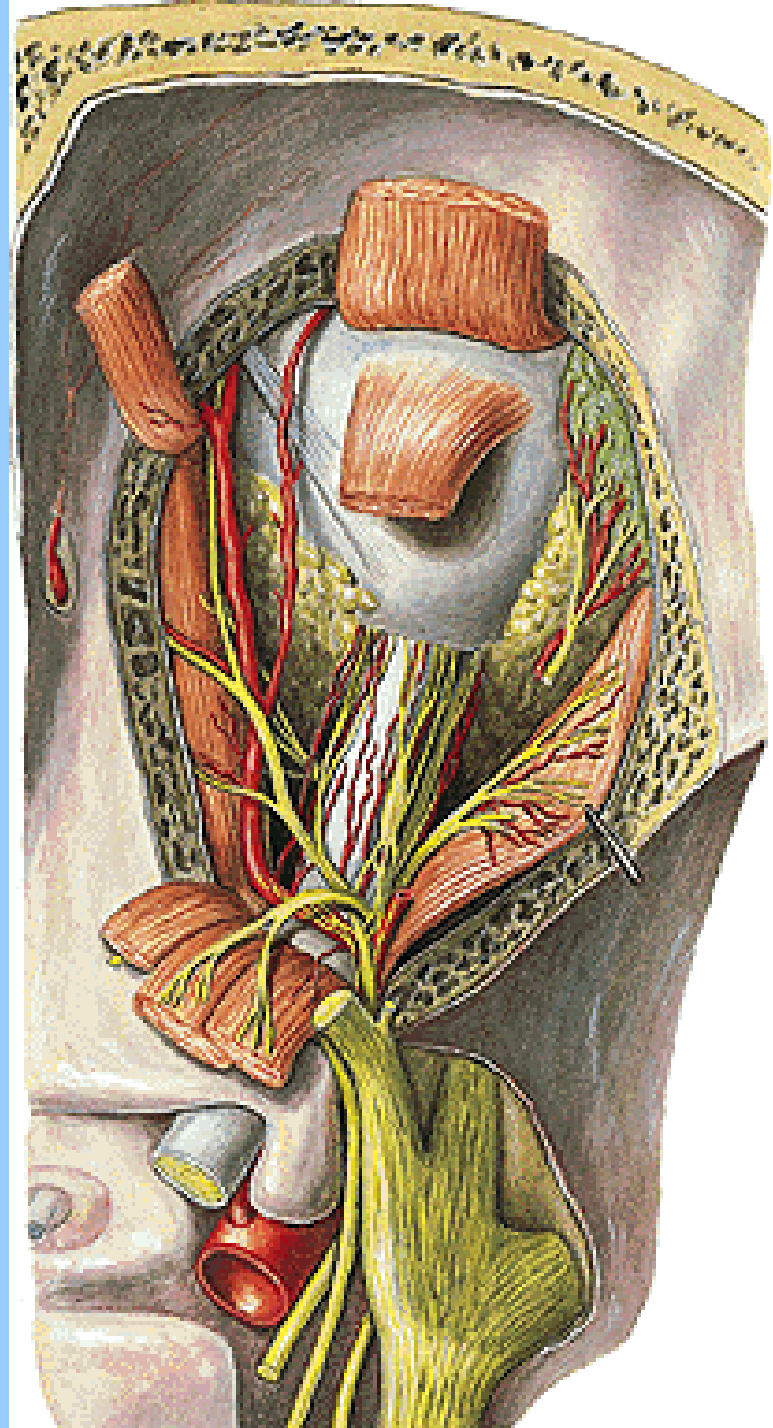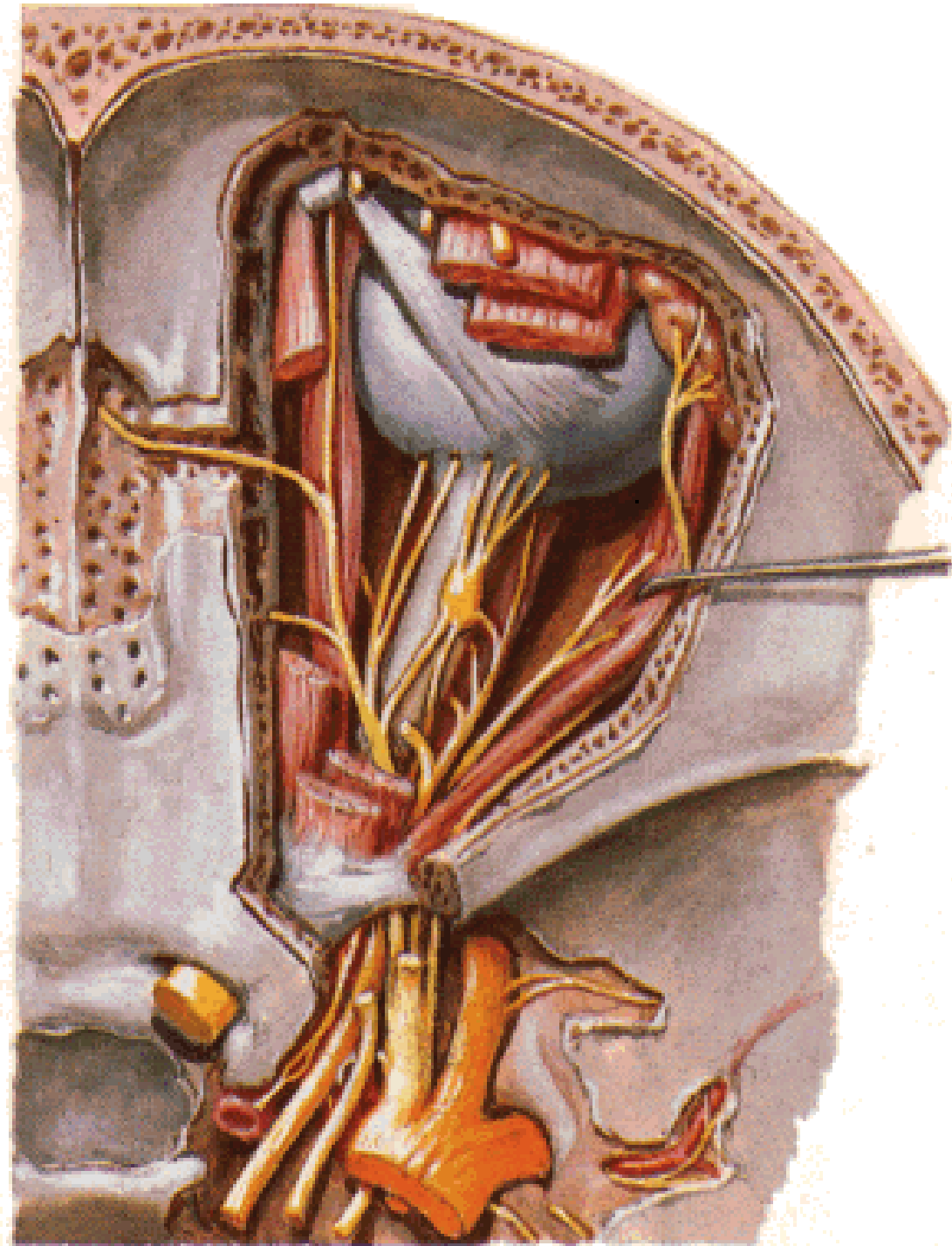
CN V/1



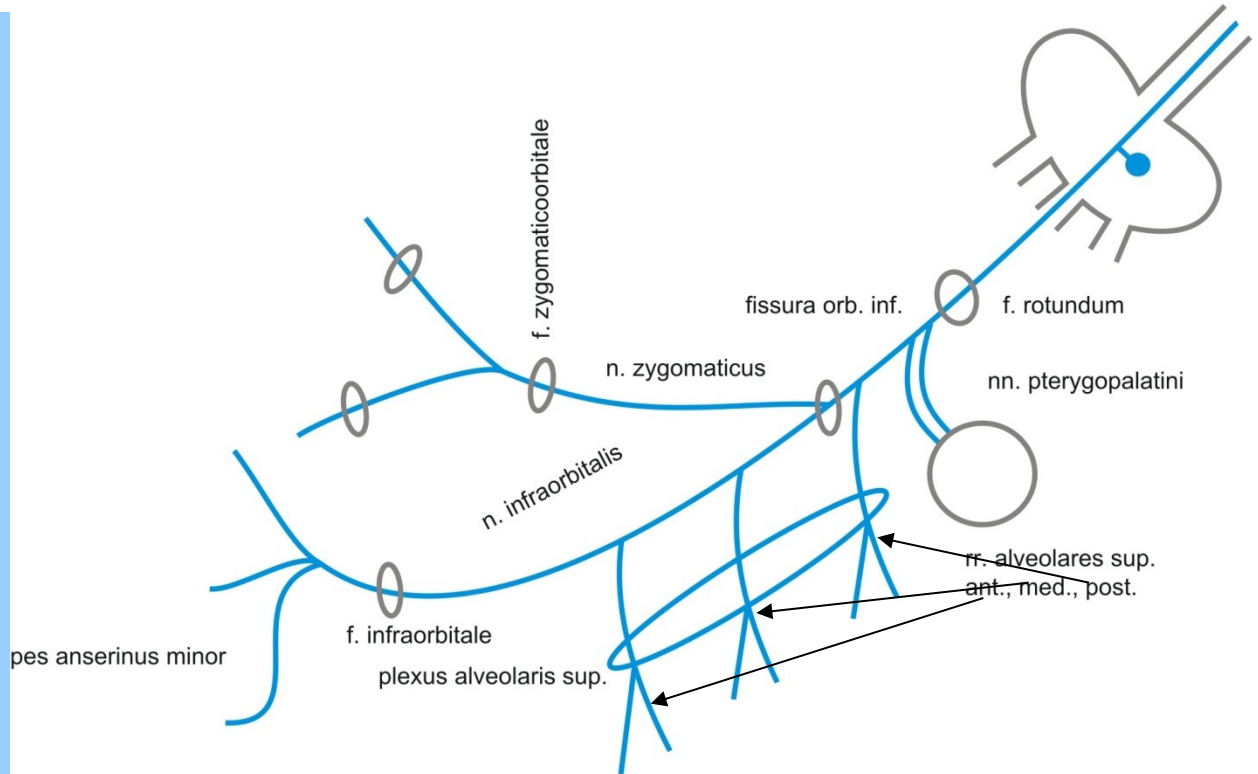
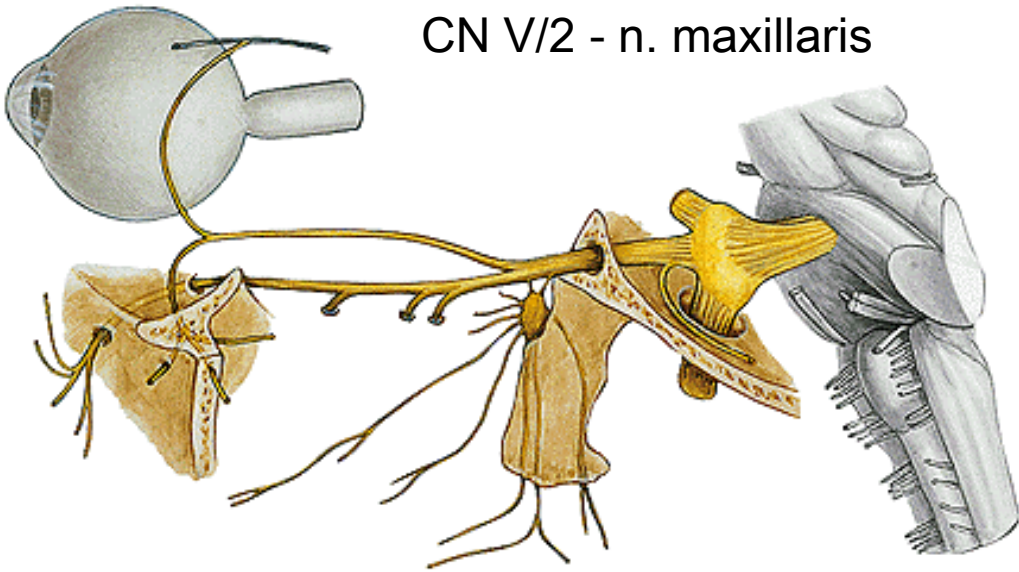
n. V/1 - n. ophthalmicus

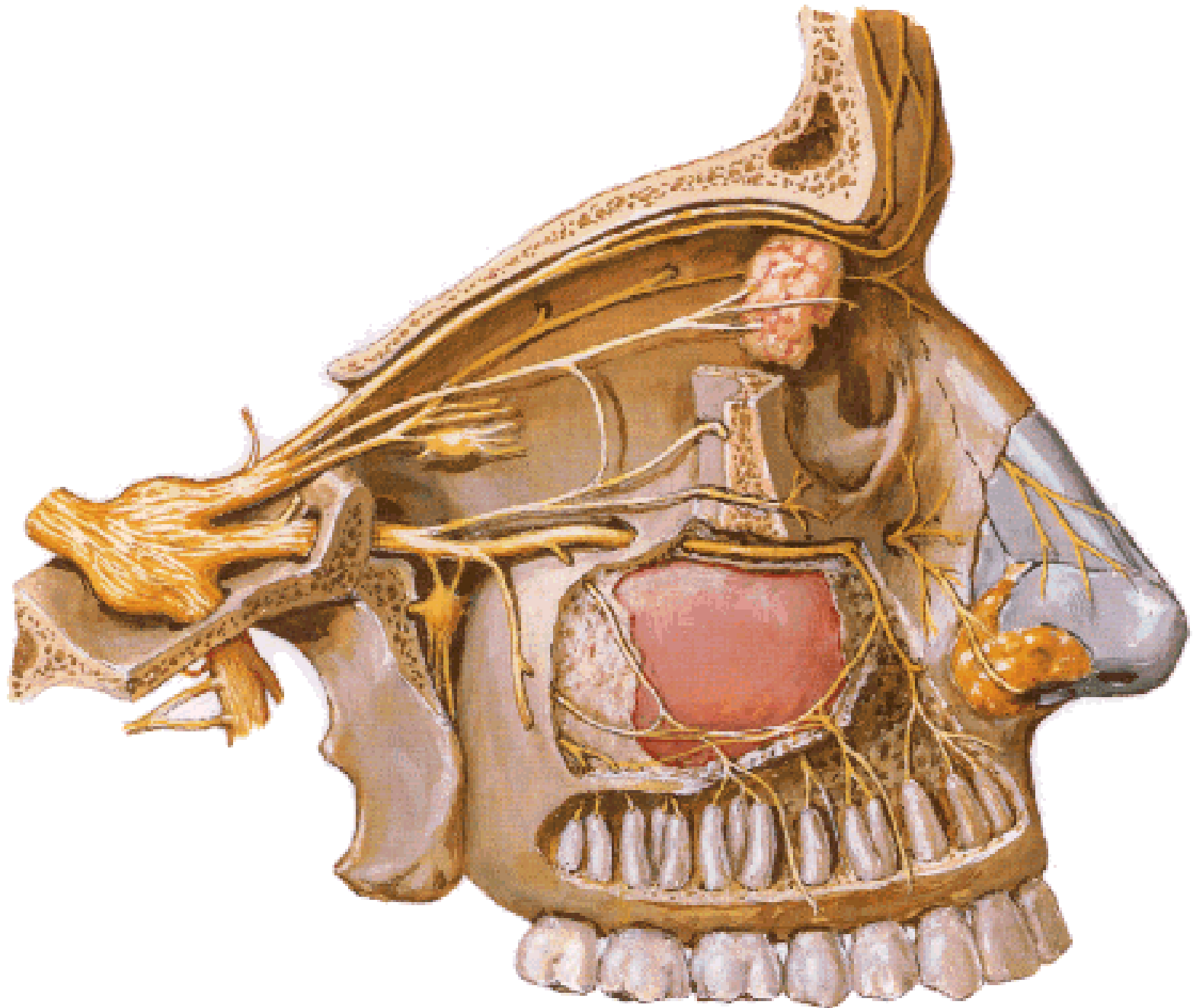




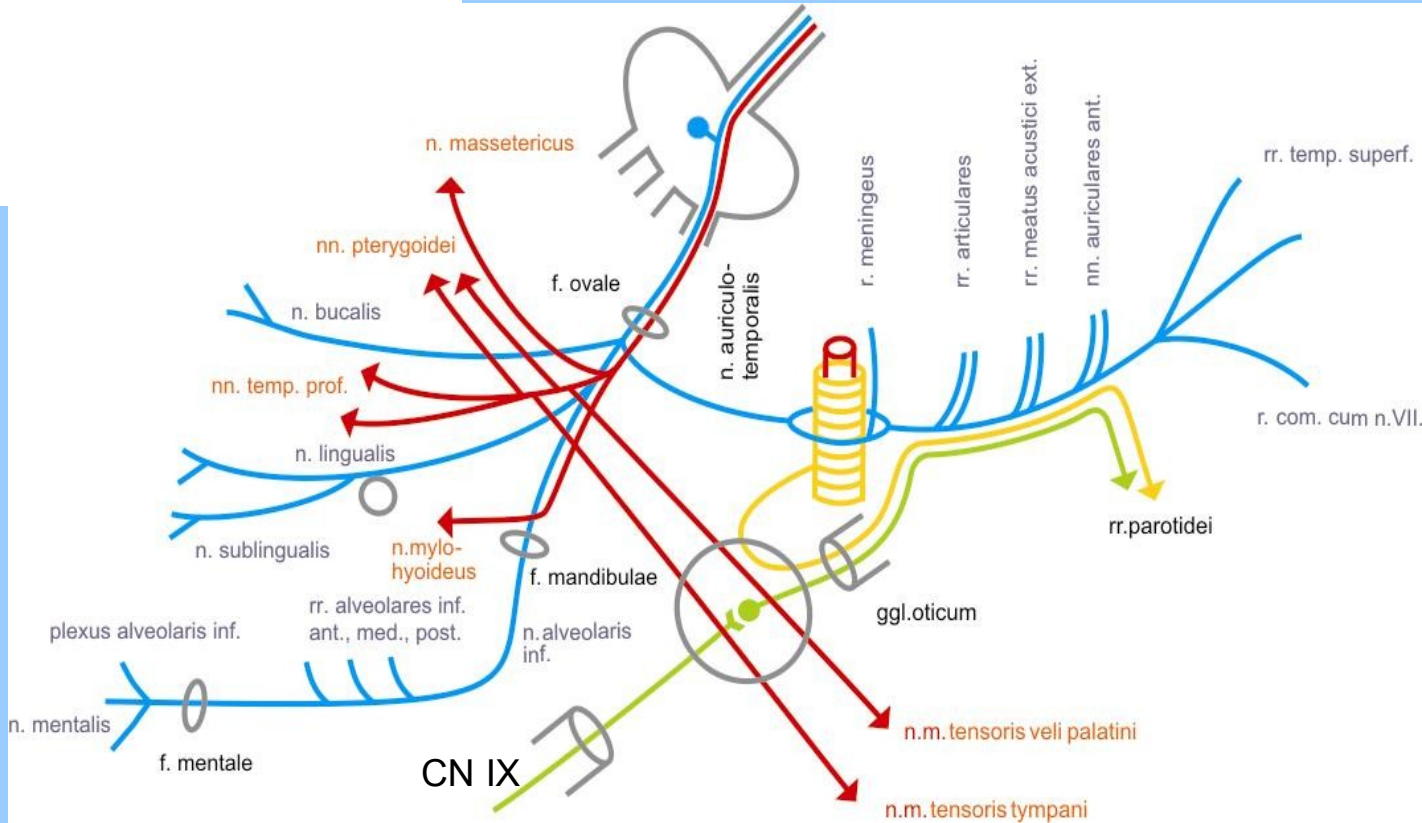
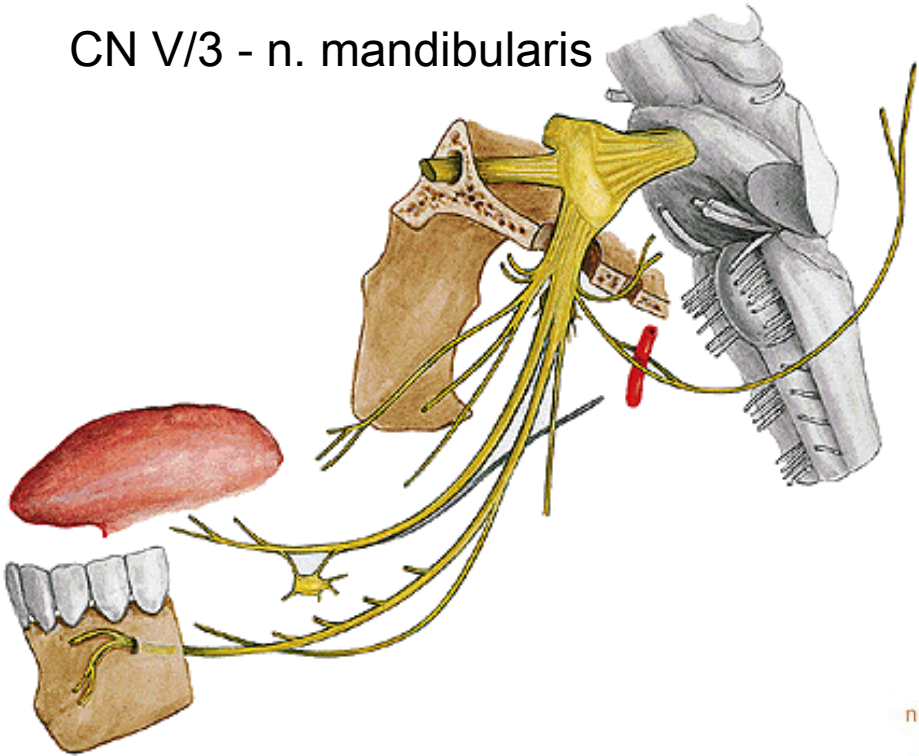


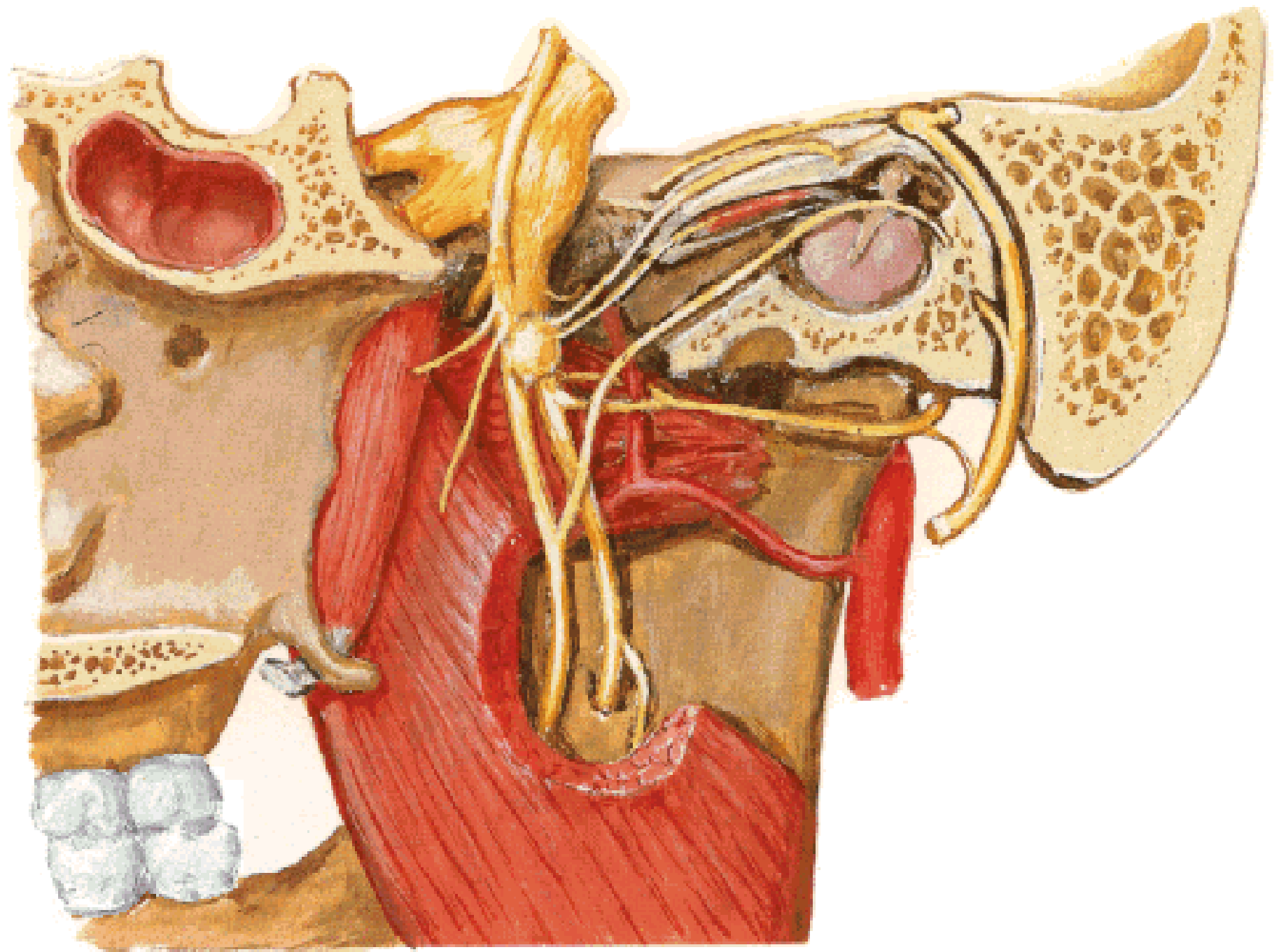
CN V/2 - n. maxillaris

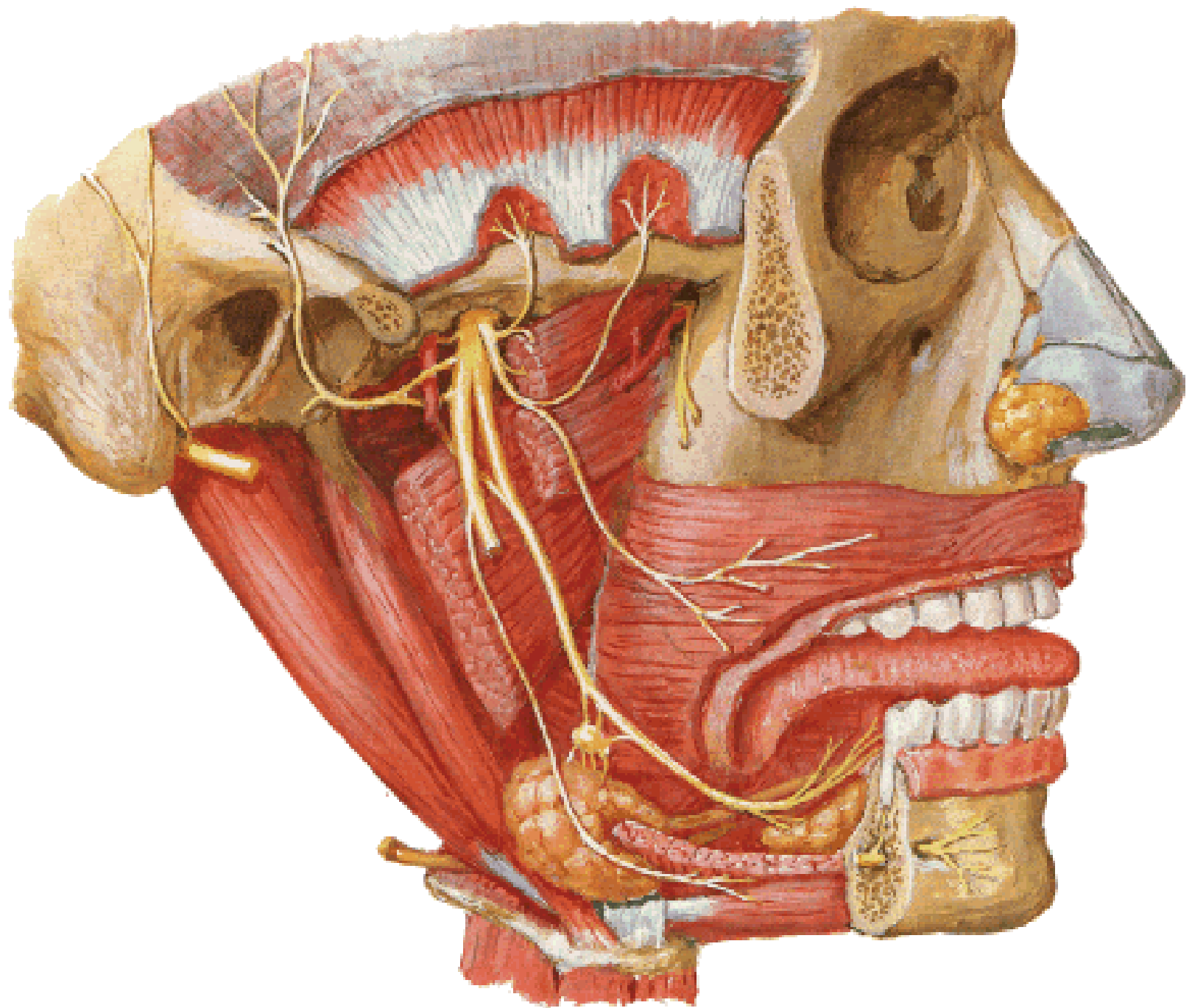


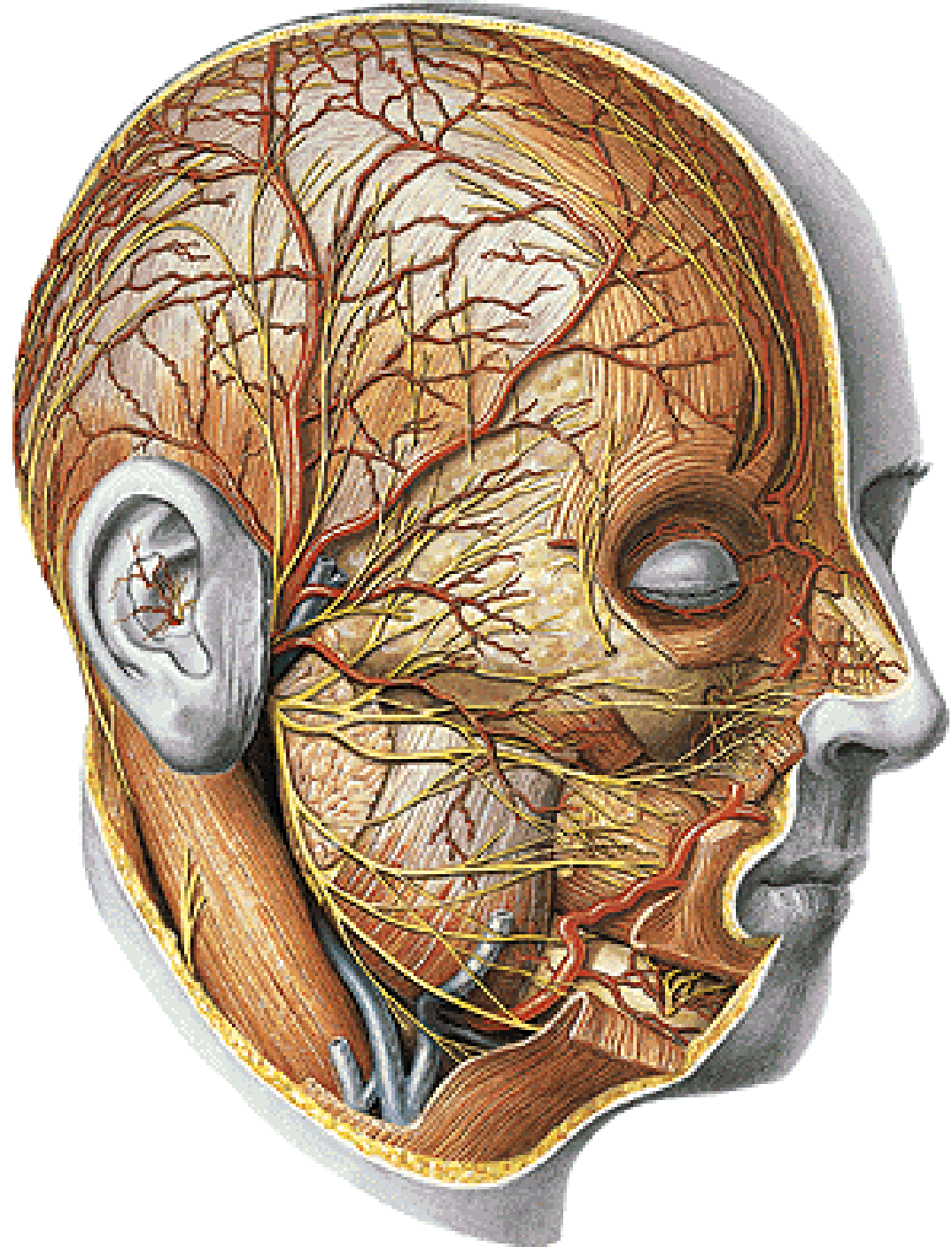


CN V/3 - n. mandibularis

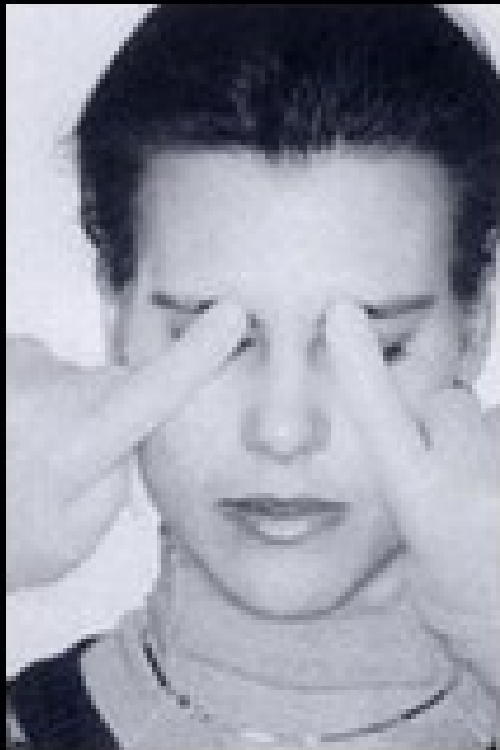


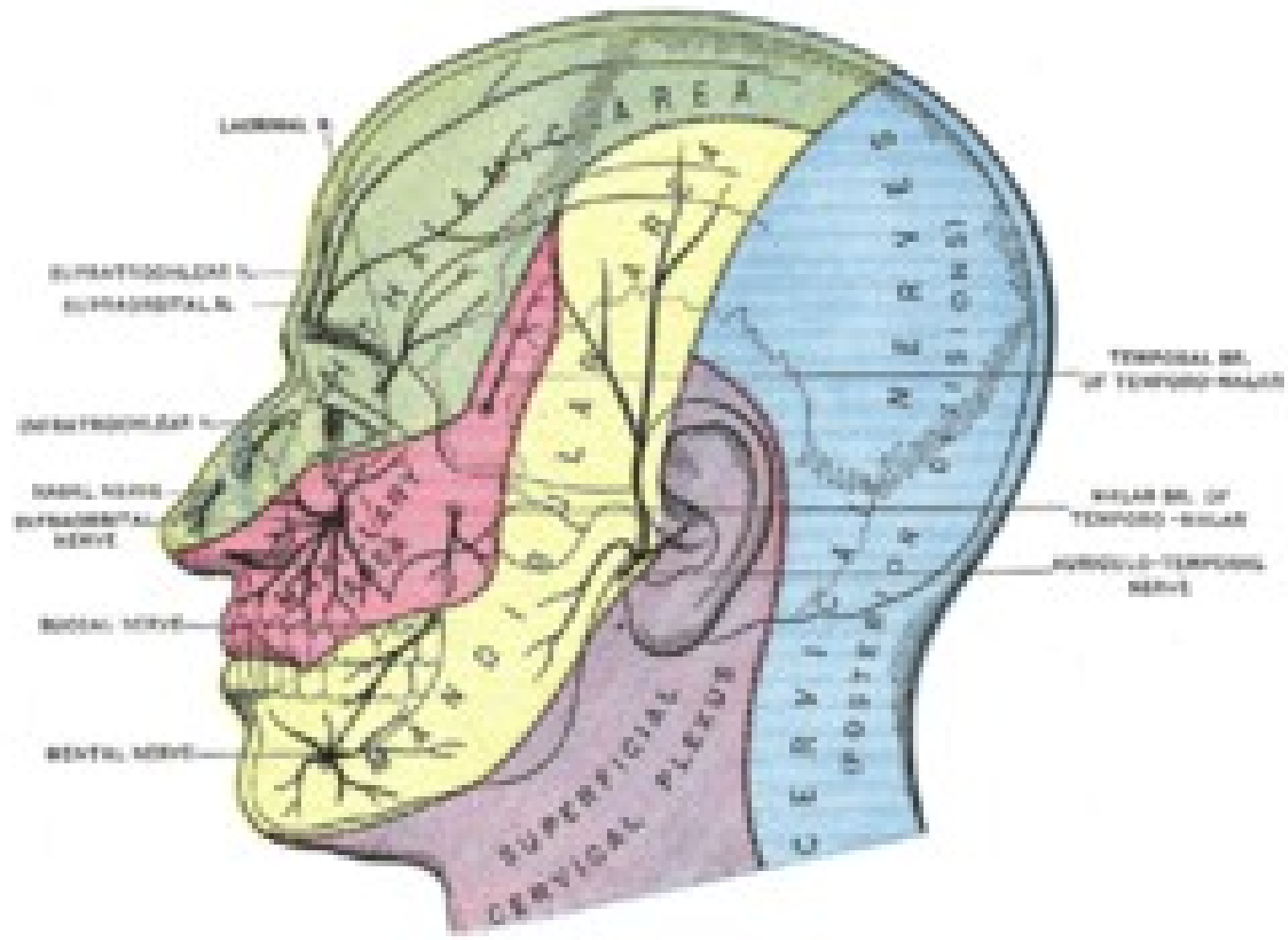




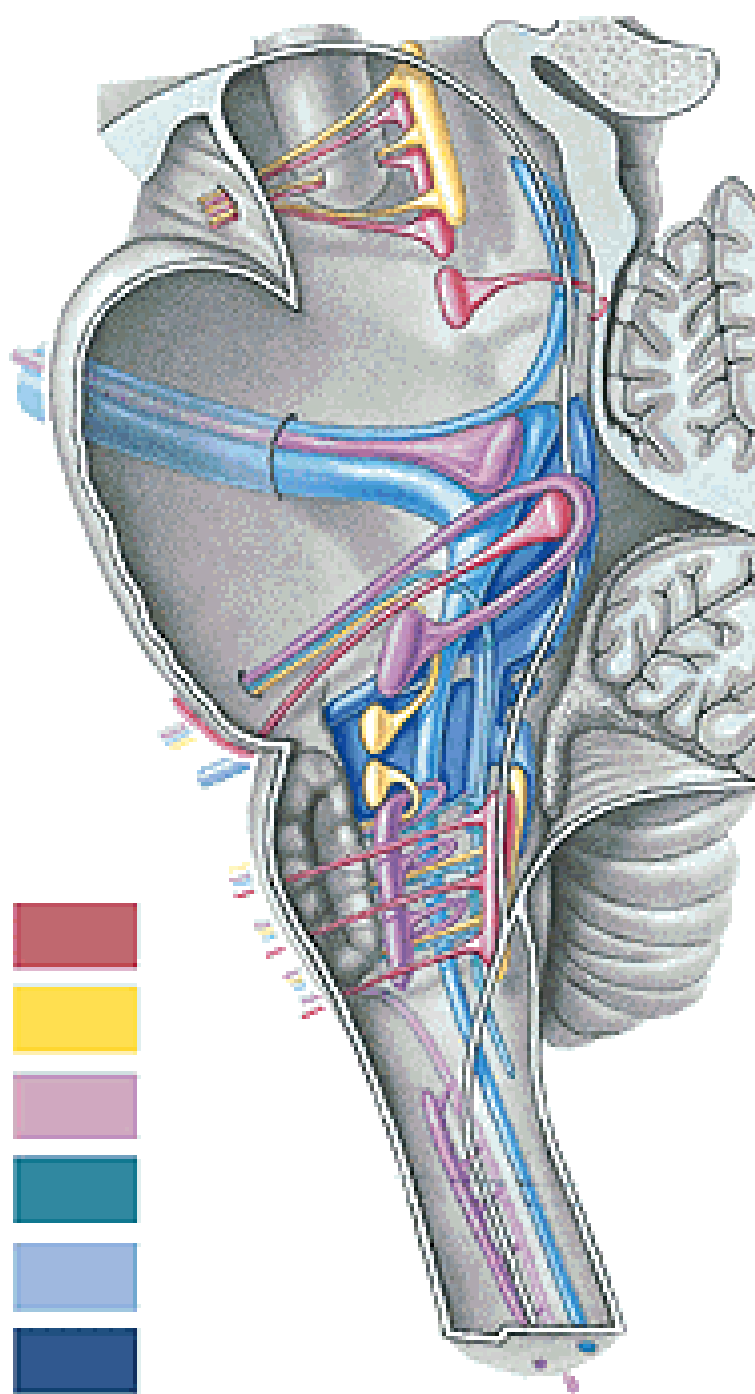


Výstupy 3 hlavních větví n. V.





CN VII




SOMATOMOTOR



VISCEROMOTOR



BRANCHIOMOTOR



SOMATOSENSORY



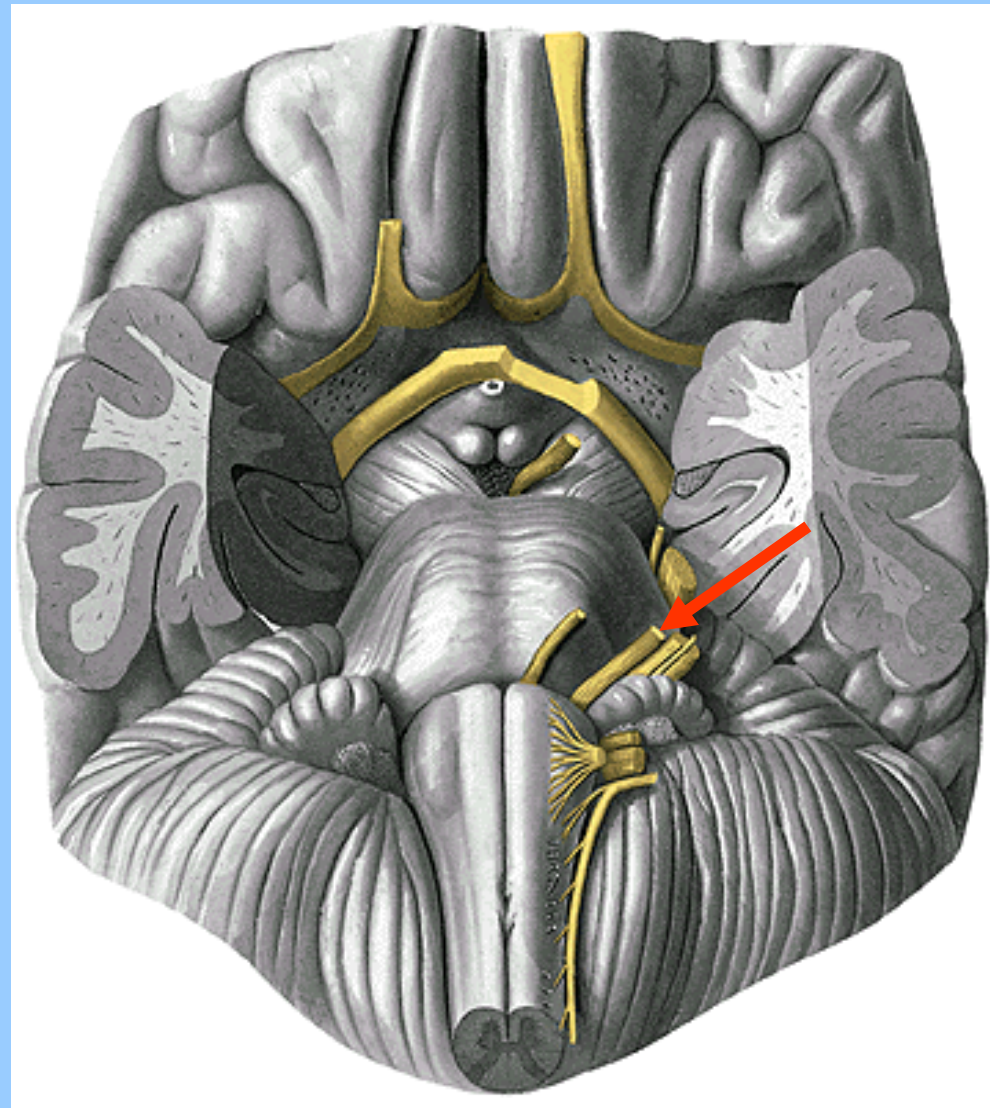
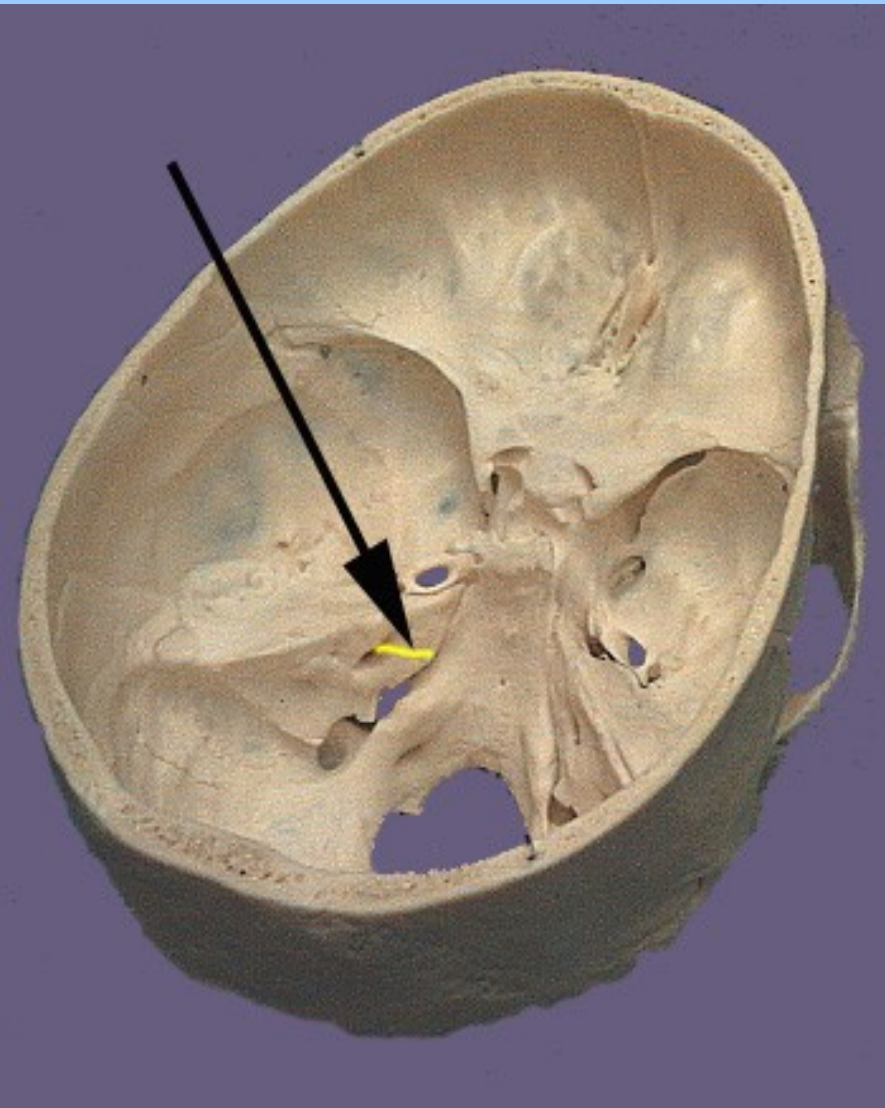
VISCEROSENSORY

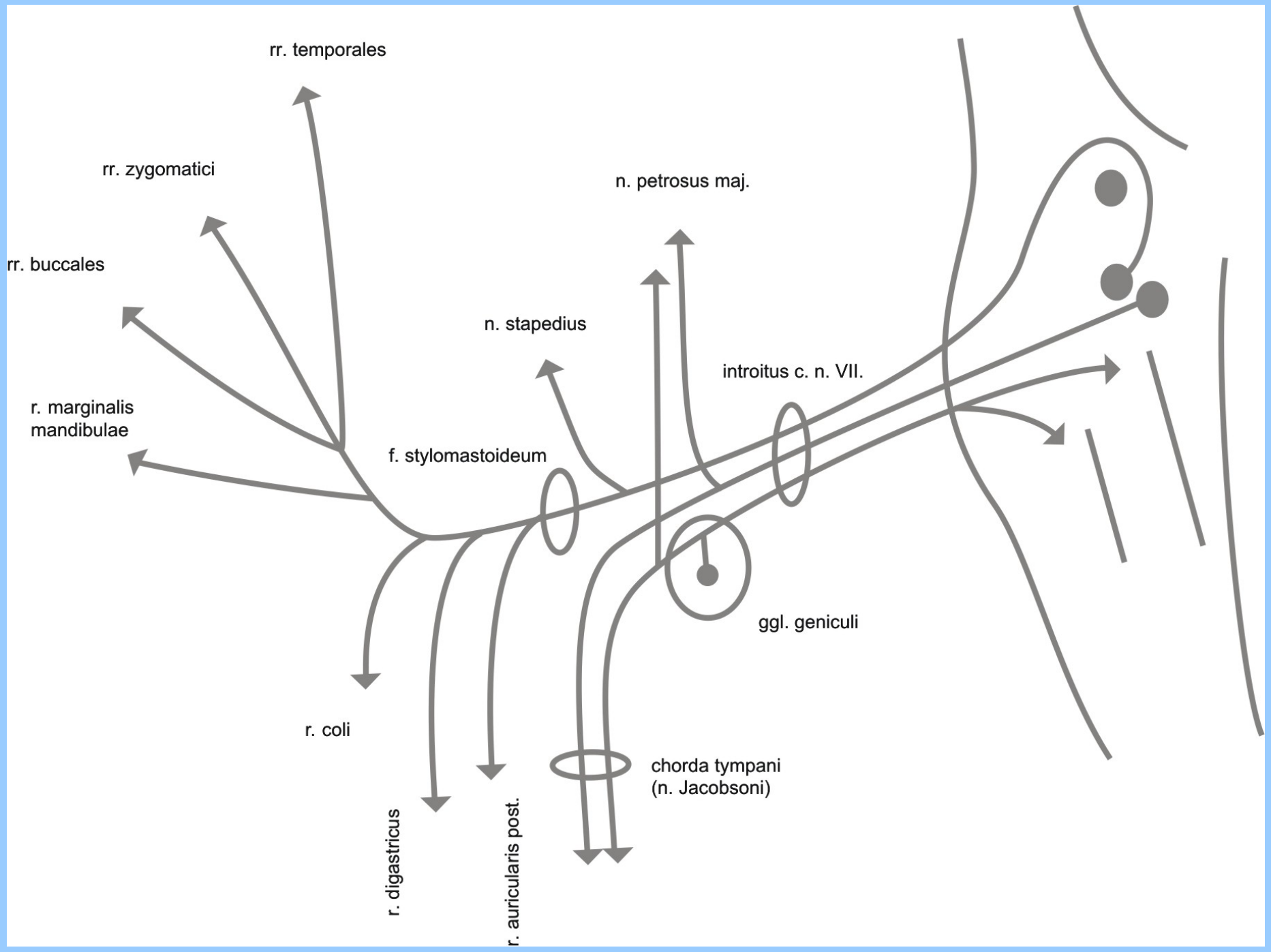


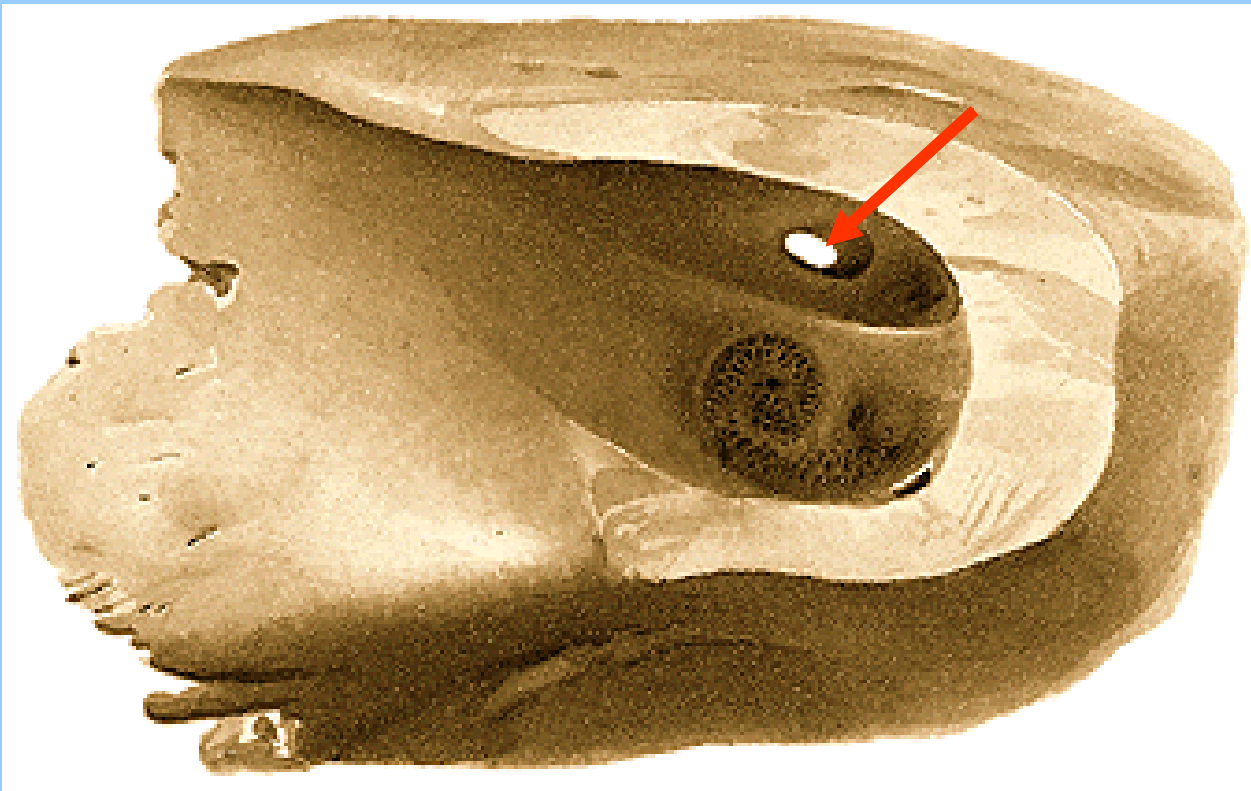
SPECIAL SENSORY



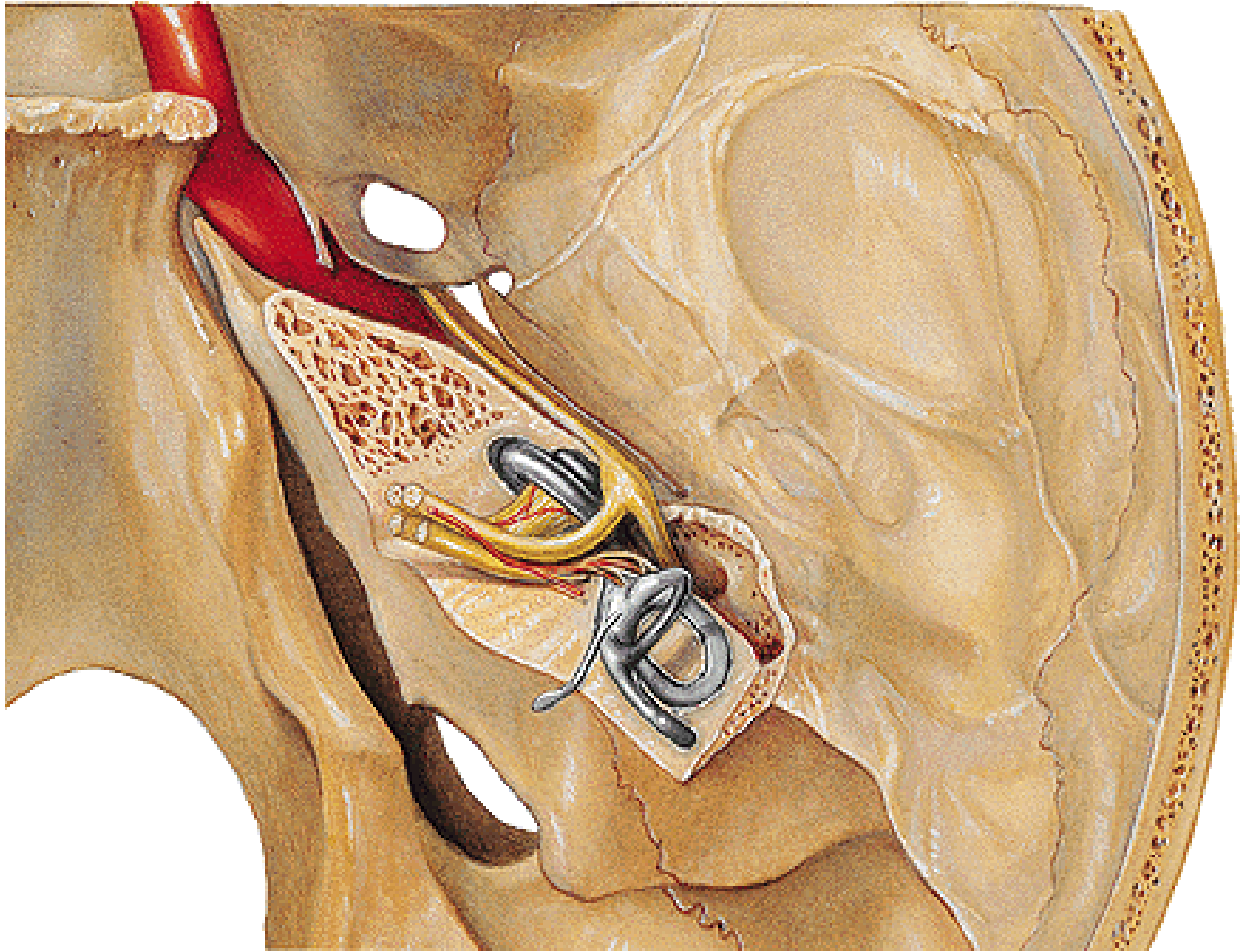
CN VII

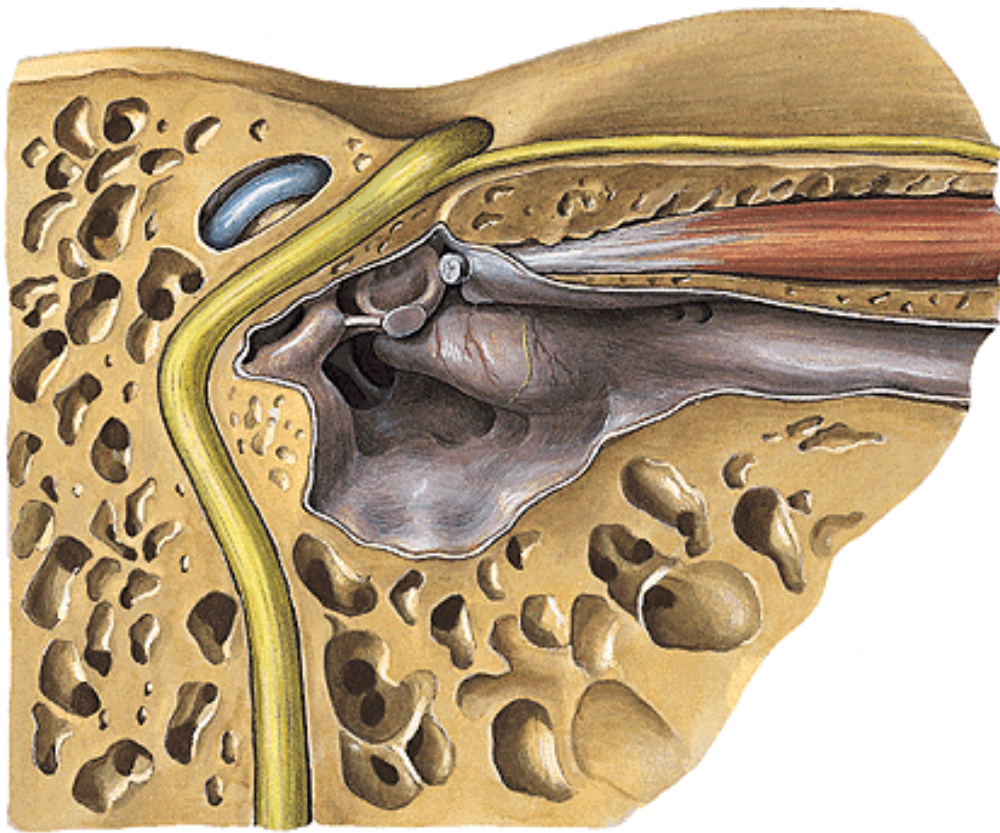






Fundus meatus acustici interni – Introitus canalis CN VII



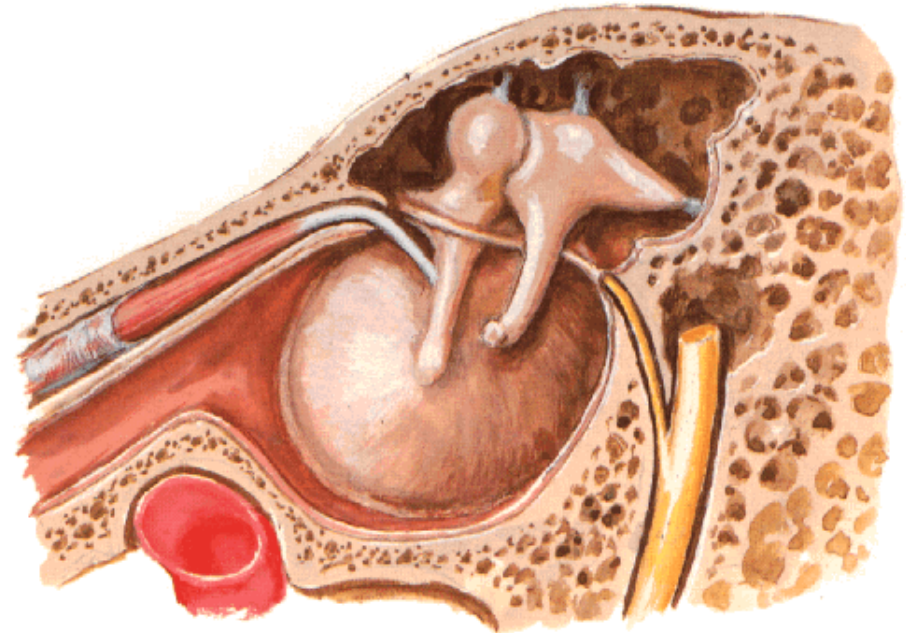


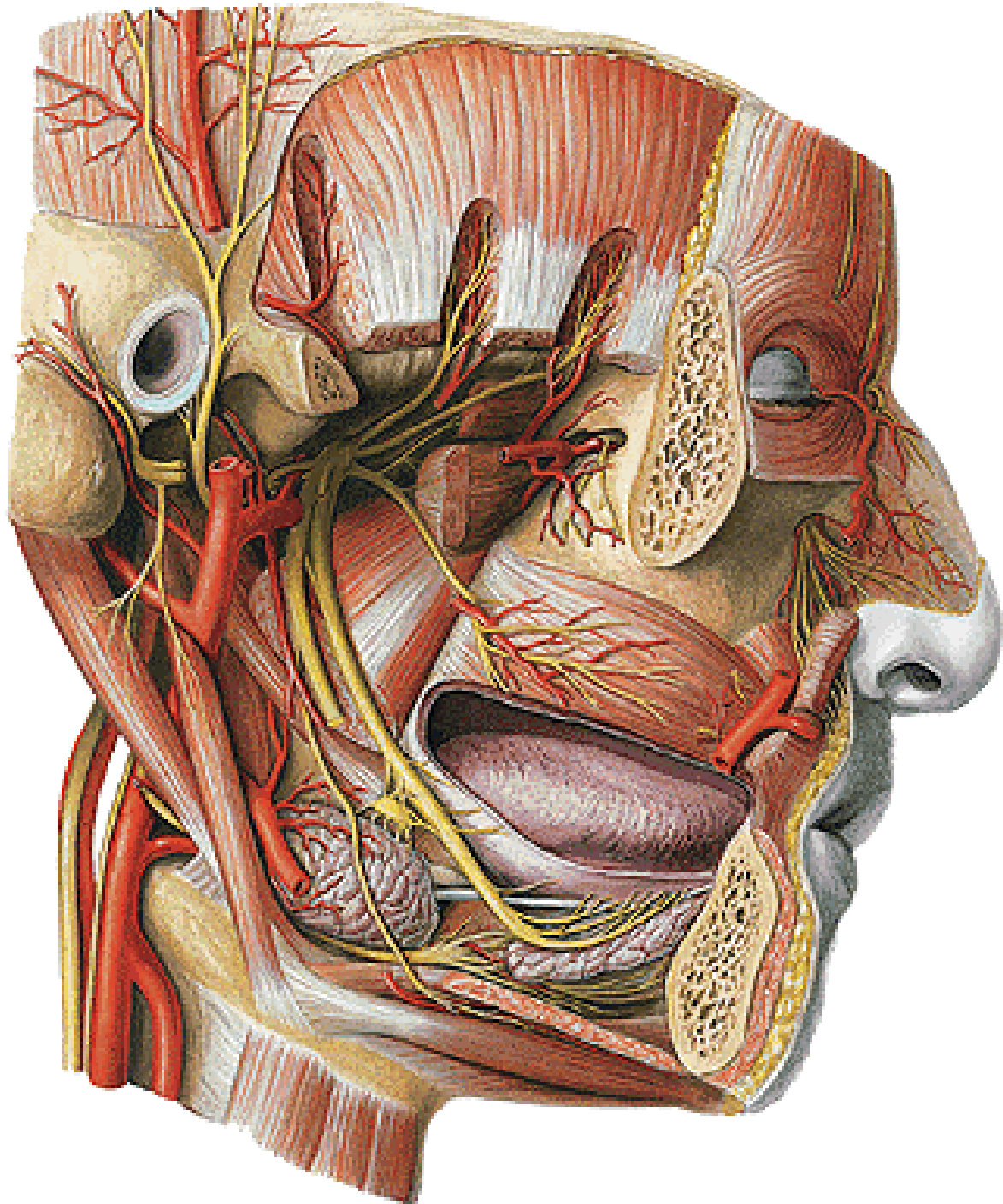
Ggl. geniculi

- n. petrosus major

Tympanic Cavity - Lateral Wall
Medial View

Chorda tympani

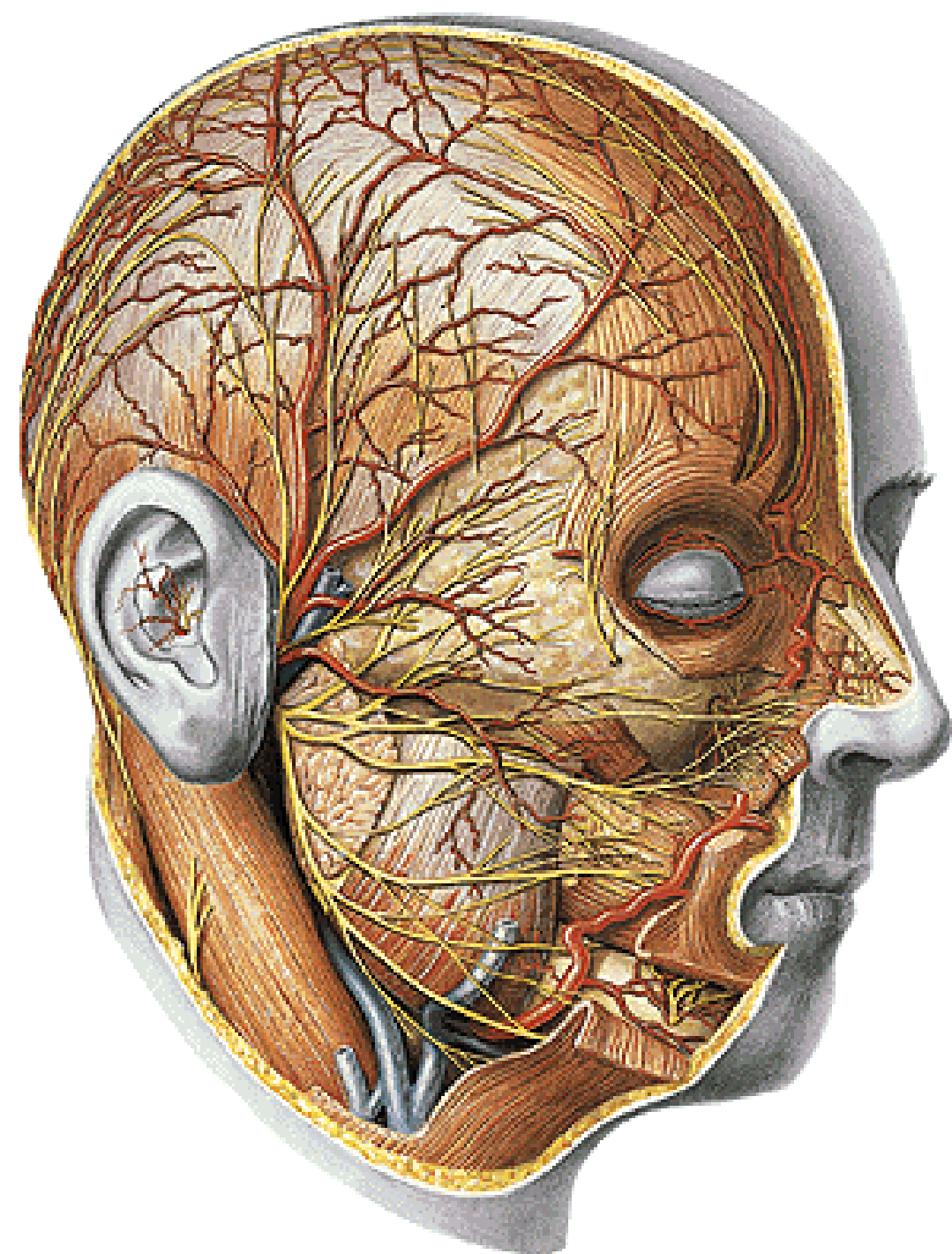




R. digastricus

R. stylohyoideus

N. auricularis post.



Plexus parotideus:

rr. temporales

rr. zygomatici

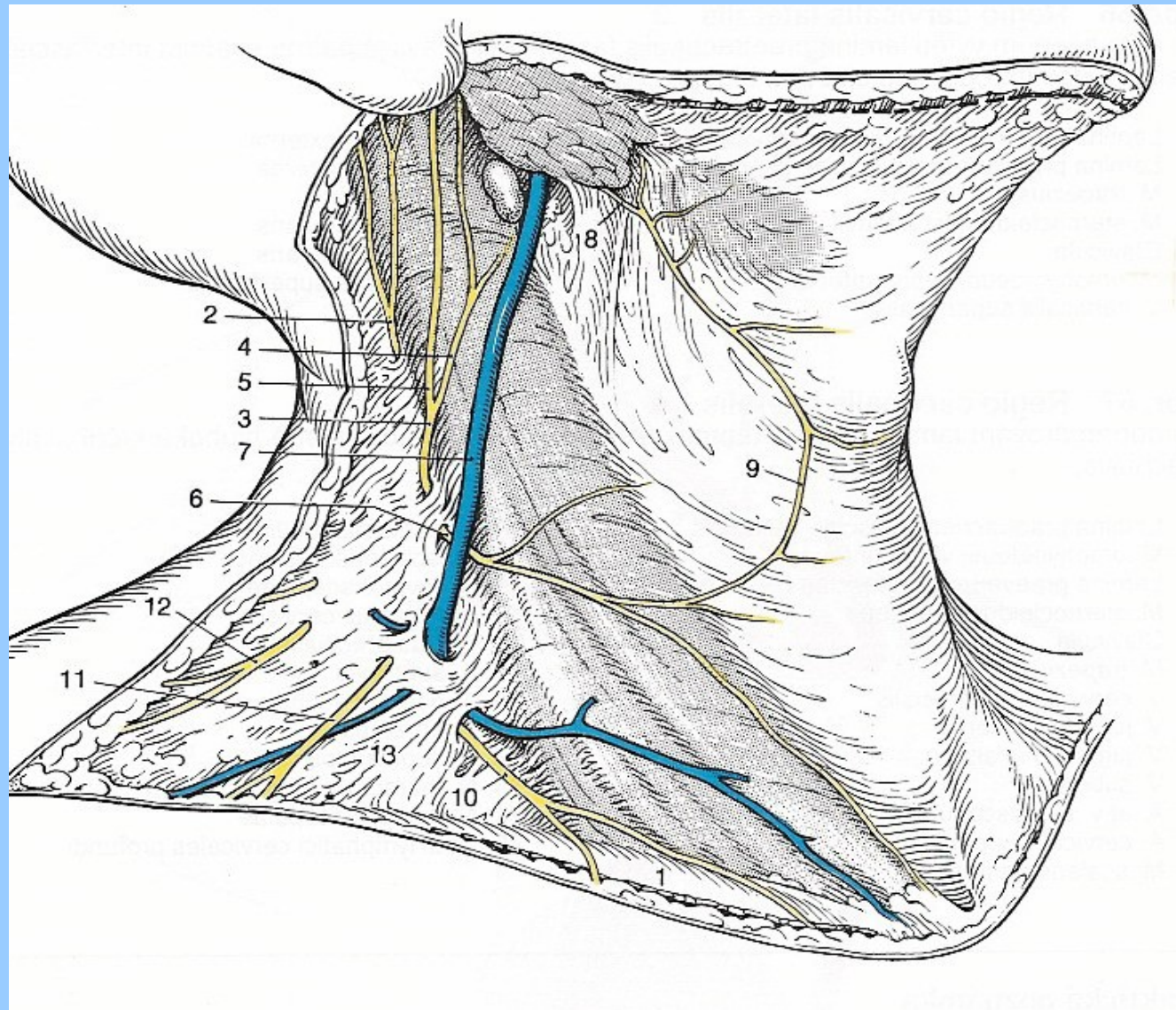
rr. buccales

r. marginalis mandibulae

r. colli

ANSA CERVICALIS SPF.

R. COLLI N. FACIALIS - N. TRANSVERSUS COLLI



- Illustrations were copied from:
- **Atlas der Anatomie des Menschen/
Sobotta. Putz,R., und Pabst,R. 20.
Auflage. München: Urban &
Schwarzenberg, 1993**
- **Netter: Interactive Atlas of Human
Anatomy. Windows Version 2.0**