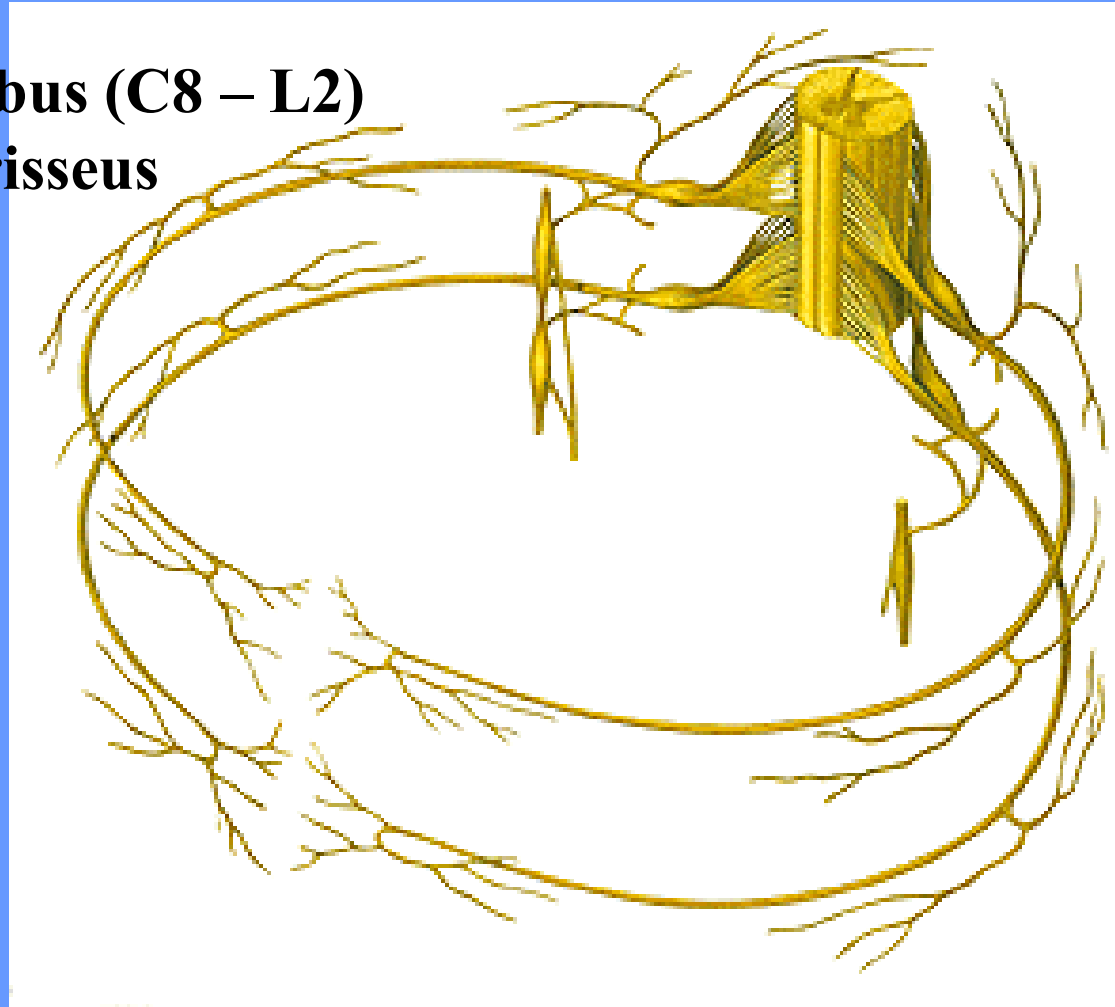


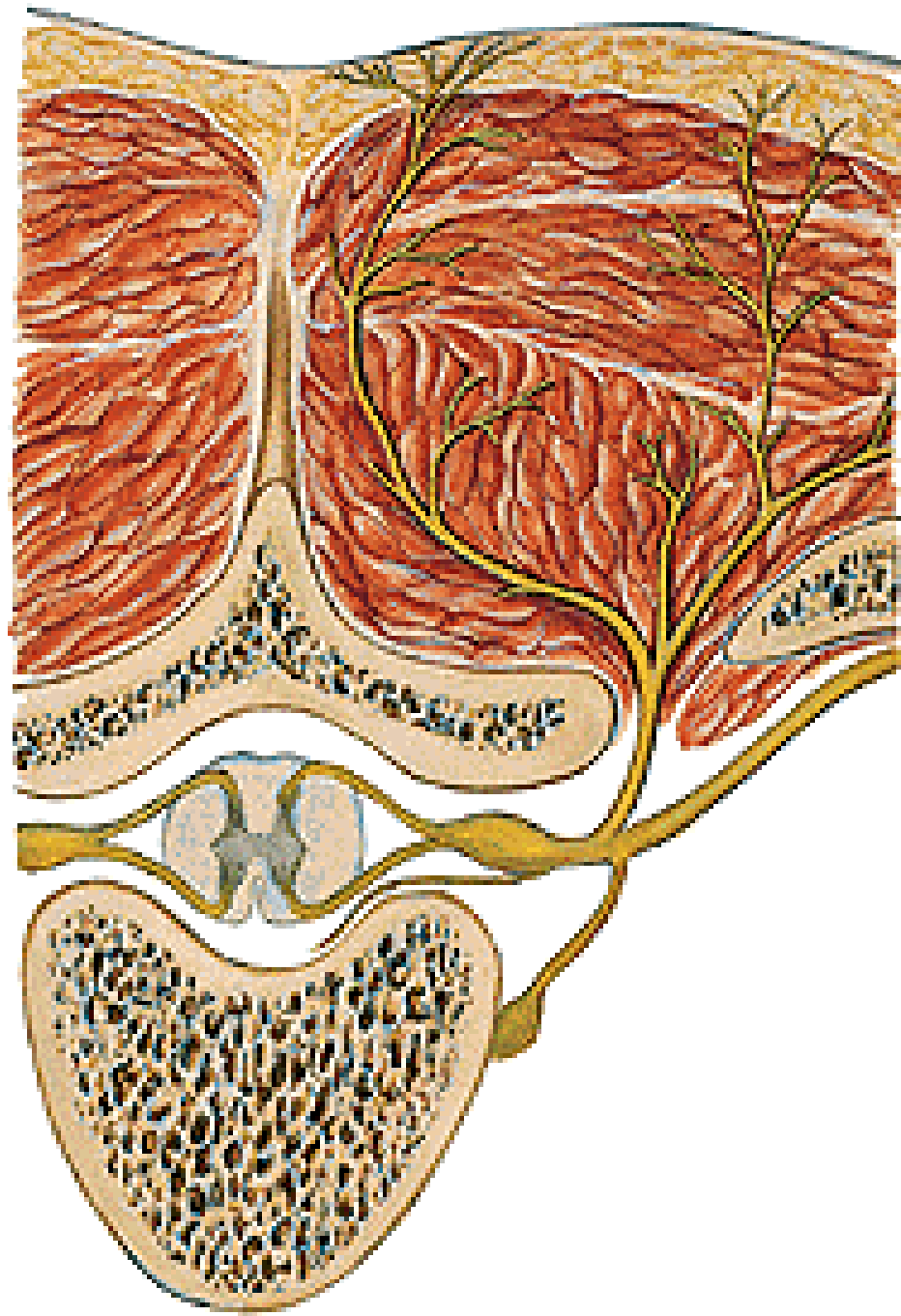
NERVUS SPINALIS

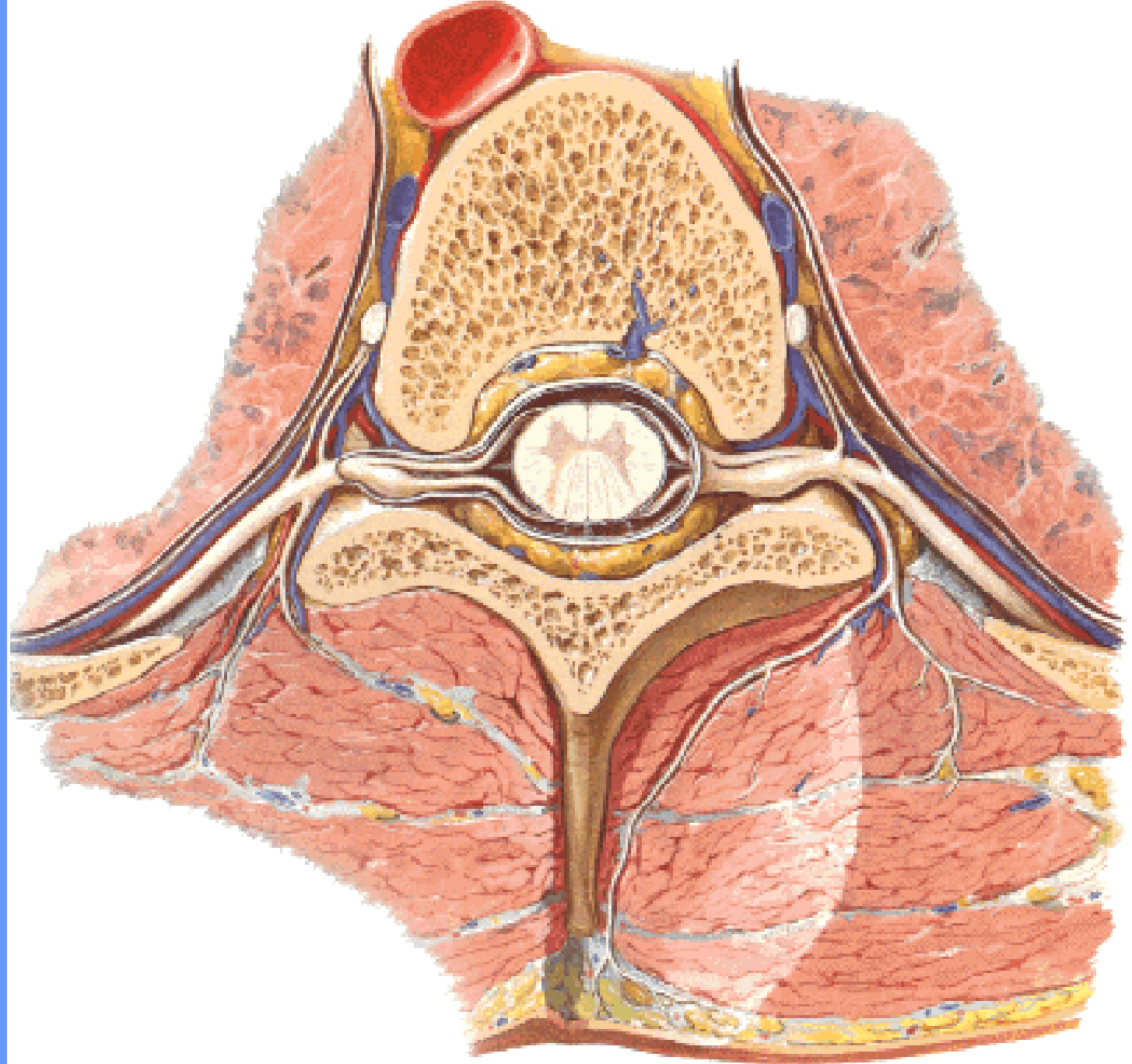
NERVUS SPINALIS:

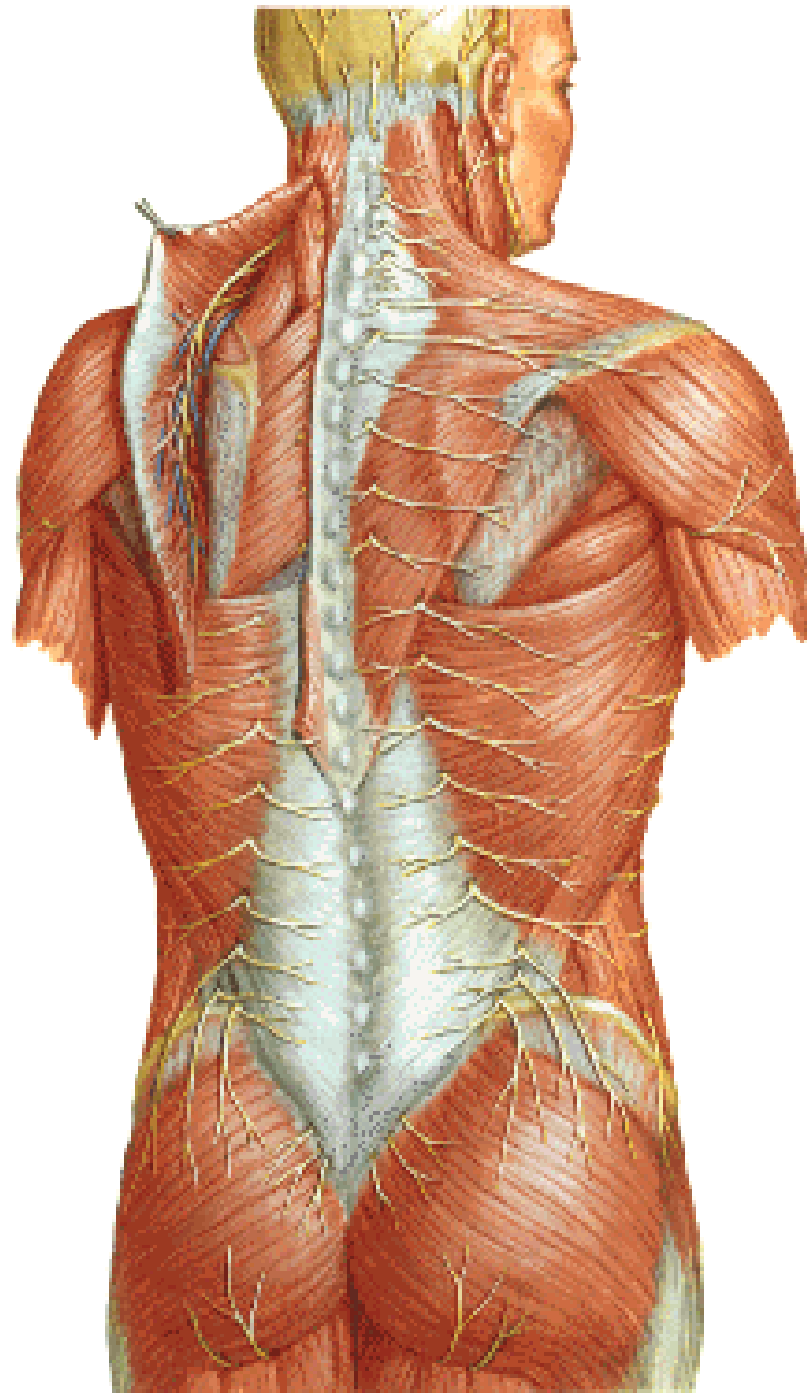
- **ramus meningeus**
- **ramus communicans albus (C8 – L2)**
- **ramus communicans griseus**
- **ramus dorsalis**
- **ramus ventralis**



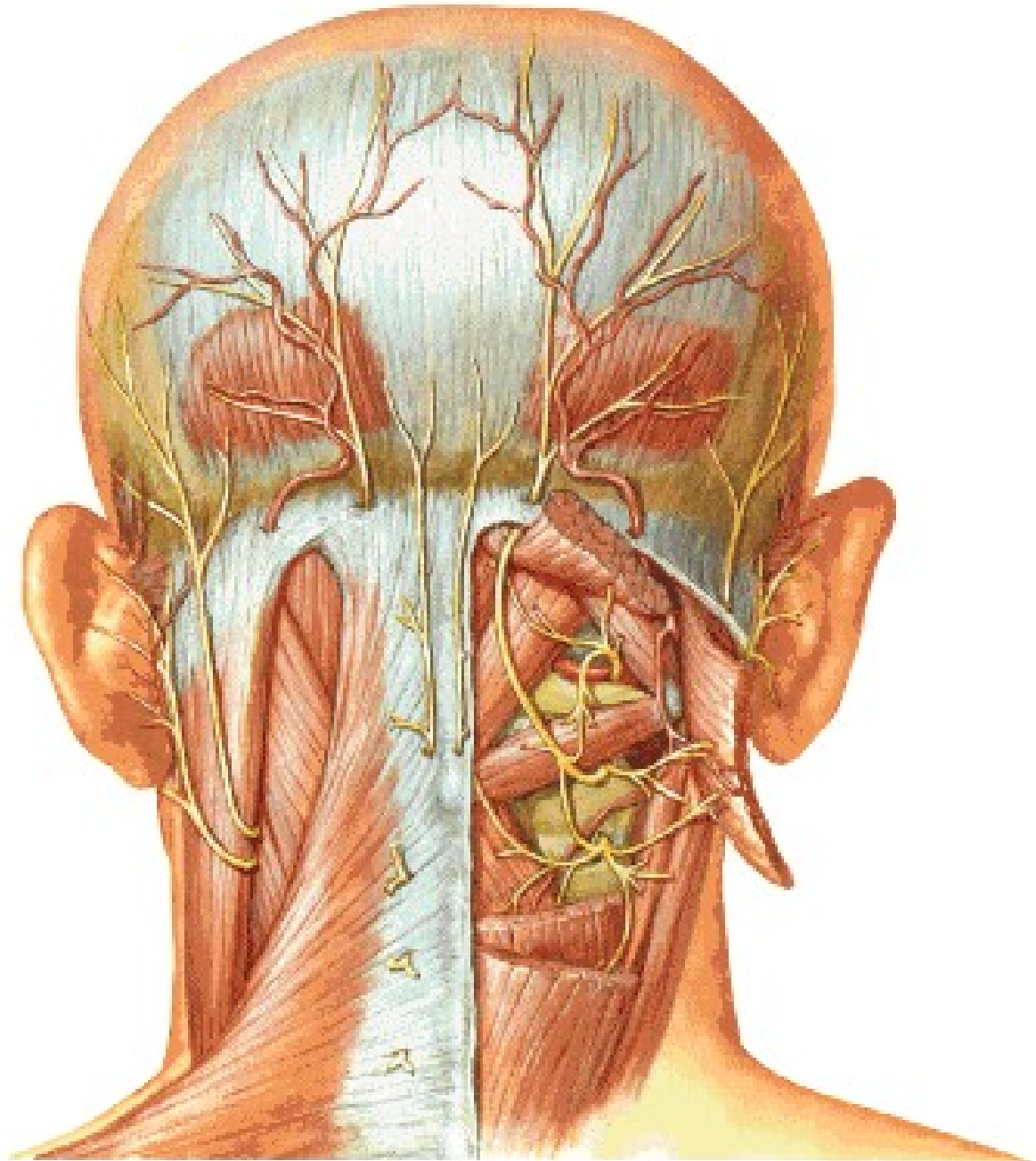
Truncus sympathicus



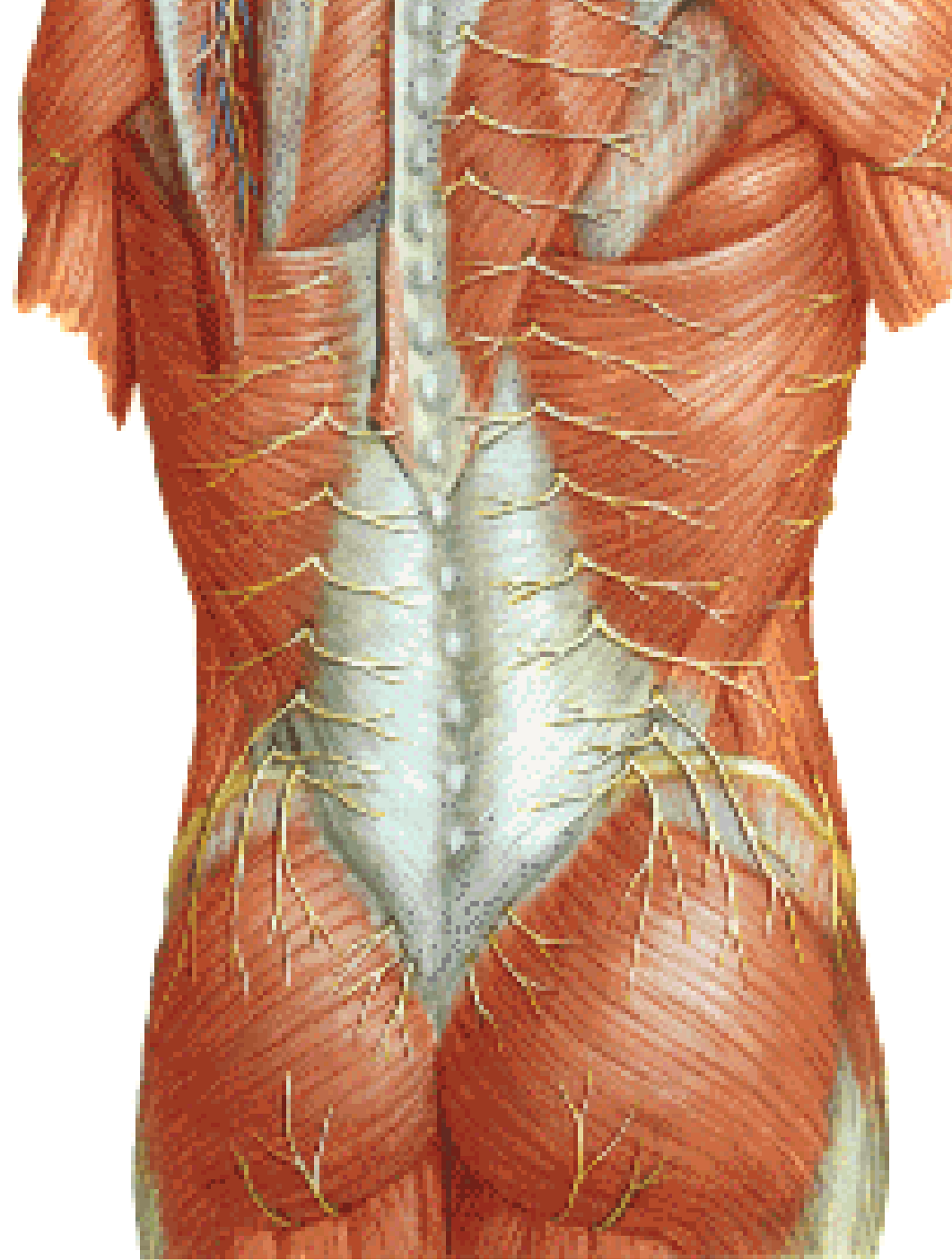




N. suboccipitalis
N. occipitalis major
N. occipitalis tertius



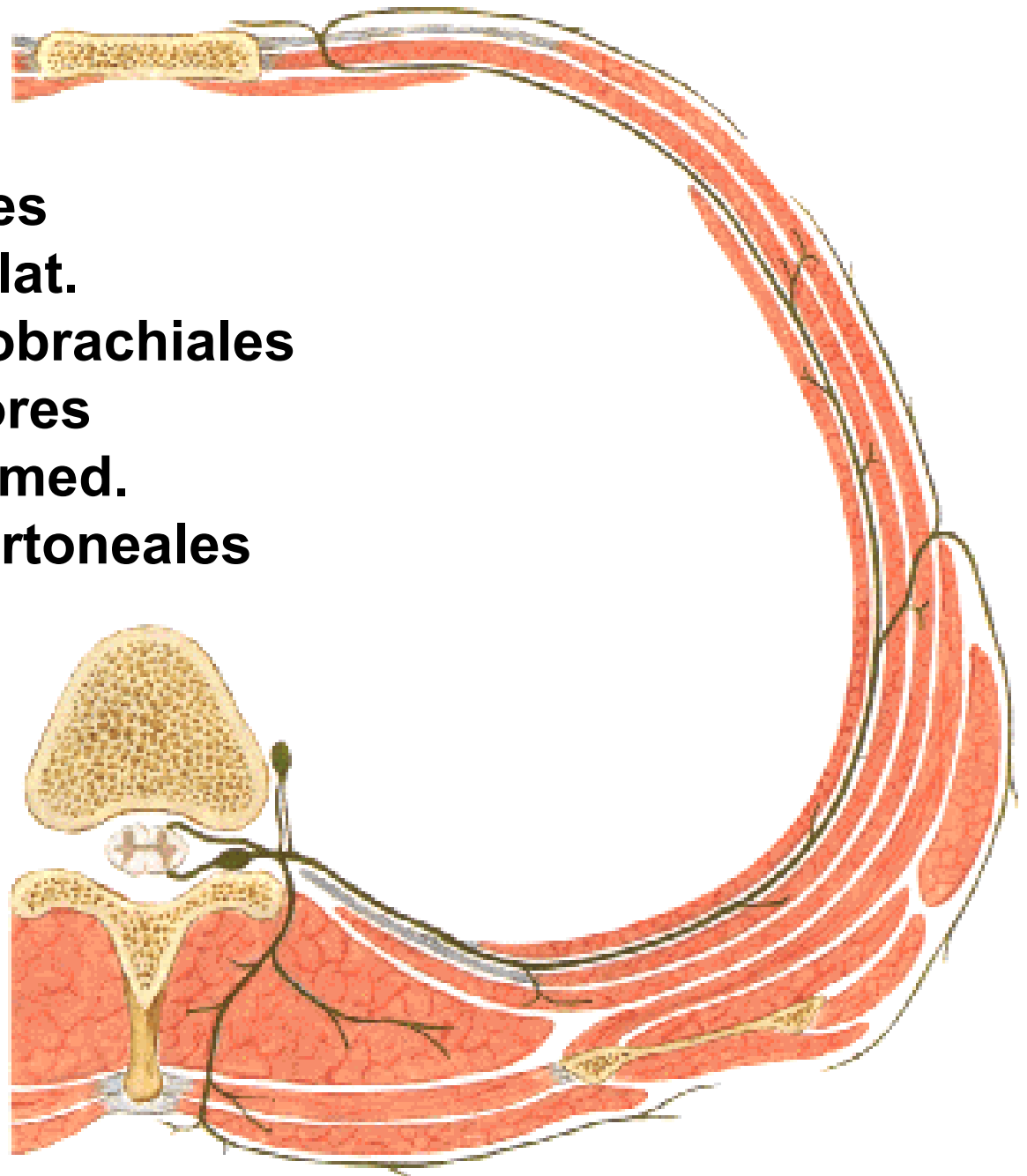
Nn. clunium superiores
Nn. clunium medii



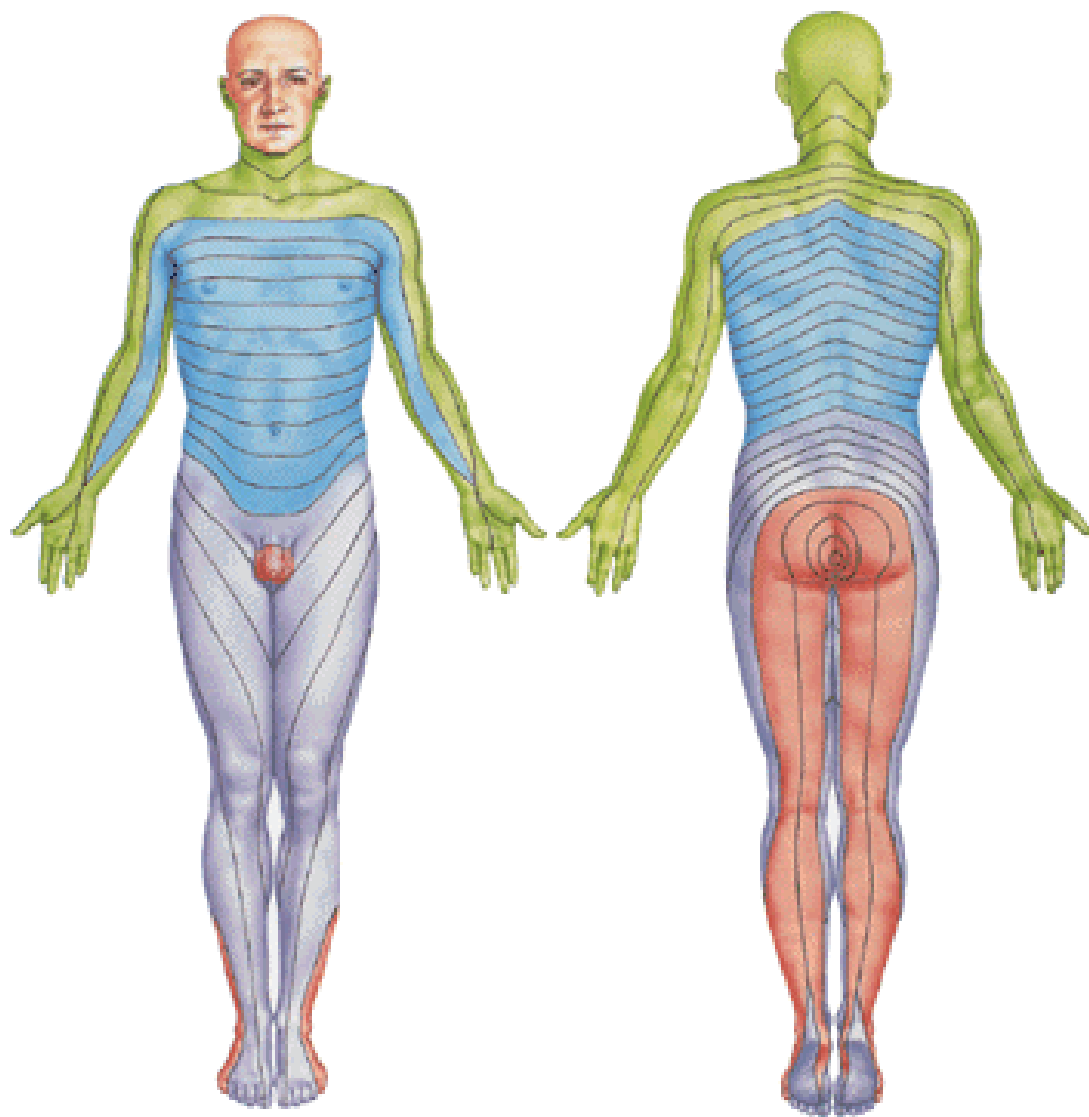
N. intercostalis

- rr. musculares
- rr. cutanei laterales
 - rr. mammarii lat.
 - nn. intercostobrachiales
- rr. cutanei anteriores
 - rr. mammarii med.
- rr. pleurales et peritoneales

N. subcostalis



Dermatomes



Illustrations and photographs were copied from:
Atlas der Anatomie des Menschen/Sobotta.
Putz,R., und Pabst,R. 20. Auflage. München:
Urban & Schwarzenberg, 1993
Netter: Interactive Atlas of Human Anatomy.
Windows Version 2.0