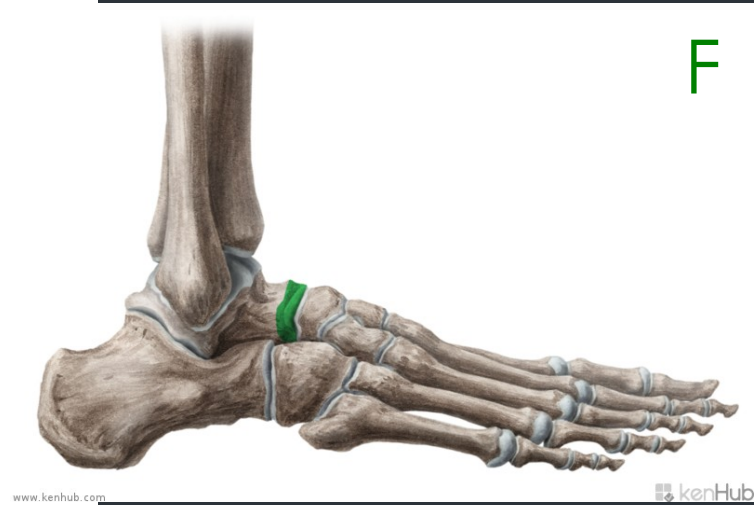
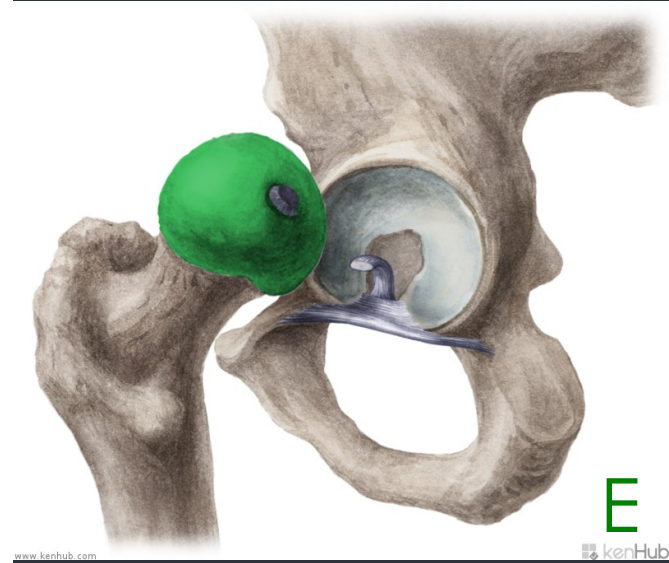
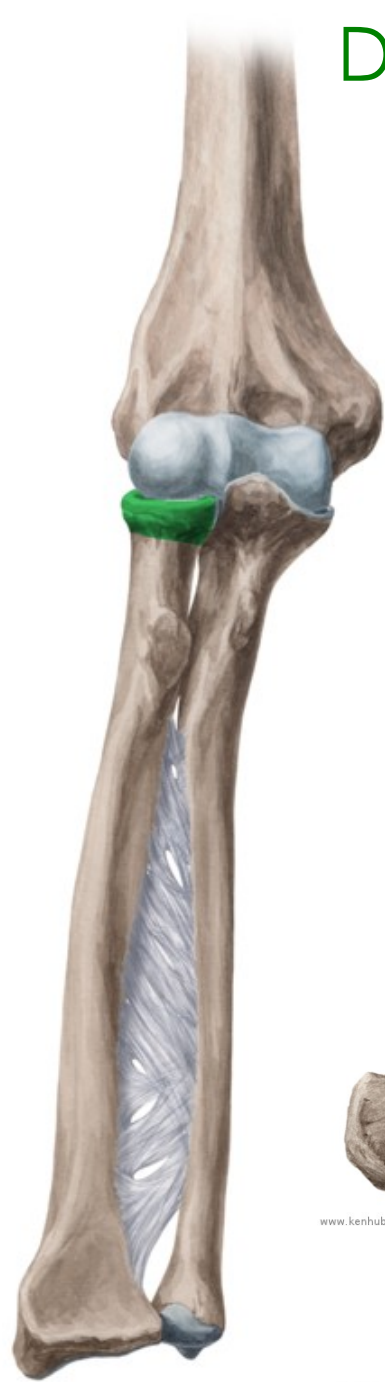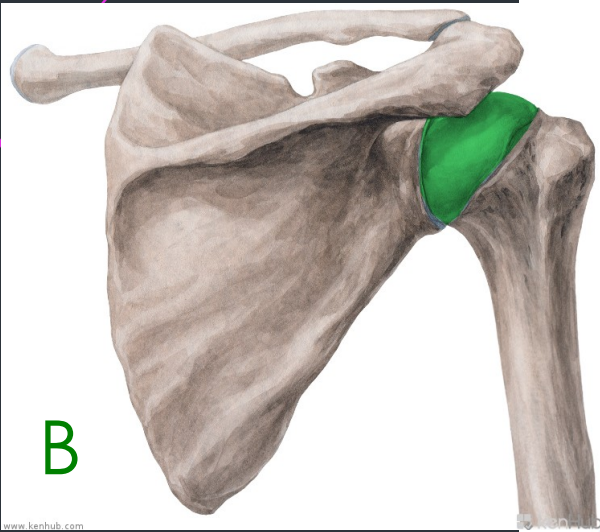
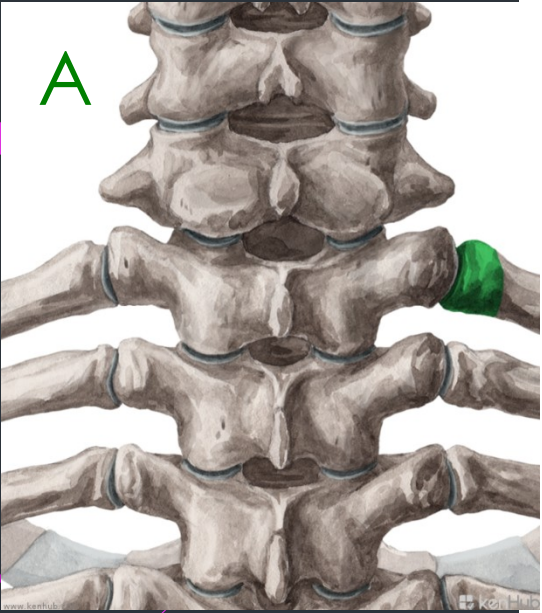




Questions

- ▶ **What means do we use to define an anatomical term?**
- ▶ **What cases are used with prepositions in medical terminology?**
- ▶ **Are there any prepositions connected with two cases?**
- ▶ **Which prepositions are connected with the ablative case?**

<http://anatomina.org/data/index.htm?cesta=obrazy/panev-celek-ilustrace-ventralne/&snimka=1&cislo=1&slozka=sys&lang=cz>



Head of... ?

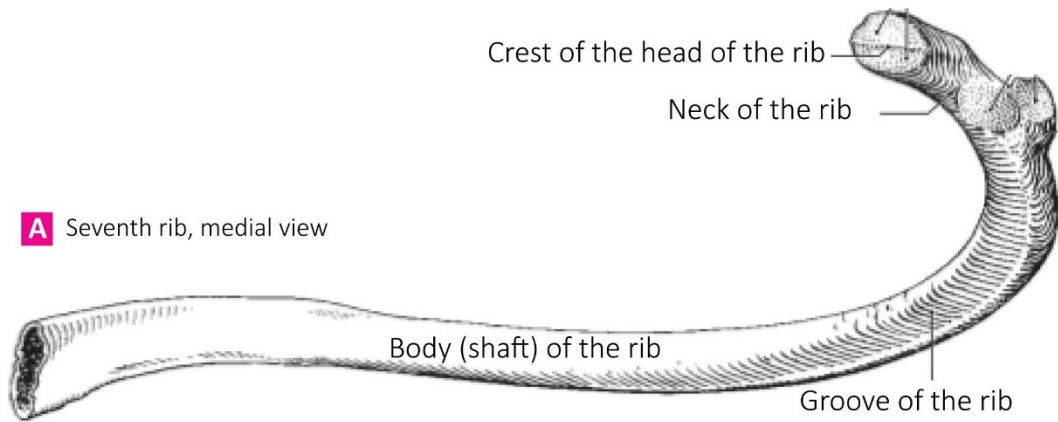
Connect the following nouns with RUPTURA or FRACTURA to create meaningful short diagnoses!

aorta ~ sclera ~ ulna ~ digitus ~ maxilla ~ ligamentum ~ trachea ~ tibia

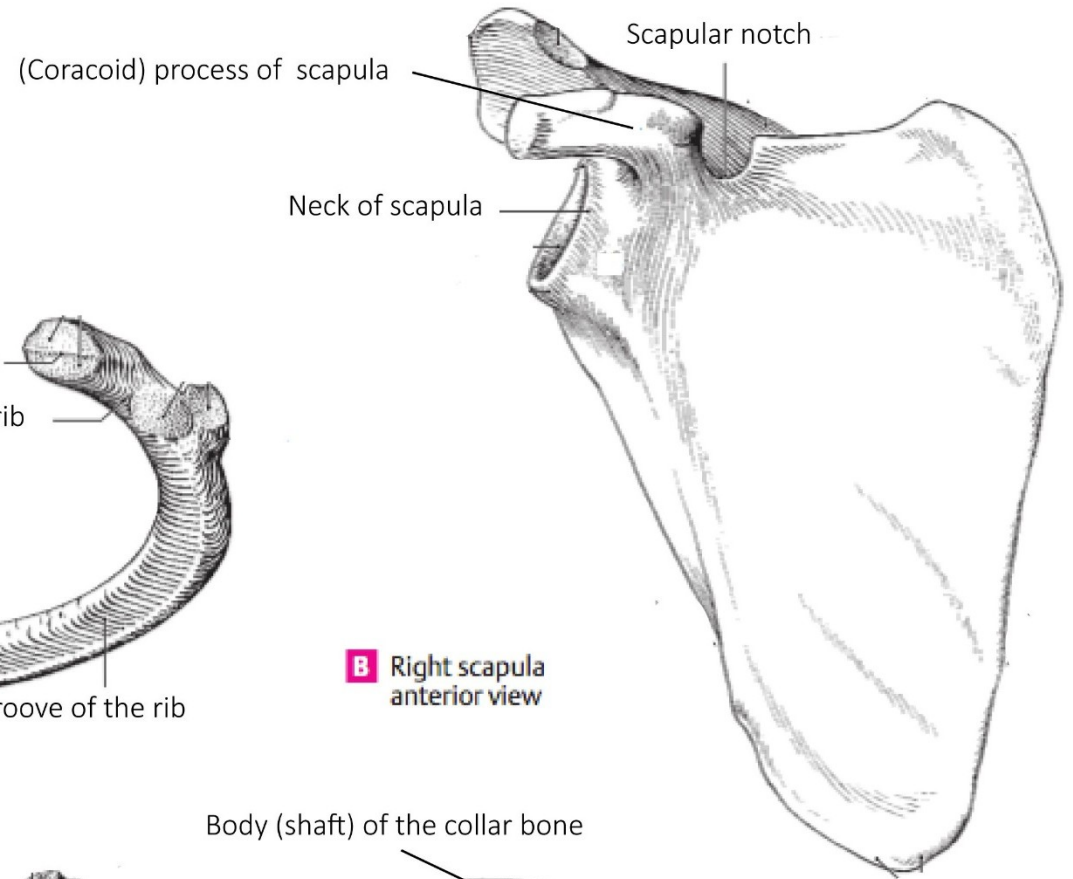
RUPTURA

FRACTURA

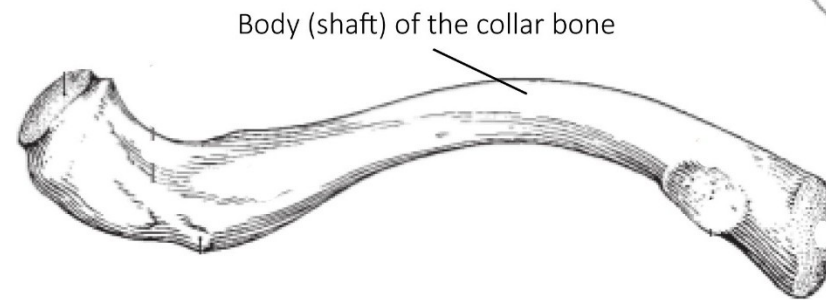
A Seventh rib, medial view



B Right scapula anterior view



C Right clavicle, inferior view



Adjectives of the 1st and 2nd declension, dictionary entry

Magnus, a, um

Magnus magna magnum

m. f. n.

coxa

oculus

crus

bucca

fibula

cervix

sulcus

arcus

metatarsus

hallux

Dexter, a, um

Dexter dextra dextrum

m. f. n.

(* liber, libera, liberum)

coxa

oculus

crus

bucca

fibula

cervix

sulcus

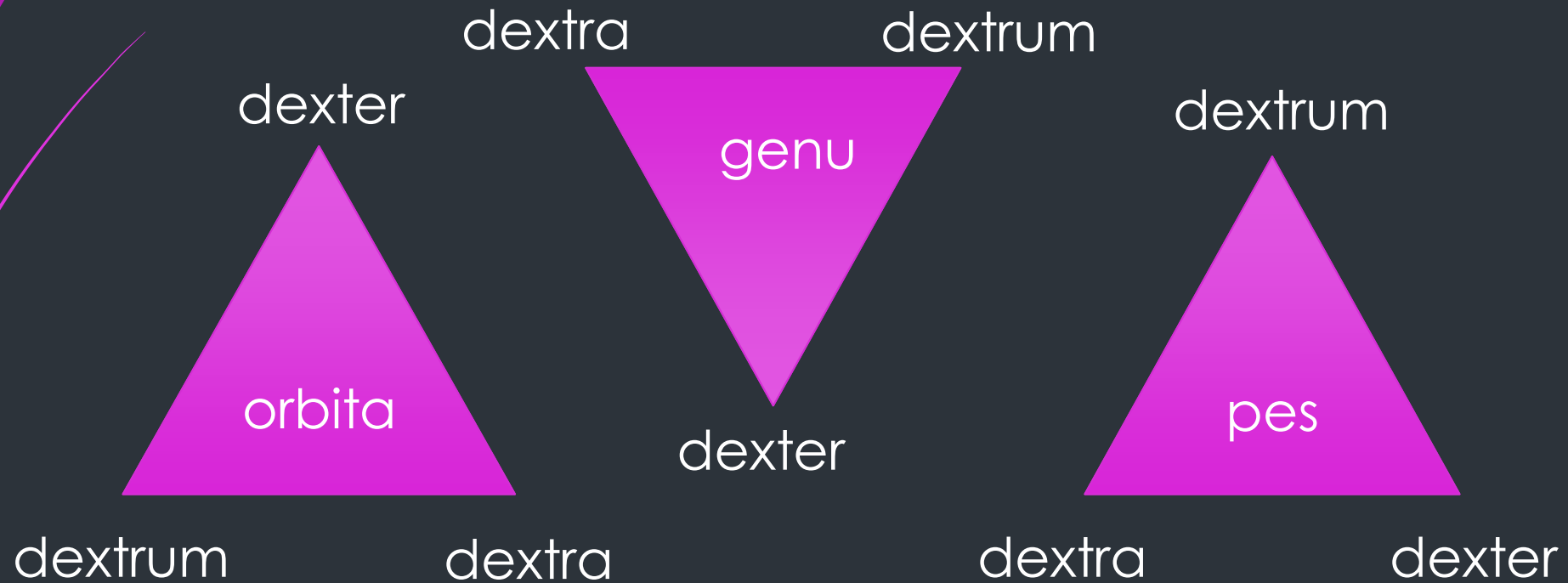
arcus

metatarsus

hallux

Agreed-attribute

What is the correct adjective for the noun in the triangle?



Za správnosť



Lekárska správa - nález

Označenie zdrav. zariadenia, odd., pracovisko

pre

Priezvisko a meno

Burdinovič Igor

rok nar.

Klin. dg

vykonané v

Dnes asi o 19.30 pri služobnom zákroku
kosti vpravo, na okolnosti spomína, v bezv
I.č. v ÚVTOS.

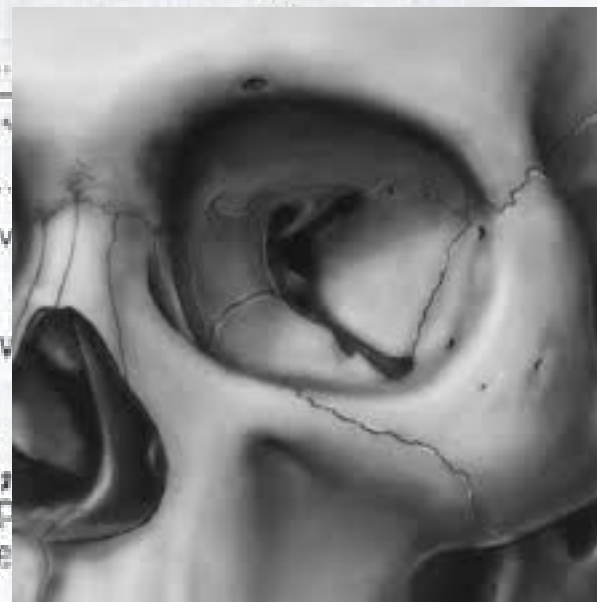Vyš: REG, / OPG, PND, Clementschitch - bez
e.o. hematoma v obl. jarmovej kosti vpravo,
opuch v obl. jarmovej kosti vpravo táto nep
bilat. bez sčodika, vizus orient. v norme
zachovalá

i.o. otváranie úst bez obmedz., sliz. BPN, skelet pevný, záryz v norm

Dg: Contusio faciei l.dx. reg. ossis zygomat.
Haematoma faciei l.dx. reg. ossis et arc. zygo at.
Ih: ine, len vyšetrenie.

Udp: Chladiť, analgetiká p.p. Vhodné v ÚVTOS predpísať Augmentin 625mg
p.o. 6-8 hod.

KO: V prípade ťažkostí ihneď



Contusio faciei l.dx. reg. ossis zygomat.

Contusio faciei lateris dextri regionis ossis zygomatici

Haematoma faciei l. dx. reg. ossis et arc. zygomat.

Haematoma faciei lateris dextri regionis ossis et arcus

zygomatici

Read and guess
the meaning:

Dg.:
*Corpus alienum trac. GI
l.dx. sine compl, sine
inflam.*

**Corpus alienum tractus
gastrointestinalis lateris
dextri sine
complicationibus, sine
inflammatione**

