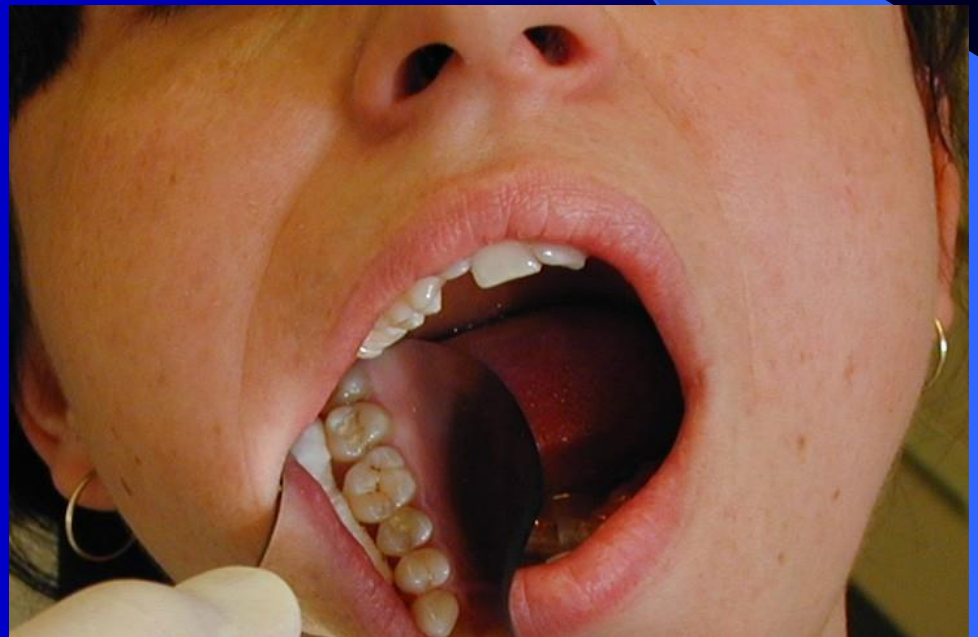

# Classification acc. to Black

- Class I.

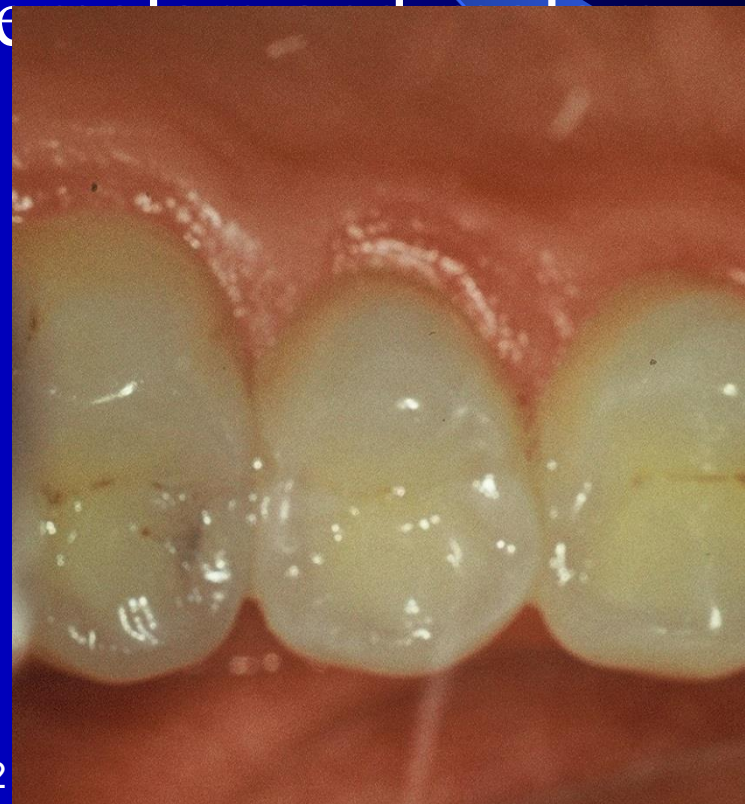Pit and fissure caries



# Classification acc. to Black

- Class II.

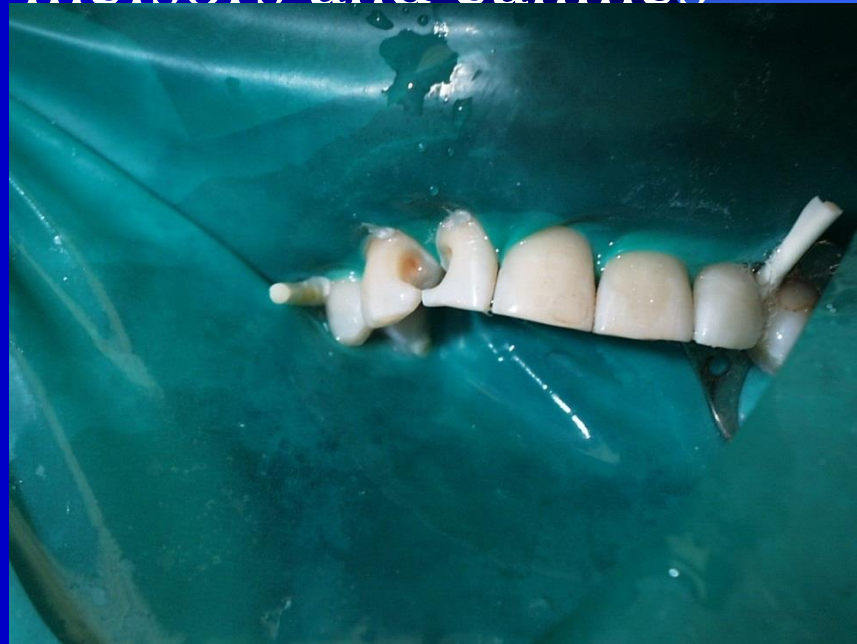Proximal surfaces in pre



# Classification acc. to Black

- Class III.

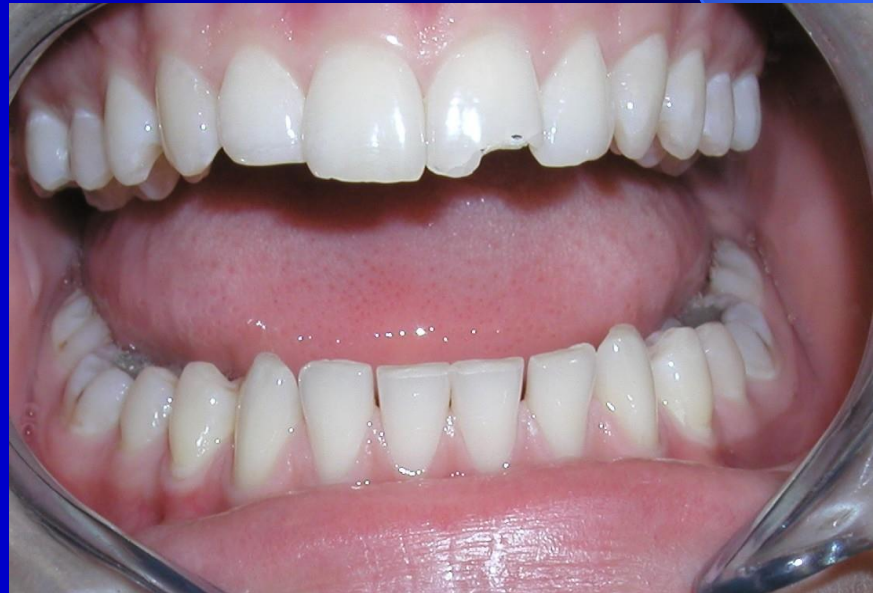Proximal surfaces of incisors and canines  
without  
lost an incisal ridge



# Classification acc. to Black

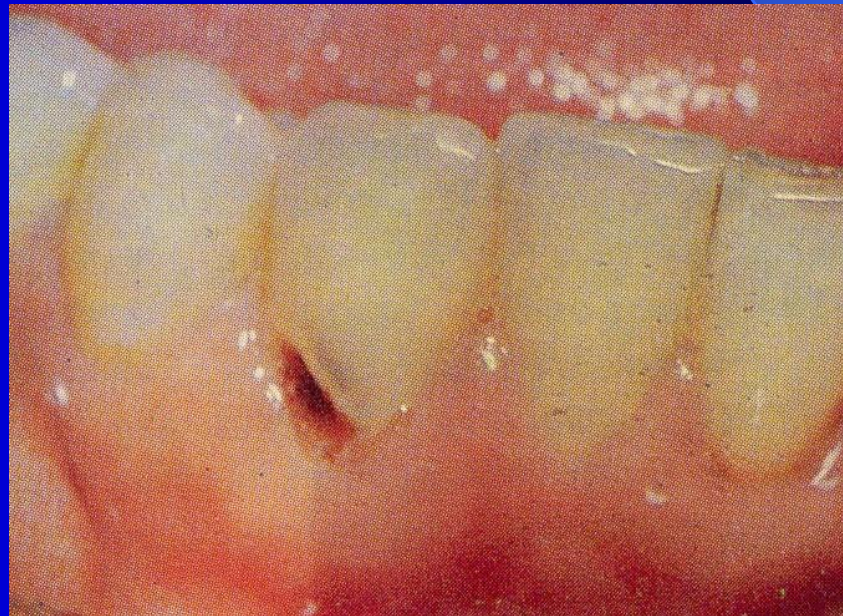- Class IV.

Proximal surfaces of incisors and canines with lost an incisal ridge



# Classification acc. to Black

- Class V. cervical lesions



# Basic rules preparation of cavities

Access to the cavity

Outlines – cavosurface margin (extention for prevention)

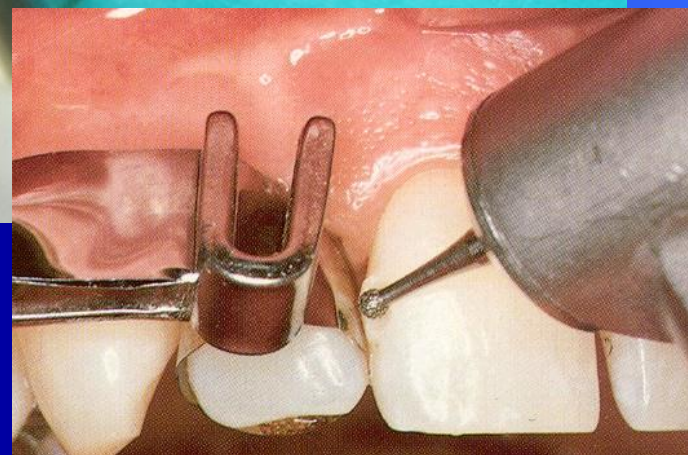
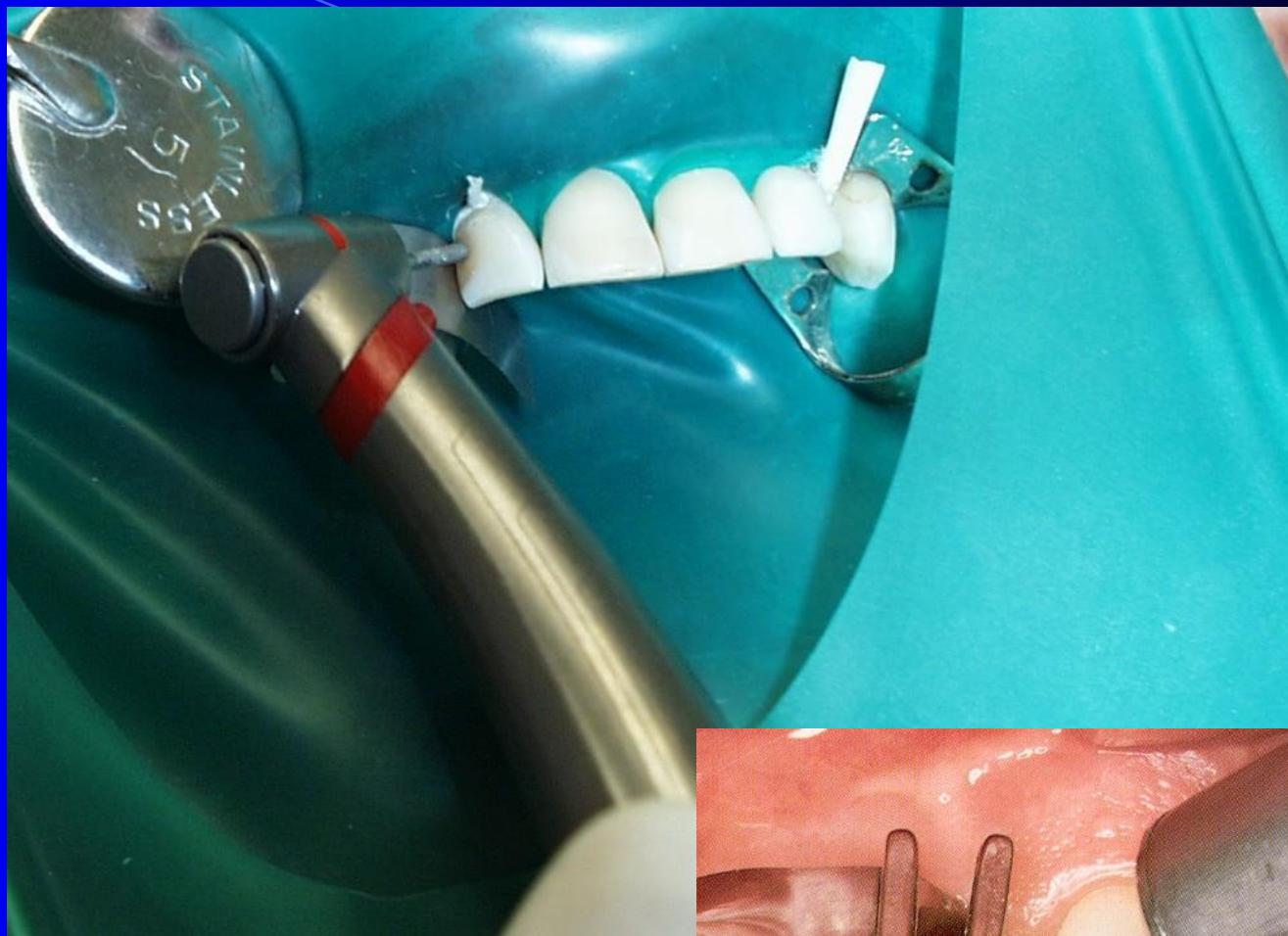Retention

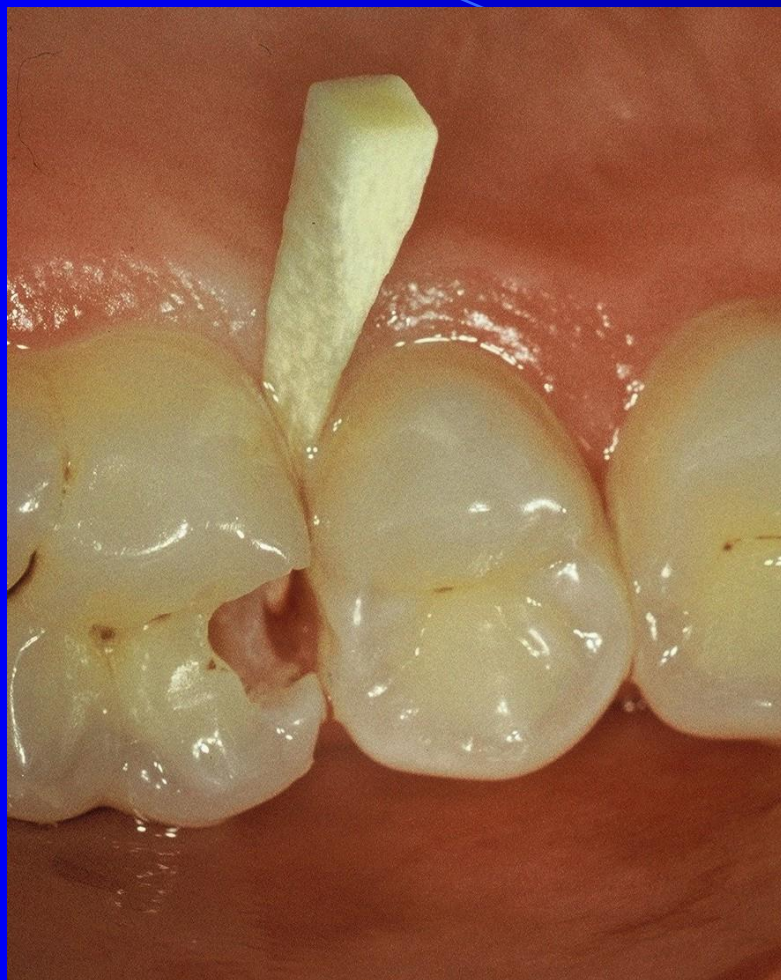
Resistance

Excavation of carious dentin

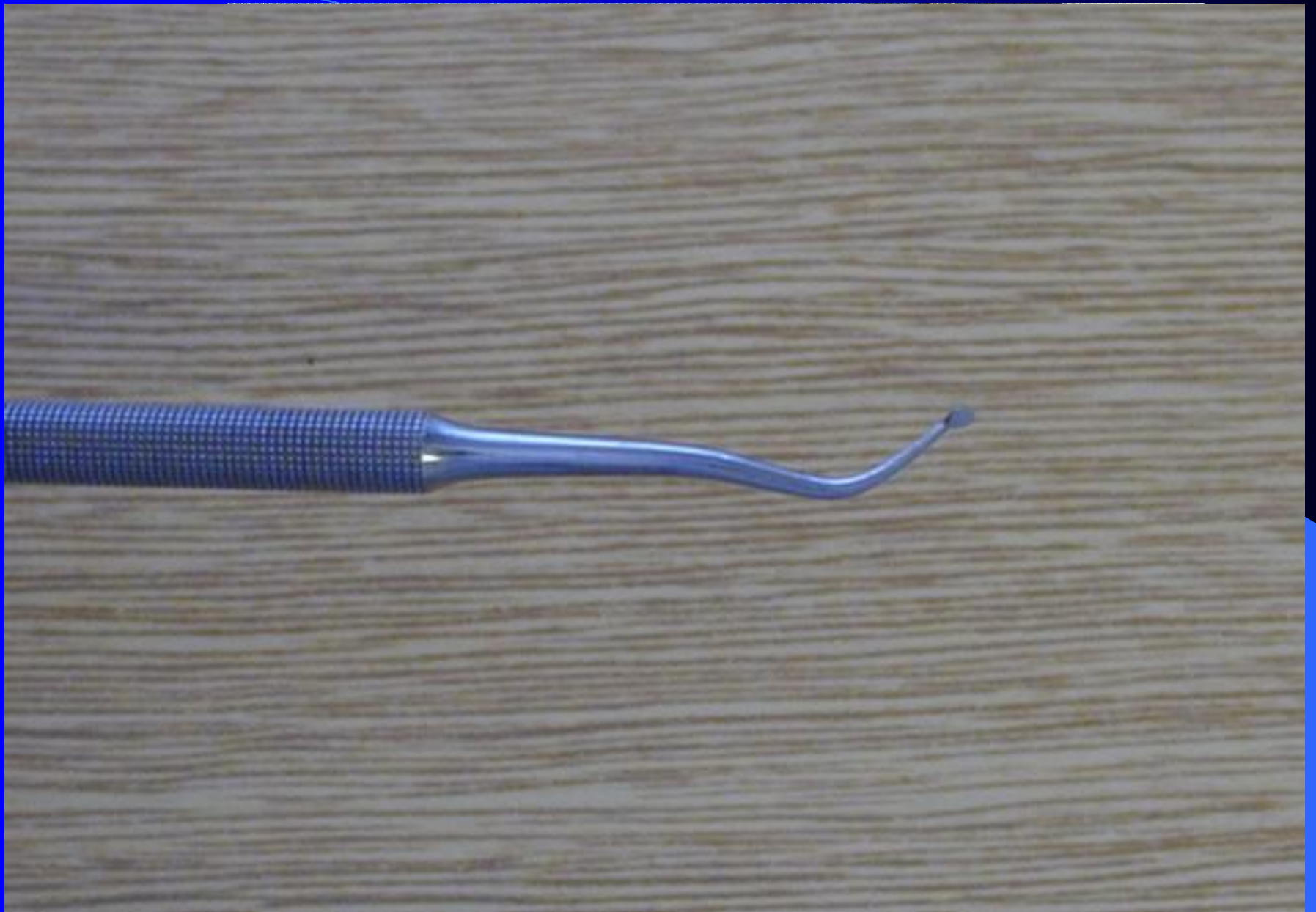Preparation of borders – finishing

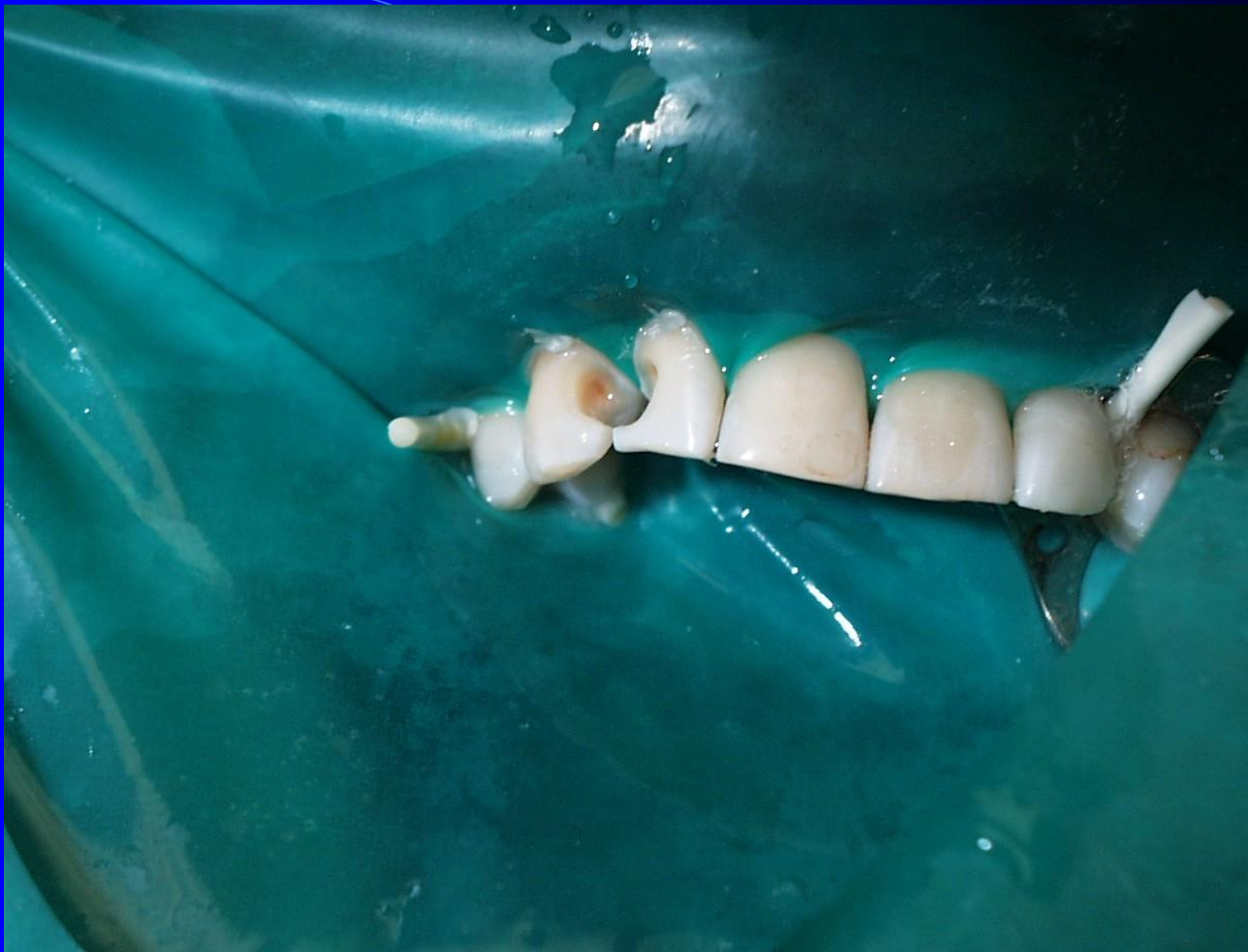Control

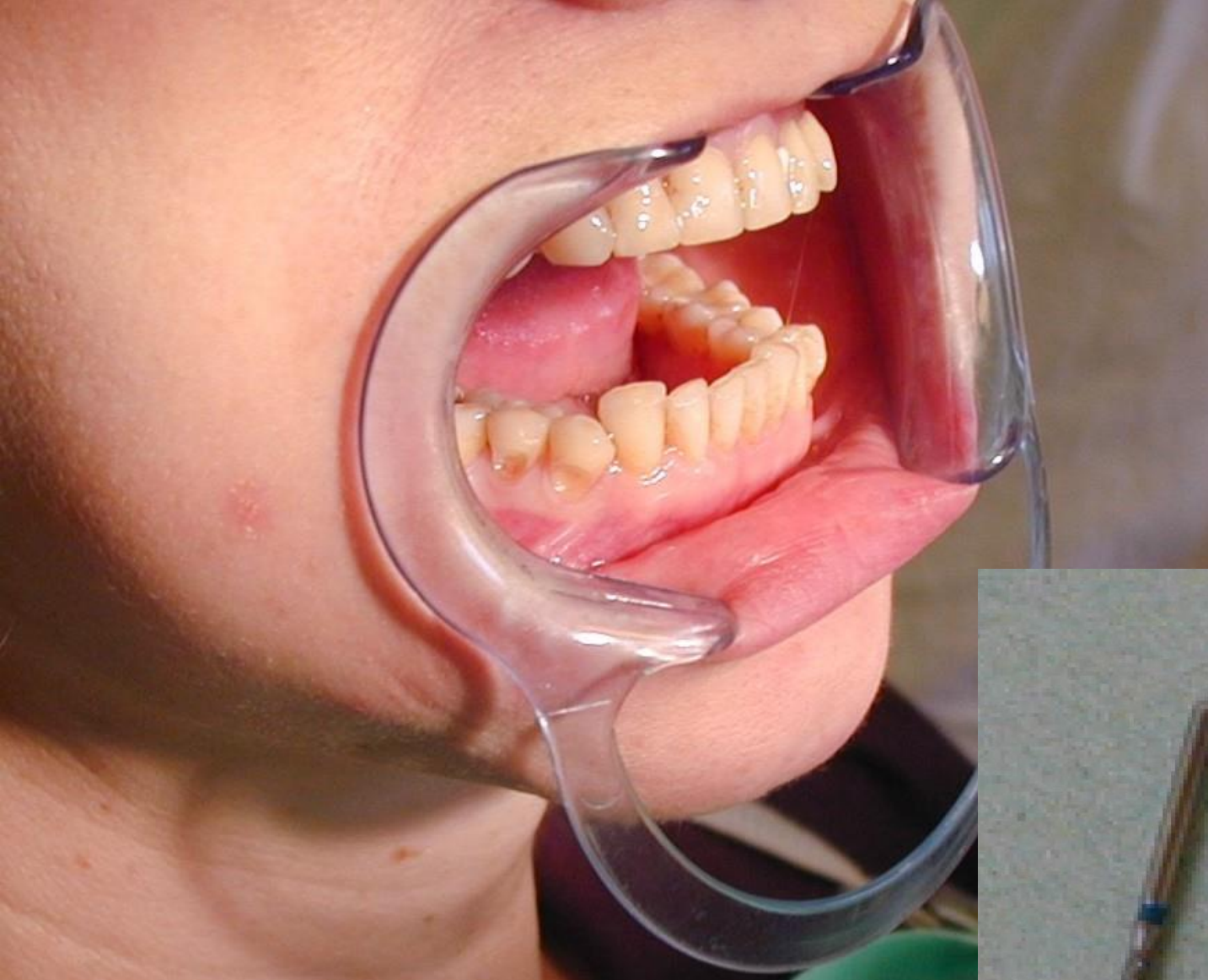








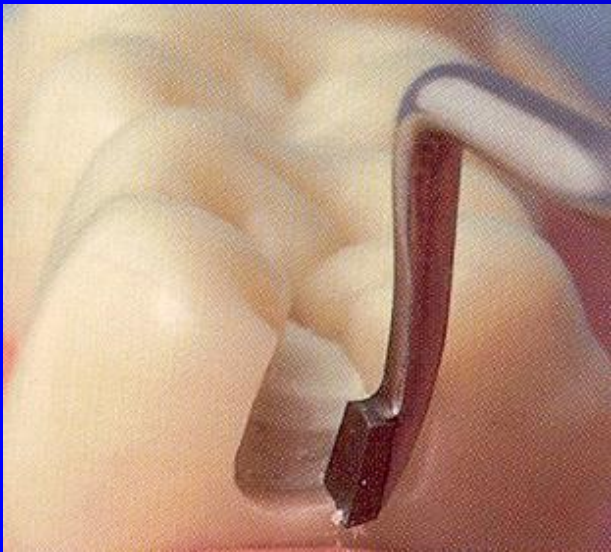
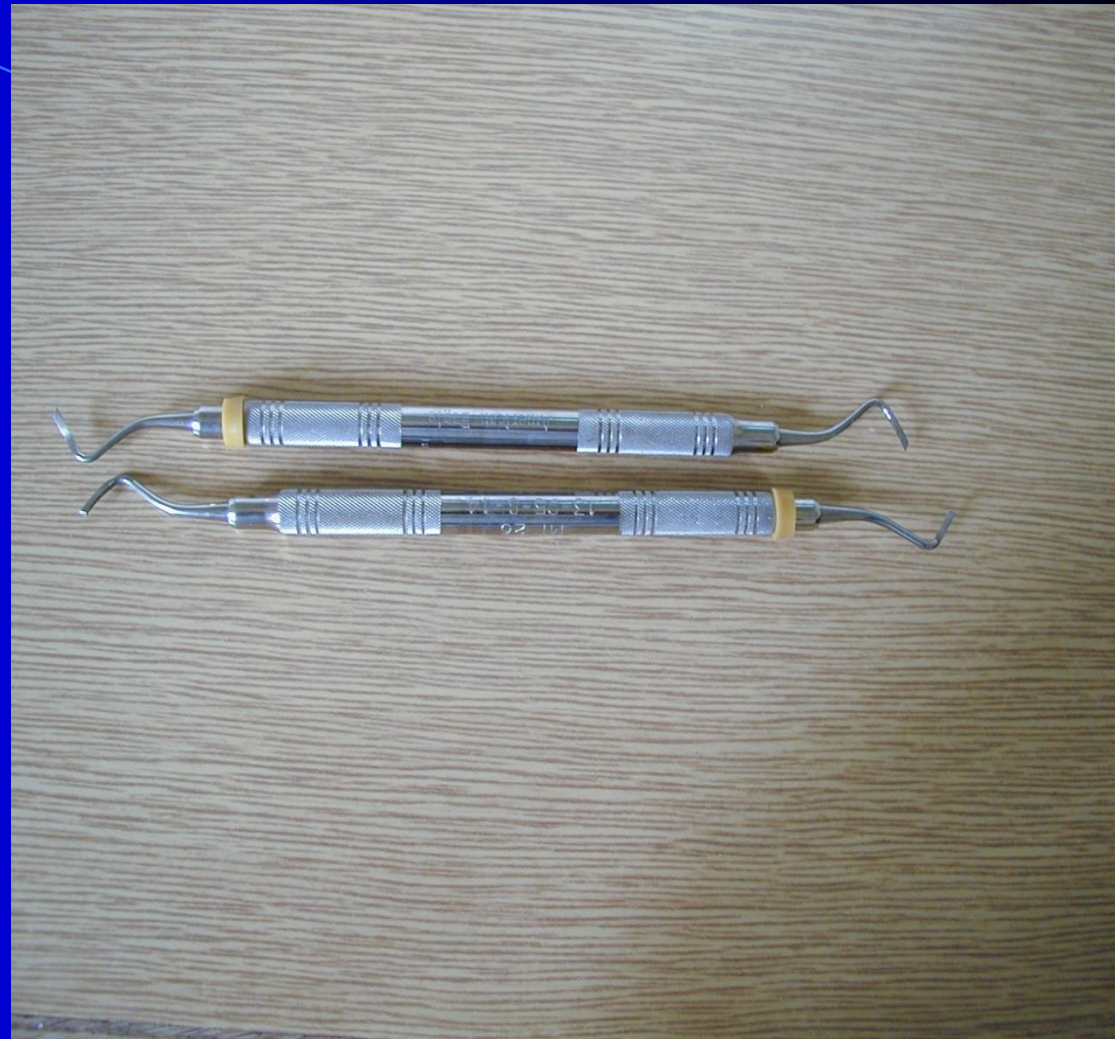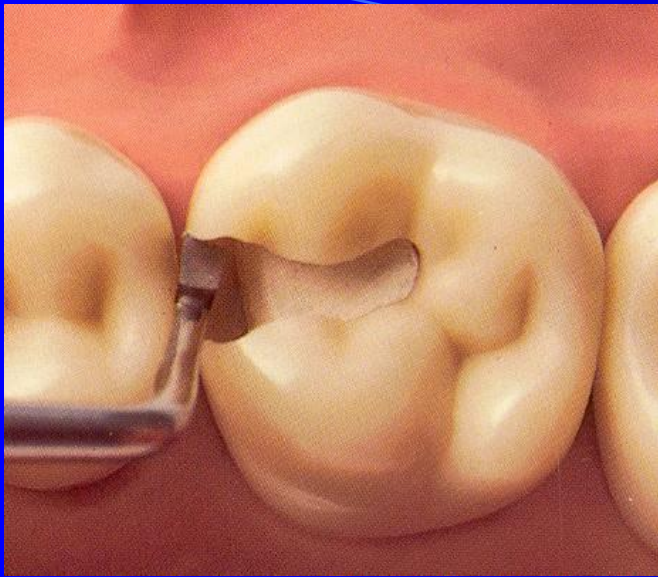




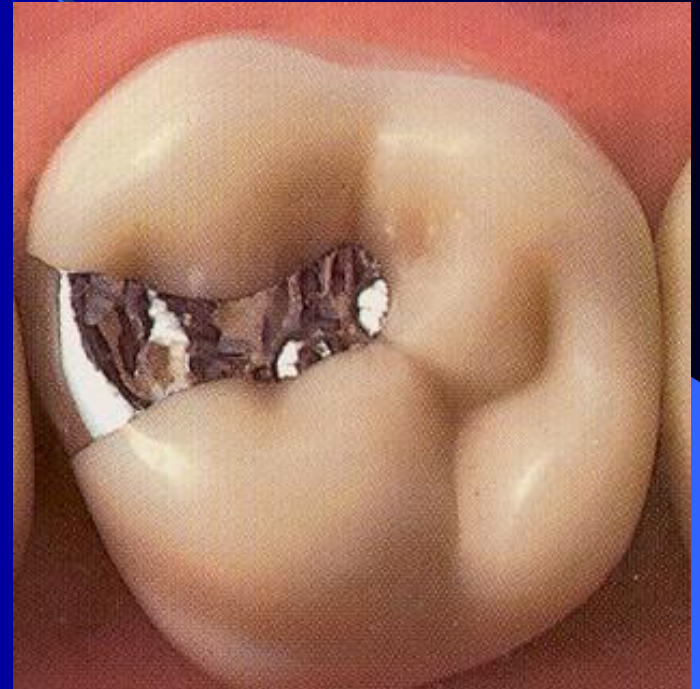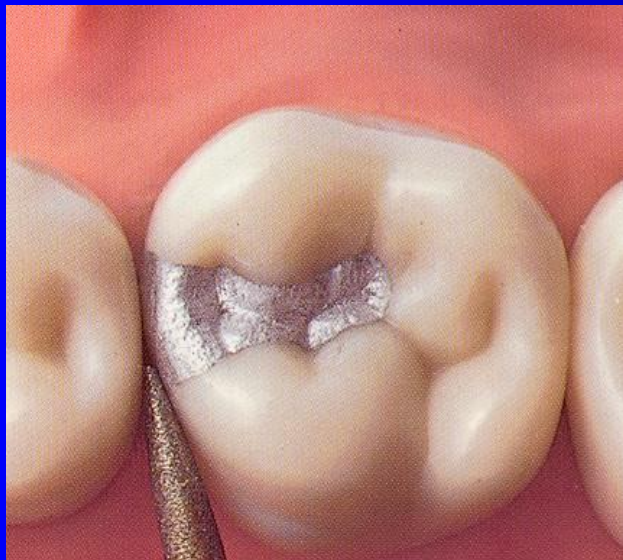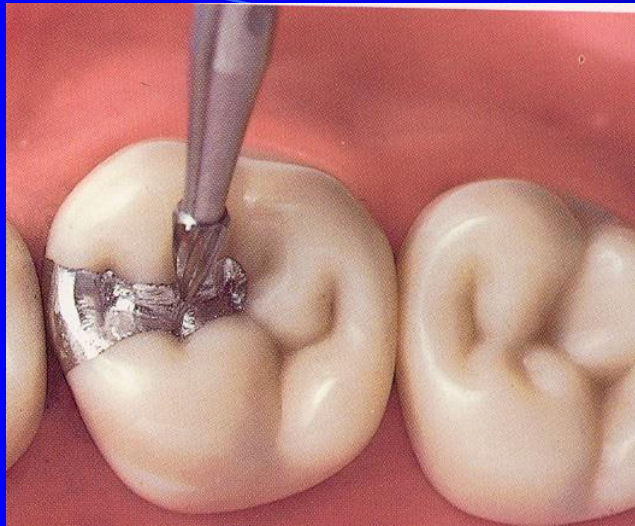
## Úprava sklovinných stěn

lenka.roubalikova@ti  
scali.cz









# Protection of dentin wound

- Dentin wound – open dentin tubules – movement of dentinal liquor – hydrodynamic effect.

## Physical reasons

-thermal

-osmotic

## Chemical reasons

## Combination



# Protection of dentin wound

Isolation

Base

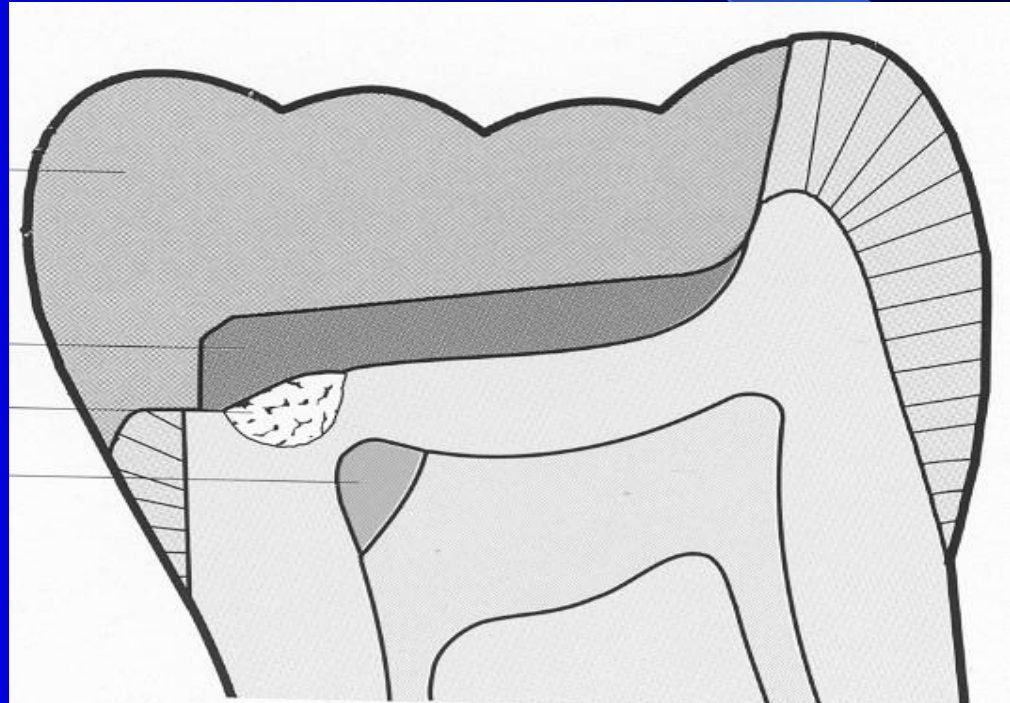
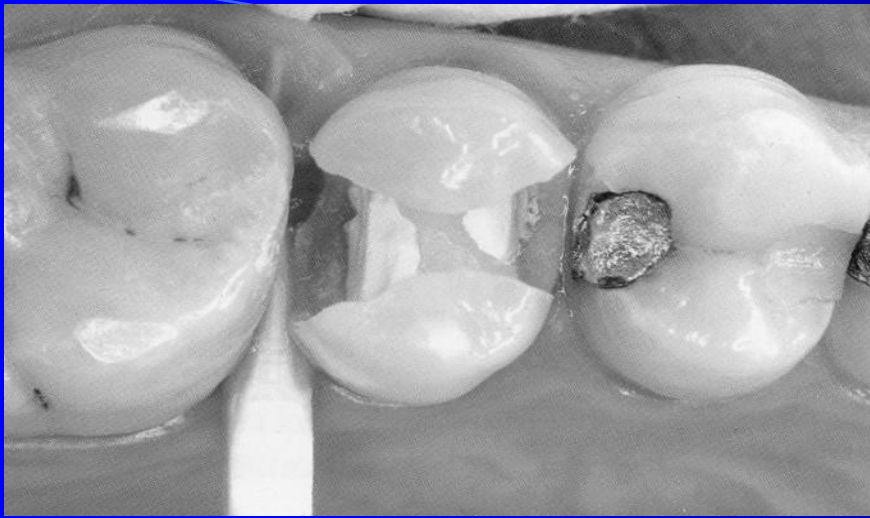
Lining

Subbase

Adhesive systems (explanation later)

# Making fillings


- Filling replaces lost hard dental tissue anatomically and functionally
- Always different properties in comparison to hard dental tissues.



# Lining



# Base



# Preparation of the cavity I.st class acc. to Black

- Cavities in fissures and pits
- (Occlusal surfaces of premolars and molars and in f. coeca)

F. Coeca: buccal surfaces of lower molars,

Palatal surfaces of lower molars, palatal surfaces of canines.

# All pit and fissure restorations.

They are assigned in to three groups.

R. on occlusal surface of premolars and molars

R. in foramina coeca – usually on occlusal two thirds of the facial and lingual surfaces of molars.

R. on lingual surface of maxillary incisors.

**Materials: Amalgam, composite.**

**Amalgam:**

Pertinent material qualities and properties

Strength

Longevity

Ease of use

Clinically proven success

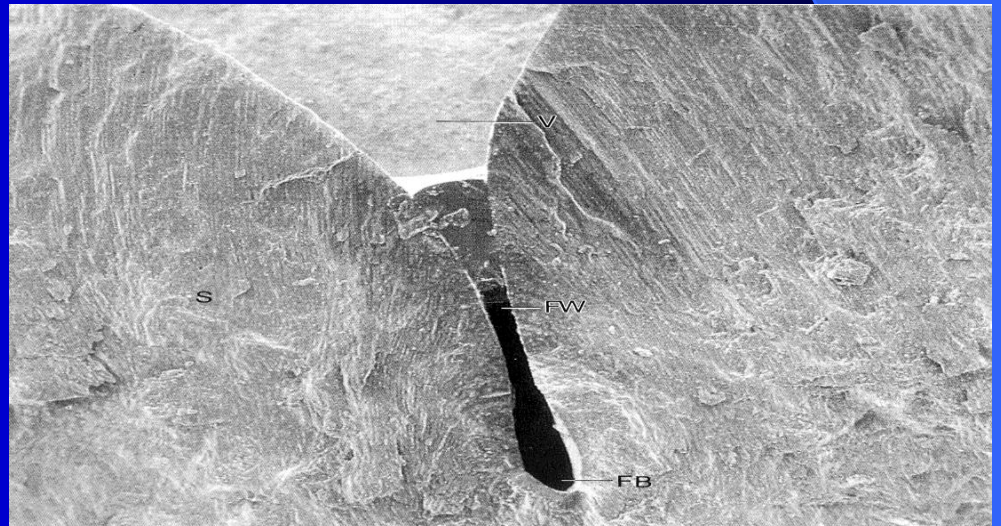
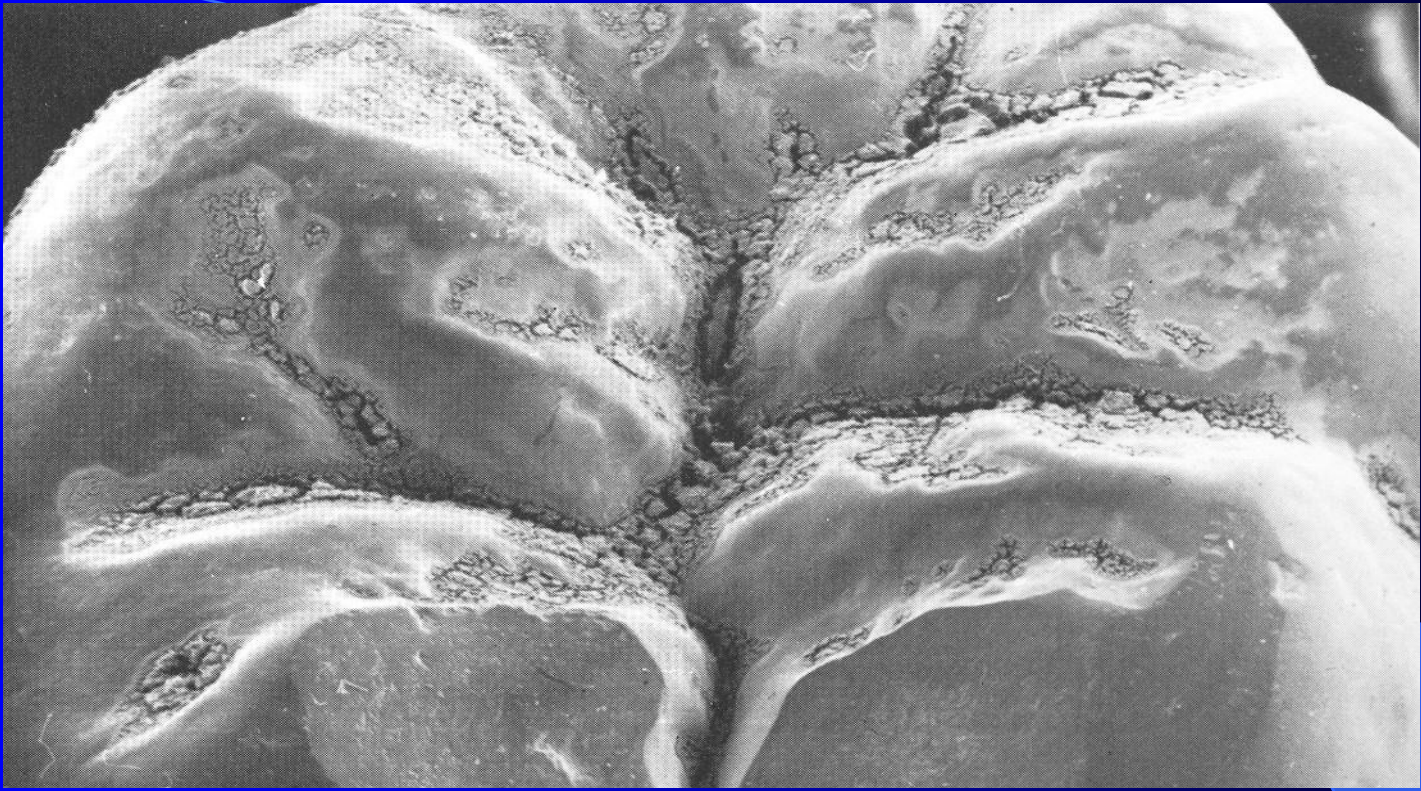


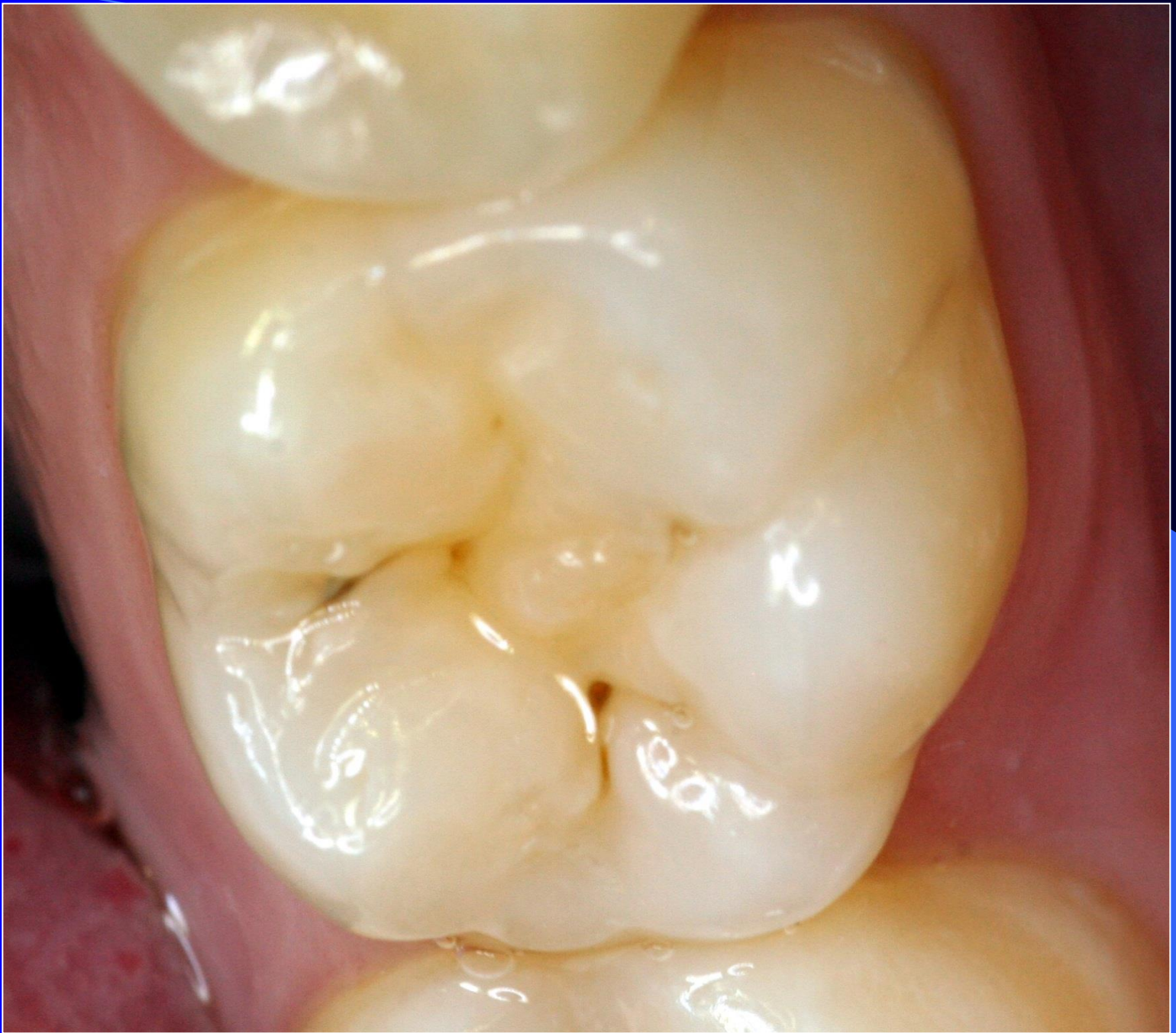# Indications

- Moderate to large restorations
- Restorations that are not in highly aesthetics areas
- Restorations that have heavy occlusal contacts
- Restorations that cannot be well isolated
- Restorations that extend onto the root surface
- Foundations
- Abutment teeth for removable partial dentures
- Temporary or caries control restorations.

# Contraindications

- Aesthetically prominent areas of posterior teeth
- Small moderate classes I. that can be well isolated





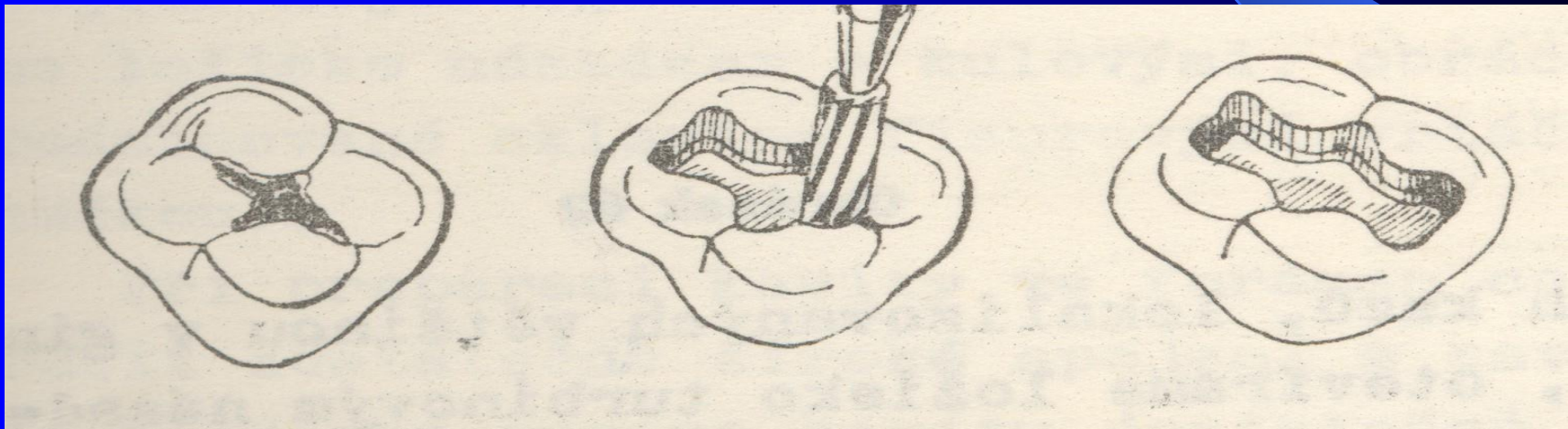
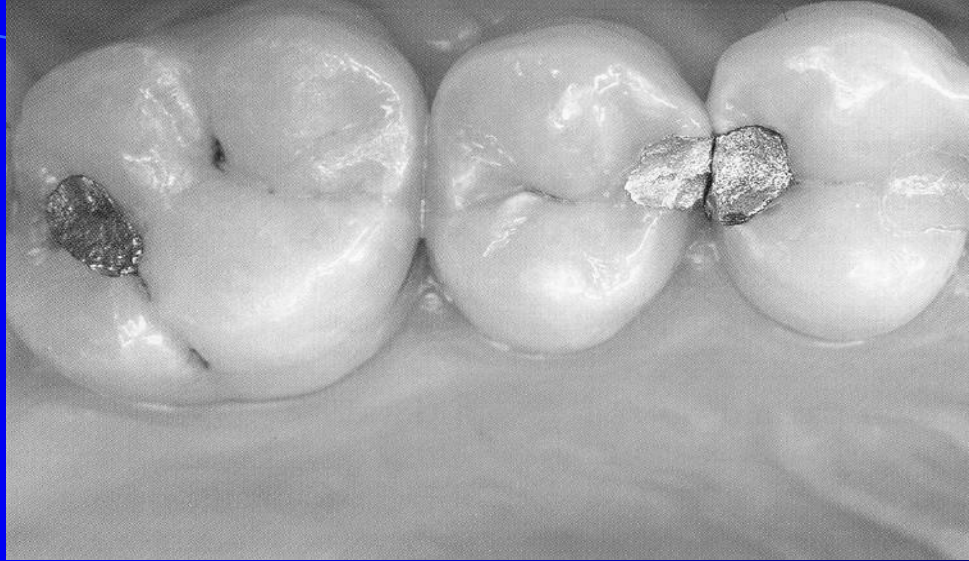
# Access to the cavity

- From the occlusal surface using the fissure bur (or diamond burs, see below).

# Outline

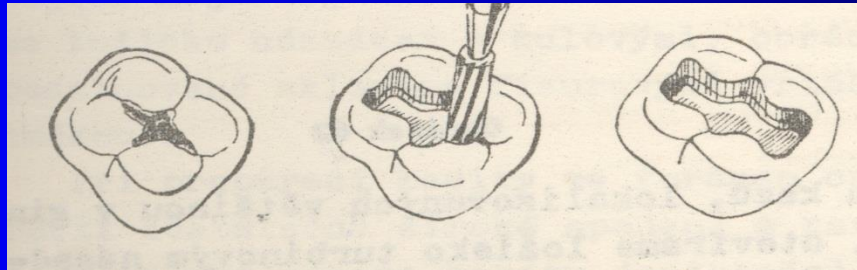
- Ideal outline includes all occlusal pits and fissures. If crista transversa and obliqua are not affected, it is recommended not to prepare them.





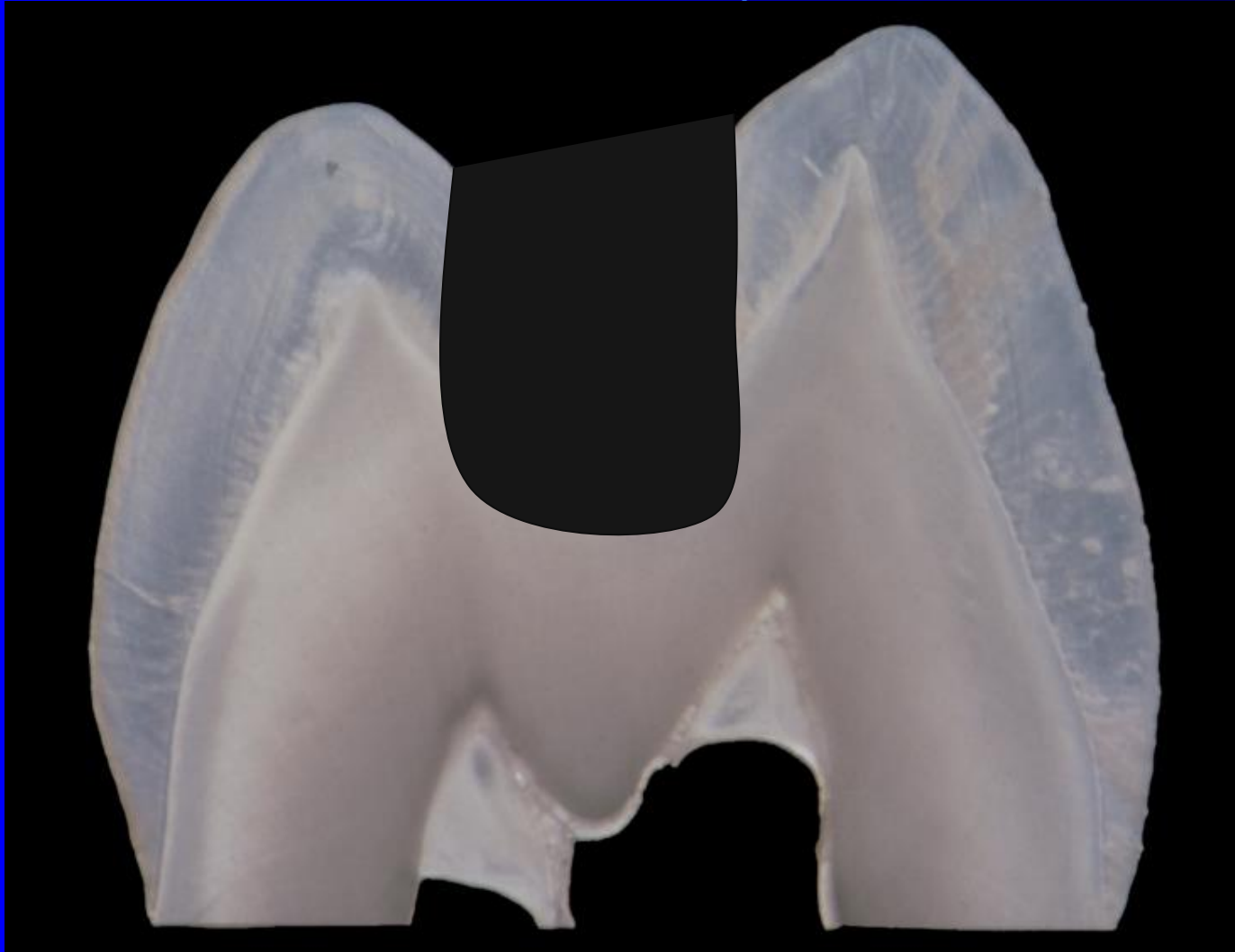# Cavosurface margin

All fissures in contact with caries lesion






Kavita sahá do ½ úbočí hrbolků



# Kavity na molárech



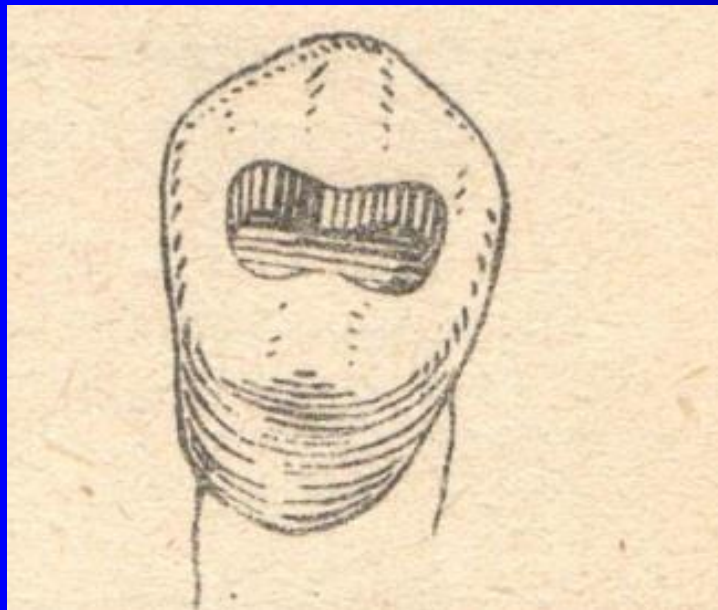Zachování crista obliqua

6

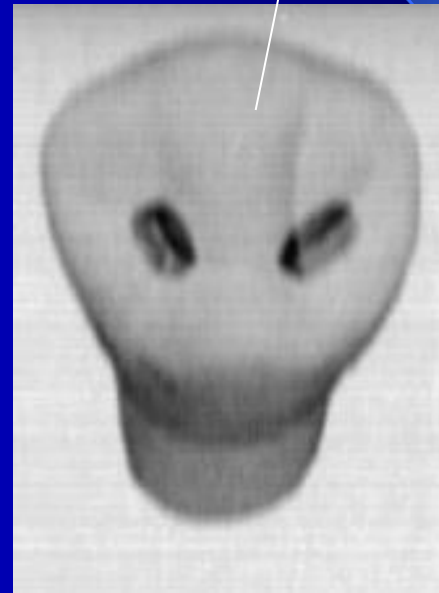7

8

Kavity na premolárech



Zachování crista transversa

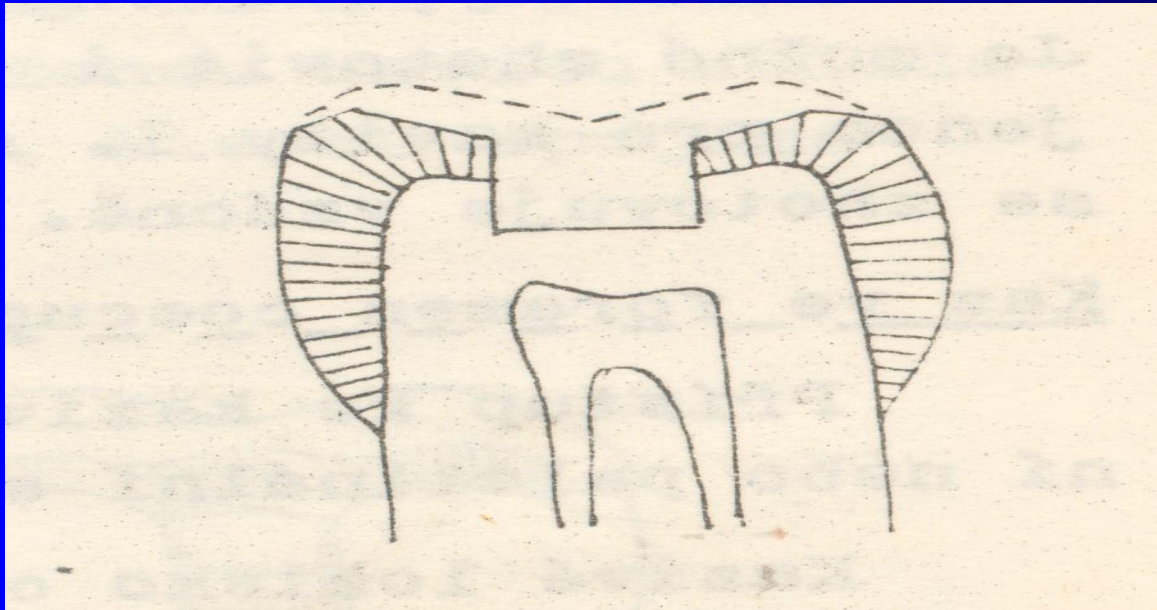


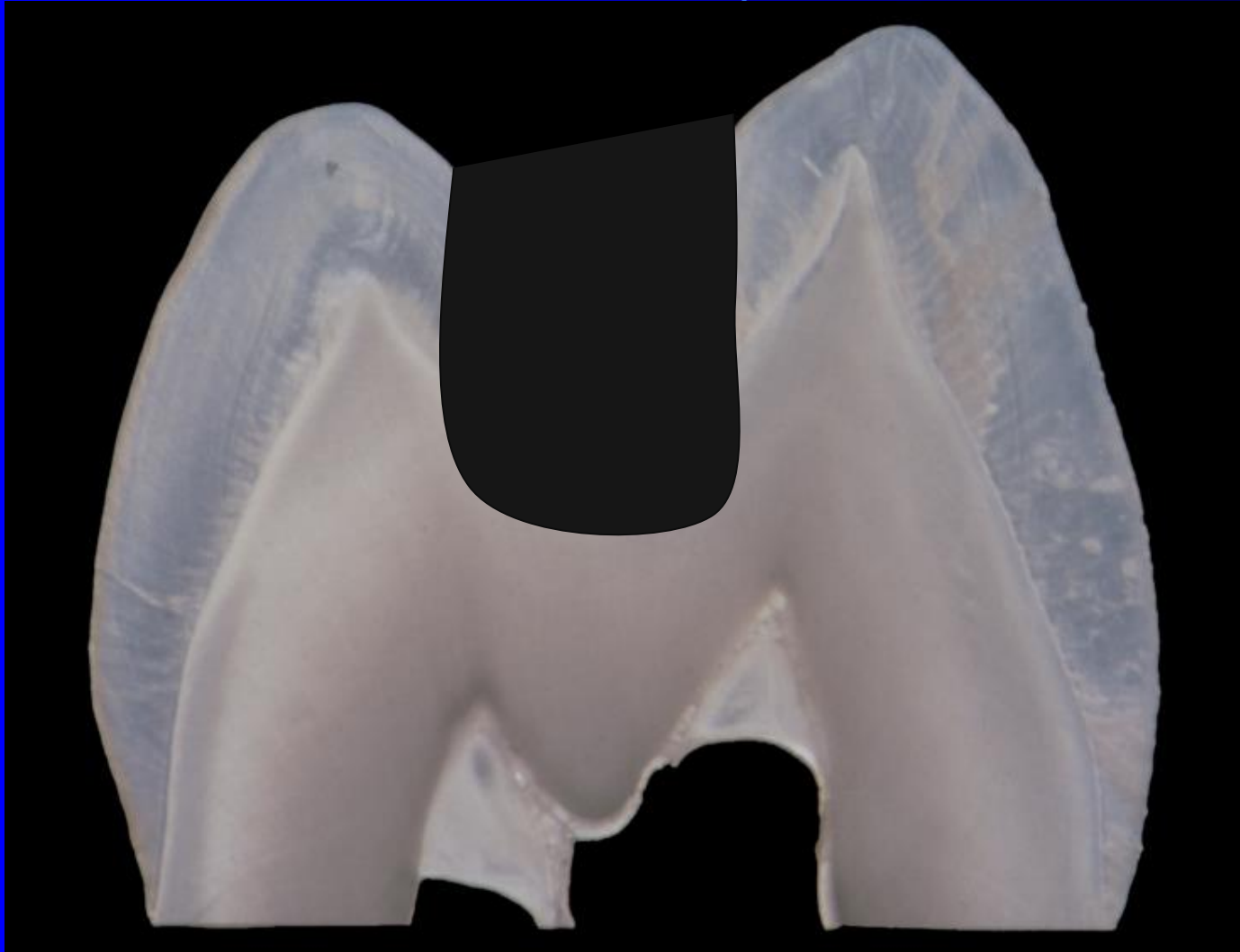# Retention principles

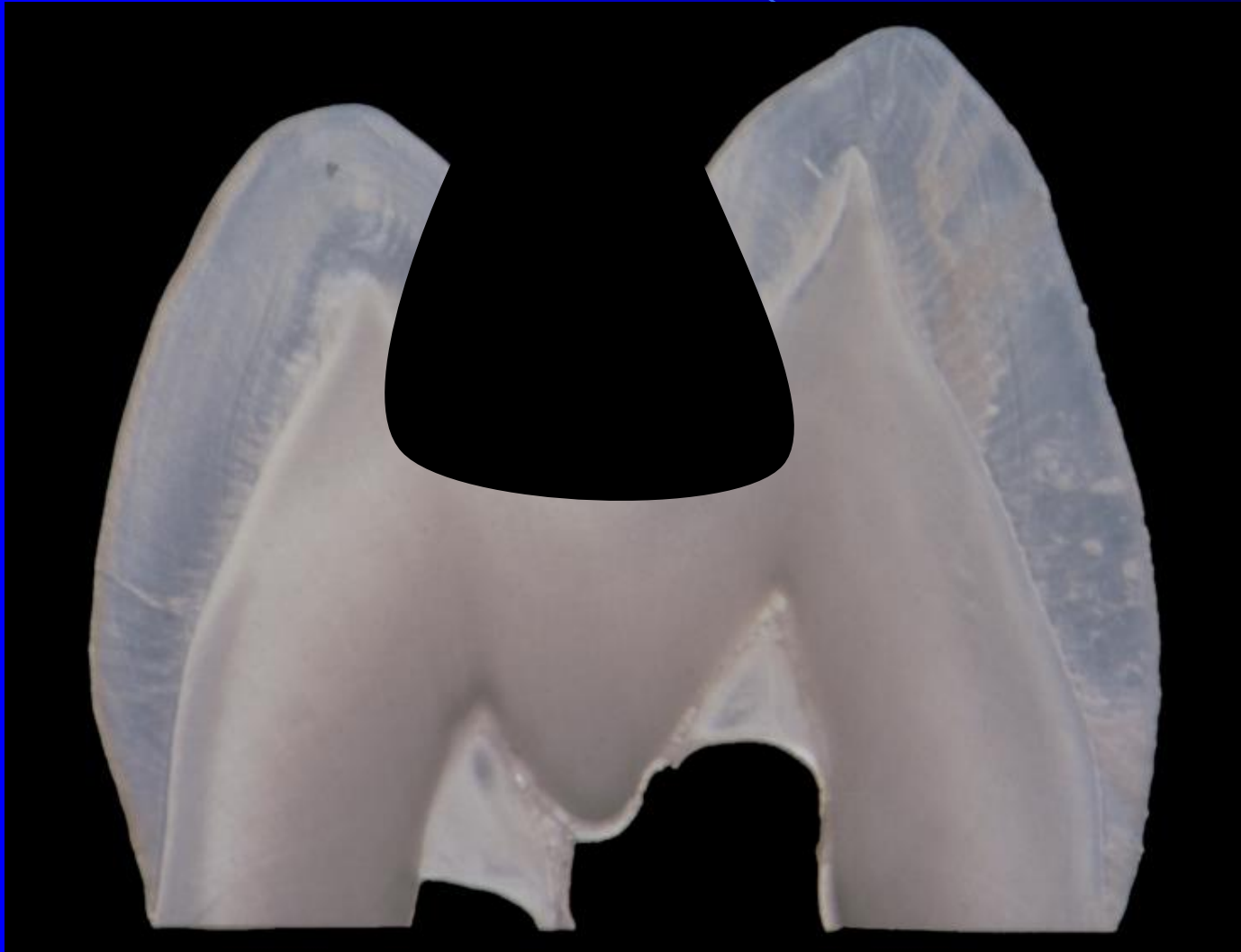- Prepare the box – the bottom is in dentin
- Undercuts can be prepared, the proximal ridges must not be weakened!

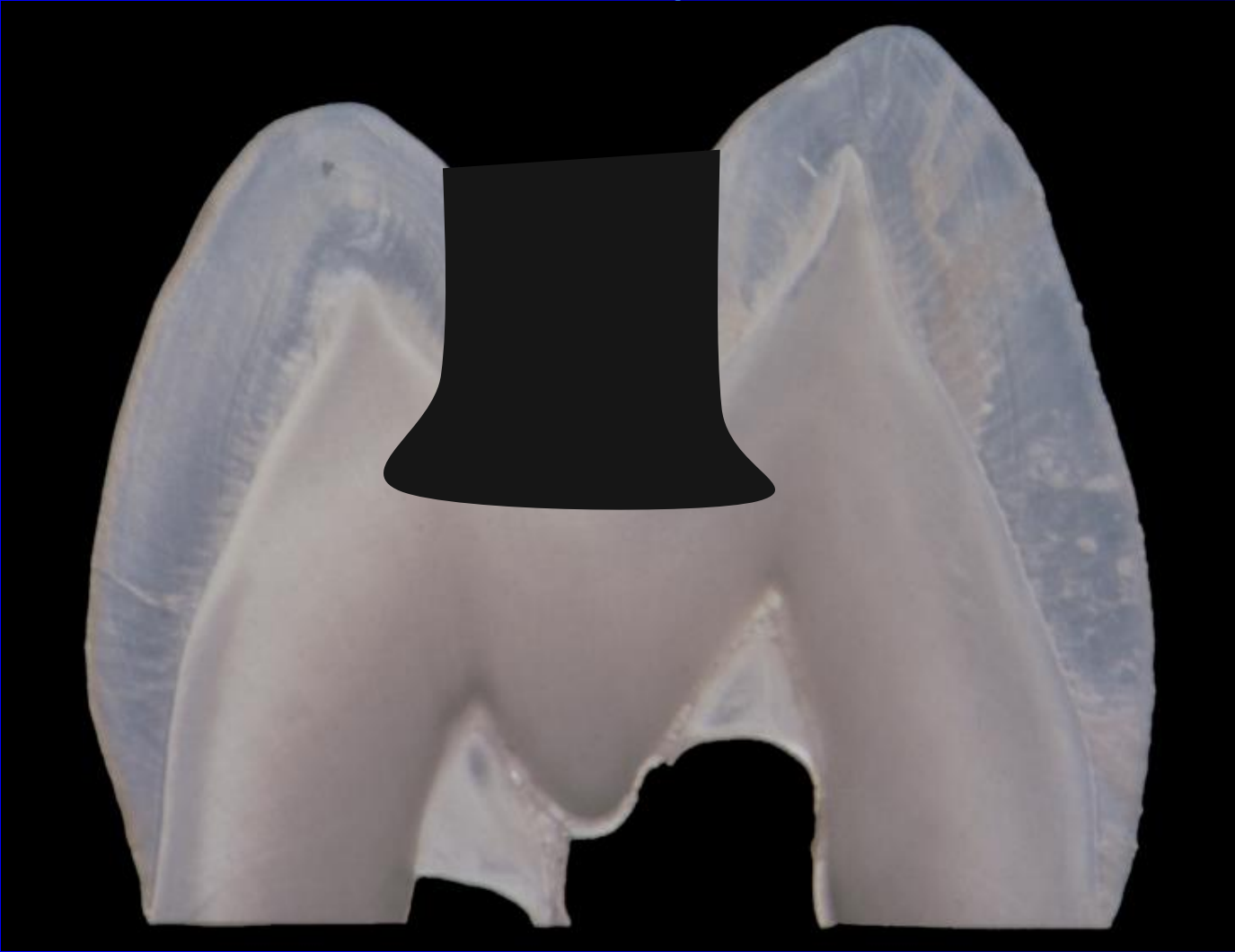# Retention principles

- Box in dentin





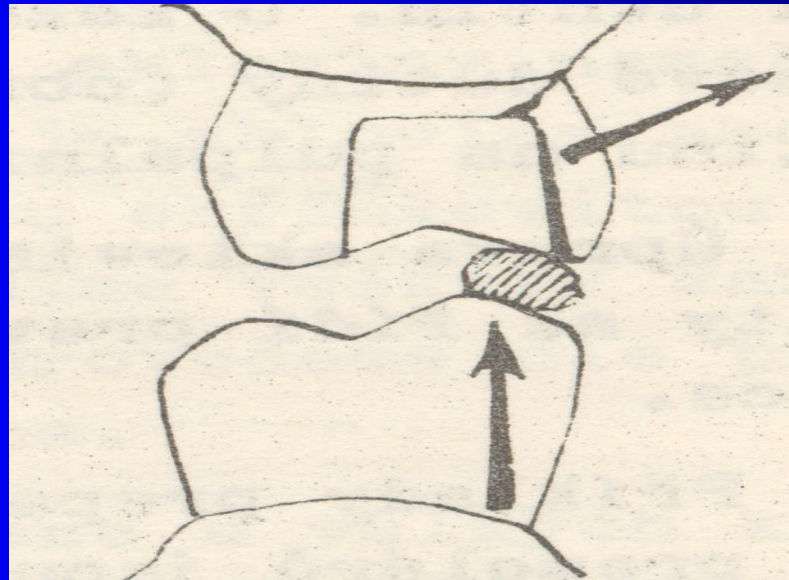
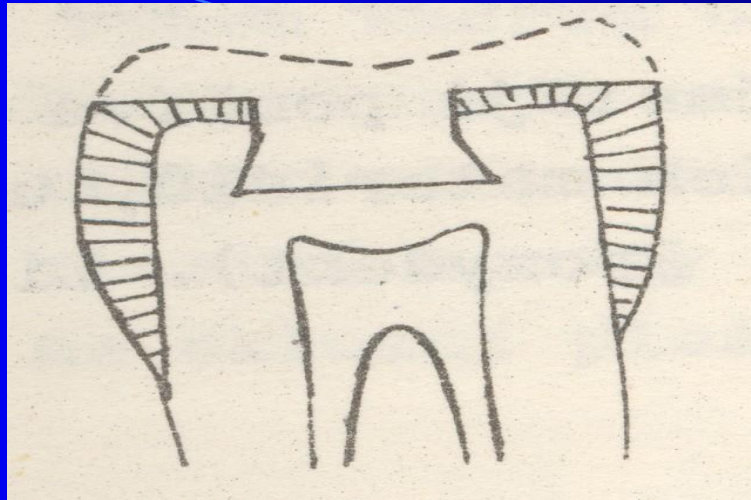


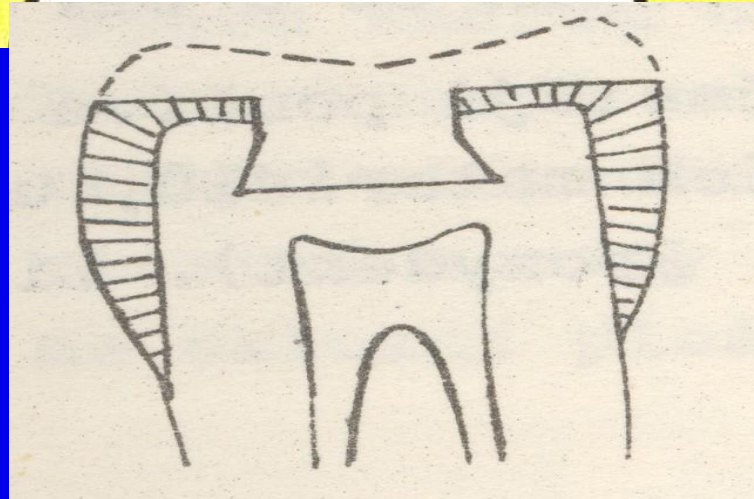
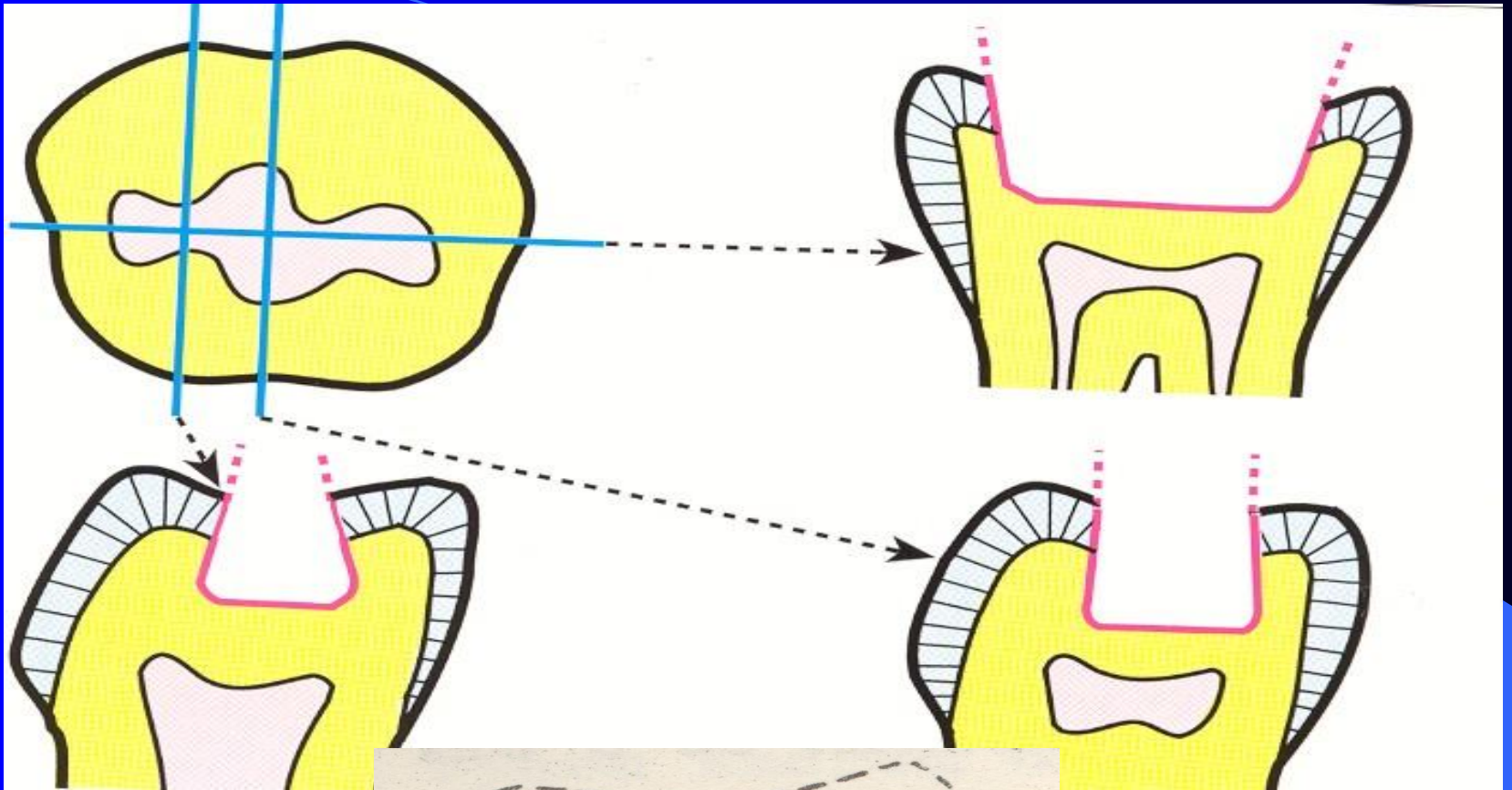




# Resistance principles

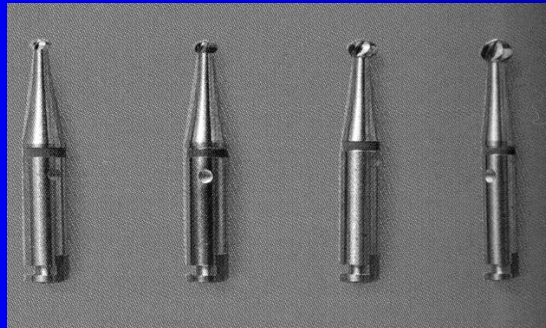
- Box – space for amalgam 1,5 – 2 mm
- Keep the facial and lingual margin extensions as minimal as possible between the central groove and the cusp tips.
- Extending the outline to include fissures, thereby placing the margins on relatively smooth sound tooth structure.
- Minimally extending into the marginal ridge without removing dentinal support.
- Never leave the enamel undermined
- All corners are round, the bottom smooth.



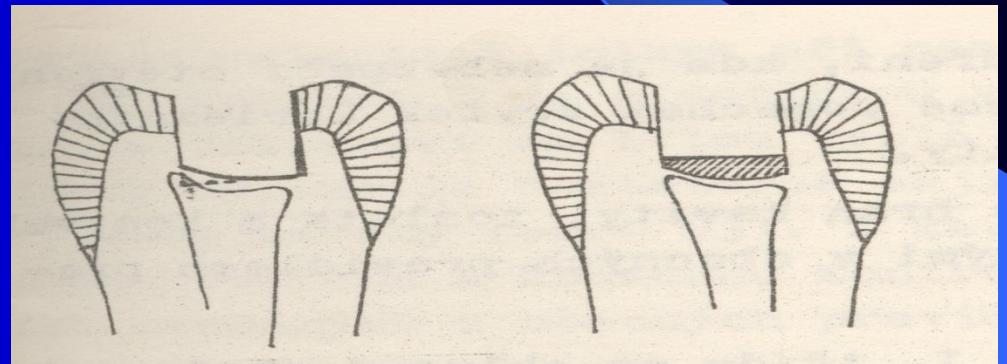
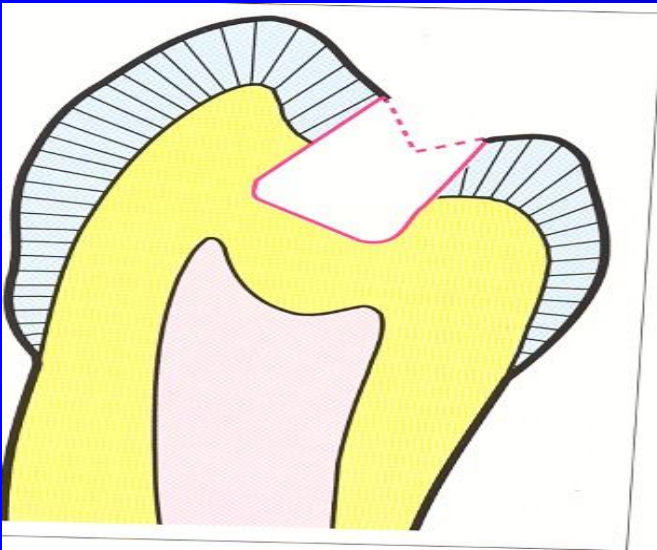


# Removal of carious, infected, dentin and remaining defective enamel.

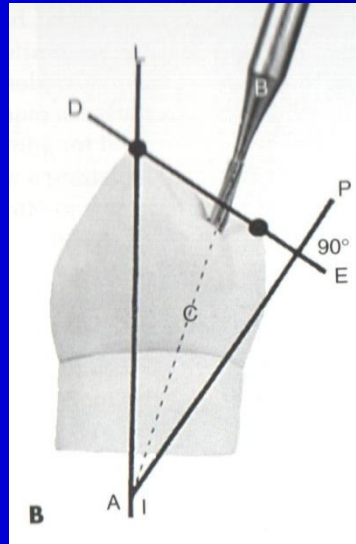
- Spoon excavator or a slowly revolving, round carbid bur of appropriate size.



# The pulpal wall and pulp chamber



# Correct direction of the bur

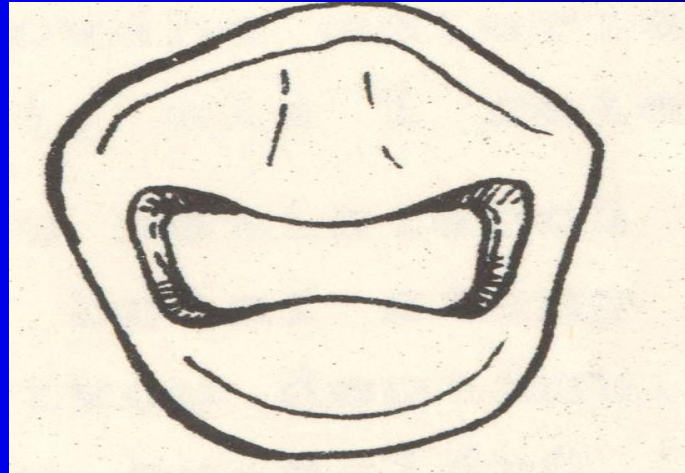


# Finishing and polishing

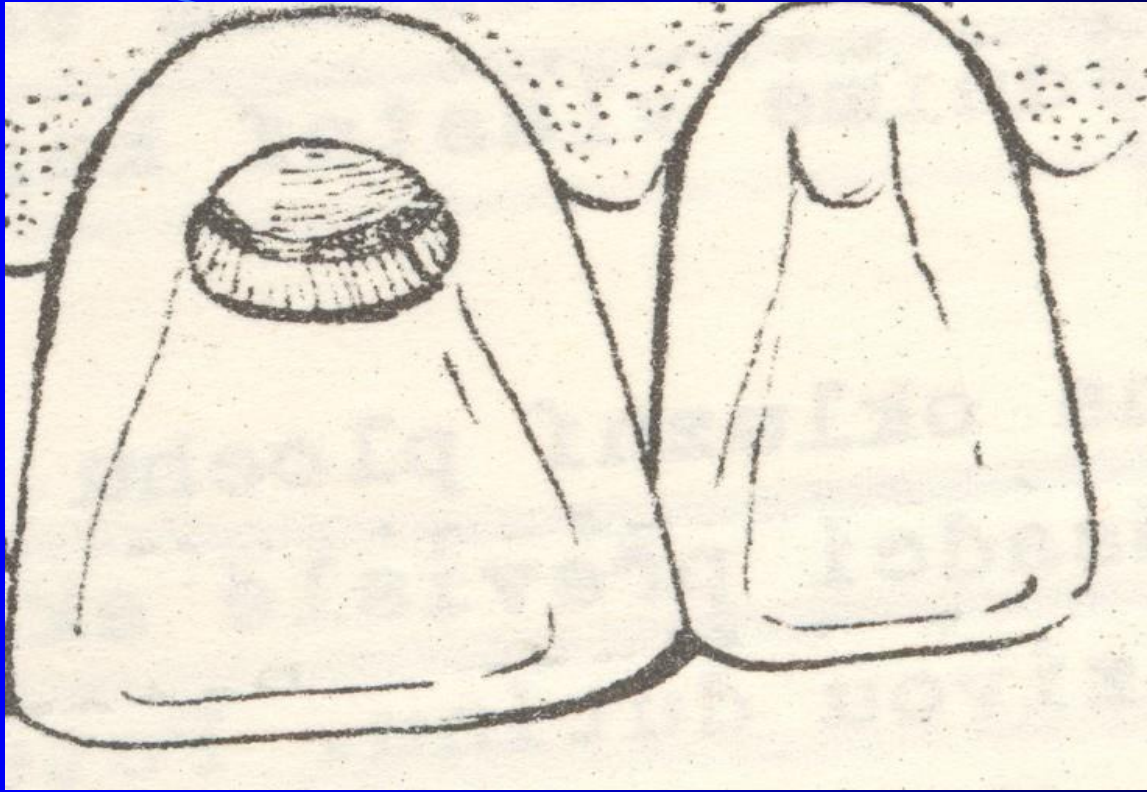
- Fine grit diamond bur.

# Preparation of borders and final check

Smoothen (red coted diamond)  
20.000 rpm.

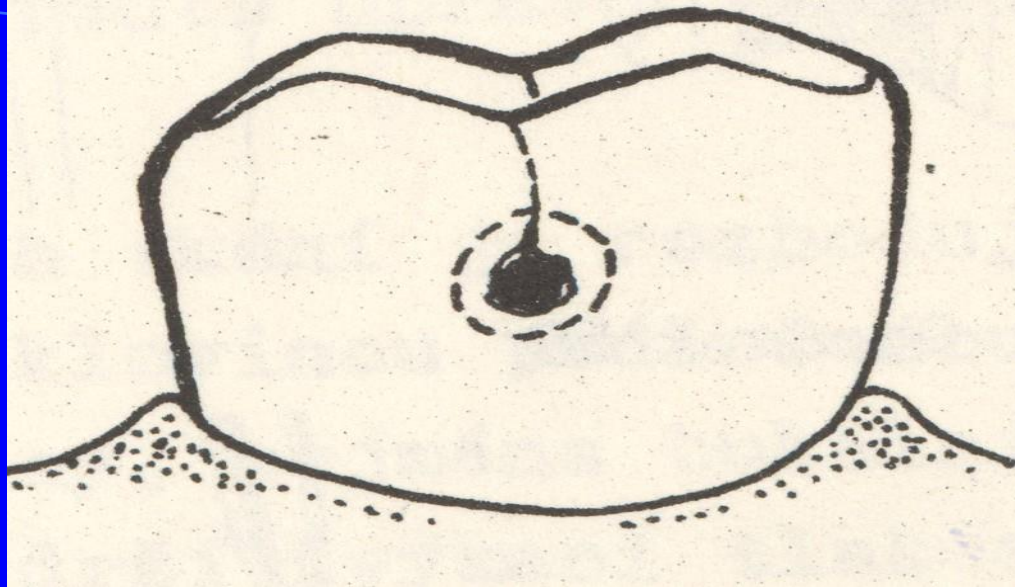





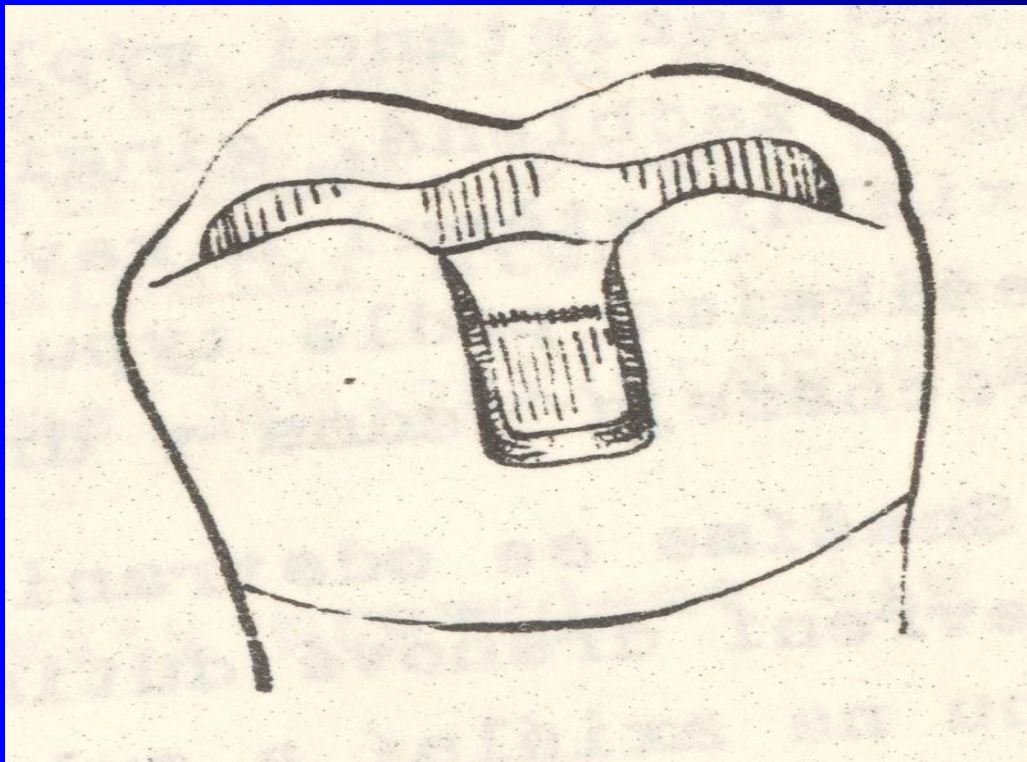

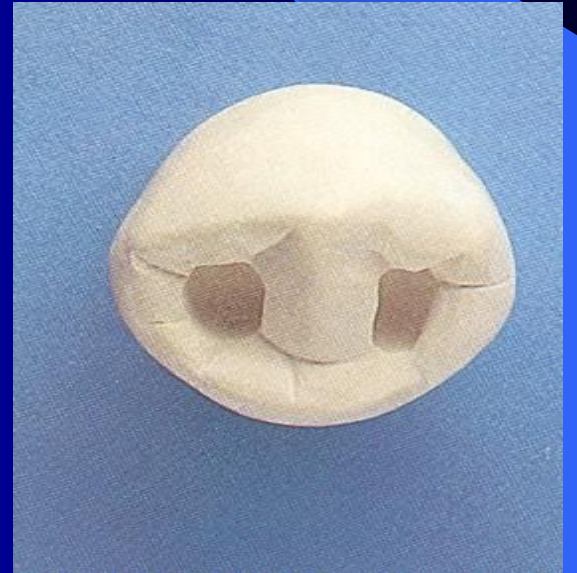
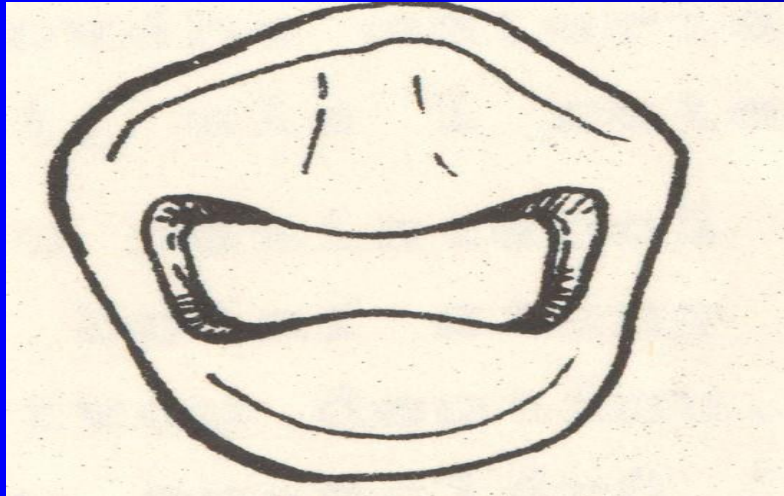
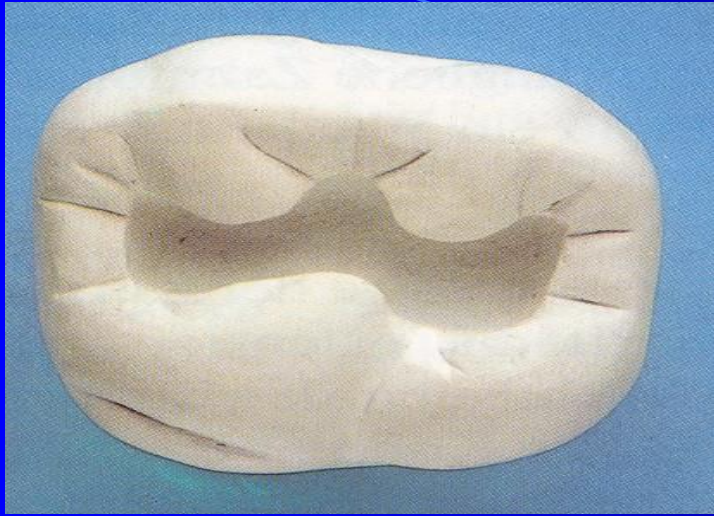F.Coecum

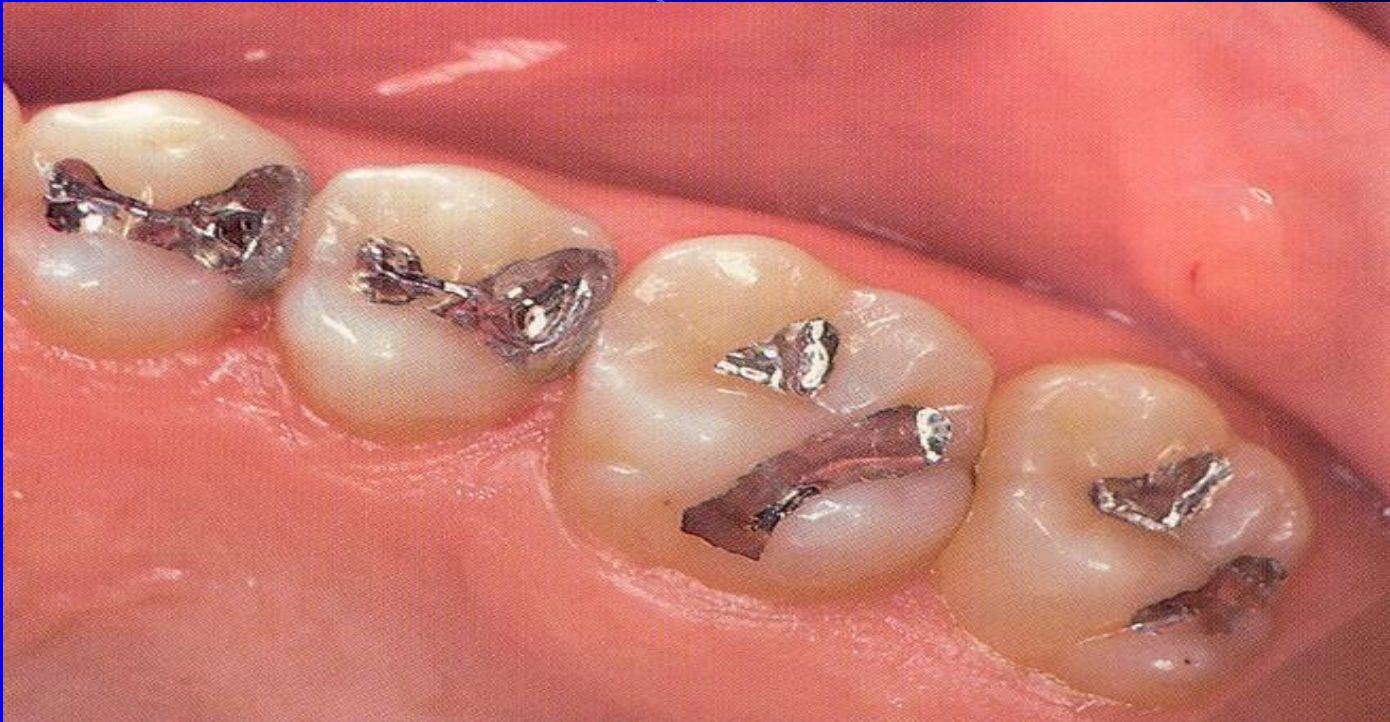Preparation is limited on carious lesion only  
undercuts



Combination of  
Cavity in f.coecum  
and occlusal cavity







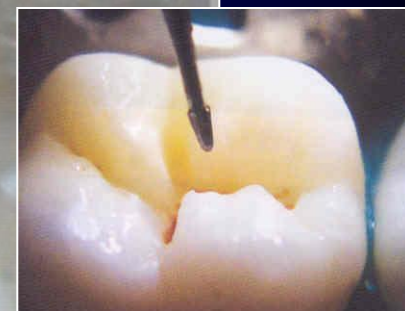
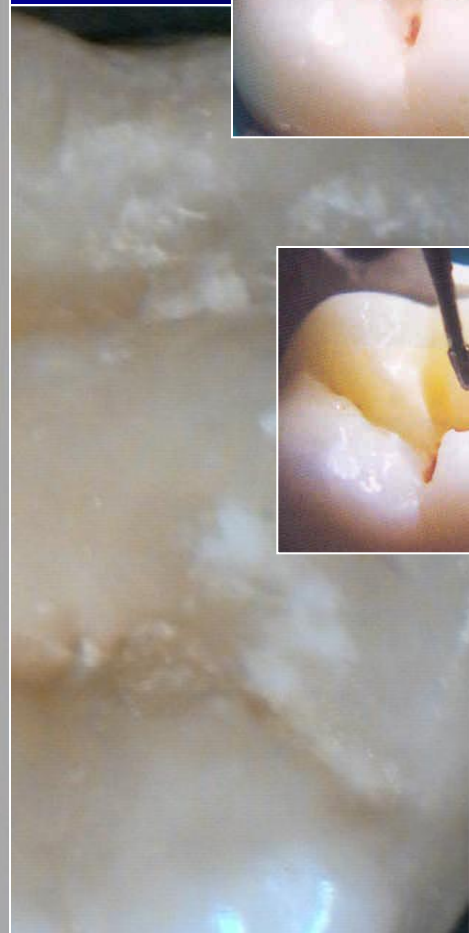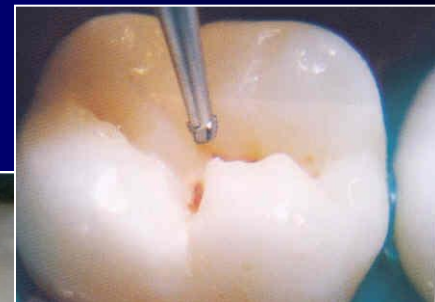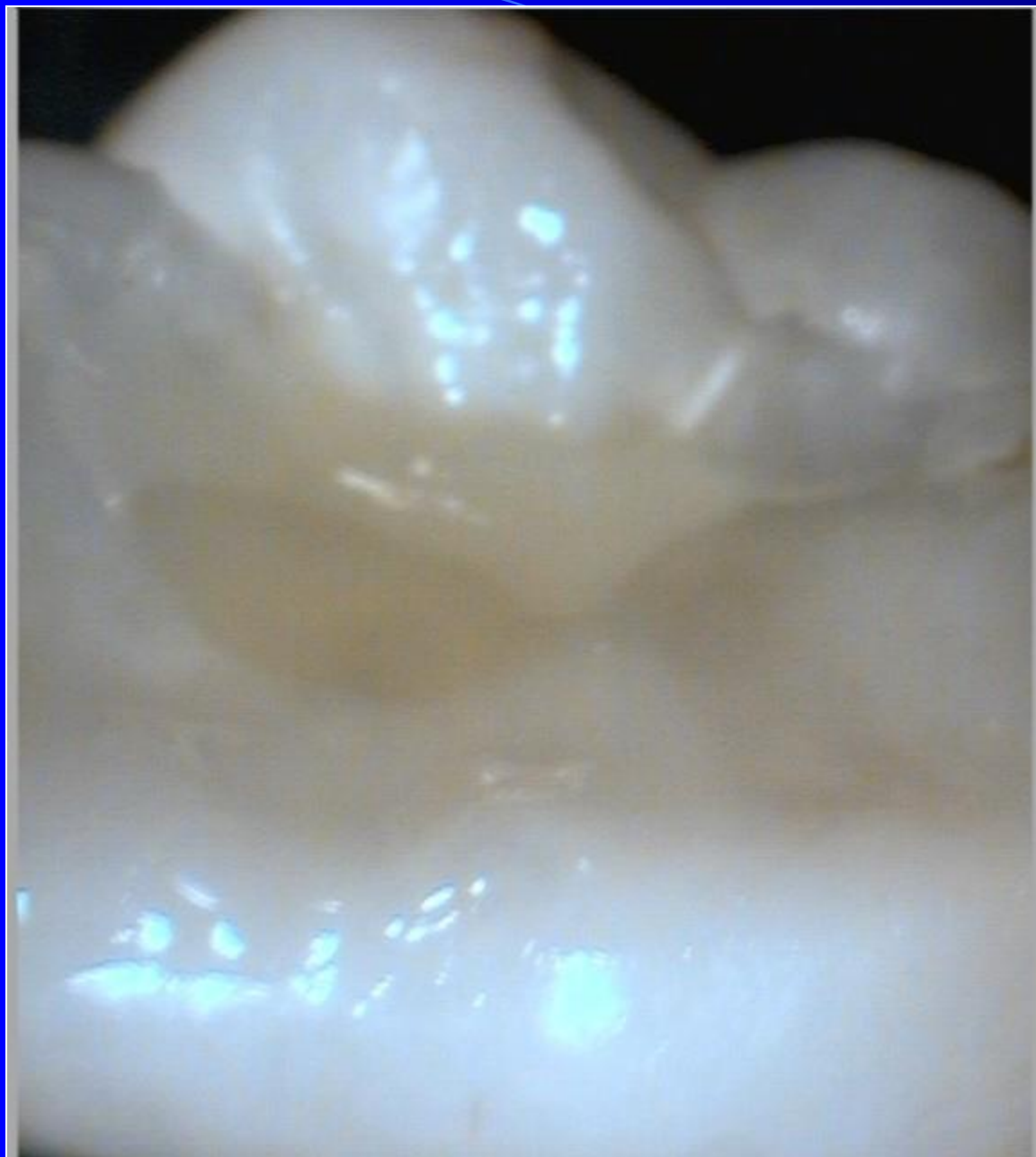
# Preparation for composit

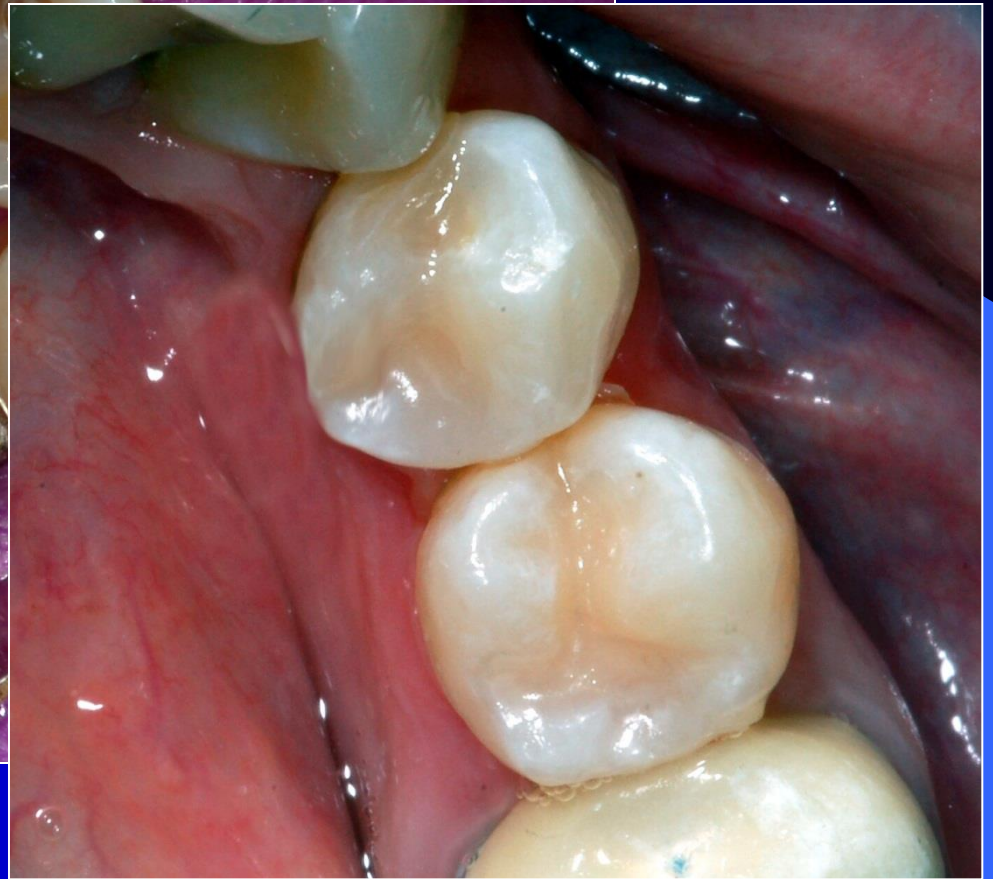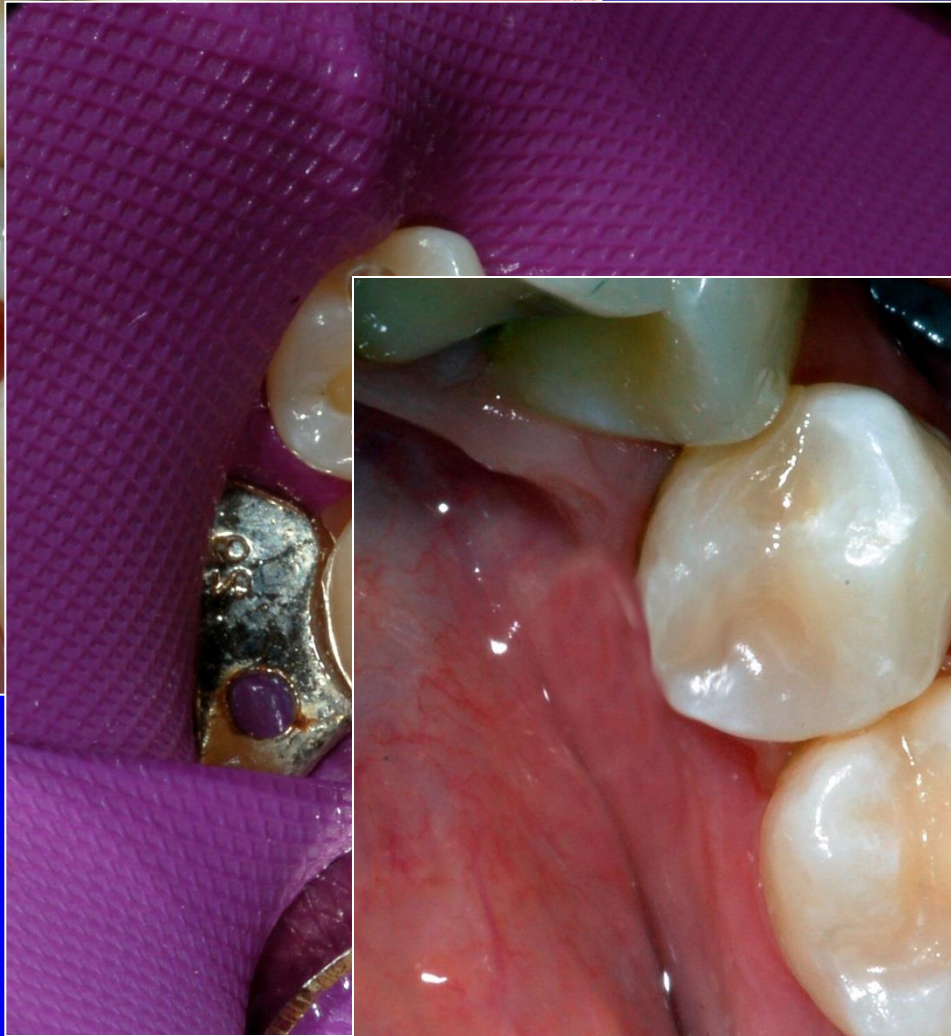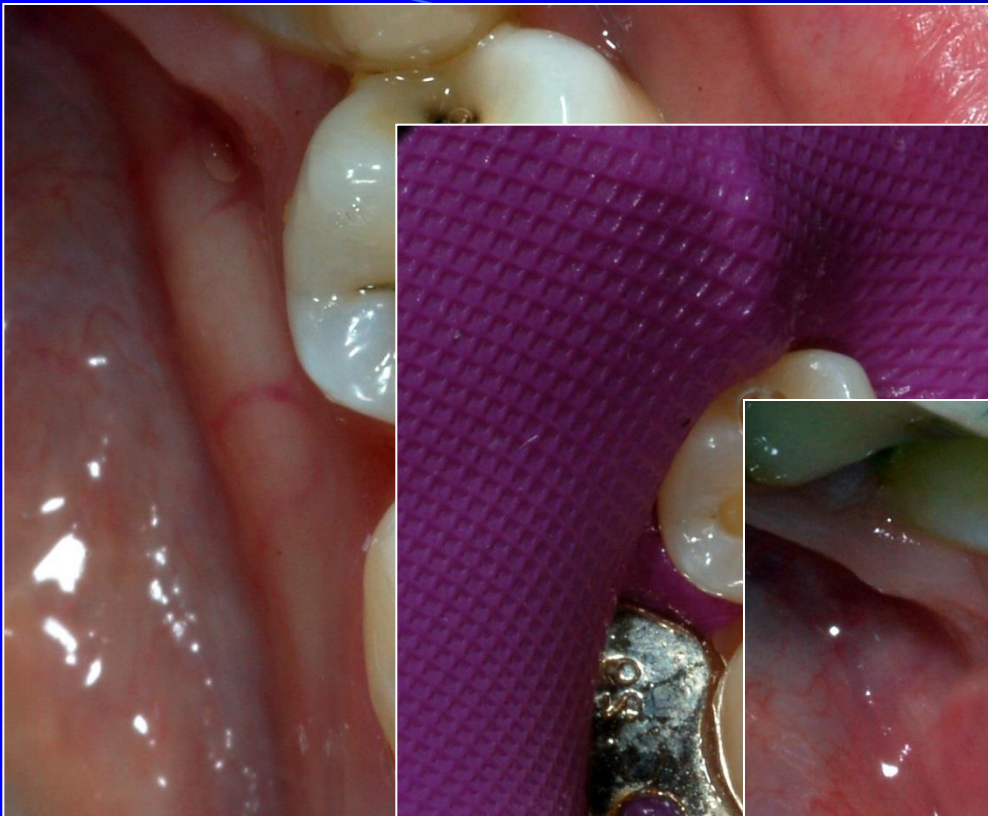Cavity is limited on the carious lesion

It has a form of deeper dish

No undercuts

More single cavities can be prepared





# Preparation for inlay

- Inlay is a rigid filling
- It is fabricated out of oral cavity in dental lab
- It is luted into the cavity using luting material -cement
- Preparation is different – the walls are divergent



